

# Immunohistochemical study of the proliferation index, oestrogen receptors and progesterone receptors A and B in leiomyomata and normal myometrium during the menstrual cycle and under gonadotrophin-releasing hormone agonist therapy

Michelle Nisolle, Stéphane Gillerot, Françoise Casanas-Roux, Jean Squifflet, Martine Berliere and Jacques Donnez<sup>1</sup>

Infertility Research Unit, Service de Gynécologie, Cliniques Universitaires St Luc, Université Catholique de Louvain, Avenue Hippocrate, 10, 1200 Bruxelles, Belgium

<sup>1</sup>To whom correspondence should be addressed

The cell proliferation-associated antigen Ki 67 and the immunohistochemical content of oestrogen receptors (ER), progesterone receptors AB (PRAB) and progesterone receptors B (PRB) were evaluated in leiomyomata and adjacent myometrium during the menstrual cycle and in leiomyomata under gonadotrophin-releasing hormone agonist (GnRHa) therapy. The proliferative status of muscular cells was measured by evaluating the percentage of nuclei staining positive for Ki 67 (proliferation index). Quantitative analysis (QH-score) was carried out using advanced stereographic computer technology to investigate ER, PRAB and PRB. Leiomyoma and myometrial biopsies were taken from 30 patients undergoing hysterectomy or myomectomy because of symptomatic leiomyomata (subgroup I). Leiomyoma biopsies were taken from 10 patients suffering from symptomatic submucosal leiomyomata, after 2 month GnRH therapy (subgroup II). During the secretory phase, the proliferation index (Ki 67) was found to be higher in leiomyomata than in myometrium, but the difference was not significant. Oestrogen receptor content was significantly higher in leiomyomata than in myometrium only during the proliferative phase of the cycle. PRAB and PRB content were found to be higher in leiomyomata than in adjacent myometrium with a statistically significant dominance of PRAB over PRB. Under GnRHa therapy, a dramatic decrease was observed in PRAB and B content as well as Ki 67 but ER content remained comparable with the results obtained during the menstrual cycle. The results suggest that leiomyomata may be under the influence of progesterone which may play a major role in their growth.

**Key words:** GnRHa/leiomyomata/proliferation index (Ki 67)/steroid receptors

## Introduction

Leiomyomata, which occur in 20–30% of women over 30 years of age, are the most common benign tumours of uterine smooth muscle cells. In the United States, they are the most common indication for hysterectomy due to menorrhagia or hypermenorrhoea (Wilcox *et al.*, 1994). Although the

mechanism of tumorigenesis is unknown, evidence suggests that leiomyomata are ovarian steroid-dependent (Buttram and Reiter, 1981; Vollenhoven *et al.*, 1990). Indeed, conditions that provoke increased ovarian steroid production (e.g. pregnancy and hormone replacement therapy) result in the rapid growth of leiomyomata.

On the other hand, conditions in which ovarian steroid concentrations are diminished [menopause and gonadotrophin-releasing hormone agonist (GnRHa) therapy] result in a decrease in the size of leiomyomata (Donnez *et al.*, 1989, 1990; Broeckmans, 1996; Gonzalez Barcena *et al.*, 1997). Medical management of fibroids with GnRHa was first described in 1983 (Filicori *et al.*, 1983) and is now approved. But because most leiomyomata return to near-pretreatment size within 4 months following cessation of GnRHa therapy and because of the adverse effects (bone loss with long-term treatment) (Devogelaer *et al.*, 1993), it should be considered as preoperative therapy to reduce tumour size rather than as a definitive alternative to surgery (Maheux *et al.*, 1985; Donnez *et al.*, 1989, 1990, 1993).

The traditional view holds that leiomyomata are only oestrogen dependent, but some experimental and clinical data suggest that progestins may be important for growth. This has led us to reconsider the role of progesterone in the understanding of leiomyoma growth and to reassess the traditional view.

Therefore, the aim of this study was to compare both myomata and adjacent myometrium in terms of proliferation and steroid receptor content throughout the menstrual cycle and during GnRHa therapy. The proliferation index (Ki 67) as well as the oestrogen receptor (ER), progesterone receptor AB (PRAB) and progesterone receptor B (PRB) content of leiomyomata and adjacent myometrium, were evaluated using immunohistochemical techniques.

## Materials and methods

### Patients

The study included 40 patients ranging in age from 29 to 50 years, diagnosed to have uterine leiomyomata requiring surgery.

In a first subgroup of 30 patients (group I), laparotomy was performed for either hysterectomy ( $n = 8$ ) or myomectomy ( $n = 22$ ). All were women with regular ovulatory cycles and none was given hormonal therapy for at least 3 months before surgery. In this study, GnRHa therapy was never administered before hysterectomy or myomectomy. During surgery, a biopsy was taken from one intramural myoma (usually the biggest one) and from normal-looking myometrium close to the myoma.

In 15 patients, biopsies were taken during the proliferative phase (days 1–14) and in 15 during the secretory phase (days 15–28). Accurate menstrual dating could be carried out according to the last

menstrual period and corroborated with appropriate histological dating of the endometrial biopsy according to previously published criteria (Noyes *et al.*, 1950).

In a second subgroup (group II), 10 patients suffering from symptomatic submucosal leiomyomata who wished to preserve their childbearing capacities were treated for 2 months with GnRHa (Zoladex®, 3.6 mg once per month; goserelin; Astra Zeneca, Macclesfield, Cheshire, UK). In this group, hysteroscopic myomectomy was performed using the technique described in a previous study (Donnez *et al.*, 1990) upon completion of the medical therapy, and a biopsy of the leiomyoma was taken during hysteroscopic surgery. No normal myometrium was removed during this type of procedure.

Biopsies were immediately placed in formaldehyde. A total of 70 biopsies were included in the histological study.

#### Measurement of the proliferation index

The proliferative status of muscular cells was measured by evaluating the percentage of nuclei staining positive for Ki 67 antibody at titre 1/100, giving the proliferation index (Gerdes *et al.*, 1984). The monoclonal antibody Ki 67 (Immunotech, Marseille, France) recognizes a nuclear antigen that is expressed in all stages of the cell cycle except G<sub>0</sub> (Gerdes *et al.*, 1983, 1984).

Tissue samples were fixed in 10% formaldehyde and embedded in paraffin. Ki 67 labelling was determined by immunoperoxidase techniques using the peroxidase–antiperoxidase (PAP) complex, which increases the reliability and sensitivity of detection to the level obtained with radioimmunoassay. Tissue sections 6 µm thick were mounted on Superfrost Plus slides and stained according to the immunocytochemical assay described by Immunotech (Clone MIB-1, Immunotech, Marseille, France). Labelling was developed with diaminobenzidine and hydrogen peroxide until nuclear brown staining was easily detectable. Positive and negative controls were carried out as previously described (Nisolle *et al.*, 1997). Resultant staining was evaluated by determination of the distribution of the stained nuclei within muscular cells. The tissue was examined on a blind basis by two observers.

The number of stained nuclei per 900–14 000 cells was counted using the ×40 objective of a light microscope (Zeiss, Oberkochen, Germany).

The  $\chi^2$  test and analysis of variance (ANOVA) were used for statistical analysis.

#### Oestrogen receptor localization

Oestrogen receptors were identified using a monoclonal antibody (mouse monoclonal antihuman ER 1D5) which recognizes ER $\alpha$  (Immunotech®, Marseille) (1/300 dilution). A negative control was prepared in each case and consisted of one section incubated with mouse immunoglobulin G (IgG) instead of mouse antireceptor antibody.

The immunostaining quantitative analysis was performed with a computerized microscope image processor. All samples were analysed field by field using the ×100 objective of an Axioskop light microscope through a CCD 72E camera (Dage: MTL, Michigan City, IN, USA). The number of fields of view analysed was 15–20, corresponding to an area of 0.1–0.147 mm<sup>2</sup> (one field ×100; 7330 mm<sup>2</sup>). The image features were displayed on a red-green-blue (RGB) monitor and stored for processing by the image analysis program we created and set on the Vidas 2.1 (Kontron Bildanalyse GmbH, Eching, Germany). In each case, positive and negative nuclei (mean: 114; range: 63–505) were selected on a blind basis and evaluated. The only selection criterion was the study of nuclei from longitudinal muscular fibres.

#### Progesterone receptor localization

Progesterone receptors were identified using a polyclonal antibody which does not distinguish between PRA and PRB (Santa Cruz®: Santa Cruz Biotechnology, Santa Cruz, CA, USA) (1/200 dilution). Since an antibody specific to PRA is not available, all immunohistochemical analysis of PRA is by subtractive deduction. Thus, it is proposed that PRA is the subtype responsible for positive immunoreactivity when the PRB subtype is not specifically detected, as published previously (Wang *et al.*, 1998). Progesterone receptor B was specifically identified using a polyclonal antibody with the same dilution ratio (Dako®, Dako, Glostrup, Denmark). In each case, positive and negative nuclei (mean: 100; range: 50–215) were evaluated.

#### Evaluation of steroid receptor content

The distribution of specific staining was thus evaluated according to an optical density scale using the values of all the positive nuclei of a given receptor in longitudinal myometrial fibres. The quantitative H-score (QH score) was calculated as follows: QH score =  $\sum P_i$ , where  $i$  is the optical density degree from 0 (negative nuclei) to 5 (high optical density) and P the percentage of stained cells for each given  $i$  (from 0 to 100%). This method is a modification of the semi-quantitative H-score analysis described (McCarty *et al.*, 1985). This modification was earlier published by our group (Nisolle *et al.*, 1994).

## Results

### Proliferative activity

Figure 1 illustrates Ki 67 immunostaining of muscular fibre nuclei of a leiomyoma and normal myometrium.

Figure 2 shows the results of the proliferation index in normal myometrium and intramural leiomyomata during the menstrual cycle and in submucosal myomata after GnRHa therapy.

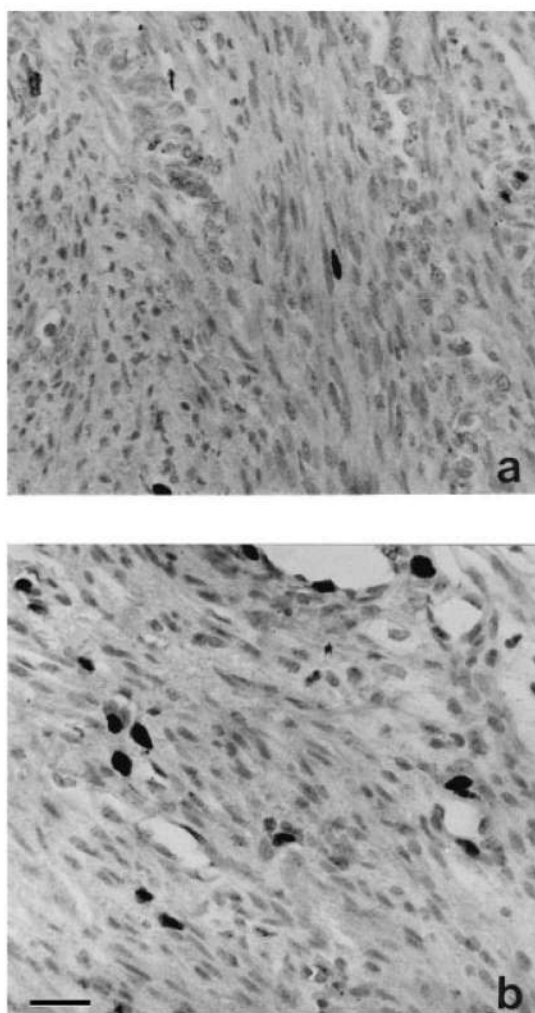
In myometrium, the proliferation index was 0.98% (range 0–2.9) during the proliferative phase and 0.43% (0–2.4) during the secretory phase, but this cyclic change was not statistically significant.

In leiomyomata, there was an increase in the proliferation index during the secretory phase but it was not statistically significant. The proliferation index was 1.10% (range 0–4.9) during the proliferative phase and 1.72% (range 0–10.5) during the secretory phase.

When the proliferation index of normal myometrium was compared with that of leiomyomata, no differences were observed during the proliferative phase. During the secretory phase, the proliferation index was found to be higher in leiomyomata than in myometrium, but this was not statistically significant. In subgroup II, after 2 months of GnRHa therapy, the proliferation index of leiomyomata was 0.52% (range 0–3.0). This value was significantly lower ( $P < 0.05$ ) than the values observed during both phases of the menstrual cycle.

### Oestrogen receptor quantitative H-score

Figure 3 shows the ER content of normal myometrium and intramural leiomyomata during the menstrual cycle and of submucosal myomata after GnRHa therapy. During the proliferative phase, the mean ER QH-score was  $23 \pm 10$  in myometrium and  $66 \pm 12$  in leiomyomata. During the secretory phase, the mean ER QH-score was  $24 \pm 10$  in myometrium



**Figure 1.** Ki 67 immunostaining of muscular fibre nuclei of normal myometrium (a) and a leiomyoma (b): positive nuclei are represented by nuclear black staining which are easily detectable. Scale bars = 100  $\mu$ m.

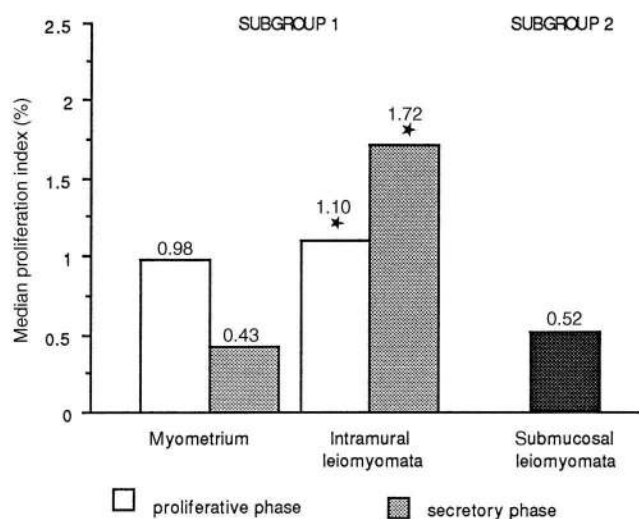
and  $40 \pm 15$  in leiomyomata. The difference observed between the QH-scores of leiomyomata and myometrium was significant ( $P < 0.01$ ) during the proliferative phase but not during the secretory phase. In subgroup II, the QH-score was  $79 \pm 16$ , not different from the QH-score obtained in leiomyomata during both phases of the menstrual cycle.

**PRAB and PRB quantitative H-scores**

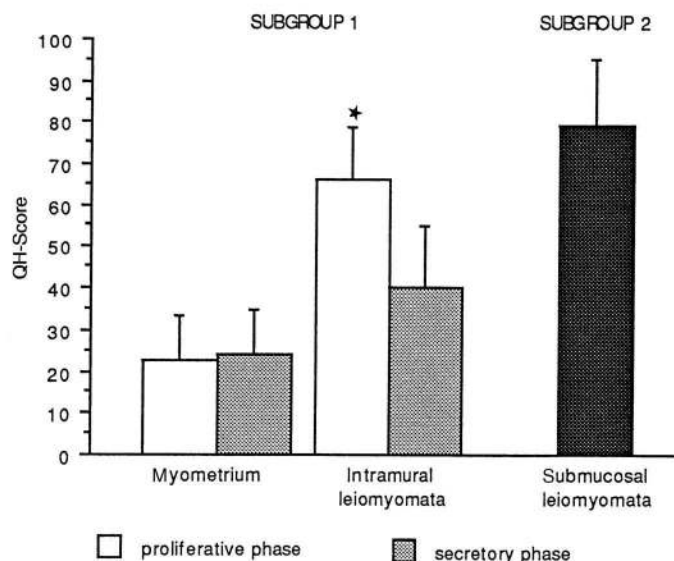
Figure 4 shows the PRAB and PRB content of normal myometrium and intramural leiomyomata during the menstrual cycle and of submucosal myomata after GnRH agonist therapy.

**Progesterone receptors A**

In myometrium, the mean PRAB QH-score was  $255.7 \pm 16.8$  during the proliferative phase and  $233 \pm 21$  during the secretory phase. In leiomyomata, the mean PRAB QH-score was  $245 \pm 26$  during the proliferative phase and  $262 \pm 25$  during the secretory phase. No significant changes in PRAB content were observed during the menstrual cycle. In subgroup II, the mean PRAB QH-score was  $98 \pm 24$ , significantly lower ( $P < 0.0002$ ) than that observed in intramural leiomyomata during both phases of the normal menstrual cycle.



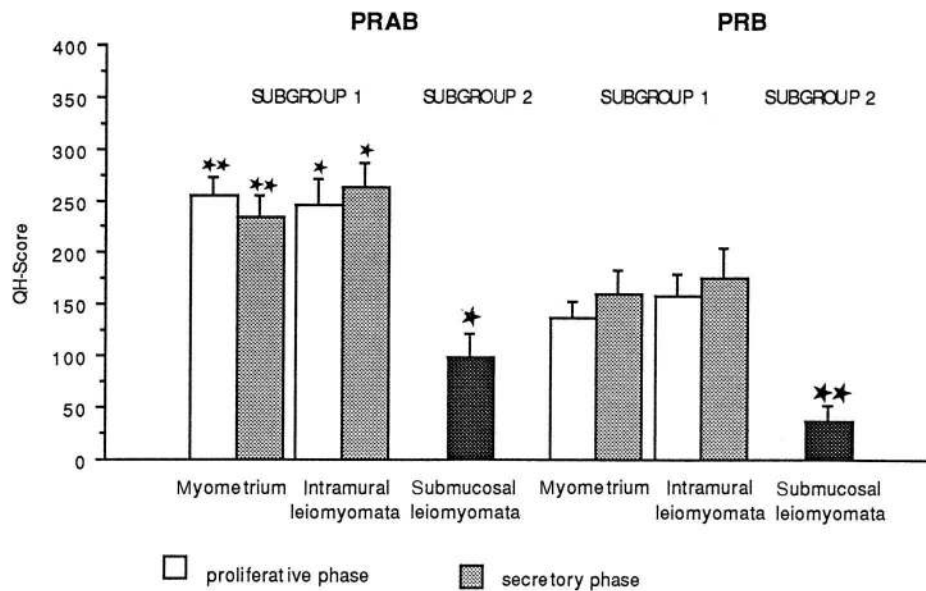
**Figure 2.** Median proliferation index (%) in normal myometrium ( $n = 30$ ) and leiomyomata ( $n = 30$ ) during both phases of the menstrual cycle (each  $n = 15$ ) and in submucosal myomata ( $n = 10$ ) after gonadotrophin-releasing hormone agonist (GnRHa) therapy. \*Significantly higher proliferation index in leiomyomata during both phases of the menstrual cycle than under GnRHa therapy ( $P < 0.05$ ). Median values are shown above each bar.



**Figure 3.** Values are mean  $\pm$  SE oestrogen receptor (ER) [quantitative H-score (QH-score)] of normal myometrium and intramural leiomyomata during both phases of the menstrual cycle and submucosal myomata after gonadotrophin-releasing hormone agonist (GnRHa) therapy. For definition of QH-score, see text. \*Significantly higher ER QH-score in leiomyomata than in myometrium during the same phase ( $P < 0.01$ ).

**Progesterone receptors B**

In myometrium, the mean PRB QH-score was  $137 \pm 16$  during the proliferative phase and  $161 \pm 23$  during the secretory phase. In leiomyomata, the PRB QH-score was  $158 \pm 22$  during the proliferative phase and  $176 \pm 29$  during the secretory phase. No significant changes were observed during the menstrual cycle with regard to PRB content in either tissue. In subgroup II, the mean PRB QH score was  $36 \pm 15$ , significantly lower [ $P < 0.0006$  (proliferative phase);



**Figure 4.** Values are mean  $\pm$  SE. Progesterone receptor (PR) AB and PRB content (QH-score) of intramural leiomyomata and normal myometrium during both phases of the menstrual cycle and submucosal myomata after gonadotrophin-releasing hormone agonist (GnRHa) therapy. \* Significantly higher than PRB content in leiomyomata during both phases of the menstrual cycle ( $P < 0.03$ ). \*\* Significantly higher than PRB content in myometrium during the proliferative phase ( $P < 0.0001$ ) and the secretory phase ( $P < 0.02$ ). ★ The PRAB QH-score of submucosal myomata was significantly lower than that observed in intramural leiomyomata during the menstrual cycle (both phases) ( $P < 0.0002$ ). ★★ The PRB QH-score of submucosal myomata was significantly lower than that observed in intramural leiomyomata during the menstrual cycle (both phases) [ $P < 0.0006$  (proliferative phase) and  $P < 0.002$  (secretory phase)].

$P < 0.002$  (secretory phase)] than that observed in leiomyomata throughout both phases of the menstrual cycle.

#### Comparison between PRAB and PRB in leiomyomata and myometrium

No changes were observed in PRAB and PRB content throughout the menstrual cycle in leiomyomata or myometrium. Progesterone receptor AB content was significantly higher than PRB content in leiomyomata during both the proliferative and secretory phases ( $P < 0.03$ ) and also in myometrium during both the proliferative phase ( $P < 0.0001$ ) and the secretory phase ( $P < 0.02$ ). The QH-scores were systematically higher for both PRAB and PRB in the nuclei of leiomyoma cells than myometrial muscular cells during the menstrual cycle, but the differences were not statistically significant.

#### Discussion

Uterine leiomyomata are defined as oestrogen-dependent benign tumours and, traditionally, medication used to provoke their shrinkage has been based on inducing hypo-oestrogenism. The only drug that has been shown to be effective in the reduction of leiomyoma size is GnRHa. Indeed, the first report demonstrating the efficacy of GnRHa therapy was published in 1985 (Maheux *et al.*, 1985). The efficacy of GnRHa has been demonstrated in several studies (Donnez *et al.*, 1989, 1990, 1993), particularly in the case of submucosal leiomyomata, where a reduction of 35% in size was observed after 2 months therapy. On the other hand, for a long time now, progesterone has been used as a medical treatment for symptomatic leiomyomata but with poor results. Moreover, no randomized, prospective studies have ever demonstrated significant benefits of progestogens alone.

Several studies have strongly suggested that myoma growth can be related to progestogens. Back in 1985, it was shown (Tiltman, 1985) that women treated with progestogens before hysterectomy demonstrated significantly higher mitotic activity in their fibroids than women untreated or pretreated with a combined oestrogen–progestogen preparation. When GnRHa and medroxyprogesterone acetate (MPA) are co-administered, the expected regression in leiomyoma size usually observed with GnRHa alone is not achieved, as reported (Friedman *et al.*, 1988). This was the first report to show a direct effect of progesterone on leiomyoma growth, but the mechanism by which MPA inhibits leuprolide-induced shrinkage was not known. The antiprogestogen RU 486 is just as effective as leuprolide acetate in decreasing both uterine volume and blood flow (Reinsch *et al.*, 1994). Others (Harrisson-Woolrych *et al.*, 1995) reported a dramatic increase in leiomyoma size in a menopausal woman taking a high dose of progesterone (megestrol acetate, 160 mg daily) and a good regression in size when the medication was stopped.

Experimental data support the clinical data. Indeed, progestins have been reported to increase uterine weight in rodents. High doses of progesterone combined with low doses of oestriol significantly increased uterine weight in ovariectomized rats when compared with low-dose oestriol treatment alone (Edgren *et al.*, 1961). In castrated rabbits, a 19-nortestosterone progestin caused a significant increase in uterine weight when compared to treatment with vehicle solution (Elton and Edgren, 1958). Oestrogen and progesterone receptors are found within myometrium and fibroids (Wilson *et al.*, 1980) and tissue cultures of both show significant growth when supplemented with progesterone.

All this led us to reconsideration of the role of progesterone

in leiomyoma growth and reassessment of the traditional view, which holds that leiomyomata are only oestrogen dependent. It was suggested that progesterone might be an important factor in the growth of leiomyomata (Smith, 1993) and the use of an antiprogestin has been proposed as a treatment for leiomyomata (Murphy *et al.*, 1993; Viville *et al.*, 1997).

In this study, leiomyomata were found to contain an increased number of cycling (Ki 67 immunoreactive) cells when compared with myometrium throughout the menstrual cycle. Moreover, the proliferative activity in leiomyomata was greater during the secretory phase, suggesting, as have other reports (Kawagushi *et al.*, 1991; Vu *et al.*, 1998), that progesterone plays a role in the growth of leiomyomata. After GnRHa therapy, a significant decrease in proliferative activity compared to untreated leiomyomata was observed, implicating oestradiol in leiomyoma growth too. Recently, it was suggested (Vi *et al.*, 1998) that the decrease in the number of cycling cells in GnRHa-pretreated leiomyomata plays a key role in myoma shrinkage. In that study, apoptosis was not observed, suggesting that the decrease in growth is mediated through a decrease in cellular proliferation. The current study confirms their hypothesis. According to the findings of in-vitro studies (Kawagushi *et al.*, 1985) and this study, it seems that the proliferative activity of leiomyomata is under the dual control of both oestradiol and progesterone.

In the present study, both oestrogen and progesterone receptors (ER and PR) were identified in leiomyomata and in myometrium. Leiomyomata were found to contain more ER than normal myometrium during both phases of the menstrual cycle. This higher ER content found in leiomyomata is in accordance with the results of the literature (Otsuk *et al.*, 1989; Circkel *et al.*, 1994; Richards and Tiltman, 1996; Lessl *et al.*, 1987) and explains why they were traditionally viewed as oestrogen-dependent tumours. Throughout the cycle, there was a decrease in the ER content of myometrium and leiomyomata. Since, in the present study, only ER $\alpha$  was detected immunohistochemically, it is suggested that a correlation exists between ER $\alpha$  and the proliferative activity. Although the respective roles of ER $\alpha$  and ER $\beta$  remain unclear, it has recently been suggested (Matsuzaki *et al.*, 1999) that oestrogenic effects occur predominantly through ER $\alpha$  and ER $\beta$  may play a role in the modulation of oestrogenic action.

On the contrary, in patients treated with GnRHa, a similar ER content was observed to that seen in untreated leiomyomata during the proliferative phase. A recent report (Englund *et al.*, 1998) observed that during GnRHa treatment, the ER amounts in leiomyomata were similar to those observed in the proliferative phase but significantly higher than those found in the secretory phase. The results of this study could be interpreted as showing a loss of sensitivity to oestrogen suppression (an absence, in leiomyomata, of down-regulation of ER despite the reduced oestrogen concentrations observed after 2 months of GnRHa therapy). It has been shown (Circkel *et al.*, 1994) that the greatest myoma shrinkage was associated with the highest ER content and the poorest reduction did not show any positive staining for ER at all. This association between myoma shrinkage and the ER status of the myoma explains the wide variation seen in myoma shrinkage.

By contrast, the results on the PR content of leiomyomata are more subject to discussion. In this study, PR persisted in both leiomyomata and adjacent myometrium during the secretory phase, as already observed (Lessey *et al.*, 1988). This persistence of PR during the secretory phase in leiomyomata and myometrium could suggest that the regulation of PR is different from that observed in endometrial glandular epithelium. There is also growing evidence that PR are not down-regulated in a variety of situations in which sustained progesterone exposure may be associated with continued responsiveness to progesterone. This demonstrates that PR persist in cells that maintain progesterone responsiveness (Clarcke and Sutherland, 1990). Another hypothesis is that PR are synthesized but their activity may be tissue-dependent. For instance, the persistence of PR in endometrial stromal cells and in a perivascular location during the secretory phase supports the role of progestin effects on spiral artery growth at this time (Wang *et al.*, 1998).

Two different types of PR could be distinguished: one oestrogen-induced and one independent of the influence of peripheral oestrogens. This interrelation was investigated by analysing the PR isoforms. Progesterone receptors belong to the superfamily of nuclear receptors. In humans, most authors favour the existence of two original forms of PR: form B (100–120 kDa) and form A (94 kDa). The transcription of the two forms is controlled by two different promoters that are both oestrogen-induced (Gronemeyer *et al.*, 1991). Under certain circumstances, PRA can repress PRB-mediated transcription by a mechanism that requires ligand binding but not DNA binding (Savouret *et al.*, 1994). Hence, PRA can have a dual role as a transcription activator and repressor. The unique properties of PRA suggest a molecular rationale for the existence of two progesterone receptor isoforms and provide a mechanism by which a single hormone promotes different responses, but the exact role of each form remains unclear (Vegeto *et al.*, 1993; Pfeifer and Strauss, 1996). Therefore, it is very important to establish the quantities of both forms (PRA and B) in leiomyomata and myometrium for a better understanding of leiomyoma growth and for future medical treatments.

In 1997, it was shown for the first time (Viville *et al.*, 1997) that both forms of progesterone receptors (PRA and PRB) were present in leiomyomata, with higher concentrations of PRA and B in leiomyomata than in normal myometrium and with a constant dominance of PRA over PRB. As there was no difference between the concentrations of mRNA encoding PRA and PRB, they suggested post-translational control of progesterone receptors.

An immunohistochemical analysis of antibodies that recognize both progesterone receptor subtypes A and B (PRAB), and antibodies that recognize specifically subtype B (PRB) has been conducted. Indeed, an antibody specific to PRA is not available. The advantage of immunohistochemistry is maintaining the tissue architecture while allowing an assessment of the cellular distribution of receptors (Nisolle *et al.*, 1994). The intensity of stained nuclei in leiomyomata and normal myometrium was determined by an advanced computer-

ized stereographic technology using image analysis (Nisolle *et al.*, 1994).

In all cases in the present study, the PRAB and PRB content were found to be higher in leiomyomata than in normal myometrium but considerable variation was observed between individual cases. This variation shows the importance of comparing tissues (leiomyomata and myometrium) from the same patient. Similar results were observed when Western blotting analysis and quantitative analysis of mRNA were used (Brandon *et al.*, 1993; Viville *et al.*, 1997). Progesterone receptor immunoreactivity was significantly reduced in leiomyomata after GnRHa administration compared with untreated tissues.

Three hypotheses have been proposed to explain the effect of progesterone on leiomyomata. Firstly, leiomyomata could escape oestrogen regulation that is present in normal tissue containing progesterone receptors. Secondly, leiomyomata may be more sensitive to oestrogen, leading to permanently high concentrations of oestradiol which could provoke a high PR content. Thirdly, increased expression of PR in leiomyomata could be the consequence of overexpression of functional ER, that results in increased organ sensitivity to oestradiol (Brandon *et al.*, 1995). In conclusion, the high proliferation index and the high PRAB and PRB content of leiomyomata during the secretory phase suggests that progesterone may play a role in myoma growth and that there is a need for prospective studies on the use of an antiprogesterin as a treatment for leiomyomata.

## References

- Brandon, D., Bethea, C., Strawn, E. *et al.* (1993) Progesterone receptor messenger ribonucleic acid and protein are overexpressed in human uterine leiomyomas. *Am. J. Obstet. Gynecol.*, **169**, 78–85.
- Brandon, D., Erickson, T., Keenan, E. *et al.* (1995) Estrogen receptor gene expression in human uterine leiomyomata. *J. Clin. Endocrinol. Metabol.*, **80**, 1876–1881.
- Broeckmans, F.J. (1996) GnRH agonist and uterine leiomyomas. *Hum. Reprod.*, **11**, 3–25.
- Buttram, V.C. and Reiter, R.C. (1981) Uterine leiomyomata: etiology, symptomatology and management. *Fertil. Steril.*, **4**, 443–445.
- Cirekel, U., Ochs, H., Roehl, A. *et al.* (1994) Estrogen and progesterone receptor content of enucleated uterine myomata after luteinizing hormone-releasing hormone. *Acta Obstet. Gynecol. Scand.*, **73**, 328–332.
- Clarcke, C.L. and Sutherland, R. (1990) Progesterin regulation of cellular proliferation. *Endocrine Rev.*, **11**, 266–301.
- Devogelaer, J.P., Nagant de Deuxchaisne, C. and Donnez, J. (1993) Endometriosis. *Lancet*, **341**, 312–313.
- Donnez, J., Schrurs, B., Gillerot, S. *et al.* (1989) Treatment of uterine fibroids with implants of gonadotropin-releasing hormone agonist: assessment by hystero-graphy. *Fertil. Steril.*, **51**, 947–950.
- Donnez, J., Gillerot, S., Bourgonjon, D. *et al.* (1990) Neodymium: YAG laser hysteroscopy in large submucous fibroids. *Fertil. Steril.*, **54**, 999–1003.
- Donnez, J., Nisolle, M., Gillerot, S. *et al.* (1993) Hystero-graphic surgery with the Nd YAG laser: a review. *Gynaecol. Endosc.*, **2**, 121–129.
- Edgren, R.A., Elton, R.L. and Calhoun, D.W. (1961) Studies on the interactions of estril and progesterone. *J. Reprod. Fertil.*, **2**, 98.
- Elton, R. L. and Edgren, R. (1958) Biological actions of 17-(2-methylallyl)-19-19-nortestosterone, an orally active progestational agent. *Endocrinology*, **63**, 464.
- Englund, K., Blanck, A., Gustavsson, I. *et al.* (1998) Sex steroid receptors in human myometrium and fibroids: changes during the menstrual cycle and gonadotropin-releasing hormone treatment. *J. Clin. Endocrinol. Metab.*, **83**, 4092–4096.
- Filicori, M., Hall, D.A., Loughlin, J.S. *et al.* (1983). A conservative approach to the management of uterine leiomyoma: pituitary desensitization by a luteinizing hormone-releasing hormone analogue. *Am. J. Obstet. Gynecol.*, **147**, 726–727.
- Friedman, A., Barbieri, R., Doubilet, P. *et al.* (1988) A randomized, double-blind trial of a gonadotropin releasing-hormone agonist (leuprolide) with or without medroxyprogesterone acetate in the treatment of leiomyomata uteri. *Fertil. Steril.*, **49**, 404–409.
- Gerdes, J., Schwab, U., Lemke, H. *et al.* (1983) Production of a mouse monoclonal antibody reactive with a human nuclear antigen associated with cell proliferation. *Int. J. Cancer*, **31**, 13–20.
- Gerdes, J., Lembke, H., Baisch, J. *et al.* (1984) Cell cycle analysis of a cell proliferation-associated human nuclear antigen defined by the monoclonal antibody Ki 67. *J. Immunol.*, **133**, 1710–1715.
- Gonzalez Barcena, D., Alvarez, R.B., Ochoa, E.P. *et al.* (1997) Treatment of uterine leiomyomas with luteinizing-hormone releasing hormone antagonist Cetrorelix. *Hum. Reprod.*, **12**, 2028–2035.
- Gronemeyer, H., Meyer, M.E., Bocquel, M.T. *et al.* (1991) Progesterin receptors: isoforms and antihormone action. *J. Steroid Biochem. Mol. Biol.*, **40**, 271–278.
- Harrison-Woolrych, M. and Robinson, R. (1995) Fibroid growth in response to high-dose progestogen. *Fertil. Steril.*, **64**, 191–192.
- Kawagushi, K., Fujii, S., Konishi, I. *et al.* (1985) Ultrastructural study of cultured smooth muscle cells from uterine leiomyoma and myometrium under the influence of sex steroid. *Gynecol. Oncol.*, **21**, 32–41.
- Kawagushi, K., Fujii, S., Konishi, I. *et al.* (1991) Immunohistochemical analysis of oestrogen receptors, progesterone receptors and Ki-67 in leiomyoma and myometrium during the menstrual cycle and pregnancy. *Virchows Arch. A. Pathol. Anat.*, **419**, 309–315.
- Lessey, B., Killam, A., Metzger, D. *et al.* (1988) Immunohistochemical analysis of human uterine estrogen and progesterone receptors throughout the menstrual cycle. *J. Clin. Endocrinol. Metabol.*, **67**, 334–340.
- Lessl, M., Klotzbuecher, M., Schoen, S. *et al.* (1997) Comparative messenger ribonucleic acid analysis of immediate early genes and sex steroid receptors in human leiomyoma and healthy myometrium. *J. Clin. Endocrinol. Metab.*, **82**, 2586–2560.
- Maheux, R., Guilloteau, C., Lemay, A. *et al.* (1985) Luteinizing hormone-releasing hormone agonist and uterine leiomyomas: a pilot study. *Am. J. Obstet. Gynecol.*, **152**, 1034.
- Marelli, G., Codegani, A.M. and Bizzi, A. (1989) Estrogen and progesterone receptors in leiomyomas and normal uterine tissues during reproductive life. *Acta Eur. Fertil.*, **20**, 19–22.
- Matsuzaki, S., Fukaya, T., Suzuki T. *et al.* (1999) Oestrogen receptor  $\alpha$  and  $\beta$  mRNA expression in human endometrium throughout the menstrual cycle. *Mol. Hum. Reprod.*, **5**, 559–564.
- McCarty, K.S. Jr, Miller, L.S., Cox, E.B. *et al.* (1985) Estrogen analyses: correlation of biochemical and immunohistochemical methods using monoclonal antireceptor antibodies. *Arch. Pathol. Lab. Med.*, **109**, 716–721.
- Murphy, A., Kettel, L.M., Morales, A.J. *et al.* (1993) Regression of uterine leiomyomata in response to the antiprogesterone RU 486. *J. Clin. Endocrinol. Metabol.*, **76**, 513–517.
- Nisolle, M., Casanas-Roux, F., Wyns, Ch. *et al.* (1994) Immunohistochemical analysis of estrogen and progesterone receptors in endometrium and peritoneal endometriosis: a new quantitative method. *Fertil. Steril.*, **4**, 751–759.
- Nisolle, M., Casanas-Roux, F. and Donnez, J. (1997) Immunohistochemical analysis of proliferative activity and steroid receptor expression in peritoneal and ovarian endometriosis. *Fertil. Steril.*, **68**, 912–919.
- Noyes, R.W., Hertig, A.T. and Rock, J. (1950) Dating the endometrial biopsy. *Fertil. Steril.*, **1**, 3–25.
- Otsuka, H., Shinoha, M., Kashyamma, M. *et al.* (1989) A comparative study of the estrogen receptor ratio in endometrium and uterine leiomyomas. *Int. J. Gynaecol. Obst.*, **29**, 189–194.
- Pfeifer, S. and Strauss, J. (1996) ‘Progesterins’. *Reprod. Endocrinol. Surg. Technol.*, **1**, 493–504.
- Reinsch, R.C., Murphy, A.A., Morales, A.J. *et al.* (1994) The effects of RU 486 and leuprolide acetate on uterine artery blood flow in the fibroid uterus: a prospective randomized study. *Am. J. Obstet. Gynecol.*, **170**, 1623–1627.
- Richards, P.A. and Tiltman, A.J. (1996) Anatomical variation of the estrogen receptor in the non-neoplastic myometrium in fibromyomatous uteri. *Virchows Arch.*, **428**, 347–351.
- Savouret, J.F., Chauchereau, A., Misrahi, M. *et al.* (1994) The progesterone receptor. Biological effects of progestins and antiprogesterins. *Hum. Reprod.*, **9**, 7–11.
- Siegel, S. (1956) *Non-parametric Statistics for the Behavioral Sciences*. International Student Editor. McGraw-Hill Book Company, New York.

- Smith, S.K. (1993) The regulation of fibroid growth: time for a re-think? *Br. J. Obstet. Gynaecol.*, **100**, 977–978.
- Tiltman, A.J. (1985) The effect of progestins on the mitotic activity of uterine fibromyomas. *Int. J. Gynecol. Pathol.*, **4**, 89–96.
- Vegeto, E., Shahbaz, N., Wen, D. *et al.* (1993) Human progesterone receptor A form is a cell- and promoter-specific repressor of human progesterone receptor B function. *Mol. Endocrinology*, **7**, 1244–1255.
- Viville, B., Charnock-Jones, D.S., Sharkey, A.M. *et al.* (1997) Distribution of the A and B forms of the progesterone receptor messenger ribonucleic acid and protein in uterine leiomyomata and adjacent myometrium. *Hum. Reprod.*, **12**, 815–822.
- Vollenhoven, B.J., Lawrence, A.S. and Healey, D.L. (1990) Uterine fibroids: a clinical review. *Br. J. Obstet. Gynaecol.*, **97**, 258–298.
- Vu, K., Greenspan, D.L., Wu, T.C. *et al.* (1998) Cellular proliferation, estrogen receptor, progesterone receptor and bcl-2 expression in GnRH agonist-treated uterine leiomyomas. *Hum. Pathol.*, **29**, 359–363.
- Wang, H., Critchley, H., Kelly, R. *et al.* (1998) Progesterone receptor subtype B is differentially regulated in human endometrial stroma. *Mol. Hum. Reprod.*, **4**, 407–412.
- Wilcox, L.S., Koonin, L.M., Pokras, R. *et al.* (1994) Hysterectomy in the United States 1988–1990. *Obstet. Gynecol.*, **83**, 549–555.
- Wilson, E.A., Young, F. and Rees, E.D. (1980) Estradiol and progesterone binding in uterine leiomyomata and in normal uterine tissue. *Obstet. Gynecol.*, **55**, 20–24.

Received on April 1, 1999; accepted on July 28, 1999