



Immunotherapy and radiotherapy for metastatic cancers

Andrew Bang¹, Jonathan D. Schoenfeld²

¹Department of Radiation Oncology, Princess Margaret Cancer Centre/University of Toronto, Toronto, Ontario, Canada; ²Department of Radiation Oncology, Brigham and Women's Hospital/Dana-Farber Cancer Institute, Boston, MA, USA

Contributions: (I) Conception and design: All authors; (II) Administrative support: None; (III) Provision of study materials or patients: None; (IV) Collection and assembly of data: A Bang; (V) Data analysis and interpretation: All authors; (VI) Manuscript writing: All authors; (VII) Final approval of manuscript: All authors.

Correspondence to: Jonathan D. Schoenfeld, MD, MPH. Assistant Professor, Department of Radiation Oncology, Brigham and Women's Hospital/Dana-Farber Cancer Institute, 450 Brookline Ave, DA L2-57, Boston, MA, USA. Email: Jonathan_Schoenfeld@dfci.harvard.edu.

Abstract: Immune checkpoint inhibitors have emerged as a breakthrough therapy in the treatment in various metastatic cancers. In parallel, the role of radiotherapy in metastatic cancers has been expanding to include stereotactic ablative radiotherapy for oligometastases, in addition to the more conventional palliation of symptoms. Thus, many patients are appropriate candidates for both radiation and immunotherapy—highlighting the need for data to guide this treatment combination in patients with metastatic disease. Here, we review the literature to address questions regarding the safety of combined treatment (focusing on radionecrosis and pneumonitis), and the impact of dose, timing and site of radiotherapy. Finally, we highlight ongoing work investigating the potential local and systemic benefit to combining these therapies.

Keywords: Checkpoint inhibitors; immunotherapy; metastatic; PD-1 inhibitors; radiotherapy

Submitted Jun 19, 2018. Accepted for publication Jul 25, 2018.

doi: 10.21037/apm.2018.07.10

View this article at: <http://dx.doi.org/10.21037/apm.2018.07.10>

Introduction

Immune checkpoint inhibitors (ICIs) have dramatically altered the landscape of treatment for metastatic solid tumors. By removing the “brakes” on the immune system, agents that target the inhibitory CTLA-4 and PD-1 receptors invigorate anti-tumor immune responses. Numerous landmark trials demonstrate the effectiveness of ICIs across tumor histologies, including malignant melanoma, non-small cell lung cancer (NSCLC), renal cell carcinoma (RCC), urothelial carcinoma, head and neck squamous cell carcinoma (HNSCC), gastric adenocarcinoma, mismatch-repair-deficient solid tumors, Hodgkin's lymphoma and Merkel cell carcinoma, where treatment with a CTLA-4, PD-1, or PD-L1 inhibitor are FDA-approved (1-9). Particularly notable among successful landmark phase 3 immunotherapy trials is a population of long-term responders along with a relatively larger population of non-responders who derive minimal, if any, benefit from therapy (10). This potential for long-

term benefit, which has now extended beyond a decade in melanoma patients, has ignited intense interest in combination treatment strategies, with the goal of maximizing the number of these long-term responders (11). Early successes include the combination of PD-1 and CTLA-4 inhibition in melanoma and renal cell carcinoma (12,13), as well as PD-1 inhibition and chemotherapy in patients with metastatic non-small cell lung cancer (14).

Take home points:

- (I) Palliative radiotherapy and more recently, immune checkpoint therapy occupy a prominent role in the treatment of metastatic disease. The combination of these treatments appears to be generally well tolerated, although practitioners need to be vigilant to identify and treat immune mediated toxicities. Potential impacts on radionecrosis in patients receiving stereotactic radiosurgery and immune checkpoint inhibitors must be balanced against favorable clinical outcomes now observed with the combination of the two treatments.

- (II) Emerging data suggest that the addition of radiation to patients with limited progression on immunotherapy may be an effective treatment strategy to allow select patients to continue to benefit from immune checkpoint blockade.
- (III) Preclinical studies and clinical data have suggested that the addition of radiotherapy to immune checkpoint blockade could improve systemic response rates—this strategy is being evaluated in prospective clinical trials.

Given that the majority of solid tumor patients will receive radiation therapy over the course of their illness (15), the combination of radiotherapy and immunotherapy for metastatic cancers is particularly appealing. In preclinical models, radiotherapy combined with ICI both enhances the local impact of radiation and the systemic effects of immunotherapy. The immunogenic effects of radiation include enhanced STING (stimulator of interferon genes) pathway activation, antigen presentation, T-cell activation and trafficking that may complement the immune effects of both CTLA-4 and PD-1 pathway inhibition (16). In particular, radiotherapy gives rise to increased uptake of exogenous DNA into the cytoplasm, upregulating interferon production through the cGAS-STING pathway, which in turn helps facilitate a mounted adaptive immune response (17). There is significant interest in understanding and harnessing rare abscopal responses that occur outside of the treatment field following targeted radiation that are likely immune mediated. However, when administered in combination with ICI, it becomes challenging to distinguish between the abscopal effect, enhanced activity of ICI, and delayed and atypical patterns of response that can be observed after both CTLA-4 and PD-1 monotherapy (18-22). Thus, prospective and ideally, randomized trials incorporating ICI and radiation are needed to demonstrate benefit.

Additionally, synergy between radiation and immunotherapy is a double-edged sword, potentially increasing the risk of either radiotherapy-mediated or immune-mediated toxicity. Inhibiting important immunologic checkpoints could increase immune cell-mediated normal tissue damage at the irradiated site. Conversely, by provoking normal tissue injury or acting through immunologic pathways, radiotherapy could worsen immune-related adverse events (ir-AEs) observed with ICIs.

In this review, we discuss the literature and present the current clinical data on the safety of combining ICIs with radiotherapy in patients with metastatic cancers, focusing on associations with the timing of radiation administration, as well as on two toxicities of particular concern in metastatic

patients receiving either brain or lung directed radiation: radionecrosis of the brain and pneumonitis. Finally, we examine the potential benefit of radiation/immunotherapy combinations on both local and systemic responses, and look towards the future to explore how to maximize benefit.

Toxicity

Overall rates of toxicity

One of the potential advantages of immunotherapy as compared to cytotoxic chemotherapy is the side effect profile which is distinct and often better tolerated. Immunologic toxicities associated with ICI vary by class of agent and include fatigue, dermatitis, myalgias, thyroid dysfunction, colitis and pneumonitis (23). However, although these immunologic toxicities are low grade in many patients, they can be severe or even fatal. Prompt recognition and treatment is required to minimize the risk of serious toxicity (24). Thus, identifying any heightened risks associated with the combination of radiation and immunotherapy is paramount.

Only recently have the first prospective studies examining the combination of radiotherapy and immunotherapy in the setting of metastatic disease been reported (*Table 1*). In these reports, grade 3–5 toxicities have ranged from 14–34% in trials using CTLA-4 inhibitors and 5–10% in patients receiving PD-1 inhibitors, generally consistent with the side effect profile expected with immune checkpoint therapy alone. Furthermore, there were few serious side effects attributed to the radiation component of treatment (18,25-30). However, none of these aforementioned studies randomized patients between ICI alone and ICI with radiotherapy, limiting the conclusions that can be drawn. More recently however, Theelen *et al.* and McBride *et al.* presented preliminary data at ASCO 2018 from two phase II randomized trials exploring the use of PD-1 inhibition with or without hypofractionated radiotherapy in patients with metastatic NSCLC and metastatic HNSCC, respectively. Theelen *et al.* demonstrated a grade 3+ toxicity rate of 22% in the control arm *vs.* 17% in the experimental arm (31) while McBride *et al.* demonstrated grade 3+ toxicities of 15% and 11% in the control and experimental arms, respectively (32). Additionally, although the phase 3 randomized PACIFIC study included locally advanced stage 3 NSCLC patients and not patients with metastatic disease, it was reassuring that grade 3+ toxicities were relatively balanced following definitive chemoradiation between the ICI and control groups (33).

Table 1 Prospective studies reporting outcomes and toxicities of combination radiotherapy and immune checkpoint inhibition in patients with metastatic disease

Study	Cancer histology	Immune checkpoint inhibitor	Site of treatment	SBRT/SRS	Dose/fractionation	Timing of radiation with ICI	Local response rate	Systemic response rate	Median survival	Toxicity
Kwon <i>et al.</i> [2014]; phase III	Prostate	Anti-CTLA-4; ipilimumab	Bone	No	8 Gy in 1 fraction	Pre \leq 2 days	-	-	OS: 11.2 months PFS: 4.0 months	All grade: 75% Grade 3+: 26%
Tywan St. Victor <i>et al.</i> [2015]; phase I	Melanoma N=22	Anti-CTLA-4; ipilimumab	Lung, liver, subcutaneous, lymph nodes	No	12 Gy in 2 fractions; 16 Gy in 2 fractions; 18 Gy in 3 fractions; 24 Gy in 3 fractions	Pre 3-5 days	CR: 5%; PR: 27%; SD: 41%	CR: 0%; PR: 18%; SD: 18%	OS: 10.7 months PFS: 3.8 months	-
Hniker <i>et al.</i> [2016]; phase II	Melanoma N=22	Anti-CTLA-4; ipilimumab	Lung, liver, bones, lymph nodes, bowel, brain	Mixed	SBRT: 18 Gy/1 - 50 Gy/4; palliative: 20 Gy/5 - 45 Gy/15	Post \leq 5 days	CR: 32%; PR: 41%; SD: 27%	CR: 14%; PR: 14%; SD: 23%	OS: 12.8 months PFS: 6.0 months	All grade: 68% Grade 3+: 14%
Tang <i>et al.</i> [2017]; phase I	Solid tumor N=35	Anti-CTLA-4; ipilimumab	Lung, liver	Yes	50 Gy in 4 fractions; 60 Gy in 10 fractions	Concurrent or post 7 days	CR: 6%; PR: 29%; SD: 55%	CR: 0%; PR: 10%; SD: 32%	OS: 10.2 months PFS: 3.2 months	Grade 3+: 34% Grade 5: 0%
Welsh <i>et al.</i> [2017]; phase II	Solid tumor N=100	Anti-CTLA-4; ipilimumab	Lung, liver	Yes	50 Gy in 4 fractions; 60 Gy in 10 fractions	Concurrent or post 7 days	-	-	OS: 12 months PFS: 5 months	Grade 3+: 27% Grade 5: 0%
Williams <i>et al.</i> [2017]; phase I	Melanoma N=16	Anti-CTLA-4; ipilimumab	Brain	Mixed	15 Gy in 1 fraction; 18 Gy in 1 fraction; 24 Gy in 1 fraction; 30 Gy in 10 fractions	Concurrent	-	CR: 0%; PR: 7%; SD: 33%	OS: 8 months PFS: 2.5 months	-
Luke <i>et al.</i> [2018]; phase II	Solid tumor N=79	Anti-PD-1; pembrolizumab	Lung, liver, bone, abdomen/pelvis	Yes	30 Gy in 3 fractions; 45 Gy in 3 fractions; 50 Gy in 5 fractions	Post \leq 7 days	-	CR: 1%; PR: 12%; SD: 31%	OS: 9.6 months PFS: 3.1 months	Grade 3+: 10%

SBRT/SRS, stereotactic body radiotherapy/stereotactic radiosurgery; ICI, immune checkpoint inhibitor; Gy, Gray; OS, overall survival; PFS, progression free survival; CR, complete response; PR, partial response; SD, stable disease.

Thus, the combination of ICI and radiotherapy appears to be generally safe in most patients. It should be noted that grade 3–4 adverse events were more common in two trials conducted at a single institution in which ablative doses of radiotherapy (60 Gy delivered over 10 fractions, 50 Gy delivered over 4 fractions) were combined with the CTLA-4 inhibitor ipilimumab. Although these patients received ipilimumab at a dose of 3 mg/kg (approved for the treatment of metastatic melanoma patients), a grade 3–4 adverse event rate of 30% was more comparable to historical rates associated with ipilimumab dosed at 10 mg/kg (27). Reassuringly, these increased severe toxicity rates were not observed in other prospective trials combining radiation with ipilimumab, nor in the recently published prospective study by Luke *et al.*, combining relatively high dose stereotactic body radiotherapy (SBRT) with the PD-1 inhibitor pembrolizumab where grade 3–4 toxicities were observed in 10% of patients (30).

Although prospective data is limited, especially in regards to combinations with PD-1 inhibitors and radiation dose/fractionation regimens most commonly used in the setting of palliative treatment, there has been an expanding number of retrospective studies evaluating outcomes (Table 2) (34–54). Reassuringly, in these studies, grade 3 or higher toxicities have ranged from 8–41% in patients treated with CTLA-4 inhibitors and 5–13% with PD-1 inhibitors, again consistent with the historical rates of adverse events with ICI alone. In a systematic review of studies combining SRS and ICIs, the authors found that although the literature was limited, concurrent therapy in the treatment of brain mets appeared to be safe overall (55). In our recently published series, we found that overall, rates of all grade (35%) and grade 3+ toxicities (8%) were consistent with historical controls (43). We did not note any correlation between the sites of radiotherapy in increasing the rate of an associated adverse event (Figure 1) (43). Interestingly, there was an association between any grade ir-AEs and biologically effective radiation dose (BED) ($P=0.01$) as shown in Figure 2 (43). However, there was no association between BED and severe toxicity, and statistical significance was lost when evaluating only patients who received radiotherapy and a PD-1 inhibitor as opposed to a CTLA-4 inhibitor (43), similar to the findings in Luke *et al.*

Questions regarding timing of therapy and development of toxicity

The relevance of timing, sequencing and interval between

radiation and ICI is an increasingly common practical question for radiation and medical oncologists alike. It should be noted that in the prospective clinical trials published to date, radiotherapy was delivered concurrently or within 7 days of the administration of ICIs (18,25–32) with the exception of the PACIFIC trial, where patients were randomized between 1–42 days following chemoradiotherapy (33).

Several of the retrospective studies summarized in Table 2 investigated whether the sequencing (radiation before *vs.* after) or temporal proximity of radiation to ICI impacted overall rates of toxicity. With regards to the sequencing of therapies, both our group as well as Qin *et al.* did not identify a significant difference in the rates of ir-AEs depending on the sequencing of the two therapies (40,43). In contrast, there may be an association between the temporal proximity of the two treatments and overall toxicity rates. Kiess *et al.* evaluated patients with advanced melanoma treated with a CTLA-4 inhibitor and stereotactic radiosurgery (SRS), and demonstrated a higher rate of grade 3–4 toxicity when SRS was given “concurrently”, defined by the delivery of SRS within 1 month of the ICI (47% *vs.* 16%) (37). We identified a trend towards higher all grade ir-AEs when radiation was delivered within 2 weeks of the receipt of an ICI (39% *vs.* 23%, $P=0.06$), but there were no differences noted in the rate of grade 3–4 toxicities (43). It remains unproven whether radiation given in close sequence to ICI increases the rates of toxicity compared to radiation given concurrently. However, given the prolonged half-life and mechanism of action of these drugs, this seems unlikely. Ongoing and future prospective studies investigating the timing of radiotherapy in relation to ICI will help better establish whether there is any association between toxicity and either the sequencing and/or interval between treatments (56).

One of the most important limitations to identifying associations between combination radiation/ICI treatment and toxicity is that both immune and radiation-induced toxicities can manifest late months, or even years in the case of radiotherapy. Thus, long-term follow up of prospective clinical trials will be important to further investigate any potential increase in toxicity rates. In the meantime, vigilance is needed to identify toxicities with later onset. Multidisciplinary communication and collaboration is essential, especially in cases where patients have discontinued ICI treatment and may be receiving radiation monotherapy when they develop ir-AEs, or to help identify previous radiation treatment fields when toxicity develops

Table 2 Retrospective studies reporting outcomes and toxicities of combination radiotherapy and immune checkpoint inhibition in patients with metastatic disease

Study	Cancer histology	Immune checkpoint inhibitor	Site of treatment	SBRT/SRS	Dose/fractionation	Timing of radiation with ICI	Local response rate	Systemic response rate	Survival	Toxicity
Barker <i>et al.</i> [2013]	Melanoma N=29	Anti-CTLA-4; ipilimumab	Extracranial	Mixed	25 Gy in 10 fractions; 24 Gy in 1 fraction; 28.5 Gy in 3 fractions; 30 Gy in 10 fractions; 30 Gy in 5 fractions; 30 Gy in 3 fractions	Concurrent	-	-	mOS: 9 months (induction) 39 months (maintenance)	Grade 3+: 41% Grade 5: 0%
Silk <i>et al.</i> [2013]	Melanoma N=33	Anti-CTLA-4; ipilimumab	Brain	Mixed	30–37.5 Gy in 10–13 fractions; 14–24 Gy in 1–5 fractions	Variable	CR: 0%; PR: 27%; SD: 32%	-	mOS: 18.3 months	-
Ahmed <i>et al.</i> [2015]	Melanoma N=26	Anti-CTLA-4; ipilimumab	Brain	Yes	20–30 Gy in 5 fractions; 16–24 Gy in 1 fraction	Variable	1 y-LC: 85%	-	mOS: 11.8 months	All grade: 15% Grade 3+: 8%
Kiess <i>et al.</i> [2015]	Melanoma N=46	Anti-CTLA-4; ipilimumab	Brain	Yes	15–24 Gy in 1 fraction	Variable	1 y-LC: 87%	-	mOS: 12.4 months	Grade 3+: 20%
Colaco <i>et al.</i> [2016]	Melanoma, lung, RCC, breast, CRC N=42	Anti-CTLA-4; anti-PD-1	Brain	Yes	15–24 Gy in 1 fraction	Variable	-	-	mOS: 9.3 months	Radiation necrosis: 33%
Liniker <i>et al.</i> [2016]	Melanoma N=35	Anti-PD-1; nivolumab, pembrolizumab	All	Mixed	8–30 Gy in 1–10 fractions	Variable	CR: 10%; PR: 43%; SD: 27%	CR: 22%; PR: 26%; SD: 31%	mOS: 6.4 months (C*) 8.6 months (S*); P=0.77	Grade 3+: 11%
Qin <i>et al.</i> [2016]	Melanoma N=44	Anti-CTLA-4; ipilimumab	Extracranial	Mixed	18–42 Gy in 1–16 fractions	Variable	-	-	mOS: 17.9 months 15.9 months (B*) 17.9 months (A*); P=0.59	Grade 3+: 18%
Aboudaram <i>et al.</i> [2017]	Melanoma N=17	Anti-PD-1; nivolumab, pembrolizumab	All	Mixed	24–45 Gy in 3–15 fractions	Variable	-	CR/PR: 65%	6 m-OS: 76% 6 m-PFS: 65%	All grade: 29% Grade 3+: 7%
Anderson <i>et al.</i> [2017]	Melanoma N=21	Anti-PD-1; pembrolizumab	Brain	Mixed	30 Gy in 5 or 10 fractions; 18–21 Gy in 1 fraction	Concurrent	CR: 35%; PR: 35%; SD: 26%	-	-	Grade 3+: 5%

Table 2 (continued)

Table 2 (continued)

Study	Cancer histology	Immune checkpoint inhibitor	Site of treatment	SBRT/SRS	Dose/fractionation	Timing of radiation with ICI	Local response rate	Systemic response rate	Survival	Toxicity
Bang <i>et al.</i> [2017]	Melanoma, Lung, RCC N=133	Anti-CTLA-4; ipilimumab; anti-PD-1; pembrolizumab	All	Mixed	8–66 Gy in 1–33 fractions	Variable	–	–	–	All grade: 35% Grade 3+: 8%
Fang <i>et al.</i> [2017]	Melanoma N=137	Anti-CTLA-4; ipilimumab; anti-PD-1; nivolumab, pembrolizumab	Brain	Mixed	12–24 Gy in 1 fraction	Variable	–	–	mOS: 16.9 months	Radiation necrosis: 27% Symptomatic RN: 15%
Hwang <i>et al.</i> [2017]	Lung N=73	Anti-PD-1; Anti-PD-L1	Lung	–	–	–	–	–	mOS: 12.1 months	–
Kaidar-Person <i>et al.</i> [2017]	Melanoma N=29	Anti-CTLA-4; ipilimumab; anti-PD-1; nivolumab, pembrolizumab	Brain	Yes	21–30 Gy in 3–5 fractions; 18–20 Gy in 1 fraction	Variable	1y-LC: 52%	–	mOS: 15 months	Radiation necrosis: 28% Symptomatic RN: 21%
Patel <i>et al.</i> [2017]	Melanoma N=20	Anti-CTLA-4; ipilimumab	Brain	Yes	15–21 Gy in 1 fraction	Variable	1 y-LC: 71%	–	1 year OS: 37%	Hemorrhage 24% Radiation necrosis: 30% Symptomatic RN: 15%
Pike <i>et al.</i> [2017]	Melanoma, lung, RCC N=137	Anti-PD-1; nivolumab, pembrolizumab	All	Mixed	8–66 Gy in 1–33 fractions	Variable	–	–	mOS: 23.5 months	Hemorrhage: 15%
Shaverdian <i>et al.</i> [2017]	NSCLC N=42	Anti-PD-1; pembrolizumab	Lung	Mixed	–	Pre	–	–	mOS: 10.7 months	All grade pulmonary: 63% Grade 3+ pulmonary: 13%
Diao <i>et al.</i> [2018]	Melanoma N=43	Anti-CTLA-4; ipilimumab	Brain	Yes	12–22 Gy in 1 fraction	Variable	CR/PR: 70%; SD: 12%	–	PFS: 4.4 months	Radiation necrosis (pathologic): 2% Hemorrhage: 18%

Table 2 (continued)

Table 2 (continued)

Study	Cancer histology	Immune checkpoint inhibitor	Site of treatment	SBRT/SRS	Dose/fractionation	Timing of radiation with ICI	Local response rate	Systemic response rate	Survival	Toxicity
Gabani <i>et al.</i> [2018]	Melanoma N=288	Anti-CTLA-4; anti-PD-1; IL-2; tumor vaccines	Extracranial	Mixed	8–67.5 Gy; SBRT: 20–50 Gy in 1–5 fractions	Variable	–	–	mOS: 15.4 months	–
Hubbeling <i>et al.</i> [2018]	NSCLC N=50	Anti-PD-1; nivolumab, pembrolizumab; anti-PD-L1; atezolizumab	Brain	Mixed	20–37.5 Gy in 10–15 fractions; SRS: 10–22 Gy in 1 fraction	Variable	–	–	–	All grade (SRS): 57% Grade 3+ (SRS): 9% All grade (WBRT): 90% Grade 3+ (WBRT): 10%
Martin <i>et al.</i> [2018]	Melanoma, lung, RCC N=115	Anti-CTLA-4; ipilimumab; anti-PD-1; nivolumab pembrolizumab	Brain	Yes	25–30 Gy in 5 fractions; 18–20 Gy in 1 fraction	Variable	–	–	–	Radionecrosis (pathologic): 3% Symptomatic RN: 20%
Nardin <i>et al.</i> [2018]	Melanoma N=25	Anti-PD-1; pembrolizumab	Brain	Yes	24–35 Gy in 3–5 fractions; 12–24 Gy in 1 fraction	Variable	LC: 80%	–	mOS: 11 months 1 y-OS: 49%	Grade 3+: 12% Radionecrosis: 16% Symptomatic RN: 12% Hemorrhage: 36%

SBRT/SRS, stereotactic body radiotherapy/stereotactic radiosurgery; ICI, immune checkpoint inhibitor; Gy, Gray; mOS, median overall survival; LC, local control; CR, complete response; PR, partial response; SD, stable disease; C*, concurrent; S*, sequential; B*, before; A*, after; PFS, progression free survival; RN, radionecrosis; WBRT, whole brain radiotherapy.

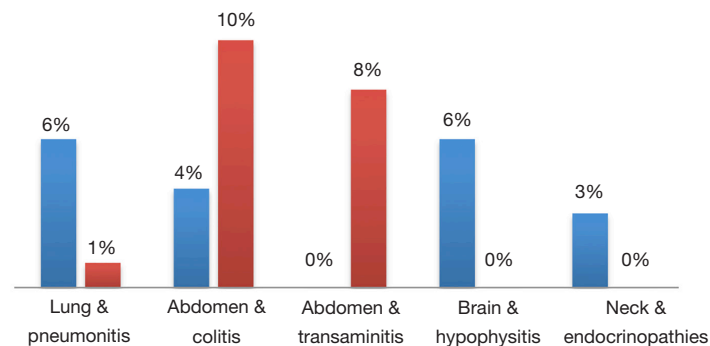


Figure 1 Rates of any-grade immune-related adverse events in patients that have (blue), or have not (red) received radiation to the corresponding anatomical location (e.g., rates of pneumonitis in patients that have (blue) or have not (red) received lung directed radiotherapy). There were no statistically significant differences in toxicities between patients who received radiotherapy to the site of interest as compared to those that did not. Blue, associated site of radiotherapy; Red, no associated site of radiotherapy.

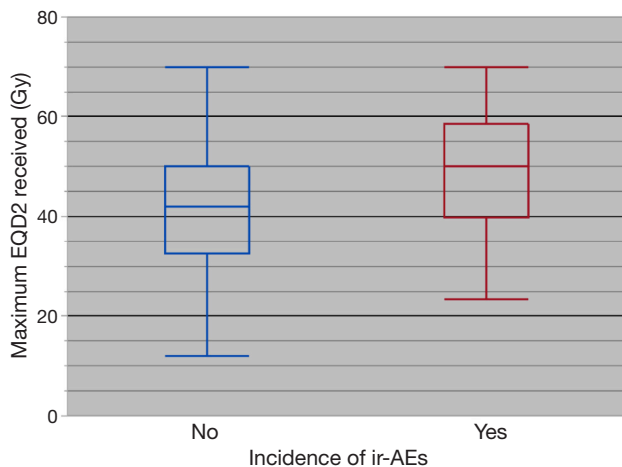


Figure 2 Any grade immune-related adverse events in relation to the equivalent 2 Gy dose (EQD2) in patients who received an immune checkpoint inhibitor and radiotherapy. There was an association between any grade immune-related adverse events and higher mean EQD2 ($P < 0.01$). ir-AEs, Immune-related adverse events; EQD2, equivalent 2 Gy dose; Gy, Gray.

after starting ICI. Particularly relevant to the latter are reports of recall ir-AEs that are localized to the radiation treatment field (57), which can only be recognized if the details of previous radiation treatment are known.

Brain radionecrosis

Although there is evidence that ICI monotherapy is efficacious in the brain (58,59), most patients with

intracranial metastases are considered for radiotherapy, especially for histologies other than melanoma, where response rates to ICI are more limited. Thus, an increasing number of patients are treated with the combination of brain-directed radiotherapy and ICI. More specifically, the use of SRS for patients with limited numbers of brain metastases has continued to increase; thus, many of these patients will receive SRS in the setting of ICI. While it can be challenging to differentiate radionecrosis from progression or pseudoprogression, several retrospective studies have estimated that following SRS treatment, radiographic radionecrosis rates range from 16–33% (38,44,46,47,54), while symptomatic radionecrosis rates range from 12–21% (44,46,47,53,54). To help answer the question of whether the addition of ICIs increases the risk of radionecrosis, Martin *et al.* and Kaidar-Person *et al.* compared rates among patients who were treated with SRS and those who received both SRS and ICIs. Martin *et al.* studied 480 patients who received SRS in a mixed population (melanoma, NSCLC, RCC). They found that patients who received a CTLA-4 or PD-1 inhibitor had higher rates of symptomatic radionecrosis than those who received SRS alone (20% *vs.* 7%, HR 2.56, $P = 0.004$) (53). Patients with metastatic melanoma appeared to be more susceptible to increased rates of symptomatic radionecrosis (HR 4.70, $P = 0.01$) (53). Kaidar-Person *et al.* also demonstrated increased symptomatic radionecrosis rates of 21% compared to 0% in patients who did not receive an ICI (46). Comparing the impact of CTLA-4 inhibitors and PD-1 inhibitors, the study by Martin *et al.* demonstrated both classes of ICIs may numerically increase rates of

radionecrosis, although the association with PD-1 inhibition was not statistically significant (HR 3.57, $P=0.06$) (53). Of note, an increasing number of studies demonstrate favorable survival in patients treated with the combination of SRS and brain metastases as compared to historical controls; this may impact the detection of radionecrosis in ways that are challenging to control for in retrospective studies.

Pneumonitis

In comparison to cytotoxic chemotherapy and CTLA-4 inhibitors, PD-1 inhibitors are associated with increased rates of pneumonitis. In a meta-analysis of 16 phase II/III studies, Wu *et al.* found the incidence of all grade pneumonitis was 2.9% and 1.5% for grade 3+ pneumonitis (60). Radiation-related pneumonitis is associated with a high dose of radiation to the lungs, and thus special attention is paid to the incidence of this toxicity when combining both treatments. When pneumonitis does develop in the setting of ICI in a patient previously treated with thoracic radiotherapy, it can be challenging to determine whether this is radiation or ICI related; this may have therapeutic implications if it prompts discontinuation of ICI therapy. Until better tools are available, evaluating the anatomical location of pneumonitis (radiation pneumonitis is generally localized to the radiation treatment field when detected in early stages, immune related pneumonitis is more diffuse) (61) and timing (radiation pneumonitis typically develops 2–9 months after radiotherapy (62) and immune related pneumonitis generally occurs between 0–19 months) (63) are generally the most helpful to guide attribution.

Reassuringly, there are several retrospective studies which have specifically evaluated rates of pneumonitis in ICI-treated patients who also received lung-directed radiation, finding no statistically significant difference in pneumonitis rates (43,45,49). In a secondary analysis of KEYNOTE-001, Shaverdian *et al.* found all grade pneumonitis rates of 8% *vs.* 1% ($P=0.15$) in patients who received thoracic-directed radiotherapy prior to ICI as compared to patients treated with ICIs alone (49). Hwang *et al.* retrospectively found all grade pneumonitis rates of 8% compared with 6% in patients previously treated with ICI combined with thoracic radiotherapy versus ICI alone (45). Interestingly, on multivariate analysis, they found that patients with an ir-AE had improved survival (HR 0.45, $P=0.03$) (45). Finally, the PACIFIC study, in which all patients received radiation to the lungs prescribed to at least 54 Gy administered 0–7 weeks before durvalumab, there was a modest

numerical increase in any grade pneumonitis (34% *vs.* 25%) in patients that received durvalumab as compared to placebo that should, at least in part, be attributed to the rate of pneumonitis expected with durvalumab monotherapy (33). However, grade 3–4 pneumonitis rates were 3% in both arms (33).

Efficacy of combined treatment strategy

Local effects

Historically, chemotherapy and targeted agents have been used for radiosensitization to enhance the local effects of radiotherapy and to improve tumor control. While immunotherapies may not act as a radiosensitizer in a classical sense, preclinical and clinical evidence suggest that radiation is less effective when treating cancers in a state of immunosuppression (64). There are not yet any randomized trials in patients with metastatic disease comparing the local control rates of radiotherapy either administered alone or in combination with ICIs. In the setting of stage III NSCLC, the PACIFIC trial demonstrated an overall response rate of 28.4% compared to 16.0% when adding consolidative durvalumab and a disease control rate of 82.2% *vs.* 71.8% (33).

In the metastatic setting, several retrospective studies have compared local control rates in patients treated with combination SRS and ICI and SRS alone. Silk *et al.* found higher local response rates of 27% compared to 9% when SRS patients also received ipilimumab (35). However, disease control rates trended in the opposite direction (59% with ipilimumab, 68% without). In the studies performed by Kaidar-Person *et al.* and Patel *et al.*, local control rates at 1-year were also numerically lower in patients treated with ipilimumab (52% *vs.* 86%, $P=0.07$ and 71% *vs.* 92%, $P=0.40$ in the two studies respectively) (46,47). However, local control following SRS is challenging to assess, especially in the setting of increased rates of radionecrosis/pseudoprogression that could potentially be observed following SRS and ICI. Pseudoprogression is not well accounted for using standard RECIST criteria, and thus alternative response criteria (irRC, iRECIST) are being utilized (21,22). More specifically for neuro-oncology, a response assessment has been developed by the RANO working group (65).

The local effects of radiotherapy could also be particularly valuable in metastatic patients who develop isolated sites of progression on ICI (66). The biologic explanation for this atypical pattern of resistance may be varied, but may, in some cases, be the result of localized loss of tumor antigens

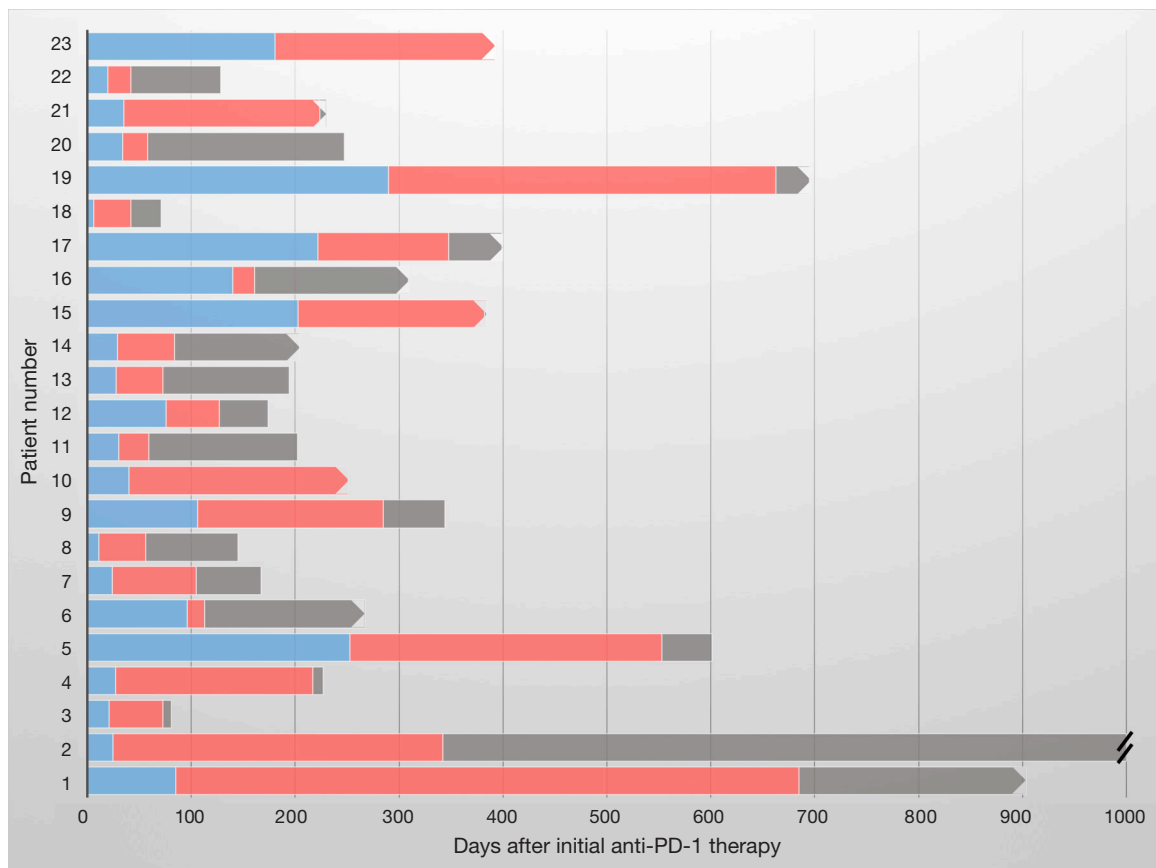


Figure 3 Timeline plot of patients with metastatic NSCLC and melanoma who received palliative radiation after progressing on anti-PD-1 therapy and were subsequently able to continue on anti-PD-1 therapy (red bars) for a median of 179 days (IQR 30–338 days). Blue, anti-PD-1 therapy delivered before RT; Red, anti-PD-1 therapy continued after RT; Grey, time off PD-1 inhibitor until death or last follow up; Blunt end, death; Pointed end, censored/ongoing follow up; Double Hash, survival beyond 1,000 days (1,491 days).

recognized by the immune system on ICI or other specific genetic changes mediating resistance (67–69). In cases such as these, focal radiation could ablate the area(s) of resistance, allowing for a sustained and more durable systemic response. Indeed, we found that among 59 patients who were treated with focal radiation for progression after starting a PD-1 inhibitor, 23 (39%) were able to continue to receive anti-PD-1 therapy for a median of 179 days (IQR 30–338, *Figure 3*) (48). In the future, better identification and biologic classification of patients with oligoprogression may further improve the utility of this combined treatment strategy.

Using radiotherapy to improve systemic immunotherapy effects

Given the favorable immunologic effects observed following

radiation *in vitro*, one of the most provocative uses of radiotherapy being explored in the metastatic setting is to administer focal radiotherapy with the purpose of igniting a systemic immune response and overcoming either primary or acquired resistance to ICI. This work was encouraged by early case reports describing unusually favorable results obtained with the combination of radiation and ICI including a response outside of the radiation field (abscopal response) in a patient previously progressing on ipilimumab with biologic evidence of immune activation (18). Another case report demonstrated evidence of activity with ipilimumab combined with radiation in a heavily pretreated NSCLC patient (70)—a tumor type that does not generally respond to anti-CTLA-4 therapy. Although the PACIFIC study did not enroll metastatic NSCLC patients, this study also demonstrated an impressive PFS benefit with a hazard

ratio of 0.52 (95% CI: 0.42–0.65, $P < 0.001$) for the PD-L1 inhibitor durvalumab as compared to placebo in patients who received prior thoracic radiotherapy with concurrent chemotherapy (33). It remains unknown whether this more pronounced benefit for durvalumab, as compared to the benefit generally observed in the metastatic populations, was due to immune stimulating effects, eradication of gross disease prior to immunotherapy (10), or perhaps a combination of these two effects. Of note, patients who were randomized within 14 days of completing radiation demonstrated a more pronounced benefit to durvalumab as compared to placebo (HR for PFS 0.39, 95% CI: 0.26–0.58, as compared with HR 0.63, 95% CI: 0.49–0.80). A better understanding of the mechanisms underlying improved responses would help refine combined treatment strategies. Indeed, the existing radiation-immunotherapy studies mentioned above as well as other retrospective studies summarized in *Table 2* are limited by significant heterogeneity regarding timing of radiation relative to ICI, sites and volume of disease to be radiated, and radiation dose/fractionation. Preclinical studies suggest these factors may impact results of combined radiation/ICI treatment significantly (71–74).

Conclusions

In summary, the combination of ICI and radiotherapy represents a promising treatment strategy for patients with metastatic cancers that is supported by preclinical evidence and early clinical data. Both prospective and an increasing amount of retrospective data suggest the combination of the two treatments is generally safe, although more study is needed to evaluate rare and late effects as well as to more accurately attribute toxicity to guide patient management. Additionally, potential increases in the rate of radionecrosis in patients receiving SRS and ICI must be balanced against the favorable clinical outcomes now observed with the combination of the two treatments (48), and is deserving of further study. In the meantime, the existing data is reassuring for the increasing number of patients who are candidates for ICI and palliative radiotherapy administered as standard of care treatment.

In addition, ongoing studies are evaluating the potential of a combined treatment strategy incorporating both radiotherapy and ICI to maximize benefit by addressing primary and acquired resistance to ICI, and by improving local control rates and palliative benefit achieved by radiation monotherapy. Existing clinical data suggests that

radiotherapy can address localized progression in patients otherwise responding to immunotherapy; some of these patients can then continue to derive durable benefit from ICI. Unknown is whether the addition of radiotherapy to ICI will be able to reliably increase response rates as it has been demonstrated in preclinical models, and if so, the specifics of the patient, tumor and treatment parameters (type of ICI, timing, dose, fractionation and site of radiotherapy) required to maximize benefit.

Acknowledgments

None.

Footnote

Conflicts of Interest: JD Schoenfeld acknowledges research funding from BMS, Merck, and consulting fees from BMS, Debiopharm Group, AZ, Nanobiotix, and Tilos Therapeutics. Another author has no conflicts of interest to declare.

References

1. Hodi FS, O'Day SJ, McDermott DF, et al. Improved survival with ipilimumab in patients with metastatic melanoma. *N Engl J Med* 2010;363:711–23.
2. Garon EB, Rizvi NA, Hui R, et al. Pembrolizumab for the treatment of non-small-cell lung cancer. *N Engl J Med* 2015;372:2018–28.
3. Motzer RJ, Escudier B, McDermott DF, George S, Hammers HJ, Srinivas S, et al. Nivolumab versus everolimus in advanced renal cell carcinoma. *N Engl J Med* 2015;373:1803–13.
4. Rosenberg JE, Hoffman-Censits J, van der Heijden MS, et al. Atezolizumab in patients with locally advanced and metastatic urothelial carcinoma who have progressed following treatment with platinum-based chemotherapy: a single-arm, multicentre, phase 2 trial. *Lancet* 2016;387:1909–20.
5. Cohen EEW, Machiels EWC, Harrington KJ, et al. KEYNOTE-040: A phase III randomized trial of pembrolizumab (MK-3475) versus standard treatment in patients with recurrent or metastatic head and neck cancer. *J Clin Oncol* 2015;33:TPS6084. [Epub ahead of print].
6. Fuchs CS, Doi T, Jang RW, et al. Safety and efficacy of pembrolizumab monotherapy in patients with previously treated advanced gastric and gastroesophageal junction

- cancer: Phase 2 clinical KEYNOTE-059 trial. *JAMA Oncol* 2018;4:e180013.
7. Le DT, Uram JN, Wang H, et al. PD-1 blockade in tumors with mismatch-repair deficiency. *N Engl J Med* 2015;372:2509-20.
 8. Ansell SM, Lesokhin AM, Borrello I, et al. PD-1 blockade with nivolumab in relapsed or refractory Hodgkin's lymphoma. *N Engl J Med* 2015;372:311-9.
 9. Nghiem PT, Bhatia S, Lipson EJ, et al. PD-1 blockade with pembrolizumab in advanced merkel-cell carcinoma. *N Engl J Med* 2016;374:2542-52.
 10. Alexander BM, Schoenfeld JD, Trippa LT. Hazards of hazard ratios – deviations from model assumptions in immunotherapy. *N Engl J Med* 2018;378:1158-9.
 11. Schadendorf D, Hodi FS, Robert C, et al. Pooled analysis of long-term survival data from phase II and phase III trials of ipilimumab in unresectable or metastatic melanoma. *J Clin Oncol* 2015;33:1889-94.
 12. Wolchok JD, Chiarion-Sileni V, Gonzalez R, et al. Overall survival with combined nivolumab and ipilimumab in advanced melanoma. *N Engl J Med* 2017;377:1345-56.
 13. Motzer RJ, Tannir NM, McDermott DF, et al. Nivolumab plus ipilimumab versus sunitinib in advanced renal-cell carcinoma. *N Engl J Med* 2018;378:1277-90.
 14. Langer CJ, Gadgeel SM, Borghaei H, et al. Carboplatin and pemetrexed with or without pembrolizumab for advanced, non-squamous non-small-cell lung cancer: a randomized, phase 2 cohort of the open-label KEYNOTE-021 study. *Lancet Oncol* 2016;17:1497-508.
 15. Lutz ST, Jones J, Chow E. Role of radiation therapy in palliative care of the patient with cancer. *J Clin Oncol* 2014;32:2913-19.
 16. Ngwa W, Irabor OC, Schoenfeld JD, et al. Using immunotherapy to boost the abscopal effect. *Nat Rev Cancer* 2018;18:313-22.
 17. Deng L, Liang H, Xu M, et al. STING-dependent cytosolic DNA sensing promotes radiation-induced Type I interferon-dependent antitumor immunity in immunogenic tumors. *Immunity* 2014;41:843-52.
 18. Hiniker SM, Reddy SA, Maeker HT, et al. A prospective clinical trial combining radiation therapy with systemic immunotherapy in metastatic melanoma. *Int J Radiat Oncol Biol Phys* 2016;96:578-88.
 19. Postow MA, Callahan MK, Barker CA, et al. Immunologic correlates of the abscopal effect in a patient with melanoma. *N Engl J Med* 2012;366:925-31.
 20. Wolchok JD, Hoos A, O'Day S, et al. Guidelines for the evaluation of immune therapy activity in solid tumors: immune-related response criteria. *Clin Cancer Res* 2009;15:7412-20.
 21. Hodi FS, Hwu WJ, Kefford R, et al. Evaluation of immune-related response criteria and RECIST v1.1 in patients with advanced melanoma treated with pembrolizumab. *J Clin Oncol* 2016;34:1510-7.
 22. Seymour L, Boerjans J, Perrone A, et al. iRECIST: guidelines for response criteria for use in trials testing immunotherapeutics. *Lancet Oncol* 2017;18:e143-52.
 23. Postow MA, Sidlow R, Hellmann MD. Immune-related adverse events associated with immune checkpoint blockade. *N Engl J Med* 2018;378:158-68.
 24. Brahmer JR, Lacchetti C, Schneider BJ, et al. Management of immune-related adverse events in patients treated with immune checkpoint inhibitor therapy: American Society of Clinical Oncology clinical practice guideline. *J Clin Oncol* 2018;36:1714-68.
 25. Kwon ED, Drake CG, Scher HI, et al. Iplimumab versus placebo after radiotherapy in patients with metastatic castration-resistant prostate cancer that had progressed after docetaxel chemotherapy (CA184-043): a multicenter, randomized, double-blind, phase 3 trial. *Lancet Oncol* 2014;15:700-12.
 26. Twyman-Saint Victor C, Rech AJ, Maity A, et al. Radiation and dual checkpoint blockade activate non-redundant immune mechanisms in cancer. *Nature* 2015;520:373-7.
 27. Tang C, Welsh JW, de Groot P, et al. Ipilimumab with stereotactic ablative radiation therapy: phase I results and immunologic correlates from peripheral T cells. *Clin Cancer Res* 2017;23:1388-96.
 28. Welsh JW, Tang C, de Groot P, et al. Phase II 5-arm trial of ipilimumab plus lung or liver stereotactic radiation for patients with advanced malignancies. *Int J Radiat Oncol Biol Phys* 2017;99:1315.
 29. Williams NL, Wuthrick EJ, Kim H, et al. Phase 1 study of ipilimumab combined with whole brain radiation therapy or radiosurgery for melanoma patients with brain metastases. *Int J Radiat Oncol Biol Phys* 2017;99:22-30.
 30. Luke JJ, Lemons JM, Karrison TG, et al. Safety and clinical activity of pembrolizumab and multisite stereotactic body radiotherapy in patients with advanced solid tumors. *J Clin Oncol* 2018;36:1611-8.
 31. Theelen W, Peulen H, Lalezari F, et al. Randomized phase II study of pembrolizumab after stereotactic body radiotherapy (SBRT) versus pembrolizumab alone in patients with advanced non-small cell lung cancer: The PEMBRO-RT study. *J Clin Oncol* 2018;36:abstr 9023.
 32. McBride SM, Sherman EJ, Tsai CJ, et al. A phase II

- randomized trial of nivolumab with stereotactic body radiotherapy (SBRT) versus nivolumab alone in metastatic (M1) head and neck squamous cell carcinoma (HNSCC). *J Clin Oncol* 2018;36:abstr 6009.
33. Antonia SJ, Villegas A, Daniel D, et al. Durvalumab after chemoradiotherapy in stage III non-small-cell lung cancer. *N Engl J Med* 2017;377:1919-29.
 34. Barker CA, Postow MA, Khan SA, et al. Concurrent radiotherapy and ipilimumab immunotherapy for patients with melanoma. *Cancer Immunol Res* 2013;1:92-8.
 35. Silk AW, Bassetti MF, West BT, et al. Ipilimumab and radiation therapy for melanoma brain metastases. *Cancer Med* 2013;2:899-906.
 36. Ahmed KA, Stallworth DG, Kim Y, et al. Clinical outcomes of melanoma brain metastases treated with stereotactic radiation and anti-PD-1 therapy. *Ann Oncol* 2016;27:434-41.
 37. Kiess AP, Wolchok JD, Barker CA. Stereotactic radiosurgery for melanoma brain metastases in patients receiving ipilimumab: safety profile and efficacy of combined treatment. *Int J Radiat Oncol Biol Phys* 2015;92:368-75.
 38. Colaco RJ, Martin P, Kluger HM, et al. Does immunotherapy increase the rate of radiation necrosis after radiosurgical treatment of brain metastases? *J Neurosurg* 2016;125:17-23.
 39. Liniker E, Menzies AM, Kong BY, et al. Activity and safety of radiotherapy with anti-PD-1 drug therapy in patients with metastatic melanoma. *Oncoimmunology* 2016;5:e1214788.
 40. Qin R, Olson A, Singh B, et al. Safety and efficacy of radiation therapy in advanced melanoma treated with ipilimumab. *Int J Radiat Oncol Biol Phys* 2016;96:72-7.
 41. Aboudaram A, Modesto A, Chaltiel L, et al. Concurrent radiotherapy for patients with metastatic melanoma and receiving anti-programmed-death 1 therapy: a safe and effective combination. *Melanoma Res* 2017;27:485-91.
 42. Anderson ES, Postow MA, Wolchok JD, et al. Melanoma brain metastases treated with stereotactic radiosurgery and concurrent pembrolizumab display marked regression; efficacy and safety of combined treatment. *J Immunother Cancer* 2017;5:76.
 43. Bang A, Wilhite TJ, Pike LRG, et al. Multicenter evaluation of the tolerability of combined treatment with PD-1 and CTLA-4 immune checkpoint inhibitors and palliative radiation therapy. *Int J Radiat Oncol Biol Phys* 2017;98:344-51.
 44. Fang P, Jiang W, Allen P, et al. Radiation necrosis with stereotactic radiosurgery combined with CTLA-4 blockade and PD-1 inhibition for treatment of intracranial disease in metastatic melanoma. *J Neurooncol* 2017;133:595-602.
 45. Hwang WL, Niemierko A, Hwang KL, et al. Clinical outcomes in patients with metastatic lung cancer treated with PD-1/PD-L1 inhibitors and thoracic radiotherapy. *JAMA Oncol* 2018;4:253-5.
 46. Kaidar-Person O, Zagar TM, Deal A, et al. The incidence of radiation necrosis following stereotactic radiotherapy for melanoma brain metastases: the potential impact of immunotherapy. *Anticancer Drugs* 2017;28:669-75.
 47. Patel KR, Shoukat S, Oliver DE, et al. Ipilimumab and stereotactic radiosurgery versus stereotactic radiosurgery alone for newly diagnosed melanoma brain metastases. *Am J Clin Oncol* 2017;40:444-50.
 48. Pike LRG, Bang A, Ott P, et al. Radiation and PD-1 inhibition: favorable outcomes after brain-directed radiation. *Radiother Oncol* 2017;124:98-103.
 49. Shaverdian N, Lisberg AE, Bornazyan K, et al. Previous radiotherapy and the clinical activity and toxicity of pembrolizumab in the treatment of non-small-cell lung cancer: a secondary analysis of the KEYNOTE-001 phase 1 trial. *Lancet Oncol* 2017;18:895-903.
 50. Diao K, Bian SX, Routman DM, et al. Combination ipilimumab and radiosurgery for brain metastases: tumor, edema and adverse radiation effects. *J Neurosurg* 2018. [Epub ahead of print].
 51. Gabani P, Robinson CG, Anstas G, et al. Use of extracranial radiation therapy in metastatic melanoma patients receiving immunotherapy. *Radiother Oncol* 2018;127:310-7.
 52. Hubbeling HG, Schapira EF, Horick NK, et al. Safety of combined PD-1 pathway inhibition and intracranial radiation therapy in non-small cell lung cancer. *J Thorac Oncol* 2018;13:550-8.
 53. Martin AM, Cagney DN, Catalano PJ, et al. Immunotherapy and symptomatic radiation necrosis in patients with brain metastases treated with stereotactic radiation. *JAMA Oncol* 2018. [Epub ahead of print].
 54. Nardin C, Mateus C, Texier M, et al. Tolerance and outcomes of stereotactic radiosurgery combined with anti-programmed cell death-1 (pembrolizumab) for melanoma brain metastases. *Melanoma Res* 2018;28:111-9.
 55. Kroeze SG, Fritz C, Hoyer M, et al. Toxicity of concurrent stereotactic radiotherapy and targeted therapy or immunotherapy: a systematic review. *Cancer Treat Rev* 2017;53:25-37.
 56. ClinicalTrials.gov [Internet]. Bethesda (MD): National

- Library of Medicine (US). 2017 Jul 21 -. Identifier NCT03223155. Concurrent or Sequential Immunotherapy and Radiation Therapy in Patients with Metastatic Lung Cancer (COSINR). 2018 Feb 21 [cited 2018 Jun 17]. Available online: <https://clinicaltrials.gov/ct2/show/NCT03223155>.
57. Shibaki R, Akamatsu H, Fujimoto M, et al. Nivolumab induced radiation recall pneumonitis after two years of radiotherapy. *Ann Oncol* 2017;28:1404-5.
 58. Margolin K, Ernstoff MS, Hamid O, et al. Ipilimumab in patients with melanoma and brain metastases: an open-label phase 2 trial. *Lancet Oncol* 2012;13:459-65.
 59. Goldberg SB, Gettinger SN, Mahajan A, et al. Pembrolizumab for patients with melanoma or non-small-cell lung cancer and untreated brain metastases: early analysis of a non-randomised, open-label, phase 2 trial. *Lancet Oncol* 2016;17:976-83.
 60. Wu J, Hong D, Zhang X, et al. PD-1 inhibitors increase the incidence and risk of pneumonitis in cancer patients in a dose-independent manner: a meta-analysis. *Sci Rep* 2017;7:44173.
 61. Nishino M, Ramaiya NH, Awad MM, et al. PD-1 inhibitor-related pneumonitis in advanced cancer patients: radiographic patterns and clinical course. *Clin Cancer Res* 2016;22:6051-60.
 62. Rodrigues G, Lock M, D'Souza D, et al. Prediction of radiation pneumonitis by dose-volume histogram parameter in lung cancer-a systematic review. *Radiother Oncol* 2004;71:127-38.
 63. Haanen JBAG, Carbone F, Robert C, et al. Management of toxicities from immunotherapy: ESMO Clinical Practice Guidelines for diagnosis, treatment and follow-up. *Ann Oncol* 2017;28:iv119-42.
 64. Lee Y, Auh SL, Wang Y, et al. Therapeutic effects of ablative radiation on local tumor require CD8+ T cells: changing strategies for cancer treatment. *Blood* 2009;114:589-95.
 65. Okada H, Weller M, Huang R, et al. Immunotherapy response assessment in neuro-oncology: a report of the RANO working group. *Lancet Oncol* 2015;16:e534-42.
 66. Gide TN, Wilmott JS, Scoyler RA, et al. Primary and Acquired Resistance to Immune Checkpoint Inhibitors in Metastatic Melanoma. *Clin Cancer Res* 2018;24:1260-70.
 67. Anagnostou V, Smith KN, Forde PM, et al. Evolution of neoantigens landscape during immune checkpoint blockade in non-small cell lung cancer. *Cancer Discov* 2017;7:264-76.
 68. George S, Miao D, Demetri GD, et al. Loss of PTEN Is Associated with Resistance to Anti-PD-1 Checkpoint Blockade Therapy in Metastatic Uterine Leiomyosarcoma. *Immunity* 2017;46:197-204.
 69. Le DT, Durham JN, Smith KN, et al. Mismatch repair deficiency predicts response of solid tumors to PD-1 blockade. *Science* 2017;357:409-13.
 70. Golden EB, Demaria S, Schiff PB, et al. An abscopal response to radiation and ipilimumab in a patient with metastatic non-small cell lung cancer. *Cancer Immunol Res* 2013;1:365-72.
 71. Young KH, Baird JR, Savage T, et al. Optimizing timing of immunotherapy improves control of tumors by hypofractionated radiation therapy. *PLoS One* 2016;11:e0157164.
 72. Beyranvand Nejad E, Welters MJP, Arens R, et al. The importance of correctly timing cancer immunotherapy. *Expert Opin Biol Ther* 2017;17:87-103.
 73. Dewan MZ, Galloway AE, Kawashima N, et al. Fractionated but not single-dose radiotherapy induces an immune-mediated abscopal effect when combined with anti-CTLA-4 antibody. *Clin Cancer Res* 2009;15:5379-88.
 74. Vanpouille-Box C, Alard A, Aryankalayil MJ, et al. DNA exonuclease Trex1 regulates radiotherapy-induced tumour immunogenicity. *Nat Commun* 2017;8:15618.

Cite this article as: Bang A, Schoenfeld JD. Immunotherapy and radiotherapy for metastatic cancers. *Ann Palliat Med* 2019;8(3):312-325. doi: 10.21037/apm.2018.07.10