

Impact of Enhanced External Counterpulsation on Peripheral Circulation

Dierk Werner, Fabian Michalk, Burkhard Hinz, Ulrike Werner, Jens-Uwe Voigt and Werner G. Daniel

ANGIOLOGY 2007 58: 185

DOI: 10.1177/0003319707300013

The online version of this article can be found at:

<http://ang.sagepub.com/content/58/2/185>

Published by:



<http://www.sagepublications.com>

Additional services and information for *Angiology* can be found at:

Email Alerts: <http://ang.sagepub.com/cgi/alerts>

Subscriptions: <http://ang.sagepub.com/subscriptions>

Reprints: <http://www.sagepub.com/journalsReprints.nav>

Permissions: <http://www.sagepub.com/journalsPermissions.nav>

Citations: <http://ang.sagepub.com/content/58/2/185.refs.html>

>> [Version of Record](#) - May 10, 2007

[What is This?](#)

Impact of Enhanced External Counterpulsation on Peripheral Circulation

Dierk Werner, MD,* Fabian Michalk, MD,[†] Burkhard Hinz, PhD,[‡] Ulrike Werner, PhD,[‡] Jens-Uwe Voigt, MD,[†] and Werner G. Daniel, MD[†], *Schwerin; Erlangen-Nuremberg, Germany*

Enhanced external counterpulsation (EECP) is a noninvasive counterpulsation technique that reduces angina and improves exercise capacity in patients with coronary artery disease. Diastolic coronary perfusion is augmented by pneumatic compression of 3 sets of cuffs wrapped around the lower extremities. Although central hemodynamic changes are well investigated, almost no data exist about the changes of peripheral circulation during EECP. In this study, 12 patients with angina and angiographic evidence of coronary artery disease were treated for 1 hour with EECP. In these patients, peripheral artery disease was excluded by duplex sonography. The patients rested 1 hour before EECP in supine position, and they remained in that position for 1 hour after the procedure. Changes of flow volumes and flow pattern of the posterior tibial artery and the brachial artery were measured by sonography at the end of all 3 periods. Furthermore, we measured the concentration of circulating prostanoids at these 3 time points. Averaged flow volume of the posterior tibial artery decreased to $69\% \pm 23\%$ ($P < .05$) during EECP and increased to $133\% \pm 34\%$ ($P < .05$) of baseline 1 hour after the procedure. In contrast, the averaged flow volume of the brachial artery increased by $9\% \pm 4\%$ ($P < .05$) during EECP and returned to baseline values after EECP. The flow pattern of the posterior tibial artery showed a second early diastolic antegrade flow caused by the cuff inflation and a reverse end-diastolic flow after the deflation of the cuffs. These flow changes caused an increase of the pulsatility index by Gosling (397% during EECP), returning to baseline values in the recovery period. Plasma concentrations of circulating prostanoids showed no significant change during EECP. Thus, pedal flow volume decreased to approximately two thirds of baseline during EECP followed by reactive hyperemia even 1 hour after the procedure; however, this decreased perfusion triggered no change of the prostacyclin/thromboxane ratio and was well tolerated by all investigated patients. The observed 4-fold increase of the peripheral pulsatility index supports the thesis of increase of shear-stress-related improvement of endothelial function during EECP.

Angiology 58:185–190, 2007

From the *Department of Cardiology, Helios-Hospital, Schwerin, the [†]Department of Cardiology/Angiology, and the [‡]Institute of Pharmacology, Friedrich-Alexander-University, Erlangen-Nuremberg, Germany

Correspondence: Dierk Werner, MD, Department of Cardiology, Helios-Hospital Schwerin, Wismarsche Strasse 393-397, 19055 Schwerin, Germany

E-mail: dierk.werner@arcor.de

DOI: 10.1177/0003319707300013

©2007 Sage Publications

Introduction

Enhanced external counterpulsation (EECP) has been developed as an additional noninvasive therapeutic option for angina pectoris. In the Multicenter Study on Enhanced External Counterpulsation, the method has been shown to decrease anginal episodes and to extend time to exercise-induced ischemia in patients with stable angina.¹ Furthermore, EECP appears to

be safe and effective in the treatment of angina in patients with impaired systolic function.² EECP received Food and Drug Administration approval for stable and unstable angina, myocardial infarction, and cardiogenic shock in 1995. The procedure is preferably used to manage angina in medically refractory patients who are not candidates for conventional coronary revascularization. At the University of Pittsburgh, the International EECP Patient Registry was founded in 1998. Currently, more than 5000 patients from more than 100 study centers, mainly in the United States are enrolled in the registry.³ The data of that registry confirmed the safety and symptomatic efficiency of the therapy.

EECP operates by electrocardiogram-triggered diastolic inflation and deflation of cuffs wrapped around the lower extremities. In this way, EECP augments diastolic arterial blood pressure, increases diastolic blood flow in the coronary, cerebral, and renal arteries,⁴ and stimulates diuresis and natriuresis.⁵ In contrast to intra-aortic balloon counterpulsation (IABP), EECP is a noninvasive procedure. Until today, a high rate of peripheral vascular problems occurs during IABP. A recent study reported a rate of 10% of cardiosurgical patients suffering from peripheral problems after IABP-like bleedings, dissections, and critical limb ischemia.⁶ Despite its external application, EECP uses the peripheral arterial blood volume to augment the perfusion of the inner organs. In contrast to many clinical studies evaluating the symptomatic effect of this procedure, only a single study measured the effects of EECP on peripheral circulation.⁷ In that study, Cai et al investigated the effect of external counterpulsation in volunteers and in a small group of dogs using different inflation/deflation patterns. The study demonstrated an increase in antegrade and retrograde flow velocities in the legs. Furthermore, they reported a dependency of the net forward blood flow on the period of cuff inflation.

In this study, we asked for the peripheral flow changes under daily conditions, that is, in patients suffering from angina using the EECP inflation/deflation time points as recommended to get maximal diastolic augmentation.⁸ Both possible processes during EECP—increase of endothelial shear stress as well as lower limb ischemia—could alternate the prostacyclin synthesis;^{9,10} therefore, we investigated the impact of EECP on the concentration of circulating prostanoids. Shear-stress-induced improvement of endothelial function is regarded as one possible mode of action of EECP.¹¹ Thus, we

measured the flow-mediated vasodilation (FDM) of the brachial artery to evaluate any acute change of endothelial function caused by the increased pulsatility during EECP.

Subjects and Methods

Twelve consecutive patients with coronary artery disease (61 ± 10 years, 3 female) participated in the study. Inclusion criteria for patients with clinically manifest coronary artery disease were angina pectoris symptoms, the angiographic evidence of hemodynamically relevant stenosis of at least 1 major coronary artery, and at least 2 of the cardiovascular risk factors, arterial hypertension, diabetes mellitus, smoking, hypercholesterolemia, and obesity, as defined by a body mass index of at least 30 kg/m². All participants abstained from smoking on the day of investigation. Oral nitrate therapy was discontinued for 24 hours. Peripheral artery disease was excluded by duplex sonography of the lower extremities. Informed consent was obtained from all study participants according to the declaration of Helsinki.

After 1 hour of rest in supine position, all patients were treated with EECP for 1 hour. The EECP machine (Enhanced External Counterpulsation, Vasomedical Inc., Westbury, NY) operated with a diastolic pressure of 250 to 300 mm Hg. Finger plethysmography was used to maximize diastolic augmentation by early inflation and late deflation of the cuffs. The patients remained in supine position for 1 hour after EECP.

Flow velocities and vessel diameter of the posterior tibial artery were measured with a 15-MHz ultrasound probe (HP 5500) at the end of all 3 study periods (rest, EECP, recovery). Generally, ultrasound investigations are complicated by many artefacts from the movement of the patients by the counterpulsation machine. The posterior tibial artery allows the detection of stable ultrasound signals while the ankle of the patient is fixed by a second investigator. The relative changes of flow volume were calculated from mean flow velocity and arterial diameter. Baseline flow volume was considered to be 100%. The formula of Gosling and King was used for calculation of the pulsatility index (maximal systolic velocity + maximal diastolic velocity/mean velocity).¹²

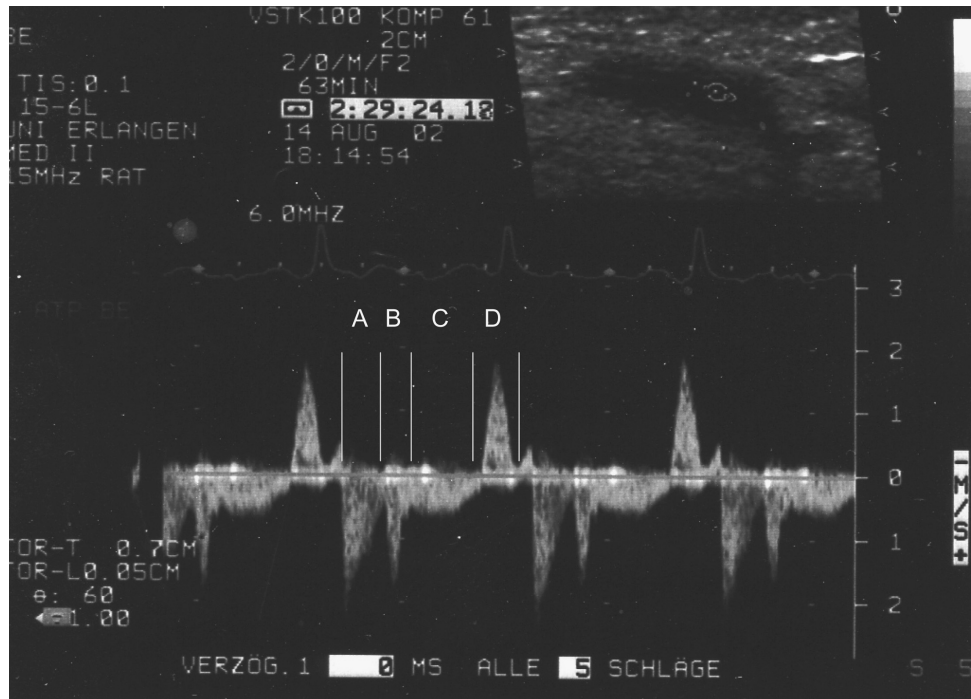


Figure 1. Flow pattern in the posterior tibial artery during EECP (A, systolic forward flow; B, early diastolic flow during cuff inflation; C, diastolic flow while cuffs are inflated; D, late-diastolic backward flow during cuff deflation).

FMD was performed according to the guidelines of the International Brachial Artery Reactivity Task Force.¹³ The brachial artery was assessed by a high-resolution ultrasound probe (15 MHz) in a temperature-controlled room. A cuff at the upper arm was inflated with suprasystolic pressure for 5 minutes. The diameter of the brachial artery was measured at baseline and 1 minute after cuff deflation.

Blood samples were taken at the end of the 3 study periods. Thereafter, circulating prostanoids were measured in the serum of the patients: 6-keto-prostaglandin $F_{1\alpha}$ (stable metabolite of prostacyclin), thromboxane B_2 (stable metabolite of thromboxane A_2), and prostaglandin E_2 . These prostanoids were determined with a commercial kit (Cayman Chemical Company, Ann Arbor, Mich) for enzyme immunoassay.

Results

The procedure was well tolerated by all patients. None complained of any discomfort of the lower extremities. Stable ultrasound signal

could be detected from the posterior tibial artery of all patients during the EECP when the ankle was fixed by a second investigator.

The flow velocities showed a very specific change during EECP. The systolic antegrade flow was followed by a sharp increase of early diastolic antegrade flow velocity caused by the cuff inflation. The end of diastole was characterized by a significant reverse flow after the deflation of the cuffs. Figure 1 shows the typical flow profile in the posterior tibial artery during EECP. These changes caused an approximately 4-fold increase of pulsatility index. Flow pattern and pulsatility index returned to baseline values after EECP.

The arterial diameter of the posterior tibial artery showed no significant change during EECP. In contrast, the posterior tibial artery was significantly dilated during the recovery period. During EECP, a significant decrease of pedal flow volume was observed. Reactive hyperemia was still found 1 hour after EECP. The posterior tibial artery was still significantly dilated and the flow volume increased (Table I).

Despite the significant changes in pulsatility and peripheral flow, no relevant changes of 6-keto-prostaglandin $F_{1\alpha}$, thromboxane B_2 , or prostaglandin E_2 occurred during or after EECP (Table II).

Table I. EECP-caused changes of diameter, flow velocity, and flow volume in the posterior tibial artery.

Measurement After 1 Hour	Diameter (mm)	Mean Flow Velocity (cm/s)	Flow Volume Compared With Baseline (%)	Pulsatility Index (Gosling)
In supine position before EECP	1.9 ± 0.2	14.4 ± 8.1	100 (baseline)	6.9 ± 1.4
EECP	1.8 ± 0.1	11.9 ± 13.5	69.2 ± 23.2*	27.4 ± 9.6*
In supine position after EECP	2.1 ± 0.1**	17.7 ± 15.3	133.1 ± 34.2**/**	6.3 ± 1.7**

* $P < .05$ compared with baseline; ** $P < .05$ compared with EECP.

Table II. EECP-caused changes of plasma concentrations of prostanoids.

Measurement After 1 Hour	6-Keto-Prostaglandin $F_{1\alpha}$ (ng/mL)	Thromboxane B_2 (ng/mL)	Prostaglandin E_2 (ng/mL)
In supine position before EECP	0.61 ± 0.32	22 ± 5	10 ± 2
EECP	0.64 ± 0.50	24 ± 4	9 ± 2
In supine position after EECP	0.62 ± 0.57	23 ± 7	13 ± 8

Table III. Impact of EECP on flow-mediated vasodilation of brachial artery.

Measurement After 1 Hour	Basal Diameter of Brachial Artery (mm)	Diameter After Hyperemia (mm)	Flow-Mediated Dilatation (%)
In supine position before EECP	3.8 ± 0.6	4.0 ± 0.5	6.3 ± 5.3
EECP	3.8 ± 0.5	4.0 ± 0.4	7.2 ± 5.0
In supine position after EECP	3.8 ± 0.6	3.9 ± 0.5	5.7 ± 4.3

The flow pattern in the brachial artery showed a second antegrade diastolic peak during EECP. The diameter of the brachial artery was not significantly affected by the counterpulsation procedure. The mean change of flow volume increased by $9\% \pm 4\%$ ($P < .05$) during EECP and returned to baseline values after EECP. Before EECP, FDM was approximately 6%, indicating an impaired endothelial function in these patients with symptomatic coronary artery disease. One hour of EECP caused a small but not significant increase of FMD (Table III).

Values during recovery also showed no change compared with baseline values.

Discussion

Symptomatic peripheral artery disease is considered as precaution for EECP treatment; however, until now, no peripheral flow measurements exist in patients with symptomatic coronary

artery disease. Thus, we conducted this study and demonstrated a significant reduction of pedal flow, as well as an extensive hyperemia after the procedure. Pedal flow volume was reduced by approximately one third of the flow volume during EECP; however, this reduced perfusion was well tolerated for 1 hour in the investigated patients with excluded peripheral artery disease. In line with this finding, data of 176 patients and volunteers from several of our own studies, as well as the MUST-EECP, indicated no clinical problem of peripheral ischemia during the EECP.^{1,14} Furthermore, the decreased perfusion during EECP did not trigger any change of the 6-keto-prostaglandin F_{1 α} /thromboxane B₂ ratio. This result is in line with an investigation of intra-aortic counterpulsation in dogs.¹⁵ Hoover et al found no significant difference of venous prostacyclin and thromboxane B₂ values between the treated animals and the sham group.

Besides possible clinical side effects for patients with severe peripheral artery disease, it has to be considered that these patients are characterized by reduced arterial vascular volume and reduced muscle mass of the lower extremities. These problems may prevent effective external counterpulsation.^{16,17} In our own study, we investigated the effects of age and atherosclerosis on maximal diastolic augmentation during EECP.¹⁸ We compared diastolic augmentation in healthy young volunteers (mean age, 28 \pm 4 years) and patients with coronary artery disease and at least 2 atherosclerotic risk factors (mean age, 64 \pm 7 years) using the same timing and inflation pressure. The peak augmented diastolic blood pressure was 115 \pm 13 mm Hg in the healthy controls and 100 \pm 24 mm Hg in the patients with atherosclerosis ($P < .05$); however, there is still a controversy if the amount of diastolic augmentation influences the antianginal effect of EECP.^{16,17,19}

The reduced peripheral flow during EECP may have similar physiologic effects like walking therapy in patients with symptomatic peripheral artery disease. Cai et al demonstrated in a dog model that 1 hour of EECP can increase the patency of collateral branches of femoral artery.⁷ A decrease of peripheral vascular resistance after EECP was described by Lawson et al.²⁰ They observed in patients with angina and unimproved radionuclide myocardial perfusion imaging after a course of 35 hours of EECP a slight increase in exercise duration time with a significant decrease of maximal double product (maximal heart

rate \times maximal systolic blood pressure). Cardiac drug therapy was held constant during the study, suggesting that EECP caused a decrease in peripheral vascular resistance. This initial finding was later supported by several studies reporting an improvement of diastolic augmentation and consequently an improved vascular compliance during the course of EECP.^{17,19}

The changes of peripheral flow pattern during EECP were also characterized by increasing pulsatility. The pulsatility index of the posterior tibial artery showed a 4-fold increase. Generally, EECP yields to a second diastolic pulse wave in all arterial vessels.⁴ By this way, EECP increases shear stress and flow pulsatility. After the single intervention, we observed only a slight, nonsignificant increase of FMD; however, Shechter et al studied the FMD after the usual scheme of 35 hours of EECP therapy.¹¹ They found an increase from 3.0% to 8.2% ($P < .01$), indicating improvement of endothelial function as a possible mode of action of EECP.

Conclusion

This study showed that the pedal blood flow decreases to two thirds of resting values during EECP accompanied by reactive hyperemia after the procedure; however, data from many different clinical studies demonstrate that EECP does not bear any risk of clinical relevant peripheral ischemia in patients without manifest peripheral artery disease. Furthermore, circulating prostanoids as markers of peripheral ischemia showed no change during EECP. Flow pattern of the posterior tibial artery was characterized by a 4-fold increase of their pulsatility index supporting the hypothesis of increased shear stress during EECP.

REFERENCES

1. Arora RR, Chou TM, Jain D, et al: The Multicenter Study on Enhanced External Counterpulsation (MUST-EECP): Effect of EECP on exercise-induced myocardial ischemia and anginal episodes. *J Am Coll Cardiol* 33:1833-1840, 1999.
2. Soran O, Kennard ED, Kelsey SF, et al: Enhanced external counterpulsation as treatment for chronic

- angina in patients with left ventricular dysfunction: A report from the International EECF Patient Registry (IEPR). *Congest Heart Fail* 8:297-302, 2002.
3. Michaels AD, Barsness GW, Soran O, et al: Frequency and efficacy of repeat enhanced external counterpulsation for stable angina pectoris (from the International EECF Patient Registry). *Am J Cardiol* 95:394-397, 2005.
 4. Werner D, Schneider M, Weise M, et al: Pneumatic external counterpulsation: A new noninvasive method to improve organ perfusion. *Am J Cardiol* 84:950-952, 1999.
 5. Werner D, Traegner P, Wawer A, et al: Enhanced external counterpulsation: A new technique to augment renal function in liver cirrhosis. *Nephrol Dial Transplant* 20:920-926, 2005.
 6. Mandak J, Lonsky V, Dominik J, et al: Vascular complications of the intra-aortic balloon counterpulsation. *Angiology* 56:69-74, 2005.
 7. Cai D, Wu R, Shao Y: Experimental study of the effect of external counterpulsation on blood circulation in the lower extremities. *Clin Invest Med* 23:239-247, 2000.
 8. Suresh K, Simandl S, Lawson WE, et al: Maximizing the hemodynamic benefit of enhanced external counterpulsation. *Clin Cardiol* 21:649-653, 1998.
 9. Rossi P, Kuukasjarvi P, Riutta A, et al: Prostacyclin and thromboxane A2 synthesis are increased in acute lower limb ischemia. *Prostaglandin Leukot Essent Fatty Acids* 55:433-436, 1996.
 10. Hanada T, Hashimoto M, Nosaka S, et al: Shear stress enhances prostacyclin release from endothelial cells. *Life Sci* 66:215-220, 2000.
 11. Shechter M, Matetzky S, Feinberg MS, et al: External counterpulsation therapy improves endothelial function in patients with refractory angina pectoris. *J Am Coll Cardiol* 42:2090-2095, 2003.
 12. Gosling RG, King HD: Arterial assessment by Doppler shift ultrasound. *Proc R Soc Med* 67:447-449, 1974.
 13. Coretti MC, Anderson TJ, Benjamin EJ, et al: Guidelines for the ultrasound assessment of endothelial-dependent flow-mediated vasodilation of the brachial artery. *J Am Coll Cardiol* 39:257-265, 2002.
 14. Werner D, Kropp J, Schellong S, et al: Practicability and limitations of enhanced external counterpulsation as an additional treatment for angina. *Clin Cardiol* 26:525-529, 2003.
 15. Hoover EL, Kharma B, Ross M, et al: The temporal relationship in arterial and venous prostacyclin and thromboxane activity during 24 hours of intraaortic balloon counterpulsation in dogs. *Ann Thorac Surg* 46:661-665, 1988.
 16. Michaels AD, Kennard ED, Kelsey SE, et al: Does higher diastolic augmentation predict clinical benefit from enhanced external counterpulsation? Data from the International EECF Patient Registry (IEPR). *Clin Cardiol* 24:453-458, 2001.
 17. Lakshmi MV, Kennard ED, Kelsey SF, et al: Relation of the pattern of diastolic augmentation during a course of enhanced external counterpulsation (EECP) to clinical benefit (from the International EECF patient Registry [IEPR]). *Am J Cardiol* 89:1303-1305, 2002.
 18. Werner D, Marthol H, Brown CM, et al: Changes of cerebral blood flow velocities during enhanced external counterpulsation. *Acta Neurol Scand* 107:1-7, 2003.
 19. Stys T, Lawson WE, Hui KCK, et al: Acute hemodynamic effects and angina improvement with enhanced external counterpulsation. *Angiology* 52:653-658, 2001.
 20. Lawson WE, Hui JCK, Zheng ZS, et al: Improved exercise tolerance following enhanced external counterpulsation: Cardiac or peripheral effect? *Cardiology* 87:271-275, 1996.