

Impact of Full Spectrum Endoscopy® (Fuse®, EndoChoice®) on adenoma detection: a prospective French pilot study

Jean-Philippe Ratone^a, Erwan Bories^a, Fabrice Caillol^a, Christian Pesenti^a, Sébastien Godat^a, Floriane Sellier^a, Solene Hoibian^a, Marine Landon^a, Cécilia Servajean^a, Chiara De Cassan^a, Valentin Lestelle^a, Jean-Patrick Casanova^a, Flora Poizat^b, Marc Giovannini^a

Paoli-Calmettes Institute, Marseille, France

Abstract

Background Currently, colonoscopy and polypectomy are the gold standard methods for the prevention of incident cases of colorectal cancer. The use of a new colonoscope (Fuse®, EndoChoice®) with a larger view of up to 330° appears to improve the adenoma detection rate (ADR). We performed a prospective observational study concerning this scope. The primary endpoint was potentially omitted adenomas (POA), i.e. adenomas seen on the side screens that will not appear on the central display during colonoscopy withdrawal without oriented movements. Secondary endpoints included our ADR, Fuse® impact on ADR, time to cecal intubation and withdrawal time.

Methods We performed a single-center prospective study in one French center. We enrolled patients over 18 years of age between January 2015 and March 2016.

Results We included 141 patients; 3 were excluded because their colonoscopies were incomplete. Our study included 78 men and 60 women (sex ratio 1.3). The mean age was 60.4 years. A total of 130 polyps were resected. In all, 88/130 were adenomas (68%) and 34/88 adenomas (39%) were POA. The mean time to cecum was 10 min, and the mean withdrawal time was 12 min. ADR was 35% for men and 31% for women. The estimated ADR without POA was 29% for men and 19% for women.

Conclusions The Fuse® system appears to be safe and efficient. POA represented 39% of all adenomas. The impact of the panoramic view on the ADR was considered substantial. The main limitations are the lack of randomization and the absence of a control group.

Keywords Panoramic view, adenoma detection rate, missed adenomas

Ann Gastroenterol 2017; 30 (5): 1-6

Introduction

Colorectal cancer (CCR) is a major public health problem. Risk factors such as personal and family history are well

^aEndoscopy Unit (Jean-Philippe Ratone, Erwan Bories, Fabrice Caillol, Christian Pesenti, Sébastien Godat, Floriane Sellier, Solene Hoibian, Marine Landon, Cécilia Servajean, Chiara De Cassan, Valentin Lestelle, Jean-Patrick Casanova, Marc Giovannini); ^bPathology Unit (Flora Poizat), Paoli-Calmettes Institute, Marseille, France

Conflict of Interest: None

Correspondence to: Dr Jean-Philippe Ratone, Paoli-Calmettes Institute, Endoscopy Unit, 232 Boulevard de sainte Marguerite, 13009 Marseille, France, e-mail: jpratone@hotmail.fr

Received 21 March 2017; accepted 12 June 2017; published online 5 July 2017

DOI: <https://doi.org/10.20524/aog.2017.0176>

known. Colonoscopy improves the detection of lesions at a curable stage. Endoscopic resection of colonic adenomas reduces cancer-related mortality rate by 31 or 53% according to two main studies [1,2]. However, this protection is imperfect, especially for carcinomas of the right colon, and interval cancer represents 3-5% of CCRs [3,4]. To reduce the interval cancer rate, several recommendations have been proposed to improve the quality of colonoscopy. One of the most relevant colonoscopy quality indicators is the adenoma detection rate (ADR). The ADR is inversely proportional to the missed cancer rate [5]. The American Society for Gastrointestinal Endoscopy (ASGE) recommends achieving an ADR of higher than 20% and 30%, respectively, for female and male patients [6].

Several technologies have been evaluated to improve the ADR. The use of high-definition endoscopy had a low impact on the ADR [7]. Virtual chromoendoscopy shows no or only a small difference. Various techniques have been used with some interesting results [8-15]: cap-assisted colonoscopy [10], Endocuff®-assisted colonoscopy [10,14] and Third-Eye®

Retroscope® colonoscopy [13]. Their main drawback is the change in the colonoscopy technique; passing through the working channel is a major limitation [10-15]. Moreover, proximal colon retroflexion was not recommended [16,17].

More recently, two new colonoscopes with wide angles of view were developed with promising results: “Extra Wide Angle View” (Olympus® medical systems, Tokyo, Japan) and Full Spectrum Endoscopy® (Fuse®, EndoChoice®, GA, USA) [18-21]. The “Extra Wide Angle View” is allowed on the lateral backward view of 16/28 adenomas [18]. Fuse® colonoscopy is safe [19,20] and has been shown in a back-to-back study to significantly decrease the miss rate of adenomas [21]. Both techniques have the advantage of avoiding any modification of the colonoscopy procedure and maintaining a free working channel.

Fuse® is equipped with three cameras that allow up to a 330-degree angle of view; each camera provides a view of 170° (Fig. 1). A tandem, randomized, multicenter study showed promising results: an increase in the adenoma rate of 41% during a second colonoscopy, including 15% of advanced adenomas [21]. The aim of this first French prospective observational study was to evaluate the efficacy and safety of the Fuse® system.

Patients and methods

Study design and patients

This single-center prospective study enrolled patients over 18 years of age referred for a colonoscopy between January 2015 and March 2016. Exclusion criteria were a history of colectomy, genetic polyposis, a planned therapeutic colonoscopy (endoscopic mucosal resection or endoscopic submucosal resection), and bad bowel preparation (Boston bowel preparation scale [BBPS]<7). The BBPS is valid and reliable scale for bowel preparation: three regions of the colon receive a segment score from 0 to 3 for a total BBPS score ranging from 0 to 9 [22]. Patients with incomplete colonoscopies were excluded from the final analysis.

The primary endpoint was potentially omitted adenomas (POA), i.e., adenomas seen only on the side cameras during the withdrawal of the colonoscope and without angulation of the tip. Polyps potentially omitted (PPO) were defined as observable polyps on lateral screens during colonoscope withdrawal that required maneuvers to be recovered on the central screen. An example of a PPO is presented in Fig. 2. The POA was therefore defined as a PPO that was considered to be an adenoma by the pathologist. Secondary endpoints included ADR, Fuse® impact on ADR, time to cecal intubation and withdrawal time.

Procedures

All patients underwent bowel preparation with either a polyethylene glycol-based solution or a sodium picosulfate

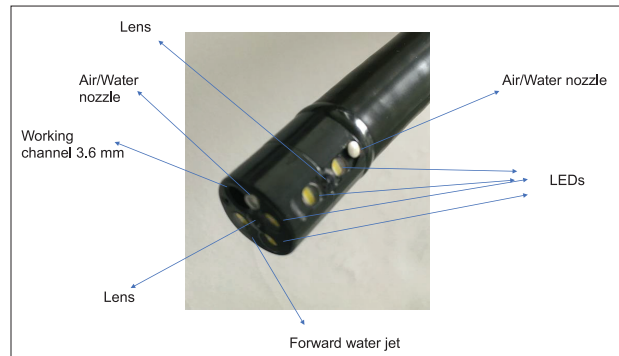


Figure 1 The Fuse® scope

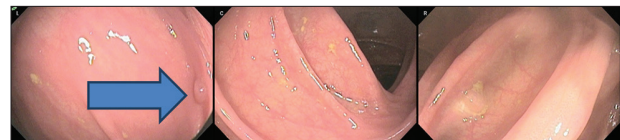

Figure 2 Example of potentially omitted adenoma on left screen

preparation. If the operator considered the preparation to be poor (BBPS<7), the patient was not included. Patients underwent conscious sedation with propofol or general anesthesia with oral intubation. All procedures were performed with a Fuse® adult standard video-colonoscopy (168 cm working length, 12.8 mm scope outer diameter, 3.8 mm working channel). CO₂ insufflation was used. Colonoscopies were performed by 6 senior operators and 5 fellows under direct supervision. Colonic polyps were resected during the procedure if necessary. Polyps were removed if they were identified as other than diminutive (1-2 mm) rectal polyps thought to be hyperplastic in nature. The removal techniques included polypectomy with diathermic forceps or cold snare, and endoscopic mucosal resection.

At the end of the procedure, a standardized computerized questionnaire was completed by the operator(s). Age, sex, colonoscopy indication, number of polyps, number of PPO and POA, complications, time to cecal intubation, withdrawal time and type of operator (senior vs. fellow) were recorded prospectively. The histology of polyps was added subsequently. Individuals who had an incomplete colonoscopy were not included in the final analysis.

Statistical analysis

Data were collected by the operators and input into a spreadsheet. Continuous variables are expressed as mean ± standard deviation.

Ethical considerations

Patients were included prospectively after informed consent during consultation or hospitalization. Institutional review board and local medical ethics committee approval was obtained.

Results

This study enrolled 141 patients between January 2015 and March 2016. Three patients were excluded because their colonoscopies were incomplete. The final analysis included 78 men and 60 women (sex ratio 1.3). The mean age was 60.4 years. The colonoscopy was performed in subjects with a familial history of CCR, a personal history of adenoma, or for digestive symptoms in 22, 46, and 70 subjects, respectively. Patient characteristics are presented in Table 1.

Complete colonoscopy was achieved in 97.9% (138/141) patients. In two cases, the colonoscopy was incomplete because of a “fixed” sigmoid without visible stricture: the colonoscopy could be completed with a pediatric scope (PENTAX medical®, Japan). In one case, the colonoscopy was incomplete because of the formation of a non-reducible sigmoid loop despite several attempts. There was no colonoscopy-related perforation. The mean time to reach the cecum was 10 min, and the mean withdrawal time was 12 min. A total of 91 colonoscopies (66%) were performed by fellows under senior supervision, and 34% were performed by seniors. The main results are shown in Table 2.

Three CCRs were found. One CCR (in the left colon) was seen mainly on a lateral screen in a diverticulum and specific maneuvers were required to visualize it in a standard forward view, but we did not consider it an omitted lesion. These three CCRs were not counted as adenomas. All patients underwent surgery because they had no synchronous metastasis.

A total of 130 polyps were resected without complications. One 10-mm adenoma could not be resected given the poor visibility on the central screen, despite multiple endoscopic movements. A second colonoscopy was proposed to the patient, but he refused. Among the resected polyps, 88/130 were adenomas (68%). The pathology of all adenomas was low grade dysplasia. In all, 52/130 polyps were classified as PPO, including 34 adenomas. Therefore, 34/88 adenomas (39%) were POA. The POA location included the left colon in 18/34 cases (53%), the transverse colon in 10 cases (29%) and the right colon in 6 cases (18%). The study design is shown in Fig. 3. In all, 8/34 (24%) POAs were between 10 and 15 mm in size, while the others were less than 10 mm in size (Table 3).

The global ADR was 34% for men (35% if one likely adenoma that could not be resected was included) and 31% for women. The estimated ADR without POA was 29% for men and 19% for women; in this situation, POA were not counted. These ADRs and estimated ADRs are presented in Table 4.

Discussion

The results of our study support the use of the Fuse® system for several reasons. First, POA represented 39% of all adenomas, which confirms our primary endpoint. The results are in agreement with a previous study that described the safety of this new scope [19-21].

The time to achievement of the Fuse® colonoscopy was acceptable; many endoscopies (66%) were performed by

Table 1 Patient characteristics

Patients characteristics	N=138
Mean age (years)	60.4
Male	78
Female	60
Sex ratio (Male: Female)	1.3
Indication for colonoscopy	
Familial history of CRC	22
Personal history of adenoma	46
Digestive clinical signs	70

CRC, colorectal cancer

Table 2 Main results

Parameters	Values
Polyps	N=130
Adenomas	N=88
POA	N=34
POA in left colon (included sigmoid)	N=18
POA in transverse colon	N=10
POA in right colon	N=6
Colorectal cancers	N=3
Global ADR (%)	34%
Men ADR (%)	35%
Women ADR (%)	31%
Time to cecum (min)	10
Withdrawal time (min)	12

POA, potentially omitted adenomas; ADR, adenoma detection rate

Table 3 Size of potentially omitted adenoma

Size of potentially omitted adenoma	N=34
<10 mm	26 (76%)
10-15 mm	8 (24%)
>15 mm	0 (0%)

Table 4 Adenoma detection rate (ADR), estimated adenoma detection rate without lateral screens and ASGE guidelines

Method of ADR estimation	ADR men	ADR women
With Fuse® complete view (330°)	35%	31%
With standard forward view (170°)	Estimated at 29%	Estimated at 19%
ASGE Guidelines	≥30%	≥20%

ASGE, American Society for Gastrointestinal Endoscopy

fellows under senior supervision. Furthermore, the resection of a PPO could be time-consuming, even if polypectomy was performed in all cases except one. Regarding the detection

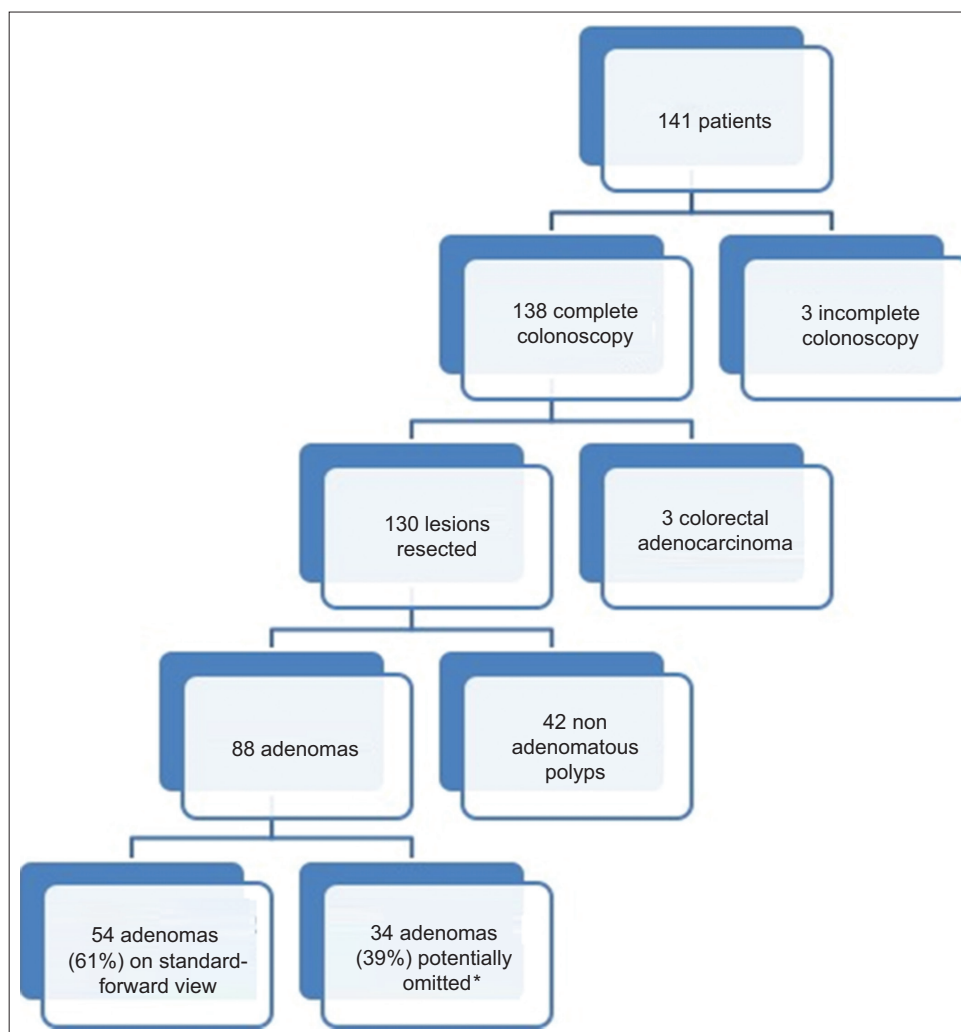


Figure 3 Study design

* A POA (potentially omitted adenoma) was an adenoma seen only on a side screen during withdrawal of the endoscope, requiring at least an ascent of the endoscope and lateral bumpers to be seen on the central screen. The presence of a POA was established by a senior endoscopist

of adenomas, the results of seniors and fellows were not analyzed separately. Indeed, the seniors assisted the fellows during all colonoscopies and it appears unlikely that the ADR was underestimated, given that the screens were analyzed by both operators. The only potential influence on colonoscopy was probably the duration of the examination, although these fellows had performed colonoscopies for at least 3 years.

The ADR for men was congruent with ASGE guidelines [6] since it was higher than 30%. The ADR for women was also in agreement with ASGE guidelines. The impact of the panoramic view on ADR was considered significant, given the 10% increase in both sexes (Table 2).

Our POA rate is compatible with back-to-back studies. Indeed, many studies have shown that up to 20% of adenomas are missed during colonoscopy because of poor visualization behind the folds and the inner curves of flexures [23]. Despite the most objective evaluation possible (the main limitation of this study), it is likely that some POAs would have been seen

with a standard colonoscopy, but not all. Therefore, a rate of 20% missed adenomas is probably very close to reality. Before a polyp was described as a PPO, insufflation was of course used, so that a polyp located behind a badly insufflated fold would not be classed as a PPO. In any case, the feasibility of Fuse® colonoscopy has been demonstrated given the good ADR.

During the evolution of the technique, quality indicators of colonoscopy have been clearly defined by professional societies [6]. Some criteria are obvious and are recommended, including good bowel preparation, informed consent, withdrawal time longer than 6 min, appropriate indication, cecal intubation, perforation lower than 1/1000, etc. [6,22,24,25]. Although the results are not spectacular in the literature, high definition and virtual chromoendoscopy ameliorate the work quality of endoscopists [7,26]. Most of these quality indicators are intended to increase the ADR, because it is a major indicator of quality and it is measurable [5,6]. It has been

estimated that 10% of the colonic surface remains to be observed under the standard forward-viewing colonoscope, even with good bowel preparation [27]. Many endoscopic techniques have shown excellent results in preliminary studies [10-15,28], but generalization is limited by changes in the technique of colonoscopy, occupation of the working channel, or increased time.

Fuse[®] colonoscopy has a low learning curve. The tandem colonoscopy trial of Gralnek *et al* demonstrated this, as did a second recently published study [19,21]. The cost and practice were the same, and it is easy to expand the use of colonoscopy to 330°, contrary to many other technologies. For example, the Third Eye[®] Retroscope[®] and Third Eye[®] Panoramic[™] devices (Avantis Medical Systems, Sunnyvale, CA, USA) are very interesting and efficient (they exhibited an increased adenoma rate of 23.2%), but usual practice appears illusory on account of the working channel occupation and the learning curve [13].

However, our study has some limitations. First, is the possible subjectivity of the primary endpoint. Indeed, though operators described what they considered to be PPOs during scope withdrawal, a certain diagnosis was difficult. Nevertheless, a non-PPO polyp is also first seen on the side screen and then on the central screen. Of course, we did not consider this situation to resemble a PPO, because PPOs required oriented movements to find them on a central screen, but subjectivity remains. Other associated limitations are the lack of randomization or a control group.

Contrary to Gralnek *et al*, we do not have “advanced” POA. One explanation could be the exclusion of patients referred for endoscopic mucosal resection (EMR) or endoscopic submucosal dissection (ESD). The resection of a polyp behind the folds could be time-consuming but resection is helped by a panoramic view. Among the POA, 8/39 (24%) had a size between 10 and 15 mm. This category of patients has thus benefited from the Fuse[®] technology, which can be questionable for patients with an infra-centimeter POA. The study by Brand *et al* describes this limit for new technologies designed to increase adenoma detection [29].

In the future, the development of lateral working channels could completely revolutionize colonoscopy, especially for EMR or ESD. The industry will probably develop other similar scopes in the coming years, and patients and doctors may agree to have a narrow view while a panoramic vision is possible.

Recently, a high-quality randomized study questioned the utility of Fuse[®] in the detection of adenomas in a population with a positive fecal immunochemical test: no difference was demonstrated in ADR [30]. This new result calls into question the superiority of the Fuse[®], suggested by the feasibility studies and demonstrated by the tandem study of Gralnek *et al*. This very interesting study encourages further clinical research into this scope to assess whether it represents a minor or major improvement in CCR screening. Several types of endoscopy center (expert or not) should be involved in future randomized trials for “real-life” studies.

Summary Box

What is already known:

- The adenoma detection rate is inversely proportional to the missed cancer rate
- Endoscopic resection of colonic adenomas reduces cancer-related mortality rate by 31 or 53% according to two main studies
- The panoramic view has been shown to be safe and may increase adenoma detection

What the new findings are:

- The feasibility of Fuse[®] colonoscopy is confirmed
- The panoramic view may detect potentially admitted adenomas in up to 39%
- This technique may improve adenoma detection for experienced physicians and could be particularly helpful for trainees

References

1. Zauber AG, Winawer SJ, O'Brien MJ, et al. Colonoscopic polypectomy and long-term prevention of colorectal-cancer deaths. *N Engl J Med* 2012;**366**:687-696.
2. Nishihara R, Wu K, Lochhead P, et al. Long-term colorectal-cancer incidence and mortality after lower endoscopy. *N Engl J Med* 2013;**369**:1095-1105.
3. Bressler B, Paszat LF, Chen Z, Rothwell DM, Vinden C, Rabeneck L. Rates of new or missed colorectal cancers after colonoscopy and their risk factors: a population-based analysis. *Gastroenterology* 2007;**132**:96-102.
4. Heresbach D, Barrioz T, Lapalus MG, et al. Miss rate for colorectal neoplastic polyps: a prospective multicenter study of back-to-back video colonoscopies. *Endoscopy* 2008;**40**:284-290.
5. Corley DA, Jensen CD, Marks AR, et al. Adenoma detection rate and risk of colorectal cancer and death. *N Engl J Med* 2014;**370**:1298-1306.
6. Rex DK, Schoenfeld PS, Cohen J, et al. Quality indicators for colonoscopy. *Gastrointest Endosc* 2015;**81**:31-53.
7. Subramanian V, Mannath J, Hawkey CJ, Ragunath K. High definition colonoscopy vs. standard video endoscopy for the detection of colonic polyps: a meta-analysis. *Endoscopy* 2011;**43**:499-505.
8. Ramsoekh D, Haringsma J, Poley JW, et al. A back-to-back comparison of white light video endoscopy with autofluorescence endoscopy for adenoma detection in high-risk subjects. *Gut* 2010;**59**:785-793.
9. Pasha SF, Leighton JA, Das A, et al. Comparison of the yield and miss rate of narrow band imaging and white light endoscopy in patients undergoing screening or surveillance colonoscopy: a meta-analysis. *Am J Gastroenterol* 2012;**107**:363-370.
10. Pohl H, Bensen SP, Toor A, et al. Cap-assisted colonoscopy and detection of Adenomatous Polyps (CAP) study: a randomized trial. *Endoscopy* 2015;**47**:891-897.
11. Pioche M, Matsumoto M, Takamaru H, et al. Endocuff-assisted colonoscopy increases polyp detection rate: a simulated randomized study involving an anatomic colorectal model and 32

- international endoscopists. *Surg Endosc* 2016;**30**:288-295.
12. DeMarco DC, Odstrcil E, Lara LF, et al. Impact of experience with a retrograde-viewing device on adenoma detection rates and withdrawal times during colonoscopy: the Third Eye Retroscope study group. *Gastrointest Endosc* 2010;**71**:542-550.
 13. Leufkens AM, DeMarco DC, Rastogi A, et al; Third Eye Retroscope Randomized Clinical Evaluation [TERRACE] Study Group. Effect of a retrograde-viewing device on adenoma detection rate during colonoscopy: the TERRACE study. *Gastrointest Endosc* 2011;**73**:480-489.
 14. van Doorn SC, van der Vlugt M, Depla A, et al. Adenoma detection with Endocuff colonoscopy versus conventional colonoscopy: a multicentre randomised controlled trial. *Gut* 2017;**66**:438-445.
 15. Halpern Z, Gross SA, Gralnek IM, et al. Comparison of adenoma detection and miss rates between a novel balloon colonoscope and standard colonoscopy: a randomized tandem study. *Endoscopy* 2015;**47**:301.
 16. Harrison M, Singh N, Rex DK. Impact of proximal colon retroflexion on adenoma miss rates. *Am J Gastroenterol* 2004;**99**:519-522.
 17. Hewett DG, Rex DK. Miss rate of right-sided colon examination during colonoscopy defined by retroflexion: an observational study. *Gastrointest Endosc* 2011;**74**:246-252.
 18. Uraoka T, Tanaka S, Oka S, et al. Feasibility of a novel colonoscope with extra-wide angle of view: a clinical study. *Endoscopy* 2015;**47**:444-448.
 19. Song JY, Cho YH, Kim MA, Kim JA, Lee CT, Lee MS. Feasibility of full-spectrum endoscopy: Korea's first full-spectrum endoscopy colonoscopic trial. *World J Gastroenterol* 2016;**22**:2621-2629.
 20. Gralnek IM, Segol O, Suissa A, et al. A prospective cohort study evaluating a novel colonoscopy platform featuring full-spectrum endoscopy. *Endoscopy* 2013;**45**:697-702.
 21. Gralnek IM, Siersema PD, Halpern Z, et al. Standard forward-viewing colonoscopy versus full-spectrum endoscopy: an international, multicentre, randomised, tandem colonoscopy trial. *Lancet Oncol* 2014;**15**:353-360.
 22. Lai EJ, Calderwood AH, Doros G, Fix OK, Jacobson BC. The Boston bowel preparation scale: a valid and reliable instrument for colonoscopy-oriented research. *Gastrointest Endosc* 2009;**69**:620-625.
 23. van Rijn JC, Reitsma JB, Stoker J, Bossuyt PM, van Deventer SJ, Dekker E. Polyp miss rate determined by tandem colonoscopy: a systematic review. *Am J Gastroenterol* 2006;**101**:343-350.
 24. Barclay RL, Vicari JJ, Doughty AS, Johanson JF, Greenlaw RL. Colonoscopic withdrawal times and adenoma detection during screening colonoscopy. *N Engl J Med* 2006;**355**:2533-2541.
 25. Sawhney MS, Cury MS, Neeman N, et al. Effect of institution-wide policy of colonoscopy withdrawal time > or = 7 minutes on polyp detection. *Gastroenterology* 2008;**135**:1892-1898.
 26. Rastogi A, Early DS, Gupta N, et al. Randomized, controlled trial of standard-definition white-light, high-definition white-light, and narrow-band imaging colonoscopy for the detection of colon polyps and prediction of polyp histology. *Gastrointest Endosc* 2011;**74**:593-602.
 27. East JE, Saunders BP, Burling D, Boone D, Halligan S, Taylor SA. Surface visualization at CT colonography simulated colonoscopy: effect of varying field of view and retrograde view. *Am J Gastroenterol* 2007;**102**:2529-2535.
 28. Leung FW, Amato A, Ell C, et al. Water-aided colonoscopy: a systematic review. *Gastrointest Endosc* 2012;**76**:657-666.
 29. Brand EC, Dik VK, van Oijen MG, Siersema PD. Missed adenomas with "behind-folds visualizing" colonoscopy technologies compared with standard colonoscopy: a pooled analysis of 3 randomized back-to-back tandem colonoscopy studies. *Gastrointest Endosc* 2017 Jan 6. [Epub ahead of print]
 30. Hassan C, Senore C, Radaelli F, et al. Full-spectrum (FUSE) versus standard forward-viewing colonoscopy in an organised colorectal cancer screening programme. *Gut* 2016 Aug 9. [Epub ahead of print]