

OPEN

Impact of geography and surgical approach on recurrence in global pilonidal sinus disease

Dietrich Doll^{1*}, Andriu Orlik², Katharina Maier¹, Peter Kauf³, Marco Schmid³, Maja Diekmann¹, Andreas P. Vogt², Verena K. Stauffer⁴ & Markus M. Luedi²

Pilonidal sinus disease (PSD) is increasing globally. A recent meta-analysis and merged-data analysis showed that recurrence rates in PSD depend essentially on follow-up time and specific surgical procedures. However, the global distribution of surgical approaches and respective recurrence rates have never been studied in PSD. We aimed at studying the impact of geographic distribution of surgical approaches to treat PSD and subsequent geography-specific recurrence rates. We searched relevant databases as described previously. Recurrence rates were then associated with reported follow-up times and geographic origin. We simulated individual patients to enable analogy across data. Globally, recurrence rates range from 0.3% for Limberg/Dufourmental approaches (95% CI 0.2–0.4) and flaps (95% CI 0.1–0.5) and up to 6.3% for incision (95% CI 3.2–9.3) at 12 months. Recurrence rates range from 0.3% for Karydakias/Bascom approaches (95% CI 0.0–0.8) up to 67.2% for incision (95% CI 7.5–100) in the USA, and 0.0% for primary asymmetric closure in Germany (95% CI 0.0–0.0). Our analysis shows that recurrence rates in PSD not only depend on therapeutic approaches and follow-up time but also on geography. Primary asymmetric closure and various flap techniques remain superior regardless of the geographical region. Some approaches have extraordinarily good outcomes in specific countries.

The incidence of pilonidal sinus disease is increasing globally. About 100/100,000 inhabitants per year are affected in Germany¹, with even higher numbers reported for Turkey². Since 2013, American, German and Italian societies have published guidelines on best clinical practice^{3–5}. While debate over the disease's etiology and pathomechanisms is ongoing^{6–9}, we showed recently that recurrence rates in PSD depend essentially on follow-up time and the specific surgical procedure used¹⁰. In a meta-analysis and merged-data analysis of surgical treatment options, follow-up times, and recurrence rates in 89,583 patients, recurrence after Limberg/Dufourmental operations was as low as 0.6% at 12 months and 1.8% at 24 months postoperatively. Recurrence after Karydakias/Bascom procedures was 0.2% (95% CI 0.1–0.3%) at 12 months and 0.6% (95% CI 0.5–0.8%) at 24 months postoperatively. Primary midline closure after 240 months was associated with recurrence rates of 67.9% (95% CI 53.3–82.4%)¹⁰ (Table 1).

Geography – and thereby specific genetic mechanisms, healthcare settings and socioeconomic factors – has been shown to affect manifold diseases, and must be considered when studying a disease worldwide^{11,12}. However, the global distribution of surgical approaches and the geography of recurrence rates have never been assessed in PSD, one of the most frequent surgical diagnoses¹.

We therefore studied the impact of geographic distribution of surgical approaches on the treatment of PSD and the associated recurrence rates in order to evaluate the quality of selected procedures. We used our previously established database of publications from the years 1833–2017 to study PSD treatment strategies, follow-up time, and country of origin¹⁰. We hypothesized that geography affects recurrence rates in PSD and an extensive analysis of data will allow specific recommendations for different geographic regions.

¹Department of Procto-Surgery, St. Marien-Krankenhaus Vechta, Teaching Hospital of the Hannover University, 49377, Vechta, Germany. ²Department of Anesthesiology and Pain Medicine, Inselspital, Bern University Hospital, University of Bern, 3010, Bern, Switzerland. ³Biomedical Statistics PROGNOSEX AG, 8001, Zurich, Switzerland. ⁴Sonnenhofspital, Lindenhofgruppe, 3010, Bern, Switzerland. *email: Dietrich.Doll@kk-om.de

Surgical method (total patients included)	12 months		24 months		60 months		120 months		Citations
	RR in % (95% CI)	Nr. at risk	RR in % (95% CI)	Nr. at risk	RR in % (95% CI)	Nr. at risk	RR in % (95% CI)	Nr. at risk	
Primary open (6351)	1.3 (1.0–1.7)	5715	4.2 (3.6–4.8)	3496	13.9 (12.2–15.6)	1222	28.1* (23.9–32.4)	241*	20–122
Primary median closure (15011)	3.1 (2.8–3.5)	12,484	8 (7.4–8.6)	6956	14.9 (13.8–15.9)	2505	27.9 (25.5–30.4)	631	20,24,27,29,31,34–38,44,46,48,52,54,56,57,59,61–66,69,73–78,81–84,86,89–91,93–100,106–108,115,118,122–248
Primary asymmetric closure (2538)	0.6 (0.3–0.9)	2432	1.1 (0.7–1.6)	1807	2.7 (1.9–3.6)	1205	6.3* (4.8–7.7)	937*	65,67,100,129,183,192,249–263
Karydakis/Bascom (6276)	0.5 (0.3–0.7)	5868	1.6 (1.2–2.0)	3630	6.3 (5.0–7.5)	853	NA	NA	16,21,29,41,49,66,78,88,133,163,172,184,189,192,195,199,200,202,262–316
Limberg/Dufourmentel (11470)	0.3 (0.2–0.4)	10,937	1.5 (1.2–1.7)	7527	5.9* (5.1–6.7)	1638*	NA	NA	25,28,31,33,52,56,67,92,100,127,128,130,131,137,139,140,148,149,163,165,170,172,174,182,190–192,201,205,207,208,231–233,243,246,267,268,270,272–274,291,292,295,297,305–309,311–313,317–398
Marsupialization (1896)	2.2 (1.4–2.9)	1253	5.7 (4.2–7.1)	800	7.8* (5.9–9.6)	566*	NA	NA	30,37,46,60,65,69,71,77,78,89,97,104,110,113,137,152,156,175,207,208,332,399–416
Limited excision (3346)	5.1 (4.2–6.0)	2746	7.4 (6.2–8.5)	1810	13.1 (11.1–15.0)	804	NA	NA	31,34,52,60,61,69,75,82,87,96,98,103,112,116,136,138,170,187,212,220,229,241,290,299,311,344,399,414,417–436
Pit picking (5432)	2.8 (2.4–3.3)	5221	6.6* (5.9–7.4)	1962*	14.2 (12.5–15.9)	1401	NA	NA	16,22,55,69,109,193,216,278,298,309,437–452
Flaps (3073)	0.3 (0.1–0.5)	2902	1.1* (0.7–1.5)	1687*	6.4* (4.9–8.0)	708*	NA	NA	91,98,100,108,135,173,185,191,193,227,309,322,343,362,369,375,379,424,434,453–488
Incision and drainage (293)	6.3* (3.2–9.3)	259*	22.3 (15.8–28.9)	243	36.8* (26.3–47.2)	121*	NA	NA	20,52,55,77,184,212,223,253,489
Phenol only (1453)	1.6* (0.9–2.3)	1244*	14.7 (12.1–17.3)	687	NA	NA	NA	NA	53,76,114,242,363,385,490–505
Laser treatment (77)	2.2* (0.0–4.8)	74*	11.8* (0.8–22.9)	47*	NA	NA	NA	NA	506–508
Others (1363)	2.8 (1.9–3.8)	1247	6.6* (4.8–8.4)	624*	19.8 (15.7–23.8)	498	NA	NA	15,16,309,430,489,509–523
Partial closure (202)	0.6* (0.0–1.4)	202*	1.1* (0.0–2.5)	201*	11.2* (5.9–16.6)	161*	NA	NA	62,98,143

Table 1. Recurrence rates (RR) in different surgical approaches deriving from including all available studies from all geographical regions for 12, 24, 60, and 120 months follow-up time.

Results

Our original search and processing strategy was described previously¹⁰. In brief, after exclusion of duplicates, we screened 5,768 studies across various databases. Data pertaining to malignancies, embryonic development, and body regions other than the presacral intergluteal location was additionally excluded, leaving 1,148 articles. Of these, 408 reports lacked data on follow-up time or on recurrence or both. Subsequently, data deriving from 740 studies was included in the merged data analysis¹⁰. The flow chart based on the preferred reporting items for systematic reviews and meta-analyses (PRISMA) can be found in our first study; the same applies for the heterogeneity analysis of the data involved¹⁰.

Looking at the overall results, the recurrence rates at 12 months ranged from 0.3% for the Limberg/Dufourmentel approach (95% CI 0.2–0.4) and the flaps approach (95% CI 0.1–0.5) to 6.3% for the incision and drainage approach (95% CI 3.2–9.3). At 60 months, the incision and drainage approach showed the highest recurrence rate: 36.8% (95% CI 26.3–47.2) (Fig. 1, Table 1).

In the United States at 12 months the recurrence rates ranged from 0.3% for the Karydakis/Bascom approach (95% CI 0.0–0.8) to 67.2% for the incision and drainage approach (95% CI 7.5–100). The Limberg/Dufourmentel approach showed the lowest recurrence rate at 60 months, with 2.3% (95% CI 0.0–4.9) (Fig. 2, Table 2).

In Germany, patients undergoing the primary asymmetric closure approach had no recurrence at 12 months (95% CI 0.0–0.0), whereas patients undergoing the pit-picking approach had a much higher recurrence rate of 21.0% (95% CI 16.7–25.3). At 120 months four surgical approaches showed recurrence below 20%: the primary open approach (10.0%) (95% CI 7.9–12.1), the primary median closure approach (16.1%) (95% CI 13.1–19.2), the primary asymmetric closure approach (7.1%) (95% CI 0.0–22.1) and the marsupialization approach (8.8%) (95% CI 2.0–15.5) (Fig. 3, Table 3).

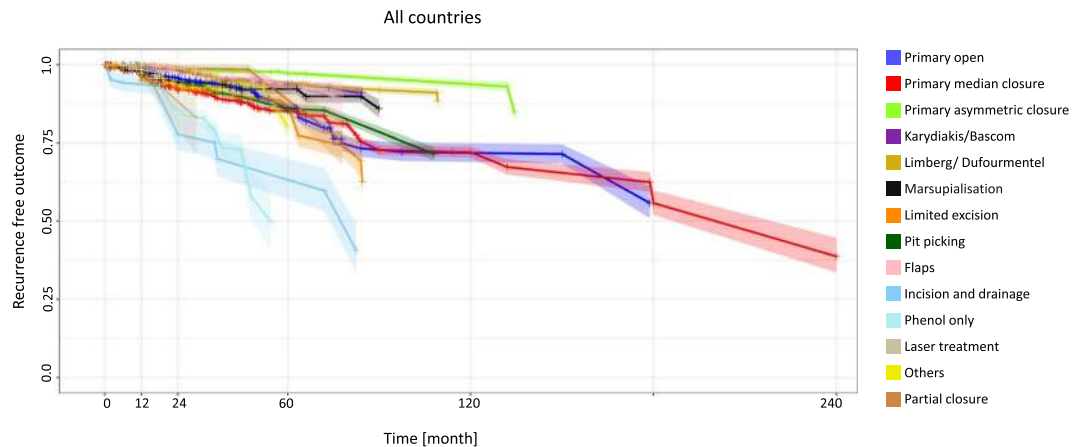


Figure 1. All countries: Kaplan-Meier estimator depicting recurrence free outcome of the study population as a function of follow-up time. The data used include all available studies from all geographical regions. 95% confidence intervals are shown by shaded lines. The number of patients at risk for 12, 24, 60, and 120 months follow-up time are shown in Table 1.

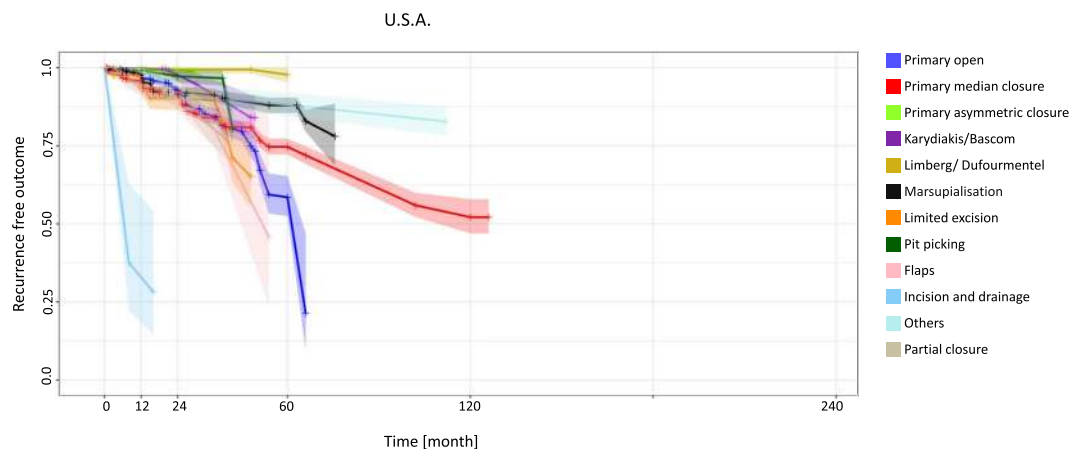


Figure 2. United States: Kaplan-Meier estimator depicting recurrence-free outcome of the study population as a function of follow-up time. The data used include all available studies from the United States. 95% confidence intervals are shown by shaded lines. The number of patients at risk of recurrence at 12, 24, 60, and 120 months of follow-up is shown in Table 2.

Patients in Turkey had very good outcomes with the flaps approach at 12 months (0.0% recurrence) (95% CI 0.0–0.0), but the incision and drainage approach was associated with recurrence of 39.4% at 12 months (95% CI 12.7–66.2) and 78.8% (95% CI 25.3–100) at 24 months (Fig. 4, Table 4).

Italy delivered outstanding results at 12 months for four procedures: recurrence was 0.0% for the primary open approach (95% CI 0.0–0.0), the primary asymmetric closure approach (95% CI 0.0–0.0), the Limberg/ Dufourmental approach (95% CI 0.0–0.0) and the flaps approach (95% CI 0.0–0.0). Recurrence was relatively low with the marsupialization approach at 12 months (4.1%) (95% CI 0.5–7.7) and with the primary asymmetric closure approach at 120 months (3.6%) (95% CI 2.4–4.8) (Fig. 5, Table 5). Similar specifics can be shown for additional countries and regions such as Australia, New Zealand, Greece and Asia (Supplemental Figs 1–3, Supplemental Tables 1–3).

Figures 6 and 7 provide an overview of recurrence rates of all procedures studied after 12 and 60 months in various geographic settings.

Discussion

We analyzed global data of more than 80,000 PSD patients for the years 1833 to 2017. Whereas in our previous study we only looked at follow-up time dependent recurrence rates of different surgical procedures, we now analyzed the geography's impact on recurrence rates. Most of the patients analyzed were from the US (8,017), Germany (4,965), Turkey (19,809) or Italy (12,443). Focusing on the surgical approaches used in different countries and regions of the world, we assessed the recurrence rates at different follow-up times and found a correlation between geography and PSD recurrence for a variety of surgical treatments.

USA	12 months		24 months		60 months		120 months		Citations
Surgical method (total patients included)	RR in % (95% CI)	Nr. at risk	RR in % (95% CI)	Nr. at risk	RR in % (95% CI)	Nr. at risk	RR in % (95% CI)	Nr. at risk	
Primary open (2124)	2.2 (1.5–2.8)	1708	7.4 (5.7–9.1)	734	41.5 (30.2–52.8)	69	NA	NA	21,37,41,43,46,57,62,63,69,77,79,104,105,107,108,111,524–540
Primary median closure (3650)	4.3 (3.6–5.1)	2754	8.5 (7.4–9.7)	2119	25.3 (21.9–28.7)	388	47.9 (37.1–58.6)	44	37,46,57,62,63,69,77,107,108,152,156,157,170,175,181,185,227,237,525–529,532,533,538,540–559
Primary asymmetric closure (176)	0.6* (0.0–1.7)	170*	0.6 (0.0–1.7)	160	NA	NA	NA	NA	257,560,561
Karydakis/Bascom (236)	0.3* (0.0–0.8)	236*	2.4* (0.2–4.7)	160*	NA	NA	NA	NA	21,41,562–565
Limberg/Dufourmentel (164)	0.6* (0.0–1.8)	156*	0.6* (0.0–1.8)	145*	2.3 (0.0–4.9)	120	NA	NA	170,351,374,566
Marsupialization (1475)	2.4 (1.4–3.3)	933	8.0* (6.0–10.1)	526*	12.1* (9.2–15.0)	332*	NA	NA	37,46,69,77,104,152,156,175,399–401,404,405,410,411,416,527,532,538,549,567–571
Limited excision (780)	5.8 (3.3–8.3)	301	10.1* (6.0–14.2)	162*	NA	NA	NA	NA	69,170,399,430,435,527,535,572–578
Pit picking (328)	0.9 (0.0–2.0)	328	2.8 (0.6–4.9)	213	NA	NA	NA	NA	69,445,579,580
Flaps (595)	6.9 (4.6–9.3)	517	10.7* (7.0–14.4)	176*	NA	NA	NA	NA	108,185,227,485,527,533,581–583
Incision and drainage (24)	67.2* (7.5–100)	16*	NA	NA	NA	NA	NA	NA	77,528
Others (374)	0.9* (0.0–1.9)	364*	8.2* (4.7–11.7)	237*	11.9* (7.5–16.3)	234*	NA	NA	430,510,520,584,585
Partial closure (215)	5.5* (2.2–8.8)	199*	8.9* (4.5–13.3)	168*	NA	NA	NA	NA	62,526,528,533,549,586

Table 2. Recurrence rates (RR) in different surgical approaches deriving from including available studies from the U.S.A. for 12, 24, 60, and 120 months follow-up time.

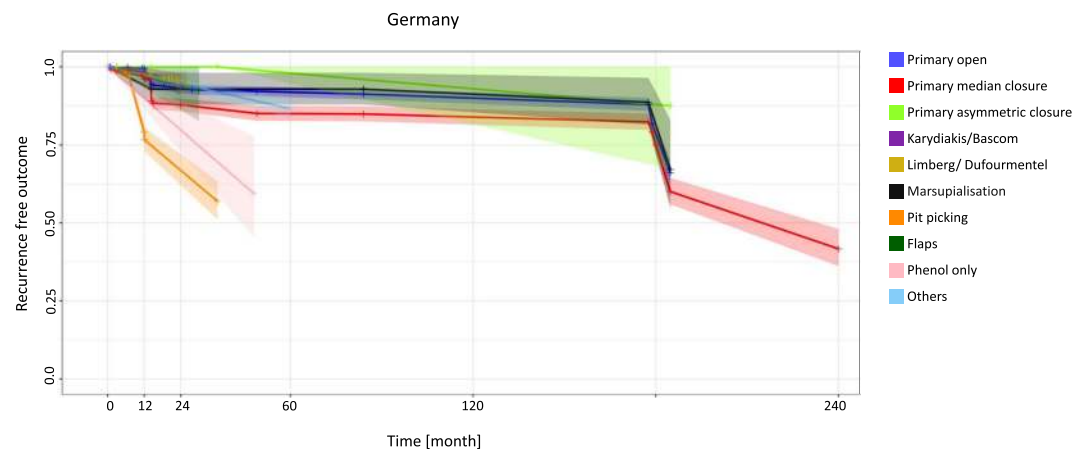


Figure 3. Germany: Kaplan-Meier estimator depicting recurrence-free outcome of the study population as a function of follow-up time. The data used include all available studies from Germany. 95% confidence intervals are shown by shaded lines. The number of patients at risk of recurrence at 12, 24, 60, and 120 months of follow-up is shown in Table 3.

Not all surgical approaches were used in all the countries analyzed, and certain preferences exist in the choice of surgical approach in each country, leading to differences in recurrence rates of specific surgical approaches between the geographical regions. Because not all nations and continents report PSD patient treatments in sufficient numbers, some geographical regions had to be excluded to ensure sufficient data quality. For example, countries in Africa, Asia and South America were not included due to missing data, and/or a very low disease burden.

The merged data analysis is potentially less powerful than a systematic review consisting entirely of randomized controlled trials (RCT’s). Many of the studies we cited could have qualified as RCT’s, but our approach enabled inclusion of enough patients to be able to compare all the surgical methods available in different geographical regions. Certain surgical approaches are not being used for treatment in all the analyzed geographical regions. This lack of data provides important information about established treatments in specific health care settings and geographic regions respectively. The patient number or number at risk also differs strongly between regions, probably pointing out specific economic and clinical peculiarities. Also, abrupt drops and interpolations in our figures need to be interpreted with caution because the curves about recurrence rates are influenced by the cohort sizes of underlying studies: The methodologies of the underlying studies may indirectly create a certain bias.

Surgical method (total patients included)	12 months		24 months		60 months		120 months		Citations
	RR in % (95% CI)	Nr. at risk	RR in % (95% CI)	Nr. at risk	RR in % (95% CI)	Nr. at risk	RR in % (95% CI)	Nr. at risk	
Primary open (1457)	0.5 (0.1–0.8)	1263	6.9* (5.3–8.5)	851*	8.1* (6.3–9.9)	752*	10* (7.9–12.1)	706*	13,26,44,54,59,64–66,92,97,115, 117,122,587,588
Primary median closure (1320)	3.9 (2.7–5.1)	1043	12.2 (9.8–14.6)	655	15.0* (12.2–17.9)	554*	16.1* (13.1–19.2)	507*	13,44,54,59,64–66,97,115,122,123, 180,211,588–590
Primary asymmetric closure (87)	0.0* (0.0–0.0)	48*	0.0* (0.0–0.0)	33*	2.0* (0.0–6.3)	26*	7.1* (0.0–22.1)	17*	65,588,591,592
Karydakis/Bascom (332)	1.5* (0.0–3.2)	226*	5.9 (2.0–9.8)	151	NA	NA	NA	NA	66,298,587
Limberg/Dufourmentel (434)	1.9* (0.5–3.4)	278*	5.1* (1.2–8.9)	54*	NA	NA	NA	NA	92,320,357,366,394,593–595
Marsupialization (98)	6.0* (1.3–10.6)	98*	7.1* (1.5–12.7)	93*	7.1* (1.5–12.7)	76*	8.8* (2.0–15.5)	57*	13,65,97,588
Pit picking (676)	21 (16.7–25.3)	553	33.1* (25.2–41.1)	158*	NA	NA	NA	NA	298,441,447,452
Flaps (26)	3.1* (0.0–7.6)	26*	6.2* (0.0–15.2)	26*	NA	NA	NA	NA	596
Phenol only (37)	10.1* (3.3–16.9)	37*	20.3* (6.7–33.8)	37*	NA	NA	NA	NA	497
Others (498)	2.7* (2.0–3.4)	498*	5.4* (4.0–6.8)	498*	13.5 (9.9–17.0)	498	NA	NA	513

Table 3. Recurrence rates (RR) in different surgical approaches deriving from including all available studies from Germany for 12, 24, 60, and 120 months follow-up time.

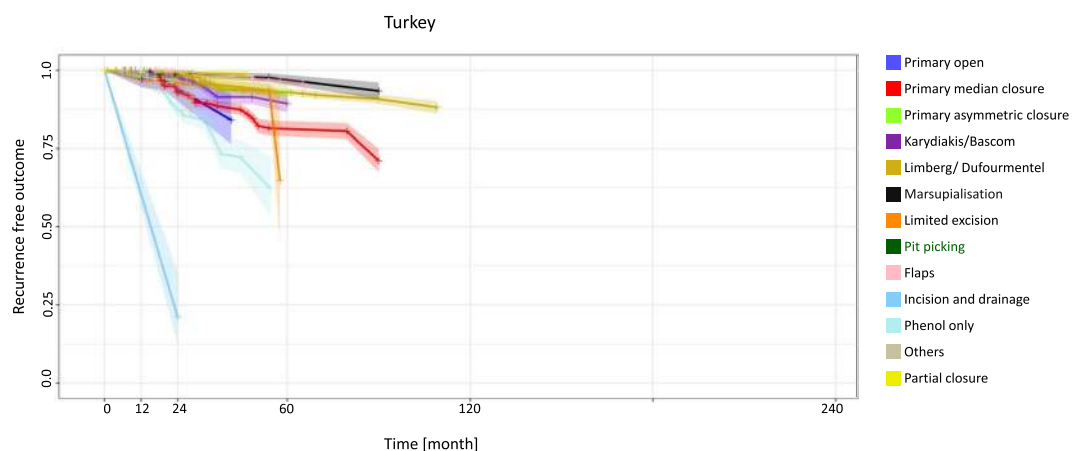


Figure 4. Turkey: Kaplan-Meier estimator depicting recurrence-free outcome of the study population as a function of follow-up time. The data used include all available studies from Turkey. 95% confidence intervals are shown by shaded lines. The number of patients at risk of recurrence at 12, 24, 60, and 120 months of follow-up is shown in Table 4.

The primary open approach showed insufficient success in most geographical regions, with a recurrence rate of 41.5% being observed at 60 months in the US. This has not been shown before, and is appalling in its magnitude. Reasons for the high recurrence rate are not yet evident. Current evidence implies that non healing beyond 6 month post-surgery should be considered as recurrent disease^{13,14}. The application of metronidazole 10% ointment has enabled a faster wound closure in patients¹⁵ and healing can be regularly expected within 6 months, however, some surgical wounds only close after 9 months or later. Further, non-healing wounds must not be confused with a scar overlying the sacral bone. By definition recurrent PSD is defined as a new sinus tract. Although stringent criteria to distinguish healing disorders versus recurrence are available, some variation in recurrence rate observation between countries might unfortunately have been published.

The primary midline closure, which is not recommended for use anymore, showed a recurrence rate of 25.3% at 60 months in the USA. The pit-picking approach had a high recurrence rate of 33.1% at 24 months in Germany and should therefore be used only selectively for the treatment of minor disease in PSD patients. Nevertheless, interim results of current studies on pit picking are more promising. In contrast to the finding in Germany, pit picking showed a very low recurrence rate of 0.8%* at 24 months in Turkey, justifying this treatment in the Turkish medical setting. Strikingly, the Karydakis/Bascom approach in Greek cohorts showed the lowest observed recurrence rate at the 120-month follow-up. Nevertheless, it should be kept in mind that Karydakis never fully disclosed his data details of several thousands of Greek recruits. In Italy, endoscopic therapy

Surgical method (total patients included)	12 months		24 months		60 months		120 months		Citations
	RR in % (95% CI)	Nr. at risk	RR in % (95% CI)	Nr. at risk	RR in % (95% CI)	Nr. at risk	RR in % (95% CI)	Nr. at risk	
Primary open (143)	2.7* (0.0–5.5)	143*	5.9* (1.4–10.4)	120*	NA	NA	NA	NA	32,114,118
Primary median closure (2902)	0.8 (0.4–1.1)	2818	7.0* (5.7–8.2)	1383*	18.8* (15.7–21.8)	417*	NA	NA	118,127,133,136,137,139,143,148,149,158–160,169,172–174,183,192,199–201,232,242,243,246,247,597–603
Primary asymmetric closure (727)	1.7 (0.7–2.8)	621	2.5 (1.1–3.8)	403	7.4 (4.4–10.4)	257	NA	NA	183,192,253,259,261,262
Karydakis/Bascom (2471)	0.8 (0.4–1.1)	2356	1.7* (1.1–2.4)	1343*	10.7 (7.4–13.9)	257	NA	NA	133,172,192,199,200,262,264,267,268,270,273,274,276,279,282,284,289–292,295,296,300,305–309,603
Limberg/Dufourmentel (7653)	0.1 (0.0–0.2)	7369	1.1 (0.8–1.4)	5624	7.1* (5.9–8.2)	988*	NA	NA	127,137,139,148,149,172,174,192,201,232,243,246,267,268,270,273,274,291,292,295,305–309,317,319,321–323,327,329,330,332,338–340,342–344,346–350,352–355,359,362–364,368,369,371–373,375,379,382,385,38–7,395,398,600,603–607
Marsupialisation (728)	0.4 (0.0–0.9)	688	1.3* (0.4–2.3)	419*	3.1* (1.4–4.7)	358*	NA	NA	137,332,402,403,415,598,599,603,606
Limited excision (1402)	3.1 (2.2–4.1)	1402	4.1* (2.8–5.5)	423*	NA	NA	NA	NA	136,290,344,417,420,424,428,429,608
Pit picking (204)	0.4* (0.0–1.0)	204*	0.8* (0.0–2.0)	204*	NA	NA	NA	NA	309
Flaps (2262)	0 (0.0–0.0)	2219	0.4* (0.1–0.8)	1292*	3.8* (2.5–5.2)	670*	NA	NA	173,309,322,343,362,369,375,379,424,454–456,458,459,461,462,464,466,469–471,473,475,476,478–481,599
Incision and drainage (52)	39.4* (12.7–66.2)	52*	78.8 (25.3–100)	52	NA	NA	NA	NA	253
Phenol only (1089)	0.5 (0.1–0.9)	990	12.6 (9.9–15.3)	607	NA	NA	NA	NA	114,242,363,385,490–496,498,504,505,609
Others (103)	2.6* (0.0–5.2)	103*	5.3* (0.1–10.4)	56*	NA	NA	NA	NA	309,509,521
Partial closure (73)	0.3* (0.0–1.1)	73*	0.7* (0.0–2.1)	73*	NA	NA	NA	NA	143

Table 4. Recurrence rates (RR) in different surgical approaches deriving from including all available studies from Turkey for 12, 24, 60, and 120 months follow-up time.

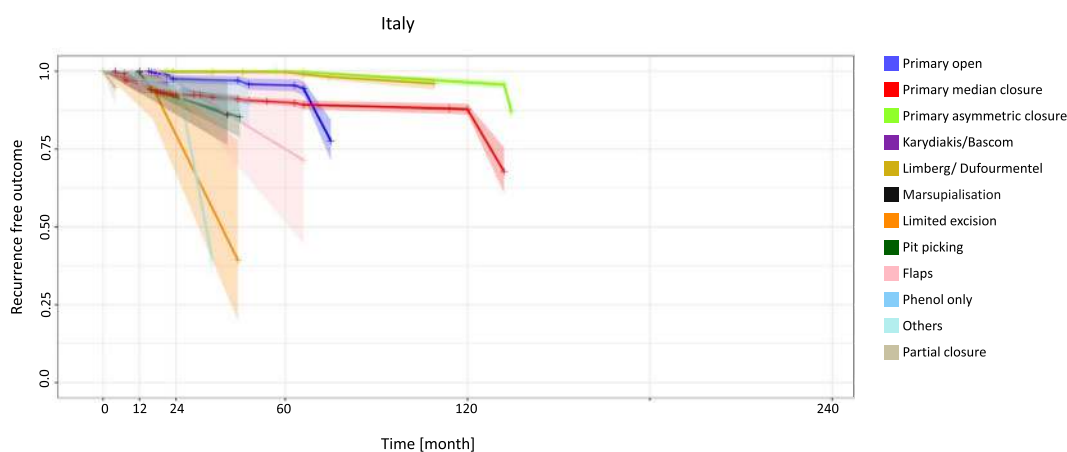


Figure 5. Italy: Kaplan-Meier estimator depicting recurrence-free outcome of the study population as a function of follow-up time. The data used include all available studies from Italy. 95% confidence intervals are shown by shaded lines. The number of patients at risk of recurrence at 12, 24, 60, and 120 months of follow-up is shown in Table 5.

Surgical method (total patients included)	12 months		24 months		60 months		120 months		Citations
	RR in % (95% CI)	Nr. at risk	RR in % (95% CI)	Nr. at risk	RR in % (95% CI)	Nr. at risk	RR in % (95% CI)	Nr. at risk	
Primary open (1243)	0 (0.0–0.0)	1203	2.5* (1.2–3.8)	441*	4.5* (2.5–6.6)	267*	NA	NA	35,56,70,72,80,91,94–96,99,100,120,610–613
Primary median closure (5583)	3.3 (2.8–3.8)	4184	7.6 (6.7–8.5)	1939	10.1* (8.8–11.4)	786*	12.2 (10.3–14.2)	382	35,56,91,94–96,99,100,129,144,146,161,162,165–168,171,179,182,186,197,205,209,214,215,218–222,610–621
Primary asymmetric closure (1099)	0.0* (0.0–0.0)	1099*	0.0* (0.0–0.0)	1096*	0.1* (0.0–0.2)	1022*	3.6* (2.4–4.8)	937*	100,129,256,260,622
Karydakis/Bascom (109)	3.7 (0.0–7.4)	109	NA	NA	NA	NA	NA	NA	16,622
Limberg/Dufourmentel (944)	0.0* (0.0–0.0)	944*	0.3* (0.0–0.7)	891*	0.3 (0.0–0.7)	618	NA	NA	56,100,165,182,205,328,334,336,623
Marsupialization (43)	4.1* (0.5–7.7)	43*	8.2* (1.0–15.4)	43*	NA	NA	NA	NA	406
Limited excision (18)	4.0* (0.0–12.4)	18*	20.4* (0.0–47.3)	16*	NA	NA	NA	NA	96,220
Pit picking (2508)	0.3 (0.1–0.5)	2508	8.4* (5.4–11.3)	1765*	NA	NA	NA	NA	16,439,444,451
Flaps (13)	0.0* (0.0–0.0)	13*	3.6* (0.0–9.6)	12*	25.0* (0.0–66.8)	8*	NA	NA	91,100
Phenol only (68)	2.6* (0.5–4.6)	68*	5.1* (1.0–9.3)	68*	NA	NA	NA	NA	613
Others (815)	3.5 (2.1–4.9)	728	5.2* (3.2–7.3)	344*	NA	NA	NA	NA	16,182,511,514,516,523,624
Partial closure (58)	NA	NA	NA	NA	NA	NA	NA	NA ⁶¹²	625–636

Table 5. Recurrence rates (RR) in different surgical approaches deriving from including all available studies from Italy for 12, 24, 60, and 120 months follow-up time.

12 months					
Procedure / Countries	All Countries	U.S.A.	Germany	Turkey	Italy
Primary open	1.3	2.2	0.5	2.7*	0
Primary median closure	3.1	4.3	3.9	0.8	3.3
Primary asymmetric closure	0.6	0.6*	0.0*	1.7	0.0*
Bascom / Karydakis	0.5	0.3*	1.5*	0.8	3.7
Limberg / Dufourmentel	0.3	0.6*	1.9*	0.1	0.0*
Marsupialisation	2.2	2.4	6.0*	0.4	4.1*
Limited excision	5.1	5.8	NA	3.1	4.0*
Pit picking	2.8	0.9	21	0.4*	0.3
Flaps	0.3	6.9	3.1*	0	0.0*
Incision and drainage	6.3*	67.2*	NA	39.4*	NA
Phenol only	1.6*	NA	10.1*	0.5	2.6*
Laser treatment	2.2*	NA	NA	NA	NA
Others	2.8	0.9*	2.7*	2.6*	3.5
Partial closure	0.6*	5.5*	NA	0.3*	NA

*extrapolated or interpolated data

Color legend:

- <1%
- 1-5%
- 5-10%
- 10-25%
- 25-50%
- > 50%
- Not available

Figure 6. Procedure-specific recurrence rates in PSD [%] are shown at the time point 12 months. Extrapolated or interpolated data are marked with an asterisk (*).

approaches of different names are emerging and first results appear to be very promising¹⁶. Given our data base embracing evidence ranging from 1833 to 2017, it is currently too early, however, to comment on their long-term recurrence rate since our data base misses the most recent publications. This approach might become a very promising approach in PSD surgery.

Therapy of open wounds following surgery has not been standardized, and may be performed by either a doctor, a nurse or a family member. This is not sufficiently well described in most of the studies we cited. Even the most recently published US guidelines do not recommend a particular type of wound care for primary open treatment¹⁷. As increased duration of open wound treatment may increase recurrence rate¹⁴, and elevated body weight with consecutive metabolic derangements may prolong wound healing, body mass index (BMI) in relation to treatment applied may further influence recurrence rate in primary and secondary treatments.

60 months					
Procedure / Countries	All Countries	U.S.A.	Germany	Turkey	Italy
Primary open	13.9	41.5	8.1*	NA	4.5*
Primary median closure	14.9	25.3	15.0*	18.8*	10.1*
Primary asymmetric closure	2.7	NA	2.0*	7.4	0.1*
Bascom / Karydakis	6.3	NA	NA	10.7	NA
Limberg / Dufourmentel	5.9*	2.3	NA	7.1*	0.3
Marsupialisation	7.8*	12.1*	7.1*	3.1*	NA
Limited excision	13.1	NA	NA	NA	NA
Pit picking	14.2	NA	NA	NA	NA
Flaps	6.4*	NA	NA	3.8*	25.0*
Incision and drainage	36.8*	NA	NA	NA	NA
Phenol only	NA	NA	NA	NA	NA
Laser treatment	NA	NA	NA	NA	NA
Others	19.8	11.9*	13.5	NA	NA
Partial closure	11.2*	NA	NA	NA	NA

*extrapolated or interpolated data

Color legend:

- <1%
- 1-5%
- 5-10%
- 10-25%
- 25-50%
- > 50%
- Not available

Figure 7. Procedure-specific recurrence rates in PSD [%] are shown at the time point 60 months. Extrapolated or interpolated data are marked with an asterisk (*).

Obviously, there is some mastery of certain surgical methods which are widely applied in some countries, and this contributes to better regional results. In other countries, the same methods used less often may show more dismal outcomes, contributing to the geographic differences in recurrence rates. Recently, Doll *et al.* have shown that patients with strong axial hair shafts are more prone to pilonidal sinus disease, and Bosche *et al.* found short cut hair less 2 cm length in the pilonidal nests^{18,19} indicating that both genetic disposition and cultural hair styles can contribute to regional variation of pilonidal sinus incidence and recurrence rate.

Furthermore, our current study analyzes results published in scientific journals. These studies are often run at large university hospitals. While industrialized countries have better resources and can document, study and report therapy outcomes, more rural countries with less funding may struggle to do so. In terms of economics, the costs of treatment may differ based on location, treating institution and type of therapy.

Our results allow a more differentiated view of PSD treatment. Surgical approaches should be selected carefully based on treatment efficacy in general, and geographical influences have to be taken into account when aiming for optimal treatment efficacy.

In summary, recurrence rates of different surgical approaches used in the treatment of PSD are influenced by geographical factors. Certain surgical approaches – such as primary asymmetric closure and different flap techniques – remain superior, regardless of the geographical region. This is powerful evidence since the clinical settings, the genetic background of the patient population and economic settings do vary between different countries. Methods such as limited excision and phenol treatment should be limited to selected settings due to their high recurrence rates. Under certain circumstances their use can be justified by the lack of need for a hospital stay or as low-cost variant of treatment. Geographic peculiarities were identified, such as high recurrence rates for the primary open approach in the US, suggesting that other methods should be preferred in the American setting. Pit picking should be selectively applied in Germany due to its high recurrence rate, and ways to improve this interesting minimal invasive procedure should be investigated. The same surgical method is already showing promising results in Turkey. In the future, detailed investigation into geographical differences in recurrence rates for the same surgical PSD method may lead to the identification of further co-factors for recurrence in pilonidal sinus disease. Therefore, the standardized definition of recurrence should uniformly be used^{13,14}.

Methods

Our original search was described previously¹⁰. In brief, we searched for the NCBI Medical Subject Heading (MeSH) term “pilonid*”, as well as [“cyst” AND “dermoid”] in MEDLINE, Ovid, PubMed Central, PubMed, Scopus, Embase, the Cochrane Central Register of Controlled Trials (CENTRAL) and other search engines to build the PSD database¹⁰. Publications from 1833 to 2017 in English, French, German, Italian, and Spanish were captured¹⁰. Reports in other languages were retrieved if recurrence at specific follow-up times and definitive treatment strategies were provided (National Health Service international prospective register of systematic reviews PROSPERO number 42016051588)¹⁰. Data were organized with Microsoft Excel (Version 2016, Microsoft Corp., Redmond, WA)¹⁰. Specific surgical approaches described in a report were listed in a data row, while columns included citation details (incl. country of origin), follow-up times, number of patients studied, recurrence, and study details¹⁰. Regularly recorded information included which hospital(s) participated and which region the patients came from. In the very few studies where this was not obvious, the patient’s country of origin was defined as where the first author’s hospital was located. If all other authors were from one hospital, and the first author exclusively was not, then the hospital of the last author defined the country. If an article addressed several surgical approaches, the data of each treatment strategy were managed separately¹⁰. Because the statistical measures

were not standardized, mean and median reports were treated equally to take into account the cluster of affected patients who were young adults¹⁰. Data presented as range of follow-up times was managed by employing the center of the given time¹⁰.

Recurrence rates in each study were then associated with the reported follow-up time. Individual patients were statistically simulated to enable an analogy across all data¹⁰. Cochrane analysis and I² calculation with Chi² tests were employed to examine heterogeneity of the included data¹⁰.

Statistical analysis and figure generation were completed with the software “R” (version 3.1.0, R-studio framework version 0.98.982). Two-tailed statistical tests were performed¹⁰. Kaplan-Meier curves of recurrence-free outcome, including pointwise 95% confidence intervals (CI), were generated with ‘survival’ in “R” (version 2.40–1) and implemented in the R package for each therapeutic group in each geographic region.

Data with unknown geographical origin were excluded. The United States, Turkey, Italy, Germany and Greece were defined as single countries; other countries were grouped into regions (Northern Europe, the Mediterranean, North America, i.e. USA and Canada, Australia/New Zealand, Indo-Arabia, Asia and South America) to obtain sufficient sample sizes.

Category. Post hoc analyses of data for a systematic review and meta-analysis, no publication before. No submission in parallel. No full or partial presentation at a meeting or podium or conference.

Ethics. This article does not contain any studies with human participants. Therefore, no informed consent had to be obtained prior to preparation of the current manuscript.

Presentation. The manuscript has not been submitted elsewhere in parallel and has not been published previously. Some of the data were presented at the International Pilonidal Sinus Disease Conference in Berlin on Sept 23, 2017 and at the 2nd International Pilonidal Sinus Conference in Vienna on Sept 28th 2019.

Data availability

All data and calculations are available to readers upon request to the corresponding author.

Received: 14 March 2019; Accepted: 20 September 2019;

Published online: 22 October 2019

References

- Doll, D. H. *et al.* Stop insulting the patient: neither incidence nor recurrence in pilonidal sinus disease is linked to personal hygiene. *Pilonidal Sinus Journal* **1**, 8 (2015).
- Duman, K., Girgin, M. & Harlak, A. Prevalence of sacrococcygeal pilonidal disease in Turkey. *Asian journal of surgery* **40**, 434–437, <https://doi.org/10.1016/j.asjsur.2016.04.001> (2017).
- Segre, D., Pozzo, M., Perinotti, R. & Roche, B. The treatment of pilonidal disease: guidelines of the Italian Society of Colorectal Surgery (SICCR). *Tech Coloproctol* **19**, 607–613, <https://doi.org/10.1007/s10151-015-1369-3> (2015).
- Steele, S. R. *et al.* Practice parameters for the management of pilonidal disease. *Dis Colon Rectum* **56**, 1021–1027, <https://doi.org/10.1097/DCR.0b013e31829d2616> (2013).
- Iesalnieks, I., Ommert, A., Petersen, S., Doll, D. & Herold, A. German national guideline on the management of pilonidal disease. *Langenbecks Arch Surg* **401**, 599–609, <https://doi.org/10.1007/s00423-016-1463-7> (2016).
- Doll, D. *et al.* The presence of occipital hair in the pilonidal sinus cavity—a triple approach to proof. *International Journal of Colorectal Disease* **33**, 567–576, <https://doi.org/10.1007/s00384-018-2988-8> (2018).
- Stone, H. B. Pilonidal Sinus. *Ann Surg* **79**, 410–414 (1924).
- Davage, O. N. The Origin of Sacrococcygeal Pilonidal Sinuses. *Am J Pathol* **30**, 1191–1205 (1954).
- Sievert, H. *et al.* The influence of lifestyle (smoking and body mass index) on wound healing and long-term recurrence rate in 534 primary pilonidal sinus patients. *International Journal of Colorectal Disease* **28**, 1555–1562, <https://doi.org/10.1007/s00384-013-1731-8> (2013).
- Stauffer, V. K. *et al.* Common surgical procedures in pilonidal sinus disease: A meta-analysis, merged data analysis, and comprehensive study on recurrence. *Sci Rep* **8**, 3058, <https://doi.org/10.1038/s41598-018-20143-4> (2018).
- Lessa, F. C. *et al.* Burden of Clostridium difficile infection in the United States. *The New England journal of medicine* **372**, 825–834, <https://doi.org/10.1056/NEJMoa1408913> (2015).
- Crotty, B. Ulcerative colitis and xenobiotic metabolism. *Lancet (London, England)* **343**, 35–38 (1994).
- Doll, D. *et al.* Timeline of recurrence after primary and secondary pilonidal sinus surgery. *Dis Colon Rectum* **50**, 1928–1934, <https://doi.org/10.1007/s10350-007-9031-4> (2007).
- Allen-Mersh, T. G. Pilonidal sinus: finding the right track for treatment. *Br J Surg* **77**, 123–32 (1990).
- Ypsilantis, E., Carapeti, E. & Chan, S. The use of topical 10% metronidazole in the treatment of non-healing pilonidal sinus wounds after surgery. *Int J Colorectal Dis* **31**, 765–767, <https://doi.org/10.1007/s00384-015-2269-8> (2016).
- Milone, M., Fernandez, L. M., Musella, M. & Milone, F. Safety and Efficacy of Minimally Invasive Video-Assisted Ablation of Pilonidal Sinus: A Randomized Clinical Trial. *JAMA Surg* **151**, 547–553, <https://doi.org/10.1001/jamasurg.2015.5233> (2016).
- Johnson, E. K., Vogel, J. D., Cowan, M. L., Feingold, D. L. & Steele, S. R. The American Society of Colon and Rectal Surgeons’ Clinical Practice Guidelines for the Management of Pilonidal Disease. *Dis Colon Rectum* **62**, 146–157, <https://doi.org/10.1097/dcr.0000000000001237> (2019).
- Doll, D. *et al.* Strength of Occipital Hair as an Explanation for Pilonidal Sinus Disease Caused by Intruding Hair. *Dis Colon Rectum* **60**, 979–986 (2017).
- Bosche, F. *et al.* The Hair in the Sinus: Sharp-Ended Rootless Head Hair Fragments can be Found in Large Amounts in Pilonidal Sinus Nests. *World J Surg* **42**, 567–573 (2018).
- Perruchoud, C., Vuilleumier, H. & Givel, J. C. Pilonidal sinus: how to choose between excision and open granulation versus excision and primary closure? Study of a series of 141 patients operated on from 1991 to 1995. *Swiss Surg* **8**, 255–258 (2002).
- Morden, P., Drongowski, R. A., Geiger, J. D., Hirschl, R. B. & Teitelbaum, D. H. Comparison of Karydakis versus midline excision for treatment of pilonidal sinus disease. *Pediatr Surg Int* **21**, 793–796, <https://doi.org/10.1007/s00383-005-1543-1> (2005).
- Mueller, X., Rothenbuehler, J. M. & Frede, K. E. Sacrococcygeal cysts. Is Lord Millar’s procedure an alternative to exeresis? *J Chir (Paris)* **128**, 487–490 (1991).
- Soll, C., Hahnloser, D., Dindo, D., Clavien, P. A. & Hetzer, F. A novel approach for treatment of sacrococcygeal pilonidal sinus: less is more. *Int J Colorectal Dis* **23**, 177–180, <https://doi.org/10.1007/s00384-007-0377-9> (2008).

24. al-Hassan, H. K., Francis, I. M. & Neglen, P. Primary closure or secondary granulation after excision of pilonidal sinus? *Acta Chir Scand* **156**, 695–699 (1990).
25. Fazeli, M. S., Adel, M. G. & Lebaschi, A. H. Comparison of outcomes in Z-plasty and delayed healing by secondary intention of the wound after excision of the sacral pilonidal sinus: results of a randomized, clinical trial. *Dis Colon Rectum* **49**, 1831–1836, <https://doi.org/10.1007/s10350-006-0726-8> (2006).
26. Menzel, T., Dorner, A. & Cramer, J. Excision and open wound treatment of pilonidal sinus. Rate of recurrence and duration of work incapacity. *Dtsch Med Wochenschr* **122**, 1447–1451, <https://doi.org/10.1055/s-2008-1047784> (1997).
27. Rao, M. M., Zawislak, W., Kennedy, R. & Gilliland, R. A prospective randomised study comparing two treatment modalities for chronic pilonidal sinus with a 5-year follow-up. *Int J Colorectal Dis* **25**, 395–400, <https://doi.org/10.1007/s00384-009-0804-1> (2010).
28. Jamal, A., Shamim, M., Hashmi, F. & Qureshi, M. I. Open excision with secondary healing versus rhomboid excision with Limberg transposition flap in the management of sacrococcygeal pilonidal disease. *J Pak Med Assoc* **59**, 157–160 (2009).
29. Dudink, R., Veldkamp, J., Nienhuijs, S. & Heemskerk, J. Secondary healing versus midline closure and modified Bascom natal cleft lift for pilonidal sinus disease. *Scand J Surg* **100**, 110–113 (2011).
30. Gupta, P. J. Radiofrequency sinus excision: better alternative to marsupialization technique in sacrococcygeal pilonidal sinus disease. *J Natl Med Assoc* **97**, 998–1002 (2005).
31. Holmebakk, T. & Nesbakken, A. Surgery for pilonidal disease. *Scand J Surg* **94**, 43–46 (2005).
32. Kement, M., Oncel, M., Kurt, N. & Kaptanoglu, L. Sinus excision for the treatment of limited chronic pilonidal disease: results after a medium-term follow-up. *Dis Colon Rectum* **49**, 1758–1762, <https://doi.org/10.1007/s10350-006-0676-1> (2006).
33. Kaser, S. A., Zengaffinen, R., Uhlmann, M., Glaser, C. & Maurer, C. A. Primary wound closure with a Limberg flap vs. secondary wound healing after excision of a pilonidal sinus: a multicentre randomised controlled study. *Int J Colorectal Dis* **30**, 97–103, <https://doi.org/10.1007/s00384-014-2057-x> (2015).
34. Mohamed, H. A., Kadry, I. & Adly, S. Comparison between three therapeutic modalities for non-complicated pilonidal sinus disease. *Surgeon* **3**, 73–77 (2005).
35. Testini, M. *et al.* Treatment of chronic pilonidal sinus with local anaesthesia: a randomized trial of closed compared with open technique. *Colorectal Dis* **3**, 427–430 (2001).
36. Al-Salamah, S. M., Hussain, M. I. & Mirza, S. M. Excision with or without primary closure for pilonidal sinus disease. *J Pak Med Assoc* **57**, 388–391 (2007).
37. Spivak, H., Brooks, V. L., Nussbaum, M. & Friedman, I. Treatment of chronic pilonidal disease. *Dis Colon Rectum* **39**, 1136–1139 (1996).
38. Aldaqal, S. M., Kensarah, A. A., Alhabboubi, M. & Ashy, A. A. A new technique in management of pilonidal sinus, a university teaching hospital experience. *Int Surg* **98**, 304–306, <https://doi.org/10.9738/INTSURG-D-13-00064.1> (2013).
39. Soll, C. *et al.* Sinusectomy for primary pilonidal sinus: less is more. *Surgery* **150**, 996–1001, <https://doi.org/10.1016/j.surg.2011.06.019> (2011).
40. Agren, M. S. *et al.* A randomized, double-blind, placebo-controlled multicenter trial evaluating topical zinc oxide for acute open wounds following pilonidal disease excision. *Wound Repair Regen* **14**, 526–535, <https://doi.org/10.1111/j.1743-6109.2006.00159.x> (2006).
41. Gendy, A. S. *et al.* A comparison of the cleft lift procedure vs wide excision and packing for the treatment of pilonidal disease in adolescents. *J Pediatr Surg* **46**, 1256–1259, <https://doi.org/10.1016/j.jpedsurg.2011.03.062> (2011).
42. Duxbury, M. S., Blake, S. M., Dashfield, A. & Lambert, A. W. A randomised trial of knife versus diathermy in pilonidal disease. *R Coll Surg Engl* **85**, 405–407, <https://doi.org/10.1308/003588403322520799> (2003).
43. Eftaiha, M. & Abcarian, H. The dilemma of pilonidal disease: surgical treatment. *Dis Colon Rectum* **20**, 279–286 (1977).
44. Holzer, B. *et al.* Efficacy and tolerance of a new gentamicin collagen fleece (Septocoll) after surgical treatment of a pilonidal sinus. *Colorectal Dis* **5**, 222–227 (2003).
45. Seleem, M. I. & Al-Hashemy, A. M. Management of pilonidal sinus using fibrin glue: a new concept and preliminary experience. *Colorectal Dis* **7**, 319–322, <https://doi.org/10.1111/j.1463-1318.2005.00808.x> (2005).
46. Solla, J. A. & Rothenberger, D. A. Chronic pilonidal disease. An assessment of 150 cases. *Dis Colon Rectum* **33**, 758–761 (1990).
47. Spyridakis, M., Christodoulidis, G., Chatzitheofilou, C., Symeonidis, D. & Tepetes, K. The role of the platelet-rich plasma in accelerating the wound-healing process and recovery in patients being operated for pilonidal sinus disease: preliminary results. *World J Surg* **33**, 1764–1769, <https://doi.org/10.1007/s00268-009-0046-y> (2009).
48. Chiedozi, L. C., Al-Rayyes, F. A., Salem, M. M., Al-Haddi, F. H. & Al-Bidewi, A. A. Management of pilonidal sinus. *Saudi Med J* **23**, 786–788 (2002).
49. Keshvari, A. *et al.* Karydakias flap versus excision-only technique in pilonidal disease. *J Surg Res* **198**, 260–266, <https://doi.org/10.1016/j.jss.2015.05.039> (2015).
50. Biter, L. U. *et al.* The use of negative-pressure wound therapy in pilonidal sinus disease: a randomized controlled trial comparing negative-pressure wound therapy versus standard open wound care after surgical excision. *Dis Colon Rectum* **57**, 1406–1411, <https://doi.org/10.1097/DCR.0000000000000240> (2014).
51. Viciano, V. *et al.* Effect of hydrocolloid dressings on healing by second intention after excision of pilonidal sinus. *Eur J Surg* **166**, 229–232 (2000).
52. Rabie, M. E. *et al.* Sacrococcygeal pilonidal disease: sinotomy versus excisional surgery, a retrospective study. *ANZ J Surg* **77**, 177–180, <https://doi.org/10.1111/j.1445-2197.2006.04002.x> (2007).
53. Stansby, G. & Greatorex, R. Phenol treatment of pilonidal sinuses of the natal cleft. *Br J Surg* **76**, 729–730 (1989).
54. Ommer, A. *et al.* Pilonidal Sinus—Primary Closure also in Case of Abscess? *Zentralbl Chir* **129**, 216–219, <https://doi.org/10.1055/s-2004-822742> (2004).
55. Matter, I., Kunin, J., Schein, M. & Eldar, S. Total excision versus non-resectional methods in the treatment of acute and chronic pilonidal disease. *Br J Surg* **82**, 752–753 (1995).
56. Falco, M. D. *et al.* Il trattamento chirurgico del sinus pilonidalis con trasposizione di lembo secondo Dufourmentel Surgical treatment of sinus pilonidalis by Dufourmentel's flap technique. *Il Giornale di chirurgia* **28**, 93–97 (2007).
57. Lukish, J. R., Kindelan, T., Marmon, L. M., Pennington, M. & Norwood, C. Laser epilation is a safe and effective therapy for teenagers with pilonidal disease. *J Pediatr Surg* **44**, 282–285, <https://doi.org/10.1016/j.jpedsurg.2008.10.057> (2009).
58. Ghnnam, W. M. & Hafez, D. M. Laser hair removal as adjunct to surgery for pilonidal sinus: our initial experience. *J Cutan Aesthet Surg* **4**, 192–195, <https://doi.org/10.4103/0974-2077.91251> (2011).
59. Baier, P. K., Baumgartner, U., Furtwangler, A., Holzinger, F. & Schoffel, U. Therapy of the pilonidal sinus—Primary wound closure or open wound after excision. *Zentralbl Chir* **127**, 310–314, <https://doi.org/10.1055/s-2002-31557> (2002).
60. Ortiz, H. H., Marti, J. & Sitges, A. Pilonidal sinus: a claim for simple track incision. *Dis Colon Rectum* **20**, 325–328 (1977).
61. Goodall, P. The aetiology and treatment of pilonidal sinus. A review of 163 patients. *Br J Surg* **49**, 212–218 (1961).
62. Kooistra, H. P. Pilonidal sinuses. Review of the literature and report of three hundred fifty cases. *Am J Surg LV* **1**, 3–17 (1942).
63. McKirdie, M. Pilonidal Sinus. *Ann Surg* **107**, 389–399 (1938).
64. Iesalnieks, I., Furst, A., Rentsch, M. & Jauch, K. W. Primary midline closure after excision of a pilonidal sinus is associated with a high recurrence rate. *Chirurg* **74**, 461–468, <https://doi.org/10.1007/s00104-003-0616-8> (2003).

65. Doll, D., Matevosian, E., Hoenemann, C. & Hoffmann, S. Incision and drainage preceding definite surgery achieves lower 20-year long-term recurrence rate in 583 primary pilonidal sinus surgery patients. *J Dtsch Dermatol Ges* **11**, 60–64, <https://doi.org/10.1111/j.1610-0387.2012.08007.x> (2013).
66. Iesalnieks, I., Deimel, S. & Schlitt, H. J. Karydakias flap for recurrent pilonidal disease. *World J Surg* **37**, 1115–1120, <https://doi.org/10.1007/s00268-013-1950-8> (2013).
67. Hosseini, M., Heidari, A. & Jafarnejad, B. Comparison of Three Surgical Methods in Treatment of Patients with Pilonidal Sinus: Modified Excision and Repair/Wide Excision/Wide Excision and Flap in RASOUL, OMID and SADR Hospitals (2004–2007). *Indian J Surg* **75**, 395–400, <https://doi.org/10.1007/s12262-012-0713-3> (2013).
68. Gupta, P. J. Comparative study between radiofrequency sinus excision and open excision in sacro-coccygeal pilonidal sinus disease. *Dig Surg* **22**, 459–463, <https://doi.org/10.1159/000092034> (2005).
69. Fitzpatrick, E. B. *et al.* Pilonidal disease in a military population: how far have we really come? *Am J Surg* **207**, 907–914, <https://doi.org/10.1016/j.amjsurg.2013.07.038> (2014).
70. Patti, R. *et al.* Use of fibrin glue in the treatment of pilonidal sinus disease: a pilot study. *G Chir* **27**, 331–334 (2006).
71. Nasr, A. & Ein, S. H. A pediatric surgeon's 35-year experience with pilonidal disease in a Canadian children's hospital. *Can J Surg* **54**, 39–42 (2011).
72. Baldelli, C. M. *et al.* A short course of granulocyte-colony-stimulating factor to accelerate wound repair in patients undergoing surgery for sacrococcygeal pilonidal cyst: proof of concept. *Cytotherapy* **14**, 1101–1109, <https://doi.org/10.3109/14653249.2012.697147> (2012).
73. Kareem, T. S. Surgical treatment of chronic sacrococcygeal pilonidal sinus. Open method versus primary closure. *Saudi Med J* **27**, 1534–1537 (2006).
74. Khawaja, H. T., Bryan, S. & Weaver, P. C. Treatment of natal cleft sinus: a prospective clinical and economic evaluation. *BMJ (Clinical research ed.)* **304**, 1282–1283 (1992).
75. Notaras, M. J. A review of three popular methods of treatment of postanal (pilonidal) sinus disease. *Br J Surg* **57**, 886–890 (1970).
76. Oueidat, D. *et al.* 25 years' experience in the management of pilonidal sinus disease. *Open Journal of Gastroenterology* **4**, 5 (2014).
77. Macfee, W. F. Pilonidal Cysts and Sinuses: A Method of Wound Closure: Review of 230 Cases. *Ann Surg* **116**, 687–699 (1942).
78. Kasim, K., Abdllhamid, N. M., Badwan, B. R. & Allowbany, A. Is There a Relation Between Natal Cleft Depth and Post-Operative Morbidity After Different Methods of Excision of Sacro-Coccygeal Pilonidal Sinus? *Indian J Surg* **77**, 201–205, <https://doi.org/10.1007/s12262-012-0762-7> (2015).
79. Swenson, S. A., Harkins, H. N. & Groesbeck, H. P. Pilonidal Sinus - Clinical Experiences with the Rogers Operation in thirty-five consecutive cases. *Am J Surg* **66**, 49–57 (1944).
80. Blanco, G., Giordano, M. & Torelli, I. Surgical treatment of pilonidal sinus with open surgical technique. *Minerva Chir* **58**, 181–187 (2003).
81. Hosseini, S. V. *et al.* The comparison between drainage, delayed excision and primary closure with excision and secondary healing in management of pilonidal abscess. *Int J Surg* **4**, 228–231, <https://doi.org/10.1016/j.ijsu.2005.12.005> (2006).
82. Fahrni, G. T. *et al.* Five-year Follow-up and Recurrence Rates Following Surgery for Acute and Chronic Pilonidal Disease: A Survey of 421 Cases. *Wounds* **28**, 20–26 (2016).
83. Kronborg, O., Christensen, K. & Zimmermann-Nielsen, C. Chronic pilonidal disease: a randomized trial with a complete 3-year follow-up. *Br J Surg* **72**, 303–304 (1985).
84. Khatoun, S. *et al.* Pilonidal sinus: Excision with primary midline closure versus open method. *J. Liaquat Univ. Med. Health Sci.* **9**, 9–11 (2010).
85. Stelzmueller, I. *et al.* Group Milleri Streptococci in perianal infections. *Colorectal disease: the official journal of the Association of Coloproctology of Great Britain and Ireland* **12**, e121–127 (2010).
86. Sondena, K., Nesvik, I., Andersen, E. & Soreide, J. A. Recurrent pilonidal sinus after excision with closed or open treatment: final result of a randomised trial. *Eur J Surg* **162**, 237–240 (1996).
87. Shafik, A. Electrocauterization in the treatment of pilonidal sinus. *Int Surg* **81**, 83–84 (1996).
88. Shah, A., Waheed, A. & Malik, A. Recurrence rates in pilonidal sinus surgery: Comparison of two techniques (Karydakias Versus Conventional Open Excision). *Pak. J. Med. Health Sci.* **3**, 91–95 (2009).
89. Obedman, M. & Vatican, D. Pilonidal sinus: a high-incidence disease among adolescents. *Int J Adolesc Med Health.* **6**, 21–36, <https://doi.org/10.1515/IJAMH.1993.6.1.21> (1993).
90. Bracho Bracho, J. & Lira Soto, N. M. Enfermedad pilonidal: tecnica cerrada Vs. tecnica abierta con anestesia local. *Boletin médico de postgrado* (1996).
91. Coda, A. & Ferri, F. Sinus pilonidalis: Removal and primary suture with aspirative draining [Sinus Pilonidalis: Escissione E Sutura Primaria Con Drenaggio Aspirativo]. *Chirurgia* **3**, 433–437 (1990).
92. Dahmann, S., Lebo, P. B. & Meyer-Marcotty, M. V. Comparison of Treatments for an Infected Pilonidal Sinus: Differences in Scar Quality and Outcome Between Secondary Wound Healing and Limberg Flap in a Prospective Study. *Handchir Mikrochir Plast Chir* **48**, 111–119, <https://doi.org/10.1055/s-0041-111322> (2016).
93. Sondena, K., Nesvik, I., Andersen, E., Pollard, M. L. & Soreide, J. A. Recurrent pilonidal sinus: Etiology and treatment. *Dig. Surg.* **12**, 117–120, <https://doi.org/10.1159/000172329> (1995).
94. Destito, C., Romagnoli, A., Pucello, D., Mercuri, M. & Marin, A. W. Pilonidal sinus: long term results of excision and closure technic. Review of the literature. *G Chir* **18**, 441–446 (1997).
95. Donati, A. *et al.* Heterologous lyophilized collagen in the secondary healing of pilonidal fistulae. *Minerva Chir* **48**, 141–145 (1993).
96. Leoni, G. *et al.* Sinus pilonidalis. Critical review of our experience [Sinus pilonidalis. Revisione critica della nostra esperienza]. *Chirurgia* **11**, 93–96 (1998).
97. Weckner, W. & Zorner, M. Treatment of pilonidal sinus [Beitrag zur Behandlung der Pilonidalkrankheit]. *Z. Arztl. Fortbild.* **75**, 903–906 (1981).
98. Meier, H. P. Recurrence in sacral dermoid (sinusitis pilonidalis sacralis). *Helv Chir Acta* **49**, 645–649 (1983).
99. Rosato, L., Fornero, G., Luc, A. R. & Clerico, G. The radical treatment of sacrococcygeal pilonidal cysts. *Minerva Chir* **52**, 1277–1279 (1997).
100. Sturniolo, G., Carditello, A., Bonavita, G., Bartolotta, M. & Saitta, E. Evaluation of the results of different types of surgical intervention for pilonidal fistula. *Minerva Chir* **39**, 1161–1164 (1984).
101. Grandjean, J. P. & Al Nashawati, G. Pilonidal disease treated by wide excision and controlled cicatrization. A report on 73 patients. *Lyon Chir* **92**, 292–295 (1996).
102. Garcia, J. C. & Dupuis, F. Surgical treatment of pilonidal disease. A new simplified technic. *J Chir (Paris)* **120**, 347–350 (1983).
103. Gupta, P. J. Radio surgery in pilonidal sinus: a new approach for the old problem. *Acta Chir Belg* **105**, 183–186 (2005).
104. Rouch, J. D. *et al.* Short- and Long-term Results of Unroofing and Marsupialization for Adolescent Pilonidal Disease. *JAMA Surg* **151**, 877–879, <https://doi.org/10.1001/jamasurg.2016.0850> (2016).
105. Houston, H. E. One-stage cure of infected pilonidal cysts. *Am Surg* **43**, 517–519 (1977).
106. Shah, S. T. A., Tahir, M., Nasir, M., Paracha, S. A. & Wahab, K. Outcome of open versus closed surgical technique for treatment of chronic pilonidal sinus: a randomized controlled trial. *Khyber Med Univ J* **5**, 146–151 (2013).
107. Tetrick, J. E. Limited excision of pilonidal cyst and sinus. *Ohio State Med J* **67**, 135–138 (1971).

108. Zagory, J. A., Golden, J., Holoyda, K., Demeter, N. & Nguyen, N. X. Excision and Primary Closure May Be the Better Option in the Surgical Management of Pilonidal Disease in the Pediatric Population. *Am Surg* **82**, 964–967 (2016).
109. Khodakaram, K., Stark, J., Hoglund, I. & Andersson, R. E. Minimal Excision and Primary Suture is a Cost-Efficient Definitive Treatment for Pilonidal Disease with Low Morbidity: A Population-Based Interventional and a Cross-Sectional Cohort Study. *World J Surg* **41**, 1295–1302, <https://doi.org/10.1007/s00268-016-3828-z> (2017).
110. Gupta, P. A comparison of two operations for pilonidal sinus disease. *Nig J Surg Res* **6**, 41–45 (2004).
111. Sasse, K. C., Brandt, J., Lim, D. C. & Ackerman, E. Accelerated healing of complex open pilonidal wounds using MatriStem extracellular matrix xenograft: nine cases. *J Surg Case Rep* **2013**, <https://doi.org/10.1093/jscr/rjt025> (2013).
112. Elbanna, H. G. *et al.* Novel Approach of Treatment of Pilonidal Sinus Disease With Thrombin Gelatin Matrix as a Sealant. *Dis Colon Rectum* **59**, 775–780, <https://doi.org/10.1097/DCR.0000000000000604> (2016).
113. Yamashita, Y., Nagae, H. & Hashimoto, I. Ambulatory Surgery for Pilonidal Sinus: Tract Excision and Open Treatment Followed by At-Home Irrigation. *J Med Invest* **63**, 216–218, <https://doi.org/10.2152/jmi.63.216> (2016).
114. Calikoglu, I. *et al.* Phenol Injection Versus Excision With Open Healing in Pilonidal Disease: A Prospective Randomized Trial. *Dis Colon Rectum* **60**, 161–169, <https://doi.org/10.1097/DCR.0000000000000717> (2017).
115. Carstensen, E. & Keichel, F. Etiology and therapy of pilonidal sinus. *Chirurg* **34**, 303–308 (1963).
116. Speter, C., Zmora, O., Nadler, R., Shinhar, D. & Bilik, R. Minimal incision as a promising technique for resection of pilonidal sinus in children. *J Pediatr Surg*, <https://doi.org/10.1016/j.jpedsurg.2017.03.040> (2017).
117. Gerhard, H. On the understanding and treating coccygeal fustulae. *Z. Arztl. Fortbild.* **57**, 841–843 (1963).
118. Ozcan, R. *et al.* Which treatment modality for pediatric pilonidal sinus: Primary repair or secondary healing? *Asian J Surg*, <https://doi.org/10.1016/j.asjsur.2017.08.006> (2017).
119. Shirah, B. H. & Shirah, H. A. Factors affecting the outcome and duration of healing of the laid open wound for sacrococcygeal pilonidal sinus: A prospective cohort study of 472 patients. *Wound Medicine* **18**, 52–56, <https://doi.org/10.1016/j.wndm.2017.06.005> (2017).
120. Zuin, M., Fogato, L. & Badin, A. Common risk factors for pilonidal sinus disease recurrence impact the onset of new cardiovascular disease in the longterm: a 5-year follow-up study. *World J Surg* (2017).
121. Danne, J., Gwini, S., McKenzie, D. & Danne, P. A Retrospective Study of Pilonidal Sinus Healing by Secondary Intention Using Negative Pressure Wound Therapy Versus Alginate or Gauze Dressings. *Ostomy Wound Manage* **63**, 47–53 (2017).
122. Doll, D. *et al.* Methylene Blue halves the long-term recurrence rate in acute pilonidal sinus disease. *Int J Colorectal Dis* **23**, 181–187, <https://doi.org/10.1007/s00384-007-0393-9> (2008).
123. Bunke, H. J., Schultheis, A., Meyer, G. & Dusel, W. Surgical revision of the pilonidal sinus with single shot antibiotics. *Chirurg* **66**, 220–223 (1995).
124. Kam, B. H. A simple surgical method of treating pilonidal sinus. *Arch Chir Neerl* **28**, 43–53 (1976).
125. Rainsbury, R. M. & Southam, J. A. Radical surgery for pilonidal sinus. *Annals of the Royal College of Surgeons of England* **64**, 339–341 (1982).
126. Sondenaar, K., Andersen, E., Nesvik, I. & Soreide, J. A. Patient characteristics and symptoms in chronic pilonidal sinus disease. *Int J Colorectal Dis* **10**, 39–42 (1995).
127. Akca, T., Colak, T., Ustunsoy, B., Kanik, A. & Aydin, S. Randomized clinical trial comparing primary closure with the Limberg flap in the treatment of primary sacrococcygeal pilonidal disease. *Br J Surg* **92**, 1081–1084, <https://doi.org/10.1002/bjs.5074> (2005).
128. Abu Galala, K. H. *et al.* Treatment of pilonidal sinus by primary closure with a transposed rhomboid flap compared with deep suturing: a prospective randomised clinical trial. *Eur J Surg* **165**, 468–472 (1999).
129. Limongelli, P. *et al.* D-shape asymmetric and symmetric excision with primary closure in the treatment of sacrococcygeal pilonidal disease. *Am J Surg* **207**, 882–889, <https://doi.org/10.1016/j.amjsurg.2013.06.013> (2014).
130. Khan, P. S., Hayat, H. & Hayat, G. Limberg flap versus primary closure in the treatment of primary sacrococcygeal pilonidal disease; a randomized clinical trial. *Indian J Surg* **75**, 192–194, <https://doi.org/10.1007/s12262-012-0430-y> (2013).
131. Dass, T. A., Zaz, M., Rather, A. & Bari, S. Elliptical excision with midline primary closure versus rhomboid excision with limberg flap reconstruction in sacrococcygeal pilonidal disease: a prospective, randomized study. *Indian J Surg* **74**, 305–308, <https://doi.org/10.1007/s12262-011-0400-9> (2012).
132. Aldean, I., Shankar, P. J., Mathew, J., Safarani, N. & Haboubi, N. Y. Simple excision and primary closure of pilonidal sinus: a simple modification of conventional technique with excellent results. *Colorectal Dis* **7**, 81–85, <https://doi.org/10.1111/j.1463-1318.2004.00736.x> (2005).
133. Can, M. F., Sevinc, M. M. & Yilmaz, M. Comparison of Karydakís flap reconstruction versus primary midline closure in sacrococcygeal pilonidal disease: results of 200 military service members. *Surg Today* **39**, 580–586, <https://doi.org/10.1007/s00595-008-3926-0> (2009).
134. Gilani, S. N. *et al.* Excision and primary closure of pilonidal sinus disease: worthwhile option with an acceptable recurrence rate. *Ir J Med Sci* **180**, 173–176, <https://doi.org/10.1007/s11845-010-0532-0> (2011).
135. Enshaei, A. & Motearefi, S. Comparison of two surgical methods, primary closure and rotational flap, in patients with chronic pilonidal sinus. *Glob J Health Sci* **6**, 18–22, <https://doi.org/10.5539/gjhs.v6n7p18> (2014).
136. Emir, S., Topuz, O., Kanat, B. H. & Bali, I. Sinotomy technique versus surgical excision with primary closure technique in pilonidal sinus disease. *Bosn J Basic Med Sci* **14**, 263–267, <https://doi.org/10.17305/bjbm.2014.4.139> (2014).
137. Osmanoglu, G. & Yetisir, F. Limberg flap is better for the surgical treatment of pilonidal sinus. Results of a 767 patients series with an at least five years follow-up period. *Chirurgia (Bucur)* **106**, 491–494 (2011).
138. Lorant, T., Ribbe, I., Mahteme, H., Gustafsson, U. M. & Graf, W. Sinus excision and primary closure versus laying open in pilonidal disease: a prospective randomized trial. *Dis Colon Rectum* **54**, 300–305, <https://doi.org/10.1007/DCR.0b013e31820246bf> (2011).
139. Onder, A. *et al.* Pilonidal sinus disease: risk factors for postoperative complications and recurrence. *Int Surg* **97**, 224–229, <https://doi.org/10.9738/CC86.1> (2012).
140. Galal Elshazly, W. & Said, K. Clinical trial comparing excision and primary closure with modified Limberg flap in the treatment of uncomplicated sacrococcygeal pilonidal disease. *Alexandria Journal of Medicine* **48**, 13–18, <https://doi.org/10.1016/j.ajme.2011.10.002> (2012).
141. Al-Jaberi, T. M. Excision and simple primary closure of chronic pilonidal sinus. *Eur J Surg* **167**, 133–135 (2001).
142. Khaira, H. S. & Brown, J. H. Excision and primary suture of pilonidal sinus. *Ann R Coll Surg Engl* **77**, 242–244 (1995).
143. Gencosmanoglu, R. & Inceoglu, R. Modified lay-open (incision, curettage, partial lateral wall excision and marsupialization) versus total excision with primary closure in the treatment of chronic sacrococcygeal pilonidal sinus: a prospective, randomized clinical trial with a complete two-year follow-up. *Int J Colorectal Dis* **20**, 415–422, <https://doi.org/10.1007/s00384-004-0710-5> (2005).
144. Tritapepe, R. & Di Padova, C. Excision and primary closure of pilonidal sinus using a drain for antiseptic wound flushing. *Am J Surg* **183**, 209–211 (2002).
145. El-Shaer, W. M. The modified gluteal sliding plication closure in the treatment of chronic pilonidal sinus. *Int J Colorectal Dis* **25**, 887–894, <https://doi.org/10.1007/s00384-010-0911-z> (2010).
146. Milone, M., Musella, M., Salvatore, G., Leongito, M. & Milone, F. Effectiveness of a drain in surgical treatment of sacrococcygeal pilonidal disease. Results of a randomized and controlled clinical trial on 803 consecutive patients. *Int J Colorectal Dis* **26**, 1601–1607, <https://doi.org/10.1007/s00384-011-1242-4> (2011).

147. Serour, F., Somekh, E., Krutman, B. & Gorenstein, A. Excision with primary closure and suction drainage for pilonidal sinus in adolescent patients. *Pediatr Surg Int* **18**, 159–161, <https://doi.org/10.1007/s003830100683> (2002).
148. Ertan, T. *et al.* Does technique alter quality of life after pilonidal sinus surgery? *Am J Surg* **190**, 388–392, <https://doi.org/10.1016/j.amjsurg.2004.08.068> (2005).
149. Alptekin, H. *et al.* Specimen index may be a predictive factor for recurrence after primary closure of pilonidal disease. *J Korean Surg Soc* **83**, 367–373, <https://doi.org/10.4174/jkss.2012.83.6.367> (2012).
150. Andersson, R. E., Lukas, G., Skullman, S. & Hugander, A. Local administration of antibiotics by gentamicin-collagen sponge does not improve wound healing or reduce recurrence rate after pilonidal excision with primary suture: a prospective randomized controlled trial. *World J Surg* **34**, 3042–3048, <https://doi.org/10.1007/s00268-010-0763-2> (2010).
151. Badawy, E. A. & Kanawati, M. N. Effect of hair removal by Nd:YAG laser on the recurrence of pilonidal sinus. *J Eur Acad Dermatol Venereol* **23**, 883–886, <https://doi.org/10.1111/j.1468-3083.2009.03147.x> (2009).
152. Lee, S. L., Tejirian, T. & Abbas, M. A. Current management of adolescent pilonidal disease. *J Pediatr Surg* **43**, 1124–1127, <https://doi.org/10.1016/j.jpedsurg.2008.02.042> (2008).
153. Othman, I. Skin glue improves outcome after excision and primary closure of sacrococcygeal pilonidal disease. *Indian J Surg* **72**, 470–474, <https://doi.org/10.1007/s12262-010-0170-9> (2010).
154. Courtney, S. P. & Merlin, M. J. The use of fusidic acid gel in pilonidal abscess treatment: cure, recurrence and failure rates. *Ann R Coll Surg Engl* **68**, 170–171 (1986).
155. Williams, R. S. A simple technique for successful primary closure after excision of pilonidal sinus disease. *Ann R Coll Surg Engl* **72**, 313–314; discussion 314–315 (1990).
156. Tejirian, T., Lee, J. J. & Abbas, M. A. Is wide local excision for pilonidal disease still justified? *Am Surg* **73**, 1075–1078 (2007).
157. Shons, A. R. & Mountjoy, J. R. Pilonidal disease: the case for excision with primary closure. *Dis Colon Rectum* **14**, 353–355 (1971).
158. Terzi, C., Canda, A. E., Unek, T., Dalgic, E. & Fuzun, M. What is the role of mechanical bowel preparation in patients with pilonidal sinus undergoing surgery? Prospective, randomized, surgeon-blinded trial. *World J Surg* **29**, 1465–1471, <https://doi.org/10.1007/s00268-005-0007-z> (2005).
159. Aysan, E., Basak, F., Kinaci, E. & Sevinc, M. Efficacy of local adrenalin injection during sacrococcygeal pilonidal sinus excision. *Eur Surg Res* **36**, 256–258, <https://doi.org/10.1159/000078861> (2004).
160. Arda, I. S., Guney, L. H., Sevmis, S. & Hicsonmez, A. High body mass index as a possible risk factor for pilonidal sinus disease in adolescents. *World J Surg* **29**, 469–471, <https://doi.org/10.1007/s00268-004-7533-y> (2005).
161. Tocchi, A. *et al.* Ambulatory closed surgery for the treatment of pilonidal sinus. *G Chir* **22**, 303–307 (2001).
162. Toccaceli, S., Persico Stella, L., Diana, M., Dandolo, R. & Negro, P. Treatment of pilonidal sinus with primary closure. A twenty-year experience. *Chir Ital* **60**, 433–438 (2008).
163. Örhalmi, J., Sotona, O., Dusek, T. & Ferko, A. Pilonidal sinus - possibilities surgical treatment. *Rozhl Chir* **93**, 491–495 (2014).
164. Russell, J. L. A method of excision and primary closure of pilonidal cysts and sinuses. *Can Med Assoc J* **60**, 267–270 (1949).
165. Muzi, M. G. *et al.* Randomized comparison of Limberg flap versus modified primary closure for the treatment of pilonidal disease. *Am J Surg* **200**, 9–14, <https://doi.org/10.1016/j.amjsurg.2009.05.036> (2010).
166. Milone, M. *et al.* Intradermal absorbable sutures to close pilonidal sinus wounds: a safe closure method? *Surg Today* **44**, 1638–1642, <https://doi.org/10.1007/s00595-013-0741-z> (2014).
167. Gipponi, M., Reboa, G., Testa, T., Giannini, G. & Strada, P. Tension-free primary closure with autologous platelet gel versus Vivostat- for the definitive treatment of chronic sacrococcygeal pilonidal disease. *In Vivo* **24**, 583–589 (2010).
168. Biffoni, M. *et al.* Pilonidal sinus. Outpatient treatment with local anesthesia. *G Chir* **30**, 173–176 (2009).
169. Inan, A., Surgit, O., Sen, M., Bozer, M. & Dener, C. One day surgery for pilonidal disease. *Bratisl Lek Listy* **112**, 572–574 (2011).
170. Lee, H. C., Ho, Y. H., Seow, C. F., Eu, K. W. & Nyam, D. Pilonidal disease in Singapore: clinical features and management. *Aust N Z J Surg* **70**, 196–198 (2000).
171. Muzi, M. G., Milito, G., Nigro, C., Cadreddu, F. & Farinon, A. M. A modification of primary closure for the treatment of pilonidal disease in day-care setting. *Colorectal Dis* **11**, 84–88, <https://doi.org/10.1111/j.1463-1318.2008.01534.x> (2009).
172. Sevinc, B. *et al.* Randomized prospective comparison of midline and off-midline closure techniques in pilonidal sinus surgery. *Surgery* **159**, 749–754, <https://doi.org/10.1016/j.surg.2015.09.024> (2016).
173. Nursal, T. Z. *et al.* Prospective randomized controlled trial comparing V-Y advancement flap with primary suture methods in pilonidal disease. *Am J Surg* **199**, 170–177, <https://doi.org/10.1016/j.amjsurg.2008.12.030> (2010).
174. Yildiz, T., Ilce, Z. & Kucuk, A. Modified Limberg flap technique in the treatment of pilonidal sinus disease in teenagers. *J Pediatr Surg* **49**, 1610–1613, <https://doi.org/10.1016/j.jpedsurg.2014.06.011> (2014).
175. Cruz, J. & Ram, M. D. Sacrococcygeal pilonidal sinus. *Dis Colon Rectum* **14**, 356–359 (1971).
176. Kaya, B., Uctum, Y., Simsek, A. & Kutanis, R. Primary closure in the treatment of pilonidal disease. An easy and effective method. *Kolon Rektum Hast Derg* **20**, 59–65 (2010).
177. Abbasi, H. R., Hosseini, S. V., Yarmohammadi, H. & Bolandparvaz, S. Comparison between two methods of excision and primary closure of pilonidal sinus. *Wound pain* **9**, 143–146 (2007).
178. Braungart, S., Powis, M., Sutcliffe, J. R. & Sugarman, I. D. Improving outcomes in pilonidal sinus disease. *J Pediatr Surg* **51**, 282–284, <https://doi.org/10.1016/j.jpedsurg.2015.10.076> (2016).
179. Milone, M. *et al.* Pilonidal sinus surgery: could we predict postoperative complications? *Int Wound J*, <https://doi.org/10.1111/iwj.12310> (2014).
180. Doll, D. *et al.* Does gentamycin affect long term recurrence rate in pilonidal sinus surgery? *European Surgery* **43**, 236–243, <https://doi.org/10.1007/s10353-011-0615-9> (2011).
181. Ferguson, L. K. Pilonidal Cysts: Treatment by Excision and Primary Suture in Ambulatory Patients. *Ann Surg* **101**, 469–477 (1935).
182. Galati, G., Sterpetti, A. V. & Tartaglia, E. Therapeutic approaches to patients with pilonidal sinus based on specific clinical characteristic. *Eur J Plast Surg* **35**, 595–598 (2012).
183. Talu, M., Yücel, O. & User, Y. Oblique excision with primary closure for the treatment of pilonidal sinus. *Eur J Plast Surg* **19**, 200–203 (1996).
184. Sakr, M. F., Hamed, H. H., Ramadan, M. A., Kantoush, H. E. & Al-Torky, H. M. Pilonidal sinus in Kuwait: Analysis of 801 consecutive patients (2012).
185. Washer, J. D., Smith, D. E., Carman, M. E. & Blackhurst, D. W. Gluteal fascial advancement: an innovative, effective method for treating pilonidal disease. *Am Surg* **76**, 154–156 (2010).
186. Muzi, M. G. *et al.* Long-term results of pilonidal sinus disease with modified primary closure: new technique on 450 patients. *Am Surg* **80**, 484–488 (2014).
187. Miocinovic, M., Horzic, M. & Bunoza, D. The treatment of pilonidal disease of the sacrococcygeal region by the method of limited excision and open wound healing. *Acta Med Croatica* **54**, 27–31 (2000).
188. Sondena, K. *et al.* Influence of failure of primary wound healing on subsequent recurrence of pilonidal sinus. combined prospective study and randomised controlled trial. *Eur J Surg* **168**, 614–618 (2002).
189. Sakr, M. F., Elserafy, M. E. & Hamed, H. M. Management of 634 Consecutive Patients with Chronic Pilonidal Sinus: A Nine-Year Experience of a Single Institute. *Surgical Science* **3**, 145–154 (2012).
190. Youssef, T., El-Awady, S. & Farid, M. Tension-free primary closure compared with modified Limberg flap for pilonidal sinus disease: a prospective balanced randomized study. *The Egyptian Journal of Surgery* **34**, 85–89 (2015).

191. Mahdy, T. Surgical treatment of the pilonidal disease: primary closure or flap reconstruction after excision. *Dis Colon Rectum* **51**, 1816–1822, <https://doi.org/10.1007/s10350-008-9436-8> (2008).
192. Saylam, B., Balli, D. N., Duzgun, A. P., Ozer, M. V. & Coskun, F. Which surgical procedure offers the best treatment for pilonidal disease? *Langenbecks Arch Surg* **396**, 651–658, <https://doi.org/10.1007/s00423-011-0768-9> (2011).
193. Smith, C. M., Jones, A., Dass, D., Murthi, G. & Lindley, R. Early experience of the use of fibrin sealant in the management of children with pilonidal sinus disease. *J Pediatr Surg* **50**, 320–322, <https://doi.org/10.1016/j.jpedsurg.2014.11.022> (2015).
194. Khanzada, T. W. & Samad, A. Recurrence after excision and primary closure of pilonidal sinus. *Pak. J. Med. Sci.* **23**, 375–379 (2007).
195. Sakr, M. F. & Moussa, M. A prospective controlled randomized trial comparing Karydakís technique and midline closure in patients with recurrent chronic pilonidal sinus. *Surg. Chronicles* **16**, 84–90 (2011).
196. Siddiqui, S. S. & Khan, M. A. Pilonidal sinus: Following the Aristotelian middle! *Pak. J. Med. Sci.* **24**, 845–848 (2008).
197. Benfatto, G. *et al.* Drainage useful in the excision and closure “per primam” of pilonidal sinus: technical notes. *Chir Ital* **55**, 621–624 (2003).
198. Bouq, Y. A., Fazili, F. M., Fawzi, H. A. G. & Parvez, T. Surgical management of pilonidal disease: Our experience. *JK Pract.* **11**, 21–26 (2004).
199. Polat, N., Albayrak, D., Ibiş, A. C. & Altan, A. Comparison between karydakís flap repair and primary closure for surgical treatment of sacrococcygeal pilonidal sinus [Sakrokoksigel pilonidal sinüsün cerrahi tedavisinde karydakís flep ameliyatı ile primer kapamanın karşılaştırılması]. *Trakya Universitesi Tip Fakultesi Dergisi* **25**, 87–94 (2008).
200. Toydemir, T., Peşluk, O., Ermeç, E. D. & Turhan, A. N. Comparison of the clinical outcomes of karydakís flap versus primary closure procedures in the surgical treatment of sacrococcygeal pilonidal sinus disease [Sakrokoksigel pilonidal sinüs hastalığının cerrahi tedavisinde karydakís flep ile primer kapama prosedürlerinin klinik sonuçlarının karşılaştırılması]. *Med. J. Bakirkoy* **8**, 78–81, <https://doi.org/10.5350/BTDMJB201208206> (2012).
201. Çağlayan, K. *et al.* The effect of different surgical methods on complications and on the quality of life in pilonidal sinus disease. *Turk. J. Surg.* **27**, 94–97, <https://doi.org/10.5097/1300-0705.UCD.950-11.03> (2011).
202. Sakr, M., Habib, M. & Shaheed, A. A. Assessment of Karydakís technique as compared with midline closure for the management of chronic pilonidal sinus. *J. Pelvic Med. Surg.* **12**, 201–206, <https://doi.org/10.1097/01.spv.0000217399.78641.43> (2006).
203. Albahadili, M. A. & Awazli, L. G. Pilonidal Sinus Excision Using Carbon Dioxide Laser 10600nm. *Iraqi J Laser* **14**, 33–40 (2015).
204. Novotny, G. M. E. and Primary Closure of Pilonidal Sinus. A Critical Review of Forty-Five Cases. *Med Serv J Can* **20**, 352–354 (1964).
205. Maniscalco, L., Speranza, G. & Maniscalco, A. The pilonidal sinus: Which management? [Il seno pilonidale: Come trattarlo?]. *Chirurgia* **14**, 81–83 (2001).
206. Corsi, P. R., Corsi, R., Moura, L. F. R. A., Guerreiro, T. D. T. & Vasconcellos, L. P. Tratamento cirurgico do cisto pilonidal atraves de ressecao e fechamento primario com retalhos cutaneos. *Revista brasileira de colo-proctologia* (2004).
207. Jarufe, C. N., Bannura, G., Contreras, J., Saxton, F. & Marro, P. Enfermedad pilonidal cronica sacrococcygea. *Rev. Chil. Cir.* **51**, 66–71 (1999).
208. Blake P. P. *et al.* Tratamiento quirurgico del quiste pilonidal. *Rev. Chil. Cir* (1997).
209. Alberti, P., Antoci, G., Pasini, M. & Pasini, G. F. Pilonidal sinus: our experience in the surgical treatment by closed method. *Minerva Chir* **45**, 733–737 (1990).
210. Aaser, P. & Gruner, O. P. Pilonidal cysts. Excision and intracutaneous absorbable primary suture. *Tidsskr Nor Laegeforen* **112**, 206–207 (1992).
211. Klug, W., Knoch, H. G. & Holland-Moritz, A. Sinus pilonidalis. *Zeitschrift für ärztliche Fortbildung* **78**, 711–714 (1984).
212. Bissett, I. P. & Isbister, W. H. The management of patients with pilonidal disease - a comparative study. *Aust N Z J Surg* **57**, 939–942 (1987).
213. Sondena, K. *et al.* The role of cefoxitin prophylaxis in chronic pilonidal sinus treated with excision and primary suture. *J Am Coll Surg* **180**, 157–160 (1995).
214. Palmieri, B., Gozzi, G. & Rossi, A. Pilonidal cysts: the state of the art and the authors’ personal experiences. *Minerva Chir* **49**, 377–382 (1994).
215. Diana, G., Muscarella, F., Pepe, D. & Speciale, A. Primary closure in the treatment of pilonidal sinus. Evaluation of immediate and remote results [La chiusura per primam nel trattamento del sinus pilonidalis. Valutazione dei risultati immediati e a distanza]. *Minerva Chir.* **41**, 765–767 (1986).
216. Muller, X. M., Rothenbuhler, J. M. & Frede, K. E. Sacro-coccygeal cyst: surgical techniques and results]. *Helv Chir Acta* **58**, 889–892 (1992).
217. Angermann, P. & Beiter, E. C. [Pilonidal cyst. A sequence treated with excision and primary suture. *Ugeskr Laeger* **146**, 24–26 (1984).
218. Mecchia, P., Tonizzo, C. A. & Flaminia, M. Pilonidal cysts and fistulas: radical excision “en bloc” and closure “per primam”. *Minerva Chir* **50**, 553–556 (1995).
219. Rossi, P. *et al.* The pilonidal sinus: its surgical treatment, our experience and a review of the literature. *G Chir* **14**, 120–123 (1993).
220. Sias, F., Licheri, S., Secci, L., Loi, R. & Daniele, G. M. Ambulatory treatment of pilonidal sinus IL Trattamento Ambulatoriale Del Sinus Pilonidalis. *Chirurgia* **7**, 639–642 (1994).
221. Pozzi, C. & Tritapepe, R. Healing of the operative wound after radical removal of the Sinus pilonidalis [Guarigione per prima intenzione dopo intervento radicale asportazione del Sinus Pilonidalis]. *Minerva Chir.* **44**, 2329–2332 (1989).
222. Virgillo, G., Mendicino, F. & Costanzo, A. Sinus pilonidalis. Brief review of literature and contribution to surgical therapy [Il Sinus Pilonidalis. Rivista sintetica della letteratura e contributo alla terapia chirurgica]. **27**, 1–40 (1975).
223. Christensen, K., Kronborg, O., Zimmermann-Nielsen, C. & Olsen, H. Incision or primary suture in acute pilonidal abscesses. A prospective randomized study. *Ugeskr Laeger* **147**, 3479–3481 (1985).
224. Sarles, J. C., Sastre, B. & Delecourt, P. Treatment of pilonidal cyst with radical excision and primary closure (author’s transl). *Gastroenterol Clin Biol* **1**, 929–932 (1977).
225. Verbeek, H. O. & Bender, J. Results of treatment of pilonidal sinus by block excision and primary suture. *Arch Chir Neerl* **26**, 311–318 (1974).
226. Schonk, J. W. Some aspects of the treatment of the pilonidal sinus. *Arch Chir Neerl* **23**, 297–302 (1971).
227. Powell, B. C., Webb, C. B., Ewing, J. A. & Smith, D. E. Gluteal Fascial Advancement for Pilonidal Cyst Disease: A 10-year Review. *Am Surg* **82**, 622–625 (2016).
228. Ghannam, W., Ghazy, H., Saed, B. & Farid, M. Limited excision and primary closure for pilonidal sinus. *Egypt J Surg* **28**, 43–47 (2009).
229. Almajid, F. M., Alabdralnabi, A. A. & Almulhim, K. A. The risk of recurrence of Pilonidal disease after surgical management. *Saudi Med J* **38**, 70–74, <https://doi.org/10.15537/smj.2017.1.15892> (2017).
230. Liboni, N. S. & Fregnani, C. H. T. G. Preliminary results from 28 cases of pilonidal cyst treated by excision and primary closure of the wound, reinforced with support suturing. *Einstein* **5**, 148–152 (2007).
231. Roshdy, H., Ali, Y., Askar, W., Awad, I. & Farid, M. Rhomboid flap versus primary closure after excision of sacrococcygeal pilonidal sinus (a prospective randomized study). *Egypt J Surg* **29**, 146–152 (2010).
232. Çağlayan, K. *et al.* Investigation of Patient Dependent Factors Effecting Complications and Recurrence in Pilonidal Sinus Disease. *Kolon Rektum Hast Derg* **21**, 103–108 (2011).

233. Pomazkin, V. I. & Mansurov, I. V. Choice of operation for treatment of patients with pilonidal sinus. *Vestn Khir Im I I Grek* **167**, 85–87 (2008).
234. Grubnik, V. V. & Bakhar, G. A. The use of a laser in the surgical treatment of an epithelial coccygeal cyst. *Klin Khir*, 23–25 (1993).
235. de Quinta Frutosa, R. *et al.* Enfermedad pilonidal. Tratamiento por exéresis en bloque con cierre primario. *Cir Esp* **68**, 570–572 (2000).
236. Wani, M., Shah, M., Wani, K. & Malik, A. Excision and primary closure of sacrococcygeal pilonidal sinus using suction drain. *International Surgery Journal*, 837–840, <https://doi.org/10.18203/2349-2902.isj20161158> (2016).
237. Bowers, W. F. & Williamson, W. S. Pilonidal sinus; preliminary report on a fresh approach. *AMA Arch Surg* **73**, 931–935 (1956).
238. Abou-Zikry, A. S., Guindi, A. & Hashem, M. Pilonidal sinus and cysts (sacro-coccygeal sinus); report of 22 cases treated by excision and primary suture. *J Egypt Med Assoc* **37**, 696–705 (1954).
239. Frostad, H. Sacral dermoidcysts. Especially with a view to their treatment. *Acta chir scand* **93**, 23 (1946).
240. Muzi, M. G. *et al.* 389 - Muzi's Tension Free Primary Closure of Pilonidal Sinus Disease: Long-Term Results on 450 Patients. *Gastroenterology* **152**, S1212–S1213, [https://doi.org/10.1016/S0016-5085\(17\)34034-9](https://doi.org/10.1016/S0016-5085(17)34034-9) (2017).
241. Darwish, A., Eskandaros, M. & Hegab, A. Sacrococcygeal pilonidal sinus: modified sinotomy versus lay-open, limited excision, and primary closure. *The Egyptian Journal of Surgery* **36**, 13–19, <https://doi.org/10.4103/1110-1121.199901> (2017).
242. Ates, U. *et al.* Pilonidal sinus disease surgery in children: the first study to compare crystallized phenol application to primary excision and closure. *J Pediatr Surg*, <https://doi.org/10.1016/j.jpedsurg.2017.05.012> (2017).
243. Kose, E., Hasbahceci, M., Tonyali, H. & Karagulle, M. Comparative analysis of the same technique-the same surgeon approach in the surgical treatment of pilonidal sinus disease: a retrospective cohort study. *Ann Surg Treat Res* **93**, 82–87, <https://doi.org/10.4174/ast.2017.93.2.82> (2017).
244. Ahmadi, M., Ahmadi, K., Ahmadi, I., Masoud Hashemian, A. & Khademhoseini, P. A Comparison between the Tie-over and Closed Suction Drainage Therapeutic Strategies in Patients Suffering from Sacral Pilonidal Sinus. *Int J Biomed Sci* **12**, 149–154 (2016).
245. Hulsten, L. Sacral Dermoid-Pilonidal Sinus. *Nord Med* **74**, 699–703 (1965).
246. Okus, A., Sevinc, B., Karahan, O. & Eryilmaz, M. A. Comparison of Limberg flap and tension-free primary closure during pilonidal sinus surgery. *World J Surg* **36**, 431–435, <https://doi.org/10.1007/s00268-011-1333-y> (2012).
247. Menten, O. *et al.* Management of pilonidal sinus disease with oblique excision and primary closure: results of 493 patients. *Dis Colon Rectum* **49**, 104–108, <https://doi.org/10.1007/s10350-005-0226-2> (2006).
248. Akinci, O. F. Limited separate elliptical excision for complicated pilonidal disease. *Colorectal Dis* **7**, 424–425, <https://doi.org/10.1111/j.1463-1318.2005.00824.x> (2005).
249. Kitchen, P. R. Pilonidal sinus: experience with the Karydakias flap. *Br J Surg* **83**, 1452–1455 (1996).
250. Marzouk, D. M., Abou-Zeid, A. A., Antoniou, A., Haji, A. & Benziger, H. Sinus excision, release of coccygocutaneous attachments and dermal-subcuticular closure (XRD procedure): a novel technique in flattening the natal cleft in pilonidal sinus treatment. *Ann R Coll Surg Engl* **90**, 371–376, <https://doi.org/10.1308/003588408X285955> (2008).
251. Senapati, A., Cripps, N. P., Flashman, K. & Thompson, M. R. Cleft closure for the treatment of pilonidal sinus disease. *Colorectal Dis* **13**, 333–336, <https://doi.org/10.1111/j.1463-1318.2009.02148.x> (2011).
252. Maghsoudi, H., Nezami, N. & Ghamari, A. A. Ambulatory treatment of chronic pilonidal sinuses with lateral incision and primary suture. *Can J Surg* **54**, 78–82, <https://doi.org/10.1503/cjs.026309> (2011).
253. Ciftci, F., Abdurrahman, I., Tosun, M. & Bas, G. A new approach: oblique excision and primary closure in the management of acute pilonidal disease. *Int J Clin Exp Med* **7**, 5706–5710 (2014).
254. Greenberg, R., Kashtan, H., Skornik, Y. & Werbin, N. Treatment of pilonidal sinus disease using fibrin glue as a sealant. *Tech Coloproctol* **8**, 95–98, <https://doi.org/10.1007/s10151-004-0063-7> (2004).
255. Kim, J. K., Jeong, J. C., Lee, J. B., Jung, K. H. & Bae, B. K. S-plasty for pilonidal disease: modified primary closure reducing tension. *J Korean Surg Soc* **82**, 63–69, <https://doi.org/10.4174/jkss.2012.82.2.63> (2012).
256. Bruscianno, L. *et al.* D-shape asymmetric excision of sacrococcygeal pilonidal sinus with primary closure, suction drain, and subcuticular skin closure: an analysis of risks factors for long-term recurrence. *Surg Innov* **22**, 143–148, <https://doi.org/10.1177/1553350614535856> (2015).
257. Zimmerman, C. E. Outpatient excision and primary closure of pilonidal cysts and sinuses. *Am J Surg* **136**, 640–642 (1978).
258. Ibrahim, A. M. R. R. Oblique excision and primary closure of pilonidal sinus (sacrococcygeal). *Trends Med. Res.* **7**, 62–69, <https://doi.org/10.3923/tmr.2012.62.69> (2012).
259. Bulus, H. & Coskun, A. Is Asymmetric excision primary closure at treatment of pylonidal sinus disease an appropriate choice? *J. Clin. Anal. Med.* **2**, 79–81, <https://doi.org/10.4328/jcam.279> (2011).
260. Docimo, L. *et al.* Primary closure of decentred wounds in surgical treatment of pilonidal sinus [La lateralizzazione della cicatrice nel trattamento chirurgico del sinus pilonidalis]. *Chirurgia* **11**, 239–244 (1998).
261. Karip, A. B. *et al.* Effect of Triclosan-Coated Suture and Antibiotic Prophylaxis on Infection and Recurrence after Karydakias Flap Repair for Pilonidal Disease: A Randomized Parallel-Arm Double-Blinded Clinical Trial. *Surg Infect (Larchmt)* **17**, 583–588, <https://doi.org/10.1089/sur.2015.207> (2016).
262. Yildiz, M. K. *et al.* Karydakias flap procedure in patients with sacrococcygeal pilonidal sinus disease: experience of a single centre in Istanbul. *Scientific World Journal* **2013**, 807027, <https://doi.org/10.1155/2013/807027> (2013).
263. Sewefy, A. M., Hassanen, A., Atia, A. M. & Saleh, S. K. Karydakias Flap With Compressing Tie-over Interrupted Sutures Without Drain versus Standard Karydakias for Treatment of Sacrococcygeal Pilonidal Sinus Disease. *Dis Colon Rectum* **60**, 514–520, <https://doi.org/10.1097/DCR.0000000000000784> (2017).
264. Akinci, O. F., Coskun, A. & Uzunkoy, A. Simple and effective surgical treatment of pilonidal sinus: asymmetric excision and primary closure using suction drain and subcuticular skin closure. *Dis Colon Rectum* **43**, 701–706; discussion 706–707 (2000).
265. Anyanwu, A. C., Hossain, S., Williams, A. & Montgomery, A. C. Karydakias operation for sacrococcygeal pilonidal sinus disease: experience in a district general hospital. *Ann R Coll Surg Engl* **80**, 197–199 (1998).
266. Abdul-Ghani, A. K., Abdul-Ghani, A. N. & Ingham Clark, C. L. Day-care surgery for pilonidal sinus. *Ann R Coll Surg Engl* **88**, 656–658, <https://doi.org/10.1308/003588406X149255> (2006).
267. Guner, A. *et al.* Limberg flap versus Bascom cleft lift techniques for sacrococcygeal pilonidal sinus: prospective, randomized trial. *World J Surg* **37**, 2074–2080, <https://doi.org/10.1007/s00268-013-2111-9> (2013).
268. Arslan, K. *et al.* Which flap method should be preferred for the treatment of pilonidal sinus? A prospective randomized study. *Tech Coloproctol* **18**, 29–37, <https://doi.org/10.1007/s10151-013-0982-2> (2014).
269. Moran, D. C., Kavanagh, D. O., Adhmed, I. & Regan, M. C. Excision and primary closure using the Karydakias flap for the treatment of pilonidal disease: outcomes from a single institution. *World J Surg* **35**, 1803–1808, <https://doi.org/10.1007/s00268-011-1138-z> (2011).
270. Ates, M., Dirican, A., Sarac, M., Aslan, A. & Colak, C. Short and long-term results of the Karydakias flap versus the Limberg flap for treating pilonidal sinus disease: a prospective randomized study. *Am J Surg* **202**, 568–573, <https://doi.org/10.1016/j.amjsurg.2010.10.021> (2011).
271. Bessa, S. S. Results of the lateral advancing flap operation (modified Karydakias procedure) for the management of pilonidal sinus disease. *Dis Colon Rectum* **50**, 1935–1940, <https://doi.org/10.1007/s10350-007-9049-7> (2007).

272. Bessa, S. S. Comparison of short-term results between the modified Karydakís flap and the modified Limberg flap in the management of pilonidal sinus disease: a randomized controlled study. *Dis Colon Rectum* **56**, 491–498, <https://doi.org/10.1097/DCR.0b013e31828006f7> (2013).
273. Can, M. F., Sevinc, M. M., Hancerliogullari, O., Yilmaz, M. & Yagci, G. Multicenter prospective randomized trial comparing modified Limberg flap transposition and Karydakís flap reconstruction in patients with sacrococcygeal pilonidal disease. *Am J Surg* **200**, 318–327, <https://doi.org/10.1016/j.amjsurg.2009.08.042> (2010).
274. Karaca, T. *et al.* Comparison of short-term results of modified Karydakís flap and modified Limberg flap for pilonidal sinus surgery. *Int J Surg* **10**, 601–606, <https://doi.org/10.1016/j.ijssu.2012.10.001> (2012).
275. Rushfeldt, C., Bernstein, A., Norderval, S. & Revhaug, A. Introducing an asymmetric cleft lift technique as a uniform procedure for pilonidal sinus surgery. *Scand J Surg* **97**, 77–81 (2008).
276. Gurer, A. *et al.* Is routine cavity drainage necessary in Karydakís flap operation? A prospective, randomized trial. *Dis Colon Rectum* **48**, 1797–1799, <https://doi.org/10.1007/s10350-005-0108-7> (2005).
277. Keshava, A., Young, C. J., Rickard, M. J. & Sinclair, G. Karydakís flap repair for sacrococcygeal pilonidal sinus disease: how important is technique? *ANZ J Surg* **77**, 181–183, <https://doi.org/10.1111/j.1445-2197.2006.04003.x> (2007).
278. Nordon, I. M., Senapati, A. & Cripps, N. P. A prospective randomized controlled trial of simple Bascom's technique versus Bascom's cleft closure for the treatment of chronic pilonidal disease. *Am J Surg* **197**, 189–192, <https://doi.org/10.1016/j.amjsurg.2008.01.020> (2009).
279. Sozen, S., Emir, S., Guzel, K. & Ozdemir, C. S. Are postoperative drains necessary with the Karydakís flap for treatment of pilonidal sinus? (Can fibrin glue be replaced to drains?) A prospective randomized trial. *Ir J Med Sci* **180**, 479–482, <https://doi.org/10.1007/s11845-010-0549-4> (2011).
280. Al-Khayat, H. *et al.* Risk factors for wound complication in pilonidal sinus procedures. *J Am Coll Surg* **205**, 439–444, <https://doi.org/10.1016/j.jamcollsurg.2007.04.034> (2007).
281. Anderson, J. H., Yip, C. O., Nagabhushan, J. S. & Connelly, S. J. Day-case Karydakís flap for pilonidal sinus. *Dis Colon Rectum* **51**, 134–138, <https://doi.org/10.1007/s10350-007-9150-y> (2008).
282. Kulacoglu, H., Dener, C., Tumer, H. & Aktimur, R. Total subcutaneous fistulectomy combined with Karydakís flap for sacrococcygeal pilonidal disease with secondary perianal opening. *Colorectal Dis* **8**, 120–123, <https://doi.org/10.1111/j.1463-1318.2005.00872.x> (2006).
283. Senapati, A., Cripps, N. P., Flashman, K. & Thompson, M. R. Cleft Closure for the Treatment of Pilonidal Sinus Disease. *Colorectal Dis* (2009).
284. Tezel, E., Bostanci, H., Anadol, A. Z. & Kurukahvecioglu, O. Cleft lift procedure for sacrococcygeal pilonidal disease. *Dis Colon Rectum* **52**, 135–139, <https://doi.org/10.1007/DCR.0b013e31819734f8> (2009).
285. Theodoropoulos, G. E., Vlahos, K., Lazaris, A. C., Tahteris, E. & Panoussopoulos, D. Modified Bascom's asymmetric midgluteal cleft closure technique for recurrent pilonidal disease: early experience in a military hospital. *Dis Colon Rectum* **46**, 1286–1291, <https://doi.org/10.1097/01.DCR.0000084409.63183.5B> (2003).
286. Bertelsen, C. A. Cleft-lift operation for pilonidal sinuses under tumescent local anesthesia: a prospective cohort study of peri- and postoperative pain. *Dis Colon Rectum* **54**, 895–900, <https://doi.org/10.1007/DCR.0b013e31820ee852> (2011).
287. Buczaccki, S., Drage, M., Wells, A. & Guy, R. Sacrococcygeal pilonidal sinus disease. *Colorectal Dis* **11**, 657, <https://doi.org/10.1111/j.1463-1318.2009.01818.x> (2009).
288. Cripps, N., Evans, J., Nordon, I. & Senapati, A. Sacrococcygeal pilonidal sinus disease. *Colorectal Dis* **11**, 105–106 (2008).
289. Demircan, F. *et al.* The effect of laser epilation on recurrence and satisfaction in patients with sacrococcygeal pilonidal disease: a prospective randomized controlled trial. *Int J Clin Exp Med* **8**, 2929–2933 (2015).
290. Kanat, B. H. *et al.* Comparison of early surgery (unroofing-curettage) and elective surgery (Karydakís flap technique) in pilonidal sinus abscess cases. *Ulus Travma Acil Cerrahi Derg* **20**, 366–370, <https://doi.org/10.5505/tjtes.2014.62547> (2014).
291. Bali, I. *et al.* Effectiveness of Limberg and Karydakís flap in recurrent pilonidal sinus disease. *Clinics (Sao Paulo)* **70**, 350–355, [https://doi.org/10.6061/clinics/2015\(05\)08](https://doi.org/10.6061/clinics/2015(05)08) (2015).
292. Ersoy, E. *et al.* Comparison of the short-term results after Limberg and Karydakís procedures for pilonidal disease: randomized prospective analysis of 100 patients. *Colorectal Dis* **11**, 705–710, <https://doi.org/10.1111/j.1463-1318.2008.01646.x> (2009).
293. Khan, M. I., Jawed, M., Bhura, S., Shaikh, U. & Arif, A. To evaluate the outcome of sacrococcygeal pilonidal sinus excision using karydakís technique. *Med. Forum Monthly* **25**, 57–59 (2014).
294. Ortega, P. M. *et al.* Is the cleft lift procedure for non-acute sacrococcygeal pilonidal disease a definitive treatment? Long-term outcomes in 74 patients. *Surg Today* **44**, 2318–2323, <https://doi.org/10.1007/s00595-014-0923-3> (2014).
295. Sit, M., Aktas, G. & Yilmaz, E. E. Comparison of the three surgical flap techniques in pilonidal sinus surgery. *Am Surg* **79**, 1263–1268 (2013).
296. Guner, A., Ozkan, O. F., Kece, C., Kesici, S. & Kucuktulu, U. Modification of the Bascom cleft lift procedure for chronic pilonidal sinus: results in 141 patients. *Colorectal Dis* **15**, e402–406, <https://doi.org/10.1111/codi.12243> (2013).
297. Iribarren, B. O., Barra, M. M., Lanzelotti, G. D., Rojas, G. M. & Peña, A. E. Comparison between Limberg and Karydakís flap for wound closure after pilonidal cyst resection. *Rev. Chil. Cir.* **67**, 399–406, <https://doi.org/10.4067/S0718-40262015000400009> (2015).
298. Iesalnieks, I., Deimel, S., Zulle, C. & Schlitt, H. J. Smoking increases the risk of pre- and postoperative complications in patients with pilonidal disease. *J Dtsch Dermatol Ges* **11**, 1001–1005, <https://doi.org/10.1111/ddg.12140> (2013).
299. Patel, L. B. & Allen, M. Prolonged delay in healing after surgical treatment of pilonidal sinus is avoidable. *Colorectal Dis* **1**, 107–110, <https://doi.org/10.1046/j.1463-1318.1999.00030.x> (1999).
300. Sahin, A., Olcucuoglu, E., Seker, D. & Kulacoglu, H. The effect of using methylene blue in surgical treatments of pilonidal disease: a prospective randomized study. *European Surgery* **46**, 148–154, <https://doi.org/10.1007/s10353-014-0276-6> (2014).
301. Kumar, N. A. & Sutradhar, P. Karydakís procedure for sacrococcygeal pilonidal sinus disease: Our experience. *Indian J Plast Surg* **47**, 402–406, <https://doi.org/10.4103/0970-0358.146615> (2014).
302. Mohamed, S. J., Kristensen, B. B., Lindgaard, L. & Bisgaard, T. Acceptable effect of multimodal analgesic treatment after a Bascom cleft lift operation. *Dan Med J* **62**, A4985 (2015).
303. Melkonian, T. E. *et al.* Short- and long-term results with Karydakís technique for sacrococcygeal pilonidal disease [Resultados a corto y largo plazo con la técnica de Karydakís para la enfermedad pilonidal sacrocóxigea]. *Rev. Chil. Cir.* **65**, 25–29 (2013).
304. Abdelrazeq, A. S., Rahman, M., Botterill, I. D. & Alexander, D. J. Short-term and long-term outcomes of the cleft lift procedure in the management of nonacute pilonidal disorders. *Dis Colon Rectum* **51**, 1100–1106, <https://doi.org/10.1007/s10350-008-9262-z> (2008).
305. Bostanoglu, S., Sakcak, I., Avsar, F. M., Cosgun, E. & Hamamci, E. O. Comparison of Karydakís technique with Limberg Flap Procedure in Pilonidal Sinus Disease: Advantages of Karydakís technique. *Pak. J. Med. Sci.* **26**, 773–777 (2010).
306. Piskin, T. *et al.* Orifice location guided excision and flap procedures for treatment of sacrococcygeal pilonidal disease. *Adv. Clin. Exp. Med.* **20**, 481–488 (2011).
307. Sozen, S. *et al.* Comparison between Karydakís flap repair and Limberg flap for surgical treatment of sacrococcygeal pilonidal sinus (short term results). *Turk. J. Surg.* **26**, 153–156, <https://doi.org/10.5097/1300-0705.UCD.609-10.01> (2010).

308. Tokaç, M., Dumlu, E. G., Aydin, M. S., Yalcin, A. & Kilic, M. Comparison of modified limberg flap and karydakias flap operations in pilonidal sinus surgery: prospective randomized study. *Int Surg* **100**, 870–877, <https://doi.org/10.9738/INTSURG-D-14-00213.1> (2015).
309. Guner, A., Cekic, A. B., Boz, A., Turkyilmaz, S. & Kucuktu, U. A proposed staging system for chronic symptomatic pilonidal sinus disease and results in patients treated with stage-based approach. *BMC Surg* **16**, 18, <https://doi.org/10.1186/s12893-016-0134-5> (2016).
310. Bannura, C., Barrera, E., Contreras, P., Melo, L. & Soto, C. Ambulatory karydakias procedure for sacrococcygeal pilonidal disease. *Rev. Chil. Cir.* **61**, 256–260 (2009).
311. Larsson, J. C., Aliaga, F. D., Granero, L. & Cornet, M. Tratamiento de la Enfermedad Pilonidal Crónica. Comparación de 3 Técnicas Quirúrgicas. *Rev Argent Coloproct* **25**, 64–70 (2014).
312. Guillermo Bannura, C. Sacrococcygeal pilonidal disease. risks factors and surgical options [Enfermedad pilonidal sacro-coccígea: Factores de riesgo y tratamiento quirúrgico]. *Rev. Chil. Cir.* **63**, 527–533 (2011).
313. Ochoa, E. M., Esquivel, C. M., Badra, R. & Cornet, M. Sacrococcygeal pilonidal disease: results of karydakias flap vs. limberg flap. *Prensa Med. Argent.* **96**, 31–37 (2009).
314. Ramzan, M., Khalid Mirza, M. & Arif Ali, M. Pilonidal Sinus; Experience with Modified Karydakias Procedure Using Subcuticular Skin Closure. *The Professional Medical Journal* **23**, 1499–1504, <https://doi.org/10.17957/tpmj/16.3602> (2016).
315. Keshvari, A., Keramati, M. R., Fazeli, M. S., Kazemini, A. & Nouritaromlou, M. K. Risk factors for complications and recurrence after the Karydakias flap. *J Surg Res* **204**, 55–60, <https://doi.org/10.1016/j.jss.2016.04.035> (2016).
316. Bannura, G. Karydakias operation for sacrococcygeal pilonidal sinus disease. *Rev Chil Cir* **57**, 340–344 (2005).
317. Cubukcu, A. *et al.* The role of obesity on the recurrence of pilonidal sinus disease in patients, who were treated by excision and Limberg flap transposition. *Int J Colorectal Dis* **15**, 173–175 (2000).
318. Arumugam, P. J., Chandrasekaran, T. V., Morgan, A. R., Beynon, J. & Carr, N. D. The rhomboid flap for pilonidal disease. *Colorectal Dis* **5**, 218–221 (2003).
319. Mentas, B. B. *et al.* Modified Limberg transposition flap for sacrococcygeal pilonidal sinus. *Surg Today* **34**, 419–423, <https://doi.org/10.1007/s00595-003-2725-x> (2004).
320. Hegele, A., Strombach, F. J. & Schonbach, F. [Reconstructive surgical therapy of infected pilonidal sinus]. *Chirurg* **74**, 749–752, <https://doi.org/10.1007/s00104-003-0657-z> (2003).
321. Kaya, B. *et al.* Modified Limberg transposition flap in the treatment of pilonidal sinus disease. *Tech Coloproctol* **16**, 55–59, <https://doi.org/10.1007/s10151-011-0799-9> (2012).
322. Yildar, M. & Cavdar, F. Comparison of the Limberg flap and bilateral gluteus maximus advancing flap following oblique excision for the treatment of pilonidal sinus disease. *Surg Today* **44**, 1828–1833, <https://doi.org/10.1007/s00595-013-0764-5> (2014).
323. Kapan, M., Kapan, S., Pekmezci, S. & Durgun, V. Sacrococcygeal pilonidal sinus disease with Limberg flap repair. *Tech Coloproctol* **6**, 27–32, <https://doi.org/10.1007/s101510200005> (2002).
324. Müller, K. *et al.* Prospective analysis of cosmesis, morbidity, and patient satisfaction following Limberg flap for the treatment of sacrococcygeal pilonidal sinus. *Dis Colon Rectum* **54**, 487–494 (2011).
325. Jimenez Romero, C., Alcalde, M., Martin, F., Pulido, A. & Rico, P. Treatment of pilonidal sinus by excision and rhomboid flap. *Int J Colorectal Dis* **5**, 200–202 (1990).
326. El-Khadrawy, O., Hashish, M., Ismail, K. & Shalaby, H. Outcome of the rhomboid flap for recurrent pilonidal disease. *World J Surg* **33**, 1064–1068, <https://doi.org/10.1007/s00268-009-9920-x> (2009).
327. Akin, M. *et al.* Comparison of the classic Limberg flap and modified Limberg flap in the treatment of pilonidal sinus disease: a retrospective analysis of 416 patients. *Surg Today* **40**, 757–762, <https://doi.org/10.1007/s00595-008-4098-7> (2010).
328. Milito, G. *et al.* Modified Limberg's transposition flap for pilonidal sinus. Long term follow up of 216 cases. *Ann Ital Chir* **78**, 227–231 (2007).
329. Daphan, C., Tekelioglu, M. H. & Sayilgan, C. Limberg flap repair for pilonidal sinus disease. *Dis Colon Rectum* **47**, 233–237 (2004).
330. Eryilmaz, R., Sahin, M., Alimoglu, O. & Dasiran, F. Surgical treatment of sacrococcygeal pilonidal sinus with the Limberg transposition flap. *Surgery* **134**, 745–749, [https://doi.org/10.1016/s0039-6060\(03\)00163-6](https://doi.org/10.1016/s0039-6060(03)00163-6) (2003).
331. Gwynn, B. R. Use of the rhomboid flap in pilonidal sinus. *Ann R Coll Surg Engl* **68**, 40–41 (1986).
332. Karakayali, F. *et al.* Unroofing and marsupialization vs. rhomboid excision and Limberg flap in pilonidal disease: a prospective, randomized, clinical trial. *Dis Colon Rectum* **52**, 496–502, <https://doi.org/10.1007/DCR.0b013e31819a3ec0> (2009).
333. Lahooti, M., Taheri, P. A., Nezami, B. G. & Assa, S. Sacrococcygeal pilonidal sinus treated by a new fascio-cutaneous flap. *Dis Colon Rectum* **51**, 588–592, <https://doi.org/10.1007/s10350-008-9211-x> (2008).
334. Lieto, E. *et al.* Dufourmentel rhomboid flap in the radical treatment of primary and recurrent sacrococcygeal pilonidal disease. *Dis Colon Rectum* **53**, 1061–1068, <https://doi.org/10.1007/DCR.0b013e3181def25> (2010).
335. Aithal, S. K., Rajan, C. S. & Reddy, N. Limberg flap for sacrococcygeal pilonidal sinus a safe and sound procedure. *Indian J Surg* **75**, 298–301, <https://doi.org/10.1007/s12262-012-0489-5> (2013).
336. Milito, G., Cortese, F. & Casciani, C. U. Rhomboid flap procedure for pilonidal sinus: results from 67 cases. *Int J Colorectal Dis* **13**, 113–115 (1998).
337. Aslam, M. N., Shoaib, S. & Choudhry, A. M. Use of Limberg flap for pilonidal sinus - a viable option. *J Ayub Med Coll Abbottabad* **21**, 31–33 (2009).
338. Topgul, K., Ozdemir, E., Kilic, K., Gokbayir, H. & Ferahkose, Z. Long-term results of limberg flap procedure for treatment of pilonidal sinus: a report of 200 cases. *Dis Colon Rectum* **46**, 1545–1548, <https://doi.org/10.1097/01.DCR.0000089114.56612.06> (2003).
339. Urhan, M. K., Kucukel, F., Topgul, K., Ozer, I. & Sari, S. Rhomboid excision and Limberg flap for managing pilonidal sinus: results of 102 cases. *Dis Colon Rectum* **45**, 656–659 (2002).
340. Kirkil, C. *et al.* The effects of drainage on the rates of early wound complications and recurrences after Limberg flap reconstruction in patients with pilonidal disease. *Tech Coloproctol* **15**, 425–429, <https://doi.org/10.1007/s10151-011-0782-5> (2011).
341. Darwish, A. M. & Hassanin, A. Reconstruction following excision of sacrococcygeal pilonidal sinus with a perforator-based fasciocutaneous Limberg flap. *J Plast Reconstr Aesthet Surg* **63**, 1176–1180, <https://doi.org/10.1016/j.bjps.2009.05.051> (2010).
342. Altintoprak, F. *et al.* Retrospective review of pilonidal sinus patients with early discharge after Limberg flap procedure. *Int Surg* **99**, 28–34, <https://doi.org/10.9738/INTSURG-D-13-00150.1> (2014).
343. Omer, Y., Hayrettin, D., Murat, C., Mustafa, Y. & Evren, D. Comparison of modified limberg flap and modified elliptical rotation flap for pilonidal sinus surgery: a retrospective cohort study. *Int J Surg* **16**, 74–77, <https://doi.org/10.1016/j.ijsu.2015.02.024> (2015).
344. Yoldas, T. *et al.* Recurrent pilonidal sinus: lay open or flap closure, does it differ? *Int Surg* **98**, 319–323, <https://doi.org/10.9738/INTSURG-D-13-00081.1> (2013).
345. Katsoulis, I. E., Hibberts, F. & Carapeti, E. A. Outcome of treatment of primary and recurrent pilonidal sinuses with the Limberg flap. *Surgeon* **4**(7–10), 62 (2006).
346. Erdem, E., Sungurtekin, U. & Nessar, M. Are postoperative drains necessary with the Limberg flap for treatment of pilonidal sinus? *Dis Colon Rectum* **41**, 1427–1431 (1998).
347. Tekin, A. Pilonidal sinus: experience with the Limberg flap. *Colorectal Dis* **1**, 29–33, <https://doi.org/10.1046/j.1463-1318.1999.00007.x> (1999).

348. Akin, M. *et al.* Rhomboid excision and Limberg flap for managing pilonidal sinus: long-term results in 411 patients. *Colorectal Dis* **10**, 945–948, <https://doi.org/10.1111/j.1463-1318.2008.01563.x> (2008).
349. Sabuncuoglu, M. Z. *et al.* Eyedrop-shaped, modified Limberg transposition flap in the treatment of pilonidal sinus disease. *Asian J Surg* **38**, 161–167, <https://doi.org/10.1016/j.asjsur.2015.03.007> (2015).
350. Afsarlar, C. E. *et al.* Treatment of adolescent pilonidal disease with a new modification to the Limberg flap: symmetrically rotated rhomboid excision and lateralization of the Limberg flap technique. *J Pediatr Surg* **48**, 1744–1749, <https://doi.org/10.1016/j.jpedsurg.2013.01.029> (2013).
351. Yamout, S. Z. *et al.* Early experience with the use of rhomboid excision and Limberg flap in 16 adolescents with pilonidal disease. *J Pediatr Surg* **44**, 1586–1590, <https://doi.org/10.1016/j.jpedsurg.2008.11.033> (2009).
352. Altinli, E., Koksall, N., Onur, E., Celik, A. & Sumer, A. Impact of fibrin sealant on Limberg flap technique: results of a randomized controlled trial. *Tech Coloproctol* **11**, 22–25, <https://doi.org/10.1007/s10151-007-0320-7> (2007).
353. Bozkurt, M. K. & Tezel, E. Management of pilonidal sinus with the Limberg flap. *Dis Colon Rectum* **41**, 775–777 (1998).
354. Colak, T., Turkmenoglu, O., Dag, A., Akca, T. & Aydin, S. A randomized clinical study evaluating the need for drainage after Limberg flap for pilonidal sinus. *J Surg Res* **158**, 127–131, <https://doi.org/10.1016/j.jss.2008.11.005> (2010).
355. Cihan, A. *et al.* Superiority of asymmetric modified Limberg flap for surgical treatment of pilonidal disease. *Dis Colon Rectum* **49**, 244–249, <https://doi.org/10.1007/s10350-005-0253-z> (2006).
356. Manterola, C., Barroso, M., Araya, J. C. & Fonseca, L. Pilonidal disease: 25 cases treated by the Dufourmentel technique. *Dis Colon Rectum* **34**, 649–652 (1991).
357. Ardelt, M. *et al.* Sequential intervention with primary excision and Limberg plastic surgery procedure for treatment of sacrococcygeal pilonidal sinus: Results of a pilot study. *Chirurg* **86**, 771–775, <https://doi.org/10.1007/s00104-014-2963-z> (2015).
358. Faux, W., Pillai, S. C. & Gold, D. M. Limberg flap for pilonidal disease: the “no-protractor” approach, 3 steps to success. *Tech Coloproctol* **9**, 153–155, <https://doi.org/10.1007/s10151-005-0216-3> (2005).
359. Karakas, B. R. *et al.* Is the lateralization distance important in terms in patients undergoing the modified Limberg flap procedure for treatment of pilonidal sinus? *Tech Coloproctol* (2014).
360. El-Tawil, S. & Carapeti, E. Use of a double rhomboid transposition flap in the treatment of extensive complex pilonidal sinus disease. *Colorectal Dis* **11**, 313–317, <https://doi.org/10.1111/j.1463-1318.2008.01596.x> (2009).
361. Sharma, P. P. Multiple Z-plasty in pilonidal sinus—a new technique under local anesthesia. *World J Surg* **30**, 2261–2265, <https://doi.org/10.1007/s00268-005-0632-6> (2006).
362. Unalp, H. R., Derici, H., Kamer, E., Nazli, O. & Onal, M. A. Lower recurrence rate for Limberg vs. V-Y flap for pilonidal sinus. *Dis Colon Rectum* **50**, 1436–1444, <https://doi.org/10.1007/s10350-007-0276-8> (2007).
363. Akan, K. *et al.* Comparison of surgical Limberg flap technique and crystallized phenol application in the treatment of pilonidal sinus disease: a retrospective study. *Ulus Cerrahi Derg* **29**, 162–166, <https://doi.org/10.5152/UCD.2013.2457> (2013).
364. Yabanoglu, H., Karagulle, E., Belli, S. & Turk, E. Results of modified Dufourmentel rhomboid flap in patients with extensive Sacrococcygeal pilonidal disease. *Acta Chir Belg* **114**, 52–57 (2014).
365. Azizi, R., Alemrajabi, M., Naderan, M. & Shoar, S. Efficacy of modified Limberg flap in surgical treatment of infected pilonidal abscess: a case–control study. *European Surgery* **46**, 144–147, <https://doi.org/10.1007/s10353-014-0273-9> (2014).
366. Jonas, J., Blaich, S. & Bahr, R. Surgery of pilonidal sinus using the Limberg flap. *Zentralbl Chir* **125**, 976–981, <https://doi.org/10.1055/s-2000-10076> (2000).
367. Kicka, M., Toporcer, T. & Radonak, J. Pilonidal sinus—a classical plastic procedure according to Limberg (Limberg flap procedure) or its modified version? *Rozhl Chir* **90**, 482–487 (2011).
368. Karakas, B. R. Comparison of Z-plasty, limberg flap, and asymmetric modified Limberg flap techniques for the pilonidal sinus treatment: review of literature. *Acta Chir Iugosl* **60**, 31–37 (2013).
369. Saydam, M. *et al.* Comparison of modified Limberg flap transposition and lateral advancement flap transposition with Burow’s triangle in the treatment of pilonidal sinus disease. *Am J Surg* **210**, 772–777, <https://doi.org/10.1016/j.amjsurg.2015.03.031> (2015).
370. Misiakos, E. P. *et al.* Limberg flap reconstruction for the treatment of pilonidal sinus disease. *Chirurgia (Bucur)* **101**, 513–517 (2006).
371. Karaca, A. S., Ali, R., Capar, M. & Karaca, S. Comparison of Limberg flap and excision and primary closure of pilonidal sinus disease, in terms of quality of life and complications. *J Korean Surg Soc* **85**, 236–239, <https://doi.org/10.4174/jkss.2013.85.5.236> (2013).
372. Yildar, M., Cavdar, F. & Yildiz, M. K. The evaluation of a modified Dufourmentel flap after S-type excision for pilonidal sinus disease. *Scientific World Journal* **2013**, 459147, <https://doi.org/10.1155/2013/459147> (2013).
373. Sungurtekin, H., Sungurtekin, U. & Erdem, E. Local anesthesia and midazolam versus spinal anesthesia in ambulatory pilonidal surgery. *J Clin Anesth* **15**, 201–205 (2003).
374. Roth, R. F. & Moorman, W. L. Treatment of pilonidal sinus and cyst by conservative excision and W-plasty closure. *Plast Reconstr Surg* **60**, 412–415 (1977).
375. Altintoprak, F. *et al.* Comparison of the Limberg flap with the V-Y flap technique in the treatment of pilonidal disease. *J Korean Surg Soc* **85**, 63–67, <https://doi.org/10.4174/jkss.2013.85.2.63> (2013).
376. Dogra, S. & Rao, P. P. Z-Plasty a Rational and Effective Technique for Pilonidal Sinus. *Hellenic Journal of Surgery* **86**, 208–211 (2014).
377. Rabbani, S. *et al.* Rhomboid excision with limberg transposition flap in the management of sacrococcygeal pilonidal sinus - a reliable surgical technique. *Pakistan J of Medical and Health Sci* **8** (2014).
378. Madbouly, K. M. Day-case Limberg flap for recurrent pilonidal sinus: does obesity complicate the issue? *Am Surg* **76**, 995–999 (2010).
379. Öz, B. *et al.* A comparison of surgical outcome of fasciocutaneous V-Y advancement flap and Limberg transposition flap for recurrent sacrococcygeal pilonidal sinus disease. *Asian J Surg* **6**, <https://doi.org/10.1016/j.asjsur.2015.10.002> (2015).
380. Rao, J., Deora, H. & Mandia, R. A Retrospective Study of 40 Cases of Pilonidal Sinus with Excision of Tract and Z-plasty as Treatment of Choice for Both Primary and Recurrent Cases. *Indian J Surg* **77**, 691–693, <https://doi.org/10.1007/s12262-013-0983-4> (2013).
381. Moosavi, S. R., Kharazm, P. & Vaghardoost, R. Surgical treatment of pilonidal sinus with a fasciocutaneous rotation flap based on an inferior pedicle. *Scand J Plast Reconstr Surg Hand Surg* **40**, 281–283, <https://doi.org/10.1080/02844310600869811> (2006).
382. Das, K. *et al.* Diathermy versus scalpel in Limberg flap in pilonidal sinus surgery. A prospective randomized trial. *Ann Ital Chir* **85**, 148–152 (2014).
383. Fahim, M. *et al.* Limberg FLAP Reconstruction for Pilonidal Sinus Disease: An Experience. *Ann Pak Inst Med Sci* **9**, 215–218 (2013).
384. Shabir, F., Khan, B. A. & Mian, M. A. Rhomboid excision with Limberg flap a novel treatment for sacrococcygeal pilonidal sinus. *Pak. J. Med. Health Sci.* **8**, 687–690 (2014).
385. Bayhan, Z. *et al.* Crystallized phenol application and modified Limberg flap procedure in treatment of pilonidal sinus disease: A comparative retrospective study. *Asian J Surg* **39**, 172–177, <https://doi.org/10.1016/j.asjsur.2015.12.007> (2016).
386. Al-Haifi, M. B. *et al.* Rhomboid flap - A primary cure for pilonidal sinus. *Kuwait Med. J.* **42**, 282–285 (2010).
387. Tardu, A., Haşlak, A., Özçinar, B. & Başak, F. Comparison of Limberg and Dufourmentel flap in surgical treatment of pilonidal sinus disease. *Turk. J. Surg.* **27**, 35–40, <https://doi.org/10.5097/1300-0705.UCD.659-11.04>

388. Sellés, R. *et al.* Complete excision and marsupialization of chronic pilonidal sacrococcygeal sinus: The ideal technique? *Cir. Esp.* **72**, 92–94, [https://doi.org/10.1016/S0009-739X\(02\)72016-2](https://doi.org/10.1016/S0009-739X(02)72016-2) (2002).
389. Tschudi, J. & Ris, H. B. Morbidity of Z-plasty in the treatment of pilonidal sinus. *Chirurg* **59**, 486–490 (1988).
390. Abu Galala, K. H., Salam, I. M. A., El Ashaal, Y. I., Chandran, V. P. & Sim, A. J. W. Excision of pilonidal sinus and primary closure by a rhomboid flap transposition. *Asian J. Surg.* **19**, 305–308 (1996).
391. Ferreira Montero, V., Garcia Fabian, A. P., Martinez Laganga, A. & Perez Ruiz, L. Rhombic plastia in the form of an 'L' for treating pilonidal cysts [La plastia en "L" de Rombo para el tratamiento de los Quistes Pilonidales]. *Cir. Esp.* **31**, 153–158 (1977).
392. Kushwaha, R., El-Tawil, S., Hibberts, F., Katsoulis, I. E. & Carapeti, E. Treatment of complex primary and recurrent pilonidal sinus with a Rhomboid Transposition Flap. *Br J Surg* **93**, 1–104 (2006).
393. Behdad, A. & Hosseinpoor, M. Z-plasty for the treatment of residual cavity after pilonidal sinus excision. *Medical Journal of the Islamic Republic of Iran* **14**, 317–319 (2001).
394. Lauterbach, H. H. & Konrad, U. Zweiphasenkonzept zur Therapie des infizierten Sinus pilonidalis. *Chir Praxis* **55**, 623–628 (1999).
395. Mutaf, M., Temel, M. & Koc, M. N. A New Surgical Technique for Closure of Pilonidal Sinus Defects: Triangular Closure Technique. *Med Sci Monit* **23**, 1033–1042 (2017).
396. Raza, M. W. *et al.* Limberg flap for pilonidal sinus. *J Rawal Med coll* **16**, 132–134 (2012).
397. Khanna, A. K. & Tiwary, S. K. Pilonidal sinus disease with especial reference to Limberg flap. *Apollo Medicine* **12**, 163–169, <https://doi.org/10.1016/j.apme.2015.07.013> (2015).
398. Mentés, O., Bagci, M., Bilgin, T., Ozgul, O. & Ozdemir, M. Limberg flap procedure for pilonidal sinus disease: results of 353 patients. *Langenbecks Arch Surg* **393**, 185–189, <https://doi.org/10.1007/s00423-007-0227-9> (2008).
399. Oncel, M. *et al.* Excision and marsupialization versus sinus excision for the treatment of limited chronic pilonidal disease: a prospective, randomized trial. *Tech Coloproctol* **6**, 165–169, <https://doi.org/10.1007/s101510200037> (2002).
400. Abramson, D. J. An open, semiprimary closure operation for pilonidal sinuses, using local anesthesia. *Dis Colon Rectum* **13**, 215–219 (1970).
401. Abramson, D. J. & Cox, P. A. The marsupialization operation for pilonidal cysts and sinuses under local anesthesia with lidocaine; an ambulatory method of treatment. *Ann Surg* **139**, 341–349 (1954).
402. Aldemir, M., Kara, I. H., Erten, G. & Tacyildiz, I. Effectiveness of collagenase in the treatment of sacrococcygeal pilonidal sinus disease. *Surg Today* **33**, 106–109, <https://doi.org/10.1007/s005950300022> (2003).
403. Ozbalci, G. S., Tuncal, S., Bayraktar, K., Tasova, V. & Ali Akkus, M. Is gentamicin-impregnated collagen sponge to be recommended in pilonidal sinus patient treated with marsupialization? A prospective randomized study. *Ann Ital Chir* **85**, 576–582 (2014).
404. Zimmerman, C. E. Outpatient excision and primary closure of pilonidal cysts and sinuses. Long-term follow-up. *Am J Surg* **148**, 658–659 (1984).
405. Brockbank, M. J. Pilonidal Cyst. *Am J Surg* **68**, 4 (1945).
406. Licheri, S. *et al.* Radical treatment of acute pilonidal abscess by marsupialization. *G Chir* **25**, 414–416 (2004).
407. Gonzalo Inostroza, L. *et al.* Pilonidal cyst abscess: Definitive treatment in a single time during the acute, short-term results [Quiste pilonidal abscedado: Tratamiento definitivo en un solo tiempo durante el episodio agudo, resultados a corto plazo]. *Rev. Chil. Cir.* **63**, 54–58 (2011).
408. Perez Oberreuter, G. *et al.* Técnica de marsupialización en quiste pilonidal: 7 años de experiencia. *Rev. Chil. Cir.* **50** (1998).
409. Duchateau, J., De Mol, J., Bostoën, H. & Allegaert, W. Pilonidal sinus. Excision–marsupialization–phenolization? *Acta Chir Belg* **85**, 325–328 (1985).
410. Abramson, D. J. Excision and delayed closure of pilonidal sinuses. *Surg Gynecol Obstet* **144**, 205–207 (1977).
411. Abramson, D. J. Outpatient management of pilonidal sinuses: excision and semiprimary closure technic. *Mil Med* **143**, 753–757 (1978).
412. Struijk, D. G., Krediet, R. T., de Glas-Vos, J. W., Boeschoten, E. W. & Arisz, L. Experiences with acute peritoneal dialysis in adults. *Ned Tijdschr Geneesk* **128**, 751–755 (1984).
413. Sahsamanis, G. *et al.* Semi-closed surgical technique for treatment of pilonidal sinus disease. *Ann Med Surg (Lond)* **15**, 47–51, <https://doi.org/10.1016/j.amsu.2017.02.004> (2017).
414. Arauz, S., Yamaguchi, N., Schmidt Goffi, F. & Zanoto, A. Tratamento cirúrgico da doença pilonidal sacrococígea: estudo comparativo entre as técnicas de marsupialização e de incisão e curetagem [Surgical treatment of sacrococcygeal pilonidal disease: a comparative study between marsupialization and incision plus curettage techniques]. *Rev Col Bras Cir* **29**, 659–662 (2002).
415. Yildirim, D., Sunamak, O., Pergel, A. & Mounla, M. Combined single step definitive treatment in acute pilonidal sinus abscess. *Surg Sci* **1**, 24–26 (2010).
416. Cavanagh, C. R. & Schnug, G. E. Definitive Treatment of the Pilonidal Abscess. *Northwest Med* **63**, 449–451 (1964).
417. Olmez, A., Kayaalp, C. & Aydin, C. Treatment of pilonidal disease by combination of pit excision and phenol application. *Tech Coloproctol* **17**, 201–206, <https://doi.org/10.1007/s10151-012-0903-9> (2013).
418. Al-Naami, M. Y. Outpatient pilonidal sinotomy complemented with good wound and surrounding skin care. *Saudi Med J* **26**, 285–288 (2005).
419. Gupta, P. J. Radiofrequency incision and lay open technique of pilonidal sinus (clinical practice paper on modified technique). *Kobe J Med Sci* **49**, 75–82 (2003).
420. Kepenekci, I., Demirkan, A., Celasin, H. & Gecim, I. E. Unroofing and curettage for the treatment of acute and chronic pilonidal disease. *World J Surg* **34**, 153–157, <https://doi.org/10.1007/s00268-009-0245-6> (2010).
421. Al Homoud, S. J., Habib, Z. S., Abdul Jabbar, A. S. & Isbister, W. H. Management of sacrococcygeal pilonidal disease. *Saudi. Med. J.* **22**, 762–764 (2001).
422. Elsey, E. & Lund, J. N. Fibrin glue in the treatment for pilonidal sinus: high patient satisfaction and rapid return to normal activities. *Tech Coloproctol* **17**, 101–104, <https://doi.org/10.1007/s10151-012-0956-9> (2013).
423. Gidwani, A. L., Murugan, K., Nasir, A. & Brown, R. Incise and lay open: an effective procedure for coccygeal pilonidal sinus disease. *Ir J Med Sci* **179**, 207–210, <https://doi.org/10.1007/s11845-009-0450-1> (2010).
424. Oram, Y., Kahraman, F., Karincaoglu, Y. & Koyuncu, E. Evaluation of 60 patients with pilonidal sinus treated with laser epilation after surgery. *Dermatol Surg* **36**, 88–91, <https://doi.org/10.1111/j.1524-4725.2009.01387.x> (2010).
425. Klin, B., Heller, O. N. & Kaplan, I. The use of the CO₂ laser in pilonidal sinus disease: preliminary results of an ambulatory prospective study. *J Clin Laser Med Surg* **8**, 31–37 (1990).
426. Jensen, S. L. & Harling, H. Prognosis after simple incision and drainage for a first-episode acute pilonidal abscess. *Br J Surg* **75**, 60–61 (1988).
427. Garg, P., Garg, M., Gupta, V., Mehta, S. K. & Lakhtaria, P. Laying open (deroofing) and curettage under local anesthesia for pilonidal disease: An outpatient procedure. *World J Gastrointest Surg.* **7**, 214–218, <https://doi.org/10.4240/wjgs.v7.i9.214> (2015).
428. Yalcin, S. & Ergul, E. A single-surgeon, single-institute experience of 59 sinotomies for sacrococcygeal pilonidal disease under local anesthesia. *Bratisl Lek Listy* **111**, 284–285 (2010).
429. Sozen, S., Ozturk, V. & Das, V. Day–Care Surgery for Pilonidal Sinus Using Sinotomy Technique and Fibrin Glue Injection. *Arch Clin Exp Surg* **1**, 138–141 (2012).
430. Qayyum, I., Bai, D. & Tsoraides, S. S. Loop drainage after debridement (LDAD): minimally invasive treatment for pilonidal cyst. *Tech Coloproctol* **20**, 591–594, <https://doi.org/10.1007/s10151-016-1469-8> (2016).
431. Isbister, W. H. & Prasad, J. Pilonidal disease. *Aust N Z J Surg* **65**, 561–563 (1995).

432. Mikkelsen, K. Pilonidal sinus. A follow-up study of out-patients treated by simple incision. *Ugeskr Laeger* **137**, 789–791 (1975).
433. Shirah, B. & Shirah, H. The Effect of Hydrogen Peroxide on the Healing of the Laid Open Wound in the Treatment of Chronic Sacrococcygeal Pilonidal Sinus: A Retrospective Database Analysis of 500 Patients. *International Journal of Surgery and Medicine* **2**, 17, <https://doi.org/10.5455/ijsm.woundhealing> (2016).
434. Malik, G. A., Choudary, T. H. & Wahab, A. Pilonidal Sinus; Prevalence and comparison of excision and primary closure with lay open procedure. *Professional Med J* **16**, 297–298 (2009).
435. Goswitz, J. T. Sacrococcygeal Pilonidal Sinus Disease. Treatment and Long-Term Follow-up in a Military Hospital Serving Combat-Ready Units. *Arch Surg* **90**, 890–892 (1965).
436. Gillquist, J. Prevention of the recurrence of so-called sacral dermoid. *Nord Med* **74**, 1315 (1965).
437. Senapati, A., Cripps, N. P. & Thompson, M. R. Bascom's operation in the day-surgical management of symptomatic pilonidal sinus. *Br J Surg* **87**, 1067–1070, <https://doi.org/10.1046/j.1365-2168.2000.01472.x> (2000).
438. Gips, M., Melki, Y., Salem, L., Weil, R. & Sulkes, J. Minimal surgery for pilonidal disease using trephines: description of a new technique and long-term outcomes in 1,358 patients. *Dis Colon Rectum* **51**, 1656–1662; discussion 1662–1653, <https://doi.org/10.1007/s10350-008-9329-x> (2008).
439. Zorcolo, L., Capra, F., Scintu, F. & Casula, G. Surgical treatment of pilonidal disease. Results with the Bascom's technique. *Minerva Chir* **59**, 387–395 (2004).
440. Edwards, M. H. Pilonidal sinus: a 5-year appraisal of the Millar-Lord treatment. *Br J Surg* **64**, 867–868 (1977).
441. Iesalnieks, I., Deimel, S., Kienle, K., Schlitt, H. J. & Zülke, C. Pit-picking surgery for pilonidal disease. *Chirurg* **82**, 927–931, <https://doi.org/10.1007/s00104-011-2077-9> (2011).
442. Colov, E. P. & Bertelsen, C. A. Short convalescence and minimal pain after out-patient Bascom's pit-pick operation. *Danish medical bulletin* **58**, A4348 (2011).
443. Mosquera, D. A. & Quayle, J. B. Bascom's operation for pilonidal sinus. *JR Soc Med* **88**, 45P–46P (1995).
444. Neola, B., Capasso, S., Caruso, L., Falato, A. & Ferulano, G. P. Scarless outpatient ablation of pilonidal sinus: a pilot study of a new minimally invasive treatment. *Int Wound J*, <https://doi.org/10.1111/iwj.12350> (2014).
445. Majeski, J. & Stroud, J. Sacrococcygeal pilonidal disease. *Int Surg* **96**, 144–147 (2011).
446. Lund, J. N. & Leveson, S. H. Fibrin glue in the treatment of pilonidal sinus: results of a pilot study. *Dis Colon Rectum* **48**, 1094–1096, <https://doi.org/10.1007/s10350-004-0905-4> (2005).
447. Iesalnieks, I., Deimel, S. & Schlitt, H. J. "Pit picking" surgery for patients with pilonidal disease: mid-term results and risk factors. *Chirurg* **86**, 482–485, <https://doi.org/10.1007/s00104-014-2776-0> (2015).
448. Klaiber, C., Staub, A., Ackermann, D. & Akovbiantz, A. The Lord-Millar operation of pilonidal sinus [Die Sakraldermoidoperation nach Lord-Millar]. *Helv. Chir. Acta* **49**, 221–222 (1982).
449. Froidevaux, A. & Marti, M. C. Sacro coccygeal cysts. Results of a new series of 51 cases [Kystes Sacro Coccygiens. Resultats d'une nouvelle serie de 51 cas]. *Lyon Chir* **73**, 269–271 (1977).
450. Jensen, S. L. & Nielsen, O. V. Lord-Millar brush method in ambulatory treatment of pilonidal cysts. *Ugeskr Laeger* **150**, 98–100 (1988).
451. Di Castro, A., Guerra, F., Sandri, G. B. & Maria Ettorre, G. Minimally invasive surgery for the treatment of pilonidal disease. The Gips procedure on 2347 patients. *Int J Surg* **36**, 201–205, <https://doi.org/10.1016/j.ijsu.2016.10.040> (2016).
452. Petersen, S. Skin preserving pit excision, so-called pit picking. *Pilonidal Sinus Journal* **3**, 1–7 (2017).
453. Awad, M. M. & Saad, K. M. Does closure of chronic pilonidal sinus still remain a matter of debate after bilateral rotation flap? (N-shaped closure technique). *Indian J Plast Surg* **39**, 157–162 (2006).
454. Polat, C. *et al.* Is oval flap reconstruction a good modification for treating pilonidal sinuses? *Am J Surg* **201**, 192–196, <https://doi.org/10.1016/j.amjsurg.2010.01.025> (2011).
455. Krand, O., Yalt, T., Berber, I., Kara, V. M. & Tellioglu, G. Management of pilonidal sinus disease with oblique excision and bilateral gluteus maximus fascia advancing flap: result of 278 patients. *Dis Colon Rectum* **52**, 1172–1177, <https://doi.org/10.1007/DCR.0b013e31819ef582> (2009).
456. Nessar, G., Kayaalp, C. & Seven, C. Elliptical rotation flap for pilonidal sinus. *Am J Surg* **187**, 300–303, <https://doi.org/10.1016/j.amjsurg.2003.11.012> (2004).
457. El-Khatib, H. A. & Al-Basti, H. B. A perforator-based bilobed fasciocutaneous flap: an additional tool for primary reconstruction following wide excision of sacrococcygeal pilonidal disease. *J Plast Reconstr Aesthet Surg* **62**, 494–498, <https://doi.org/10.1016/j.bjps.2007.11.043> (2009).
458. Dizen, H., Yoldas, O., Yildiz, M., Cilekar, M. & Dilektaşlı, E. Modified elliptical rotation flap for sacrococcygeal pilonidal sinus disease. *ANZ J Surg* **84**, 769–771, <https://doi.org/10.1111/ans.12818> (2014).
459. Turan, A., Isler, C., Bas, S. C., Genc, B. & Ozsoy, Z. A new flap for reconstruction of pilonidal sinus: lumbar adipofascial turnover flap. *Ann Plast Surg* **58**, 411–415, <https://doi.org/10.1097/01.sap.0000243999.36577.3f> (2007).
460. Schrogendorfer, K. F. *et al.* Prospective evaluation of a single-sided innervated gluteal artery perforator flap for reconstruction for extensive and recurrent pilonidal sinus disease: functional, aesthetic, and patient-reported long-term outcomes. *World J Surg* **36**, 2230–2236, <https://doi.org/10.1007/s00268-012-1639-4> (2012).
461. Berkem, H. *et al.* V-Y advancement flap closures for complicated pilonidal sinus disease. *Int J Colorectal Dis* **20**, 343–348, <https://doi.org/10.1007/s00384-004-0699-9> (2005).
462. Acarturk, T. O., Parsak, C. K., Sakman, G. & Demircan, O. Superior gluteal artery perforator flap in the reconstruction of pilonidal sinus. *J Plast Reconstr Aesthet Surg* **63**, 133–139, <https://doi.org/10.1016/j.bjps.2008.07.017> (2010).
463. Schoeller, T., Wechselberger, G., Otto, A. & Papp, C. Pilonidal sinus: experience with the Karydakis flap. *Br J Surg* **84**, 890–891 (1997).
464. Dylek, O. N. & Bekereciödlü, M. Role of simple V-Y advancement flap in the treatment of complicated pilonidal sinus. *Eur J Surg* **164**, 961–964 (1998).
465. Mackowski, A. & Levitt, M. Outcomes of the house advancement flap for pilonidal sinus. *ANZ J Surg*, <https://doi.org/10.1111/ans.13077> (2015).
466. Ekcı, B. & Gokce, O. A new flap technique to treat pilonidal sinus. *Tech Coloproctol* **13**, 205–209, <https://doi.org/10.1007/s10151-009-0500-8> (2009).
467. Lashen, A. E., Saad, K. & Raslan, M. Crossed triangular flaps technique for surgical treatment of chronic pilonidal sinus disease. *Arch Surg* **143**, 503–505, <https://doi.org/10.1001/archsurg.143.5.503> (2008).
468. Awad, M. M., Saad, K. M., Tolba, A. M. & Gharib, O. H. A simple novel technique for closure of simple and complex pilonidal sinus with either simple (tongue-shaped) or bilobed rotation flap. *Indian J Plast Surg* **44**, 47–50 (2007).
469. Eryilmaz, R., Okan, I., Coskun, A., Bas, G. & Sahin, M. Surgical treatment of complicated pilonidal sinus with a fasciocutaneous V-Y advancement flap. *Dis Colon Rectum* **52**, 2036–2040, <https://doi.org/10.1007/DCR.0b013e3181beb537> (2009).
470. Basterzi, Y. *et al.* Reconstruction of extensive pilonidal sinus defects with the use of S-GAP flaps. *Ann Plast Surg* **61**, 197–200, <https://doi.org/10.1097/SAP.0b013e3181587a06> (2008).
471. Saray, A., Dirlik, M., Caglikulekci, M. & Turkmenoglu, O. Gluteal V-Y advancement fasciocutaneous flap for treatment of chronic pilonidal sinus disease. *Scand J Plast Reconstr Surg Hand Surg* **36**, 80–84 (2002).

472. Venus, M. R. & Titley, O. G. Outcomes in the repair of pilonidal sinus disease excision wounds using a parasacral perforator flap. *Ann R Coll Surg Engl* **94**, 12–16, <https://doi.org/10.1308/003588412X13171221499748>, <https://doi.org/10.1308/003588412X13373405387339> (2012).
473. Yuksel, B. C., Berkem, H., Ozel, H. & Hengirmen, S. A new surgical method of pilonidal sinus treatment: a bilaterally paralel elliptic fascio-cutaneous advancement flap technique. *Bratisl Lek Listy* **113**, 728–731 (2012).
474. Sahasrabudhe, P., Panse, N., Waghmare, C. & Waykole, P. V-y advancement flap technique in resurfacing postexcisional defect in cases with pilonidal sinus disease-study of 25 cases. *Indian J Surg* **74**, 364–370, <https://doi.org/10.1007/s12262-011-0403-6> (2012).
475. Ozdemir, H., Unal Ozdemir, Z., Tayfun Sahiner, I. & Senol, M. Whole natal cleft excision and flap: an alternative surgical method in extensive sacrococcygeal pilonidal sinus disease. *Acta Chir Belg* **114**, 266–270 (2014).
476. Kayaalp, C., Olmez, A., Aydin, C. & Piskin, T. Tumescant local anesthesia for excision and flap procedures in treatment of pilonidal disease. *Dis Colon Rectum* **52**, 1780–1783, <https://doi.org/10.1007/DCR.0b013e3181b553bb> (2009).
477. Onishi, K. & Maruyama, Y. Sacral adipofascial turn-over flap for the excisional defect of pilonidal sinus. *Plast Reconstr Surg* **108**, 2006–2010 (2001).
478. Sungur, N. *et al.* V-Y rotation advancement fasciocutaneous flap for excisional defects of pilonidal sinus. *Plast Reconstr Surg* **117**, 2448–2454, <https://doi.org/10.1097/01.prs.0000219170.74059.94> (2006).
479. Demiryilmaz, I. *et al.* Application of fasciocutaneous V-Y advancement flap in primary and recurrent sacrococcygeal pilonidal sinus disease. *Med Sci Monit* **20**, 1263–1266, <https://doi.org/10.12659/MSM.890752> (2014).
480. Yucel, E., Tezcan, L. & Yilmaz, O. C. “Flag Excision an Flap” Procedure: a Novel Modification for Off-Midline Closure After Pilonidal Sinus Excision. *Indian J Surg* (2015).
481. Yazar, M. *et al.* Cosmetic closure of pilonidal sinus defects with bilateral transpositional adipofascial flaps. *J Plast Surg Hand Surg* **47**, 292–296, <https://doi.org/10.3109/2000656X.2013.765884> (2013).
482. Elalfy, K., Emile, S., Lotfy, A., Youssef, M. & Elfeki, H. Bilateral gluteal advancement flap for treatment of recurrent sacrococcygeal pilonidal disease: A prospective cohort study. *Int J Surg* **29**, 1–8, <https://doi.org/10.1016/j.ijssu.2016.03.006> (2016).
483. Al Najjar, M. J. & Al-Helfy, S. H. A. Elliptical Rotation Flap for Complicated Pilonidal Sinus. *Iraqi JMS* **13**, 56–63 (2015).
484. Kauer, O. G., Correa, V. R. & Rojas, P. H. Utilizacion del colgajo romboidal simple en el tratamiento quirurgico de la enfermedad pilonidal. *Rev. Chil. Cir.* **51**, 623–626 (1999).
485. Trooskin, S. Z. Pilonidal cyst: wide excision and primary closure with an advancement flap. *J Med Soc N J* **82**, 367–370 (1985).
486. Stroosma, O. C. Gluteal fascioplasty as a method of primary closure in the treatment of pilonidal sinus. *Arch Chir Neerl* **30**, 61–64 (1978).
487. Schoeller, T., Wechselberger, G., Otto, A. & Papp, C. Definite surgical treatment of complicated recurrent pilonidal disease with a modified fasciocutaneous V-Y advancement flap. *Surgery* **121**, 258–263 (1997).
488. Fjermers, H. Pilonidal cysts; treatment by Holman's operation. *Acta Chir Scand* **113**, 374–379 (1957).
489. Javed, M. A. *et al.* Comparison of conventional incision and drainage for pilonidal abscess versus novel endoscopic pilonidal abscess treatment (EPAT). *Tech Coloproctol* **20**, 871–873, <https://doi.org/10.1007/s10151-016-1546-z> (2016).
490. Kayaalp, C., Olmez, A., Aydin, C., Piskin, T. & Kahraman, L. Investigation of a one-time phenol application for pilonidal disease. *Med Princ Pract* **19**, 212–215, <https://doi.org/10.1159/000285291> (2010).
491. Kaymakcioglu, N. *et al.* Treatment of pilonidal sinus by phenol application and factors affecting the recurrence. *Tech Coloproctol* **9**, 21–24, <https://doi.org/10.1007/s10151-005-0187-4> (2005).
492. Sakcak, I., Avsar, F. M. & Cosgun, E. Comparison of the application of low concentration and 80% phenol solution in pilonidal sinus disease. *JRSM Short Rep* **1**, 5 (2010).
493. Girgin, M. *et al.* Minimally invasive treatment of pilonidal disease: crystallized phenol and laser depilation. *Int Surg* **97**, 288–292, <https://doi.org/10.9738/CC130.1> (2012).
494. Aygen, E., Arslan, K., Dogru, O., Basbug, M. & Camci, C. Crystallized phenol in nonoperative treatment of previously operated, recurrent pilonidal disease. *Dis Colon Rectum* **53**, 932–935, <https://doi.org/10.1007/DCR.0b013e3181d8283b> (2010).
495. Dag, A., Colak, T., Turkmenoglu, O., Sozutek, A. & Gundogdu, R. Phenol procedure for pilonidal sinus disease and risk factors for treatment failure. *Surgery* **151**, 113–117, <https://doi.org/10.1016/j.surg.2011.07.015> (2012).
496. Dogru, O., Camci, C., Aygen, E., Girgin, M. & Topuz, O. Pilonidal sinus treated with crystallized phenol: an eight-year experience. *Dis Colon Rectum* **47**, 1934–1938 (2004).
497. Schneider, I. H., Thaler, K. & Kockerling, F. Treatment of pilonidal sinuses by phenol injections. *Int J Colorectal Dis* **9**, 200–202 (1994).
498. Aksoy, H. M., Aksoy, B. & Egemen, D. Effectiveness of topical use of natural polyphenols for the treatment of sacrococcygeal pilonidal sinus disease: a retrospective study including 192 patients. *Eur J Dermatol* **20**, 476–481, <https://doi.org/10.1684/ejd.2010.0978> (2010).
499. Girgin, M. & Kanat, B. H. The results of a one-time crystallized phenol application for pilonidal sinus disease. *Indian J Surg* **76**, 17–20, <https://doi.org/10.1007/s12262-012-0548-y> (2014).
500. Kelly, S. B. & Graham, W. J. Treatment of pilonidal sinus by phenol injection. *Ulster Med J* **58**, 56–59 (1989).
501. Maurice, B. A. & Greenwood, R. K. A Conservative Treatment of Pilonidal Sinus. *Br J Surg* **51**, 510–512 (1964).
502. Stewart, T. J. & Bell, M. The treatment of pilonidal sinus by phenol injection. *Ulster Med J* **38**, 167–171 (1969).
503. Hegge, H. G., Vos, G. A., Patka, P. & Hoitsma, H. F. Treatment of complicated or infected pilonidal sinus disease by local application of phenol. *Surgery* **102**, 52–54 (1987).
504. Yuksel, M. E. Pilonidal sinus disease can be treated with crystallized phenol using a simple three-step technique. *Acta Dermatovenerol Alp Pannonica Adriat* **26**, 15–17 (2017).
505. Emiroglu, M. *et al.* The effect of phenol concentration on the treatment of pilonidal sinus disease: Early results of a prospective randomized study. *Int Surg*, <https://doi.org/10.9738/INTSURG-D-15-00120.1> (2016).
506. Lindholt-Jensen, C. S., Lindholt, J. S. & Beyer, M. Nd-YAG laser treatment of primary and recurrent pilonidal sinus. *Lasers Med Sci* **27**, 505–508 (2012).
507. Landa, N., Aller, O., Landa-Gundin, N., Torrontegui, J. & Azpiazu, J. L. Successful treatment of recurrent pilonidal sinus with laser epilation. *Dermatol Surg* **31**, 726–728 (2005).
508. Shafagh, Y., Beheshti, A., Charkhchian, M. & Rad, F. S. Successful treatment of pilonidal disease by intense pulsed light device. *Adv Clin Exp Med* **23**, 277–282 (2014).
509. Isik, A. *et al.* The use of fibrin glue without surgery in the treatment of pilonidal sinus disease. *Int J Clin Exp Med* **7**, 1047–1051 (2014).
510. Rao, A. C. Cutting seton for pilonidal disease: a new approach. *Tech Coloproctol* **10**, 242–244, <https://doi.org/10.1007/s10151-006-0287-9> (2006).
511. Meinero, P., Mori, L. & Gasloli, G. Endoscopic pilonidal sinus treatment (E.P.Si.T.). *Tech Coloproctol* **18**, 389–392, <https://doi.org/10.1007/s10151-013-1016-9> (2014).
512. Hussain, Z. I., Aghahoseini, A. & Alexander, D. Converting emergency pilonidal abscess into an elective procedure. *Dis Colon Rectum* **55**, 640–645, <https://doi.org/10.1097/DCR.0b013e31824b9527> (2012).
513. Evers, T. *et al.* Trends in incidence and long-term recurrence rate of pilonidal sinus disease and analysis of associated influencing factors. *Zhonghua Wai Ke Za Zhi* **49**, 799–803 (2011).

514. Milone, M. *et al.* Video-assisted ablation of pilonidal sinus: a new minimally invasive treatment—a pilot study. *Surgery* **155**, 562–566, <https://doi.org/10.1016/j.surg.2013.08.021> (2014).
515. Chia, C. L., Tay, V. W. & Mantoo, S. K. Endoscopic pilonidal sinus treatment in the Asian population. *Surg Laparosc Endosc Percutan Tech* **25**, e95–97, <https://doi.org/10.1097/SLE.000000000000131> (2015).
516. Meinero, P. *et al.* Endoscopic pilonidal sinus treatment (EPSiT): a prospective multicentre trial. *Colorectal Dis*, <https://doi.org/10.1111/codi.13322> (2016).
517. Hemanta, P., Kumar, R. R. & Rao, M. M. Ksharasutra therapy - a minimal invasive parasurgical method in the treatment of sacrococcygeal pilonidal sinus (Nadi vrana): Result of a pilot study. *Intern. J. Res. Ayurveda Pharm.* **3**, 668–670, <https://doi.org/10.7897/2277-4343.03518> (2012).
518. Borde, C. M. & Bruck, H. G. The indications for split thickness skin grafting in recurrent pilonidal sinus [Die Indikation zur Spalthautplastik bei rezidivierendem pilonidalem Sinus (Sakraldermoid)]. *Wiener Klinische Wochenschrift* **85**, 624–628 (1973).
519. Jain, Y. *et al.* Endoscopic pilonidal abscess treatment: a novel approach for the treatment of pilonidal abscess. *Ann R Coll Surg Engl* **99**, 134–136, <https://doi.org/10.1308/rcsann.2016.0260> (2017).
520. Berger, H. The medical treatment of pilonidal disease. *N Y State J Med* **49**, 1313 (1949).
521. Gecim, I. E., Goktug, U. U. & Celasin, H. Endoscopic Pilonidal Sinus Treatment Combined With Crystalized Phenol Application May Prevent Recurrence. *Dis Colon Rectum* **60**, 405–407, <https://doi.org/10.1097/DCR.0000000000000778> (2017).
522. Suarez Valladares, M. J. & Rodriguez-Prieto, M. A. Laser Nd:YAG to treat primary pilonidal cysts: an alternative treatment. *Br J Dermatol*, <https://doi.org/10.1111/bjd.15929> (2017).
523. Giarratano, G. *et al.* Endoscopic Pilonidal Sinus Treatment: Long-Term Results of a Prospective Series. *JSLs* **21**, <https://doi.org/10.4293/JSLs.2017.00043> (2017).
524. Rogers, H. & Dwight, R. W. Pilonidal Sinus: Observations on One Hundred Forty Cases Treated by Cautery Excision. *Ann Surg* **107**, 400–418 (1938).
525. Close, A. S. Pilonidal cysts: an analysis of surgical failures. *Ann Surg* **141**, 523–526 (1955).
526. Hoffert, P. W. & Healy, M. J. Jr. Pilonidal sinus and cyst: an analysis of the results of surgical therapy in 229 consecutive cases. *Bull N Y Acad Med* **28**, 612 (1952).
527. Dwight, R. W. & Maloy, J. K. Pilonidal sinus; experience with 449 cases. *N Engl J Med* **249**, 926–930, <https://doi.org/10.1056/NEJM195312032492303> (1953).
528. Breidenbach, L. & Wilson, H. L. Pilonidal Cysts and Sinuses. *Ann Surg* **102**, 455–463 (1935).
529. Palumbo, L. T., Larimore, O. M. & Katz, I. A. Pilonidal cysts and sinuses; a statistical review. *AMA Arch Surg* **63**, 852–857 (1951).
530. Kleckner, M. S. Pilonidal Sinus: Its surgical management. *Trans Am Proctol Soc* **36**, 166 (1936).
531. Mathesheimer, J. L. An ambulant method for the treatment of pilonidal disease. *Am J Surg* **69**, 230–231 (1945).
532. Lawrence, K. B. & Baker, W. J. The marsupialization operation for pilonidal sinus; a comparison with other surgical methods in 359 cases. *N Engl J Med* **245**, 134–139, <https://doi.org/10.1056/NEJM195107262450403> (1951).
533. Kleiman, A. Pilonidal cyst; follow-up studies on 481 patients. *US Armed Forces Med J* **3**, 575–580 (1952).
534. Guyuron, B., Dinner, M. I. & Dowden, R. V. Excision and grafting in treatment of recurrent pilonidal sinus disease. *Surg Gynecol Obstet* **156**, 201–204 (1983).
535. Jordan, M. H. & Meinecke, H. M. Ambulatory surgery for pilonidal disease. *Am Surg* **45**, 360–363 (1979).
536. Feigenbaum, H. A. Excision of acute pilonidal cyst abscess; a preliminary report. *Am J Surg* **94**, 636–637 (1957).
537. Brust, J. C. & Sarner, J. B. Pilonidal cyst. *N Y State J Med* **48**, 2138–2144 (1948).
538. Larsen, B. B. Comparative results-in operations for pilonidal cysts. *Arch Surg* **56**, 516–521 (1948).
539. Heaton, J. R. Surgical treatment of pilonidal disease. *J Mich State Med Soc* **56**, 1566–1567 passim (1957).
540. Grau, H. R. Pilonidal sinus; etiology of recurrence. *J Int Coll Surg.* **15**, 591–604 (1951).
541. Heifetz, C. J. Pilonidal disease; a study of fifty consecutive cases treated successfully by excision and primary closure. *Am J Surg* **96**, 405–410 (1958).
542. Comarr, A. E. Pilonidal cysts and/or sinuses: primary closure with the wirebution retention technic. *Am J Surg* **97**, 328–330 (1959).
543. Ross, R. L. Recurrent pilonidal cyst and sinus; a plan of preoperative preparation, operation and postoperative care. *Calif Med* **85**, 183–186 (1956).
544. Leichtling, J. J. Simple primary closure for sacrococcygeal pilonidal disease. *Am J Surg* **113**, 441–444 (1967).
545. Larsen, B. B. Pilonidal cysts and sinuses; a technic for excision and primary closure. *Ann Surg* **123**, 1090–1100 (1946).
546. Hamilton, J. E. & Cattnach, L. M. Comparative study of chemotherapies in the surgery of pilonidal sinus. *Am J Surg* **74**, 449–454 (1947).
547. Goldman, B. Combined therapy for pilonidal (sacrococcygeal) cyst and sinus; roentgen epilation of operative field prior to surgical excision with primary closure. *J Int Coll Surg.* **18**, 903–909 (1952).
548. Ferguson, L. K. & Mecray, P. M. Pilonidal Cysts: Excision and primary suture in ambulatory patients. *Am J Surg* **36**, 270–277 (1937).
549. Larkin, L. C. Pilonidal cyst; analysis of 100 consecutive cases, emphasizing treatment by radical excision, primary closure and penicillin therapy. *Surg Gynecol Obstet* **82**, 694–704 (1946).
550. Bear, N. E. & Woldman, V. F. Treatment of pilonidal cysts. *Wis Med J* **44**, 1166–1169 (1945).
551. Bentivegna, S. S. & Procaro, P. Primary closure of pilonidal cystectomy. *Am Surg* **43**, 214–216 (1977).
552. Laforet, E. G. Pilonidal sinus; a method of treatment by primary closure. *Am J Surg* **93**, 873–875 (1957).
553. Finestone, E. O. Technic of excision and primary closure of pilonidal sinus. *N Y State J Med* **52**, 1291–1294 (1952).
554. Turner, F. P. & O'Neil, J. W. Treatment of pilonidal sinus by primary closure; a seven-year study. *AMA Arch Surg* **78**, 398–405 (1959).
555. Hamilton, J. E., Stephens, G. & Claugus, C. E. Pilonidal Sinus: Excision and Primary Closure. *Surgery* **54**, 597–603 (1963).
556. Beardsley, J. M. Treatment of pilonidal cyst and sinus. *AMA Arch Surg* **68**, 608–611 (1954).
557. Ziegler, H. R., Murphey, D. R. Jr. & Meeke, E. M. Pilonidal cyst and sinus; a new method of excision with primary closure. *Surgery* **20**, 690–703 (1946).
558. Bellis, C. J. Pilonidal cyst; treatment by a uniformly successful method. *J Int Coll Surg.* **13**, 334–337 (1950).
559. Kleitsch, W. P. & Cherry, L. D. Pilonidal sinus; a rational scheme of treatment. *Mil Surg* **111**, 96–106 (1952).
560. Casten, D. F., Tan, B. Y. & Ayuyao, A. A technique of radical excision of pilonidal disease with primary closure. *Surgery* **73**, 109–114 (1973).
561. Brezin, D., Love, C. & Lawrence, J. Pilonidal cyst. *Am J Surg* **60**, 264–266 (1943).
562. Bascom, J. & Bascom, T. Failed pilonidal surgery: new paradigm and new operation leading to cures. *Arch Surg* **137**, 1146–1150; discussion 1151 (2002).
563. Bascom, J. & Bascom, T. Utility of the cleft lift procedure in refractory pilonidal disease. *Am J Surg* **193**, 606–609; discussion 609, <https://doi.org/10.1016/j.amjsurg.2007.01.008> (2007).
564. Immerman, S. C. Treatment of pilonidal disease using the Bascom 'Cleft-Lift' procedure. *Am Surg* **80**, E49–50 (2014).
565. Bascom, J. U. Repeat pilonidal operations. *Am J Surg* **154**, 118–122 (1987).
566. Mansoor, A. & Dickson, D. Z-plasty for treatment of disease of the pilonidal sinus. *Surg Gynecol Obstet* **155**, 409–411 (1982).
567. Abramson, D. J. A simple marsupialization technic for treatment of pilonidal sinus: long-term follow up. *Ann Surg* **151**, 261–267 (1960).
568. Neumeister, C. A. A modification of the marsupialization operation for pilonidal disease. *South Med J* **56**, 730–732 (1963).

569. Cavanagh, C. R., Schnug, G. E., Girvin, G. W. & McGonigle, D. J. Definitive marsupialization of the acute pilonidal abscess. *Am Surg* **36**, 650–651 (1970).
570. van Ess, L. J. Surgical management of pilonidal disease. *Am J Proctol* **16**, 389–393 (1965).
571. Uhle, A. O. Eventration of pilonidal cysts and sinuses. *Northwest Med* **56**, 687–690 (1957).
572. Gage, A. A. & Dutta, P. Cryosurgery for pilonidal disease. *Am J Surg* **133**, 249–254 (1977).
573. O'Connor, J. J. Surgery plus freezing as a technique for treating pilonidal disease. *Dis Colon Rectum* **22**, 306–307 (1979).
574. Miller, R. J. Pilonidal disease. A logical approach. *Postgrad Med* **41**, 382–385 (1967).
575. Matino, J. J., Banerjee, S., Brown, S. H. & Waldron, J. E. Human dermal tissue allograft use in treating chronic pilonidal sinus. *Conn Med* **74**, 393–398 (2010).
576. Shafiroff, B. G. & Doubilet, H. The conservative treatment of pilonidal cyst. *N Y State J Med* **46**, 891–893 (1946).
577. Crile, G. Jr. A definitive ambulatory treatment for infected pilonidal cysts. *Surgery* **24**, 677–679 (1948).
578. Korb, J. H. Infected pilonidal cysts; a simplified method of treatment. *Mil Surg* **108**, 29–34 (1951).
579. Bascom, J. Pilonidal disease: long-term results of follicle removal. *Dis Colon Rectum* **26**, 800–807 (1983).
580. Bascom, J. Pilonidal disease: origin from follicles of hairs and results of follicle removal as treatment. *Surgery* **87**, 567–572 (1980).
581. Turner, F. P. Pilonidal sinus: primary closure with equal musculofascial flaps and removable far-and-near sutures; analysis of fifty-nine consecutive cases. *Ann Surg* **140**, 687–694 (1954).
582. Cherry, J. K. Primary closure of pilonidal sinus. *Surg Gynecol Obstet* **126**, 1263–1269 (1968).
583. Dwight, R. W. Pilonidal sinus; an evaluation of plastic closure using flaps of gluteal muscle. *AMA Arch Surg* **64**, 438–442 (1952).
584. Feit, H. L. The use of thorium X in treatment of pilonidal cyst: a preliminary report. *Dis Colon Rectum* **3**, 61–64 (1960).
585. Armstrong, J. H. & Barcia, P. J. Pilonidal sinus disease. The conservative approach. *Arch Surg* **129**, 914–917 discussion 917–919 (1994).
586. Pyrttek, L. J. & Bartus, S. A. Excision of Pilonidal Cyst with Simplified Partial Wound Closure. *Surg Gynecol Obstet* **118**, 605–608 (1964).
587. Petersen, S. *et al.* Short-term results of Karydakias flap for pilonidal sinus disease. *Tech Coloproctol* **11**, 235–240 (2007).
588. Doll, D., Luedi, M. M., Evers, T., Kauf, P. & Matevossian, E. Recurrence-free survival, but not surgical therapy per se, determines 583 patients' long-term satisfaction following primary pilonidal sinus surgery. *Int J Colorectal Dis* **30**, 605–611, <https://doi.org/10.1007/s00384-015-2130-0> (2015).
589. Vogel, P. & Lenz, J. Treatment of pilonidal sinus with excision and primary suture using a local, resorbable antibiotic carrier. Results of a prospective randomized study. *Chirurg* **63**, 748–753 (1992).
590. Denkers, D. & Girona, J. Der abszedierte Sinus pilonidalis der Steißbeinregion - Möglichkeiten der chirurgischen Versorgung. *Coloproctology* **18**, 257–259 (1996).
591. Eichfuss, H. P., Eichen, R., Koch, G. & Eckert, P. Primary closure of the sinus pilonidalis. *Chirurg* **49**, 124–126 (1978).
592. Eichfuss, H. P., Schontag, H. & Pfeiffer, M. A new surgical procedure for treating sacrococcygeal fistulas and cysts. [Ein neues Operationsverfahren der Steissbeinfisteln und -zysten]. *Aktuel Chir* **17**, 138–140 (1982).
593. Hasse, F. M., Rademacher, C., Bingham, K. & Lohlein, D. The Dufourmentel flap-plasty for treatment of chronic pilonidal sinus. *Chirurg* **69**, 663–666 (1998).
594. Jaschke, C. W., Mahrlein, R. & Mangold, G. Results of the Limberg transposition flap in the treatment of pilonidal sinus. *Zentralbl Chir* **127**, 712–715, <https://doi.org/10.1055/s-2002-33579> (2002).
595. Friedl, P. G., Rappold, E. M. & Jager, C. Effective and minimally painful surgery of pilonidal sinus - asymmetric transposition flap according to Dufourmentel. *J Dtsch Dermatol Ges* **9**, 333–335, <https://doi.org/10.1111/j.1610-0387.2011.07662.x> (2011).
596. Geuenich, A. & Hannekum, A. Primary closure of pilonidal sinus through a slide-swing operation. *Chirurg* **52**, 114–117 (1981).
597. Akinci, O. F., Coskun, A., Ozgonul, A. & Terzi, A. Surgical treatment of complicated pilonidal disease: limited separate elliptical excision with primary closure. *Colorectal Dis* **8**, 704–709, <https://doi.org/10.1111/j.1463-1318.2006.01022.x> (2006).
598. Fuzun, M. *et al.* Which technique for treatment of pilonidal sinus—open or closed? *Dis Colon Rectum* **37**, 1148–1150 (1994).
599. Aydede, H., Erhan, Y., Sakarya, A. & Kumkumoglu, Y. Comparison of three methods in surgical treatment of pilonidal disease. *ANZ J Surg* **71**, 362–364 (2001).
600. Cihan, A. *et al.* Modified Limberg flap reconstruction compares favourably with primary repair for pilonidal sinus surgery. *ANZ J Surg* **74**, 238–242, <https://doi.org/10.1111/j.1445-2197.2004.02951.x> (2004).
601. Yetim, I., Ozkan, O. V., Dervisoglu, A., Erzurumlu, K. & Canbolant, E. Effect of gentamicin-absorbed collagen in wound healing in pilonidal sinus surgery: a prospective randomized study. *J Int Med Res* **38**, 1029–1033 (2010).
602. Kaya, B., Uctum, Y., Simsek, A. & Kutanis, R. Treatment of Pilonidal Sinus with Primary Closure. *A Simple and Effective Method. Kolon Rektum Hast Derg.* **20**, 59–65 (2010).
603. Küçükkartallar, T., Tekin, A. & Vatansev, C. The comparison of the results of different operation techniques for pilonidal sinus disease. *Genel Tip Derg* **17**, 95–97 (2007).
604. Özgultekin, R. *et al.* Therapy of pilonidal sinus with the Limberg transposition flap. *Chirurg* **66**, 192–195 (1995).
605. Yilmaz, S., Kirimlioglu, V. & Katz, D. R. *Am J Surg* **166**, 269 (2000).
606. Yetişir, F., Kaya, O. & Baran, I. The comparison of marsupialization and Limberg flap in the treatment of pilonidal disease. *Türk. J. Surg.* **21**, 184–190 (2005).
607. Zorlu, M. *et al.* Early results with the Mutaf technique: a novel off-midline approach in pilonidal sinus surgery. *Ann Surg Treat Res* **90**, 265–271, <https://doi.org/10.4174/ast.2016.90.5.265> (2016).
608. Arik, M. K. & Borazan, E. Phenol application combined with minimally invasive surgery for pilonidal sinus treatment [Pilonidal sinüste minimal invaziv cerrahi ile kombine fenol uygulamalarimiz]. *Anatolian J. Clin. Invest.* **5**, 165–168 (2011).
609. Yilmaz, M., Engin, O. & Uyar, M. E. Crystalline Phenol Practices and Clinical Results in our Patients with Pilonidal Sinus. *J Universal Surg* **3**, 1–4 (2015).
610. Castronovo, G., Ciulla, A., Urso, G., Tomasello, G. & Damiani, S. Pilonidal sinus: an retrospective analysis of 205 cases. *Ann Ital Chir* **74**, 559–563 (2003).
611. Bianco, V., Basile, C. & Tortorella, M. Sacrococcygeal pilonidal sinus disease. Treatment by “open” and “closed” technique: personal experience. *G Chir* **24**, 145–147 (2003).
612. Cimarelli, S. & Magnano, G. Treatment of pilonidal sinus. Our experience. *Minerva Chir* **44**, 1131–1134 (1989).
613. Pezzangora, V., Averno, V. & Barina, R. Treatment of fistulized pilonidal sinuses by phenol injection. *Chir Ital* **32**, 848–854 (1980).
614. Ciccolo, A. *et al.* Treatment of pilonidal disease in short-stay surgery: personal method. *Ann Ital Chir* **75**, 603–605 (2004).
615. Filingeri, V. & Gravante, G. Radiofrequency sinus excision. *Dig. Surg.* **23**, 125, <https://doi.org/10.1159/000094136> (2006).
616. Brearley, R. Treatment of pilonidal sinus. *Br Med J* **2**, 1256 (1959).
617. Del Papa, M., Mobili, M., Attardo, S., Paolucci, G. & Braccioni, U. Radical excision and primary suture of pilonidal sinus: our experience. *Ann Ital Chir* **63**, 507–509; discussion 509–510 (1992).
618. Cianci, F. & Marinaccio, F. Treatment of pilonidal sinus by radical excision and primary closure. Our experience. *Minerva Chir* **39**, 1111–1115 (1984).
619. Cortese, M., Benedetti Valentini, G. & Giacomini, S. Personal experience in the treatment of pilonidal sinus. *Minerva Chir* **40**, 1137–1139 (1985).
620. Vitale, A., Barberis, G., Maida, P. & Salzano, A. Use of biological glue in the surgical treatment of sacrococcygeal fistulas. *G Chir* **13**, 271–272 (1992).

621. Muzi, M. G. *et al.* Muzi's Tension Free Primary Closure of Pilonidal Sinus Disease: Long-Term Results on 450 Patients. *Gastroenterology* **152**, S1212–S1213, [https://doi.org/10.1016/s0016-5085\(17\)34034-9](https://doi.org/10.1016/s0016-5085(17)34034-9) (2017).
622. De Nardi, P., Gazzetta, P. G., Fiorentini, G. & Guarneri, G. The cleft lift procedure for complex pilonidal disease. *European Surgery* **48**, 250–257, <https://doi.org/10.1007/s10353-016-0428-y> (2016).
623. Casula, G., Uccheddu, A. & Figus, M. Long term results of the Z-plasty method in the treatment of pilonidal sinus. *Minerva Chir* **38**, 617–620 (1983).
624. Meinero, P. & Mori, L. Endoscopic pilonidal sinus treatment (E.P.Si.T): a new mininvasive procedure. *Journal of the American College of Surgeons* **219**, e75, <https://doi.org/10.1016/j.jamcollsurg.2014.07.583> (2014).
625. Roberton, H. R. Pilonidal surgery. *Med J Aust* **1**, 375–376 (1981).
626. Thomas, D. Pilonidal sinus: a review of the literature and a report of 100 cases. *Med J Aust* **2**, 184–188 (1968).
627. Kitchen, P. R. B. Pilonidal sinus: Excision and primary closure with a lateralised wound - the Karydakos operation. *Aust. New Zealand J. Surg.* **52**, 302–305 (1982).
628. McDermott, F. T. Pilonidal sinus treated by Z-plasty. *Aust N Z J Surg* **37**, 64–69 (1967).
629. Hobbs, A. F. An operative technique for the treatment of pilonidal sinus. *Aust N Z J Surg* **36**, 337–342 (1967).
630. Stephens, F. O. & Sloane, D. R. Management of pilonidal sinus—a modern approach. *Med J Aust* **1**, 395–396 (1968).
631. Owen Smith, M. S. Phenol irrigation for pilonidal sinus. **121**, 79–86 (1975).
632. Evangelou, G. & Tiniakos, G. Treatment of pilonidal sinus disease based on pathological observations. *Int Surg* **59**, 493–496 (1974).
633. Karydakos, G. E. Easy and successful treatment of pilonidal sinus after explanation of its causative process. *Aust N Z J Surg* **62**, 385–389 (1992).
634. Karydakos, G. E. New approach to the problem of pilonidal sinus. *Lancet* **2**, 1414–1415 (1973).
635. Toubanakos, G. Treatment of pilonidal sinus disease with the Z-plasty procedure (modified). *Am Surg* **52**, 611–612 (1986).
636. Zambouras, D. H. & Karavas, N. Operative Behandlung des Sakraldermoids durch eine neue modifizierte Marsupialisationsmethode. *Chirurg* **7**, 330–331 (1971).

Acknowledgements

We acknowledge the editorial assistance of Jeannie Wurz, Science Writer in the Department of Anesthesiology and Pain Medicine, Inselspital, Bern University Hospital, University of Bern, 3010 Bern, Switzerland.

Author contributions

Statistical analysis and calculations: A.O., V.S., M.M.L., P.K., M.S. and D.D. Manuscript editing and interpretation of data: A.O., V.S., M.M.L., P.K., M.S., M.D., A.P.V., K.M.W. and D.D. Manuscript writing: A.O., V.S., M.M.L., A.P.V., P.K. and D.D. Graphic design: A.O., V.S., M.M.L., P.K., M.S. and D.D. Data acquisition: A.O., V.S., M.M.L., M.D., K.M.W. and D.D.

Competing interests

Dietrich Doll, Andriu Orlik, Katharina Maier, Peter Kauf, Marco Schmid, Maja Diekmann, Andreas P. Vogt, Verena K. Stauffer and Markus M. Luedi declare no competing financial interests. This research received no specific grant from any funding agency in the public, commercial, or not-for-profit sectors. There are no relevant or minor financial relationships of authors, their relatives, or next of kin with external companies.

Additional information

Supplementary information is available for this paper at <https://doi.org/10.1038/s41598-019-51159-z>.

Correspondence and requests for materials should be addressed to D.D.

Reprints and permissions information is available at www.nature.com/reprints.

Publisher's note Springer Nature remains neutral with regard to jurisdictional claims in published maps and institutional affiliations.



Open Access This article is licensed under a Creative Commons Attribution 4.0 International License, which permits use, sharing, adaptation, distribution and reproduction in any medium or format, as long as you give appropriate credit to the original author(s) and the source, provide a link to the Creative Commons license, and indicate if changes were made. The images or other third party material in this article are included in the article's Creative Commons license, unless indicated otherwise in a credit line to the material. If material is not included in the article's Creative Commons license and your intended use is not permitted by statutory regulation or exceeds the permitted use, you will need to obtain permission directly from the copyright holder. To view a copy of this license, visit <http://creativecommons.org/licenses/by/4.0/>.

© The Author(s) 2019