

# We are IntechOpen, the world's leading publisher of Open Access books Built by scientists, for scientists

5,900

Open access books available

145,000

International authors and editors

180M

Downloads

Our authors are among the

154

Countries delivered to

TOP 1%

most cited scientists

12.2%

Contributors from top 500 universities



WEB OF SCIENCE™

Selection of our books indexed in the Book Citation Index  
in Web of Science™ Core Collection (BKCI)

Interested in publishing with us?  
Contact [book.department@intechopen.com](mailto:book.department@intechopen.com)

Numbers displayed above are based on latest data collected.  
For more information visit [www.intechopen.com](http://www.intechopen.com)



# Impacted First and Second Permanent Molars: Overview

*Sanaa Alami, Hakima Aghoutan, Meriem Bellamine  
and Farid El Quars*

## Abstract

Impaction of a permanent tooth is a relatively common clinical occurrence in the human dentition. First mandibular molars and maxillary second molars are rarely impacted with a reported prevalence of 0–2.3% for second molars, 0.02% for the maxillary first molar, and of less than 0.01% for the mandibular first molar. The failures in their eruption mechanism may occur due to an obstacle such as the presence of a supernumerary tooth or an odontoma, lack of adequate space in the arch, an abnormal eruption path, or with idiopathic etiology. It is an asymptomatic pathology which is usually a casual discovery. Early diagnosis and treatment of permanent molars eruption disturbances contributes to optimal outcomes and favorable long-term prognosis by reduction of complication. The purpose of this chapter is (1) to define prevalence and etiopathogeny of impacted first and second permanent molars, (2) to pinpoint the needs of earlier diagnosis, and finally (3) to highlight the treatment options.

**Keywords:** unerupted, impacted teeth, first molars, second molars, permanent molars, retained asymptomatic molars, uprighting molars, orthodontic treatment

## 1. Introduction

Impaction of a permanent tooth is a relatively common clinical occurrence in the human dentition. It mostly involves the mandibular and maxillary third molars, the maxillary canines or central incisors, and the mandibular second premolars while the first mandibular molars and maxillary second molars are seldom concerned. It deals with an abnormality of position in the wake of the failure of eruption [1].

Raghoobar et al. [2] suggested that teeth of the permanent dentition, of which the first and second molars, may fail to erupt either as a result of mechanical obstruction, such as the presence of a supernumerary tooth or an odontoma, lack of adequate space in the arch, or because of disruption to the eruptive mechanism itself, or idiopathic etiology.

This multifactorial origin disturbance entails various clinical forms. Thereby, a broad range of terms are used so as to illustrate this phenomenon: retention and impaction. In reality, each of these words designates various etiologic factors and involves an accurate diagnostic what leads to the prognosis and the treatment of such a disturbance.

This asymptomatic pathology is most of the time a casual discovery and may incite various pathologic conditions of neighboring and opposing teeth, such as caries, periodontitis or roots resorption, and eventually malocclusions. And so, it is

an unpredictable situation dentists have to keep up with through the use of proper clinical and radiological assessment [2–5].

Indeed, optimal outcomes can be reached if both of diagnosis and treatment of such a disturbance are early done. However, multiple local factors are involved in the failure of eruption and influence its prognosis and treatment. Among them are inclination axis, stage of the root formation, and the depth of the molar, although their exact roles have not been established and the age of the patient is probably a key factor in the evolution of the cases [1–3].

The treatment options are based on the type of eruptive abnormality and the age of the patient, including observation, orthodontic or surgical approaches and extraction of the unerupted molar. Each approach has its indications, contraindications, advantages, and disadvantages [1, 2].

This chapter copes with an overview of this pathology and aims (1) to recall the mechanisms of normal and disturbed eruption, (2) to define prevalence and etiopathogeny of impacted first and second permanent molars, (3) to shed light on the needs of earlier diagnosis, and ultimately (4) to bring the limelight on the treatment options.

## **2. Normal and disturbed eruption of permanent molars**

Eruption comes down to a process of biological maturation which involves the axial movement of a tooth from the developmental position within the jaw toward the functional position in the occlusal plane [1, 6]. The grounds of this biological mechanism remain unknown even if several hypotheses have already been argued. Amidst these hypotheses, root growth, hydrostatic pressure, and selective bone deposition and resorption are not sufficiently supported by experimental data.

Moreover, there is no denying that the periodontal ligament and the dental follicle provide the required force to generate this tooth eruption. However, although this theory is widely disregarded because eruption also occurs in its absence, it obviously remains the cogent argument. To sum up the foregoing, eruption is a multifactorial process in which the loss of one factor can be successfully offset by another [7].

The eruption of the first and second permanent molars is especially significant for the coordination of facial growth, and for providing sufficient occlusal support for undisturbed mastication [1, 6]. Their eruption differs from that of other permanent teeth in the sense that [2]:

- They do not have preceding primary teeth.
- Their development is sequentially initiated in the tuberosity of the maxilla and at the junction of the ascending and horizontal ramus of the mandible.
- As a result of the growth of the jaws, the relative position of the first molar shifts anteriorly at the time of the development of the second molar.
- At the beginning, the occlusal surface of the mandibular molars is mesial while that of the maxillary molars is distally inclined.
- During growth of the jaws, the crowns gradually move to an upright position.
- Just after emergence, half of the roots of lower first permanent molars and central incisors have been formed while three quarters of the roots of all other tooth have normally been formed.

Eruption disturbances of teeth are usual and can have a negative sway on the development of the tooth and jaw system. The clinical spectrum of eruption disturbances may vary from delayed eruption to failure of eruption.

Failure of eruption, unlike delayed eruption, is considered as the inability of the tooth to emerge in the oral cavity [1]. It may affect one or several teeth, in either the primary or the permanent dentition, and can be partial or complete. In this case, teeth may be totally covered by bone or soft tissue. In every instance, the failure is contingent on underlying etiology [8].

Average eruption ages have been established for each dental category; however, there is individual variability in the eruption pattern and dental development. First molars emerge on the mean at 6 years of dental age. Eruption of the permanent second molars occurs, typically, few months after primary second molars, and maxillary primary canines are replaced by their successors at dental age 12 [9]. According to Helm and Seidler, it normal emergence was defined as in the maxilla 12.4 and 11.9 years in the mandible, and 11.9 and 11.4 years for boys and girls, respectively [1, 6].

It is important to consider that 6-month delay in eruption of a permanent mandibular second molar compared with its contralateral counterpart or a 1-year delay in eruption of both molars should indicate a need for further radiographic investigation [9]. When eruption of a permanent tooth is at least 2 years behind schedule, disorder eruption should be suspected [3].

### 3. Epidemiology

Impaction of a permanent tooth most commonly involves the mandibular and maxillary third molars that accounts for more than 80% of all impacted teeth. In [9], the following teeth concerned by the impaction are the maxillary canines or central incisors and the mandibular second premolars themselves followed by first mandibular molars and maxillary second molars.

Failure of first and second permanent molars is rare. Their prevalence has only been reported in a few studies. Baccetti [6] found a prevalence rate of 1.7% failure of eruption of both first and second molars. According to Grover [1], for the first permanent molar, it stands for 0.01 and 0.06% in the case of the second one.

Palma et al. [1] and Valmaseda-Castellón et al. [5] found lower second molars to be the most frequently affected, followed by upper second molars. First permanent molar impaction is seldom, with prevalence rates of 0.02% for the maxillary and of less than 0.01% for the mandibular. As regards Grover and Lorton, they found that the prevalence rate of impaction of upper second molars is 0.08% of the population and 0.06% for lower second molars [5].

Likewise, Bondemark and Tsiopa [6] have determined the frequency of anomalies concerning the position and the eruption affecting the second permanent molar. In a point of fact, there is an overall prevalence of eruption disturbances of 2.3% including 1.5%, for ectopic eruption, 0.6% for primary retention, and 0.2% for impaction.

The findings in South Indian population, with an age range of 15–67 years, brought to the limelight that the prevalence of impacted second mandibular molars was about 0.16% [10].

Such rates explain that earlier studies have focused only on the prevalence of disturbed eruption of the lower second molar.

Furthermore, the prevalence of second lower molar seems to be linked to the age of the patient. The results show the frequency higher as patients are younger. Indeed, the prevalence in Sweden was estimated to be around 0.15% for cases

between 10 and 19 years old according to Varpio and Wellfelt, while it accounts for 0.58% for 12-year-old Chinese children according to Davis. Shapira et al. found that the Chinese-American population was representing a higher prevalence (2.3%) of mandibular second molar impaction compared with the Israeli population (1.4%). Likewise, Shiu-yin Cho [9] found higher prevalence of 1% in Chinese schoolchildren.

As regards genders, some studies found a marked prevalence of this abnormality in males [1, 6]. On the contrary, other studies argued that there are more females with impacted lower second molars than males [3, 9, 10]. But in reality, not any significant difference has already been detected [3, 6, 9].

Additionally, the findings of some comparative analysis revealed that the prevalence of eruption has been increasing compared to the previous rates [1, 9, 11]. Evan et al. in their studies aimed to investigate the incidence of lower second molar impaction among two samples of 200 orthodontic patients referred to the Orthodontic Department of Bristol Dental Hospital consecutively in 1976 and 1986. Thereby they concluded in favor of this statement [11].

#### 4. Etiopathogeny

Numerous local factors are involved in the failure of eruption, and they influence its prognosis and treatment. Teeth of the permanent dentition may fail to erupt either as a result of mechanical obstruction which could be idiopathic or pathological or because of the eruptive mechanism disruption [2]. According to Andreasen et al. [4], three main causes have been involved in the eruption disturbances. These causes include ectopic tooth position, obstacles in the eruption path, and failures in the eruption mechanism.

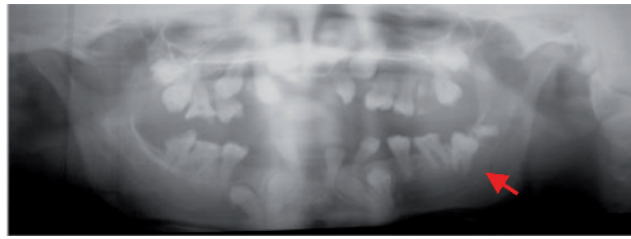
The failures of the eruption mechanism may occur due to the presence of an obstacle such as a supernumerary tooth or an odontoma, lack of adequate space in the arch, an abnormal eruption path, or an idiopathic etiology.

As a whole, causes of eruption disturbances, particularly failure of tooth eruption, could be categorized into general and local factors. It may depend on syndromic and non-syndromic problems for both kinds of factors [4, 6, 12].

- Systemic factors are present in patients with certain syndromes. Usually, multiple teeth are affected. However, eruption failure in the permanent dentition is associated with small number of syndromes [8] (**Figure 1**).
- In cases with local eruption disturbance, only one or a few teeth are affected. Local factors related to the failure of eruption include malocclusion disturbances of the deciduous dentition, the position of the adjacent teeth, lack of space in the dental arch, idiopathic factors, supernumerary teeth, odontomas, or cysts.
- Heredity is also mentioned as an etiological factor. Recently, mutations in parathyroid hormone receptor 1 have been identified in several familial cases of primary failure of eruption. Nevertheless, on occasion, the failure of eruption of first and second permanent molars is not associated with any systemic conditions or genetic alterations.

Differential diagnosis for these abnormal eruption patterns was not easy to identify either clinically or radiographically before starting the treatment.

We may conclude that the eruption disturbances of permanent molars may occur due to an impaction, primary retention, or secondary retention [1, 2].



**Figure 1.**  
*Panoramic radiograph of a 17-year-old patient with mental and growth retardation. We can note the agenesis of 15, 31, and 48, as well as multiple retentions including 37 inclined distally and overlapped by the germ of 38.*

These terms are used indifferently and often synonymously. The etiology of the three disorders is, however, different as is their diagnosis and treatment approach [13].

#### **4.1 Etiology of impaction**

Impaction is the cessation of the eruption of a tooth. Tooth was deemed to be impacted when its complete eruption to occlusal height was prevented by an abnormal contact with another tooth in the same arch [11].

The majority of cases are caused by a clinically or radiographically detectable physical barrier in the eruption path, which is independent of the eruption process. It may be supernumerary teeth and odontogenic tumors or cysts. Impaction may also due to an unusual orientation of the tooth germ [1, 2]. Idiopathic factors was also mentioned as other factor that cause impaction.

In most cases, the impaction of maxillary first molars is usually associated with an ectopic eruption path at a mesial angle to the normal path of eruption. It may be the result of failure of the molar to upright from its mesial inclination during eruption [2].

Insufficient space in the dental arches has been also considered as an etiological factor for impaction of second lower molar. It could be explained by the fact that the increase in arch length does not synchronize with the eruption of the second molar, more commonly in the mandible than in the maxilla [1, 11, 12, 14]. The erupting mandibular second premolar and second molar may quite often compete for space in the posterior area of the arch. When this space is inadequate, the earlier erupting second premolar may result in the impaction of the second molar [15].

In addition, the developing third molar may also compete for space behind and above the second molar, resulting in its impaction. Its potential involvement in the second lower molar impaction was suggested, due to its altered position caused by dento-alveolar disproportion. As a result, many authors recommended to extract the third molars, as prophylactic measure, to allow for correct eruption of the second molars in teenagers. However, the relationship between impaction of lower second molars and ectopic third molars is often a controversial subject. All the more so, at the usual age of eruption of the second molar, the third molar cannot constitute a barrier in the eruption path [1, 5].

#### **4.2 Etiology of primary retention**

Primary retention is synonymous of “unerupted” and “embedded.” It is defined as cessation of eruption before gingival emergence, with neither a physical barrier in the eruption path nor being the result of (or and not due to) an abnormal position. The arrest of the eruption process occurs before the crown has penetrated the oral mucosa, and the non-resorbing bone occlusally of a primarily retained molar should be considered as a normal barrier in the eruption path [2, 16].

According to Raghoobar [8], primary retention is an isolated condition associated with a localized failure of eruption but no other identifiable local or systemic involvement. It may be caused by a defect in the eruption mechanism and is associated with a disturbance in the resorption of overlying bone. It is not due to an abnormality of the periodontal ligament; but the disturbance in the dental follicle constitutes the main etiological factor that fails to initiate the metabolic events responsible for bone resorption in the eruption trajectory. According to Raghoobar et al. [8], primary retention of permanent teeth is an isolated condition associated with a localized failure of eruption but no other identifiable local or systemic involvement.

### **4.3 Etiology of secondary retention**

Secondary retention is synonymous of “submerged,” “reimpaction,” and “reincclusion.” It refers to unexplained cessation of eruption after emergence, precisely after a tooth has penetrated the oral mucosa as reported by Raghoobar [8]. This abnormality occurs without the evidence of a physical barrier in the eruption path ectopic position, and it affects less frequently permanent molars than primary molars [2, 13, 16].

The etiology of secondary retention is not well understood. Trauma, infection, disturbed local metabolism, and genetic factors have been suggested as etiological factors. However, ankylosis is probably the main factor in its development. Raghoobar et al. [13] examined 26 secondary retained lower second molars, and they found that all of them had ankylosed areas. However, it is still not clear whether the state of ankyloses was a result of arrested eruption or if it was the primary cause resulting in arrested eruption.

All these factors present something of a diagnostic challenge to the clinician. It is important to distinguish between these three phenomena in order to understand the clinical features and to choose an adequate treatment.

## **5. Diagnostic approach**

The failure of eruption is an asymptomatic pathology. That means that it is usually a casual discovery and its diagnosis is generally made late. It may incite various pathologic conditions on the permanent dentition such as caries, periodontitis, pericoronitis, and risk of root resorption of adjacent teeth as well as the situations leading to the loss of permanent teeth, incomplete development of the alveolar process, shortening of the facial height, and occlusal disturbances. Thus, it is suggested that these abnormalities should be diagnosed and treated at an early age [3, 5].

Indeed, prompt diagnosis is essential in order to improve prognosis and to palliate the consequences of the failure of eruption of permanent molars. It involves full medical history, and it appropriates clinical and radiographic examinations which are sufficient to distinguish clearly between impaction, primary, and secondary retention [1, 2, 17]. As eruption time may vary between individuals, an appropriate follow-up of children with mixed dentition is required at 6-month intervals to manage their eruption pattern and dental development, especially in cases of posterior crowding and when molar retention is suspected [9].

### **5.1 Clinical analysis**

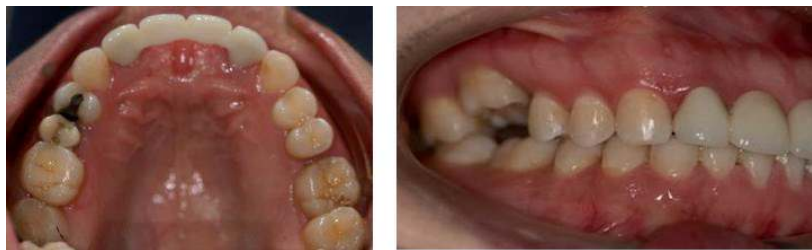This is a crucial step in the management of these abnormalities. It is important to raise the civil age, which must be correlated with dental age in order to claim a

possible eruption delay. A child is considered to be late toothed when the dental and civil ages differ by more than 2 years from the average values for permanent teeth.

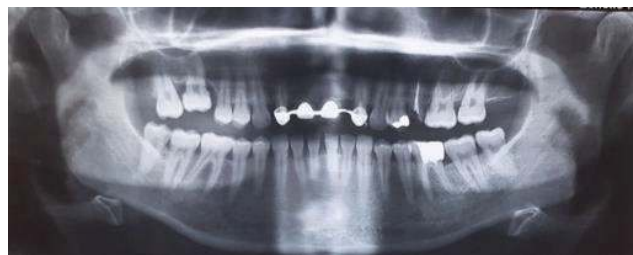
In addition, it is imperative to note on questioning a history of trauma or infection as well as a possible notion of heredity, emphasizing a family history of eruption failure or ankylosis affecting at least one primary tooth [8]. This facilitates the identification of the clinical form of the abnormality according to possible etiological factors.

The clinical examination cannot claim to make a reliable diagnosis of dental impaction or retention. Only radiographic analysis will make it possible to conclude this and above all to decide between the three clinical forms, namely, impaction, primary, or secondary retention.

Some signs, although rare, could be characteristic of particularly secondary dental retention. Indeed, clinically secondary retention is usually suspected on the one hand when a molar is in infra-occlusion at an age when the tooth would normally be in occlusion (**Figures 2 and 3**) This is because the adjacent teeth continue to erupt but the growth of the alveolar process in the affected area stops. On the other hand, the involvement of ankylosis might be detected with the percussion test [3].



**Figure 2.**  
*Intraoral photographs showing arrested eruption of the tooth 16 after gingival rupture associated with an infraocclusion in this side and growth cessation of the alveolar process.*



**Figure 3.**  
*The orthopantomogram revealed the absence of a physical obstacle and a vertical position of the tooth 16 related to secondary retention.*

However, particular attention should be focused on the number of teeth with delayed eruption, referring to the contralateral tooth. A 6-month delay in eruption of a permanent mandibular second molar compared with its contralateral or a 1-year delay in eruption of both molars should justify suspicion of molar retention and should indicate a need for further radiographic investigation [9].

The involvement of ankylosis might be detected with the percussion test and radiographic evidence of the periodontal ligament obliteration. The scanner or the cone beam computed tomography are the only tools which may identify the ankylosis' diagnosis [3].

## 5.2 Radiographic analysis

Unerupted molar is often detected in a routine panoramic radiograph during pedodontic or orthodontic evaluation and treatment planning. But, it is usually not



the main reason for referral to the orthodontist. Early detection and treatment is imperative to avoid possible complications and to eliminate the need for advanced orthodontic and surgical treatment [15].

The radiological examination must first conclude that the germs of unerupted molars are present. Also, as reported by Vedtofte [12, 18], it should also focus on registration of dental abnormalities in tooth retained and dentition in general such as:

- Root deflection dilacerations
- Taurodontism
- Invagination
- Resorption or tooth decay in adjacent primary or permanent teeth (primary molar or second premolar in case of impacted first molars, and first molar in case of impacted second molar)

Vedtofte and Andreasen [18] found a high prevalence of dens invagination and taurodontic in second lower molars with arrested eruption (**Figure 4**). They suggested that there was an association between morphological deviations and periodontal membrane malfunction, the latter causing eruption disturbances. Root dilacerations were also observed in arrested eruption upper and lower molars but they are not related to a particularly deep bony position of the molar. It could explain the association between root abnormalities and eruptive disorders in permanent molars [12].

In addition, some measurements must be recorded on the orthopantomogram as the angulation of impacted tooth and depth of retention. The inclination axis of the molars is measured from tracing long axis of unerupted teeth and adjacent teeth, perpendicular to the tangent to the tips of the cusps. The angle between these lines is measured for each side of the jaw in order to conclude an average value [9, 11, 12] (**Figure 5**).

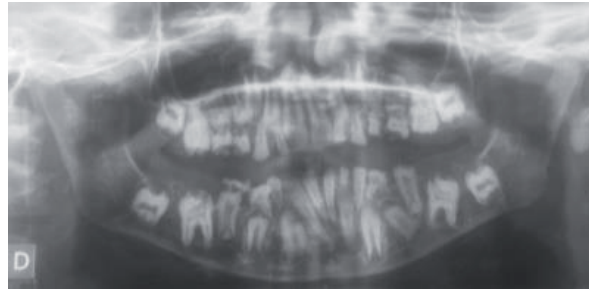
The degree of non-eruption could be evaluated radiographically in millimeters of bone, from the alveolar ridge to the central fossa of the unerupted molar or vertical distance between distal marginal ridge of the first molar and mesial marginal ridge of the impacted second molar [1, 3] (**Figure 6**).

Because permanent teeth may fail to erupt either as a result of mechanical obstruction or disruption to the eruptive mechanism itself [2], both clinical and radiographical diagnosis approach should conclude in an impaction, primary, or secondary retention on the basis of the various etiological factors, which are as follows:

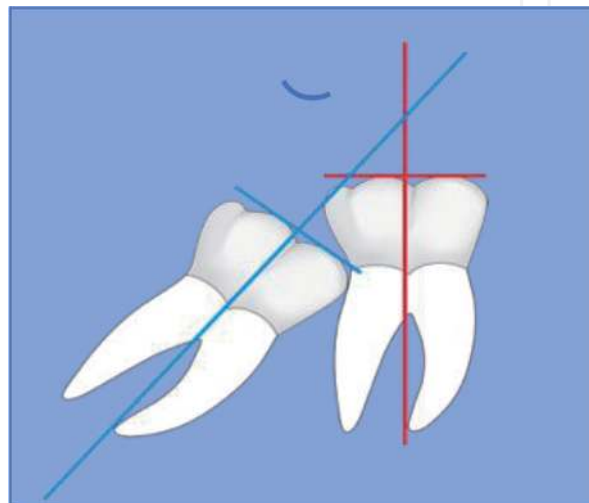
- The detection of mechanical obstruction and posterior crowding typical of molar impaction;
- The root growth stage;
- The signs of ankylosis characteristic of secondary retention.

### *5.2.1 Radiological characteristics of impaction*

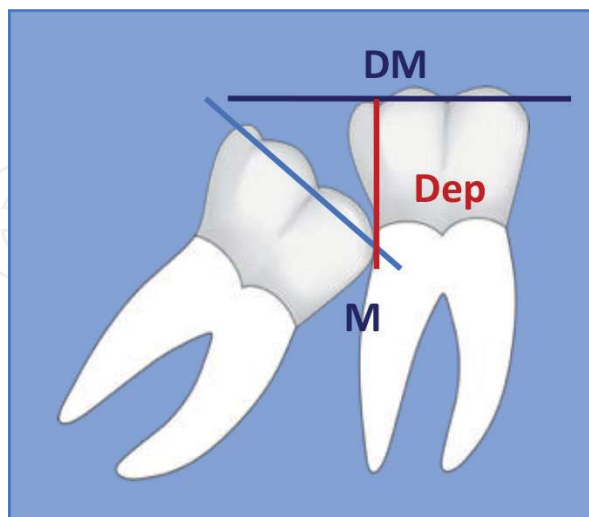
The orthopantomograph reveals, in this specific case, odontogenic cysts, odontoma, supernumerary teeth, or signs of insufficient space in the posterior side



**Figure 4.**  
*Panoramic radiograph of a 13-year-old patient showing a delayed eruption of first and second permanent molars with intrapulpal calcifications and taurodontism of the first lower permanent molars and second lower premolars. We also note the reinclusions of the second temporary molars.*



**Figure 5.**  
*Readapted from [11, 12]. Registration of angulation of impacted teeth from the angle between long axis of first and second lower molars. Angle greater than  $40^\circ$  means mesial inclination. Angle between  $40$  and  $-20^\circ$  means vertical position. Angle less than  $-20^\circ$  means distal inclination.*



**Figure 6.**  
*Readapted from [3]. Registration of impacted teeth depth from distal marginal ridge of the first molar ( $DM_1$ ) to the mesial marginal ridge of the impacted second molar.*

of dental arch as malposition of the tooth germs of the third molars overlapping with lower second molar.

The great majority of mandibular second molar impaction was associated with a degree of mesial angulation which could be radiographically seen as an oblique

or even horizontal position of the tooth. A very rare case of an inverted impacted second molar where its crown was directed toward the lower border of the mandible was reported [15].

Nevertheless, when the first molar is affected, the radiographs show a mesial inclination and atypical resorption of the distal surface of the adjacent primary second molar. The main sign is the long axis which is not parallel to the normal eruption path [2].

### 5.2.2 Radiological characteristics of primary retention

Because the arrest of the eruption process occurs before the crown has penetrated the oral mucosa, the crown is often covered by bone and mucosa. Thus, the non-resorbing bone occlusally should be considered as a normal barrier in the eruption path [2, 16].

Primary retention is defined as an incomplete tooth eruption despite the presence of a clear eruption pathway. Radiographically, the molar is normally oriented in its eruption path, and roots are deeply situated and sometimes completely formed. The growth of roots has occurred apically due to bone resorption around the radicular portion [4, 16].

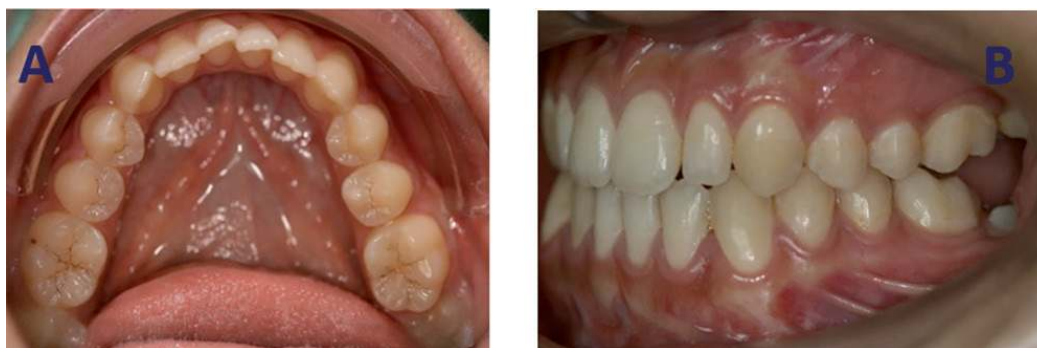A follow-up of at least 6 months is necessary to detect radiographically whether the tooth is showing any eruptive movement or not, in order to make a differential diagnosis between primary and secondary retention.

### 5.2.3 Radiological characteristics of secondary retention

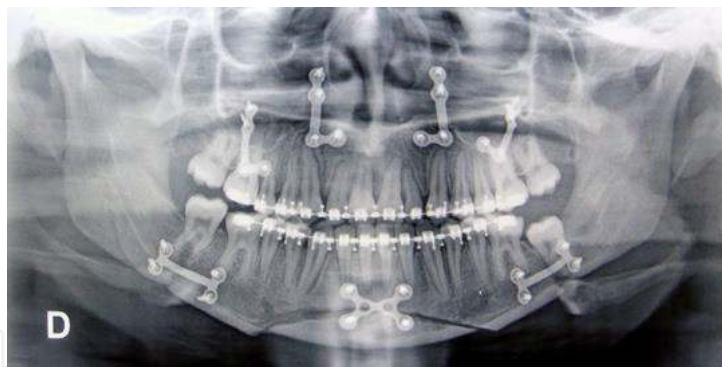
Ankylosis was suggested to be the main etiological factor in secondary retained permanent teeth. Histological study conducted by Raghoobar compared 26 secondarily retained molars removed in children group (mean age =  $16.2 \pm 3.9$  years), with six normally erupted molars which were removed for orthodontic or prosthetic reasons [13]. The author found areas of ankylosis along the roots of all secondary retained molars located at the bifurcation and interradicular root surface in 81% of the cases.

Thus, it is difficult to specify the diagnosis of such disturbance only from orthopantomographs. Intraoral periapical radiographs allows to identify a periodontal obliteration and hypercementosis. The computed tomography scan represents supplemental examination to bring a definitive diagnosis of ankylosis [3].

Another factor in favor with the diagnosis of secondary retention is tooth position. Wellfelt maintains that ankylosis is often suspected in vertically positioned teeth (**Figures 7 and 8**).



**Figure 7.** Intraoral photographs (A) before treatment and (B) 2 years after orthodontic and surgical treatment, showing arrested eruption of 37 after gingival rupture, with no movement of this tooth related to secondary retention.



**Figure 8.**  
*Post-treatment panoramic radiograph revealed vertical position of retained tooth.*

Finally, primary and secondary retention could be differentiated considering the stage during which the molar stops the eruption process [2]. In addition, the mesial angulation of the molars is characteristic of the impaction, whereas in the primary and secondary retention, tooth is rather vertical.

## 6. Treatment

The diagnosis characteristics of eruption disorders are different but the treatment approaches are identical in some cases. Primary and secondary retention of permanent molars reflects disturbances in a particular stage of the eruptive process, while impaction is due to a physical barrier or an abnormal tooth position and thus not directly related to a particular eruptive stage. It is important to distinguish between these three phenomena in order to understand the clinical features and to choose a suitable treatment [2, 8].

### 6.1 Decision-making factors of treatment

Multiple local factors are involved in the failure of eruption and influence its prognosis and treatment. We cite lack of space in the arch, dental anatomy, inclination axis, stage of the root formation, and the depth of the molar. Although their exact roles have not been yet established. The age of the patient is probably a key factor in the evolution of the case.

Several entities are an indicator of retention's severity and could influence the prognosis and treatment protocol of unerupted permanent molars. The following variables could be mentioned [1, 3]:

- Dental inclination,
- Degree of non- eruption,
- Stage of root formation,
- Age.

The inclination axis of the molars has certainly an impact on clinical treatment results [1]. Wellfelt [1] reported that the mesioangular inclination was most successfully treated because the ankylosis is often suspected in vertically positioned teeth, thus in secondary retention.

The degree of non-eruption or depth of the impaction seems to be a less decisive factor in the evolution than the stage of root formation. In fact, it was reported that when roots of the unerupted tooth are completely formed, the chances of successful treatment decrease [1]. Furthermore, Fu et al. found, in their study conducted on a Taiwanese population, that the impacted depth was highly and positively correlated with the initial uprighting period [3].

This could explain that patient's age is considered as a key factor in the prognosis of this disorder. Most pediatric population studies show that resulting malocclusions and abnormalities in adjacent and opposing teeth are frequent and start at very early ages. [5] Furthermore, we have mentioned that the age affects certainly the initial uprighting period, but it has a small impact on the performance and outcomes of the technique. Thus, these teeth malposition should be diagnosed and treated at an early age. Fu et al. suggested that there was a statistically significant relationship between poor evolution of the unerupted molar and the following factors: age over 14 and root formation of the unerupted molar in its last stages [3].

Finally, both diagnosis and treatment planning should be placed into the perspective of the patient's age, the stage of eruption, as well as of factors like the patient's needs and self-image [2]. Even if the disturbances do not occur frequently, it is important to develop an early diagnosis in order to start the treatment at the optimal time, between 11 and 14 years, when root formation is incomplete [3, 6].

## **6.2 Treatment modalities**

Eruption disturbances may manifest clinically and radiographically as impaction, primary retention, or secondary retention. The treatment protocol for its management is based on the type of eruptive abnormality and the age of the patient. Treatment options include observation, surgical exposure or repositioning, orthodontic uprighting, and extraction of the unerupted molar. Each modality has its indications, contra-indications, advantages, and disadvantages.

Generally, as stated by Andreasen [8], the active orthodontic and/or surgical treatment is indicated in cases of impacted ectopic erupting teeth and primary retention. However, a primary observation period seems to be required before any intervention to confirm diagnosis through a radiographical follow-up. Spontaneous eruption into normal occlusion could occur in rare cases. Abstention is recommended in cases of secondary retention due to ankylosis, or deeply impacted lower second molars. Extraction may be the norm in case of failure of teeth repositioning.

Due to low frequency of impacted first molars, numerous studies and case reports are available regarding the clinical management of second molar disturbed eruption. All approaches and techniques can also be applied to unerupted first molars despite their low incidence.

### *6.2.1 Observation*

Kavadia and others underline the importance of tight control of impacted lower second molars. They suggest that active treatment should only be considered after an observation period of at least 12 months exclude the possibility of self-correction [9].

So when the identified etiology is an obstacle, the early removal of the barrier usually allows the molar to erupt spontaneously.

Furthermore, abnormal position of the germ of a third molar may form a barrier causing impaction of the second molar. The recommended treatment is removal of the third molar at the age of 11–14 years in combination with a thorough follow-up of the eruption of the second molar [2]. In other cases, some clinicians advocate removal of the second molar allowing eruption of the third molar at its position [14].

Once the chance of self-correction has been ruled out, dentists should discuss with patients and parents the various treatment options for the impacted molars, which may include [9]:

- Orthodontic uprighting
- Surgical repositioning
- Extraction of the impacted second molar to allow the third molar to drive mesially
- Extraction of the impacted second molar and transplant of the third molar into the extraction site.

### *6.2.2 Orthodontic uprighting*

Generally, as stated by Andreasen [8], the active orthodontic treatment is indicated in cases of impacted ectopic erupting teeth and primary retention. Orthodontic approach is important to provide a good occlusion and to reduce the risk of caries and periodontal disease and can be performed with or without extraction of the adjacent third molar. However, in cases of extreme horizontal impaction or widely diverging roots, orthodontic uprighting of permanent molars is contraindicated [2, 15].

The optimal moment for uprighting is when two-thirds of the roots have been formed, between 11 and 14 years old for second molar. Molars with fully formed roots have a poor prognosis [2].

Beyond age, orthodontic modalities are depending of mesial tipping and depth of concerned teeth. So, when orthodontics is indicated, an efficient mechanics plan is required [13]. Numerous methods can be considered:

- Conventional appliances
- Distalization segment wire
- Temporary skeletal anchorage.

All of these methods, however, have limitations, especially in the approach of deeply impacted teeth.

#### *6.2.2.1 Conventional appliances*

When a second molar is slightly mesially angulated with a sufficient emerging area, several devices have been suggested in the literature to correct simply this malposition such as separating elastic or brass ligature wire between tipped teeth and neighboring one. These artifices operate as a spring, relieving contact between the teeth and allowing “self-correction” and eruption [15].

Interarch vertical elastics and a removable appliance with an uprighting spring have been also reported [4].

The correction of this abnormality can also be done simply by including the impacted molar in the orthodontic treatment from the first stage of alignment and leveling of the orthodontic treatment. A tube is then bonded to the vestibular surface of the molar, which will be engaged in the continuous arch. Alignment and distalization will be ensured by superelastic arches and a push coil spring

(**Figure 9**). A variant of the same device can be proposed; the superelastic wire used for alignment and leveling of the teeth is curved distally of impacted molar which is engaged in the tube and bended on mesial (**Figure 10**).

Such methods might require considerable treatment time with the risk of extending the overall duration of orthodontic treatment. Indeed, since the arch sections cannot change, the leveling of the dental arches is delayed. This widely justifies the use of fixed auxiliaries as an efficient alternative.

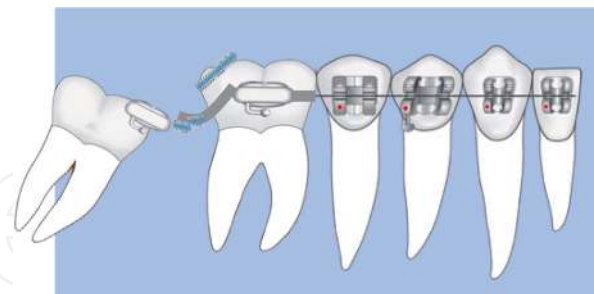
#### 6.2.2.2 Distalization segment wire/auxiliary spring fixed

A button, mini tube, or eyelet button is usually bonded on the visible area of the tooth. An auxiliary segment is constructed of flexible wire nickel titanium, copper Ni Ti, or titanium molybdenum alloy (TMA) with loop. This cantilever is generally placed after leveling of the dental arch, which is then used as stable unity for distalization of impacted tooth. In fact, molar uprighting requires good anchorage control, and subsequently, a full-arch fixed appliance is necessary to protect from undesirable tooth movements [19]. Continuous 0.019 × 0.025 stainless steel wire from first molar to second premolar or first molar is recommended as an anchorage unit.

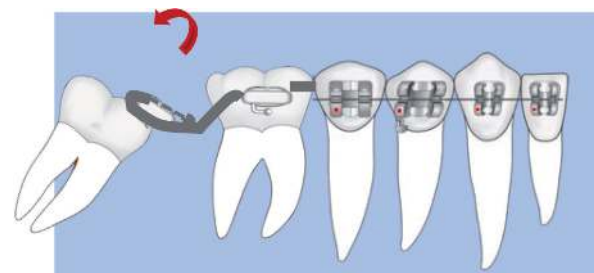
Then, NiTi wire can be used to upright the tooth. Finally, the tube is bonded to introduce the tooth into the conventional wire to complete leveling and finish treatment [14, 15, 20].

Various patterns have been revealed in the literature, from the simplest to the most complex, taking advantage of the elastic properties of wire alloys.

The 0.016 × 0.022 Ni-Ti or 0.016 × 0.025 Cu Ni-Ti may be used to distalize angulated molar. The segment wire is inserted between the retained molar and the neighboring tooth on the arch. Due to its superelasticity, the wire is curved and then bonded to the occlusal face of the adjacent tooth. A moment of force is generated resulting in move of the molar to the distal (**Figures 11 and 12**).



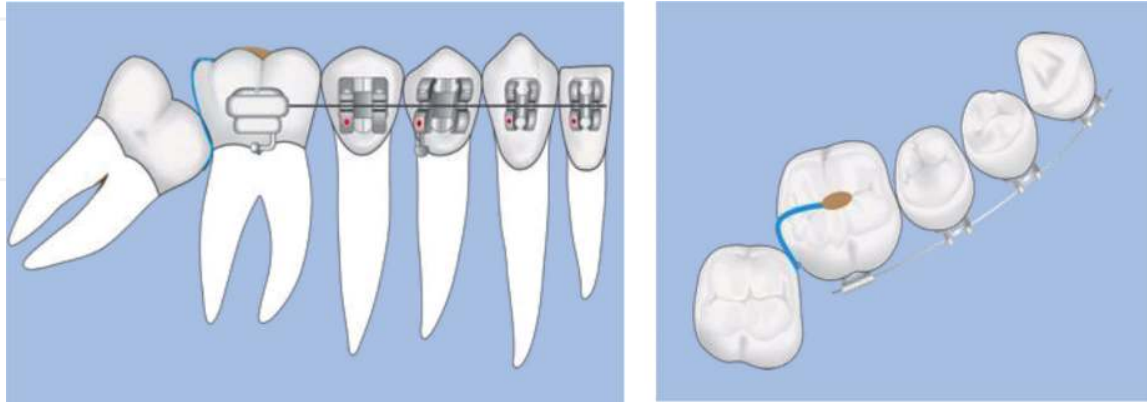
**Figure 9.**  
*Association of superelastic wire and coil spring between first and second lower molars.*



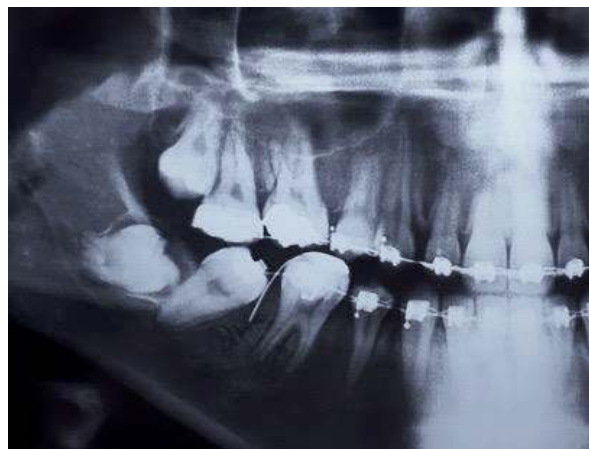**Figure 10.**  
*Continuous superelastic wire curved in distal of second lower molar then introduced into the tube to achieve its distalization.*

Like Fu et al. [4], the same sections of Ni-Ti or copper Ni-Ti can be used to upright orthodontically the mandibular second molar. The sectional wire is here ligated on the continuous wire that served to align and level the dental arch (**Figure 13**).

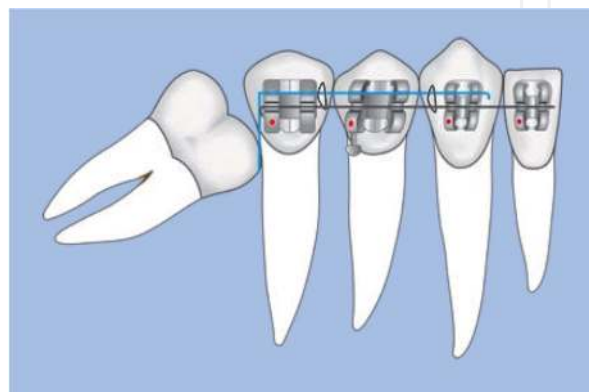
In other retrospective study, Fu et al. [3] described the pole arm appliance as an effective treatment modality and success predictable for impacted second lower molar.



**Figure 11.**  $0.016 \times 0.022$  Ni-Ti or  $0.016 \times 0.025$  Cu Ni-Ti sectional wire, placed between first and second retained molars, is occlusally curved and bonded on occlusal face of first molar aligned on the arch.



**Figure 12.** Right quadrant of a panoramic radiograph illustrating the placement of the  $0.016 \times 0.022$  Ni-Ti sectional wire between first molar (46) and lower retained second molar (47).



**Figure 13.**  $0.016 \times 0.022$  Ni-Ti or  $0.016 \times 0.025$  Cu Ni-Ti sectional wire, ligated to stainless steel continuous arch wire and then introduced between second premolars and impacted first molar, produces a sufficient moment to distalize the impacted tooth.



The pole arm is constructed of  $0.016 \times 0.022$  inch titanium molybdenum alloy (TMA) wire (**Figure 14**). The distal part is inserted from lingual side under the contact point, between first molar and second angulated molar, then it is pushed buccally. The uprighting spring is curved to the mesial dental arch and ligated to the anchor wire. Finally, the lingual extremity is fixed with composite resin on the occlusal surface of the first molar (**Figure 15**). The reactivation of the pole arm is recommended every 6 weeks, simply by lifting the buccal arm occlusally.

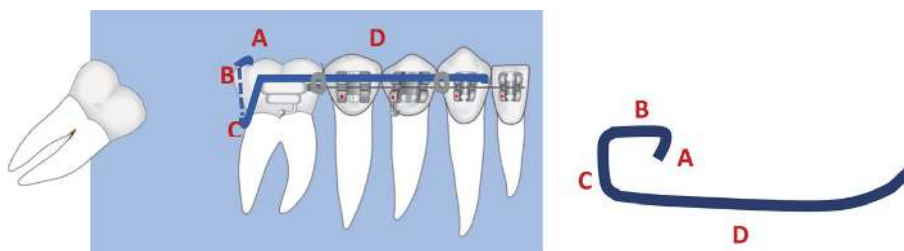
Majourau et al. [14] proposed  $0.017 \times 0.025$  TMA “cemented springs” whose distal part is supported by a stainless steel button bonded to disto-occlusal surface of the retained molar. The auxiliary wire is inserted from the distal of the first molar auxiliary tube. Then, it is curved to give it the configuration of loop. The spring is activated through a combination of the gingival loop form and open coil inserted between a loop and the auxiliary molar tube (**Figure 16**).

All the appliances aforementioned have the advantage of avoiding early bonding of impacted molars as well as the need of surgical exposure of sufficient surface for the bonding.

Then, when the impacted second molar had been uprighted to some degree, a tube can be bonded to it for further alignment.

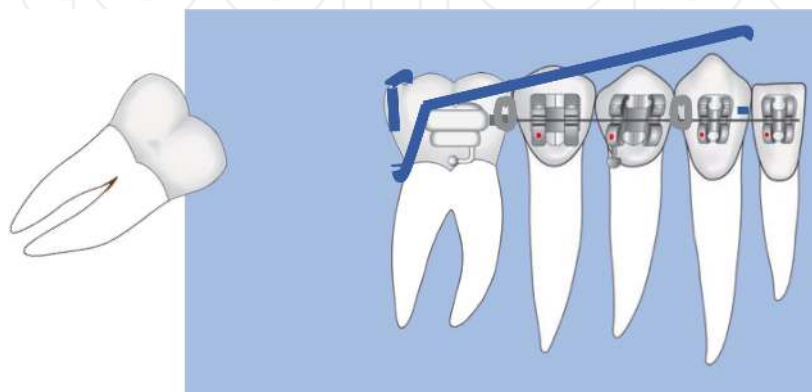
TMA uprighting spring, with or without helical loop is needed to finish distal displacement of molar and to produce eruptive force to bring teeth into occlusion with their upper opponents.

Majourau [14] reports using  $0.017 \times 0.025$  TMA cantilever spring, which is engaged in the second molar tube and hooked distally to the canine. The intrusive



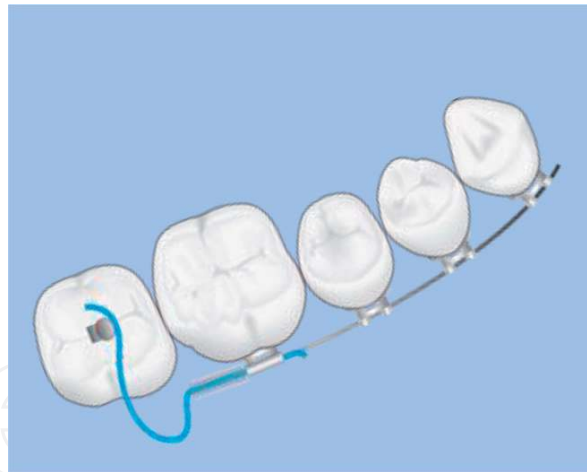**Figure 14.**

The pole arm uprighting spring of  $0.016 \times 0.022$  TMA is used. The lingual extremity is bonded on occlusal surface of adjacent tooth; then, the arm is introduced from lingual under contact point. The buccal part is curved and ligated to anchor continuous arch wire (readapted from [3]).

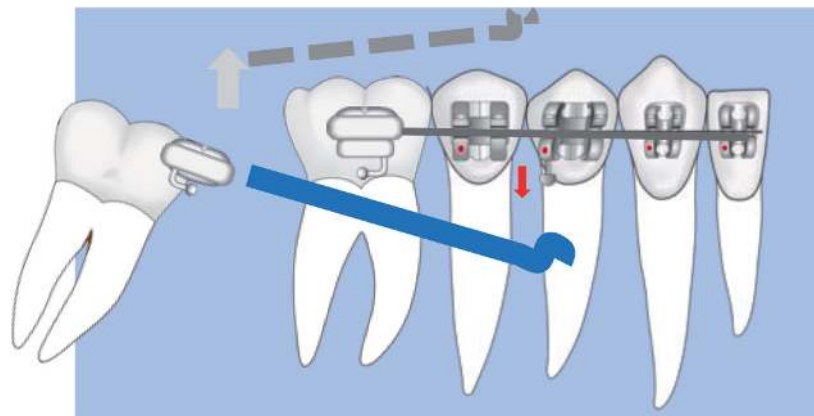


**Figure 15.**

The activation of pole arm uprighting spring is ensured by a plicature leading the mesial arm occlusally (readapted from [3]).



**Figure 16.** Illustrative diagram of 0.017 × 0.025 TMA sectional wire associated with open coil to upright impacted the second lower molar. TMA spring is bent around the button, then configured as loop, and finally inserted from distal in accessory tube of the first molar. Continuous 0.019 × 0.025 stainless steel wire from first molar to first molar is used as an anchorage unit (readapted from [14]).



**Figure 17.** Illustration of eruptive force produced by TMA cantilever spring without loop. This sectional wire is required to achieve impacted molar repositioning in correct occlusion (readapted from [14]).

force was negligible since a continuous stiff stainless steel wire consolidated the lower arch from first molar to first molar (**Figure 17**).

Many others suggested the use of tip back cantilever of 0.017 × 0.025 TMA wire with loop [15, 21, 22]. It is a long cantilever which gives a high moment-to-force ratio and produces effects on the tooth in three planes, mainly in the mesiodistal direction and the vertical direction providing both distal crown tipping and molar extrusion (**Figure 18**).

### 6.2.2.3 Temporary skeletal anchorage

Orthodontic treatment methods, with continuous or segment wire, for molar uprighting have some disadvantages, including extrusion of the target molar, unwanted reciprocal movement of the anchorage units, need for bulky appliances, and longer treatment time. The development of orthodontic miniscrew implants provided solutions to most of these problems [19].

Skeletal anchorages have some advantages in that they reduce the side effects formerly associated with dental anchorage and provide vertical and distal traction

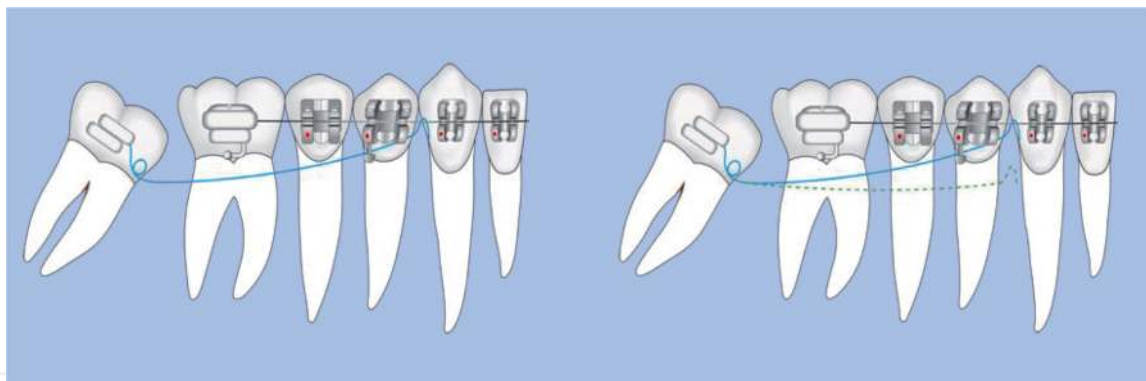
forces simultaneously with proper line of action and moment. It is also beneficial for obtaining [19] [23] Thus, orthodontic miniscrews have a major impact on reducing the overall treatment time unlike conventional treatment.

Moreover, they simplify the design of orthodontic devices. All the abovementioned devices can be used in combination with it to avoid the need for dental anchoring. Depending on the situation, the skeletal anchor can be used directly; the minivis serves as a docking point for the sectional wire with direct application of an appropriate force system. Lee et al. suggest uprighting second molar into two steps, using an open coil spring and a stainless steel uprighting spring (**Figures 19 and 20**) [19].

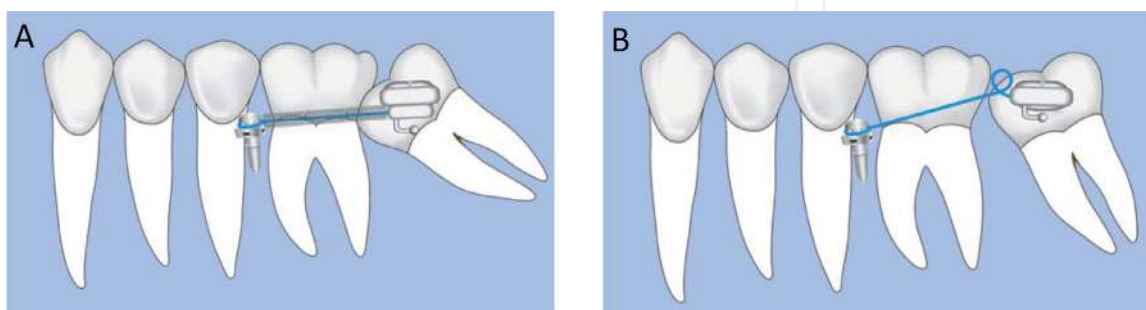
Conventional orthodontic methods are often the best alternative to extraction or surgically repositioning of the first and second permanent molars. It produces certainly excellent outcomes, but could not be successfully predicted or may be contraindicated for horizontally position, deeply impaction or molars with gross displacement [9, 15, 19]. In such challenging cases, a combination of surgical and orthodontic treatment is appropriate [2, 4].

### 6.2.3 Surgical approaches

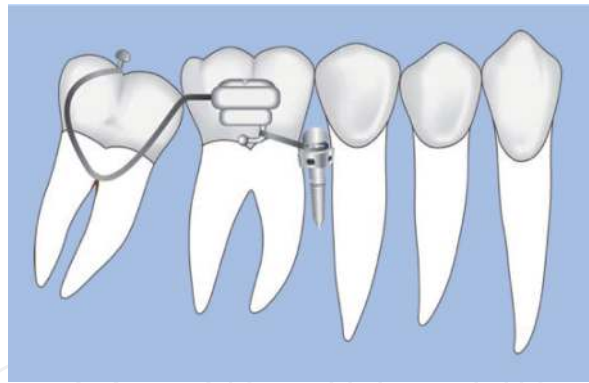
Surgical approaches of unerupted permanent molars included surgical exposure for orthodontic uprighting and traction into their correct position in the arch, as well as challenging treatment options of surgical repositioning. It consists essentially of uprighting and repositioning of the impacted molar, eventually including extraction of the third molar [15] [20]. Posterior available space should be analyzed



**Figure 18.** Diagram of tip back cantilever: It is a long uprighting spring of  $0.017 \times 0.025$  TMA. The activation force is directed to the occlusal (readapted from [15, 21, 22]).



**Figure 19.** Miniscrews used as direct anchor with segmental wire and coil spring to distalize and extrude the second lower molar. In the first step (A), the distalization is ensured by  $0.016$  stainless steel wire and open coil spring. In the second step (B), tip back moment is delivered from  $0.016 \times 0.022$  in. Stainless steel wire spring to upright impacted molar (from Lee et al., readapted from [19]).



**Figure 20.**  
*Miniscrews used as indirect anchor to reinforce dental stable unit then with tip back cantilever to extrude it.*

before planning orthodontic and surgical traction, to prevent periodontal risks. Removal of the third molar often completes this procedure, and more rarely, the second molar when the first one is impacted. Undoubtedly, analysis of anatomic location, desired eruption path, and available space should precede the uprighting process for a favorable outcome [19].

#### 6.2.3.1 Surgical exposure

In cases of horizontally or deeply impaction, orthodontics alone cannot straighten the molar because of the limited access. A surgical exposure is required following by orthodontic traction or luxation.

Magnusson et al. in their study found that [24]:

- Surgical exposure was the most successful treatment and the best choice of treatment, with a success rate of 70%.
- The success rate was 50% when surgical exposure was combined with extraction of the third molar and/or luxation of the second molar.
- Surgical exposure of the second molar, with or without extraction of the third molar and/or luxation of the second molar, seems to result in the most successful treatment in both jaws.

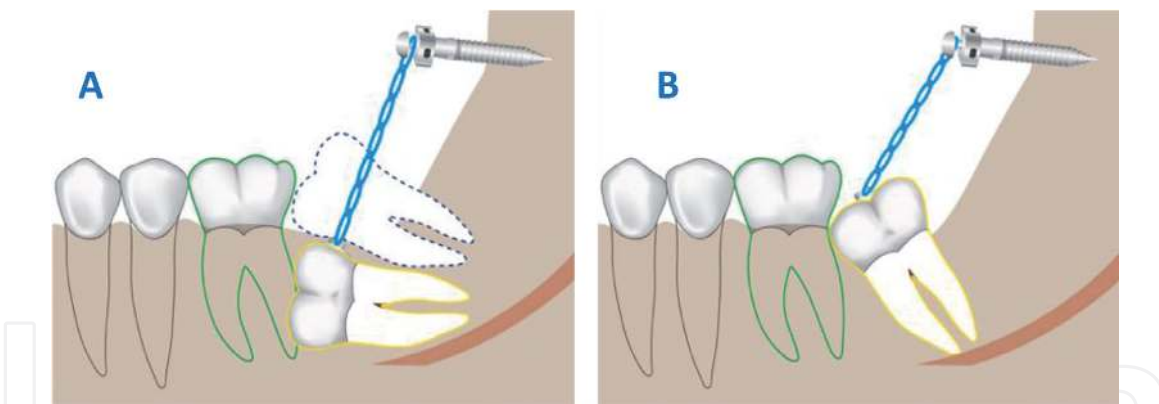
##### 6.2.3.1.1 Surgical exposure and orthodontic traction

It consists of exposure and uncovering the crown, followed by bonding an orthodontic attachment. Temporary skeletal anchorage is the appropriate and efficient means to upright and tract the tooth in its ideal position [15, 23].

Kim [23] suggested the use of 1.3–1.2 mm × 8 mm mini screws in the retromolar area following extraction of the third molar. Traction is initiated on the day of surgery with elastic threads that were replaced every 4 weeks.

Chang [25] reported a simple, effective, and expedient mechanics for managing horizontally and deeply impaction of second lower molar in only 4 months. 2 × 14 mm stainless steel bone screw is positioned superiorly in ramus under local anesthesia. He proposed to (**Figure 21**):

- First, remove all obstructions to eruption, as ectopic position of the third molar follicle



**Figure 21.**

*Illustration of surgical exposure and traction of second lower molar through bone screw. The button is bonded to the accessible surface (A) and then moved if necessary (B) so as to obtain a sufficient amplitude of traction on the minivis. 2 × 14 mm stainless steel bone screw is inserted into the ascending ramus, and power chain is connected between attachment and screw (readapted from [25]).*

- Expose surgically and luxate the lower second molars to rule out an eventual ankylosis. The covered bone is removed down to the level of the cementoenamel junction for optimal molar uprighting.
- Bond button or eyelet on distal surface and then connect elastic chain from attachment to bone screw before closing soft tissue with interrupted sutures to control blending.

#### 6.2.3.1.2 Surgical exposure and luxation

Luxation is an effective technique with good long-term prognosis. Such approach finds its major indication in favorable impacted molars before complete apical root edification. Indeed, it has been reported that molars luxated prior to complete root formation erupted spontaneously and continued their normal root development.

The potential risks of luxation include pulpal devitalization and root fracture, although a prophylactic endodontic treatment of the luxated molar is not recommended.

During the 1916s, luxation has been described to be used successfully in ankylosed permanent molars that are typical of secondary retention, although luxation seems to promote new areas of ankylosis rather than breaking bony connections [2].

The prognosis seems to be better than that of dental transplant because the tooth is not removed from its socket and the apical blood vessels are not damaged.

#### 6.2.3.2 Surgical repositioning

It is a simple technique which produces fast results; it seems to be the most convenient procedure when patient compliance is minimal, when impacted teeth have limited access or failed to respond to orthodontics methods, or for angle of inclination of less than 75° [9, 15, 26]. Nevertheless, there is a risk of pulp necrosis, root resorption, and ankylosis [9].

Several authors suggested that this procedure usually lead to predictable successful results if root formation is not completed, usually between the ages of 11 and 14. According to Botton [17], if surgery is performed too soon, then the tooth may be unstable and may shift from its position. If performed too late, then there is risk of root fracture and possible disruption of blood supply leading to pulpal necrosis [17] [24].

Removal of the third adjacent molar is often necessary to make surgical uprighting easier. In addition to that, surgically tipped molar should be stabilized for few weeks.

Boyton et al. [17] Kravitz et al. [26] describe the stages of surgical uprighting of second lower molar. After intrasulcular incision from the distobuccal line angle of the first molar to posteriorly the external oblique ridge, a full-thickness mucoperiosteal flap is raised to expose the second and third molars if it is present. Then, distal and buccal bone of molar is removed to expose the cement-enamel junction avoiding any contact with the cementum and periodontal ligament fibers that may cause external root resorption.

The surgeon uses steady and gentle force with straight elevator to elevate the tooth distally and prevent root fracture. Sometimes, the surgeon removes additional distal bone to perform the molar uprighting. When the occlusal surface of impacted molar is approximately level with the occlusal plane, the patient is instructed to bite down gently to ensure that the molar is just below the occlusal plane to prevent occlusal trauma. The site should be irrigated with copious amounts of normal saline and then closed with sutures. The attached gingiva should be kept intact and positioned appropriately to ensure a healthy periodontal environment for the newly positioned second molar.

Some recommended bonding a tube to the molar as soon as it is repositioned. For others, an intact lingual and buccal plate or a periodontal dressing prevents the tooth from migrating buccally or lingually [17, 26].

According to Boyton, no additional autogenous bone or bone substitutes are needed to stabilize the tooth. Other authors [27] advocate the use of absorbable gelatin sponge or autogenous alveolar bone to stabilize the repositioned second molars.

An immediate postoperative Panorex is recommended. The follow-up includes a 1-week postoperative appointment and then another appointment in 6 months for a repeated Panorex. Orthodontic treatment should begin 1–2 weeks after surgery, with a mandibular arch-wire extended through the second-molar bracket for stabilization.

## **7. Extraction**

Surgical extraction of unerupted permanent molar is indicated when exposure, luxation, and orthodontics treatment fail, in the presence of a pathological process, or when prognosis is poor because of fully formed roots or extremely unfavorable position [2, 15].

Extraction as an alternative procedure of retention treatment can be considered in two different approaches as follows:

- Extraction of retained or impacted second molar with the intention of replacing it with the third molar. The third molar drift mesially when it is at low Nolla stage from 5 to 8. Nevertheless, success of this treatment depends on the eruption path of the third molar which could be unpredictable [5, 9, 15]. Magnusson et al., in their study evaluating the outcome after treatment and without treatment of retained second molars, found that treatment with removal impacted molar replaced with the third molar was the least successful both in the maxilla and mandible. They reported that few molars that did erupt were all malpositioned with a risk for elongation of the antagonist because of the delayed eruption of third molar [24].

- Extraction of the impacted second molar followed by immediate transplantation of retained molar or third molar into the extraction site. It is technically demanding and carries a risk of pulp necrosis, root resorption, and ankylosis [9, 15, 24].
- Both transplantation and surgical repositioning were suggested as invasive techniques because of the deeply impacted positions with high risk of neurovascular damage, mandibular fracture, or the deep infrabony defect on the distal surface of adjacent teeth [24].

## **8. Conclusion**

The eruption failure of first and second permanent molars is rare and asymptomatic. This disturbance is often detected in a routine panoramic radiograph during pedodontic or orthodontic evaluation and represents a real diagnostic and therapeutic challenge for the practitioner.

Considering the main etiological factors, three clinical forms can be distinguished: impaction, primary, and secondary retention. Therefore, it is crucial to diagnose this abnormality early for an optimal treatment time and outcomes, as well as reduction of dental and periodontal complications.

Its management is considered difficult and unpredictable, and there is no clear standard solution. Despite observation, abstention, or extraction of unerupted permanent molars, several orthodontic and surgical methods for uprighting impacted molars was reported. All of the methods have specific indications, advantages, and disadvantages depending of clinical form, retention depth, stage of root formation, and age of patient.

If the prognosis of orthodontic and/or surgery repositioning of impacted and primary retained molars is favorable, the treatment of secondary retention seems to depend on the age of the patient and the extent of infraocclusion and malocclusion.

The major treatment concern of secondarily retained molars is that these molars cannot be moved orthodontically due to an abnormal periodontal ligament. By contrast, orthodontics or combined surgical-orthodontic approach is a major modality in treatment of impacted teeth as these molars often have an abnormal position in the eruption path. Primarily retained molars can also be moved orthodontically, but this is often not necessary because of the normal position in the eruption tract.

## **Acknowledgements**

The authors would like to express their gratitude to all the specialists in the orthodontics and pedodontics department at the Ibn Rochd University Hospital of Casablanca for their kind contribution to the work. Their special thanks go especially to Dr. N. Falah, Z. El Jalil, S. El Kaki, A. Moutawakil, and L. Bouchghel.

## **Conflict of interest**

The authors declare that they have no conflict of interest.

IntechOpen

### **Author details**

Sanaa Alami<sup>1\*</sup>, Hakima Aghoutan<sup>1</sup>, Meriem Bellamine<sup>2</sup> and Farid El Quars<sup>1</sup>

1 Faculty of Dental Medicine, Department of Dento-facial Orthopedic,  
Hassan II University of Casablanca, Morocco

2 Department of Orthodontics, Casablanca Hospital center, Morocco

\*Address all correspondence to: [sanalami1@yahoo.fr](mailto:sanalami1@yahoo.fr)

### **IntechOpen**

© 2019 The Author(s). Licensee IntechOpen. This chapter is distributed under the terms of the Creative Commons Attribution License (<http://creativecommons.org/licenses/by/3.0>), which permits unrestricted use, distribution, and reproduction in any medium, provided the original work is properly cited. 



## References

- [1] Palma C, Coelho A, González Y, Cahuana A. Failure of eruption of first and second permanent molars. *Journal of Clinical Pediatric Dentistry*. 2015;27:239-245. DOI: 10.17796/jcpd.27.3.dm4v13441p161928
- [2] Raghoobar GM, Boering G, Vissink A, Stegenga B. Eruption disturbances of permanent molars: A review. *Journal of Oral Pathology and Medicine*. 1991;20:159-166. DOI: 10.1111/j.1600-0714.1991.tb00913.x
- [3] Fu PS, Wang JC, Wu YM, Huang TK, Chen WC, Tseng YC, et al. Impacted mandibular second molars. A retrospective study of prevalence and treatment outcome. *The Angle Orthodontist*. 2012;82:670-675. DOI: 10.2319/102111-656.1
- [4] Fu PS, Wang JC, Chen CH, Huang TK, Tseng CH, Hung CC. Management of unilaterally deep impacted first, second, and third mandibular molars. *The Angle Orthodontist*. 2012;82:565-571. DOI: 10.2319/062411-409.1
- [5] Valmaseda-Castellón E, De-la-Rosa-Gay C, Gay-Escoda C. Eruption disturbances of the first and second permanent molars: Results of treatment in 43 cases. *American Journal of Orthodontics and Dentofacial Orthopedics*. 1999;116:651-658. DOI: 10.1016/S0889-5406(99)70200-3
- [6] Bondemark L, Tsiopa J. Prevalence of ectopic eruption, impaction, retention and agenesis of the permanent second molar. *The Angle Orthodontist*. 2007;77:773-778. DOI: 10.2319/072506-306.1
- [7] Cassetta M, Altieri F, di Mambro A, Galluccio G, Barbato E. Impaction of permanent mandibular second molar: A retrospective study. *Medicina Oral, Patología Oral y Cirugía Bucal*. 2013;18:564-568. DOI: 10.4317/medoral.18869
- [8] Ahmad S, Bister D, Cobourne MT. The clinical features and aetiological basis of primary eruption failure. *European Journal of Orthodontics*. 2006;28:535-540. DOI: 10.1093/ejo/cjl033
- [9] Cho SY, Ki Y, Chu V, Chan J. Impaction of permanent mandibular second molars in ethnic Chinese school children. *Journal of the Canadian Dental Association*. 2008;74(6):521. Available from: [www.cda-adc.ca/jcda/vol-74/issue-6/521.html](http://www.cda-adc.ca/jcda/vol-74/issue-6/521.html)
- [10] Srinivasan MR, Poorni S, Venkatesh A, Vasanthi B. Prevalence of impacted permanent mandibular second molars in south Indian population: A cross-sectional study. *Indian Journal of Dental Research*. 2016;27:540-543. DOI: 10.4103/0970-9290.195645
- [11] Evans R. Incidence of lower second permanent molar impaction. *British Journal of Orthodontics*. 2014;15:199-203. DOI: 10.1179/bjo.15.3.199
- [12] Cassetta M, Altieri F, Calasso S. Etiological factors in second mandibular molar impaction. *Journal of Clinical and Experimental Dentistry*. 2014;6:150-154. DOI: 10.4317/jced.51382
- [13] Raghoobar GM, Boering G, Jansen H, Vissink A. Secondary retention of permanent molars: A histologic study. 1989;18:427-431. DOI: 10.1111/j.1600-0714.1989.tb01338.x
- [14] Majourau A, Norton LA. Uprighting impacted second molars with segmented springs. *American Journal of Orthodontics and Dentofacial Orthopedics*. 1995;107:235-238. DOI: 10.1016/S0889-5406(95)70137-0

- [15] Shpack N, Finkelstein T, Lai YH, Kuftinec MM, Vardimon A, Shapira Y. Mandibular permanent second molar impaction treatment options and outcome. *Open Journal of Dentistry and Oral Medicine*. 2013;**1**:9-14. DOI: 10.13189/ojdom.2013.010103
- [16] Hanisch M, Hanisch L, Kleinheinz J, Jung S. Primary failure of eruption (PFE): A systematic review. *Head and Face Medicine*. 2018;**14**:2-9. DOI: 10.1186/s13005-018-0163-7
- [17] Boynton T, Lieblich SE. Surgical uprighting of second molars. *Atlas of the Oral and Maxillofacial Surgery Clinics of North America*. 2013;**21**: 235-237. DOI: 10.1016/j.cxom.2013.05.001
- [18] Vedtofte H, Andreasen JO, Kjær I. Arrested eruption of the permanent lower second molar. *European Journal of Orthodontics*. 1999;**21**:31-40. DOI: 10.1093/ejo/21.1.31
- [19] Magkavali-Trikka P, Emmanouilidis G, Papadopoulos MA. Mandibular molar uprighting using orthodontic miniscrew implants: A systematic review. *Progress in Orthodontics*. 2018;**19**:1-12. DOI: 10.1186/s40510-017-0200-2
- [20] Yordanova G. Treatment of impacted lower left second molar and over erupted upper second molar. *Journal of Dental Health, Oral Disorders and Therapy*. 2018;**9**:106-108. DOI: 10.15406/jdhodt.2018.09.00338
- [21] Sawicka M, Racka-pilszak B, Rosnowska-Mazurkiewicz A. Uprighting partially impacted permanent second molars. *The Angle Orthodontist*. 2007;**77**:148-154. DOI: 10.2319/010206-461
- [22] Shapira Y, Borell G, Nahlieli O, Kuftinek MM. Uprighting mesialy impacted mandibular permanent second molars. *The Angle Orthodontist*. 1998;**68**:173-178
- [23] Kim K-J, Park JH, Kim M-J, Jang H-I, Chae J-M. Posterior available space for uprighting horizontally impacted mandibular second molars using orthodontic microimplant anchorage. *Journal of Clinical Pediatric Dentistry*. 2018;**43**:56-63. DOI: 10.17796/1053-4625-43.1.11
- [24] Magnusson C, Kjellberg H. Impaction and retention of second molars: Diagnosis, treatment and outcome. *The Angle Orthodontist*. 2008;**79**:422-427. DOI: 10.2319/0003-3219(2009)079[0422:iarosm]2.0.co;2
- [25] Lin S-Y, Chang C, Roberts WE. Simple mechanics to upright horizontally impacted molars with ramus screws. *Orthodontic Journal of Nepal*. 2016;**5**:42-47. DOI: 10.3126/ojn.v5i2.15231
- [26] Kravitz ND. Surgical uprighting of lower second molars. *Journal of Clinical Orthodontics*. 2016;**50**(1):33-40. Available from: [www.jco-online.com](http://www.jco-online.com)
- [27] Johnson JV, Quirk GP. Surgical repositioning of impacted mandibular second molar teeth. *American Journal of Orthodontics and Dentofacial Orthopedics*. 1987;**91**:242-251. DOI: 10.1016/0889-5406(87)90454-9