

## Review Article

# Importance of the right ventricle in valvular heart disease

E. Nagel, M. Stuber\* and O. M. Hess

Cardiology, University Hospital, Zürich, Switzerland and \*Institute of Biomedical Engineering, Federal Institute of Technology, Zürich, Switzerland

The importance of the right ventricle as a determinant of clinical symptoms, exercise capacity, peri-operative survival and postoperative outcome has been underestimated for a long time. Right ventricular ejection fraction has been used as a measure of right ventricular function but has been found to be dependent on loading conditions, ventricular interaction as well as on myocardial structure. Altered left ventricular function in patients with valvular disease influences right ventricular performance mainly by changes in afterload but also by ventricular interaction. Right ventricular function and regional wall motion can be determined with right ventricular angiography, radio-nuclide ventriculography, two-dimensional echocardiogra-

phy or magnetic resonance imaging. However, the complex structure of the right ventricle and its pronounced translational movements render quantification difficult. True regional wall motion analysis is, however, possible with myocardial tagging based on magnetic resonance techniques. With this technique a baso-apical shear motion of the right ventricle was observed which was enhanced in patients with aortic stenosis.

(*Eur Heart J* 1996; 17: 829–836)

**Key Words:** Right ventricle, ventricular function, valve disease, pulmonary artery pressure, ventricular interaction, postoperative changes, myocardial tagging.

## Introduction

The importance of right ventricular function has been underestimated in the past, especially its role as a determinant of cardiac symptoms, exercise tolerance and survival in patients with valvular disease of the left heart. The pump function of the right ventricle has been thought not to be relevant for the overall function of the heart<sup>[1,2]</sup> and to improve if the cause for its dysfunction is removed<sup>[3]</sup>. However, our understanding of the role of the right ventricle in the maintenance of normal cardiac function has changed dramatically. It has been shown that right ventricular function is a major determinant of cardiac symptoms and exercise capacity in chronic heart failure<sup>[4,5]</sup>. An increase in pulmonary wedge pressure as a result of mitral or aortic valve disease is associated with a rise in mean pulmonary artery pressure. Thus, right ventricular afterload increases, as dilatation of the right ventricle develops with a resultant drop in the right

ventricular ejection fraction. As a consequence, the tricuspid valve annulus dilates and may induce tricuspid regurgitation<sup>[6]</sup> with secondary right ventricular volume overload.

Right heart failure is mainly a clinical diagnosis and, thus, exact quantification is difficult. Early detection of right ventricular dysfunction is important and depends largely on the imaging technologies. Due to the complex structure and asymmetrical shape of the right ventricle, assessment of right ventricular function is often problematic. Echocardiography relies on geometrical assumptions or a three-dimensional analysis of the right ventricle which is not always sufficiently visualized<sup>[7]</sup>. Radionuclide angiography requires injection of radioactive markers and has a low spatial resolution. This technique suffers from attenuation artifacts and differentiation between the right ventricle and right atrium may be difficult<sup>[8–10]</sup>. Contrast angiography is invasive and requires contrast injection in potentially haemodynamically unstable patients. Newer methods such as spiral computed tomography or magnetic resonance imaging<sup>[11]</sup> allow better analysis of right ventricular function than other imaging techniques, but they are not yet available in all institutions. Most data on right ventricular function stem from clinical studies performed with

Submitted for publication 24 July 1995, and accepted 7 August 1995.

With support from the Swiss Cardiology Foundation.

Correspondence: Otto M. Hess, MD, Cardiology, University Hospital, Rämistr. 100, 8091 Zurich, Switzerland.

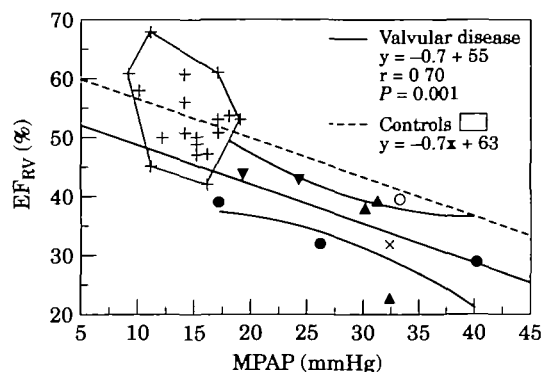
radionuclide angiography<sup>[12,13]</sup> or right ventricular angiography<sup>[14,15]</sup>.

### Right ventricular ejection performance in relation to pulmonary haemodynamics

Right ventricular ejection fraction is dependent on right ventricular afterload and, thus, on left ventricular or left atrial filling pressures<sup>[16-19]</sup>. An increase in left ventricular afterload is compensated for by an increase in mass to reduce left ventricular fibre stress. The right ventricle, however, is more sensitive to changes in load which is probably due to the smaller muscle mass and, thus, higher wall stress of a given load. Thus, a decrease in right ventricular ejection fraction with an increase in pulmonary artery pressure has been reported in patients with valvular or coronary artery disease<sup>[20]</sup> as well as in patients with chronic obstructive pulmonary disease<sup>[21,22]</sup>. A rapid improvement or normalisation of right ventricular ejection fraction has been found after reduction of pulmonary artery pressure with nitroglycerin<sup>[16]</sup>, single lung transplantation<sup>[21]</sup> or left heart valve replacement. Right ventricular ejection fraction as a function of mean pulmonary arterial pressure has been plotted from several different studies (Fig. 1) and a close relationship between these two parameters documenting the load-sensitivity of the right ventricle has been observed. The steeper slope between mean pulmonary arterial pressure and right ventricular ejection fraction when compared to the slope between left ventricular systolic pressure and left ventricular ejection fraction (Fig. 2) demonstrates that the left ventricle can tolerate a higher load than the right. Right ventricular ejection fraction is reduced by approximately 10% (55 to 45%), when right ventricular afterload is doubled from 25 to 50 mmHg. However, a doubling of left ventricular afterload from 125 to 250 mmHg leads to a similar reduction in left ventricular ejection fraction from 70 to 60%.

The close correlation between right ventricular ejection fraction and mean pulmonary arterial pressure for patients with cardiac valve diseases indicates that right ventricular afterload rather than contractility is the major determinant of right ventricular ejection fraction. However, some studies in patients with chronic right ventricular pressure overload showed a reduced systolic ejection performance with a downward shift of the relationship between right ventricular ejection fraction and mean pulmonary arterial pressure below the 95% confidence limit (Fig. 1). The assessment of right ventricular contractility is difficult and has been attempted by right ventricular dp/dt, right ventricular end-systolic pressure/volume relationship, right ventricular maximal elastance or mean normalized systolic ejection rate<sup>[23,24]</sup>. However, none of these parameters is very sensitive and, thus, quantification of right ventricular contractile function remains difficult.

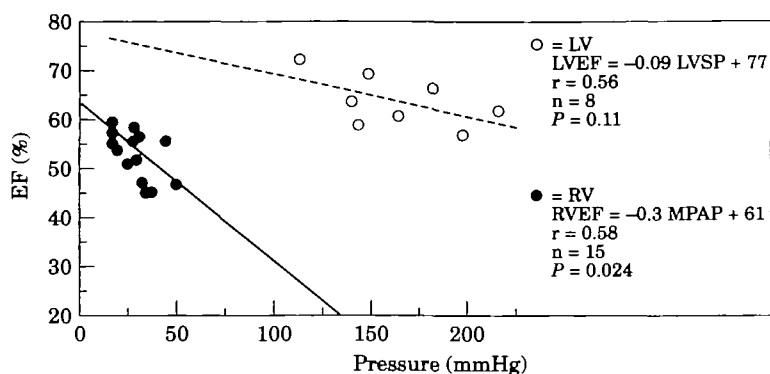
In most patients with aortic valve disease, right ventricular ejection fraction is maintained, whereas it



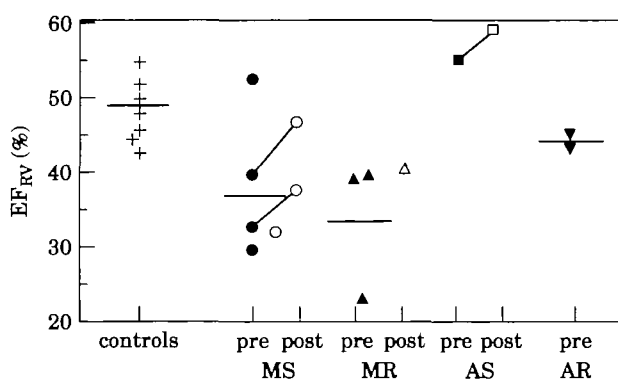
**Figure 1** Relationship between radionuclide right ventricular ejection fraction ( $EF_{RV}$ ) and mean pulmonary artery pressure (MPAP). Data are taken from the literature. Control data (hatched area) are from two studies representing individual values of 18 patients<sup>[17,18]</sup>. The data points of the patients with valvular disease represent one study each<sup>[18,19,21,25,26,28,31]</sup>. The solid line shows the correlation for patients with various valvular heart disease; the dashed line shows the correlation for controls. ▲ = mitral regurgitation; ▼ = aortic regurgitation; ● = mitral stenosis; ○ = mitral stenosis after replacement or valvuloplasty; + = controls; × = mitral regurgitation and aortic regurgitation.

is typically reduced in patients with mitral valve disease<sup>[19,25-29]</sup> (Fig. 3). Mitral valve disease generally influences the right ventricle more than aortic valve disease<sup>[30,31]</sup>. Left atrial volume overload in mitral insufficiency and pressure overload in mitral stenosis may cause an increase in pulmonary vascular resistance with an increase in the afterload of the right ventricle (Table 1, Fig. 4) and, thus, a decrease in right ventricular ejection fraction (Fig. 3). In contrast, left ventricular function is usually normal or even enhanced in mitral regurgitation due to low impedance leak<sup>[32]</sup>. A mild decrease of left ventricular function represents an early sign of myocardial dysfunction with a sudden worsening after valve replacement<sup>[33]</sup>, whereas a decrease in right ventricular ejection fraction usually represents a state of pressure overload hypertrophy.

Pulmonary artery pressure often decreases immediately after mitral valve surgery (Fig. 4) with a normalization of pulmonary pressure within 6 months. It may, however, stay elevated for more than 2 years in patients with severe pulmonary hypertension before operation (Fig. 5)<sup>[34]</sup>. This can be explained by the structural changes of the pulmonary vessels which may return only slowly after operation or may be irreversible<sup>[35]</sup>. A normalization of right ventricular ejection fraction, concurrent with a normalization of pulmonary artery pressure, has been reported in most patients after mitral valve operation<sup>[28,29]</sup>. However, in some cases right ventricular ejection fraction does not normalize but remains depressed. This is explained by the occurrence of myocardial dysfunction due to rheumatic heart disease<sup>[36]</sup> or high wall stress, secondary to ventricular dilatation<sup>[25]</sup>. The extent of right ventricular dilatation and the duration of chronic pressure overload beyond



**Figure 2** Relationship between angiographic RV (●) ejection fraction ( $EF_{RV}$ ) and mean pulmonary artery pressure (MPAP) as well as left ventricular (○) ejection fraction and peak systolic pressure (LVSP). The slope of the regression line is steeper for the right ventricle than for the left ventricle, indicating a higher load-sensitivity of the right ventricle. Data are taken from the literature; each data point represents one different study<sup>[116,17,30,37,38,40,41]</sup>.



**Figure 3** Mean radionuclide right ventricular ejection fraction ( $EF_{RV}$ ) in pre- and postoperative patients with valvular disease of the left heart<sup>[12,17-19,21,26,28,31,39]</sup>. Please note that the right ventricular ejection fraction is abnormal in patients with mitral stenosis or regurgitation probably because of altered after-load condition, whereas right ventricular function is normal in aortic valve disease.

which no normalization of right ventricular ejection fraction can be achieved is, however, not known.

Pulmonary haemodynamics are usually normal, or only slightly altered, in aortic valve disease<sup>[34]</sup>. Equally symptomatic patients with aortic insufficiency have lower pulmonary artery pressures<sup>[27]</sup> and better right ventricular ejection fraction than those with mitral valve disease<sup>[26]</sup> (Fig. 3). Similarly, the size of the right coronary artery was normal in severe aortic valve disease, whereas it was significantly increased in patients with mitral valve disease when compared to controls, indicating that secondary pulmonary hypertension is associated with right ventricular hypertrophy and enlargement of the right coronary artery<sup>[37,38]</sup>. Although pulmonary haemodynamics are only slightly altered in patients with aortic valve disease, an increase of right ventricular ejection fraction and a reduction of

pulmonary blood volume and pulmonary capillary wedge pressure was found immediately after aortic valve replacement<sup>[39]</sup>.

### Right ventricular ejection performance in chronic volume overload of the right ventricle

Some authors have distinguished between patients with right ventricular pressure overload with and without tricuspid regurgitation<sup>[40-42]</sup> and found higher mean pulmonary artery pressures and lower right ventricular ejection fractions in those with tricuspid regurgitation<sup>[40]</sup>, although there is a low impedance leak with regurgitation into the right atrium. In some patients functional tricuspid regurgitation will normalize after left heart valve replacement when the right ventricle gets smaller and the tricuspid annulus shrinks to its normal size after correction or right ventricular pressure overload<sup>[3,43]</sup>, whereas in others it may not<sup>[44,45]</sup>. These patients with significant tricuspid regurgitation after valvular surgery have a poor prognosis whether operated on or not<sup>[46]</sup>. The severity of tricuspid insufficiency beyond which no normalization of right ventricular dimensions will occur remains, however, unclear. The gold standard for the assessment of tricuspid insufficiency is right ventricular angiography, but there are several drawbacks—such as catheter-induced extrasystoles, poor filling of the right ventricle and the impossibility of exactly quantifying the severity of the lesion<sup>[47,48]</sup>. Newer, non-invasive methods, such as contrast echocardiography<sup>[49-51]</sup>, colour-coded Doppler echocardiography<sup>[52]</sup> or magnetic resonance imaging<sup>[53]</sup> allow semiquantitative evaluation of tricuspid insufficiency, although exact quantification is also not possible. Doppler echocardiography allows us to detect minimal, so-called 'physiological' tricuspid regurgitation in almost all patients, especially the young<sup>[54-56]</sup>.

**Table 1** Data from the literature on mean pulmonary artery pressure (MPAP) pre- and postoperative right ventricular ejection fraction (RVEF) and left ventricular ejection fraction (LVEF) as well as NYHA classification

Author	Year	Valve lesion	n	Tech	Pre-operative				Postoperative	
					MPAP	RVEF	LVEF	NYHA	MPAP	RVEF
Morrison <sup>[17]</sup>	1983	Controls	9	R	15 ± 3	55 ± 5	70 ± 9	—	—	—
Große <sup>[16]</sup>	1983	Controls	8	A	15 ± 2	55 ± 4	71 ± 8	—	—	—
Nienaber <sup>[18]</sup>	1987	Controls	10	R	14 ± 4	52 ± 8	—	—	—	—
Unterberg <sup>[41]</sup>	1989	Controls	18	A	15 ± 7	58 ± 7	66 ± 14	—	—	—
Hirata <sup>[19]</sup>	1992	Controls	9	R	—	45 ± 5	62 ± 7	—	—	—
Mayer <sup>[68]</sup>	1994	Controls	10	A	12 ± 2	—	63 ± 4	—	—	—
Iskandrian <sup>[25]</sup>	1984	MR	21	R	32 ± 10	23 ± 10	57 ± 15	—	—	—
Morrison <sup>[31]</sup>	1985	MR	12	R	31 ± 10	39 ± 10	49 ± 18	2-4	—	—
Unterberg <sup>[41]</sup>	1989	MR	26	A	23 ± 9	51 ± 11	63 ± 17	—	—	—
Niles <sup>[26]</sup>	1990	MR	18	R	30 ± 12	38 ± 9	52 ± 10	>2	—	—
Vassalli <sup>[38]</sup>	1993	MR	10	A	25 ± 7	—	62 ± 9	2-4	16 ± 3	—
Iskandrian <sup>[25]</sup>	1984	MS	22	R	40 ± 20	29 ± 12	49 ± 14	—	—	—
Cohen <sup>[28]</sup>	1985	MS	8	R	26 ± 7	32 ± 6	48 ± 8	2-8	—	37 ± 9
Unterberg <sup>[41]</sup>	1989	MS	35	A	25 ± 9	56 ± 13	62 ± 12	—	—	—
Hirata <sup>[19]</sup>	1992	MS	11	R	17 ± 3	39 ± 4	48 ± 10	2-4	—	46 ± 6
Burger <sup>[29]</sup>	1993	MS*	11	T	32	40	—	2-3	22	45
Mayer <sup>[68]</sup>	1994	MS*	15	A	30 ± 11	—	56 ± 7	2-1	23 ± 10	—
Morrison <sup>[31]</sup>	1985	AR	9	R	19 ± 8	44 ± 9	52 ± 11	1-8	—	—
Unterberg <sup>[30]</sup>	1987	AR	23	A	18 ± 7	54 ± 9	57 ± 13	—	—	—
Niles <sup>[26]</sup>	1990	AR	15	R	24 ± 12	43 ± 8	45 ± 12	≥2	—	—
Villari <sup>[37]</sup>	1992	AR	7	A	21 ± 8	—	59 ± 8	1-8	17 ± 5	—
Trikas <sup>[27]</sup>	1994	AR	19	R	32 ± 2	—	—	2-5	—	—
Harpole <sup>[39]</sup>	1990	AS	11	R	—	54 ± 13	52 ± 16	3-4	—	58 ± 8
Villari <sup>[37]</sup>	1992	AS	8	A	20 ± 6	—	55 ± 13	1-7	21 ± 6	—

n=Number of patients; Tech=technique; MR=mitral regurgitation; MS=mitral stenosis; AR=aortic regurgitation; AS=aortic stenosis; \*=mitral valvuloplasty; A=angiography; R=radionuclide ventriculography; T=thermodilution.

However, this regurgitation has no haemodynamic effects and thus no clinical consequences.

## Right/left ventricular interaction

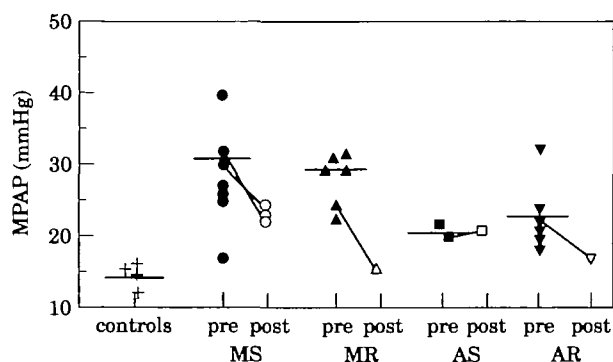
### Left-to-right interaction

Apart from the influences of the left ventricle on the right ventricle via the pulmonary circulation, the left ventricle acts also on right ventricular function through the interventricular septum<sup>[57-59]</sup>. In the experimental animal, the exclusion of the right ventricle leads to an elevation of systemic venous pressure, a decline in pulmonary artery pressure, a reduction in cardiac output and a drop in arterial pressure<sup>[60,61]</sup>. However, scarring of the right ventricular myocardium by cauterization<sup>[11]</sup> or the exchange of the right ventricle with a non-contractile pericardial patch<sup>[62]</sup> is associated with reasonable right ventricular ejection fraction due to the function of the septum — which is able to maintain cardiac output as long as the right ventricle is not dilated. In a study of Hoffman *et al.*<sup>[62]</sup>, left ventricular contraction contributed 24% of its own stroke work to the generation of right ventricular stroke work via the interventricular septum. In pulmonary hypertension this contribution increased to 35%. A negative linear

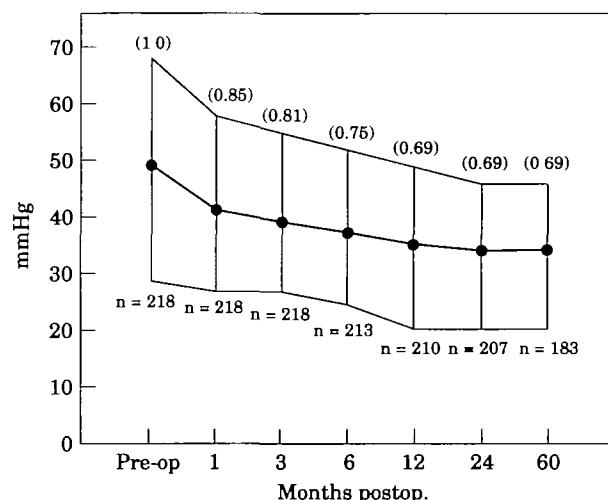
correlation between right ventricular size and left or right ventricular stroke work was demonstrated. Thus, even though left-to-right ventricular interaction may compensate for a reduction in right ventricular function, in the presence of right ventricular pressure or volume overload it will not suffice to maintain adequate cardiac output without a sufficiently contracting right ventricle.

### Right-to-left ventricular interaction

The filling state of the right ventricle influences the motion of the interventricular septum and thus, left ventricular performance<sup>[63,64]</sup>. Right ventricular volume overload with dilatation of the right ventricle and right atrium causes an increase in intrapericardial pressure (=pericardial constraint), reducing venous return, cardiac output and, thus, left ventricular function<sup>[65]</sup>. These effects can be significantly diminished by opening or removing the pericardium. A recent study using magnetic resonance tagging in patients with right ventricular hypertrophy has shown an increased curvature of the septum and a decreased septal shortening<sup>[66]</sup>. Ventricular interaction through the interventricular septum was reported to be less important than interaction through the pulmonary circulation but appeared to be of great importance for the balance of the right and left



**Figure 4** Mean pulmonary artery pressure (MPAP) of controls, patients with mitral regurgitation (MR), mitral stenosis (MS), aortic stenosis (AS) and aortic regurgitation (AR). Each data point represents one single study<sup>[16-19,21,25-30,37,38,68]</sup>. Pre- (pre) and post-operative (post) values are plotted; however, post-operative studies are rare and, thus, data points are limited. Most patients show normalization of MPAP after correction of the valvular lesion, except for mitral stenosis (see below).



**Figure 5** Mean pulmonary artery pressure early and late after valve replacement in patients with increased pulmonary vascular resistance, before operation<sup>[34]</sup>. Please note that normalization of pulmonary artery pressure takes years after correction of the valvular lesion. Five years after operation of mean pulmonary artery pressure remained slightly elevated in these patients. (Published with the permission of the editors and authors of reference 34.)

cardiac output<sup>[63]</sup>. An increase in right ventricular volume will affect not only left ventricular systolic function, but also left ventricular diastolic properties. In patients with pulmonary hypertension an abnormal septal motion and an increased chamber stiffness of the left ventricle has been reported<sup>[67]</sup>. Right-to-left ventricular interaction with a correlation between end-diastolic filling pressure of the right and left ventricle ( $r=0.71$ ) was observed in patients with mitral stenosis which was lost after mitral valvuloplasty<sup>[68]</sup>. A possible explanation for

the loss of right ventricular/left ventricular interaction is the mobilization of the subvalvular apparatus with an increased regional wall motion of the posterior wall.

Thus, right-to-left or left-to-right ventricular interaction is mediated through three mechanisms: (1) pulmonary circulation with changes in right ventricular loading conditions, (2) geometry and motion of the interventricular septum (e.g. by common myocardial fibres), and (3) pericardial constraint.

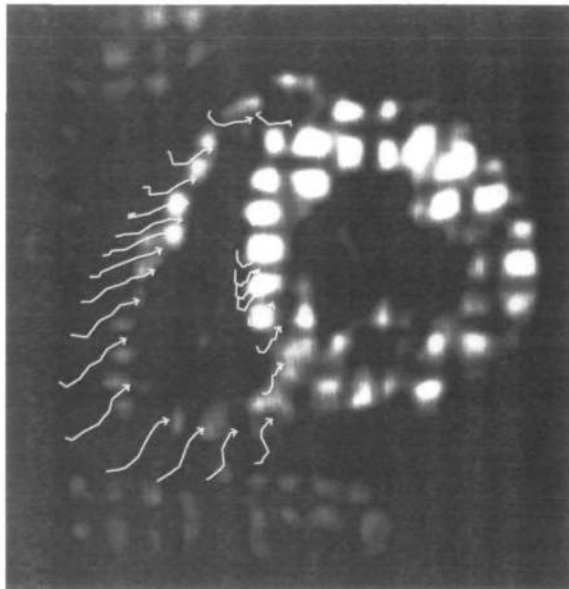
## Right ventricular regional wall motion

Regional wall motion of the right ventricle has been assessed with various techniques, including right ventricular angiography<sup>[20,69]</sup>, two-dimensional echocardiography and radionuclide ventriculography as well as newer methods such as conventional magnetic resonance imaging and myocardial tagging. Most of these techniques have given conflicting results due to the complex geometry of the right ventricle and the pronounced translational movements of the heart.

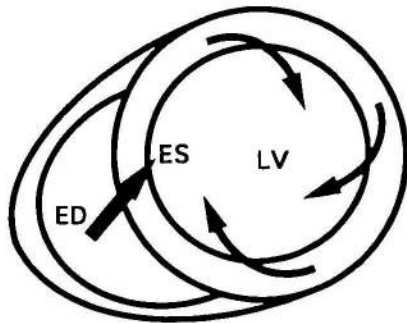
Myocardial tagging<sup>[70-72]</sup> allows the non-invasive labelling of specific myocardial regions and, in contrast to most other techniques, the assessment of true regional function of the right ventricle<sup>[73]</sup>. Conventional parameters for the description of regional right ventricular wall motion, such as radial shortening and regional area reduction, are dependent on the shape and motion of the right ventricle. Consequently, these parameters vary between different regions and planes. Regional circumferential shortening, which is dependent on the local shortening of the myocardium, is, however, more uniformly distributed in the different regions with a coefficient of variance which is significantly ( $P<0.01$ ) smaller than for radial shortening or regional area reduction. Using myocardial tagging, a baso-apical shear motion of the right ventricle was observed which is the result of the 'wringing motion' of the left ventricle<sup>[73]</sup>. This 'wringing motion' is characterized by a clockwise rotation of the left ventricle at the base and a counterclockwise rotation at the apex which pulls the right ventricle in these directions through a network of common myocardial fibres between the two ventricles (Fig. 6). This baso-apical shear motion is significantly increased in patients with aortic stenosis when compared to controls (Fig. 7), probably as a result of the previously described left-to-right ventricular interaction.

## Importance of the right ventricle as a prognostic factor in valve surgery

The importance of the right ventricle for peri-operative morbidity and mortality was recognized several years ago. Thus, the right ventricle plays an important role not only for survival but also for the postoperative course and functional recovery of the patient with valve disease of the left heart.



A

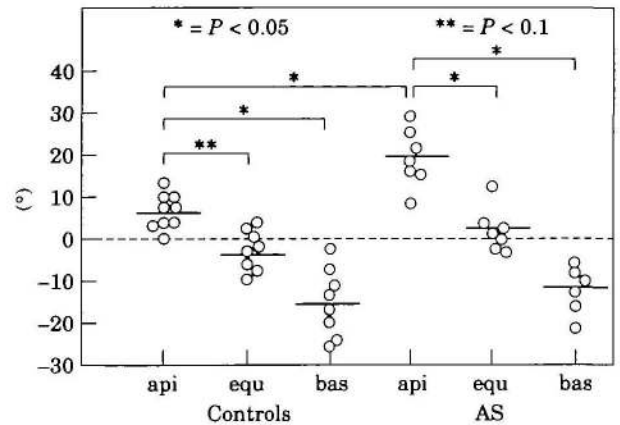


B

**Figure 6** (A) Magnetic resonance myocardial tagging in a volunteer. The right ventricle is shown in a basal short axis-view at end-systole. The arrows indicate the regional wall motion calculated from the intersection points of the rectangular grid. (B) In a schematic drawing the motion pattern of the left and right ventricle at the base is depicted and indicates the left ventricular clockwise rotation which pulls the right ventricle in this direction causing a baso-apical shear motion. ED=end-diastole; ES=end-systole.

### Mitral valve disease

Generally, the prognosis of patients with mitral valve disease and depressed right ventricular function improves significantly after successful mitral valve replacement or repair<sup>[19,36]</sup>. However, according to Pinzani *et al.*<sup>[74]</sup>, in the presence of right ventricular failure, mortality increases peri-operatively from 5 to 11% ( $P < 0.02$ ) and, during follow-up, from 8 to 22% ( $P < 0.0005$ ). Hirata *et al.*<sup>[19]</sup> reported, in patients with a pre-operative right ventricular ejection fraction of less than 40%, no normalization of right ventricular ejection fraction after valve surgery. The persistence of symptoms after operation was higher in patients with a pre-operative right ventricular ejection fraction of less than 30% compared to those with a right ventricular ejection fraction of more than 30%<sup>[36]</sup>. If right heart failure persisted after



**Figure 7** Shear angles of the centre of gravity at the apex, equator and base. The baso-apical shear motion is more pronounced in the hypertrophied than in the normal ventricle. AS=aortic stenosis; api=apical; equ=equatorial; bas=basal.

valve replacement, patients had a higher 5-year mortality (39%) than patients without right heart failure (4%;  $P < 0.0001$ ) after surgery<sup>[74]</sup>.

A small number of patients developed right heart failure early after mitral valve surgery. These patients had a poor prognosis, with a mortality of 72% within 75 months of operation<sup>[74]</sup>. The aetiology of peri-operative right heart failure is multifactorial, and the pathophysiology is not yet fully understood.

Groves and coworkers<sup>[75]</sup> reported a significantly lower exercise duration, a decreased maximal oxygen consumption and a lower anaerobic threshold in patients with than without tricuspid regurgitation late after successful mitral valve replacement. The presence of tricuspid insufficiency can explain the incomplete recovery from valvular surgery or the return of clinical symptoms in patients without prosthetic valve failure, persisting pulmonary hypertension or congestive heart failure. In the present study it was not possible to differentiate between (1) right ventricular pump failure with secondary tricuspid regurgitation and (2) tricuspid regurgitation with secondary right ventricular failure as the precipitating cause.

### Aortic valve disease

Survival and postoperative symptoms in patients with aortic regurgitation are usually better than they are in mitral regurgitation<sup>[26]</sup>. Patients with combined mitral and aortic regurgitation had a poorer right and left ventricular ejection fraction than those with mitral regurgitation alone. The postoperative outcome of these patients with combined aortic and mitral regurgitation was less favourable than in those with isolated valvular lesions because four of eight patients died, and three of those surviving suffered asymptomatic deterioration within 72 months. However, these differences did not reach statistical significance owing to the small number of patients.

## Conclusions

The assessment of right ventricular function is difficult because of its complex geometry and pronounced translational motions. Several invasive and non-invasive techniques have been used for estimating right ventricular function. Right ventricular ejection fraction was found to be dependent on pulmonary circulation with alterations in right ventricular loading conditions, right ventricular geometry and motion of the interventricular septum (ventricular interaction) as well as myocardial structure. Pulmonary artery pressure is usually increased in patients with mitral valve disease but only slightly altered in patients with aortic valve disease. Irreversible damage to the right ventricle has been described in patients with advanced mitral valve disease but the point where no normalization after correction of the valve lesion occurs has yet to be determined.

## References

- [1] Starr I, Jeffers WA, Mead RH. The absence of conspicuous increments in venous pressure after severe damage to the right ventricle of the dog and a discussion of the relation between clinical congestive heart failure and heart disease. *Am Heart J* 1943; 26: 291–301.
- [2] Sade RM, Castaneda AR. The dispensable right ventricle. *Surgery* 1975; 77: 624–31.
- [3] Braunwald NS, Ross J Jr, Morrow AG. Conservative management of tricuspid regurgitation in patients undergoing mitral valve replacement. *Circulation* 1967; 35: 163–9.
- [4] Engler R, Ray R, Higgins CB. Clinical assessment and follow up of functional capacity in patients with chronic congestive cardiomyopathy. *Am J Cardiol* 1982; 49: 1832–7.
- [5] Baker BJ, Wilen MM, Boyd CM, Dinh H, Francis JA. Relation of right ventricular ejection fraction to exercise capacity of patients with chronic left ventricular failure. *Am J Cardiol* 1984; 54: 596–9.
- [6] Ubago JL, Figueroa A, Ochoteco A, Colman T, Duran RM, Duran CG. Analysis of the amount of tricuspid valve annular dilatation required to produce functional tricuspid regurgitation. *Am J Cardiol* 1983; 52: 155–8.
- [7] Levine RA, Gibson TC, Aretz T *et al.* Echocardiographic measurement of right ventricular volume. *Circulation* 1984; 69: 497–505.
- [8] Marving J, Høilund-Carlsen PF, Chraemmer-Jørgensen B, Gadsbøll N. Are right and left ventricular ejection fractions equal? ejection fractions in normal subjects and in patients with first acute myocardial infarction. *Circulation* 1985; 72: 502–14.
- [9] Dell'Italia LJ, Starling MR, Walsh RA, Badke FR, Lasher JC, Blumhardt R. Validation of attenuation-corrected equilibrium radionuclide angiographic determinations of right ventricular volume: comparison with cast-validated biplane cineventriculography. *Circulation* 1985; 72: 317–26.
- [10] Manno BV, Iskandrian AS, Hakki AH. Right ventricular function: methodologic and clinical considerations in non-invasive scintigraphic assessment. *J Am Coll Cardiol* 1984; 3: 1072–81.
- [11] Sechtem U, Pflugfelder PW, Gould RG, Cassidy MM, Higgins CB. Measurement of right and left ventricular volumes in healthy individuals with cine MR imaging. *Radiology* 1987; 167: 425–30.
- [12] Maddahi J, Berman DS, Matsuoka DT *et al.* A new technique for assessing right ventricular ejection fraction using rapid multiple gated equilibrium cardiac blood pool scintigraphy. *Circulation* 1979; 60: 581–9.
- [13] Goldberg HL, Herrold EM, Hochreiter C *et al.* Videodensitometric determination of right ventricular and left ventricular ejection fraction. *Am J Noninv Cardiol* 1987; 1: 18–23.
- [14] Goerke RJ, Carlsson E. Calculation of right and left ventricular volumes: method using computer equipment and biplane angiograms. *Invest Radiol* 1967; 2: 360–7.
- [15] Lange PE, Onnasch D, Farr FL, Heintzen PH. Angiocardiographic right ventricular volume determination. Accuracy, as determined from human casts and clinical applications. *Eur J Cardiol* 1978; 8: 477–501.
- [16] Grose R, Strain J, Yipintoso T. Right ventricular function in valvular heart disease: relation to pulmonary artery pressure. *J Am Coll Cardiol* 1983; 2: 225–32.
- [17] Morrison DA, Goldman S, Wright AL *et al.* The effect of pulmonary hypertension on systolic function of the right ventricle. *Chest* 1983; 84: 250–7.
- [18] Nienaber CA, Spielmann RP, Wasmus G, Montz R, Mathey DG, Bleifeld DG. Right ventricular ejection fraction from equilibrium krypton-81 m blood pool scans: a noninvasive predictor of pulmonary artery hypertension. *Eur Heart J* 1987; 8: 297–307.
- [19] Hirata N, Sakakibara T, Shimazaki Y *et al.* Preoperative and postoperative right ventricular junction during exercise in patients with mitral stenosis. *J Thorac Cardiovasc Surg* 1992; 104: 1029–34.
- [20] Heywood JT, Grimm J, Hess OM, Jakob M, Krayenbuehl HP. Right ventricular systolic function during exercise with and without significant coronary artery disease. *Am J Cardiol* 1991; 67: 681–6.
- [21] Kramer MR, Valantine HA, Marshall SE, Starnes VA, Theodore J. Recovery of the right ventricle after single-lung transplantation in pulmonary hypertension. *Am J Cardiol* 1994; 73: 494–500.
- [22] Lazar JM, Flores AR, Grandis DJ, Orije JE, Schulman DS. Effects of chronic right ventricular pressure overload on left ventricular diastolic function. *Am J Cardiol* 1993; 72: 1179–82.
- [23] Finnegan P, Forbes MV, Bishop JM. Evaluation of pressure-derived indices of right ventricular contractility. *Eur J Cardiol* 1977; 6: 139–155.
- [24] Niehues B, Schwantz V, Hagemann K *et al.* Die Bedeutung der dp/dtmax für die Beurteilung der Kontraktilität des rechten Ventrikels. *Z Kardiol* 1973; 62: 1029–40.
- [25] Iskandrian AS, Hakki A, Ren J *et al.* Correlation among right ventricular preload, afterload and ejection fraction in mitral valve disease: radionuclide, echocardiographic and hemodynamic evaluation. *J Am Coll Cardiol* 1984; 3: 1403–11.
- [26] Niles N, Borer JS, Kamen M, Hochreiter C, Devereux R, Roman M. Preoperative left and right ventricular performance in combined aortic and mitral regurgitation: comparison with isolated aortic or mitral regurgitation. *Am J Cardiol* 1990; 65: 1372–8.
- [27] Trikas A, Papadopoulos P, Triposkiadis F *et al.* Factors affecting the postoperative exercise capacity of patients with mitral stenosis and aortic regurgitation. *Cardiology* 1994; 85: 201–6.
- [28] Cohen M, Horowitz SF, Machac J, Mindich BP, Fuster V. Response of the right ventricle to exercise in isolated mitral stenosis. *Am J Cardiol* 1985; 55: 1054–8.
- [29] Burger W, Kneissl GD, Kober G, Schröder R. Effect of balloon valvuloplasty for mitral stenosis on right ventricular function. *Am J Cardiol* 1993; 71: 994–6.
- [30] Unterberg R, Römmich P, Völker W, Mauser M, Karsch KR. Einfluß der Volumenbelastung des linken Ventrikels bei Aorten- und Mitralinsuffizienz auf die Geometrie und Funktion der rechten Kammer. *Z Kardiol* 1987; 76: 761–9.
- [31] Morrison DA, Lancaster L, Henry R, Goldman S, Turgeon J. Right ventricular function at rest and during exercise in aortic and mitral valve disease. *J Am Coll Cardiol* 1985; 5: 21–8.
- [32] Wisenbaugh T, Spann JF, Carabello BA. Differences in myocardial performance and load between patients with similar amounts of chronic aortic versus chronic mitral regurgitation. *J Am Coll Cardiol* 1984; 3: 916–23.

- [33] Corin WJ, Monrad WS, Murakami T, Nonogi H, Hess OM, Krayenbuehl HP. The relationship of afterload to ejection performance in chronic mitral regurgitation. *Circulation* 1987; 76: 59–67.
- [34] Horstkotte D, Niehues R, Schulte HD, Strauer BE. Belastbarkeit nach Herzklappenersatz. *Z Kardiol* 1994; 83 (Suppl 3): 111–20.
- [35] Harris P, Heath D (eds). *The human pulmonary circulation*. Edinburgh. Churchill Livingstone, 1977.
- [36] Borer JS, Hochreiter C, Rosen S. Right ventricular function in severe non-ischaemic mitral insufficiency. *Eur Heart J* 1991; 12 (Suppl B): 22–5.
- [37] Villari B, Hess OM, Meier C *et al*. Regression of coronary artery dimensions after successful aortic valve replacement. *Circulation* 1992; 85: 972–8.
- [38] Vassalli G, Hess OM, Krogmann ON *et al*. Coronary artery size in mitral regurgitation and its regression after mitral valve surgery. *Am Heart J* 1993; 126: 1091–8.
- [39] Harpole DH, Jones RH. Serial assessment of ventricular performance after valve replacement for aortic stenosis. *J Thorac Cardiovasc Surg* 1990; 99: 645–50.
- [40] Brilla C, Konz KH, Karsch KR, Seipel L. Right ventricular function in mitral/aortic valve disease with and without tricuspid incompetence. *Z Kardiol* 1986; 75 (Suppl 2): 114–6.
- [41] Unterberg R, König S, Völker W, Piesch-Breifeld B, Karsch KR. Funktion des rechten Ventrikels bei Patienten mit Mitralvitien. *Z Kardiol* 1989; 78: 386–93.
- [42] Morrison DA, Ovitt T, Hammermeister KE. Functional tricuspid regurgitation and right ventricular dysfunction in pulmonary hypertension. *Am J Cardiol* 1988; 62: 108–12.
- [43] Simon R, Oelert H, Borst HG, Lichtlen PR. Influence of mitral valve surgery on tricuspid incompetence concomitant with mitral valve disease. *Circulation* 1980; 62: 1152–7.
- [44] Duran CMG, Pomar JL, Colman T, Figueroa A, Revuelta JM, Ubago JL. Is tricuspid valve repair necessary? *J Thorac Cardiovasc Surg* 1980; 80: 849–60.
- [45] Breyer RH, McClenathan JH, Michaelis LL, McIntosh CL, Morrow AG. Tricuspid regurgitation. A comparison of nonoperative management, tricuspid annuloplasty and tricuspid valve replacement. *J Thorac Cardiovasc Surg* 1976; 72: 867–74.
- [46] King RM, Schaff HV, Danielson GK *et al*. Surgery for tricuspid regurgitation late after mitral valve replacement. *Circulation* 1984; 70 (Suppl I): 1193–7.
- [47] Cairns KB, Kloster FE, Bristow JD, Lees MH, Griswold HE. Problems in the hemodynamic diagnosis of tricuspid insufficiency. *Am Heart J* 1968; 75: 173–5.
- [48] Stewart D, Leman RB, Kaiser J, Mann DL. Catheter-induced tricuspid regurgitation: incidence and clinical significance. *Chest* 1991; 99: 651–5.
- [49] Curtius JM, Thyssen M, Breuer HM, Loogen F. Doppler versus contrast echocardiography for diagnosis of tricuspid regurgitation. *Am J Cardiol* 1985; 56: 333–6.
- [50] Jaksch R, Karsch KR, Seipel L. Accuracy in detection and quantification of tricuspid regurgitation by contrast and Doppler echocardiography. *Z Kardiol* 1986; 75 (Suppl 2): 33–4.
- [51] Ruffmann K, Hess OM, Krayenbühl HP. Diagnostik der Trikuspidalinsuffizienz anhand von klinischen Zeichen und Kontrast-Echokardiographie. *Schweiz Med Wschr* 1983; 113: 1999–2003.
- [52] Suzuki Y, Kambara H, Kadota K *et al*. Detection and evaluation of tricuspid regurgitation using a real-time two-dimensional color-coded Doppler flow imaging system: comparison with contrast two-dimensional echocardiography and right ventriculography. *Am J Cardiol* 1986; 57: 811–5.
- [53] Nagel E, Jungehülsing M, Smolarz K *et al*. Diagnose und Quantifizierung der Trikuspidalinsuffizienz mit dynamischer Magnetresonanztomographie: Vergleich mit rechtsventrikulärer Angiographie. *Z Kardiol* 1991; 80: 561–8.
- [54] Berger M, Hecht SR, van Tosh A, Lingam U. Pulsed and continuous wave Doppler echocardiographic assessment of valvular regurgitation in normal subjects. *J Am Coll Cardiol* 1989; 13: 1540–5.
- [55] Kostucki W, Vandembosche JL, Friart A, Englert M. Pulsed Doppler regurgitant flow patterns of normal valves. *Am J Card* 1986; 58: 309–13.
- [56] Yoshida K, Yoshikawa J, Shakudo M *et al*. Color Doppler evaluation of valvular regurgitation in normal subjects. *Circulation* 1988; 78: 840–7.
- [57] Elzinga G, van Grondelle R, Westerhof N, van den Bos GC. Ventricular interference. *Am J Physiol* 1974; 226: 941–7.
- [58] Feneley MP, Gavaghan TP, Baron DW, J A. B, Roy PR, Morgan JJ. Contribution of left ventricular contraction to the generation of right ventricular systolic pressure in the human heart. *Circulation* 1985; 71: 473–80.
- [59] Weber KT, Janicki JS, Shroff S, Fishman AP. Contractile mechanics and interaction of the right and left ventricles. *Am J Cardiol* 1981; 47: 686–92.
- [60] Rose JC, Cosimano SJJ, Hufnagel CA, Massullo EA. The effects of exclusion of the right ventricle from the circulation in dogs. *J Clin Invest* 1955; 34: 1625.
- [61] Furey SAI, Zieske HA, Levy MN. The essential function of the right ventricle. *Am Heart J* 1984; 107: 404.
- [62] Hoffman D, Sisto D, Frater RWM, Nikolic SD. Left-to-right ventricular interaction with a noncontracting right ventricle. *J Thorac Cardiovasc Surg* 1994; 107: 1496–502.
- [63] Slinker BK, Glantz SA. End-systolic and end-diastolic ventricular interaction. *Am J Physiol* 1986; 251: H1062–75.
- [64] Weyman AE, Wann S, Feigenbaum H, Dillon JC. Mechanism of abnormal septal motion in patients with right ventricular volume overload: a cross-sectional echocardiographic study. *Circulation* 1976; 54: 179–86.
- [65] Hess OM, Bhargava V, Ross J Jr, Shabetai R. The role of the pericardium in interactions between the cardiac chambers. *Am Heart J* 1983; 106: 1377–83.
- [66] Dong SJ, Crawley AP, MacGregor JH *et al*. Regional left ventricular systolic function in relation to the cavity geometry in patients with chronic right ventricular pressure overload. *Circulation* 1995; 91: 2359–70.
- [67] Krayenbuehl HP, Turina J, Hess OM. Left ventricular function in chronic pulmonary hypertension. *Am J Cardiol* 1978; 41: 1150.
- [68] Mayer I, Jakob M, Suetsch G, Lattmann J, Vassalli G, Hess OM. Reversal of increased diastolic stiffness in mitral stenosis after successful valvuloplasty. *Circulation* 1994; 90 (Suppl 2): 1–483 (Abstr.).
- [69] Unterberg R, Plesak L, Voelker W, Karsch KR. Quantitative segmentale Wandfunktionsanalyse der rechten Kammer bei Herzgesunden. *Z Kardiol* 1988; 77: 120–24.
- [70] Axel L, Dougherty L. MR imaging of motion with spatial modulation of magnetization. *Radiology* 1989; 171: 841–5.
- [71] Zerhouni EA, Parish DM, Rogers WJ, Yang A, Shapiro EP. Human heart: tagging with MR imaging: a method for noninvasive assessment of myocardial motion. *Radiology* 1988; 169: 59–63.
- [72] Fischer SE, McKinnon GC, Maier SE, Boesiger P. Improved myocardial tagging contrast. *Mag Resonance Med* 1993; 30: 191–200.
- [73] Nagel E, Stuber M, Fischer SE, Boesiger P, Simon R, Hess OM. Assessment of right ventricular motion with magnetic resonance tissue tagging and slice following technique. *J Nuclear Cardiology* 1995; 2 (Suppl): 42 (Abstr.).
- [74] Pinzani A, de Gevigney G, Pinzani V, Milon H, Delahaye JP. L'insuffisance cardiaque droite pré- et postopératoire des mitraux et mitro-aortiques. *Arch Mal Coeur* 1993; 86: 27–34.
- [75] Groves PH, Lewis NP, Ikram S, Maire R, Hall RJC. Reduced exercise capacity in patients with tricuspid regurgitation after successful mitral valve replacement for rheumatic mitral valve disease. *Br Heart J* 1991; 66: 295–301.