



Citation for published version:

Pandit, H, Liddle, AD, Kendrick, BJL, Jenkins, C, Price, AJ, Gill, HS, Dodd, CAF & Murray, DW 2013, 'Improved fixation in cementless unicompartmental knee replacement: Five-year results of a randomized controlled trial', *Journal of Bone and Joint Surgery, American Volume*, vol. 95, no. 15, pp. 1365-1372.
<https://doi.org/10.2106/JBJS.L.01005>

DOI:

[10.2106/JBJS.L.01005](https://doi.org/10.2106/JBJS.L.01005)

Publication date:

2013

Document Version

Publisher's PDF, also known as Version of record

[Link to publication](#)

Publisher Rights

Unspecified

University of Bath

Alternative formats

If you require this document in an alternative format, please contact:
openaccess@bath.ac.uk

General rights

Copyright and moral rights for the publications made accessible in the public portal are retained by the authors and/or other copyright owners and it is a condition of accessing publications that users recognise and abide by the legal requirements associated with these rights.

Take down policy

If you believe that this document breaches copyright please contact us providing details, and we will remove access to the work immediately and investigate your claim.

Improved Fixation in Cementless Unicompartamental Knee Replacement

Five-Year Results of a Randomized Controlled Trial

H. Pandit, DPhil, FRCS(Orth), A.D. Liddle, BSc, MRCS, B.J.L. Kendrick, BSc, FRCS(Orth), C. Jenkins, MSc, A.J. Price, DPhil, FRCS(Orth), H.S. Gill, DPhil, C.A.F. Dodd, FRCS, and D.W. Murray, MD, FRCS(Orth)

Investigation performed at Nuffield Department of Orthopaedics, Rheumatology and Musculoskeletal Sciences, University of Oxford, and the Nuffield Orthopaedic Centre, Oxford, United Kingdom

Background: When used for appropriate indications, unicompartamental knee replacement is associated with fewer complications, faster recovery, and better function than total knee replacement. However, joint registries demonstrate a higher revision rate for unicompartamental knee replacement. Currently, most unicompartamental knee replacements are cemented; common reasons for revision include aseptic loosening and pain. These problems could potentially be addressed by using cementless implants, with coatings designed to improve fixation. The objectives of this study were to compare the quality of fixation as well as clinical outcomes of cemented and cementless unicompartamental knee replacements at five years of follow-up.

Methods: A randomized controlled trial was established with sixty-three knees (sixty-two patients) receiving either cemented (thirty-two patients) or cementless Oxford unicompartamental knee replacements (thirty patients). Fixation was assessed with fluoroscopic radiographs aligned to the bone-implant interface at one and five years. Outcome scores, including the Oxford Knee Score, Knee Society objective and functional scores, and Tegner Activity Score, were collected preoperatively and at six months and one, two, and five years postoperatively. At each postoperative time point, these were recorded as absolute scores and change from the preoperative score.

Results: Four patients died during the study period. There were no revisions. Mean operative time was nine minutes shorter in the cementless group ($p = 0.049$). At five years, there was no significant difference in any outcome measure except the Knee Society functional score and the change in the Knee Society functional score, which were significantly better in the cementless group ($p = 0.003$ for both). There were significantly more tibial radiolucencies in the cemented group (twenty of thirty knees versus two of twenty-seven knees; $p < 0.001$). There were nine complete radiolucencies in the cemented group and none in the cementless group ($p = 0.01$).

Conclusions: Cementless fixation provides improved fixation at five years compared with cemented fixation in mobile-bearing unicompartamental knee replacements, maintaining equivalent or superior clinical outcomes with a shorter operative time and no increase in complications.

Level of Evidence: Therapeutic Level I. See Instructions for Authors for a complete description of levels of evidence.

Longitudinal studies of unicompartamental knee replacement have demonstrated excellent survivorship and functional outcomes with a greater range of motion and a higher rate of return to work and sport than total knee replacement¹⁻⁴. Unicompartamental knee replacement is associ-

ated with lower mortality (hazard ratio for total knee replacement, adjusted for age and sex, is 1.65 [95% confidence interval (CI), 1.44 to 1.89] compared with unicompartamental knee replacement at zero to 1.5 years according to the Australian Orthopaedic Association National Joint Replacement Registry)⁵, lower rates

Disclosure: One or more of the authors received payments or services, either directly or indirectly (i.e., via his or her institution), from a third party in support of an aspect of this work. In addition, one or more of the authors, or his or her institution, has had a financial relationship, in the thirty-six months prior to submission of this work, with an entity in the biomedical arena that could be perceived to influence or have the potential to influence what is written in this work. No author has had any other relationships, or has engaged in any other activities, that could be perceived to influence or have the potential to influence what is written in this work. The complete **Disclosures of Potential Conflicts of Interest** submitted by authors are always provided with the online version of the article.

of postoperative complications (odds ratio of 2.8 in matched patients)⁶, faster recovery⁷, shorter inpatient stay, and lower costs compared with total knee replacement⁸.

However, all national joint registries have demonstrated a higher revision rate for unicompartmental knee replacement than for total knee replacement^{5,9}. As a result, the procedure has not gained widespread acceptance and the majority of patients suitable for unicompartmental knee replacement continue to receive total knee replacement¹⁰. The most common reasons given for revision of unicompartmental knee replacement in national joint registries are aseptic loosening and pain⁵. Currently, most designs of unicompartmental knee replacements are inserted with cement, and many are performed using a minimally invasive technique. Cementation is challenging in minimally invasive unicompartmental knee replacement, and cementation errors may lead to loosening, pain, and excess wear^{11,12}. It has been suggested that cementless fixation may decrease the prevalence of these problems, reducing the failure rate overall¹³.

In loose joint replacements, the bone-implant (or bone-cement) interface becomes replaced by a layer of soft tissue, manifesting radiographically as a thick, poorly defined radiolucent area, known as a pathological radiolucency¹⁴. Often, a fine, well-defined radiolucent line is present at the bone-cement interface of well-functioning cemented unicompartmental knee replacements and total knee replacements¹⁵⁻¹⁷. These so-called physiological radiolucencies are not associated with pain or loosening, but indicate suboptimal fixation as they demonstrate a layer of fibrocartilage at the interface¹⁸. It is believed that if this layer of fibrocartilage is not present, the fixation will be of higher quality. If a patient complains of persistent pain following a unicompartmental knee replacement and has a physiological radiolucency, surgeons less familiar with these radiolucencies may attribute this pain to the presence of a radiolucent line, and convert the unicompartmental knee replacement to a total knee replacement. These revisions are often unnecessary as anteromedial tibial pain can frequently occur in the early postoperative period and usually resolves spontaneously¹⁹. This may be a result of changes in bone stresses following surgery²⁰.

The most commonly used prosthesis for unicompartmental knee arthroplasty is the Oxford unicompartmental knee replacement (Biomet, Bridgend, United Kingdom)²¹. This device uses a fully congruent mobile bearing to minimize wear and to preserve normal kinematics over the lifetime of the implant. It has been in use for over thirty years, accounts for 70% of unicompartmental knee replacement implantations in the U.K., and is fixed to bone using cement. In specialist centers, the long-term revision rate of the Oxford unicompartmental knee replacement is similar to that of total knee replacement with superior functional outcomes^{3,22,23}. An additional advantage of the mobile bearing is that, aside from the effects of friction, the loads transmitted between the bearing and the femoral and tibial components are almost entirely compressive²⁴. As a result, the loads transmitted across the bone-implant interfaces are also predominantly compressive with minimal shear stress, suggesting that the device may be ideal for cementless fixation.

A modified version of the Oxford unicompartmental knee replacement that allows cementless fixation by the addition of a porous titanium and calcium hydroxyapatite coating, which should rapidly stimulate bone ingrowth and secure long-term fixation, has been introduced. The tibial component of the Oxford unicompartmental knee replacement is flat, allowing accurate assessment of the bone-implant fixation if radiographs are precisely aligned with the tibial component using fluoroscopic guidance. With use of this technique, physiological radiolucencies have been reported to be observed in 60% to 97% of knees with a cemented Oxford unicompartmental knee replacement¹⁶.

As part of the assessment of cementless Oxford unicompartmental knee replacements, a randomized, controlled study was undertaken with the primary aim of comparing the quality of fixation of the cemented and cementless designs of the Oxford unicompartmental knee replacement as evidenced by the prevalence of radiolucent lines. The secondary aim of the study was to compare functional outcomes of patients with these two prostheses. Preliminary results have been published at one year¹³. This study describes the clinical and radiographic outcomes at five years.

Materials and Methods

The trial protocol was registered with the Oxfordshire Research Ethics Committee (C02.101), and ethical approval was granted. From 2003 to 2007, sixty-two patients (sixty-three knees) were recruited for the study following institutional ethical approval. Inclusion criteria were patients with symptomatic end-stage anteromedial osteoarthritis who fulfilled the published criteria for Oxford unicompartmental knee replacement (full-thickness cartilage loss in the medial compartment, full-thickness cartilage preservation in the lateral compartment, and a functionally intact anterior cruciate ligament [ACL] and medial collateral ligament)¹⁹. Anterior knee pain, full-thickness cartilage loss in the patellofemoral joint, obesity, age, or activity level were not considered contraindications to unicompartmental knee replacement²⁵⁻²⁸. Patients who had previously undergone high tibial osteotomy or ACL reconstruction were excluded.

Following randomization, a cemented Oxford unicompartmental knee replacement was implanted in thirty-three knees, and a cementless Oxford unicompartmental knee replacement was implanted in thirty. All patients were assessed prospectively at the preoperative visit and then at six months and at one, two, and five years after surgery, by a research physiotherapist. Both assessor and patient were blinded to the method of fixation used. Clinical assessment included the Oxford Knee Score²⁹, Knee Society Score (functional and objective components)³⁰, and Tegner Activity Score³¹.

In all knees, Oxford Phase-III instrumentation (Biomet) was used to implant prostheses using the minimally invasive surgical technique described elsewhere¹⁹. Intraoperatively, suitability for unicompartmental knee replacement was confirmed by examination of the ACL and articular surfaces in the retained lateral compartment. The choice of implant (cemented or cementless) was determined according to a random sequence generated by computer and recorded in a series of opaque, sealed envelopes. After confirmation of the suitability of the patient for unicompartmental knee replacement, the next envelope in the sequence was opened and the implant was chosen accordingly.

Implant Design and Implantation

Patients in the cemented group received the Oxford Phase-III unicompartmental knee replacement (Biomet). The cementless implant is similar but modified to allow cementless implantation (see Appendix). The tibial component is identical to the cemented version, except that the cement pocket is filled with a layer of

porous titanium and the surfaces in contact with bone are coated with calcium hydroxyapatite. The femoral component is similarly filled with porous titanium and coated with hydroxyapatite on the inner surface. In order to improve primary fixation, its central peg is cylindrical rather than conical (as in the cemented version), and there is another, smaller peg anteriorly to confer rotational stability. The anterior part of the femoral component extends an additional 17° to allow implantation in a more flexed position and to support the anterior peg. Neither the femoral pegs nor the vertical lateral wall are covered with porous titanium, but both are coated with hydroxyapatite. Aside from these modifications, the cementless femoral component is identical to the cemented version. Identical mobile meniscal bearings, manufactured from direct compression-molded ultra-high molecular weight polyethylene, were used in both groups.

The operative technique for implantation with cement is described in detail elsewhere¹⁹. To secure good primary fixation in cementless implantation, a specially designed, so-called toothbrush saw is used to create a narrower keel slot than that used with cemented implantation, and both components are firmly impacted after implantation. The femoral component is implanted between 5° and 10° flexed relative to the position required for the cemented prosthesis to minimize the risk of shear forces at the interface in high flexion. The operative technique is otherwise identical to that used for the cemented implant. Surgery was performed by one of six surgeons. Most knee arthroplasties (78%; forty-nine of sixty-three) were performed by one of three senior surgeons (D.W.M., C.A.F.D., and A.J.P.) with extensive experience with cemented Oxford unicompartmental knee replacements. The remaining procedures were performed by one of three senior trainees under direct or indirect supervision of one of the three senior surgeons. The postoperative program was identical for the two groups, with early weight-bearing encouraged in all patients.

Postoperative Follow-up and Data Collection

Data on the operative findings, implant sizes, and operative time were recorded at the time of surgery. Patients were seen for functional assessment by the same blinded physiotherapist who used the same scores as were collected preoperatively and at six months and one, two, and five years following surgery. Complications that occurred between visits were reported to the research physiotherapist who recorded them contemporaneously. Immediately after surgery and at six months, one year, and five years postoperatively, anteroposterior and lateral radiographs were made using a technique designed to produce an accurate image of the bone-implant interface. The radiographs were made under fluoroscopic guidance, by adjusting the x-ray beam until it was parallel to the bone-implant interface (either the underside of the tibial component on the anteroposterior radiograph or the flat, posterior surface of the femoral component on the lateral radiograph), before the definitive image was recorded digitally¹⁶. Radiographs were assessed by two assessors blinded to the clinical outcome. Radiolucencies were defined as being physiological (<2 mm in depth, with a sclerotic margin, appearing within the first postoperative year before remaining unchanged on subsequent radiographs) or pathological (thick, progressive, and not associated with a sclerotic margin). The area under the tibial component was divided into six zones (Fig. 1); if all six zones were involved, the radiolucency was considered complete, and if fewer than six zones were involved, the radiolucency was considered partial (see Appendix). In common with previous studies of the cemented Oxford unicompartmental knee replacement, we considered the vertical, lateral wall to be non-weight-bearing and did not record or attach any importance to radiolucencies present in this zone^{16,32}.

Statistical Analysis

A power calculation was performed with the expectation that the frequency of radiolucencies in knees with a cemented Oxford unicompartmental knee replacement would be 70%, with a halving of this figure in the cementless group being considered clinically important. For 80% power, with a significance level set at 0.05, thirty patients were required per group. Using values for functional outcomes recorded in a previous large study of cemented Oxford unicompartmental knee replacements³, a difference of 6 points for the Oxford Knee Score, 10 points for the Knee Society objective score, 12 points for the Knee Society functional score, and 1 point for the Tegner Activity Score would attain significance at the same power with the same sample size.

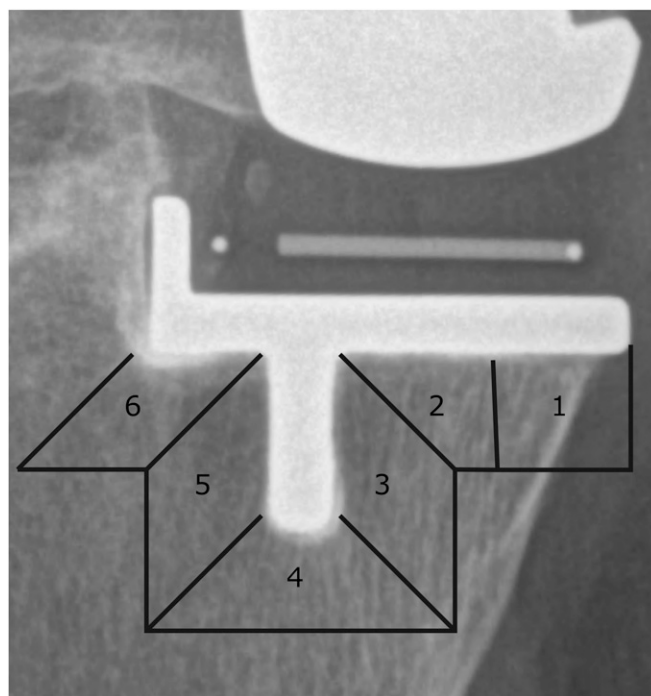


Fig. 1
Six zones of radiolucency below the tibial tray of the Oxford unicompartmental knee replacement.

Each outcome score was analyzed both as an absolute score preoperatively and at one, two, and five years postoperatively, and as change from the preoperative scores at the same follow-up intervals (one, two, and five-year change in the Oxford Knee Score, Knee Society functional score, Knee Society objective score, and Tegner Activity Score). Descriptive statistics revealed normal distribution of surgical duration, preoperative scores, and change scores, but negative skewness of one and five-year data. Negative logarithmic transformations were performed to transform the data distribution to normality and parametric tests (independent-samples t tests) were used for duration of surgery and all functional scores. Tables with results contain nontransformed data. The Fisher exact test was used to compare the proportion of radiolucencies in the two groups.

Source of Funding

Biomet, the manufacturer of the implant, partially funded the study but was not involved in the planning or undertaking of the study. Support for this study was received from the National Institute for Health Research (NIHR) Biomedical Research Unit into Musculoskeletal Disease. Mr. Liddle was supported by a Royal College of Surgeons Surgical Research Fellowship.

Results

The study groups were well matched for age (mean, 63.8 years [range, forty-six to seventy-eight years] in the cemented group and 64.7 years [range, forty-five to eighty-two years] in the cementless group), sex (a male-to-female ratio of 20:12 [63% male] in the cemented group and a ratio of 16:14 [53% male] in the cementless group), and body mass index (mean, 28.9 kg/m² [range, 20.1 to 37.7 kg/m²] in the cemented group and 27.9 kg/m² [range, 21.3 to 39.9 kg/m²] in the cementless group). There was no significant difference between the preoperative scores of the two groups on any measure.

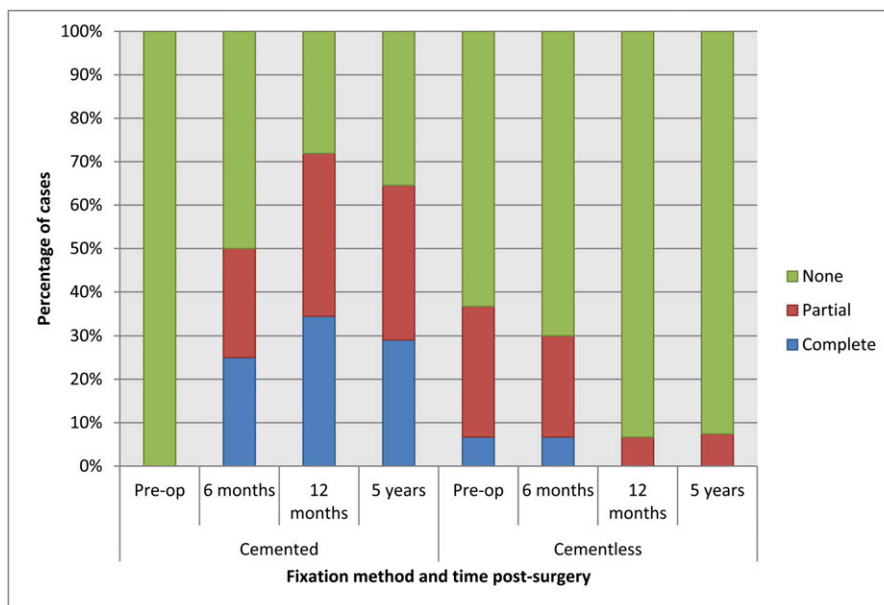


Fig. 2
Percentage of partial and complete radiolucencies on the immediate postoperative radiograph and at six months, one year, and five years postoperatively.

There were no revisions. One patient (in the cemented group) died within six months after surgery, and three additional patients (two in the cementless group and one in the cemented group) died, all from causes unrelated to the unicompartmental knee replacement, in the second through fifth years. One patient in the cementless group left the study because of poor health also between the second and fifth years. Final clinical analysis was performed on fifty-eight patients (thirty-one in the cemented group and twenty-seven in the cementless group). One patient in the cemented group had moved out of our catchment area after the first year and was unable to attend for his final radiographic follow-up, completing his functional assessments by mail; final radiographic analysis was therefore performed on fifty-seven patients.

One patient in the cemented group developed complex regional pain syndrome and continued to experience symptoms despite medical treatment (at five years, the Oxford Knee Score was 8 [the change in the score was -13], Knee Society functional score was 40, Knee Society objective score was 9, and the Tegner Activity Score was 2). One patient in the cementless group developed a postoperative hematoma and underwent exploration, lavage, and bearing exchange on day 10. This patient recovered fully and had no further surgery. There were no other complications. The mean surgical time (expressed as the time that the patient was in the operating room) was 95.7 minutes (range, sixty-five to 135 minutes) in the cemented group and 86.5 minutes (range, fifty to 110 minutes) in the cementless group; the difference was significant ($p = 0.049$).

Radiographic Outcome (see Appendix)

At five years, there was no evidence of femoral or tibial loosening, indicated by either implant subsidence or a pathological radiolucency, in either group. No radiolucency of any type was

observed adjacent to the femoral component in any patient in either group at any stage. At five years, one patient in the cementless group had radiographic evidence of progression of osteoarthritis, with narrowing of the joint space in the retained lateral compartment. The patient was asymptomatic, and the functional scores remained excellent (the Oxford Knee Score was 45, the Knee Society functional score was 100, the Knee Society objective score was 85, and the Tegner Activity Score was 3). None of the remaining five-year radiographs demonstrated any adverse features.

Twenty of thirty-one knees (thirty patients) in the cemented group had a physiological radiolucency at five years compared with two of twenty-seven patients in the cementless group; the difference was significant ($p < 0.001$). All radiolucencies were <1 mm thick. Both radiolucencies in the cementless group were partial; nine of the twenty radiolucencies in the cemented group were complete. Therefore, complete radiolucencies were seen in nine of thirty knees in the cemented group compared with zero of twenty-seven knees in the cementless group ($p = 0.01$). There was no progression of radiolucencies in the cementless group from one to five years, and radiolucencies that were evident immediately and at six months postoperatively had resolved by one year (Fig. 2). In the cemented group, radiolucencies developed over the first year and remained stable. There was complete agreement on radiographic findings between the two assessors.

Functional Outcome

Overall, all functional scores were significantly improved at one and five years compared with preoperative scores. Scores remained stable from the first to the fifth postoperative year (Table I).

At two and five years, neither the absolute score nor the change in the Oxford Knee Score displayed any significant

TABLE I Clinical Outcomes at One, Two, and Five Years*

	Preop.	1 Yr	2 Yr	5 Yr
Oxford Knee Score				
Cemented group	21.7 ± 6.4	39.0 ± 9.2	38.8 ± 9.0	39.0 ± 10.4
Cementless group	21.1 ± 6.1	41.7 ± 5.3	41.5 ± 6.5	39.4 ± 9.9
Knee Society Score objective component				
Cemented group	44.2 ± 17.7	87.7 ± 10.8	80.6 ± 18.1	80.1 ± 19.3
Cementless group	41.6 ± 11.1	88.1 ± 8.4	84.5 ± 13.5	78.8 ± 14.0
Knee Society Score functional component				
Cemented group	60.6 ± 12.6	87.5 ± 16.0	86.6 ± 14.5	78.8 ± 18.4†
Cementless group	60.3 ± 13.8	90.5 ± 11.7	91.5 ± 12.9	92.0 ± 12.7†
Tegner Activity Score				
Cemented group	1.9 ± 0.8	2.9 ± 0.9	2.5 ± 0.8‡	2.6 ± 0.8
Cementless group	1.9 ± 0.7	3.1 ± 1.1	3.1 ± 1.1‡	2.9 ± 0.6

*The values are given as the mean and the standard deviation. †The difference was significant ($p = 0.003$). ‡The difference was significant ($p = 0.04$).

difference between the groups (Fig. 3). At five years, the mean Oxford Knee Score (and standard deviation) was 39.0 ± 10.4 in the cemented group and 39.4 ± 9.9 in the cementless group ($p = 0.88$); the mean change in the Oxford Knee Score was 17.9 ± 9.7 in the cemented group and 18.4 ± 9.5 in the cementless group ($p = 0.84$). At five years, the mean Knee Society functional score demonstrated a significantly superior outcome in the cementless group both for absolute (92.0 ± 12.7 versus 78.8 ± 18.4 ; $p = 0.003$) and change scores ($30.8 \pm$

17.1 versus 16.4 ± 17.8 ; $p = 0.003$), although there was no significant difference in either score at two years (Fig. 4). The minimum clinically important difference in the Knee Society functional score has been estimated at between 11.5 and 20.5 points³³, which suggests a clinically important difference in our cohort. The five-year difference remains significant if the patient with complex regional pain syndrome is excluded (the mean score for the cemented group increases to 80.17 ± 17.2 [$p = 0.005$] for absolute Knee Society functional score

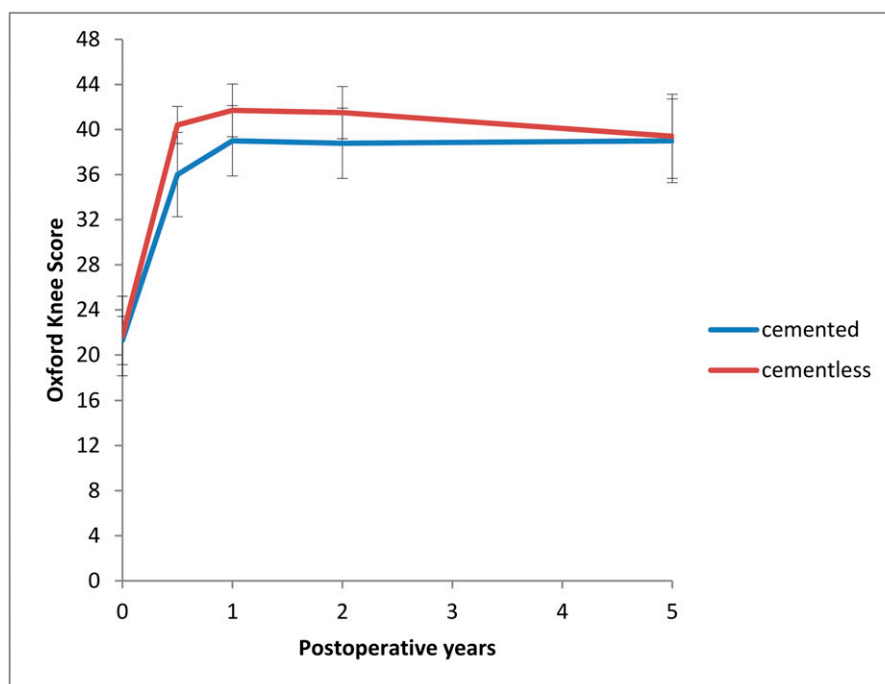


Fig. 3
The mean Oxford Knee Scores (and 95% confidence interval) for each group, demonstrating the stability of the scores beyond the first postoperative year.

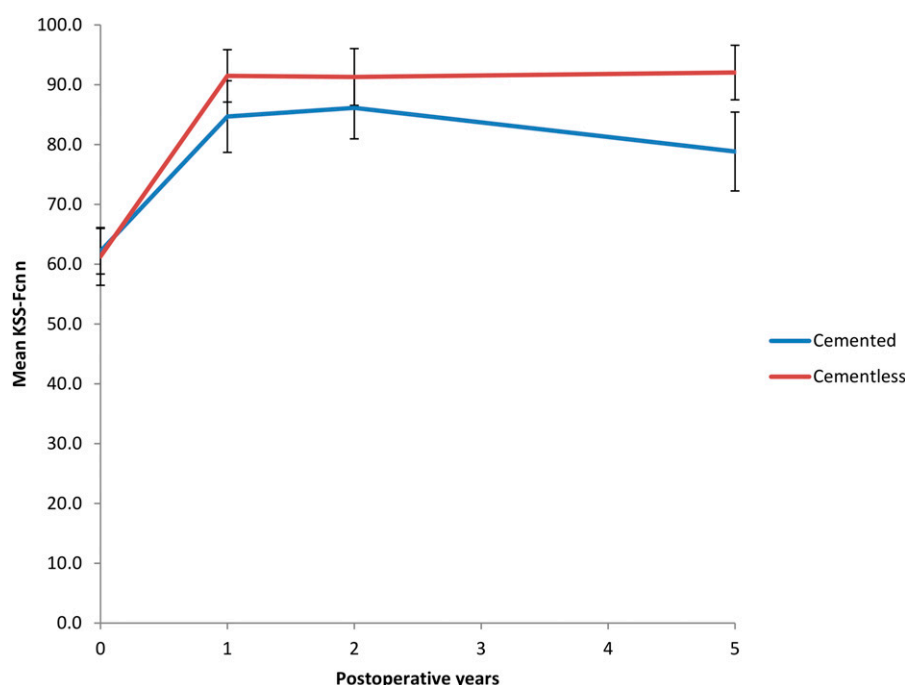


Fig. 4
The mean Knee Society Scores (KSS) (and 95% confidence interval) for function (Fcn) for both groups.

and to 17.59 ± 17.01 [$p = 0.007$] for the change in the Knee Society functional score). The Tegner Activity Score is significantly better in the cementless group at two years (mean, 3.1 ± 1.1 versus 2.5 ± 0.8 ; $p = 0.04$), but the difference did not persist to five years. Neither the Knee Society objective score nor the change in that score demonstrated a significant difference between groups at any time point. No significant change in clinical outcome in each group or overall was detected following the first year.

Discussion

This study demonstrates that cementless fixation of the Oxford unicompartmental knee replacement is associated with a significantly reduced prevalence of radiolucencies compared with cemented fixation at five years, with equivalent or superior functional outcomes. There were no complete radiolucencies in the cementless group, indicating secure fixation in all knees. Radiolucencies did not progress between one and five years, suggesting that once the cementless component is securely fixed, it will remain so for subsequent years. The elimination of cementation conferred the additional advantage of reducing the operative time by a mean of over nine minutes. Although it was not formally assessed, the surgeons involved in the study found the procedure was simpler when it was performed without cement than when it was performed with cement. As well as being quicker, the cementless technique appears to be forgiving of a suboptimal method of implantation, as evidenced by the radiolucencies associated with inadequate seating of the tibial tray disappearing within the first year.

This study was powered to detect a significant difference in radiographic outcomes, and a larger number of patients

would be required to achieve sufficient power to determine a difference in functional outcome. While the apparent superior functional performance of the cementless implant by a single outcome measure is encouraging and may be a manifestation of improved fixation, we would treat this with a degree of caution until it is replicated in studies with larger numbers. However, on the basis of this study, we conclude that the functional outcome of the cementless prosthesis is at least as good as the cemented prosthesis at five years.

The cementless Oxford unicompartmental knee replacement was introduced to improve the reliability of fixation in unicompartmental knee replacement and to exclude failures resulting from errors in cementation. Aseptic loosening accounts for 48.3% of revisions of unicompartmental knee replacements in the Australian Orthopaedic Association National Joint Replacement Registry⁵; improved fixation should decrease the prevalence of aseptic loosening, which should have a profound effect on the revision rate of unicompartmental knee replacement as demonstrated in national joint registries.

Occasionally, pain occurs early after unicompartmental knee replacements and then tends to improve spontaneously¹⁹. However, if pain is associated with radiolucency, the implant may be considered to be loose and require revision. We expect a decrease in the prevalence of radiolucency to result in a decreased prevalence of revision for unexplained pain, which is the second most common cause of revision (behind loosening) in national joint registries^{5,9}. Other problems associated with cement and cementation technique may be prevented by the use of cementless fixation. Loose fragments of cement can cause pain and mechanical symptoms within the knee and may need to be removed arthroscopically³⁴; excess cement that is not removed

may prevent normal bearing movement and lead to excess wear and failure¹¹, and components that are not fully seated because of excess cement may tighten the soft tissues, causing pain¹⁹.

Concerns about the quality of tibial fixation have limited the use of cementless designs of total knee replacement following early reports of high rates of failure secondary to tibial loosening³⁵. The prevalence of loosening is likely to be lower for the Oxford unicompartmental knee replacement as the use of a mobile bearing reduces shear forces transmitted across the bone-implant interface. As a result, the forces across the bone-implant interface are almost entirely compressive³⁶, which is ideal for cementless fixation. In contrast, a total knee replacement has shear and tensile forces, which are less conducive to effective cementless fixation. This assertion is supported by the results of this study, which show evidence of reliable fixation at five years, and particularly by the fact that all thirteen knees that did not demonstrate adequate seating on postoperative radiographs had good evidence of fixation at one year and beyond.

The size of the study population limits the conclusions we can draw about complications or contraindications. A large, prospective, multicenter study is necessary to fully assess the complications and contraindications to cementless fixation. Following satisfactory one-year results from the patients in the present report, we recruited such a cohort and 1000 patients have currently reached a minimum of one year of follow-up. This cohort has demonstrated an early complication rate similar to that of the cemented prosthesis with no additional contraindications³². As a result, we now exclusively use cementless fixation in the setting of primary unicompartmental knee replacement.

On the basis of the results of this randomized controlled trial demonstrating improved fixation, and the large cohort demonstrating no increase in complications, we believe the cementless device should be used more widely. We anticipate that the widespread use of the cementless device

will result in a lower failure rate for unicompartmental knee replacement.

Appendix

eA A table showing the radiographic outcomes at one, two, and five years and figures demonstrating the cementless Oxford unicompartmental knee replacement and radiolucencies associated with a cemented prosthesis and a cementless prosthesis are available with the online version of this article as a data supplement at jbjs.org. ■

NOTE: The authors thank Barbara Marks, Jo Brown, and Jenny Ferris for their contribution to the preparation of the manuscript and the data presented therein. We also thank the radiographers who produced the radiographs analyzed in this paper. Finally, we thank the patients who participated in the study.

H. Pandit, DPhil, FRCS(Orth)
A.D. Liddle, BSc, MRCS
B.J.L. Kendrick, BSc, FRCS(Orth)
A.J. Price, DPhil, FRCS(Orth)
D.W. Murray, MD, FRCS(Orth)
Nuffield Department of Orthopaedics,
Rheumatology and Musculoskeletal Sciences,
University of Oxford,
Botnar Research Centre,
Windmill Road, Headington,
Oxford OX3 7LD, United Kingdom.
E-mail address for D.W. Murray: david.murray@ndorms.ox.ac.uk

C. Jenkins, MSc
C.A.F. Dodd, FRCS
Nuffield Orthopaedic Centre,
Windmill Road, Headington,
Oxford OX3 7HE, United Kingdom

H.S. Gill, DPhil
University of Bath,
Claverton Down,
Bath BA2 7AY, United Kingdom

References

- Price AJ, Rees JL, Beard DJ, Gill RH, Dodd CA, Murray DM. Sagittal plane kinematics of a mobile-bearing unicompartmental knee arthroplasty at 10 years: a comparative in vivo fluoroscopic analysis. *J Arthroplasty*. 2004 Aug;19(5):590-7.
- Walton NP, Jahromi I, Lewis PL, Dobson PJ, Angel KR, Campbell DG. Patient-perceived outcomes and return to sport and work: TKA versus mini-incision unicompartmental knee arthroplasty. *J Knee Surg*. 2006 Apr;19(2):112-6.
- Pandit H, Jenkins C, Gill HS, Barker K, Dodd CA, Murray DW. Minimally invasive Oxford phase 3 unicompartmental knee replacement: results of 1000 cases. *J Bone Joint Surg Br*. 2011 Feb;93(2):198-204.
- Lisowski LA, van den Bekerom MP, Pilot P, van Dijk CN, Lisowski AE. Oxford Phase 3 unicompartmental knee arthroplasty: medium-term results of a minimally invasive surgical procedure. *Knee Surg Sports Traumatol Arthrosc*. 2011 Feb;19(2):277-84.
- Australian Orthopaedic Association National Joint Replacement Registry Annual Report. 2011. <https://aoanjrr.dmac.adelaide.edu.au/documents/10180/44800/Annual%20Report%202011?version=1.2&t=1347337258367>. Accessed 2012 Jun 1.
- Brown NM, Sheth NP, Davis K, Berend ME, Lombardi AV, Berend KR, Della Valle CJ. Total knee arthroplasty has higher postoperative morbidity than unicompartmental knee arthroplasty: a multicenter analysis. *J Arthroplasty*. 2012 Sep;27(8)(Suppl):86-90.
- Lombardi AV Jr, Berend KR, Walter CA, Aziz-Jacobo J, Cheney NA. Is recovery faster for mobile-bearing unicompartmental than total knee arthroplasty? *Clin Orthop Relat Res*. 2009 Jun;467(6):1450-7.
- Willis-Owen CA, Brust K, Alsop H, Miraldo M, Cobb JP. Unicompartmental knee arthroplasty in the UK National Health Service: an analysis of candidacy, outcome and cost efficacy. *Knee*. 2009 Dec;16(6):473-8.
- UK National Joint Registry 9th Annual Report. 2012. http://www.njrcentre.org.uk/njrcentre/Portals/0/Documents/England/Reports/9th_annual_report/NJR%209th%20Annual%20Report%202012.pdf. Accessed 2012 Jun 1.
- Arno S, Maffei D, Walker PS, Schwarzkopf R, Desai P, Steiner GC. Retrospective analysis of total knee arthroplasty cases for visual, histological, and clinical eligibility of unicompartmental knee arthroplasties. *J Arthroplasty*. 2011 Dec;26(8):1396-403. Epub 2011 Feb 25.
- Kendrick BJ, Longino D, Pandit H, Svard U, Gill HS, Dodd CA, Murray DW, Price AJ. Polyethylene wear in Oxford unicompartmental knee replacement: a retrieval study of 47 bearings. *J Bone Joint Surg Br*. 2010 Mar;92(3):367-73.
- Dervin GF, Carruthers C, Feibel RJ, Giachino AA, Kim PR, Thurston PR. Initial experience with the Oxford unicompartmental knee arthroplasty. *J Arthroplasty*. 2011 Feb;26(2):192-7.
- Pandit H, Jenkins C, Beard DJ, Gallagher J, Price AJ, Dodd CA, Goodfellow JW, Murray DW. Cementless Oxford unicompartmental knee replacement shows reduced radiolucency at one year. *J Bone Joint Surg Br*. 2009 Feb;91(2):185-9.
- Mukherjee K, Pandit H, Dodd CA, Ostlere S, Murray DW. The Oxford unicompartmental knee arthroplasty: a radiological perspective. *Clin Radiol*. 2008 Oct;63(10):1169-76.

- 15.** Ecker ML, Lotke PA, Windsor RE, Cella JP. Long-term results after total condylar knee arthroplasty. Significance of radiolucent lines. *Clin Orthop Relat Res.* 1987 Mar;(216):151-8.
- 16.** Gulati A, Chau R, Pandit HG, Gray H, Price AJ, Dodd CA, Murray DW. The incidence of physiological radiolucency following Oxford unicompartmental knee replacement and its relationship to outcome. *J Bone Joint Surg Br.* 2009 Jul;91(7):896-902.
- 17.** Voss F, Sheinkop MB, Galante JO, Barden RM, Rosenberg AG. Miller-Galante unicompartmental knee arthroplasty at 2- to 5-year follow-up evaluations. *J Arthroplasty.* 1995 Dec;10(6):764-71.
- 18.** Kendrick BJ, James AR, Pandit H, Gill HS, Price AJ, Blunn GW, Murray DW. Histology of the bone-cement interface in retrieved Oxford unicompartmental knee replacements. *Knee.* 2012 Dec;19(6):918-22.
- 19.** Goodfellow J, O'Connor J, Dodd CA, Murray D. Unicompartmental arthroplasty with the Oxford knee. 1st ed. Oxford: Goodfellow; 2011.
- 20.** Simpson DJ, Price AJ, Gulati A, Murray DW, Gill HS. Elevated proximal tibial strains following unicompartmental knee replacement—a possible cause of pain. *Med Eng Phys.* 2009 Sep;31(7):752-7.
- 21.** UK National Joint Registry 8th Annual Report. 2011. <http://www.njrcentre.org.uk/njrcentre/portals/0/documents/NJR%208th%20annual%20report%202011.pdf>. Accessed 2012 June 1.
- 22.** Price AJ, Svard U. A second decade lifetable survival analysis of the Oxford unicompartmental knee arthroplasty. *Clin Orthop Relat Res.* 2011 Jan;469(1):174-9.
- 23.** Vorlat P, Putzeys G, Cottenie D, Van Isacker T, Pouliart N, Handelberg F, Casteleyn PP, Gheysen F, Verdonk R. The Oxford unicompartmental knee prosthesis: an independent 10-year survival analysis. *Knee Surg Sports Traumatol Arthrosc.* 2006 Jan;14(1):40-5.
- 24.** O'Connor JJ, Goodfellow JW, Dodd CA, Murray DW. Development and clinical application of meniscal unicompartmental arthroplasty. *Proc Inst Mech Eng H.* 2007 Jan;221(1):47-59.
- 25.** Beard DJ, Pandit H, Gill HS, Hollinghurst D, Dodd CA, Murray DW. The influence of the presence and severity of pre-existing patellofemoral degenerative changes on the outcome of the Oxford medial unicompartmental knee replacement. *J Bone Joint Surg Br.* 2007 Dec;89(12):1597-601.
- 26.** Beard DJ, Pandit H, Ostlere S, Jenkins C, Dodd CA, Murray DW. Pre-operative clinical and radiological assessment of the patellofemoral joint in unicompartmental knee replacement and its influence on outcome. *J Bone Joint Surg Br.* 2007 Dec;89(12):1602-7.
- 27.** Liddle AD, Pandit H, Jenkins C, Price AJ, Dodd CA, Gill HS, Murray DW. Preoperative pain location is a poor predictor of outcome after Oxford unicompartmental knee arthroplasty at 1 and 5 years. *Knee Surg Sports Traumatol Arthrosc.* 2012 Sep 22. Epub 2012 Sep 22.
- 28.** Pandit H, Jenkins C, Gill HS, Smith G, Price AJ, Dodd CA, Murray DW. Unnecessary contraindications for mobile-bearing unicompartmental knee replacement. *J Bone Joint Surg Br.* 2011 May;93(5):622-8.
- 29.** Murray DW, Fitzpatrick R, Rogers K, Pandit H, Beard DJ, Carr AJ, Dawson J. The use of the Oxford hip and knee scores. *J Bone Joint Surg Br.* 2007 Aug;89(8):1010-4.
- 30.** Insall JN, Dorr LD, Scott RD, Scott WN. Rationale of the Knee Society clinical rating system. *Clin Orthop Relat Res.* 1989 Nov;(248):13-4.
- 31.** Tegner Y, Lysholm J. Rating systems in the evaluation of knee ligament injuries. *Clin Orthop Relat Res.* 1985 Sep;(198):43-9.
- 32.** Liddle AD, Pandit H, O'Brien S, Doran E, Penny ID, Hooper GJ, Burn PJ, Dodd CA, Beverland DE, Maxwell AR, Murray DW. Cementless fixation in Oxford unicompartmental knee replacement: a multicentre study of 1000 knees. *Bone Joint J.* 2013 Feb;95(2):181-7.
- 33.** Roos EM, Engelhart L, Ranstam J, Anderson AF, Irrgang JJ, Marx RG, Tegner Y, Davis AM. ICRS recommendation document: patient-reported outcome instruments for use in patients with articular cartilage defects. *Cartilage.* 2011 Apr;2(2):122-36.
- 34.** Clark M, Campbell DG, Kiss G, Dobson PJ, Lewis PL. Reintervention after mobile-bearing Oxford unicompartmental knee arthroplasty. *Clin Orthop Relat Res.* 2010 Feb;468(2):576-80.
- 35.** Duffy GP, Berry DJ, Rand JA. Cement versus cementless fixation in total knee arthroplasty. *Clin Orthop Relat Res.* 1998 Nov;(356):66-72.
- 36.** O'Connor JJ, Goodfellow JW. Theory and practice of meniscal knee replacement: designing against wear. *Proc Inst Mech Eng H.* 1996;210(3):217-22.