

Improving Breast Cancer Surgery: A Classification and Quadrant per Quadrant Atlas for Oncoplastic Surgery

Krishna B. Clough, MD, Gabriel J. Kaufman, MD, Claude Nos, MD, Ines Buccimazza, MD, and Isabelle M. Sarfati, MD

Department of Surgery, The Paris Breast Center (L'Institut du Sein), Paris, France

ABSTRACT

Background. Oncoplastic surgery (OPS) has emerged as a new approach for extending breast conserving surgery (BCS) possibilities, reducing both mastectomy and re-excision rates, while avoiding breast deformities. OPS is based upon the integration of plastic surgery techniques for immediate reshaping after wide excision for breast cancer. A simple guide for choosing the appropriate OPS procedure is not available.

Objective. To develop an Atlas and guideline for oncoplastic surgery (OPS) to help in patient selection and choice of optimal surgical procedure for breast cancer patients undergoing BCS.

Methods. We stratify OPS into two levels based on excision volume and the complexity of the reshaping technique. For resections less than 20% of the breast volume (level I OPS), a step-by-step approach allows easy reshaping of the breast. For larger resections (level II OPS), a mammoplasty technique is required.

Results. We identified three elements that can be used for patient selection and for determination of the appropriate OPS technique: excision volume, tumor location, and glandular density. For level II techniques, we defined a quadrant per quadrant Atlas that offers a different mammoplasty for each quadrant of the breast.

Conclusions. OPS is the “third pathway” between standard BCS and mastectomy. The OPS classification and Atlas improves patient selection and allows a uniform approach for surgeons. It proposes a specific solution for different scenarios and helps improve breast conservation outcomes.

INTRODUCTION

Breast Conservation Limitations

Breast conservation surgery (BCS) combined with post-operative radiotherapy has become the preferred locoregional treatment for the majority of patients with early-stage breast cancer, with equivalent survival to that of mastectomy and improved body image and lifestyle scores. The success of BCS for breast cancer is based on the tenet of complete removal of the cancer with adequate surgical margins, while preserving the natural shape and appearance of the breast. Achieving both goals together in the same operation can be challenging, and BCS has not always produced good cosmetic results in all patients. One of the limiting factors is the amount of tissue removed, not only in terms of absolute volume but also in relation to tumor location and relative size of breast. If either of these two goals is not obtainable, mastectomy is often proposed to the patient. An alternative is to downsize the tumor preoperatively with either chemotherapy or hormone therapy. However, not all tumors respond to neoadjuvant treatment. The failure of classical BCS techniques to offer solutions for challenging scenarios has stimulated the growth and advancement of new techniques in breast surgery during the past decade.

Oncoplastic Surgery Defined

Oncoplastic surgery (OPS) has emerged as a new approach to allow wide excision for BCS without compromising the natural shape of the breast. It is based upon integration of plastic surgery techniques for immediate breast reshaping after wide excision for breast cancer. The conceptual idea of OPS is not new, and its oncologic efficacy in terms of margin status and recurrence compare favorably with traditional BCS.¹⁻⁴

Oncoplastic techniques for breast conservation range from simple reshaping and mobilization of breast tissue to more advanced mammoplasty techniques that allow resection of up to 50% of the breast volume. Our goal is to develop a clear classification system of oncoplastic techniques and outline a systematic approach for all breast surgeons to follow when undertaking BCS.

ONCOPLASTIC PRINCIPLES: SELECTION CRITERIA

Elements for Selection

We identify three elements to select patients who would benefit from an oncoplastic approach for BCS. The two factors already recognized as major indications for OPS are excision volume and tumor location.⁵ The third additional element we evaluate is glandular density. When taken into consideration together, these three elements comprise a sound guideline for determining when and what type of OPS to perform and, more importantly, to reduce the guesswork in performing BCS.

Excision Volume

The first element, excision volume, is the single most predictive factor of surgical outcome and potential for breast deformity. Studies have suggested that, once 20% of the breast volume is excised, there is a clear risk of deformity.⁶ Excision volume compared to the total breast volume is estimated preoperatively. Through systematic determination of specimen weights, accurate preoperative estimation of excision volume can be achieved. The average specimen from BCS weighs 20–40 g; as a general rule 80 g of breast tissue is the maximum weight that can be removed from a medium-sized breast without resulting in deformity.

OPS techniques allow for significantly greater excision volumes while preserving natural breast shape. All OPS studies have demonstrated that an average of 200 g up to 1000 g or more can be removed from a medium to large sized breast during BCS with no cosmetic compromise.⁷ Reshaping of the breast is based upon the rearrangement of breast parenchyma to create a homogenous redistribution of volume loss. This redistribution can be achieved easily though either advancement or rotation of breast tissue into the lumpectomy cavity. Others advocate the harvesting of a latissimus dorsi “miniflap” to fill in the defect. This volume replacement technique has been recently described by Rainsbury.⁵ In general, this approach is reserved for small-sized breasts and will not be discussed here.

Tumor Location

The location of the tumor is the second factor in planning OPS. There are zones that are at high risk of deformity during BCS when compared with more forgiving locations. The upper outer quadrant of the breast is a favorable location for large-volume excisions. In this location, defects can readily be corrected by mobilization of adjacent tissue. Excision from less favorable locations, such as the lower pole or upper inner quadrants of the breast, often creates a major risk for deformity. For example, a “bird’s beak” deformity is classically seen on excision of tumors from the lower pole of the breast.¹ Therefore, a key tool used in planning the appropriate surgical approach is evaluating the tumor location and the associated risk of deformity. For extensive resections, we have developed an oncoplastic Atlas of surgical techniques based on tumor location. This Atlas provides a specific mammoplasty technique for each segment of the breast.

Glandular Density

Glandular density is the final component of a complete OPS evaluation before surgery and is evaluated both clinically and radiographically. Although the clinical exam is reliable, mammographic evaluation is a more reproducible approach for breast density determination. Breast density predicts the fatty composition of the breast and determines the ability to perform extensive breast undermining and reshaping without complications. Breast density can be classified into four categories based on the Breast Imaging Reporting and Data System (BIRADS): fatty (1), scattered fibroglandular (2), heterogeneously dense (3) or extremely dense breast tissue (4).⁸

Undermining the breast from both the skin and pectoralis muscle (dual-plane undermining) is a major requirement to perform level I OPS. A dense glandular breast (BIRADS 3/4) can easily be mobilized by dual-plane undermining without risk of necrosis. Low-density breast tissue with a major fatty composition (BIRADS 1/2) has a higher risk of fat necrosis after extensive undermining. Low breast density should provoke the decision to either limit the amount of undermining during level I OPS or proceed to a level II OPS that requires only posterior undermining, leaving the skin attached.

Oncoplastic Classification System

We propose a new classification of OPS techniques into two levels based upon the amount of tissue excised and the relative level of surgical difficulty. A level I approach is based on dual-plane undermining, including the nipple–areola complex (NAC), and NAC recentralization if nipple

deviation is anticipated. No skin excision is required. Level II techniques allow major volume resection. They encompass more complex procedures derived from breast reduction techniques. These “therapeutic mammoplasties” involve extensive skin excision and breast reshaping.⁹ They result in a significantly smaller, rounder breast.

Bilevel Classification

Our bilevel classification system leads to a practical guide of OPS techniques (Table 1). This guide allows for selection of the most appropriate OPS procedure during surgical planning.

- I. If less than 20% of the breast volume is excised, a level I procedure is often adequate. These procedures can be performed by all breast surgeons without specific training in plastic surgery.
- II. Anticipation of 20–50% breast volume excision will require a level II procedure with excision of excess skin to reshape the breast. They are based upon mammoplasty techniques and require specific training in OPS.

Another major consideration in the patient selection criteria is glandular density. If the breast parenchyma is fatty in composition, it may be risky to use a level I technique. Therefore, when planning a large resection in a fatty breast, employing a level II procedure will result in a safer outcome and better cosmetic result.

TABLE 1 Oncoplastic decision guide

Criteria	Level I	Level II
Maximum excision volume ratio	20%	20–50%
Requirement of skin excision for reshaping	No	Yes
Mammoplasty	No	Yes
Glandular characteristics	Dense	Dense or fatty

TABLE 2 Level I OPS: step-by-step surgical approach

Procedure	Result
Skin incision	Allows wide access for excision and reshaping
Skin undermining	Facilitates wide excision and glandular mobilization for reshaping
NAC undermining	Avoids displacement of nipple towards excision defect
Full-thickness excision	Prevents anterior and posterior margin involvement
Glandular reapproximation	Late-occurring deformity is avoided
Deepithelialization and NAC repositioning	Recenters NAC on new breast mound

General Considerations for all OPS Techniques and Patient Counseling

Although oncoplastic procedures can provide high satisfaction with the final breast shape and in some situations may avoid the need for mastectomy, OPS may result in longer and multiple scars. The patient should be aware of the possible asymmetry caused by level II OPS. Because of the extensive resection, an asymmetry in volume is expected compared with the contralateral breast. This asymmetry may require immediate symmetrization of the contralateral side if desired by the patient, or can be performed as a second-stage procedure.

All oncoplastic procedures begin with the preoperative marking of the patient sitting in the upright position prior to induction of anesthesia. Once marked, both breasts are draped into the operative field for comparison. The patient is centered on the operating room table to accommodate both the supine and upright position, as she will be transitioned between these positions to allow optimal reshaping and symmetry. The patient is then secured into place with either arms extended, for access to the axilla, or both arms at the sides if no axillary surgery is needed.

STEP-BY-STEP APPROACH FOR LEVEL I OPS

There are six steps for level I OPS (Table 2; Figs. 1, 2). They begin with skin incision (1) followed by undermining of the skin (2) and NAC (3). After completion of undermining, a full-thickness glandular excision is performed from the subcutaneous fat to the pectoralis fascia (4). The glandular defect is closed with tissue reapproximation (5). If required, an area in the shape of a crescent bordering the areola is deepithelialized and the NAC is repositioned (6).

Oncoplastic surgery is based upon allowing wide excisions with free margins, not on minimizing incision length. Short incisions limit mobilization of the gland and do not permit creation of adequate glandular flaps to fill in excision defects. This effective mobilization of the gland is a key component of breast reshaping after wide excisions.

FIG. 1 Level I OPS: surgical concept. **1** Initial extensive skin undermining. **2** Excision of the lesion from subcutaneous tissue to pectoralis fascia. **3** Reapproximation and suturing of the gland

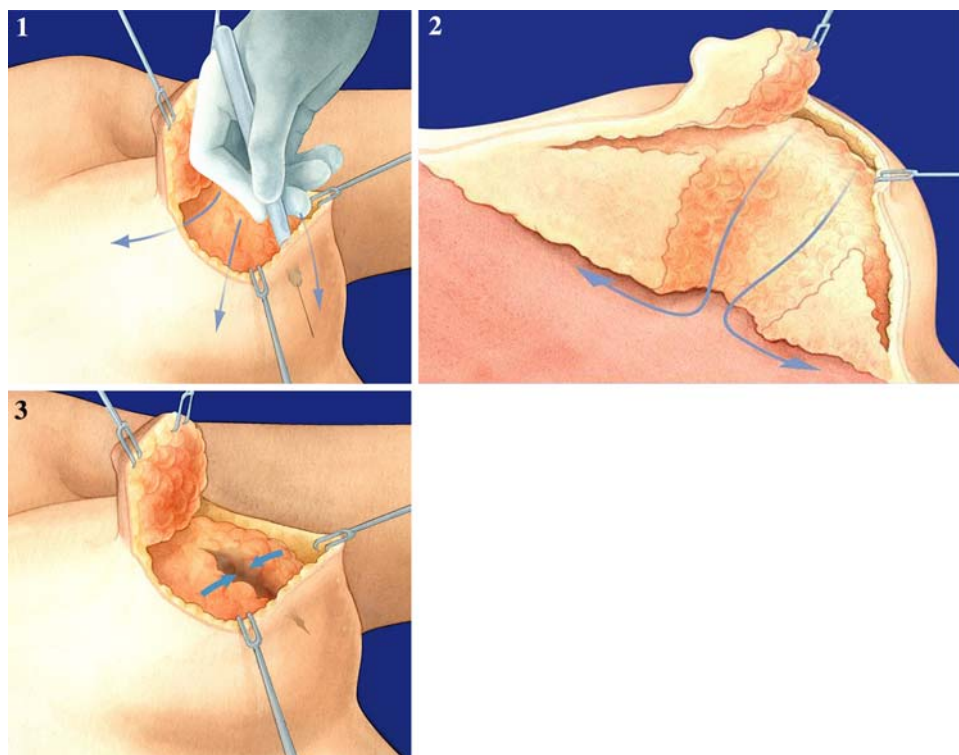
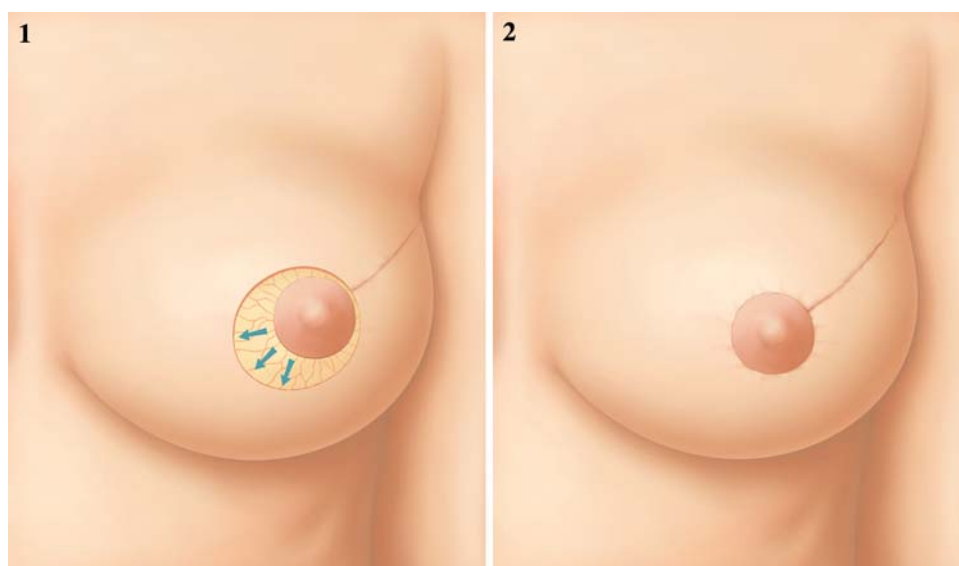


FIG. 2 Level I OPS: nipple recentralization. **1** A skin crescent is deepithelialized opposite to the lumpectomy bed in the upper-outer quadrant. **2** NAC is recentralized to avoid NAC deviation post lumpectomy



The location of the incision is at the discretion of the operating surgeon. All incisions should allow for both en bloc excision of the cancer, without causing fragmentation of the specimen, and extensive undermining to facilitate reshaping. For level I procedures, if a direct incision over the tumor is chosen, the general principle is to follow Kraissl's lines of tension to limit visible scarring.¹⁰ However, in many cases an indirect incision along the areola border is possible and can be extended by a radial extension towards the tumor.

Skin Undermining

One of the key factors of level I OPS techniques is extensive subcutaneous undermining. It is easier to undermine the skin before excising the lesion. The undermining follows the mastectomy plane and extends anywhere from one-fourth to two-thirds of the surface area of the breast envelope. Extensive skin undermining facilitates both tumor resection and glandular redistribution after removal of the tumor. The area of undermining should be

reduced if risk factors for fat necrosis are present. The two main risk factors are smoking history and fatty composition of the breast.

NAC Undermining

Extensive resections lead to NAC deviation towards the excision area. NAC repositioning is easily performed with simple undermining: this is a key component of both level I and II OPS. The first step is to completely transect the terminal ducts and separate the NAC from the underlying breast tissue. A width of 0.5–1 cm of attached glandular tissue is maintained to ensure the integrity of the vascular supply. This appropriate amount of subareolar tissue prevents NAC necrosis and avoids venous congestion. Ultimately, the level of NAC sensitivity may be reduced after extensive mobilization and undermining.¹¹

Glandular Resection

Our standard approach is to perform full-thickness excisions from the subcutaneous fat underlying the skin down to the pectoralis fascia. A full-thickness excision ensures free anterior and posterior margins, leaving only the lateral margins in question. The breast parenchyma itself is excised in a fusiform pattern oriented towards the NAC. This shape facilitates reapproximation of the remaining gland. Before closing the defect, metal clips are placed on the pectoralis muscle and lateral edges of the resection bed to guide future radiotherapy.

Defect Closure

During standard BCS, breast tissue is either reapproximated or left open, allowing for the eventual formation of a hematoma or seroma. Seroma formation, however, does not always result in predictable long-term cosmetic results for larger-volume excisions. Once reabsorption of the seroma occurs, the excision cavity becomes prominent due to fibrosis and retraction of the surrounding tissue, creating a noticeable defect and causing NAC displacement towards the previous excision cavity. Extensive resections require closing the cavity and redistribution of the volume loss. Tissue can be mobilized from lateral positions of the remaining gland or recruited from the central portion of the breast. This allows creation of glandular flaps that are sutured together to close the defect.

NAC Repositioning

Avoiding NAC displacement is a key element for both levels I and II OPS. An unnatural position of the NAC

deviated towards the excision site can be one of the major sources of patient dissatisfaction after BCS. This result should be expected after all extensive volume resections. NAC repositioning is difficult to attempt after radiotherapy; therefore, immediate recentralization is preferred and should be anticipated during initial resection.¹² An area of periareolar skin opposite the excision defect is deepithelialized in the shape of a crescent. For level I procedures, the width of deepithelialization can measure up to 6 cm. Deepithelialization should be achieved sharply, using a scalpel blade or fine scissors. This technique is simple and safe, and is used systematically in aesthetic surgery of the breast. The vascular supply of the NAC after its separation from the gland and deepithelialization is based on the dermal vasculature.¹³

LEVEL II ONCOPLASTIC SURGERY

A major consideration when choosing between OPS levels is the extent of excision volume. A level I approach is suitable for excision volumes less than 20% of the entire gland. In most quadrants, the resulting glandular defect can usually be filled by advancement of adjacent tissue. Level II techniques are reserved for situations that require major volume excisions of 20–50%. They are based upon different mammoplasty techniques. To simplify the selection of the appropriate technique, we devised an Atlas based on tumor location. This Atlas does not contain an exhaustive list of options, but provides one or two surgical techniques for each tumor location. Existing mammoplasty techniques were initially adapted for OPS for specific tumor locations such as lower-pole cancers.^{1,14,15} In other locations, such as the lower inner and upper outer quadrants, a series of new mammoplasty techniques were created to serve for breast cancer treatment.¹⁶

TABLE 3 Level II OPS: quadrant per quadrant Atlas (orientation for left breast)

Clock position	Procedures
5–7 o'clock Lower pole	Superior pedicle mammoplasty/ inverted T or vertical scar
7–8 o'clock Lower inner quadrant	Superior pedicle mammoplasty/V scar
9–11 o'clock Upper inner quadrant	Batwing
12 o'clock Upper pole	Inferior pedicle mammoplasty or round block mammoplasty
1–2 o'clock Upper outer quadrant	Racquet mammoplasty/radial scar
4–5 o'clock Lower outer quadrant	Superior pedicle mammoplasty/J scar
Central subareolar	Inverted T or vertical-scar mammoplasty with NAC resection

The superior pedicle reduction mammoplasty will serve as a model for the technical description of all mammoplasty techniques. Schematically rotating the NAC pedicle opposite the site of tumor excision allows the application of this technique for a variety of tumor locations. These procedures are listed in a clockwise direction and described for the left breast (Table 3).

Because of the volume excised, level II OPS will generally result in a breast that is smaller, rounder, and higher than the contralateral breast. Thus, the need for

contralateral symmetrization should be discussed in the preoperative setting. Either immediate or delayed symmetrization can be performed depending on the amount of tissue resection and the desire of the patient.

Lower-Pole Location (5–7 O'clock)

General Principles The lower pole of the breast was the first recognized high-risk location for deformity (Picture 1).^{1,15,17} Retraction of the skin and downward

PICTURE 1 1, 2 “Birds beak” deformity of the lower pole

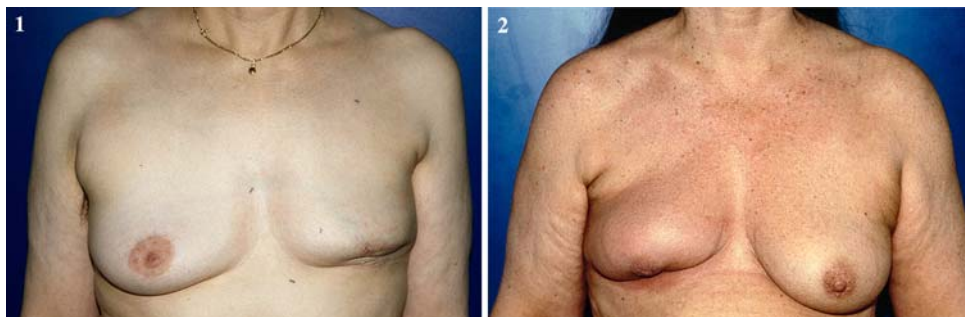
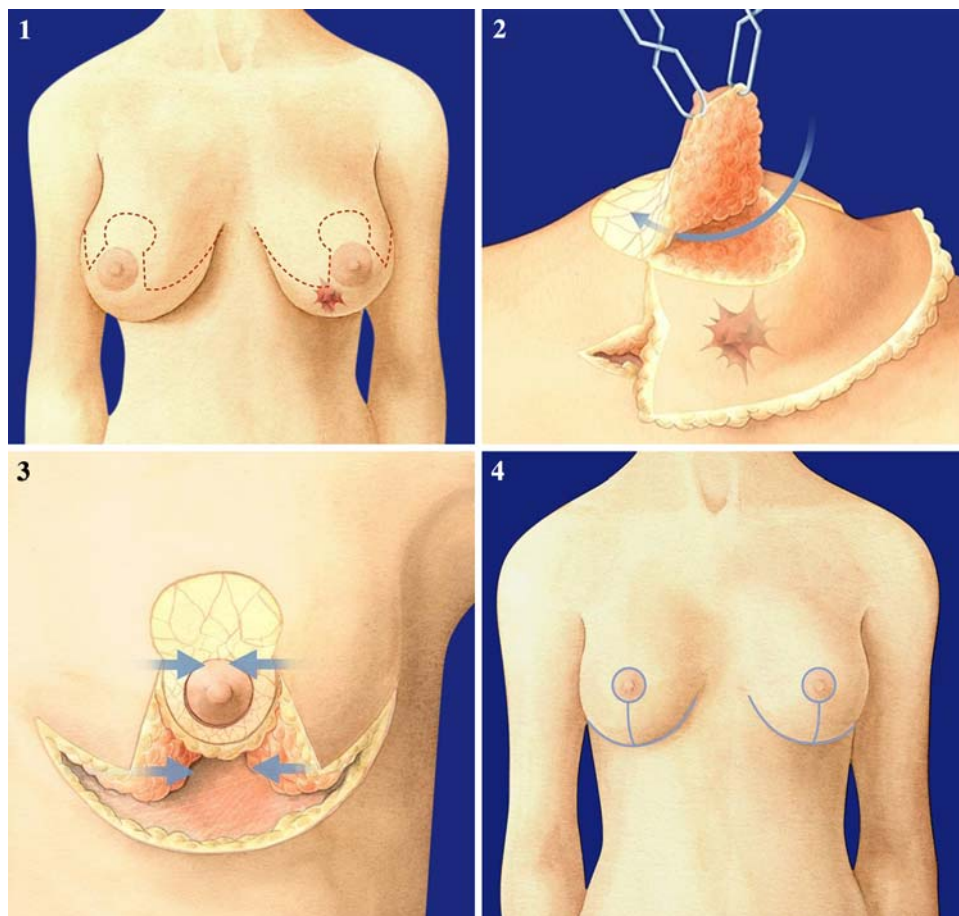
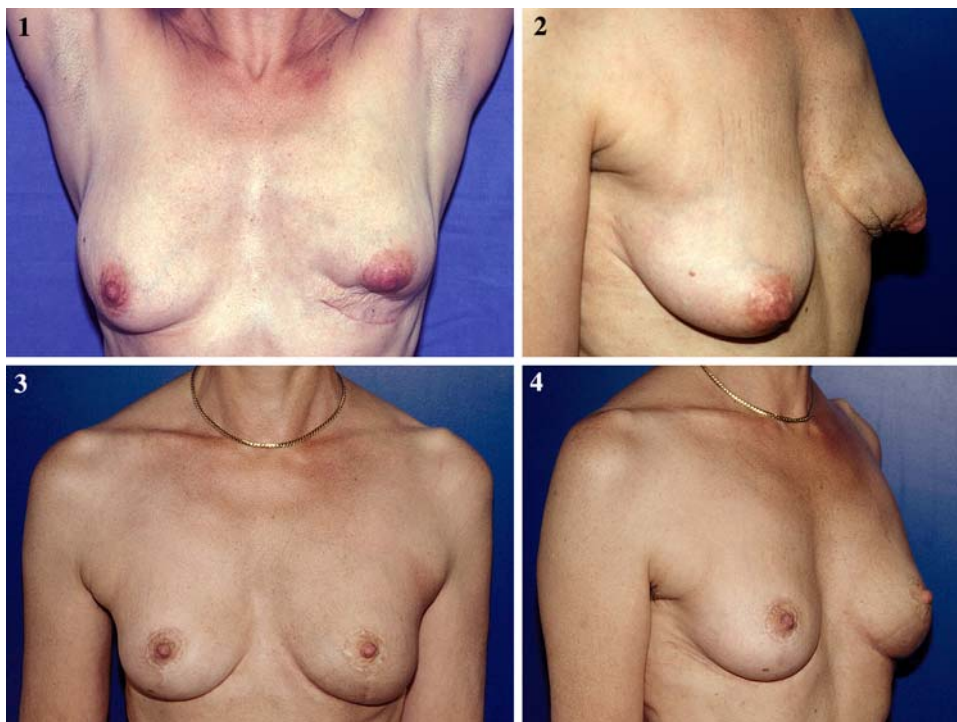


FIG. 3 Level II OPS: superior pedicle mammoplasty for lower pole lesion (6 o'clock). 1 Preoperative drawings. 2 Superior pedicle deepithelialized and elevated. 3 Reapproximation of medial and lateral glandular flaps after wide excision. 4 Final result after reshaping and contra lateral symmetrization



PICTURE 2 Re-excision of lower-pole lesion for positive margins. The patient was offered mastectomy prior to consultation, however, utilizing a level II OPS technique both negative margins and a natural shape of the breast were achieved. **1** After first resection patient has both deformity and positive margins. **2** Deformity of lower pole. **3, 4** Results after mammoplasty and left breast radiotherapy



deviation of the NAC resulting from excision of tissue from the 6 o'clock position became known as the "bird's beak" deformity. A superior pedicle mammoplasty can allow for large-volume excision at the lower pole without causing NAC deviation with the added benefit of breast reshaping.

Technique: Superior Pedicle Mammoplasty with Inverted T Scar/Vertical Scar The superior pedicle mammoplasty technique that we routinely use results in inverted T and periareolar scars as seen in most breast reduction patients. The procedure has been described in detail in a previous paper (Fig. 3).¹⁸ It begins with deepithelialization of the area surrounding the NAC. The NAC is then dissected away from the underlying breast tissue on a superior dermoglandular pedicle. The inframammary incision is then completed, followed by wide undermining of the breast tissue off the pectoralis fascia. The undermining starts inferiorly and then proceeds superiorly beneath the tumor while encompassing the medial and lateral aspects of the breast as well as the NAC. The tumor is removed en bloc with a large margin of normal breast tissue and overlying skin as determined by the preoperative drawings.

Mobilization of the breast tissue from the pectoralis muscle allows for palpation of both the deep and superficial surfaces of the tumor, improving the ability to

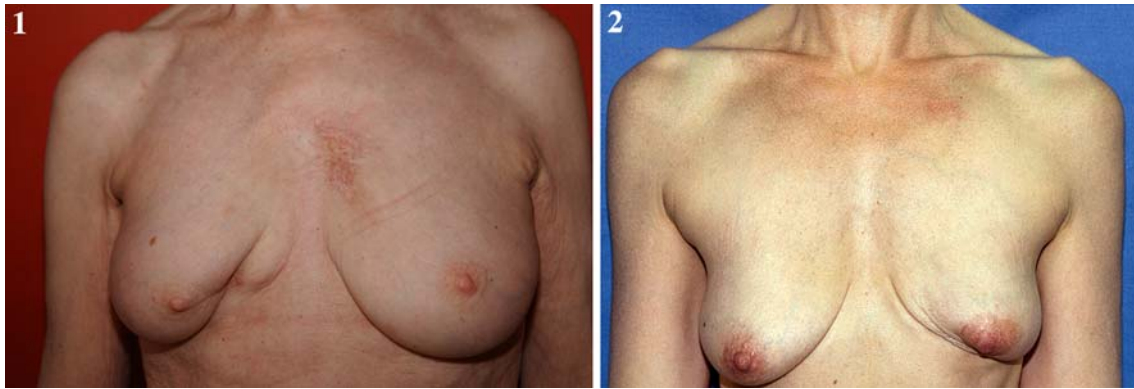
obtain adequate lateral margins. Once the resection is completed, the breast is reshaped by reapproximation of the medial and lateral glandular columns towards the midline to fill in the defect, followed by NAC recentralization (Picture 2).

One possible modification to this technique is the vertical-scar mammoplasty described by Lejour and Lassus.^{19,20} The site and volume of excision are identical to the inverted T-scar, but this approach avoids the sub-mammary scar.

A new approach for patients with moderate- to small-sized breasts who present with lower-pole tumors near the inframammary fold has recently been described by Nos. This technique is based on the creation of a fascio-cutaneous flap and harvesting of underlying fatty tissue below the inframammary fold. The flap is then rotated to fill in the area of defect created by the segmental excision of the cancer.²¹

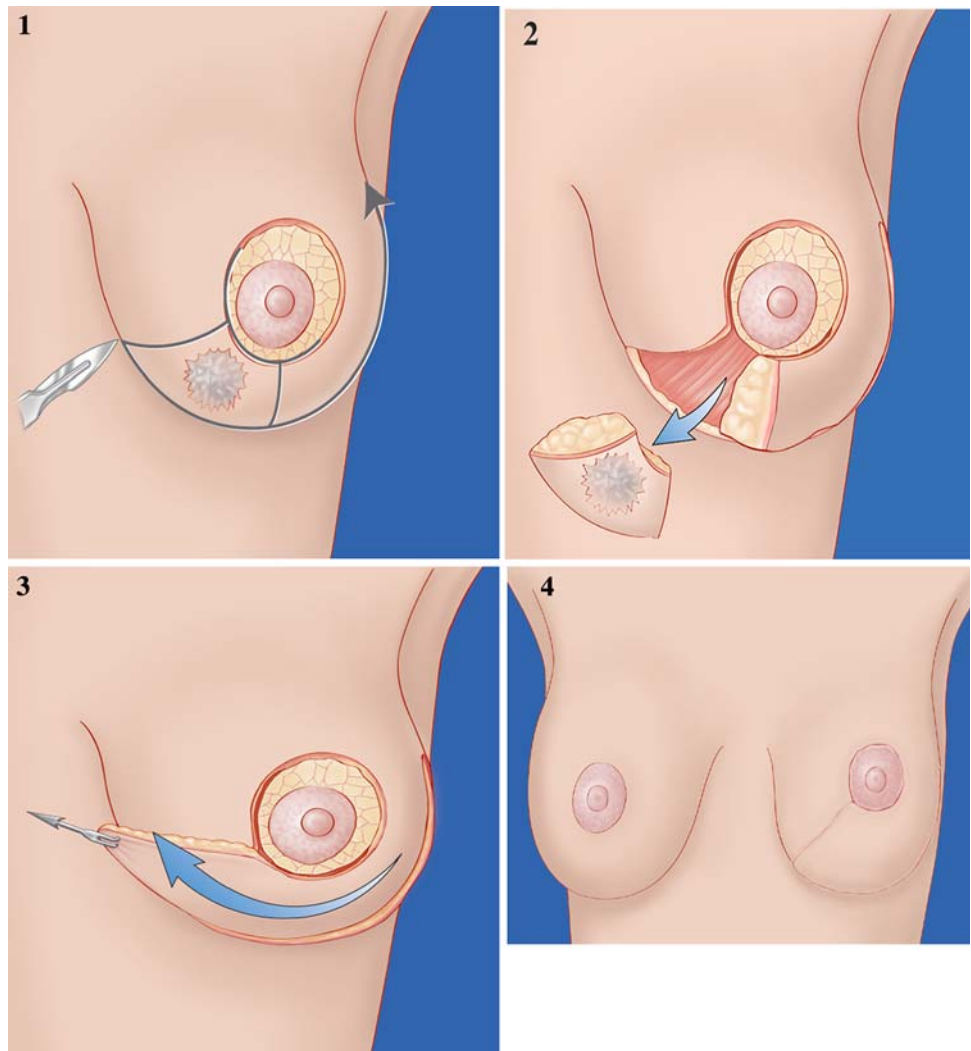
Lower Inner Quadrant (7–9 O'clock)

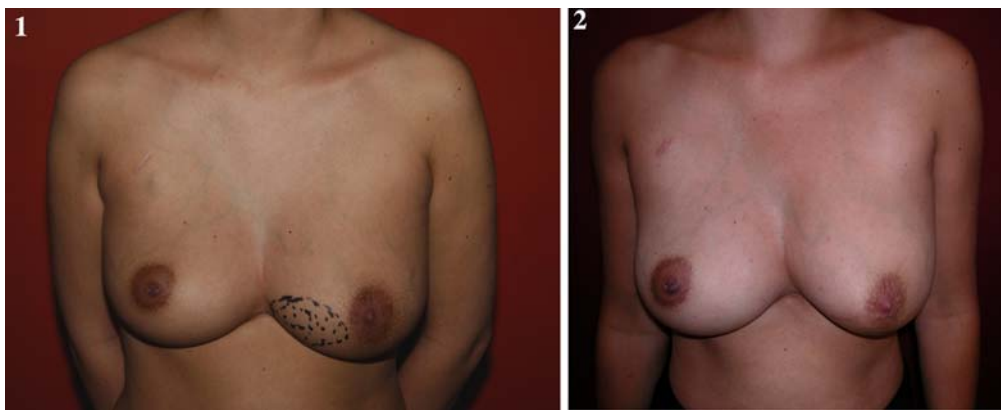General Principles Superior pedicle mammoplasty can be used for tumors located from 5 to 7 o'clock. However, adaptation for tumors located more medially, between 7 and 9 o'clock, is more difficult and requires a novel level II technique (Picture 3).²²



PICTURE 3 1, 2 Lower inner quadrant deformity

FIG. 4 Level II OPS: V-mammoplasty for lower inner quadrant (7–8 o'clock). **1** Preoperative drawings. **2** Full-thickness excision and inframammary incision. **3** Medial rotation of lateral glandular flap to fill in the defect and reshape the breast. **4** Resulting scars





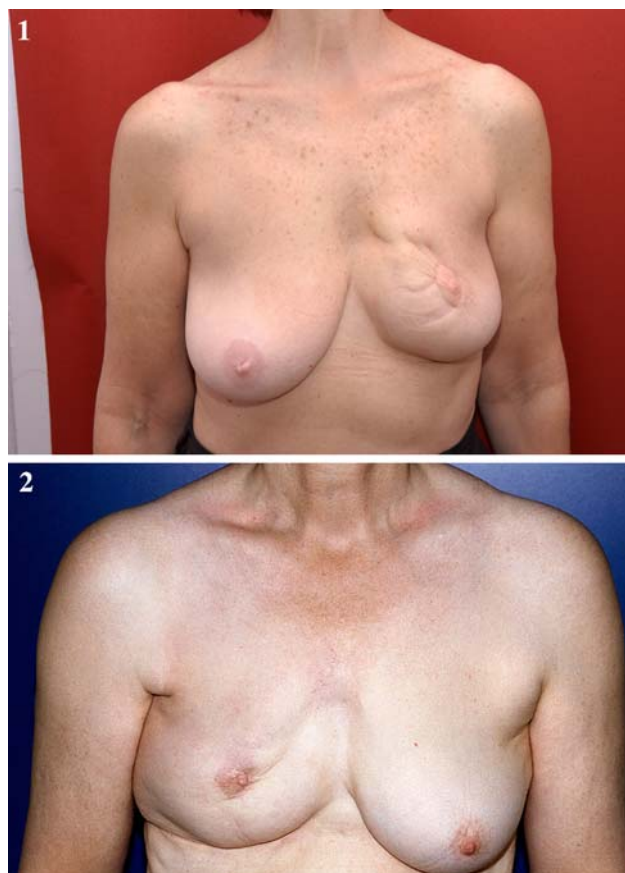
PICTURE 4 V-Mammoplasty. 1 Patient underwent neoadjuvant treatment; however, extensive microcalcifications required wide excision of lesion. 2 Natural shape of breast maintained after excision

Technique: V-Mammoplasty This procedure involves excising a pyramidal section of gland, with its base located in the submammary fold and apex at the border of the areola. The section is removed en bloc, including the skin attached to the gland down to the pectoralis fascia. The submammary fold is then incised, from the resection site to the anterior axillary line. The incision is taken laterally as far as necessary to perform adequate rotation of the remaining gland into the defect. The lower pole of the breast is then entirely undermined off the pectoralis muscle and is transferred medially to fill the defect. The NAC is then recentralized on a deepithelialized superior-lateral pedicle (Picture 4; Fig. 4).

Upper Inner Quadrant (10–11 O'clock)

Special caution is needed when considering BCS for lesions in the upper inner quadrant of the breast. A wide excision in this location can have a significant impact on the overall quality of the breast shape by distorting the visible breast line known as the “décolleté” (Picture 5).

For moderate resections, level I techniques can be utilized safely. For more extensive excisions, we currently have not developed a standard level II oncoplastic procedure that reliably addresses the limitations of BCS at this troublesome location. Silverstein has described an effective OPS procedure to address the upper inner quadrant. His approach utilizes a batwing excision pattern.²³ Silverstein’s OPS solution is innovative and reproducible; however, more research is needed when performing large excisions exceeding 20% of the breast volume in this area.



PICTURE 5 1, 2 Upper inner quadrant deformity

Upper Pole (11–1 O'clock)

General Principles Excision of lesions located at the 12 o'clock position rarely causes a deformity (Picture 6), as

they can be excised widely followed by volume redistribution with tissue from the central location. For large excision volumes (Picture 6), repair of upper-pole resections can be accomplished through an inferior pedicle mammoplasty. This mammoplasty is commonly performed in the United States as a breast reduction technique and utilizes an inverted T-scar pattern.²⁴ Another possible approach is a round block mammoplasty with a periareolar scar.

Techniques: Inferior Pedicle Mammoplasty The skin markings are identical to those described for the superior pedicle. The resection, however, is located in the upper pole; hence, the vascular supply of the NAC is based on its inferior and posterior glandular attachments. The inferior pedicle is deepithelialized and advanced upwards towards

the excision defect to achieve volume redistribution. Complementary resection is performed in the inner and outer lower quadrants to optimize the breast shape (Fig. 5).

Round Block Mammoplasty The round block mammoplasty utilizes a periareolar incision and was originally described by Benelli.^{25,26} The procedure starts by making two concentric periareolar incisions, followed by deepithelialization of the intervening skin. The outer edge of deepithelialization is incised and the entire skin envelope is undermined in a similar manner to performing a mastectomy. The NAC remains vascularized by its posterior glandular base. Wide excision of the tumor and surrounding tissue is performed from the subcutaneous plane down to the pectoralis fascia. The medial and lateral glandular flap are then mobilized off the pectoralis muscle

PICTURE 6 1, 2 Upper pole deformity

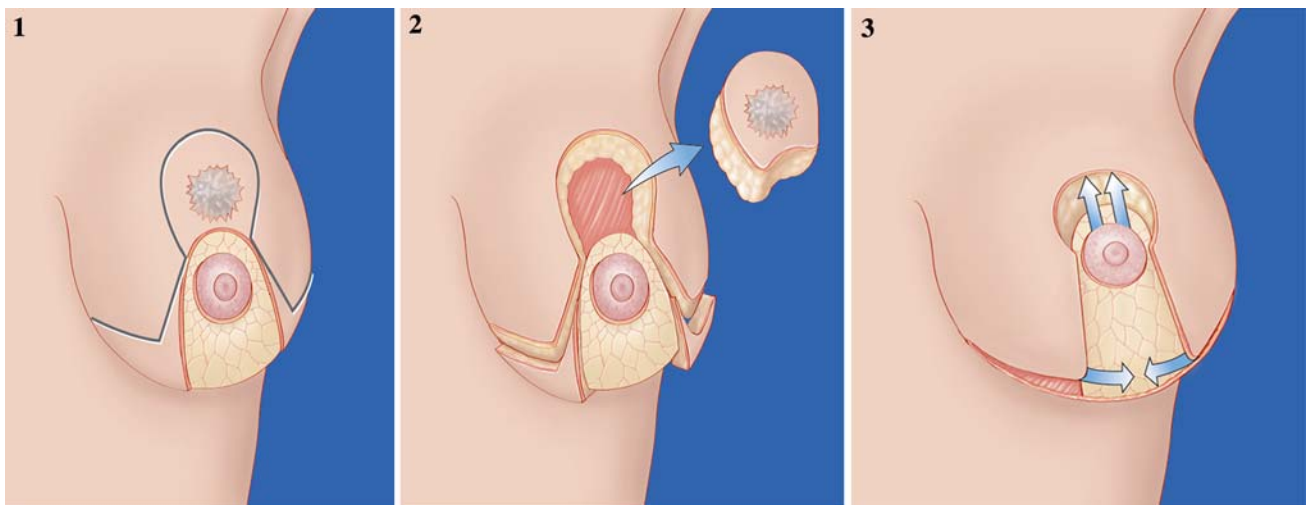
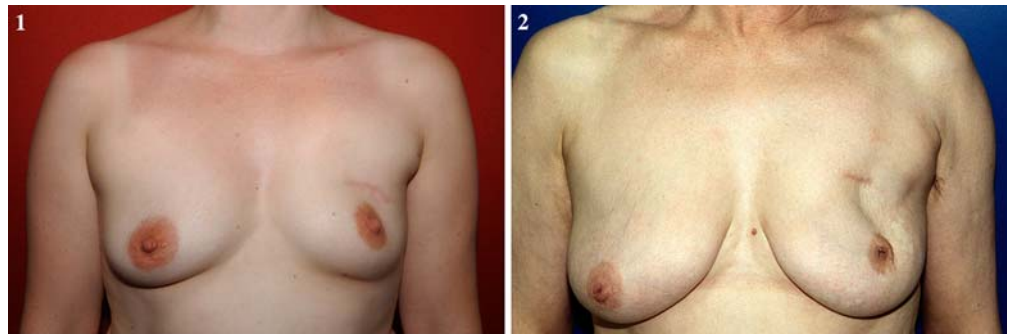
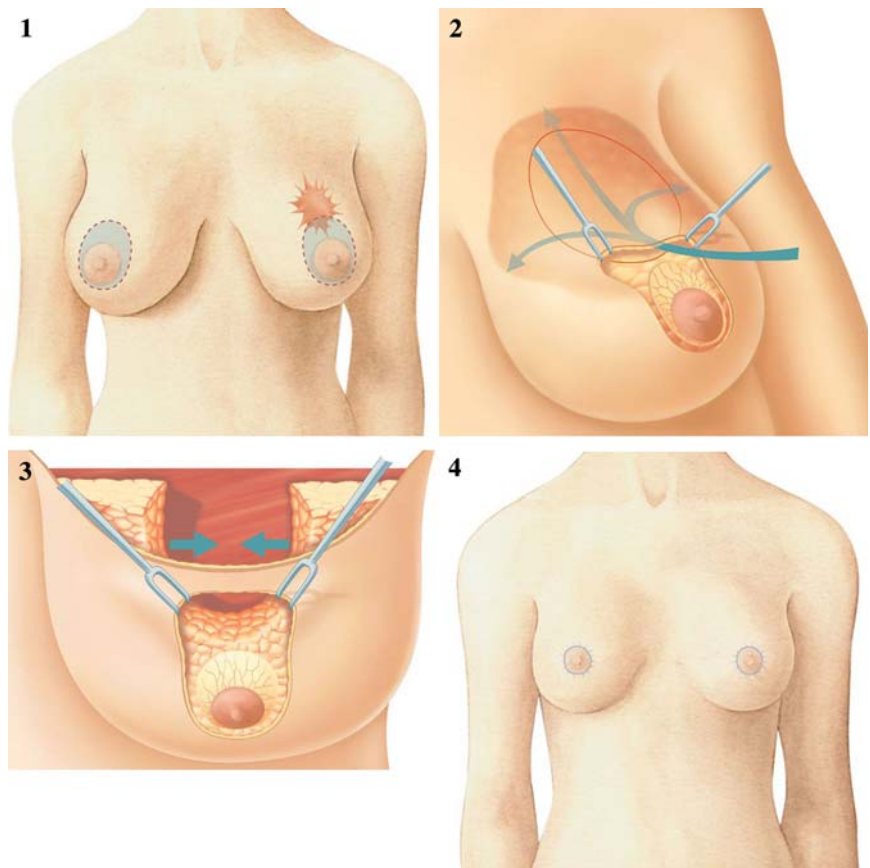
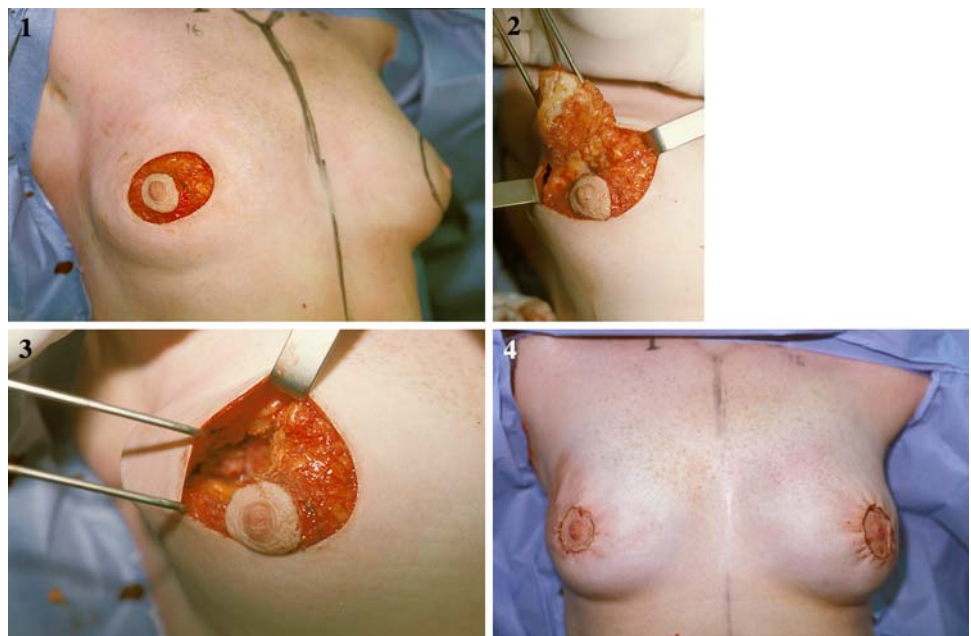


FIG. 5 Level II OPS: Inferior pedicle mammoplasty for 12 o'clock tumors. **1** Preoperative drawings. Inferior pedicle deepithelialized. **2** Tumor resection. Complementary resection of medial and lateral pillars. **3** Advancement of inferior pedicle into the defect and skin closure

FIG. 6 Level II OPS: round block technique for upper pole lesion (11–1 o'clock). **1** Skin drawing and concentric periareolar incisions. **2** Circumferential skin undermining. **3** Reapproximation of the glandular flaps. **4** Resulting scars



PICTURE 7 Round block: 3-cm invasive lobular cancer in the upper pole, patient undergoing round block. **1** Incision. **2** Tumor removal. **3** Excision cavity. **4** Final result



and sutured together. The periareolar incisions are then approximated, resulting only in a periareolar scar. Although we have used the round block mammoplasty initially for upper-pole tumors, it is a versatile technique that can be

easily adapted for tumors in any location of the breast. It is a challenging technique as the reduced skin excision mandates sophisticated glandular reshaping (Picture 7; Fig. 6).

Upper Outer Quadrant (1–3 O'clock)

General Principles This is the most “forgiving” of all quadrants. In this quadrant, large lesions can often be excised with standard BCS without causing deformity. However, resection of greater than 20% of the breast volume will result in retraction of the overlying skin with NAC displacement towards the excision site (Picture 8). Level II OPS can be utilized to increase

resection possibilities while limiting the risk of postoperative deformities.

Technique: Racquet Mammoplasty A large portion of the upper outer quadrant can be excised utilizing a direct incision over the tumor, from the NAC towards the axilla, similar to a quadrantectomy.^{27,28} After wide excision, the reshaping is performed by mobilizing lateral and central gland into the cavity and suturing it together. Central gland

PICTURE 8 1, 2 Upper outer quadrant deformity

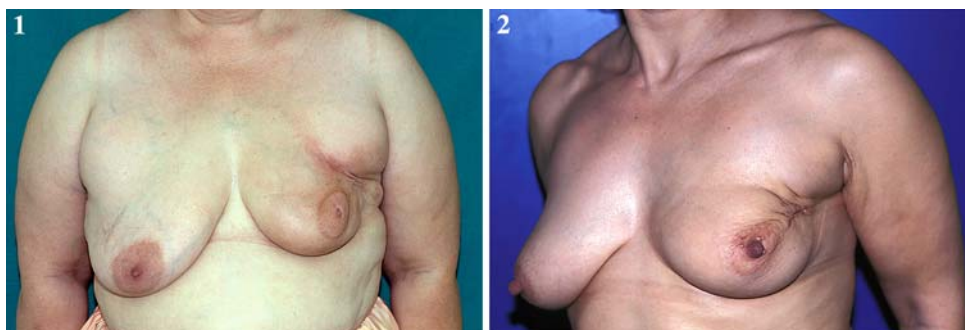
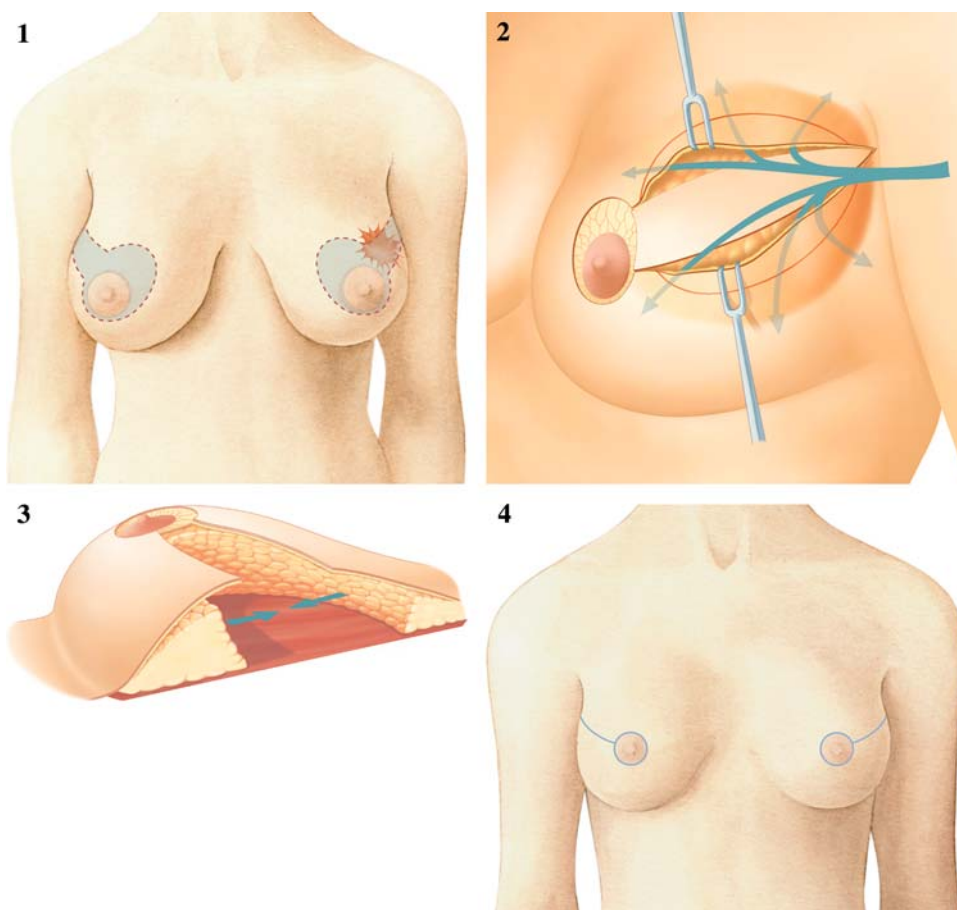
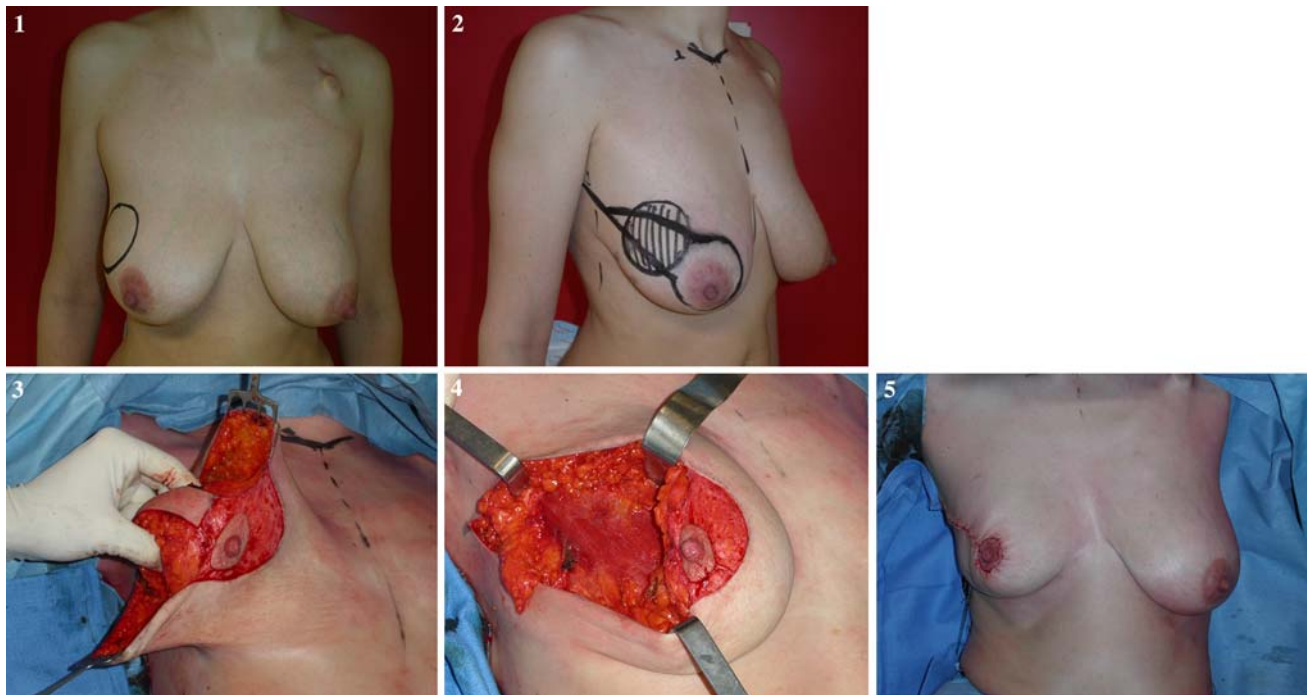


FIG. 7 Level II OPS: racquet technique for upper outer quadrant (1–3 o'clock). **1** Racquet technique preoperative drawings. **2** Skin excision and quadrant undermining. **3** Reapproximation and NAC recentralization. **4** Final result with periareolar and lateral scars



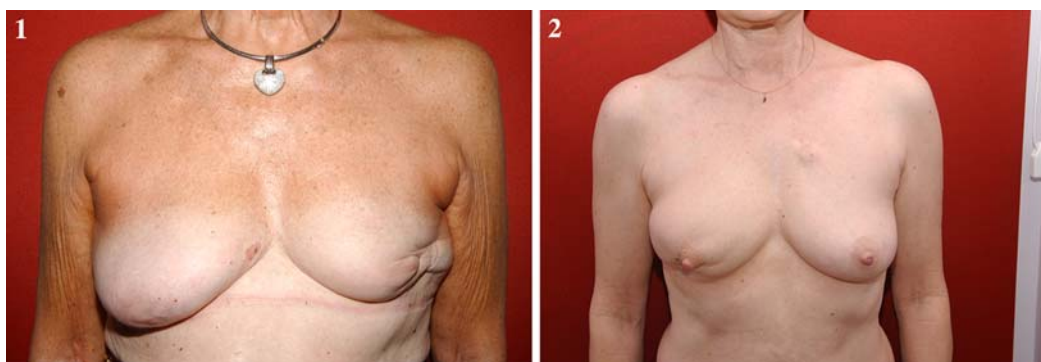


PICTURE 9 Racquet mammoplasty. Patient underwent neoadjuvant treatment with poor response and large residual tumor. **1** Upper outer quadrant tumor. **2** Skin markings. **3** Excision of tumor. **4** Excision cavity. **5** Final result prior to contralateral symmetrization

advancement is easily accomplished through NAC undermining. Complete detachment of the retroareolar gland from the NAC enables maximal mobility of the central gland for volume redistribution. Once the defect is eliminated, the NAC is placed in its optimal position, at the center of the new breast mound. This mammoplasty results in a long radial scar over the original tumor site with a periareolar extension (Picture 9; Fig. 7).

Lower Outer Quadrant (4–5 O'clock)

General Principles Like for the lower inner pole, the inverted T mammoplasty does not “fit” well for this quadrant. The optimal procedure to avoid lateral retraction of the breast and deviation of the NAC is a J-type mammoplasty (Picture 10).²⁹



PICTURE 10 1, 2 Lower outer deformity

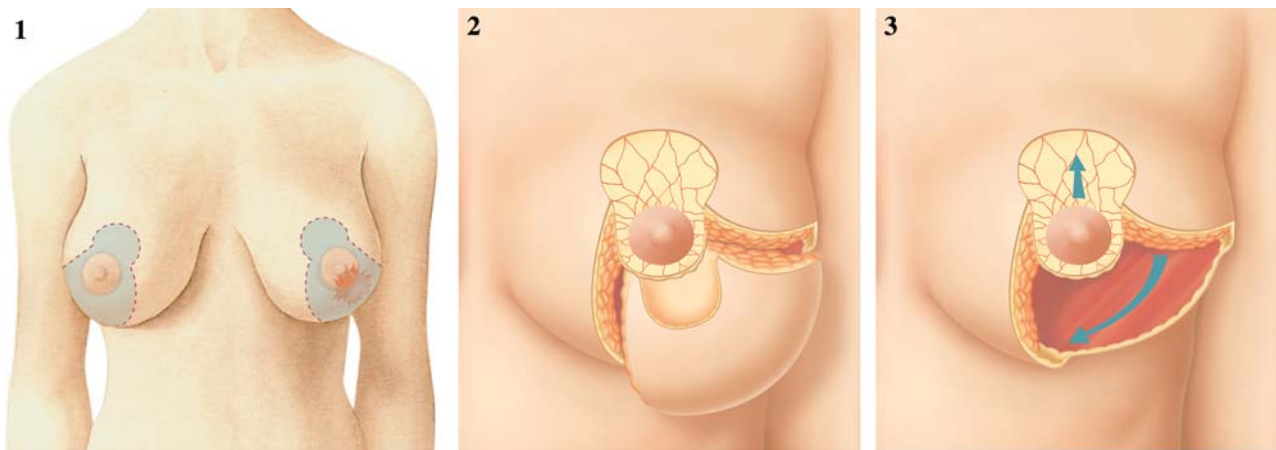


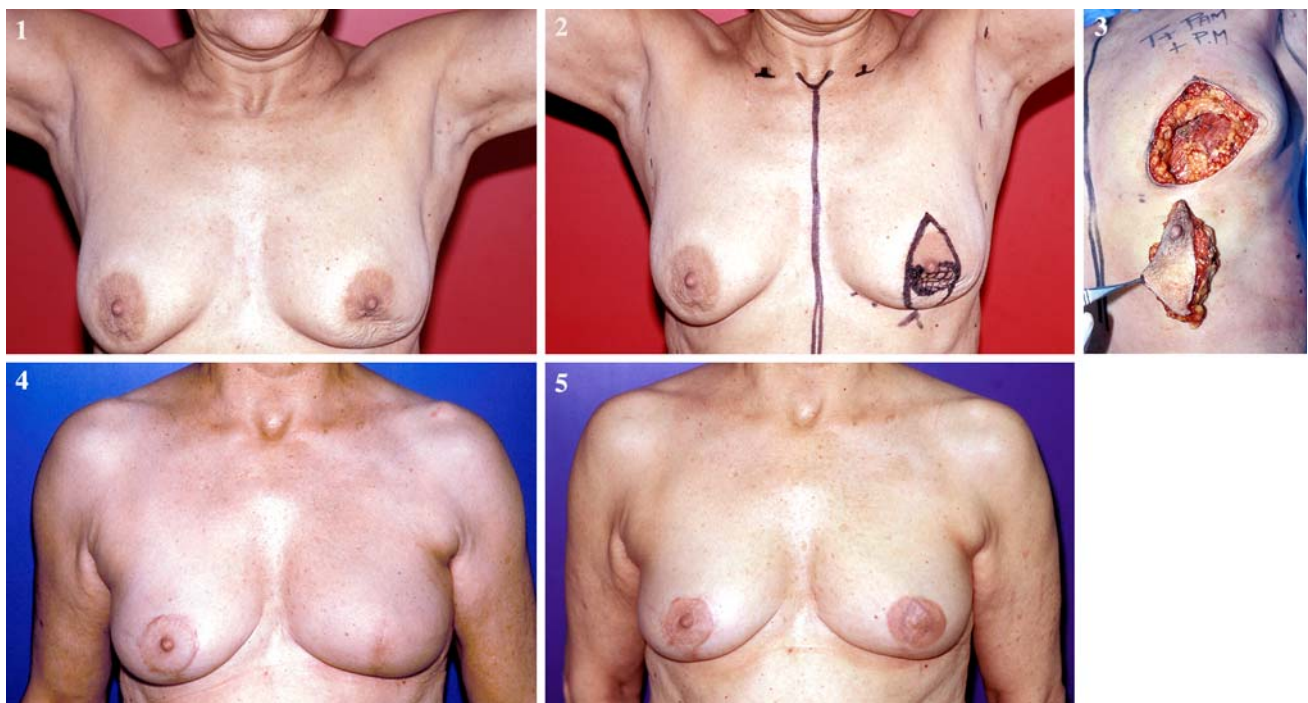
FIG. 8 Level II OPS: J-mammoplasty for lower outer quadrant (4–5 o'clock). **1** Preoperative drawings. **2** Excision specimen and deepithelialization of NAC pedicle. **3** Breast reshaping and NAC recentralization

Technique: J-Mammoplasty Like for all lower pole excisions, the NAC is carried on a deepithelialized superior pedicle. The first incision begins at the medial edge of the deepithelialized periareolar area and then gently curves downwards with a concavity to the inframammary crease. The second incision starts at the lateral border of the deepithelialized zone and follows a similar pattern. The parenchymal excision then follows the skin pattern in the shape of the letter J. Lateral and central gland can then be recruited into the excision defect to

achieve an equitable redistribution of remaining breast volume. The NAC is recentralized in its optimal position (Fig. 8).

Retroareolar Location

General Principles Subareolar breast cancers are candidates for BCS. However, superficial subareolar tumors are associated with a risk of NAC involvement



PICTURE 11 Lejour/vertical mammoplasty. **1** Centrally located tumor with involvement of the NAC. **2** Skin marking. **3** Excision of tumor and NAC. **4** Postoperative result. **5** NAC tattoo

approaching 50%.³⁰ In such cases en bloc removal of the NAC with the tumor may be required. This often results in a poor cosmetic outcome with a flat breast. If the patient has a glandular breast allowing wide undermining for reshaping, a level I OPS is a reasonable option. As in other locations, level II mammoplasty techniques are reserved for patients with fatty breasts or for patients for whom excision of more than 20% of the breast volume is required. There are a number of mammoplasty approaches that can be chosen for the centrally located lesion. They include the inverted T mammoplasty with resection of the NAC, a modified Lejour or J pattern with NAC excision or Grisotti's technique.³¹ The latter offers the advantage of allowing for immediate NAC reconstruction through preservation of a skin island on an advancement flap.³²

Technique: Modified Inverted T Mammoplasty Oncoplastic techniques for centrally located tumors have been outlined by Huemer et al.³³ Preferentially we utilize an inverted T or vertical incision, similar to the superior pedicle mammoplasty. The only modification is that the two vertical incisions encompass the NAC, which is removed together with the tumor. The NAC is usually reconstructed at a later stage, after completion of radiotherapy, but can also be reconstructed during the same procedure (Picture 11).

DISCUSSION

Advantages of Oncoplastic Surgery

Until recently, the breast surgeon could provide only two options for patients with breast cancer: either a modified radical mastectomy or a segmental excision followed by radiation. Integration of plastic surgery techniques at time of tumor excision has delivered a third pathway, enabling surgeons to perform major resections involving more than 20% of breast volume without causing deformity. This new combination of oncologic and reconstructive surgery is commonly referred to as oncoplastic surgery. This "third pathway" allows surgeons to extend the indications for BCS without compromise of oncologic goals or the esthetic outcome. It is a logical extension of the quadrantectomy technique described by Veronesi.³⁴ With immediate reshaping employed through OPS, major resections can now be achieved with enhanced cosmetic outcomes.³⁵⁻³⁷

Another advantage of OPS is avoiding the need for secondary reconstruction by preventing breast deformities.³⁸ Prior to the development of OPS, patients with major deformities were secondarily referred to plastic surgeons.

Despite continued efforts to treat these deformities, the results of postoperative repair of BCS defects in irradiated tissue were found to be poor, regardless of the surgical procedure or team.³⁹⁻⁴² Immediate reshaping of the breast eliminates the need for complex delayed reconstruction of deformities after BCS.

Indications for Oncoplastic Surgery

The main indication for OPS is large lesions for which a standard excision with safe margins would either seem impossible or lead to a major deformity. Extensive ductal carcinoma in situ (DCIS), lobular carcinoma, multifocality, and partial or poor responses to neoadjuvant treatment (Picture 4, 9) are all potential indications for OPS intervention. Standard BCS that results in positive margins constitutes an additional category of patients (Picture 2).⁴³

Oncoplastic Validation

Oncoplastic surgery is fully integrated into a multidisciplinary environment. Pre- and postoperative treatments are not modified. During surgery, the original tumor bed is clipped, allowing precise localization for postoperative radiotherapy. Our prospective analysis of a series of 100 patients undergoing level II OPS demonstrated 5-year overall and disease-free survival rates of 95.7% and 82.8% respectively.¹⁸ A more recent retrospective review of an extended series of 298 patients treated with OPS demonstrated 5-year recurrence-free and overall survival rates of 93.7% and 94.6%, respectively. This series confirms the initial equivalent comparison of OPS and standard BCS.⁴⁴ Rietjens has reported in his long-term results from the European Institute of Oncology no local relapse in the pT1 cohort. The pT2 and pT3 combined group had a 5-year local recurrence rate of 8% and a mortality rate of 15%. The overall local recurrence rate was determined to be 3%.⁴⁵

Complications of Oncoplastic Surgery

Surgeons embarking in OPS should be aware of the risk of complications and the factors that increase this risk. Glandular necrosis is the most challenging complication. Aggressive undermining of both the skin envelope and gland from the pectoralis muscle can lead to glandular necrosis if the breast is fatty. Areas of fat necrosis can become infected and cause wound dehiscence resulting in postoperative treatment delay. Our prospective evaluation of complications in our initial series demonstrated a high incidence of delayed wound healing (9%).¹⁸ This rate has been considerably reduced since we began incorporating

the third key element, breast density, into our decision-making process. Our complication rate is now less than 5%, with only three cases over the last 150 procedures in which postoperative treatment was delayed. There are no increased treatment delays with the more extensive level II techniques and the remodeling process has not affected continued screening and radiographic follow-up of patients.⁴⁶

Growth of Oncoplastic Surgery Field

Oncoplastic surgery level II techniques are numerous and are generating increased attention in the surgical literature. Most authors describe the utilization of the inverted T-mammoplasty for all quadrants of the breast.^{47–49} Thus, for upper-pole tumors, the excision defect is filled by extensive mobilization of the lower gland. In our experience the implementation of the same reduction mammoplasty pattern for tumors in all locations of the breast has significant limitations. Advancement of distant breast tissue to fill the defect is at high risk of complications due to tissue necrosis. Kronowitz reports a 26% complication rate in a series of 50 patients. Our Atlas is based upon a direct excision of skin over the tumor that allows reshaping and avoids complications due to extensive glandular mobilization. Because almost all cosmetic mammoplasties rely on inverted T-incisions, we had to develop new mammoplasty patterns specifically for breast cancer treatment. These include the V- and racquet mammoplasty techniques. We also adapted old techniques, such as the J-mammoplasty, that had been abandoned by most plastic surgeons. Thus, we developed almost one technique for each quadrant of the breast.

Integration into Current Surgical Practice

Difficulty in performing advanced level II techniques might constitute a limitation for the implementation of the Atlas. However, training for OPS can be acquired gradually, and level I techniques do not require any advanced training. One solution for the more complex cases is to incorporate a dual-team approach with the plastic surgeon. However, we would favor OPS training for all future breast surgeons for a long-term solution.^{50,51}

CONCLUSION

Oncoplastic surgery allows for wide resections with favorable cosmesis and integrates into a standard multidisciplinary approach for BCS. The ultimate goal is to allow large-volume resections with free margins and fewer re-excisions and mastectomies than is obtainable with

standard BCS. We propose to stratify OPS into two levels. We define three key factors for technique selection: excision volume, tumor location, and glandular density. Even though we are aware that there is no clear-cut division between standard BCS and oncoplasty, and that a crossover between levels I and II exists, we strongly advocate the adoption of a standardized OPS classification system. This classification should help training in OPS. Surgeons will be able to select appropriate courses and training experiences based on the distinct levels. The OPS classification and Atlas is intended to assist surgeons to choose the optimal approach for each individual patient to avoid complications and obtain the best oncologic and cosmetic results.

REFERENCES

1. Clough KB, Soussaline M, Campana F, Salmon RJ. Mammoplasty combined with irradiation: conservative treatment of cancers located in the lower quadrants. *Ann Chir Plast Esthet.* 1990;35(2):117–22.
2. Cothier-Savey I, Otmegzguine Y, Calitchi E, et al. Value of reduction mammoplasty in the conservative treatment of breast neoplasm. A propos of 70 cases. *Ann Chir Plast Esthet.* 1996;41(4):346–53.
3. Petit JY, Rietjens M, Garusi C, et al. Integration of plastic surgery in the course of breast-conserving surgery for cancer to improve results and radicality of tumor excision. *Recent Results Cancer Res.* 1998;152:202–11.
4. Spear SL, Pelletiere CV, Wolfe AJ, et al. Experience with reduction mammoplasty combined with breast conservation therapy in the treatment of breast cancer. *Plast Reconstr Surg.* 2002;111(3):1102–09.
5. Rainsbury R. Surgery insight: oncoplastic breast-conserving reconstruction-indications, benefits, choices and outcomes. *Nat Clin Pract Oncol.* 2007;4(11):657–64.
6. Bulstrode NW, Shortri S. Prediction of cosmetic outcome following conservative breast surgery using breast volume measurements. *Breast.* 2001;10:124–6.
7. Kaur N, Petit JY, Rietjens M, et al. Comparative study of surgical margins in oncoplastic surgery and quadrantectomy in breast cancer. *Ann Surg Oncol.* 2005;12(7):539–45.
8. American College of Radiology. Breast imaging reporting and data systems (BI-RADS), American College of Radiology, Reston, VA; 2003.
9. McCulley SJ, Macmillan RD. Therapeutic mammoplasty: analysis of 50 consecutive cases. *Br J Plast Surg.* 2005;58(7):902–7.
10. Kraissl CJ. The selection of appropriate lines for elective surgical incisions. *Plast Reconstr Surg.* 1951;8(1):1–28.
11. Schlenz I, Rigel S, Schemper M, Kuzbari R. Alteration of nipple and areola sensitivity by reduction mammoplasty: a prospective comparison of five techniques. *Plast Reconstr Surg.* 2005;115(3):743–51.
12. Petit JY, De Lorenzi F, Rietjens M, et al. Technical tricks to improve the cosmetic results of breast-conserving treatment. *Breast.* 2007;16(1):13–6.
13. O'Dey D, Prescher A, Pallua N. Vascular reliability of the nipple-areola complex-bearing pedicles: an anatomical microdissection study. *Plast Reconstr Surg.* 2007;119(4):1167–77.
14. Smith ML, Evans GR, Gurlek A, et al. Reduction mammoplasty: its role in breast conservation surgery for early-stage breast cancer. *Ann Plast Surg.* 1998;41(3):234–9.

15. Clough KB, Nos C, Salmon RJ, et al. Conservative treatment of breast cancers by mammoplasty and irradiation: a new approach to lower quadrant tumors. *Plast Reconstr Surg*. 1995;96(2):363–70.
16. Vlajcic Z, Zic R, Stanec S, Stanec Z. Omega and inverted omega incision: a concept of uniform incisions in breast surgery. *Ann Plast Surg*. 2004;53(1)31–8.
17. Nos C, Fitoussi A, Bourgeois D, et al. Conservative treatment of lower pole breast cancers by bilateral mammoplasty and radiotherapy. *Eur J Surg Oncol*. 1998;24(6):508–14.
18. Clough KB, Lewis J, Couturaud B, et al. Oncoplastic Techniques allow extensive resections for breast-conserving therapy of breast carcinomas. *Ann Surg*. 2003;237(1):26–34.
19. Lejour M. Reduction of mammoplasty scars: from a short infra-mammary scar to a vertical scar. *Ann Chir Plast Esthet*. 1990;35(5):369–79.
20. Lassus C. A 30-year experience with vertical mammoplasty. *Plast Reconstr Surg*. 1996;97(2):373–80.
21. Renouvel F, Nos C, Clough KB, Lecuru F. Preliminary outcome of breast cancer located at the lower quadrant treated with a thoracmammary flap. *Bull Cancer*. 2008;95(7):773–8.
22. Clough KB, Kroll S, Audretsch W. An approach to the repair of partial mastectomy defects. *Plast Reconstr Surg*. 1999;104(2):409–20.
23. Anderson BO, Masetti R, Silverstein MJ. Oncoplastic approaches to partial mastectomy: an overview of volume-displacement techniques. *Lancet Oncol*. 2005;6:145–57.
24. Spear SL, pelletiere CV, Wolfe AJ, et al. Experience with reduction mammoplasty combined with breast conservation therapy in the treatment of cancer. *Plast Reconstr Surg*. 2003;111(3):1102–9.
25. Benelli L. A new periareolar mammoplasty: the “round block” technique. *Aesthetic Plast Surg*. 1990;14(2):93–100.
26. Hammon DC. Short scar periareolar inferior pedicle reduction (SPAIR) mammoplasty. *Plast Reconstr Surg*. 1999;103(3):890–901.
27. Veronesi U, Banfi A, Saccozzi R, et al. Conservative treatment of breast cancer. A trial in progress at the cancer institute of Milan. *Cancer*. 1977;39(6)2822–6.
28. Veronesi U, Banfi A, del Vecchio M, et al. Comparison of Halsted mastectomy with quadrantectomy, axillary dissection, and radiotherapy in early breast cancer: long term results. *Eur J Cancer Clin Oncol*. 1986;22:1085–9.
29. Gasperoni C, Salgarello M, Gasperoni P. A personal technique: mammoplasty with J scar. *Ann Plast Surg*. 2002;48(2):124–30.
30. Laronga C, Kemp B, Johnston D, et al. The incidence of occult nipple-areola complex involvement in breast cancer patients receiving a skin-sparing mastectomy. *Ann Surg Oncol*. 1999;6(6):609–13.
31. McCulley SJ, Durani P, Macmillan RD. Therapeutic mammoplasty for centrally located breast tumors. *Plast Reconstr Surg*. 2006;117(2):366–73.
32. Galimberti V, Zurrada S, Grisotti A, et al. Central small size breast cancer: how to overcome the problem of nipple and areola involvement. *Eur J Cancer*. 1993;29A(8)1093–6.
33. Huemer G, Schrenk P, Moser F, et al. Oncoplastic techniques allow breast-conserving treatment in centrally located breast cancers. *Plast Reconstr Surg*. 2007;120(2):390–8.
34. Veronesi U, Lunini A, Galimberti V, Zurrada S. Conservation approaches for the management of stage I/II carcinoma of the breast: Milan cancer institute trials. *World J Surg*. 1994;18(1):70–5.
35. Mariani L, Salvadori B, Veronesi U, et al. Ten year results of a randomized trial comparing two conservative strategies for small size breast cancer. *Eur J Cancer*. 1998;149(3):219–25.
36. Amichetti M, Busana L, Caffo O. Long term cosmetic outcome and toxicity in patients treated with quadrantectomy and radiation therapy for early-stage breast cancer. *Oncology*. 1995;52:177–81.
37. Giacalone PL, Roger P, Dubon O, et al. Comparative study of the accuracy of breast reconstruction in Oncoplastic surgery and quadrantectomy in breast cancer. *Ann Surg Oncol*. 2006;14(2):605–14.
38. Dewar JA, Benhamou E, Arrigada R, et al. Cosmetic results following lumpectomy, axillary dissection and radiotherapy for small breast cancer. *Radiother Oncol*. 1998;12(4):273–80.
39. Petit J-Y, Regault L, Zekri A, et al. Poor aesthetic results after conservative treatment of breast cancer. Techniques of partial breast reconstruction. *Ann Chir Plast Esthet*. 1989;34:103–8.
40. Clough KB, Thomas S, Fitoussi A, et al. Reconstruction after conservative treatment for breast cancer. cosmetic sequelae: classification revisited. *Plast Reconstr Surg*. 2004;114(7):1743–53.
41. Berrino P, Campora E, Leone S, Santi P. Correction of type II breast deformities following conservative cancer surgery. *Plast Reconstr Surg*. 1992;90:846–53.
42. Bostwick J, Paletta C, Hartampf CR. Conservative treatment for breast cancer: complications requiring reconstructive surgery. *Ann Surg*. 1986;203:481–90.
43. Schwartz GF, Veronesi U, Clough KB, et al. Proceedings of the consensus conference on breast conservation, April 28 to May 1, 2005, Milan, Italy. *Cancer*. 2006;107(2):242–50.
44. Staub G, Fitoussi A, Falcou MC, Salmon RJ. Breast cancer surgery: use of mammoplasty. Results. Series of 298 cases. *Ann Chir Plast Esthet*. 2007;53(2):124–34.
45. Rietjens M, Urban CA, Petit JY, et al. Long-term oncologic results of breast conservation treatment with oncoplastic surgery. *Breast*. 2007;16(4):387–95.
46. Brown FE, Sargernt SK, Cohen SR, Morain WD. Mammographic changes following reduction mammoplasty. *Plast Reconstr Surg*. 1987;80(5):691–8.
47. Munhoz AM, Montag E, Arruda EG, et al. Superior-medial dermoglandular pedicle reduction mammoplasty for immediate conservative breast surgery reconstruction: technical aspects and outcome. *Ann Plast Surg*. 2006;57(5):502–8.
48. Kronowitz SJ, Hunt KK, Kuerer HM, et al. Practical guidelines for repair of partial mastectomy defects using the breast reduction technique in patients undergoing breast conservation therapy. *Plast Reconstr Surg*. 2007;120(7):1755–68.
49. Losken A, Styblo TM, Carlson GW, et al. Management algorithm and outcome evaluation of partial mastectomy defects treated using reduction or mastopexy techniques. *Ann Plast Surg*. 2007;59(5):235–42.
50. Association of Breast Surgery at BASO. Oncoplastic breast-surgery: a guide to good practice. *Eur J Surg Oncol*. 2007;33(1)S1–23.
51. Skillman JM, Humzah MD. The future of breast surgery: a new subspecialty of oncoplastic breast surgeons? *Breast*. 2003;12(3):161–2.