

In-Laboratory Removal of Femoral Sheath Following Protamine Administration in Patients Having Intracoronary Stent Implantation

Manuel Pan, MD, José Suárez de Lezo, MD, Alfonso Medina, MD, Miguel Romero, MD, Enrique Hernández, MD, José Segura, MD, Francisco Melian, MD, Fernando Wangüemert, MD, Manuel Landin, MD, Fernando Benítez, MD, Manuel Amat, MD, Francisco Velasco, MD, and Antonio Torres, MD

After coronary stent implantation, antithrombotic therapy is required; however, the specific drug combination to use is still under debate.¹ The ideal regimen should avoid subacute stent thrombosis and hemorrhagic complications and allow an early hospital discharge. The purpose of this study is the evaluation of the safety and efficiency of neutralizing circulating heparin with protamine administration immediately after coronary stent implantation. We hypothesized that the in-laboratory removal of the femoral sheath could reduce groin complications and would shorten the postprocedural period of bed rest and hospital stay after stent implantation. To test this hypothesis, our study compares, in a randomized way, the hospital course of patients with early sheath removal after protamine administration with those in which the femoral sheath was removed after the complete spontaneous disappearance of heparin activity.

•••

Between November 1995 and April 1996, 228 consecutive patients with successful coronary stent implantation were enrolled in the study. Inclusion criteria for the study were: (1) symptomatic coronary heart disease (stable or unstable syndromes), (2) a coronary vessel >2.5 mm in diameter, (3) adequate accessibility to the target lesions to be stented, (4) angiographic primary success, and (5) written informed consent.

All patients enrolled in the study were premedicated with low-molecular weight heparin (Fragmin, Pharmacia, Stockholm, Sweden) antifactor Xa 10,000 IU/day, ticlopidine 500 mg/day, and aspirin 150 mg/day. This antithrombotic regimen began the day before the procedure and continued for 3 weeks.² Diagnostic coronary angiography was performed using regular 6 to 7Fr catheters and standard projections. The procedure of stent implantation was carried out using an 8Fr guiding catheter. During the therapeutic phase all patients received a 2 mg/kg bolus of intravenous unfractionated heparin. After successful stent implantation, patients were randomized into 2 groups. Group I was comprised of 117 patients who intravenously received 2 mg/kg of protamine (1 mg of protamine per 1 mg of heparin). In this group of patients the femoral sheath was removed in the hemodynamic

laboratory immediately after the procedure. Group II was consisted of 111 patients that did not receive protamine, and the femoral sheath was removed 8 to 10 hours after the intravenous bolus of heparin (Figure 1).

The stent deployment technique was performed according to the type of stent employed. Twelve patients from group I and 11 patients from group II had intracoronary ultrasound to assess stent implantation. In this study we used 4 types of stents: Palmaz-Schatz (Johnson and Johnson Interventional Systems, Warren, New Jersey), Wiktor (Medtronic, Inc., Minneapolis, Minnesota), Wallstent (Bülach, Switzerland), and MultiLink (Temecula, California). All lesions were predilated with a balloon equal to or slightly smaller than the vessel size. The stent was deployed and expanded to reach a diameter slightly higher than the vessel diameter. The mean pressure with the last balloon was 11 ± 3 atm. The Palmaz-Schatz stent was the most frequently used. The technique of implantation has been previously described.²⁻⁴ The Wiktor stent was selected when a large side branch began near the target lesion or in lesions located at severe bend points. The Wallstent was selected for long lesions in native arteries or lesions located in saphenous vein grafts. The ACS Multilink stent was the last incorporated in our laboratory and was preferred for lesions located distally.

All sheaths were removed by trained nonphysician personnel or by cardiology residents. The groin compression was carried out manually for 15 to 20 minutes. Once the hemostasis was achieved, a period of 18 hours of strict bed rest was prescribed. A 1- to 2-kg sand bag was also positioned over the inguinal zone to provide additional compression. After this period, a visual inspection of the inguinal zone was performed and if no hematoma was present, the patient was encouraged to deambulate in the hospital for an additional period of 24 to 48 hours. Those patients with an absence of symptoms or groin complications were discharged. Blood analysis for monitoring the coagulation system was not routinely performed. There were no intraprocedural groin problems that could alter the randomization process. Although personnel involved in the care of patients were aware of the removal sheath strategy, the decision of prolonging bed rest and inguinal compression in case of hematoma or bleeding was only related to the magnitude of the groin complication.

From the Hospital "Reina Sofía," University of Córdoba, Córdoba, and the Hospital del Pino, University of Las Palmas, Las Palmas de Gran Canaria, Spain. Dr. Pan's address is: Servicio de Cardiología, Hospital Reina Sofía, Avda. Menéndez Pidal 1, 14004-Córdoba, Spain. Manuscript received March 28, 1997; revised manuscript received and accepted July 23, 1997.

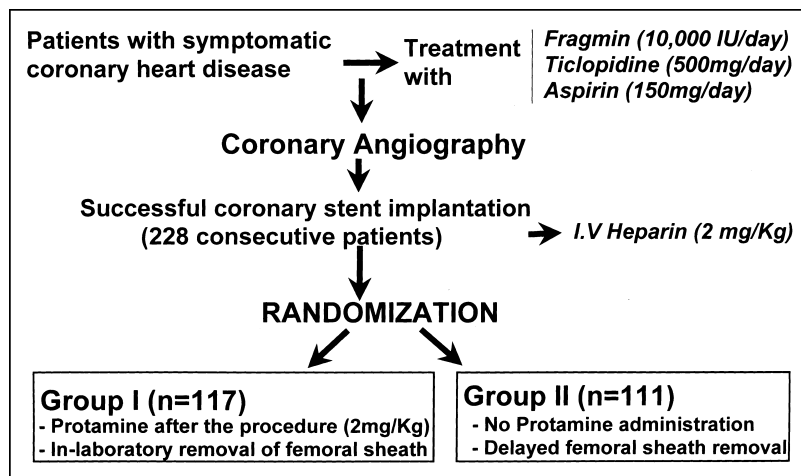


FIGURE 1. Patient flowchart and study design.

	Group I (n = 117)	Group II (n = 111)
Clinical data		
Age (yrs)	59 ± 9	59 ± 10
Men	96 (82%)	93 (84%)
Smoking	77 (66%)	68 (61%)
Serum total cholesterol (mg/dl)	207 ± 81	226 ± 29
Systemic hypertension	61 (52%)	52 (47%)
Diabetes mellitus	22 (19%)	29 (26%)
Unstable angina pectoris	57 (49%)	56 (50%)
Previous myocardial infarction	16 (14%)	19 (17%)
Previous coronary surgery	5 (4%)	2 (2%)
Angiographic data		
Stented artery/patient	1.2 ± 0.46	1.2 ± 0.47
Vessel diameter (mm)	3.2 ± 0.57	3.2 ± 0.62
Minimal lumen diameter (mm)	0.65 ± 0.3	0.76 ± 0.4
Lesion length (mm)	12 ± 7	12 ± 8
Thrombus containing lesions	14 (12%)	12 (11%)
Ejection fraction (%)	61 ± 11	58 ± 12
Procedural data		
Number of stents/vessel	1.35 ± 0.7	1.28 ± 0.5
Type of stent		
Palmaz-Schatz	129 (68%)	122 (72%)
Wiktor	30 (16%)	29 (17%)
Wallstent	19 (10%)	12 (7%)
Multilink	12 (6%)	7 (4%)
Inflation pressure (atm)	11 ± 3	11 ± 3
Stenosis poststent implantation (%)	5 ± 10	7 ± 11

Data are expressed as mean ± SD. A Student-Fisher unpaired *t* test was used to compare quantitative data from patients in the 2 groups. The chi-square or Fisher's exact test was used to compare qualitative variables. A *p* value <0.05 was considered statically significant.

Baseline clinical data are shown in Table I. There were no significant differences between groups in terms of age, sex, risk factors, clinical condition, or incidence of previous coronary surgery. Of those patients with diabetes, 13 (5 patients from group I and 8 patients from group II) were insulin dependent. Table I also summarizes baseline angiographic characteristics of both groups of patients. As can be seen, there

were no significant differences regarding the number of stented vessels per patient, vessel size, minimal lumen diameter, lesion length, ejection fraction, or the incidence of thrombus-containing lesions.

Data related to the procedure are listed in Table I. Again, there was no statistical significance between groups. Thus, the type of stent employed, the number of stents per vessel, the inflation pressure, and the percent of residual stenosis after stenting were similar in both groups of patients.

There was no subacute stent thrombosis and no patients died. One patient from group II had chest pain with ST elevation 5 hours after the procedure. New coronary angiography

showed the stented segment without an intraluminal filling defect and a vessel occlusion distal to the stent due to an occlusive dissection; this was corrected with the implantation of a second stent. Six patients (3 from group I and 3 from group II) had mild persistent dissection without blood flow compromise. Groin hematoma and pseudoaneurysm occurred in 1 patient from group I and in 1 patient from group II. These 2 patients did not require groin surgery and were successfully treated by prolonged bed rest and inguinal compression. Bed rest and hospital stay were shorter in group I patients (*p* <0.05) (Table II).

Immediately after the administration of total doses of protamine, 17 patients (15%) had transient back pain, 6 patients (5%) had hypotension, and 2 patients (2%) a cutaneous rash. All symptoms were successfully treated in the laboratory with analgesics, intravenous fluid infusion, or corticoids. The initial incidence of side effects was reduced with a slower administration of protamine dilution.

•••

Aggressive anticoagulation after stent implantation was associated with frequent groin complications despite prolonged immobilization and careful management of the local puncture site.^{2,5-9} Although several attempts were made to decrease local complications, such as using 6Fr guiding catheters,¹⁰ transradial approach,¹¹ or the development of new devices for local hemostasis,¹² the dramatic reduction of local complications began with new antithrombotic regimens.^{2,9,13-15} Our study was carried out with patients treated under 1 of these new regimens, which has been previously described.² We tried to reduce the bed rest period after the procedure by neutralizing the circulating heparin and removing the femoral sheath immediately. Several goals were pursued with this strategy: (1) to minimize the discomfort derived from prolonged bed rest (because many patients with unstable angina were in bed several days before the procedure); (2) to reduce hospital stay, because the waiting time of heparin clearance was saved; and (3) to reduce groin complications, because groin problems have been as-

TABLE II Results

	Group I	Group II
Outside of laboratory vessel occlusion*	0	1 (0.9%)
Death	0	0
Stent thrombosis	0	0
Systemic bleeding	0	0
Groin hematoma and pseudoaneurysm	1 (0.9%)	1 (0.9%)
Groin surgery	0	0
Hospital stay (hrs)	85 ± 44	103 ± 47

*Occlusive dissection distal to the stent.
p = NS.

sociated with the duration of intravenous heparin infusion after the procedure.¹⁶

Due to the inherent thrombogenicity of the stent, protamine has rarely been administered after the coronary implantation of this device, because of the possibility of promoting stent thrombosis. Before undergoing the study, we postulated that pretreatment with antiplatelets and low-molecular weight heparin would protect the patient from subacute stent thrombosis once the effect of intravenous unfractionated heparin had disappeared, which would allow the immediate removal of the femoral sheath. After the completion of the study, no patient had subacute stent thrombosis, so the safety of this drug in the context of stent implantation has been demonstrated.

After this study, we utilized this new strategy in our patients treated with stents. Thus, since May 1996 an additional 509 patients with successful stent implantation have been treated with this protocol. The postprocedure hospital stay has been reduced to 2 days in patients with no complications (16 to 18 hours of bed rest and 24 hours of in-hospital deambulation). The incidence of severe groin hematoma remains about the same (1.5%).

Protamine to neutralize circulating heparin may be safely administered immediately after stent implantation. This strategy could be of benefit in patients with hemorrhagic risk, or those in which large femoral cannulas need to be removed after assistance with percutaneous circulatory support. This strategy may be of additional value because it

favors the action of new devices for local hemostasis, and in general, it could reduce the time of bed rest and hospital stay.

- Serruys PW, Di Mario C. Who was thrombogenic: the stent or the doctor. *Circulation* 1995;91:1891-1893.
- Pan M, Suárez de Lezo J, Velasco F, Romero M, Medina A, Segura J, Hernández E, Pavlovic DJ, Melián F, Gallardo A, Zayas R, Ruiz M, Torres A. Reduction of thrombotic and hemorrhagic complications after stent implantation. *Am Heart J* 1996;132:1119-1126.
- Pan M, Medina A, Romero M, Suárez de Lezo J, Hernández E, Pavlovic DJ, Melián F, Marrero J, Cabrera JA. Peripheral stent recovery after failed intracoronary delivery. *Cathet Cardiovasc Diagn* 1992;27:230-233.
- Medina A, Melian F, Suarez de Lezo J, Pan M, Romero M, Hernández E, Marrero J, Ortega JR, Pavlovic DJ. Effectiveness of coronary stenting for the treatment of chronic total occlusion in angina pectoris. *Am J Cardiol* 1994;73:1222-1224.
- Urban P, Sigwart U, Golf S, Kaufmann U, Sadeghi H, Kappenberger L. Intravascular stenting for stenosis of aortocoronary venous bypass grafts. *J Am Coll Cardiol* 1989;13:1085-1091.
- De Scheerder IK, Strauss BH, De Feyter PJ, Beatt KJ, Baur LH, Wijns W, Heyndrix GR, Suryapranata H, Brand M, Buis Beerd, Serruys PW. Stenting of venous bypass grafts: a new treatment modality for patients who are poor candidates for reintervention. *Am Heart J* 1992;123:1046-1054.
- Herrmann HC, Buchbinder M, Clemen MW, Fischman D, Goldberg S, Leon MB, Schatz RA, Tierstein P, Walker CM, Hirshfeld JW. Emergent use of balloon-expandable coronary artery stenting for failed percutaneous transluminal coronary angioplasty. *Circulation* 1992;86:812-819.
- Carrozza JP, Kuntz RE, Levine MJ, Pomerantz RM, Fishman RF, Mansour M, Gibson CM, Senerchia CC, Diver DJ, Safian RD, Baim DS. Angiographic and clinical outcome of intracoronary stenting: immediate and long-term results from a large single-center experience. *J Am Coll Cardiol* 1992;20:328-337.
- Schömig A, Neumann FJ, Kastrati A, Schühlen H, Blasini R, Hadamitzky M, Walter H, Zitzmann-Roth EM, Richardt G, Alt E, Schmitt C, Ulm K. A randomized comparison of antiplatelet and anticoagulant therapy after the placement of coronary-artery stents. *N Engl J Med* 1996;334:1084-1089.
- Urban P, Meier B, Haine E, Verine V, Mehan V. Coronary stenting through 6 French guiding catheters. *Cathet Cardiovasc Diagn* 1993;28:263-266.
- Kiemeneij F, Laarman GJ. Percutaneous transradial artery approach for coronary Palmaz-Schatz stent implantation. *Am Heart J* 1994;128:167-174.
- Camenzind E, Grossholz M, Urban P, Dorsaz PA, Didier D, Meier B. Collagen application versus manual compression: a prospective randomized trial for arterial puncture site closure after coronary angioplasty. *J Am Coll Cardiol* 1994;24:655-662.
- Colombo A, Hall P, Nakamura S, Almagor Y, Maiello L, Martini G, Gaglione A, Goldberg SL, Tobis JM. Intracoronary stenting without anticoagulation accomplished with intravascular ultrasound guidance. *Circulation* 1995;91:1676-1688.
- Fernández Avilés F, Alonso JJ, Duran JM, Gimeno F, Muñoz JC, Fuente L, San Roman JA. Subacute occlusion, bleeding complications, hospital stay and restenosis after Palmaz-Schatz coronary stenting under a new antithrombotic regimen. *J Am Coll Cardiol* 1996;27:22-29.
- Karrillon GJ, Morice MC, Benveniste E, Bunouf P, Aubry P, Cattani S, Chevalier B, Commeau P, Cribier A, Eiferman C, et al. Intracoronary stent implantation without ultrasound guidance and with replacement of conventional anticoagulation by antiplatelet therapy. *Circulation* 1996;94:1519-1527.
- Friedman HZ, Cragg DR, Glazier SM, Gangadharan V, Marsalese DL, Schreiber TL, O'Neill WW. Randomized prospective evaluation of prolonged versus abbreviated intravenous heparin therapy after coronary angioplasty. *J Am Coll Cardiol* 1994;24:1214-1219.