

In vitro differentiation of myxoid liposarcomas maintained in organ culture system

J. Tardio-Dovao, J. Escalona-Zapata and M.D. Diez-Nau

Department of Pathology, General Hospital «Gregorio Marañón», Madrid, Spain

Summary. Liposarcoma falls into the differential diagnosis of myxoid malignant mesenchymal tumors. On the other hand, its relation with white or brown fat is controversial. Two cases of liposarcoma have been studied by organ culture, a method which provides cell and tissue redifferentiation in vitro. Both cases developed successively cytoplasmic glycogen granules and lipid droplets as well as a single lipidic vacuole in the late phase of cultivation as a marker of fat differentiation. Our results support the possibility of identifying myxoid liposarcomas as well as their origin from white fat tissue.

Key words: Myxoid liposarcoma, Organ culture, Fat tissue

Introduction

Organ culture is a type of organized growth «in vitro». Due to the environmental conditions, the explant grows uniformly, cellular emigration decreases and the tridimensional histological structure is maintained.

It has been used for the study of many biological problems (Parker, 1950; Paul, 1960), such as the basic characteristics of neoplasms (Sipe et al., 1973). However, there are few studies on soft tissue tumors with organ culture. Particularly, there are no references in the literature about liposarcoma; one of the most frequent types.

Among liposarcoma, the myxoid variant offers problems in its differential diagnosis with other neoplasms. Moreover, it can mimic malignant fibrous histiocytoma, myxomas and myxosarcomas, as well as some recurrence of dermatofibrosarcoma protuberans.

The present work analyzes the growth «in vitro» of

two cases of myxoid liposarcoma by organ culture as well as a method to widen the knowledge about the basic characteristics of this neoplasm.

Materials and methods

The present study is based on two male patients, aged 40 and 45, with tumors located in deep soft tissues of the left leg, diagnosed as liposarcoma by conventional techniques.

2mm³ sterile fresh fragments were obtained from each tumor and were explanted on a bed of «spongostan» and incubated in CMRL 1066 medium, supplemented with beef serum and glutamine, and maintained in a CO₂ oven under continuous oscillation of 3-4 cycles/minute.

Periodic controls with phase contrast microscopy were done every three days during the first two weeks, and every 15 days until the third month.

Every week, an explant was fixed in Bouin fixative and slides were stained with haematoxylin-Eosin, P.A.S., P.A.S.-diastase, Alcian Blue (pH 2.5) and Masson trichrome.

On days 9 and 45, some explants were ultrastructurally studied after being fixed in 2.5% glutaraldehyde, osmicated and embedded in Epon. Ultrathin slides were placed on copper grids and stained with uranyl nitrate and lead citrate.

Results

Both tumors showed the habitual histological features of common myxoid liposarcomas: primitive mesenchymal cells and few lipoblasts in a variable stage of differentiation, scattered in a prominent myxoid matrix vascularized by thin, ramified capillary plexus (Enzinger and Weiss, 1988) (Fig. 1).

In organ culture, the first controls showed a solid mass of small round or short elongated cells with an isomorphic round or oval-shaped centrally-located

nucleus in a scarce eosinophilic cytoplasm. Among these cells, uni- or multivacuolated adipoblasts could be found. On the third day of cultivation, these latter cells constituted less than 5% of the cell population in the explants in case 1 and 15-20% in case 2 (Fig. 2a,b).

In this initial phase, electron microscopic study showed that the predominant cells were primitive mesenchymal cells and early adipoblasts with small lipid droplets (Fig. 3).

Right after the first controls, cells containing intracytoplasmic glycogen granules were found (Fig. 4). The number of these glycogen-rich cells increased gradually until they reached 80% of the culture population on the twelfth day, and decreased slowly from this moment onwards.

In both cultures, a progressive differentiation was shown with the development of an increasing number of adipoblasts, most of them univacuolated.

Between the 30th and 60th days, these adipoblasts constituted more than 90% of the cell population (Fig. 5a,b). At this time, the ultrastructural study showed more evolved adipoblasts, either univacuolated or containing a large dominant droplet which pushed the nucleus towards the periphery and diminished the cytoplasm to a thin edge with few organelles (Fig. 6).

Yet, the presence of acid mucopolysaccharides in the intercellular matrix could be demonstrated by Alcian blue stain.

Discussion

The differential diagnosis of myxoid soft tissue neoplasms includes several entities; both malignant or benign tumors and pseudotumoral inflammatory lesions (Mackenzie, 1981).

Differential diagnosis of tumors has been improved in the last years by the development of electron microscopy and immunohistochemistry, but there are some cases in which the problems remain, such a liposarcomas.

Due to the absence of a specific marker for liposarcoma (Weiss et al., 1983; Cocchia et al., 1983; Dekmezian et al., 1987) as well as the difficulties inherent to electron microscopy sampling (Ghadially, 1978; Tsuneyoshi et al., 1983), the diagnosis in most cases has been based on the demonstration of adipoblasts with light microscopy. Yet, these are frequently few and, moreover there are other kinds of droplet-rich cells which may cause confusion.

Organ culture has contributed to the knowledge of the basic characteristics of neoplasms and their

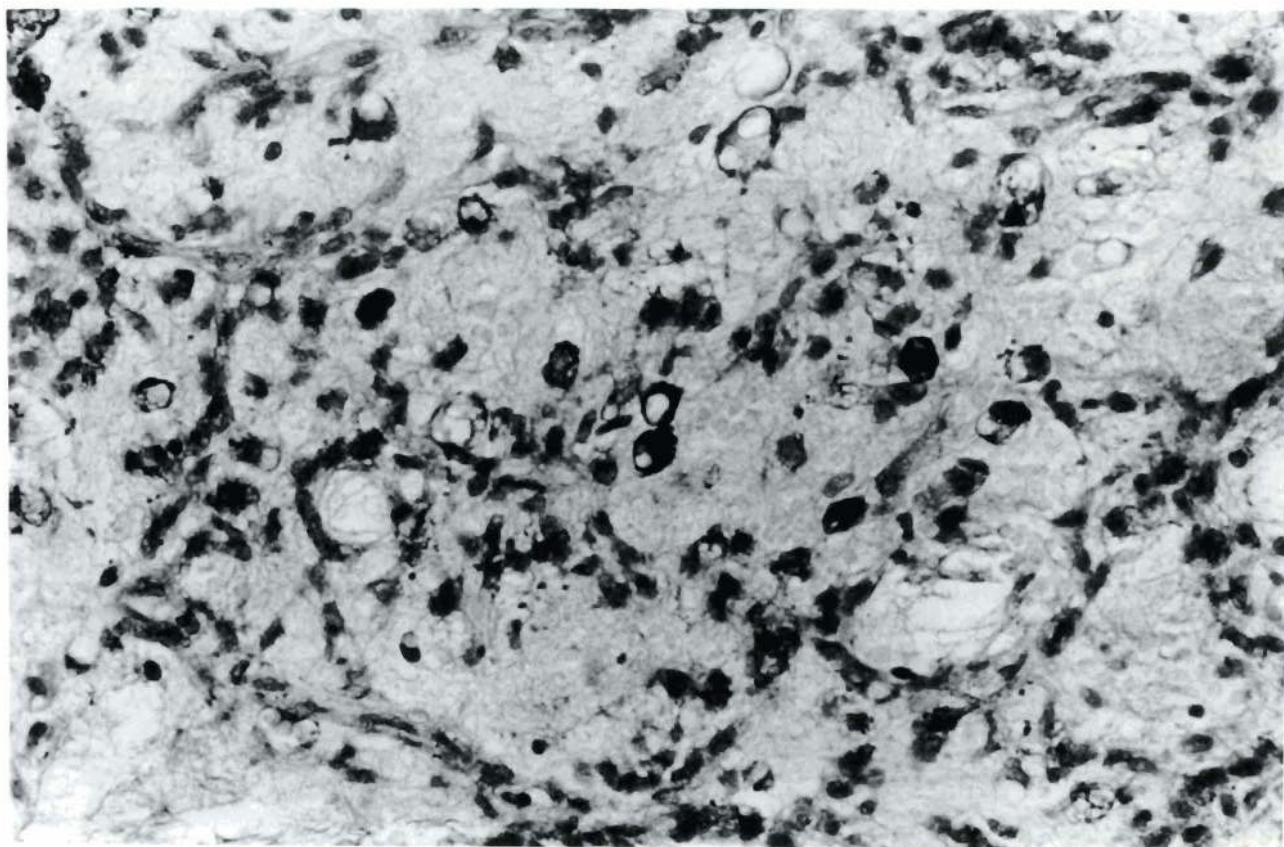


Fig. 1. Myxoid liposarcoma. P.A.S. Prominent myxoid matrix with a network of capillaries and mesenchymal cells. Some lipoblasts show a P.A.S. - positive cytoplasm (glycogen). x 200

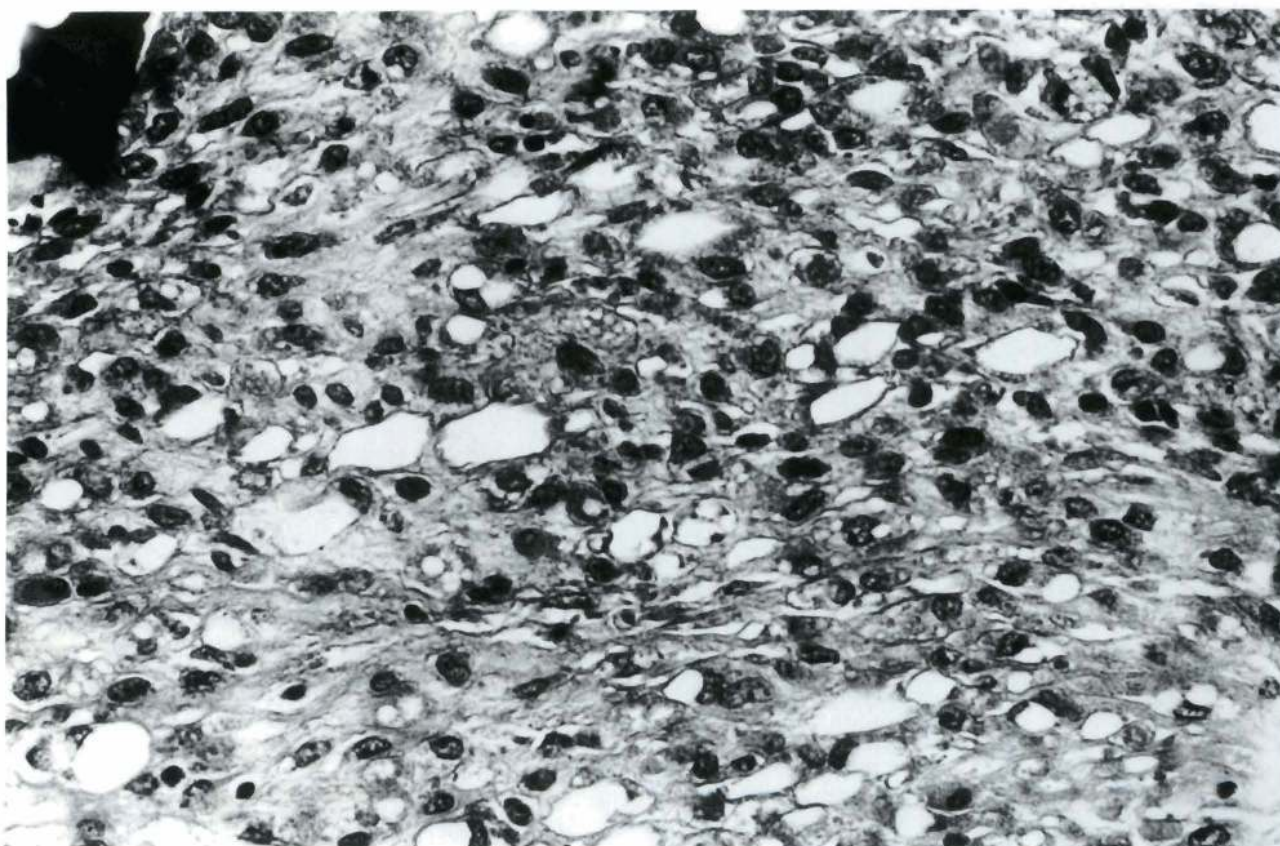
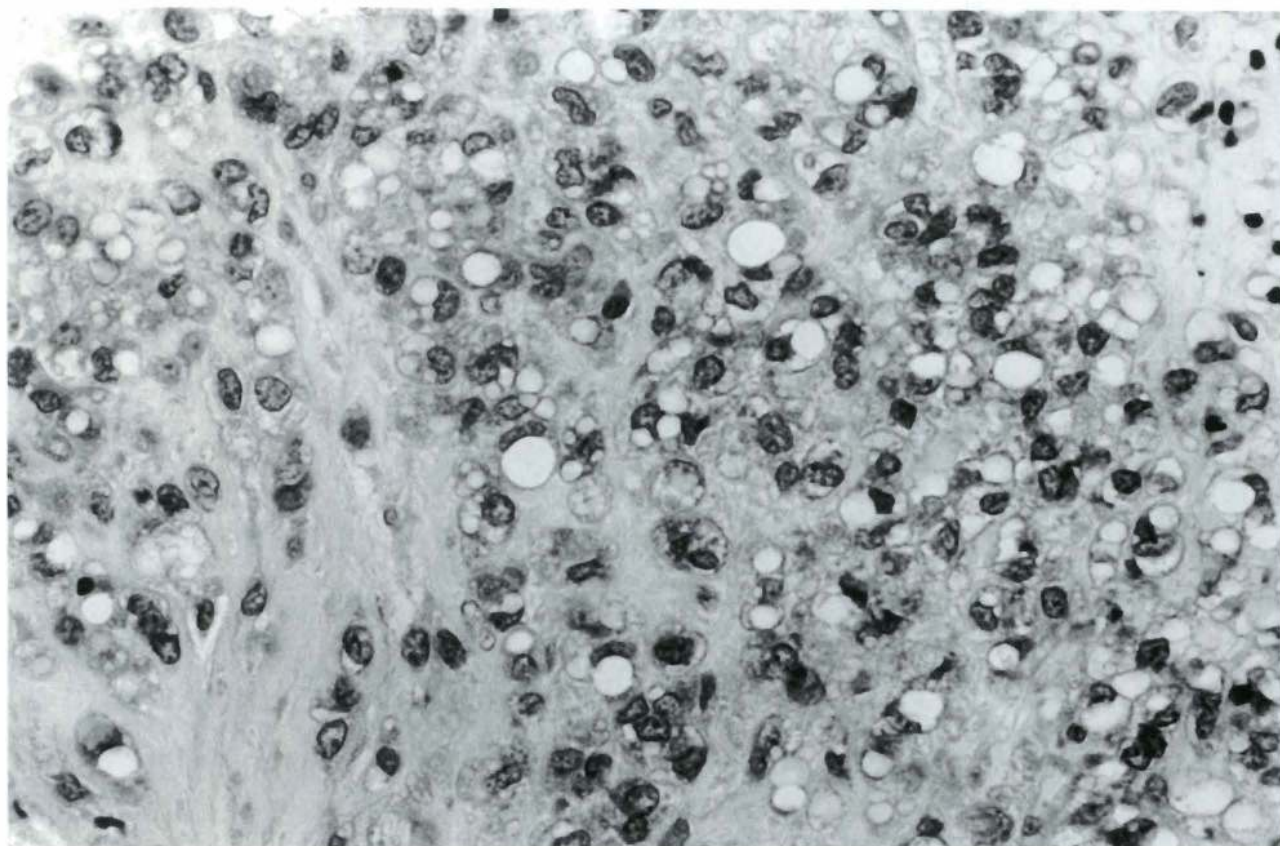


Fig. 2. a. Case 1. C.O. 215. H-E. After 15 days of cultivation, the myxoid matrix is reduced. Some tumoral cells show the features of lipoblasts with multivacuolated cytoplasm. x 200. **b.** Case 2. C.O. 341.H-E. After 12 days of cultivation, the myxoid matrix is also reduced and only some cells show lipid-rich cytoplasm. x 200

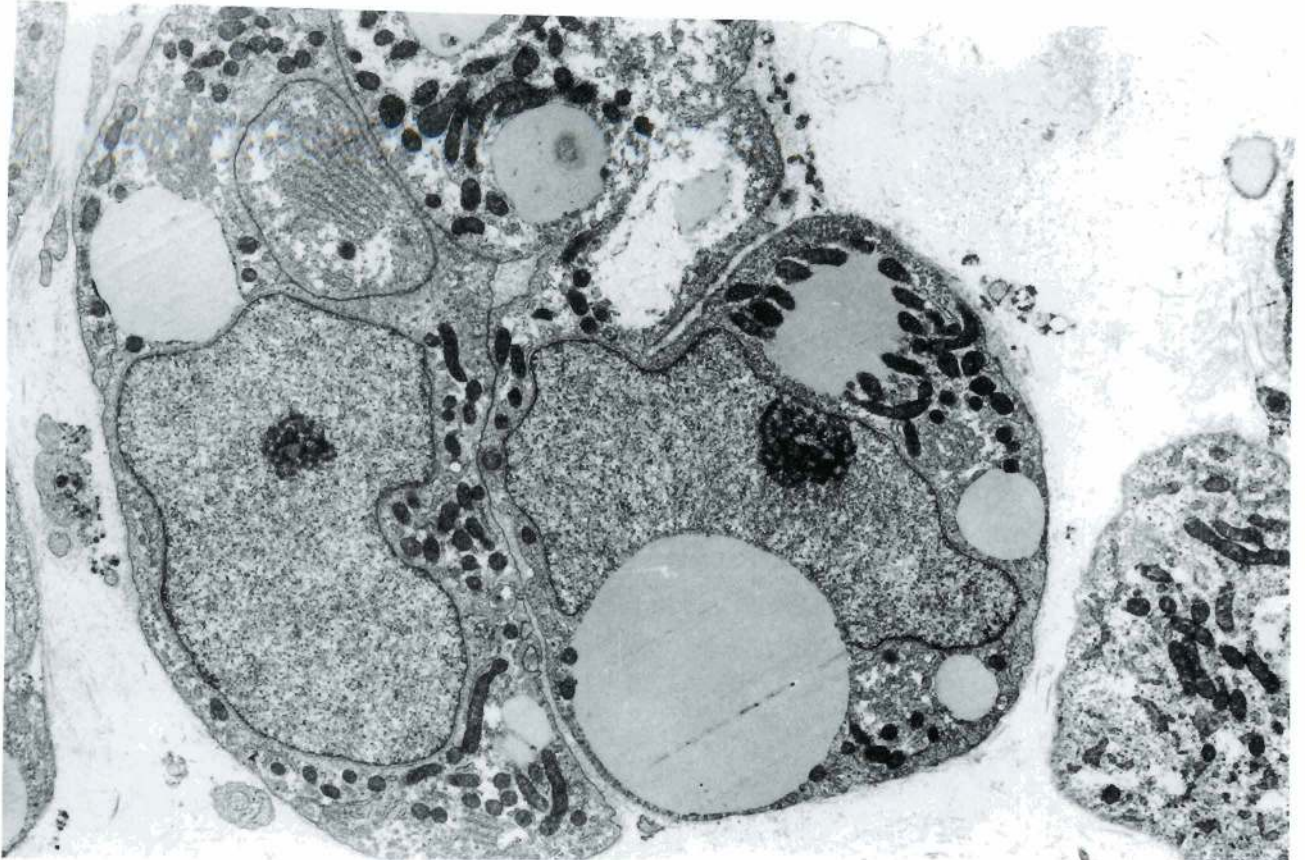


Fig. 3. Case 1. Electron microscopy. The cultivated cells show a glycogen-rich cytoplasm with some mitochondria and small lipid droplets without membrane (15 days of cultivation). x 5,000

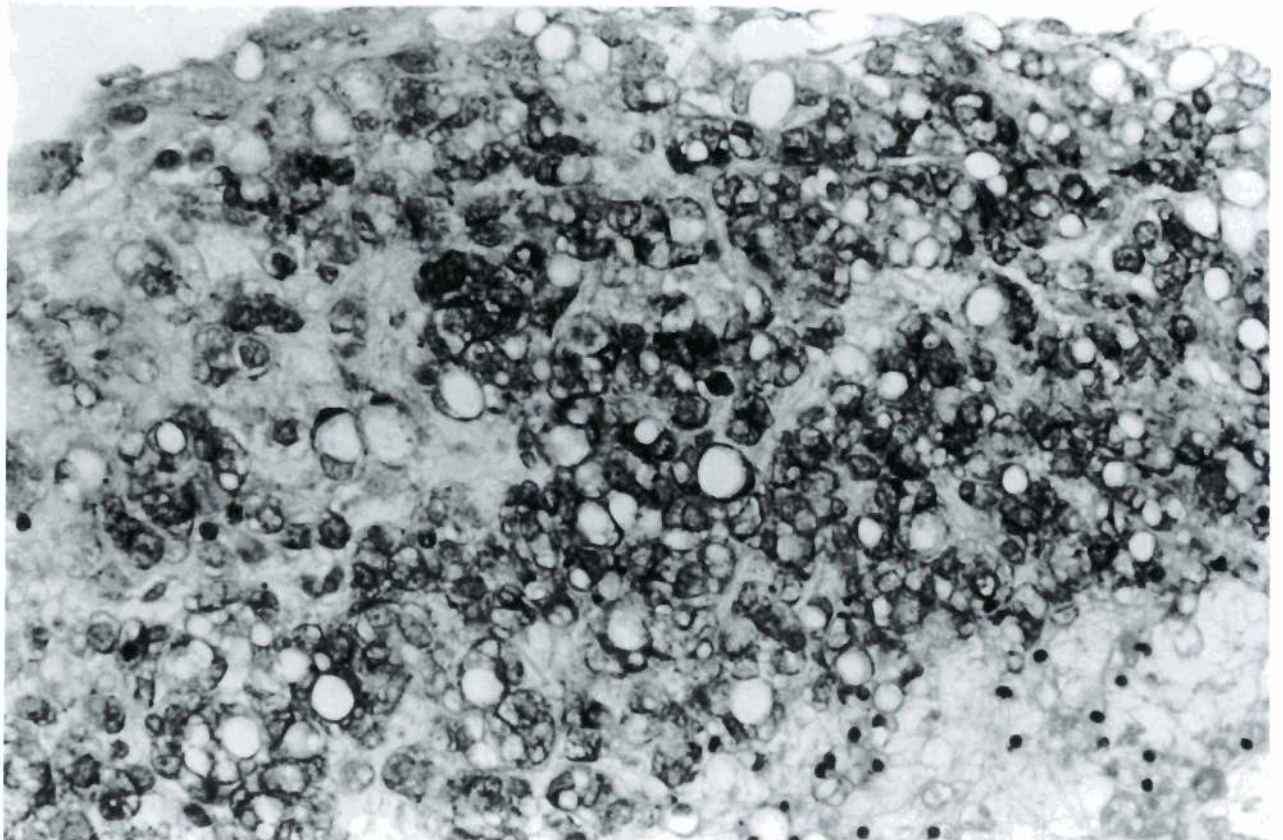


Fig. 4. Case 1. P.A.S. The lipoblasts show a glycogen-rich cytoplasm among the lipid vacuoles. x 200

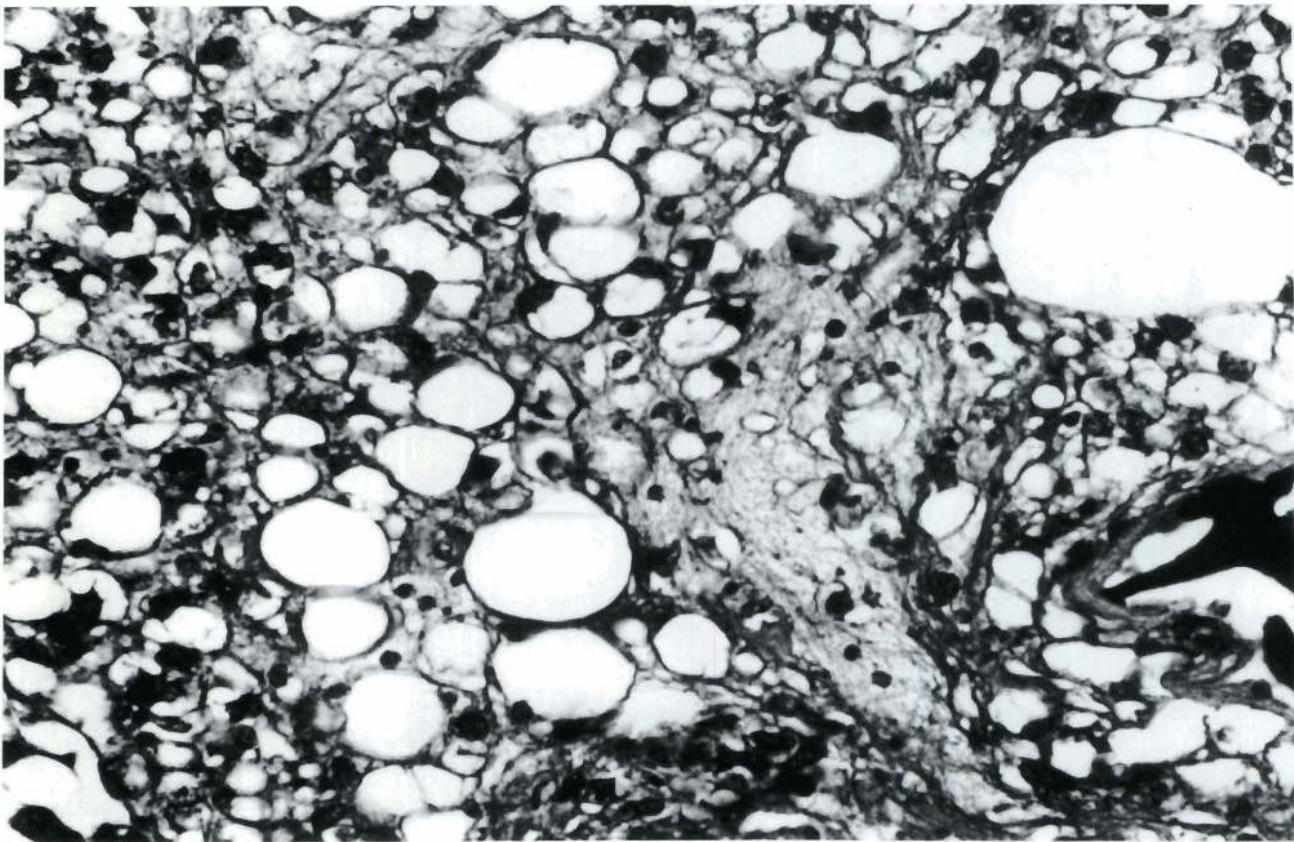
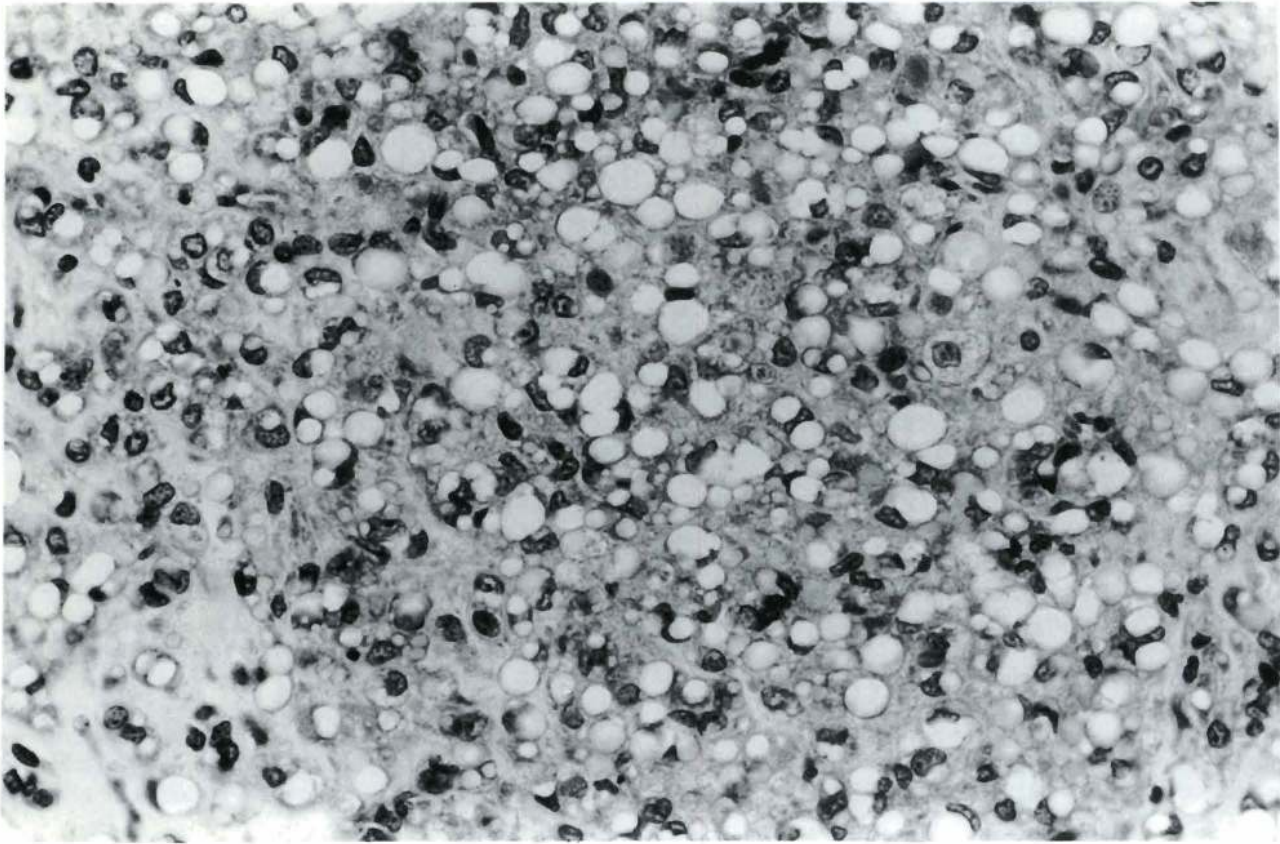


Fig. 5. a. Case 1. C.O. 215. H-E. After 50 days of cultivation, the myxoid matrix has disappeared and most of the cells show a single lipid droplet. x 200. b. Case 2. C.O. 341. H-E. Also in this case, the well-differentiated fat cells are conspicuous. x 200

Organ culture of myxoid liposarcomas

identification, especially because of the cell and tissue differentiation obtained under certain environmental conditions (Sipe et al., 1973). This phenomenon, as far we known, has not been described in liposarcomas.

Our two cases showed a progressive differentiation with development of adipoblasts showing a progressive level of maturation.

This way of differentiation is similar to that of the fat tissue during intrauterine growth (Napolitano, 1963; Iyama et al., 1979). In both cases, undifferentiated mesenchymal cells were first laden with glycogen, which was gradually substituted by lipid droplets. These droplets tended to join to each other, displacing the nucleus towards the periphery so that the cells acquired a round shape.

In the last phase, the cell acquired a «signet ring» morphology. A single large lipidic vacuole displaced the nucleus and restricted the cytoplasm to a thin edge with few organelles. This cell did not yet contain glycogen.

The progressive reduction of the myxoid intercellular matrix from the initial phase of the cultivation depends, in our opinion, not on the differentiation of the tumoral tissue but on the fluid diffusion phenomena between the interphase explant-culture medium, and has no

significance in the differentiation process of the tumoral tissue.

These observations confirm the origin of liposarcomas from white fat, a fact that has been supported by electron microscopical studies (Bolen and Thornig, 1980; Rossouw et al., 1986) and which is also another fact against a possible histogenetic relation with brown fat (Lagace et al., 1979).

As to the differential diagnosis «in vitro», the cultural characteristics of malignant fibrous histiocytoma are completely different, as they are composed of larger cells, showing a higher pleomorphism, and even the development of histiocytic giant cells. There is neither cellular vacuolization, nor fat loading.

Neither are there other soft tissue tumors taking part in the differential diagnosis of myxoid liposarcoma to leiomyosarcoma, fibrosarcoma, myxoma, etc. that show a growth pattern «in vitro» different to that of liposarcoma (personal observation).

In conclusion, myxoid liposarcomas show a characteristic behaviour in organ culture based on a progressive predominance of adipoblasts, whereas the primitive mesenchymal cells diminish. This redifferentiation «in vitro» is similar to the maturation of foetal white fat tissue and allows its

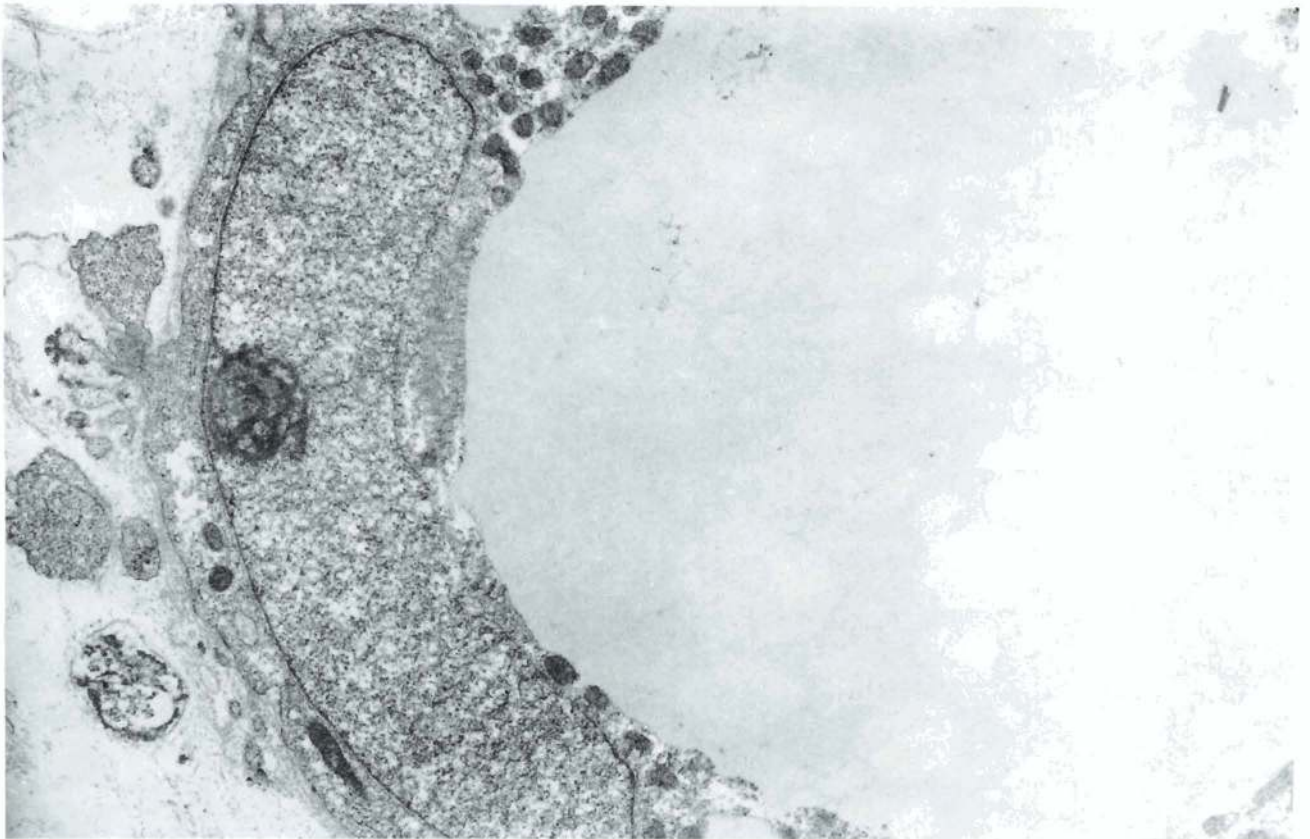


Fig. 6. Case 2. Electron microscopy. As with light microscopy, the ultrastructure shows the redifferentiation of the tumoral cells. The cytoplasm is reduced to a small ring containing the nucleus because of the development of a large, single lipid droplet (50 days of cultivation). x 6,000

differential diagnosis from other soft tissue myxoid neoplasms.

Acknowledgements. The authors would like to thank Dr. Alvarez for the ultrastructural study, Mrs. Magdalena Blanco and Mrs. Loli Carneros for their histochemical work, Mr. Luis A. López-Rodríguez for the photographic work, Ms. Concha Bermejo for the typing of the original and Ms. Teresa Escalona for the translation into English.

References

- Bolen J.W. and Thorning D. (1980). Benign lipoblastoma and myxoid liposarcoma. A comparative light- and electron-microscopic study. *Am. J. Surg. Pathol.* 4, 163-174.
- Cocchia D., Lauriola L., Stolfi V.M., Tallini G. and Michetti F. (1983). S-100 antigen labels neoplastic cells in liposarcoma and cartilaginous tumors. *Virchows Arch. (A)* 402, 139-143.
- Dekmezian R., Zaatari G.S. and Austin G.E. (1987). An immunohistochemical study for apolipoprotein B in human sarcomas. *Arch. Pathol. Lab. Med.* 111, 433-435.
- Enzinger F.M. and Weiss S.W. (1988). *Soft tissue tumors*. 2nd. Ed. C.V. Mosby Co. St. Louis.
- Ghadially F.N. (1978). *Diagnostic electron microscopy of tumours*. 2nd Ed. Butterworth. London. pp 369-373.
- Iyama K., Ohzono K. and Usuku G. (1979). Electron microscopical studies on the genesis of white adipocytes: differentiation of immature pericytes into adipocytes in transplanted preadipose tissue. *Virchows Arch. (B)* 31, 143-155.
- Lagace R., Jacob S. and Seemayer T.A. (1979). Myxoid liposarcoma. An electron-microscopic study: Biological and histogenetic considerations. *Virchows Arch. (A)* 384, 159-172.
- Mackenzie D.H. (1981). The myxoid tumors of somatic soft tissue. *Am. J. Surg. Pathol.* 5, 443-458.
- Napolitano L. (1963). The differentiation of white adipose cells. An electron microscope study. *J. Cell Biol.* 18, 663-679.
- Parker R.C. (1950). *Methods of tissue culture*. 2nd. Ed. Paul B. Hoeber Inc. New York.
- Paul J. (1960). *Cell and tissue culture*. 2nd. Ed. Livingstone Ltd. Edinburg.
- Rossouw D.J., Cinti S. and Dickersin R. (1986). Liposarcoma. An ultrastructural study of 15 cases. *Am. J. Clin. Pathol.* 85, 649-667.
- Sipe J.C., Herman M.M. and Rubinstein L.J. (1973). Electron microscopic observations on human glioblastomas and astrocytomas maintained in organ culture system. *Am. J. Pathol.* 73, 589-606.
- Tsuneyoshi M., Hashimoto H. and Enjoji M. (1983). Myxoid malignant fibrous histiocytoma versus myxoid liposarcoma. A comparative, ultrastructural study. *Virchows Arch. (A)* 400, 187-199.
- Weiss S.W., Langloss J.M. and Enzinger F.M. (1983). Value of S-100 protein in the diagnosis of soft tissue tumours with particular reference to benign and malignant Schwann cell tumors. *Lab. Invest.* 49, 299-308.

Accepted May 15, 1992