



Incidental venous thromboembolism: is anticoagulation indicated?

Marcello Di Nisio^{1,2} and Marc Carrier³

¹Department of Medicine and Ageing Sciences, G. D'Annunzio University, Chieti, Italy; ²Department of Vascular Medicine, Academic Medical Center, Amsterdam, The Netherlands; and ³Department of Medicine, Ottawa Hospital Research Institute at the University of Ottawa, Ottawa, Ontario, Canada

Patients with cancer have a high risk of venous thromboembolism (VTE) and about one-half of these events are incidentally detected. The prognosis of incidental VTE appears to be similar to symptomatic events, with comparably high rates of recurrent VTE in this patient population. In the absence of major contraindications, anticoagulant treatment with low-molecular-weight heparin for 3 to 6 months is generally recommended for incidental proximal deep vein thrombosis as well as for incidental pulmonary embolism that involves multiple subsegmental or more proximal pulmonary arteries. The decision of whether to extend treatment beyond 3 to 6 months should be evaluated on a case-by-case basis after periodic reassessment of the risks factors for bleeding and recurrent VTE while also taking into account patient preferences. The clinical relevance of a single incidental subsegmental pulmonary embolism without concomitant deep vein thrombosis is uncertain and either a watchful approach or a shorter course of anticoagulation to minimize the bleeding risk may also be considered. Preliminary evidence suggests that anticoagulation treatment may be beneficial for cancer patients with incidental distal deep vein thrombosis or incidental splanchnic vein thrombosis.

Learning Objectives

- Understand the incidence and prognostic relevance of incidental venous thromboembolism
- Learn the management options for incidental deep vein thrombosis and pulmonary embolism

Introduction

Patients with cancer have a high risk of developing venous thromboembolic events (VTEs), including deep venous thrombosis (DVT) and pulmonary embolism (PE), because of a state of chronic hypercoagulability caused by the cancer itself and by cancer therapies such as chemotherapy or radiotherapy.¹ About one-half of all VTEs in cancer patients are incidentally detected without any clinical suspicion of VTE at the time of diagnosis.^{2,3} Although incidental VTEs may be truly asymptomatic, as many as two-thirds of affected patients report symptoms such as cough and fatigue or signs indicative of potential DVT.⁴⁻⁷ These clinical findings, however, may be often regarded as poorly specific for the presence of VTE and considered a side effect of the underlying cancer or its associated treatment.

In this review, we discuss the clinical relevance of incidental VTE in patients with cancer and critically evaluate the evidence on the efficacy and safety of anticoagulation in these patients.

Prevalence of incidental VTE

The prevalence of incidental VTE seems to vary broadly from less than 1% to 15% or higher, with most studies reporting incidental PE

(Tables 1-3).^{2,6,8-15} This large variation probably stems from differences in study populations (eg, tumor type and stage), frequency and type of imaging tests used, and single vs double reading of the diagnostic scans.² Incidental VTEs are mostly diagnosed by multidetector computed tomography (MDCT) scans requested for baseline staging, treatment response evaluation, or routine surveillance while off anticancer treatment. Although these scans do not represent the standard imaging tests for the diagnosis of VTE (ie, compression ultrasonography for DVT, CT pulmonary angiography or ventilation/perfusion lung scan for PE), the high spatial and temporal resolution of modern MDCT in conjunction with high-concentration contrast media enables the detection of VTEs even in routine CT scans.

The collimation of MDCT influences test accuracy with smaller slice thickness carrying a higher sensitivity, reduced artifacts, and increased detection of peripheral thrombosis such as subsegmental PEs.^{9,15} In a large prospective evaluation of 999 cancer patients undergoing contrast-enhanced chest CT examination for cancer follow-up, 30% of the 5-mm scans erroneously interpreted as negative were correctly reclassified when the collimation was decreased to 1.25 mm.¹⁵ Confident diagnosis of a filling defect at thick slices can be difficult with the potential of false positives resulting from partial voluming, respiratory or cardiogenic movement artifacts, and the presence of adjacent peribronchial lymph nodes. Tresoldi and colleagues found that thinner reconstructions allowed a confident diagnosis of 3% to 10% of cases that remained uncertain at the first 5-mm evaluation.¹⁵ False-positive results may still be

Conflict-of-interest disclosure: M.D.N. is on the Board of Directors or an advisory committee for Daiichi Sankyo, BMS, and Pfizer and has received honoraria from Daiichi Sankyo and Bayer Health Care. M.C. has received research funding and honoraria from BMS, Leo Pharma, Bayer, Pfizer, and Sanofi.

Off-label drug use: None disclosed.

Table 1. Incidental PE in cancer patients

Reference	Study design	Cancer patients (N)	Cancer type	CT reassessment	CT scanner	Slice thickness	iPE, n (%)
3	Retrospective	3270	Mixed	Yes	64-row MDCT	5 mm	129 (3.9)
44	Prospective	1090	Mixed	Yes	NR	2.5 mm	14 (1.28)
6	Retrospective	207	Lung	No	NR	NR	5 (2.4)
45	Prospective	588	Mixed	Yes	4-row MDCT	5-8 mm	10 (1.7)
46	Prospective	2085	Mixed	NR	NR	2 mm	44 (2.1)
47	Retrospective	410	Mixed	Yes	4-row MDCT	5 mm	14 (3.4)
48	Prospective	385	Mixed	No	4-row MDCT	5-8 mm	10 (2.6)
49	Retrospective	403	Mixed	Yes	4-row MDCT	3.75 mm	16 (4.0)
50	Retrospective	397	Mixed	Yes	NR	8 mm	13 (3.3)
51	Retrospective	787	Mixed	Yes	16-row MDCT	2.5 mm	15 (1.9)
52	Prospective	343	Mixed	Yes	4- or 16-row MDCT	1-3 mm	18 (5.2)
53	Retrospective	765	Mixed	Yes	16-row MDCT	2.5 mm	17 (2.2)
54	Retrospective	8014	Lung	No	NR	NR	180 (2.2)
8	Retrospective	342	Mixed	Yes	4- or 16-row MDCT	1-3 mm	6 (1.8)
55	Retrospective	1921	Mixed	Yes	NR	NR	24 (1.2)
9	Prospective	407	Mixed	Yes	64-row MDCT	1 and 5 mm	18 (4.4)
10	Retrospective	135	Pancreas	No	NR	NR	4 (3.0)
11	Retrospective	13 783	Mixed	No	4- or 64-row MDCT	5-7 mm	202 (1.47)
12	Retrospective	1331	Mixed	No	PET-CT	3 mm	9 (0.7)
56	Retrospective	453	Prostate	No	NR	NR	3 (0.66)
57	Retrospective	838	Mixed	No	NR	NR	3 (0.36)
13	Retrospective	220	Gastrointestinal	No	NR	NR	13 (5.9)
14	Retrospective	141	Lung	Yes	6- or 64-row MDCT	2.5 mm	21 (14.9)
15	Prospective	999	Mixed	Yes	64-row MDCT	1.25 and 5 mm	51 (5.1)

iPE, incidental pulmonary embolism; NR, not reported; PET, positron emission tomography.

a concern when peripheral thrombosis such as subsegmental PE is incidentally detected. Confirmation by CT pulmonary angiography is often not feasible in these cases because of additional radiation and contrast exposure for the patient as well as increased health care costs. Interobserver variability may also complicate the diagnosis of incidental VTE. Two studies showed a high level of agreement between radiologists for proximal incidental PEs,^{16,17} but a disappointingly lower agreement for filling defects that involved segmental and subsegmental branches.¹⁷ Therefore, it is important to review the images of reported incidental peripheral filling defects with an experienced radiologist to avoid false-positive diagnosis of incidental subsegmental PE in this patient population and an unnecessary exposure to potentially harmful anticoagulation treatment.

Data on the prevalence of incidental DVT of the extremities are sparse and show a large variation from less than 1% to about 7% (Table 2). These estimates may significantly underestimate the actual prevalence of incidental DVT because systematic assessment of

the veins down to the trifurcation area or in the upper limb is not routinely performed.

SVT

Although generally regarded as a relatively rare type of VTE, splanchnic vein thrombosis (SVT) is increasingly diagnosed in patients with cancer, which may be partly explained by the frequent detection of incidental SVT on repeated imaging tests performed for cancer staging and response assessment.¹⁸⁻²⁰ As for VTE at other sites, the prevalence of incidental SVT ranges broadly from less than 2%^{8,12} to more than 20%¹⁰ (Table 3). The type of cancer evaluated as well as type and frequency of imaging tests performed may affect these estimates, as suggested by a recent retrospective cohort of 135 pancreatic cancer patients in whom a diagnosis of incidental SVT was confirmed in as many as 23% of patients.¹⁰ In a small retrospective series of 18 cancer patients with incidental SVT, thrombosis more frequently involved the portal (61%) and superior mesenteric (50%) veins, with multiple veins affected in 44% of the patients.²¹

Table 2. Incidental DVT of the extremities in cancer patients

Reference	Study design	Cancer patients (N)	Cancer type	Scanner	Incidental DVT, n (%)	Most proximal vein			
						Inferior vena cava	Ileofemoral	popliteal	UEDVT
44	Prospective	1090	Mixed	NR	3 (0.3)	0	3	NR	NR
6	Retrospective	207	Lung	NR	3 (1.45)	NR	NR	NR	3
50	Retrospective	339	Mixed	NR	23 (6.8)	1	23	0	0
10	Retrospective	135	Pancreas	NR	6 (4.44)*	0	5	NR	1
12	Retrospective	1331	Mixed	PET-CT	8 (0.6)	0	4	0	3
56	Retrospective	453	Prostate	NR	13 (2.9)	NR	NR	NR	NR
57	Retrospective	838	Mixed	NR	8 (0.95)	4	4	NR	1

UEDVT, upper extremity DVT.

*Events.

Table 3. Incidental SVT in cancer patients

Reference	Study design	Cancer patients (N)	Cancer type	Scanner	Patients with incidental SVT, n (%)	Site of SVT, n
44	Prospective	1090	Mixed	NR	3 (0.27)	Superior mesenteric vein = 1 Pelvic = 1
6	Retrospective	207	Lung	NR	3 (1.45)	Gonadal = 1 Portal vein = 2
10	Retrospective	135	Pancreas	NR	31 (22.96)	Hepatic vein = 1 47 DVTs* Portal vein = 18 Splenic = 14 Superior mesenteric vein = 11 Inferior mesenteric vein = 4 Hepatic = 1 Gonadal = 1
12	Retrospective	1331	Mixed	PET-CT	2 (0.15)	Portal vein = 1 Superior mesenteric vein = 1
57	Retrospective	838	Mixed	NR	8 (0.95)	Portal vein = 5 Superior mesenteric vein = 3 Renal vein = 1
58	Retrospective	1442	Mixed	64-row MDCT	36 (2.5)	NR

*Events.

Prognosis of incidental VTE

About 60% of all incidental PEs involve the main or lobar arteries; bilateral lung involvement occurs in approximately one-third of cases (Table 4). Few small studies have suggested that incidental PE may present a lower embolic burden when compared with symptomatic PE.^{3,22} However, these studies may have underestimated the actual thrombotic load.

Several studies reported a similar prognosis for incidental and symptomatic VTE in patients with cancer.^{5,23-26} In a prospective study of cancer patients newly diagnosed with VTE, the incidence of recurrent VTE (11% vs 18%), major bleeding (7% vs 10%), and overall survival (71% vs 71%) were comparable in patients with incidental and symptomatic VTE over a mean follow-up of 477 days.²⁴ Similar findings have consistently been reported in other studies,^{6,17} whereas some investigators found better survival rates in cancer patients with incidental VTE.^{6,14} Differences in study populations, type of incidental VTE, and thrombotic load

evaluated could explain these discrepant findings. In a case-control study that compared mortality rates of 70 cancer patients with incidental PE with 137 control patients without PE, the former group had a significantly lower median survival (8 vs 12 months; hazard ratio [HR], 1.51; 95% confidence interval [CI], 1.01-2.27), with a difference that was apparently driven by the poor prognosis of proximal PEs.⁴ Survival of patients with incidental subsegmental PEs (n = 17) was comparable to that of controls without PE and significantly better than survival of patients with incidental proximal PE (7 months vs 12 months; HR, 1.70; 95% CI, 1.06-2.74).

Isolated subsegmental PE

The clinical relevance of PE confined to 1 or more subsegmental branches (ie, isolated symptomatic or incidental subsegmental PE) is unclear. Symptomatic subsegmental PE might have limited clinical relevance, with a number of retrospective studies showing no recurrent VTE during 3 months of follow-up in patients with isolated symptomatic subsegmental PE in whom anticoagulant therapy was

Table 4. Radiologic characteristics of incidental pulmonary embolism in cancer patients

Reference	iPE (N)	Most proximal arterial thrombus location, n (%)						
		Main	Lobar	Segmental	Subsegmental	Central	Peripheral	Bilateral (%)
5	66	4 (6.1)	14 (21.2)	38 (57.6)	10 (15.2)	18 (27.3)	48 (72.7)	NR
4	70	7 (10.0)	26 (37.1)	20 (28.6)	17 (24.3)	33 (47.1)	37 (52.9)	NR
6	5	3 (60)	NR	1 (20)	1 (20)	3 (60)	2 (40)	2 (40)
45	13	4 (30.8)	4 (30.8)	5 (38.5)	0 (0.0)	8 (61.5)	5 (38.5)	6 (46.2)
49	16	0 (0.0)	8 (50.0)	7 (43.8)	1 (6.3)	8 (50.0)	8 (50.0)	6 (37.5)
54	113	NR	NR	56 (49.6)	0 (0.0)	57 (50.4)	56 (49.6)	32 (28.3)
9	18	4 (22.2)	5 (27.8)	6 (33.3)	3 (16.7)	9 (50.0)	9 (50.0)	NR
11	202	62 (30.7)	62 (30.7)	65 (32.2)	13 (6.4)	124 (61.4)	78 (38.6)	NR
12	9	4 (44.4)	2 (22.2)	3 (33.3)	0	6 (66.7)	3 (33.3)	NR
57	3	NR	NR	2 (66.7)	0 (0.0)	1 (33.3)	2 (66.7)	NR
14	21	2 (9.5)	6 (28.6)	13 (61.9)	0 (0.0)	8 (38.1)	13 (61.9)	5 (23.8)
15	51	3 (5.9)	11 (21.6)	27 (52.9)	10 (19.6)	14 (27.4)	37 (72.6)	14 (27.5)
23	45	NR	NR	30 (66.7)	4 (8.9)	11 (24.4)	34 (75.6)	NR
24	56	NR	NR	NR	NR	36 (64.3)	20 (35.7)	23 (41.1)
Total	674	93 (13.8)	130 (19.3)	260 (38.6)	59 (8.7)	325 (48.2)	349 (51.8)	67 (30.2)

withheld.²⁷ By contrast, in a combined post hoc analysis of 2 large prospective cohort studies, den Exter and colleagues suggested that subsegmental PE is associated with similar rates of recurrent VTE, bleeding, and mortality as PEs that involve more proximal arteries.²⁸ In a recent cross-sectional chart review of 2213 patients who underwent CT pulmonary angiography, 28% of 82 patients diagnosed with symptomatic subsegmental PE had active malignancy and only 22% of them received anticoagulant treatment.²⁹ Major bleeding complications occurred in 2 of the 43 patients who received anticoagulation for subsegmental PE, whereas none of the patients with subsegmental PE developed recurrent VTE.

In most studies, incidental subsegmental PE accounted for less than 10% of all incidental PEs, although a prevalence as high as 20% to 24% has been reported.^{2,30} In a recent individual patient data meta-analysis, van der Hulle and colleagues pooled data of 926 cancer patients with incidental PE from 11 cohorts, including 9 with a retrospective design.³⁰ Recurrent VTE seemed to occur at similar rates in patients with subsegmental PE and those with a more proximal PE (7.8% and 5.5%) with a high risk of recurrence in subsegmental PEs among cancer patients that were left untreated (4 of 42). None of these studies analyzed the prognosis of multiple vs single subsegmental PEs separately.

SVT

The prognosis of incidental SVT is unclear. Whereas some studies reported a prognosis similar to patients without incidental SVT, others have not. A small case series of cancer patients showed that the overall median survival was similar in patients with incidental SVT compared with age and stage-matched controls without SVT (11 vs 12 months).²¹ Another study reported comparable 3- and 6-month survival rates in patients with incidental and symptomatic SVT.¹⁰ Similarly, a retrospective cohort study including 626 patients with pancreatic cancer undergoing chemotherapy has reported that the overall survival was comparable in patients diagnosed with incidental SVT and those who did not develop any VTE ($P = .17$).³¹ Finally, a large international prospective cohort of 604 patients with SVT (22% solid cancer, 9% hematological malignancy), with approximately one-third of incidental events, reported that 9% (12/136) of patients with cancer developed a recurrent VTE for an incidence of 7.6 per 100 patient-years and an overall rate of major bleeding complications of 4.4 per 100 patient-years over a follow-up period of 2 years.¹⁹ In a post hoc analysis conducted on the subgroup with incidental SVT, the long-term prognosis was comparable to symptomatic SVT with a non-negligible incidence of recurrent VTE; 11% (7/62) of patients with cancer and incidental SVT developed a recurrent event for an incidence of 8.1 per 100 patient-years.²⁰

Screening for incidental VTE

The high prevalence of incidental VTE raises the question about the usefulness of early detection of these VTEs by means of screening tests with potential benefits to patients from timely institution of treatment. Candidate patients could be those with pancreatic, hepatobiliary, upper gastrointestinal tract, brain, or ovarian cancer^{3,11} and patients with advanced or metastatic disease^{2,3,5,6} in whom a higher prevalence of incidental VTE has been reported. The utility of screening for incidental DVT was evaluated in 35 cancer (mostly pancreatic and gastroesophageal) patients starting a new chemotherapy regimen and regarded to be at high risk of VTE.³² Serial ultrasonography was performed before initiation of chemotherapy and repeated at 4-week intervals for up to 16 weeks. Ultrasonography detected incidental DVT in 3 (9.3%) cases at baseline, none at weeks 4 and 8, and 1 DVT (5.6%) at week 12. These findings suggest the potential usefulness of

ultrasonography to screen for incidental DVT in high-risk populations before chemotherapy with low yield of serial testing. In another prospective study that adopted an even more extensive screening strategy with CT and whole-leg compression ultrasonography, incidental VTE was diagnosed in 27 of 117 patients (23%). More than one-half of the VTEs were distal DVTs of the leg ($n = 18$), 6 were proximal DVT, 2 were catheter-related thrombosis, and 2 were incidental PEs.³³ The clinical significance of these incidental VTEs detected on screening ultrasonography is unknown and needs further assessment before it can be integrated in clinical practice. Furthermore, the cost-effectiveness of these screening approaches requires further evaluation.

Management

International clinical guidelines recommend 3 to 6 months of low-molecular-weight heparin (LMWH) treatment of cancer-associated symptomatic VTE.³⁴ The decision to continue or withdraw treatment after this initial period as well as the type and dose of anticoagulant should be evaluated case-by-case considering the benefit-to-risk ratio, drug availability, and patient preference.

The indications for the management of incidental VTEs in patients with cancer are largely extrapolated from randomized studies in cancer-associated symptomatic VTE.³⁵ In the only randomized study on the treatment of incidental VTE published to date, 64 patients with cancer and incidental PE were randomized to warfarin (dose-adjusted to achieve an international normalized ratio between 2.0 and 3.0) or fondaparinux (7.5 mg subcutaneously once daily) for 90 days.³⁶ There were no differences in recurrent PE (7 of 32 warfarin patients and 6 of 32 fondaparinux patients, $P = .32$) or in thrombotic events in other locations (6 in both groups, $P = .46$). Major bleeding occurred less frequently in patients treated with fondaparinux ($n = 3$) than in those on warfarin ($n = 6$) (9% vs 19%, $P < .01$). However, the small size of the study, the poorly reported patient characteristics, outcomes, and quality of treatment, as well as the use of off-label fondaparinux as control, seriously limit the generalizability and validity of these findings.

In the individual patient data meta-analysis by van der Hulle and colleagues, 79% of patients received prolonged therapeutic LMWH, 11% vitamin K antagonists, 4.4% another treatment including an inferior vena cava filter or unfractionated heparin, and 5.7% received no treatment.³⁰ No information on the intensity of anticoagulation was provided, but the 6-month risks of recurrent VTE, major bleeding and mortality were 5.8%, 4.7%, and 37%, respectively. Recurrent VTE occurred at similar rates in patients treated with LMWH and vitamin K antagonists (6.2% vs 6.4%). However, the risk of major bleeding complications was fourfold higher in patients on vitamin K antagonists compared with those using LMWH (13% vs 3.9%; HR, 3.9; 95% CI, 1.6-10). In a subanalysis of the Registro Informatizado de Enfermedad TromboEmbólica registry, 20 recurrent VTEs and 45 major bleeding events were diagnosed in 715 cancer patients with incidental PE during a mean 235 days of anticoagulant therapy.³⁷ The rate of major bleeding exceeded that of symptomatic PE (10.1/100 patient-years vs 3.17/100 patient-years, respectively), as did the rate of fatal bleeding compared with the rate of fatal PE (2.66 vs 0.66 deaths per 100 patient-years, respectively). After anticoagulant treatment discontinuation, there were 27 VTEs (14 symptomatic PEs and 13 DVTs) and 5 major bleeding events during a mean follow-up of 117 days. The rate of major bleeding was lower than the rate of symptomatic PE (3.00 vs 8.37 events per 100 patient-years, respectively), with no differences in fatal events. Interpretation of these studies should be done with caution given their

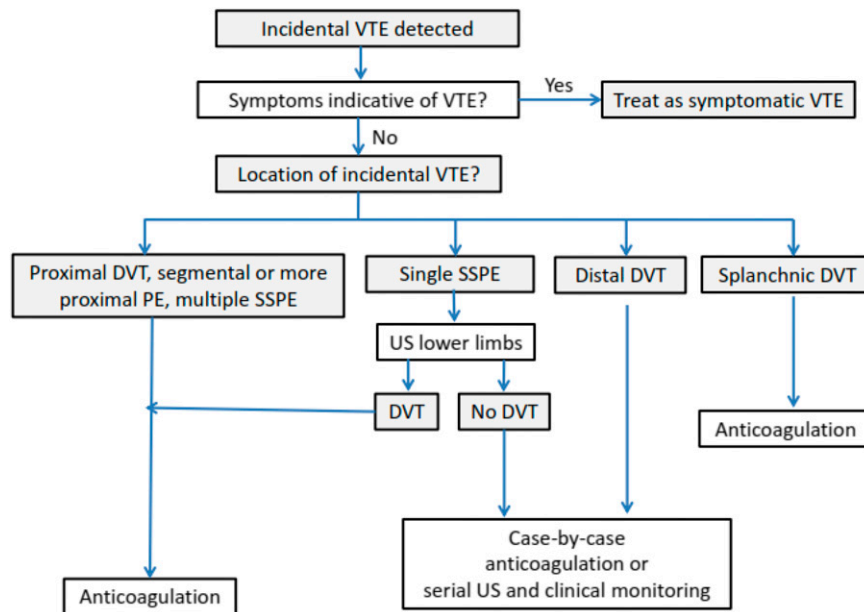


Figure 1. Management of incidental venous thromboembolism.

limitations, including indication or treatment biases, and their relatively small sample size. Nonetheless, these data suggest that patients with incidental VTE are at high risk of recurrent VTE and major bleeding; the risk-benefit ratio seems to support the same management as symptomatic events using LMWH for 3 to 6 months³⁵ (Figure 1). Similar considerations as for symptomatic VTE apply to the extension of LMWH treatment beyond this period.³⁵ This is consistent with current clinical practice guidelines recommendations.³⁴ Warfarin could be an alternative if LMWH is not available, affordable, or acceptable to patients. Data on the use of direct oral anticoagulants for VTE treatment in patients with cancer are scarce.^{34,35} Although not contraindicated, these agents cannot be recommended until further evidence from ongoing studies becomes available (NCT02073682, NCT02583191, ISRCTN86712308).

Few aspects of the management of incidental VTE remain controversial. Although full doses of LMWH are suggested during the initial treatment phase of incidental VTE,^{34,35} physicians need to consider that the age of incidentally detected clots may vary from days to months depending on the interval between imaging tests. A radiologic suspicion of an older clot, especially when VTE is not extensive, could prompt the use of a shorter course of full-intensity anticoagulation with earlier tapering of the dose.^{34,35}

Isolated subsegmental PE

Single isolated subsegmental PE may have limited clinical relevance with uneventful follow-up in patients left untreated and survival rates that are similar to those of cancer patients without PE,^{4,38} although data have been conflicting.³⁰ Routine anticoagulation could potentially unnecessarily expose these patients to the risk of anticoagulant-related bleeding without meaningful benefits. Therefore, it is important to initially review the images of reported incidental single isolated subsegmental PE to avoid false positives and confirm the diagnosis. In patients with a confirmed diagnosis, a conservative strategy using serial ultrasonography would potentially be reasonable, especially in cancer patients at high risk of bleeding.³⁵ Some relatively small studies have suggested that concomitant incidental DVT is not an infrequent finding in patients with incidental PE.^{4,5} Therefore, the

use of bilateral lower limb compression ultrasonography could be helpful to ascertaining the degree of thrombotic burden in a patient with an isolated, single subsegmental PE and enhance the confidence with which to recommend anticoagulation.³⁵ If the decision has been made to treat cancer patients with single, isolated subsegmental PE without DVT, a shorter duration of anticoagulation seems reasonable to minimize bleeding risks. The decision to initiate anticoagulant therapy in these cases should carefully consider patient preferences, effect on patient quality of life, and costs.³⁵ Physicians' attitudes toward isolated subsegmental PE has been explored in several surveys over the past several years.³⁹⁻⁴¹ The proportion of clinicians who are comfortable with withholding anticoagulation in patients with isolated subsegmental PE has ranged from 5% in the presence of concomitant cancer³⁹ to 31% in patients without cancer if additional imaging tests could be performed to exclude a higher thrombotic burden.⁴⁰ In a third survey, the majority of the physicians chose to anticoagulate cancer patients with incidental subsegmental PE despite the uncertain clinical significance of these PEs.⁴¹

Distal DVT

Whether cancer patients with incidental distal DVT require treatment is controversial. Two recent studies evaluated the clinical course of symptomatic distal DVT in patients with cancer.^{42,43} In a substudy of a multicenter, prospective, observational cohort of patients with VTE, the prognosis of 92 cancer patients with symptomatic isolated distal DVT was compared with 92 matched cancer patients with symptomatic proximal DVT and 184 patients without cancer with an isolated distal DVT.⁴² Relative to patients with cancer and proximal DVT, those with cancer-related isolated distal DVT had a similar risk of death (40.8% vs 38.3% patient-years), major bleeding (3.8% vs 3.6% patient-years), and a higher risk of VTE recurrence (5.4% vs 11.5% patient-years). Of 16 recurrent events that occurred in patients with cancer-related isolated distal DVT, 75% were major VTEs (6 PE and 6 proximal DVT). In another recent retrospective cohort of patients with cancer and symptomatic isolated distal DVT, the risk of death (44.8%) and VTE recurrence (13.2 events per 100 patient-years) were substantial during a mean follow-up of 13.9 months.⁴³

Although incidental distal DVT was not evaluated in these studies, the findings suggest that distal DVT may have a poor prognosis in patients with cancer. Based on the observed high risk of recurrent VTE, a course of anticoagulation could be preferable over a more watchful approach with serial compression ultrasonography to detect thrombus extension into the proximal veins³⁵; however, doses and duration of anticoagulant treatment remain to be established.

SVT

The prognostic relevance of SVT and the need to provide anticoagulant treatment of incidental SVT are a matter of debate. Small case series have suggested that SVT may be complicated by recurrent VTE if left untreated with rates as high as 29%.²¹ In the prospective cohort of 604 patients with SVT mentioned previously, anticoagulant therapy was associated with a reduction in thrombotic complications without an increase in the risk of major bleeding.¹⁹ Generalization of these findings to the whole group of patients with cancer and SVT is hampered by the relatively small number of cancer patients included (n = 136), confounding by indication, and the heterogeneity in duration and dosage of anticoagulant treatment provided. The broad variation in the management of SVT as observed in this and earlier studies could be the result of a lack of robust data from randomized controlled trials as well as the physicians' perception of the delicate balance between bleeding and thrombotic risk in these patients. Patients with SVT frequently present concomitant bleeding risk factors such as esophageal varices or thrombocytopenia secondary to hypersplenism, which should be weighed against risk factors for DVT extension or recurrence. In patients with incidental SVT who are neither actively bleeding nor have a very high risk of bleeding, anticoagulant therapy is suggested when thrombosis appears to be acute or shows progression or extension over time.³⁵ Anticoagulant treatment should be continued for at least 3 months.^{18,34,35} Long-term or indefinite anticoagulation should be evaluated on a case-by-case basis with periodic assessment of the risk-to-benefit ratio, patient burden and preferences, and health care costs.

In conclusion, anticoagulant treatment is recommended for incidental proximal DVT and incidental PE that involves multiple subsegmental or more proximal pulmonary arteries. The clinical relevance of isolated subsegmental PE without concomitant DVT is uncertain and either a watchful approach or a shorter course anticoagulation may be considered. Preliminary evidence suggests that incidental distal DVT and SVT may benefit of anticoagulant treatment.

Correspondence

Marcello Di Nisio, Department of Medicine and Ageing Sciences, G. D'Annunzio University, Via dei Vestini 31, 66100 Chieti, Italy; e-mail: mdinisio@unich.it.

References

1. Timp JF, Braekkan SK, Versteeg HH, Cannegieter SC. Epidemiology of cancer-associated venous thrombosis. *Blood*. 2013;122(10):1712-1723.
2. van Es N, Bleker SM, Di Nisio M. Cancer-associated unsuspected pulmonary embolism. *Thromb Res*. 2014;133(Suppl 2):S172-S178.
3. Bach AG, Schmoll H-J, Beckel C, et al. Pulmonary embolism in oncologic patients: frequency and embolus burden of symptomatic and unsuspected events. *Acta Radiol*. 2014;55(1):45-53.
4. O'Connell C, Razavi P, Ghalichi M, et al. Unsuspected pulmonary emboli adversely impact survival in patients with cancer undergoing routine staging multi-row detector computed tomography scanning. *J Thromb Haemost*. 2011;9(2):305-311.
5. Sahut D'Izarn M, Caumont Prim A, Planquette B, et al. Risk factors and clinical outcome of unsuspected pulmonary embolism in cancer patients: a case-control study. *J Thromb Haemost*. 2012;10(10):2032-2038.
6. Connolly GC, Menapace L, Safadjou S, Francis CW, Khorana AA. Prevalence and clinical significance of incidental and clinically suspected venous thromboembolism in lung cancer patients. *Clin Lung Cancer*. 2013;14(6):713-718.
7. Khorana AA, O'Connell C, Agnelli G, Liebman HA, Lee AY; Subcommittee on Hemostasis and Malignancy of the SSC of the ISTH. Incidental venous thromboembolism in oncology patients. *J Thromb Haemost*. 2012;10(12):2602-2604.
8. Farrell C, Jones M, Girvin F, Ritchie G, Murchison JT. Unsuspected pulmonary embolism identified using multidetector computed tomography in hospital outpatients. *Clin Radiol*. 2010;65(1):1-5.
9. Browne AM, Cronin CG, English C, NiMhuircheartaigh J, Murphy JM, Bruzzi JF. Unsuspected pulmonary emboli in oncology patients undergoing routine computed tomography imaging. *J Thorac Oncol*. 2010;5(6):798-803.
10. Menapace LA, Peterson DR, Berry A, Sousou T, Khorana AA. Symptomatic and incidental thromboembolism are both associated with mortality in pancreatic cancer. *Thromb Haemost*. 2011;106(2):371-378.
11. Shinagare AB, Guo M, Hatabu H, et al. Incidence of pulmonary embolism in oncologic outpatients at a tertiary cancer center. *Cancer*. 2011;117(16):3860-3866.
12. Callejas MF, Errázuriz JI, Castillo F, et al. Incidental venous thromboembolism detected by PET-CT in patients with cancer: prevalence and impact on survival rate. *Thromb Res*. 2014;133(5):750-755.
13. Singh R, Sousou T, Mohile S, Khorana AA. High rates of symptomatic and incidental thromboembolic events in gastrointestinal cancer patients. *J Thromb Haemost*. 2010;8(8):1879-1881.
14. Tiseo M, Bersanelli M, Pesenti Barili M, et al. Asymptomatic pulmonary embolism in lung cancer: prevalence and analysis of clinical and radiological characteristics in 141 outpatients. *Tumori*. 2012;98(5):594-600.
15. Tresoldi S, Flor N, Luciani A, Lombardi MA, Colombo B, Cornalba G. Contrast enhanced chest-MDCT in oncologic patients. Prospective evaluation of the prevalence of incidental pulmonary embolism and added value of thin reconstructions. *Eur Radiol*. 2015;25(11):3200-3206.
16. den Exter PL, van der Hulle T, Hartmann IJC, et al. Reliability of diagnosing incidental pulmonary embolism in cancer patients. *Thromb Res*. 2015;136(3):531-534.
17. Bleker SM, Beenen LF, Di Nisio M, et al. Incidental pulmonary embolism in cancer patients: Interobserver agreement on the diagnosis and extent with a focus on distal clots. *Thromb Res*. 2016;147:46-51.
18. Ageno W, Dentali F, Squizzato A. How I treat splanchnic vein thrombosis. *Blood*. 2014;124(25):3685-3691.
19. Ageno W, Riva N, Schulman S, et al. Long-term clinical outcomes of splanchnic vein thrombosis: results of an international registry. *JAMA Intern Med*. 2015;175(9):1474-1480.
20. Riva N, Ageno W, Schulman S, et al; International Registry on Splanchnic Vein Thrombosis (IRSVT) study group. Clinical history and anti-thrombotic treatment of incidentally detected splanchnic vein thrombosis: a multicentre, international prospective registry. *Lancet Haematol*. 2016;3(6):e267-e275.
21. Bozas G, Ramasamy S, Avery G, Maraveyas A. Unsuspected visceral venous thrombosis, in patients with cancer of the gastrointestinal system. *Thromb Res*. 2012;130(4):682-684.
22. den Exter PL, Kroft LJ, van der Hulle T, Klok FA, Jiménez D, Huisman MV. Embolic burden of incidental pulmonary embolism diagnosed on routinely performed contrast-enhanced CT-imaging in cancer patients. *J Thromb Haemost*. 2013;11(8):1620-1622.
23. den Exter PL, Hooijer J, Dekkers OM, Huisman MV. Risk of recurrent venous thromboembolism and mortality in patients with cancer incidentally diagnosed with pulmonary embolism: a comparison with symptomatic patients. *J Clin Oncol*. 2011;29(17):2405-2409.
24. Font C, Farrús B, Vidal L, et al. Incidental versus symptomatic venous thrombosis in cancer: a prospective observational study of 340 consecutive patients. *Ann Oncol*. 2011;22(9):2101-2106.

25. Larsen AC, Brøndum Frøkjær J, Wishwanath Iyer V, et al. Venous thrombosis in pancreaticobiliary tract cancer: outcome and prognostic factors. *J Thromb Haemost.* 2015;13(4):555-562.
26. Shinagare AB, Okajima Y, Oxnard GR, et al. Unsuspected pulmonary embolism in lung cancer patients: comparison of clinical characteristics and outcome with suspected pulmonary embolism. *Lung Cancer.* 2012; 78(2):161-166.
27. Carrier M, Righini M, Wells PS, et al. Subsegmental pulmonary embolism diagnosed by computed tomography: incidence and clinical implications. A systematic review and meta-analysis of the management outcome studies. *J Thromb Haemost.* 2010;8(8):1716-1722.
28. den Exter PL, van Es J, Klok FA, et al. Risk profile and clinical outcome of symptomatic subsegmental acute pulmonary embolism. *Blood.* 2013; 122(7):1144-1149, quiz 1329.
29. Goy J, Lee J, Levine O, Chaudhry S, Crowther M. Sub-segmental pulmonary embolism in three academic teaching hospitals: a review of management and outcomes. *J Thromb Haemost.* 2015;13(2):214-218.
30. van der Hulle T, den Exter PL, Planquette B, et al. Risk of recurrent venous thromboembolism and major hemorrhage in cancer-associated incidental pulmonary embolism among treated and untreated patients: a pooled analysis of 926 patients. *J Thromb Haemost.* 2016;14(1): 105-113.
31. Olmos VP, Adrian SG, Podesta MC, et al. Splanchnic vein thrombosis in ambulatory pancreatic cancer patients receiving chemotherapy [published online ahead of print]. *J Clin Oncol.* doi:10.1200/jco.2015.33.15_suppl. e20658.
32. Khorana AA, Rubens D, Francis CW. Screening high-risk cancer patients for VTE: a prospective observational study. *Thromb Res.* 2014;134(6): 1205-1207.
33. Kitayama H, Tsuji Y, Sugiyama J, Kondo T, Hirayama M. Venous thromboembolism in hospitalized cancer patients receiving chemotherapy in Japan: a prospective observational study. *Ann Oncol.* 2015;26: 116.
34. Lyman GH, Khorana AA, Kuderer NM, et al; American Society of Clinical Oncology Clinical Practice. Venous thromboembolism prophylaxis and treatment in patients with cancer: American Society of Clinical Oncology clinical practice guideline update. *J Clin Oncol.* 2013; 31(17):2189-2204.
35. Di Nisio M, Lee AYY, Carrier M, Liebman HA, Khorana AA; Subcommittee on Haemostasis and Malignancy. Diagnosis and treatment of incidental venous thromboembolism in cancer patients: guidance from the SSC of the ISTH. *J Thromb Haemost.* 2015;13(5):880-883.
36. Amato B, Compagna R, Rocca A, et al. Fondaparinux vs warfarin for the treatment of unsuspected pulmonary embolism in cancer patients. *Drug Des Devel Ther.* 2016;10:2041-2046.
37. Peris M, Jiménez D, Maestre A, et al; RIETE Investigators. Outcome during and after anticoagulant therapy in cancer patients with incidentally found pulmonary embolism. *Eur Respir J.* 2016;48(5):1360-1368.
38. Donato AA, Khoche S, Santora J, Wagner B. Clinical outcomes in patients with isolated subsegmental pulmonary emboli diagnosed by multidetector CT pulmonary angiography. *Thromb Res.* 2010;126(4): e266-e270.
39. den Exter PL, van Roosmalen MJG, van den Hoven P, et al. Physicians' management approach to an incidental pulmonary embolism: an international survey. *J Thromb Haemost.* 2013;11(1):208-213.
40. Carrier M, Kimpton M, LE Gal G, et al. The management of a sub-segmental pulmonary embolism: a cross-sectional survey of Canadian thrombosis physicians. *J Thromb Haemost.* 2011;9(7):1412-1415.
41. Lim WY, Bozas G, Noble S, Hart S, Maraveyas A. Anticoagulating the subsegmental pulmonary embolism in cancer patients: a survey amongst different medical specialties. *J Thromb Thrombolysis.* 2015;40(1):37-41.
42. Galanaud J-P, Sevestre M-A, Pernod G, et al. Long-term outcomes of cancer-related isolated distal deep vein thrombosis: the OPTIMEV study. *J Thromb Haemost.* 2017;15(5):907-916.
43. Dentali F, Pegoraro S, Barco S, et al. Clinical course of isolated distal deep vein thrombosis in patients with active cancer: a multicenter cohort study [published online ahead of print 21 June 2017]. *J Thromb Haemost.*
44. Escalante CP, Gladish GW, Qiao W, et al. Prospective cohort study of cancer patients diagnosed with incidental venous thromboembolism on routine computed tomography scans. *Support Care Cancer.* 2017;25(5): 1571-1577.
45. Gosselin MV, Rubin GD, Leung AN, Huang J, Rizk NW. Unsuspected pulmonary embolism: prospective detection on routine helical CT scans. *Radiology.* 1998;208(1):209-215.
46. Boswell WD, Pierce J, Fahimi A, Parisky Y, Sheth P. Incidental pulmonary emboli detected by multi-detector row spiral CT in cancer patients. *Cancer Imaging.* 2004;5:1-7.
47. Storto ML, Di Credico A, Guido F, Larici AR, Bonomo L. Incidental detection of pulmonary emboli on routine MDCT of the chest. *AJR Am J Roentgenol.* 2005;184(1):264-267.
48. Sebastian AJ, Paddon AJ. Clinically unsuspected pulmonary embolism—an important secondary finding in oncology CT. *Clin Radiol.* 2006;61(1): 81-85.
49. Gladish GW, Choe DH, Marom EM, Sabloff BS, Broemeling LD, Munden RF. Incidental pulmonary emboli in oncology patients: prevalence, CT evaluation, and natural history. *Radiology.* 2006;240(1): 246-255.
50. Cronin CG, Lohan DG, Keane M, Roche C, Murphy JM. Prevalence and significance of asymptomatic venous thromboembolic disease found on oncologic staging CT. *AJR Am J Roentgenol.* 2007;189(1):162-170.
51. Rita Larici A, Calandriello L, Maggi F, Torge M, Bonomo L. Prevalence of incidental pulmonary emboli in oncology patients. *Radiology.* 2007; 245(3):921-922, author reply 921-922.
52. Ritchie G, McGurk S, McCreath C, Graham C, Murchison JT. Prospective evaluation of unsuspected pulmonary embolism on contrast enhanced multidetector CT (MDCT) scanning. *Thorax.* 2007;62(6): 536-540.
53. Hui GC, Legasto A, Wittram C. The prevalence of symptomatic and coincidental pulmonary embolism on computed tomography. *J Comput Assist Tomogr.* 2008;32(5):783-787.
54. Sun J-M, Kim TS, Lee J, et al. Unsuspected pulmonary emboli in lung cancer patients: the impact on survival and the significance of anticoagulation therapy. *Lung Cancer.* 2010;69(3):330-336.
55. Di Nisio M, Ferrante N, De Tursi M, et al. Incidental venous thromboembolism in ambulatory cancer patients receiving chemotherapy. *Thromb Haemost.* 2010;104(5):1049-1054.
56. Chaturvedi S, Sidana S, Elson P, Khorana AA, McCrae KR. Symptomatic and incidental venous thromboembolic disease are both associated with mortality in patients with prostate cancer. *PLoS One.* 2014; 9(8):e94048. doi: 10.1371/journal.pone.0094048. eCollection 2014.
57. Douma RA, Kok MGM, Verberne LM, Kamphuisen PW, Büller HR. Incidental venous thromboembolism in cancer patients: prevalence and consequence. *Thromb Res.* 2010;125(6):e306-e309.
58. Ageno W, Squizzato A, Togna A, et al. Incidental diagnosis of a deep vein thrombosis in consecutive patients undergoing a computed tomography scan of the abdomen: a retrospective cohort study. *J Thromb Haemost.* 2012;10(1):158-160.