

See discussions, stats, and author profiles for this publication at: <https://www.researchgate.net/publication/277602884>

# Increased prevalence and geographic spread of the cardiopulmonary nematode *Angiostrongylus vasorum* in fox populations in Great Britain

Article in *Parasitology* · June 2015

DOI: 10.1017/S0031182015000463 · Source: PubMed

CITATIONS

67

READS

917

12 authors, including:



**Collette Taylor**

Royal Veterinary College

7 PUBLICATIONS 78 CITATIONS

[SEE PROFILE](#)



**Jane Learmount**

Department for Environment, Food and Rural Affairs

43 PUBLICATIONS 688 CITATIONS

[SEE PROFILE](#)



**Nor Azlina Abdul Aziz**

Universiti Putra Malaysia

22 PUBLICATIONS 165 CITATIONS

[SEE PROFILE](#)



**Clara Montgomery**

Harper Adams University

8 PUBLICATIONS 92 CITATIONS

[SEE PROFILE](#)

Some of the authors of this publication are also working on these related projects:



Tools to support sustainable helminth control in horses [View project](#)



Hoverfly pollination and pollen transport networks [View project](#)

# Increased prevalence and geographic spread of the cardiopulmonary nematode *Angiostrongylus vasorum* in fox populations in Great Britain

C. S. TAYLOR<sup>1</sup>, R. GARCIA GATO<sup>2</sup>, J. LEARMOUNT<sup>2</sup>, N. A. AZIZ<sup>1,3</sup>,  
C. MONTGOMERY<sup>1</sup>, H. ROSE<sup>1</sup>, C. L. COULTHWAIT<sup>4</sup>, J. W. MCGARRY<sup>4</sup>,  
D. W. FORMAN<sup>5</sup>, S. ALLEN<sup>5</sup>, R. WALL<sup>1</sup> and E. R. MORGAN<sup>1\*</sup>

<sup>1</sup> *Veterinary Parasitology & Ecology Group, University of Bristol, School of Biological Sciences, Bristol Life Sciences Building, 24, Tyndall Avenue, Bristol BS8 1TQ, UK*

<sup>2</sup> *Animal and Plant Health Agency, Sand Hutton, York, North Yorkshire YO411LZ, UK*

<sup>3</sup> *Faculty of Bioresource and Food Industry, Universiti Sultan Zainal Abidin, School of Animal Sciences, Tembilaka Campus, 22200 Besut, Terengganu, Malaysia*

<sup>4</sup> *School of Veterinary Science, University of Liverpool, Great Newton Street, Liverpool L3 5RP, UK*

<sup>5</sup> *Swansea Ecology Research Team, Department of Biosciences, Swansea University, Singleton Park, Swansea SA2 8PP, UK*

(Received 5 March 2015; revised 21 March 2015; accepted 22 March 2015)

## SUMMARY

The nematode *Angiostrongylus vasorum* is becoming more widely recorded globally, and is of increasing concern as a cause of disease in dogs. Apparent geographic spread is difficult to confirm due to a lack of standardized disease recording systems, increasing awareness among veterinary clinicians, and recent improvements in diagnostic technologies. This study examines the hypothesis that *A. vasorum* has spread in recent years by repeating the methods of a previous survey of the fox population. The hearts and lungs of 442 foxes from across Great Britain were collected and examined by dissection and flushing of the pulmonary circulation and microscopic inspection of tracheal scrapes. Sampling and parasite extraction methods were identical to an earlier survey in 2005 to ensure comparability. Prevalence of *A. vasorum* was 18.3% (exact binomial confidence bounds 14.9–22.3), compared with 7.3% previously (5.3–9.9,  $n = 546$ ), and had increased significantly in most regions, e.g. 7.4% in the Northern UK (previously zero) and 50.8% in the south-east (previously 23.2%). Other nematodes identified were *Crenosoma vulpis* (prevalence 10.8%, CI 8.1–14.2) and *Eucoleus aerophilus* (31.6%, CI 27.3–36.2). These data support the proposal that *A. vasorum* has increased in prevalence and has spread geographically in Great Britain.

Key words: angiostrongylosis, epidemiology, distribution, climate, helminth, parasite, wildlife disease, canine.

## INTRODUCTION

*Angiostrongylus vasorum* is found in Europe, Africa and North and South America, where its distribution in endemic countries is typically patchy with foci of high and low prevalence (Koch and Willeesen, 2009; Morgan *et al.* 2009; Conboy, 2011). Interest in *A. vasorum* has increased in recent years due to first reports of its occurrence in many countries, such as Slovakia (Hurnikova *et al.* 2013), Poland (Demiaszkiewicz *et al.* 2014), Serbia (Simin *et al.* 2014), the USA (Kistler *et al.* 2014) and Belgium (Jolly *et al.* 2015), and apparently expanding distribution in countries in which it is already known to be present. Putative range expansion in *A. vasorum* has been attributed variously to climate change through increased abundance of its gastropod mollusc intermediate hosts, increased pet movements facilitating

spread to new areas, and increased abundance and urbanization of foxes, the main wildlife host in Europe (Helm *et al.* 2010; Morgan and Shaw, 2010).

Knowledge of current and potential future parasite distribution is of particular importance to veterinary clinicians, since dogs are susceptible to infection and subsequent disease can be severe and even fatal (Koch and Willeesen, 2009; Elsheikha *et al.* 2014). Infected dogs are difficult to identify as the clinical signs are inconsistent and can include coughing, dyspnoea and coagulopathies, while until recently diagnostic tests were cumbersome and of low sensitivity (Koch and Willeesen, 2009; Traversa, 2013). In common with most other canine diseases, clinical cases and laboratory diagnoses are not centrally collated or subject to standardized criteria, so robust data on which to base objective assessment of prevalence and distribution are lacking. As a result, claims that the parasite is spreading have proven controversial, and are putatively driven at least in part by increased awareness (Morgan, 2014).

In the United Kingdom (UK), *A. vasorum* was first identified in foxes and dogs in the southwestern

\* Corresponding author. Veterinary Parasitology & Ecology Group, University of Bristol, School of Biological Sciences, Bristol Life Sciences Building, 24, Tyndall Avenue, Bristol BS8 1TQ, UK. E-mail: [eric.morgan@bristol.ac.uk](mailto:eric.morgan@bristol.ac.uk)

county of Cornwall in 1979 (Jones *et al.* 1980; Simpson and Neal, 1982). Since then its distribution appears to have increased, with foci emerging in both Southwest and Southeast England (Cobb and Fisher, 1990; Chapman *et al.* 2004; Simpson, 2014), and reports in dogs in Northern England (Yamakawa *et al.* 2009) and in dogs and foxes in Scotland (Helm *et al.* 2009; Philbey and Delgado, 2013). A survey of 546 foxes collected in 2005–2006 found overall prevalence to be 7.3%, with large regional variation and an absence from Northern England and Scotland (Morgan *et al.* 2008). These data provide a baseline against which to compare more recent epidemiological data, without confounding variables such as changes in veterinary clinical awareness, and diagnostic and prevention protocols.

The aim of this study was therefore to determine whether and to what extent *A. vasorum* infection has increased in the fox population in Great Britain over the past 8 years, in terms of both geographic distribution and prevalence, by repeating the methods used in the earlier survey. These data are important to guide evidence-based recommendations for case management, treatment and prevention in dogs. Furthermore, critical local examination of the hypothesis that *A. vasorum* is spreading could inform the same debate in other countries, and contribute to general understanding of the epidemiology of this important parasitic infection of canids.

## MATERIALS AND METHODS

### *Sample collection and nematode collection*

Hearts, lungs and tracheae were obtained from 424 foxes culled between October 2013 and March 2014 as part of a surveillance programme for trichinellosis run by the UK Animal and Plant Health Agency. Sampling of the fox population was opportunistic, with the majority shot for pest control, as well as a smaller number of road-kill carcasses. An additional 18 foxes were obtained after being found dead or euthanized following injury, and submitted to Liverpool University and the Gower Bird Hospital, Swansea. Foxes were classified by sex and age, using tooth eruption (aged adult, young adult and juvenile).

The method of parasite recovery followed exactly that described by Morgan *et al.* (2008), which was itself adapted from Jeffery *et al.* (2004). Briefly, the right chambers of the heart and major pulmonary arteries were first opened, followed by the trachea, and any worms seen removed. A small area of trachea (c. 1 cm<sup>2</sup>) was scraped using a clean scalpel blade and recovered material smeared onto a microscope slide for examination for parasite eggs and larvae. Thereafter, the bronchi and major pulmonary veins were clamped and water directed under pressure into the parenchyma using a 50 mL syringe

and blunt cannula. This retrograde flushing was designed to force *A. vasorum* adults from the arterial vessels and out of the heart. Lung lobes were flushed repeatedly in turn, until tissues appeared pale and devoid of blood, and flushed fluid ran clear. The fluid was examined in a shallow white tray for adult worms, and then passed through a sieve, and the retained material again inspected. After flushing, the pulmonary arterial circulation was dissected and any worms remaining *in situ* were removed, and finally lungs were coarsely shredded and inspected for worms. This combination of flushing and dissection was found to maximize recovery of *A. vasorum* in the previous survey (Morgan *et al.* 2008), and was replicated in order to obtain comparable results. Worms were identified morphologically, and the identity of suspected specimens of *A. vasorum* confirmed using the descriptions provided by Kamensky, 1905 (as cited by Ubelaker, 1986). Freshly taken tracheal scrapes were examined for larvae (of *A. vasorum* and *Crenosoma vulpis*) and eggs (of *Eucoleus aerophilus*) (McGarry and Morgan, 2009; Traversa *et al.* 2010). Six specimens did not have tracheal scrapes taken due to damage to the trachea, which meant a total of 436 specimens were examined thoroughly for all three species of helminth.

### *Statistical analysis*

Samples were categorized regionally as North (including Scotland), Midlands, South, East and Southeast based on Ordnance Survey National Grid references and using the same criteria as Morgan *et al.* (2008). Overall and regional *A. vasorum* and *E. aerophilus* prevalence was compared with data from Morgan *et al.* (2008) using Chi-squared ( $\chi^2$ ) tests. The absence of robust prior data precluded analysis of any putative change in *C. vulpis* prevalence (see Morgan *et al.* 2008). Confidence intervals (CI) for prevalence were estimated using the exact binomial method. Intensity of infection was determined only for *A. vasorum* as the other helminths were identified on a presence–absence basis, e.g. presence of fragments of adult *E. aerophilus* in sieved material, or eggs/larvae of *E. aerophilus* and *C. vulpis* in tracheal scrapes. Associations between fox sex and age and the presence of each helminth species were determined by binary logistic regression. Associations between burden of *A. vasorum* and the factors identified as significant in binary logistic regression were examined by Mann–Whitney tests. All analyses were conducted using IBM Statistics SPSS v. 21 and Microsoft Excel 2010. ArcGIS 10 (ESRI, California) was used for mapping the distribution of *A. vasorum* in foxes, based on carcase collection point. The location of the first reported infections in foxes in Scotland (Philbey and Delgado, 2013) was added to the distribution map, but these foxes were not included in prevalence estimates in order to avoid bias. In order to assess

the potential confounding influence of weather on between-year comparisons of *A. vasorum* prevalence, growing degree days for parasite development in the intermediate host were calculated for 2013 and 2005 averaged across the known endemic regions, based on the observed development times in experimentally infected snails (Roberts, unpublished MSc thesis, University of Bristol). Average annual UK rainfall in the same years was obtained from the UK Met Office ([www.metoffice.gov.uk](http://www.metoffice.gov.uk), accessed 4 March 2015).

## RESULTS

Nematodes were found in 46.4% of foxes (95% CI 41.6–51.2). The overall prevalence of infection with *A. vasorum* was 18.3% (CI 14.9–22.3), and infection intensity ranged from 1 to 53 adult worms (mean intensity 6.3, s.d. 7.3; median intensity 3.5, 1st–3rd quartiles 1–8;  $n = 76$  infected). Of 420 adult *A. vasorum* for which the stage of extraction was recorded, 69% were found in the heart, 26.5% in the lung flush, 4% in the dissected pulmonary blood vessels and 0.5% in the trachea (presumably having been moved mechanically during organ extraction and processing).

Foxes infected with *A. vasorum* were unevenly distributed across Great Britain (Fig. 1) and prevalence varied strongly by region, being highest in the Southeast (50.8%) and lowest in the North (7.4%) and East (12.9%) (Fig. 2). The overall prevalence of *A. vasorum* was significantly higher than that recorded in the previous survey ( $\chi^2 = 29.51$ , 1 D.F.,  $P < 0.001$ ). Similarly, prevalence in all regions except for the South ( $\chi^2 = 1.62$ , 1 D.F.,  $P = 0.20$ ) was significantly higher than in the 2005–2006 study ( $\chi^2 \geq 9.49$ , 1 D.F.,  $P \leq 0.002$ ).

*Crenosoma vulpis* (overall prevalence 10.8%,  $n = 436$ , CI 8.1–14.2) and *E. aerophilus* (31.6%,  $n = 436$ , CI 27.3–36.2) were the only other parasites identified. Overall sample size was slightly lower for these species (436 cf. 442) because the trachea was sometimes truncated during organ recovery, and therefore not always examined. The overall recorded prevalence of *E. aerophilus* was lower than in 2005–2006 (31.6% compared with 39% previously;  $\chi^2 = 5.48$ , 1 D.F.,  $P = 0.019$ ). Foxes infected with *E. aerophilus* were widely distributed around the UK, including Scotland. The distribution of *C. vulpis* was broadly similar to *A. vasorum*, with prevalence highest in the Southeast and lowest in the North (Table 1). Of foxes found to be infected, 98% (*C. vulpis*) and 91% (*E. aerophilus*) would have been identified by the discovery of immature stages in the tracheal scraping alone. Mixed infections were recorded in 11.2% of foxes sampled (23.1% of those infected by at least one species) (Table 2). Despite particular vigilance for *Dirofilaria immitis*, which is exotic to the UK, no infected foxes were found (upper exact binomial CI = 1.1%).

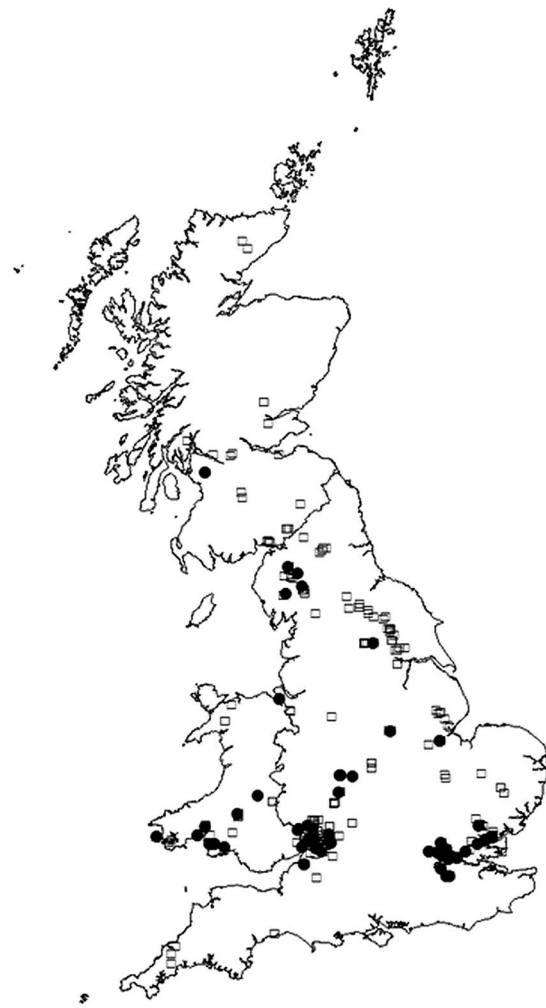


Fig. 1. Distribution of foxes infected (filled circles) and uninfected (open squares) with *Angiostrongylus vasorum*. Locations represent collection points of carcasses; some points overlap.

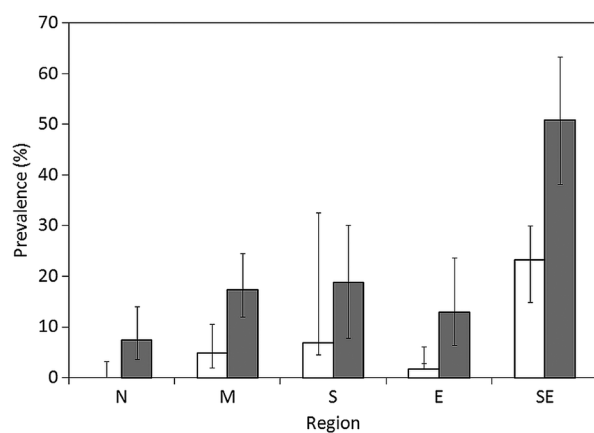


Fig. 2. The regional prevalence of *Angiostrongylus vasorum* in the current study (shaded), compared with the previous comparable survey in 2005–2006 (Morgan *et al.* 2008). Error bars represent exact binomial 95% confidence intervals. N, North (including Scotland; UK Ordnance Survey, OS, grid squares H, NC–NZ, SD–SJ); M, Midlands (SK–SP); S, South (SS–SY); E, East (TA–TM); SE, Southeast (TQ–TV).

Table 1. Regional prevalence of *Crenosoma vulpis* and *Eucoleus aerophilus* in foxes (CI = 95% exact binomial confidence intervals). Sample sizes per region are given between brackets, first for the current study, followed by those reported in Morgan *et al.* (2008)

Region	<i>C. vulpis</i> (%)	CI	<i>E. aerophilus</i> (%)	CI
North (122; 138)	4.3	1.6–10.2	30.7	22.7–40
Midlands (155; 126)	10.5	6.3–16.7	29.2	22.3–37.1
East (72; 128)	4.3	1.1–12.9	40.5	29.1–53
Southeast (64; 125)	25	15.4–37.7	10.9	4.8–21.8
South (32; 29)	9.7	2.6–26	46.9	29.4–64.9
Overall	10.8	8.1–14.2	31.6	27.3–36.2

Table 2. Frequency of single, dual and triple infections with *Angiostrongylus vasorum* (Av), *Crenosoma vulpis* (Cv) and *Eucoleus aerophilus* (Ea) in the sampled foxes ( $n = 436$ )

Species	Frequency	% of infected foxes (% of total foxes)
Av	43	Single infections: 76.9 (37.4)
Cv	16	
Ea	104	
Av and Cv	15	Dual infections: 20.3 (9.8)
Av and Ea	17	
Ea and Cv	11	
Av, Cv and Ea	6	Triple infections: 2.8 (1.4)

Binary logistic regression confirmed that region was a significant predictor of *A. vasorum* prevalence (Wald statistic = 40.35, 4 D.F.,  $P < 0.001$ ). The occurrence of *A. vasorum* was also positively associated with that of *C. vulpis* (binary logistic regression, Wald statistic = 6.665,  $P = 0.01$ , odds ratio, OR = 2.64, 95% CI 1.26–5.52). Infection with *C. vulpis* was, in turn, positively associated with the presence of *A. vasorum* (Wald statistic = 14.31,  $P < 0.001$ , OR = 4.00, CI 1.95–8.22). Infection with *E. aerophilus* was not significantly associated with the presence of either of the other two species. No significant associations were found between infection with any of the three nematode species and fox age or sex.

Estimated growing degree days for *A. vasorum* development in the intermediate host were slightly fewer in 2013 (1796) than in 2005 (1992). Rainfall was very similar between years (UK annual average 1086.2 mm in 2013, and 1091.0 mm in 2005; 99% of 1961–1990 average in both cases).

## DISCUSSION

The importance of wildlife as potential reservoirs of pathogens which may infect domestic animals and humans is attracting growing interest because of apparent increases in wildlife-related disease (Daszak *et al.* 2000; Taylor *et al.* 2001). This may be associated with factors such as expansion of housing and agriculture into rural areas, increased popularity of wildlife as pets, and increased exposure of companion animals to novel pathogens and vectors due to a rise in pet movements (Chomel *et al.* 2007).

Unlicensed rehabilitation and movement of wildlife species has also been identified as a potential risk factor for disease dissemination in the UK (Anon., 2007). The red fox, *Vulpes vulpes*, has been implicated as a reservoir of numerous pathogens internationally, including the rabies virus, *Echinococcus multilocularis*, *Sarcoptes scabiei*, *Trichinella spiralis* and *A. vasorum* (Deplazes *et al.* 2004; Balastrieri *et al.* 2006; Letková *et al.* 2006).

Whatever the impact of the fox as a reservoir of *A. vasorum*, infection in foxes is likely to indicate changes in parasite distribution more reliably than reports of clinical cases or surveys of dogs, dog owners and veterinarians, since these are likely to be strongly influenced by veterinary practitioner awareness, recruitment bias and advances in diagnostic technologies (Morgan *et al.* 2010; Schnyder *et al.* 2013; Kirk *et al.* 2014). In comparison with a previous survey of foxes in Great Britain (Morgan *et al.* 2008), whose methods were replicated as exactly as possible, the present results clearly indicate a northward expansion of this parasite, as well as an increase in prevalence in most areas in which the parasite was previously observed.

There is a risk with once-repeated cross-sectional surveys that point differences between years lead to the erroneous supposition of an increasing trend in infection levels. Thus, higher prevalence in 2013/14 than in 2005/06 could in principle be due to better short-term weather conditions for transmission of *A. vasorum*, rather than spreading parasite distribution. However, neither average precipitation nor estimated growing degree days were higher

overall in 2013 than in 2005. Another potential limitation of the present study design is that foxes were not randomly sampled, but taken opportunistically. By chance, there were therefore fine scale differences in the extent to which different localities were represented. For example, fewer foxes were sampled from near the Scotland–England border than in the earlier survey, while more were sampled from Cumbria. In some cases, such as the increased number of foxes obtained from Wales, this could explain apparent local increases in prevalence. Nevertheless, sampling intensity at regional level was similar in both surveys, and fine scale local variation is likely to contribute to random error but not systematic bias. If anything, smaller numbers of foxes sampled during the current survey in the Southeast (see Table 2) should cause downward bias in overall prevalence. Unintended sampling bias cannot therefore easily explain the consistent pattern of increased (generally more than doubled) prevalence in different regions.

The most likely explanation for the observed results is genuine expansion in the distribution of *A. vasorum*. This was previously suspected from observed cases in dogs (e.g. Helm *et al.* 2009; Yamakawa *et al.* 2009) and foxes (Philbey and Delgado, 2013) outside established endemic areas, and widespread reports by veterinary practices (Kirk *et al.* 2014). Serological surveys in dogs have documented broad distribution of *A. vasorum* infection in the southern part of Great Britain (Schnyder *et al.* 2013), but did not extend north to areas previously assumed to be uninfected. The present results provide the most robust evidence to date for northward spread and generally increasing abundance of *A. vasorum* in the UK. Factors underlying this trend could be, *inter alia*, effects of long-term climate change on intermediate host availability and/or parasite development rate, increasing dog movement, or increasing transmission through the fox population. There appears to be no fundamental climatic barrier to the establishment of *A. vasorum* throughout the UK (Morgan *et al.* 2009) and further range expansion is to be expected.

The other, bronchopulmonary nematode species, *C. vulpis* and *E. aerophilus*, were also commonly found, though comparison with the earlier survey is less reliable due to unavoidable differences in the proportion of trachea available for inspection, and the dominant performance of tracheal scrapes as a method of detection in the present study. Microscopic examination of tracheal scrapes for immature stages seemed to be an efficient way of detecting infection with these parasites, and could be incorporated into future surveys. Infection with *C. vulpis* and *A. vasorum* were positively associated, perhaps because they both use gastropod intermediate hosts, though such an association was not detected in foxes in Newfoundland (Jeffery *et al.* 2004).

The apparently increasing distribution and abundance of *A. vasorum* in the UK has implications for

the diagnosis and prevention of infection in dogs, since case management and recommended chemoprophylactic regimes should take account of local risk. Within this widening range, there is significant regional variation, with relatively lower prevalence in foxes in the North and East. These regions have lower fox population densities (Webbon *et al.* 2004), while rainfall is also lower than average in the East of Great Britain, possibly reducing the abundance or activity of slug intermediate hosts (South, 1992). Previous studies also reported a wide range of prevalence in foxes in endemic areas of other countries, of between 4.2 and 92% (Jeffery *et al.* 2004; Tønsberg *et al.* 2004; Saeed *et al.* 2006; Magi *et al.* 2009; Franssen *et al.* 2014). As well as being a cause of disease in dogs, *A. vasorum* has also been shown to cause pathology and disease in foxes (Poli *et al.* 1991; Jeffery *et al.* 2004; Morgan *et al.* 2008; Philbey and Delgado, 2013; Eleni *et al.* 2014), and could affect fox health and population dynamics. While much remains to be elucidated concerning the epidemiology of angiostrongylosis in dogs and foxes, time series of infection levels and distribution such as that presented here will be important to define trends and advance understanding.

#### ACKNOWLEDGEMENTS

Thanks to Barnaby Dobson, Andrew Cooke and the team at APHA for assistance with the collection and transport of material, and to Adrian Philbey for sharing information on fox locations in Scotland.

#### FINANCIAL SUPPORT

Fox collections were funded by the UK Food Standards Agency under grant FS231058. C.S.T. was kindly funded by a grant from the Wellcome Trust (WT082161MA) and N.A.A. by a PhD scholarship from the Ministry of Higher Education, Government of Malaysia. J.W.M. would like to thank Roland Schaper and Bayer Animal Health for financial support.

#### REFERENCES

- Anonymous (2007). *Consultation on Working Towards a Wildlife Health Strategy*. Department for Environment, Food and Rural Affairs, UK, 37 pp.
- Balastrieri, A., Remonti, L., Ferrari, N., Ferrari, A., Lo Valvo, T. and Robetto, S. (2006). Sarcocystis mangle in wild carnivores and its co-occurrence with parasitic helminths in the Western Italian Alps. *European Journal of Wildlife Research* **52**, 196–201.
- Chapman, P., Boag, A. K., Guitan, J. and Boswood, A. (2004). *Angiostrongylus vasorum* infection in 23 dogs (1999–2002). *Journal of Small Animal Practice* **45**, 435–440.
- Chomel, B. B., Belotto, A. and Meslin, F. X. (2007). Wildlife, exotic pets and emerging zoonoses. *Emerging Infectious Diseases* **13**, 6–11.
- Cobb, M. A. and Fisher, M. A. (1990). *Angiostrongylus vasorum*: transmission in south east England. *Veterinary Record* **121**, 529.
- Conboy, G. A. (2011). Canine angiostrongylosis: the French heartworm: an emerging threat in North America. *Veterinary Parasitology* **176**, 382–389.
- Daszak, P., Cunningham, A. A. and Hyatt, A. D. (2000). Emerging infectious diseases of wildlife: threats to biodiversity and human health. *Science* **287**, 443–449.

- Demiaszkiewicz, A.W., Pyziel, A.M., Kuligowska, I. and Lachowicz, J.** (2014). The first report of *Angiostrongylus vasorum* (Nematoda; Metastrongyloidea) in Poland, in red foxes (*Vulpes vulpes*). *Acta Parasitologica* **59**, 758–762.
- Deplazes, P., Hegglin, D., Gloor, S. and Romig, T.** (2004). Wilderness in the city: the urbanization of *Echinococcus multilocularis*. *Trends in Parasitology* **20**, 77–84.
- Eleni, C., Grifoni, G., Di Egidio, A., Meoli, R. and De Liberato, C.** (2014). Pathological findings of *Angiostrongylus vasorum* infection in red foxes (*Vulpes vulpes*) from Central Italy, with the first report of a disseminated infection in this host species. *Parasitology Research* **113**, 1247–1250.
- Elsheikha, H.M., Holmes, S.A., Wright, I., Morgan, E.R. and Lacher, D.W.** (2014). Recent advances in the epidemiology, clinical and diagnostic features, and control of canine cardio-pulmonary angiostrongylosis. *Veterinary Research* **45**, 92.
- Franssen, F., Nijse, R., Mulder, J., Cremers, H., Dam, C., Takumi, K. and van der Giessen, J.** (2014). Increase in number of helminth species from Dutch red foxes over a 35-year period. *Parasites and Vectors* **7**, 1–10.
- Helm, J., Gilleard, J.S., Jackson, M., Redman, E. and Bell, R.** (2009). A case of canine *Angiostrongylus vasorum* in Scotland confirmed by PCR and sequence analysis. *Journal of Small Animal Practice* **50**, 255–259.
- Helm, J.R., Morgan, E.R., Jackson, M.W., Wotton, P. and Bell, R.** (2010). Canine angiostrongylosis: an emerging disease in Europe. *Journal of Veterinary Emergency and Critical Care* **20**, 98–109.
- Hurnikova, Z., Miterpakova, M. and Mandelik, R.** (2013). First autochthonous case of canine *Angiostrongylus vasorum* in Slovakia. *Parasitology Research* **112**, 3505–3508.
- Jeffery, R.A., Lankester, M.W., McGrath, M.J. and Whitney, H.G.** (2004). *Angiostrongylus vasorum* and *Crenosoma vulpis* in red foxes (*Vulpes vulpes*) in Newfoundland, Canada. *Canadian Journal of Zoology—Revue Canadienne de Zoologie* **82**, 66–74.
- Jolly, S., Poncelot, L., Lempereur, L., Caron, Y., Bayrou, C., Cassart, D., Grimm, F. and Losson, B.** (2015). First report of a fatal autochthonous canine *Angiostrongylus vasorum* infection in Belgium. *Parasitology International* **64**, 97–99.
- Jones, G.W., Neal, C. and Turner, G.R.** (1980). *Angiostrongylus vasorum* infection in dogs in Cornwall. *Veterinary Record* **106**, 83.
- Kirk, L., Limon, G., Guitan, F.J., Hermosilla, C. and Fox, M.T.** (2014). *Angiostrongylus vasorum* in Great Britain: a nationwide postal questionnaire survey of veterinary practices. *Veterinary Record* **175**, 118.
- Kistler, W.M., Brown, J.D., Allison, A.B., Nemeth, N.M. and Yabsley, M.J.** (2014). First report of *Angiostrongylus vasorum* and *Hepatozoon* from a red fox (*Vulpes vulpes*) from West Virginia, U.S.A. *Veterinary Parasitology* **200**, 216–220.
- Koch, J. and Willeßen, J.L.** (2009). Canine pulmonary angiostrongylosis: an update. *Veterinary Journal* **179**, 348–359.
- Letková, V., Lazar, P., Goldová, M. and Košuthová, L.** (2006). The red fox (*Vulpes vulpes*) as a source of zoonoses. *Veterinarski Arhiv* **76**, S73–S81.
- Magi, M., Guardone, L., Dell’Omodarme, M., Prati, M.C., Mignone, W., Torracca, B., Monni, G. and Macchioni, F.** (2009). *Angiostrongylus vasorum* in red foxes (*Vulpes vulpes*) and badgers (*Meles meles*) from central and Northern Italy. *Hystrix—Italian Journal of Mammalogy* **20**, 121–126.
- McGarry, J.W. and Morgan, E.R.** (2009). Identification of first-stage larvae of metastrongyles from dogs. *Veterinary Record* **165**, 258–261.
- Morgan, E.R.** (2014). Canine pulmonary angiostrongylosis: can a worm change its spots? *Veterinary Record* **175**, 116–117.
- Morgan, E.R. and Shaw, S.** (2010). *Angiostrongylus vasorum* infection in dogs: continuing spread and developments in diagnosis and treatment. *Journal of Small Animal Practice* **51**, 616–621.
- Morgan, E.R., Tomlinson, A., Hunter, S., Nichols, T., Roberts, E., Fox, M.T. and Taylor, M.A.** (2008). *Angiostrongylus vasorum* and *Eucoleus aerophilus* in foxes (*Vulpes vulpes*) in Great Britain. *Veterinary Parasitology* **154**, 48–57.
- Morgan, E.R., Jefferies, R., Krajewski, M., Ward, P. and Shaw, S.E.** (2009). Canine pulmonary angiostrongylosis: the influence of climate on parasite distribution. *Parasitology International* **58**, 406–410.
- Morgan, E.R., Jefferies, R., Van Otterdijk, L., McEniry, R.B., Allen, F., Bakewell, M. and Shaw, S.E.** (2010). *Angiostrongylus vasorum* infection in dogs: presentation and risk factors. *Veterinary Parasitology* **173**, 255–261.
- Philbey, A.W. and Delgado, D.** (2013). Detection of *Angiostrongylus vasorum* in red foxes in Scotland. *Veterinary Record* **173**, 148–148.
- Poli, A., Arispici, M., Mancianti, F. and Abramo, F.M.A.** (1991). Pathology of naturally acquired *Angiostrongylus vasorum* infection in the red fox *Vulpes vulpes*. *Angewissenschaft Parasitenkunde* **32**, 121–126.
- Saeed, I., Maddox-Hyttel, C., Monrad, J. and Kapel, C.M.O.** (2006). Helminths of red foxes (*Vulpes vulpes*) in Denmark. *Veterinary Parasitology* **139**, 168–179.
- Schnyder, M., Schaper, R., Bilbrough, G., Morgan, E.R. and Deplazes, P.** (2013). Seroepidemiological survey for canine angiostrongylosis in dogs from Germany and the UK using combined detection of *Angiostrongylus vasorum* antigen and specific antibodies. *Parasitology* **140**, 1442–1450.
- Simin, S., Kosic, L.S., Kuruca, L., Pavlovic, I., Savovic, M. and Lalosevic, V.** (2014). Moving the boundaries to the South-East: first record of autochthonous *Angiostrongylus vasorum* infection in a dog in Vojvodina province, northern Serbia. *Parasites and Vectors* **7**, 396.
- Simpson, V.** (2014). *Angiostrongylus vasorum* in Cornwall. *Veterinary Record* **175**, 178–179.
- Simpson, V.R. and Neal, C.** (1982). *Angiostrongylus vasorum* infection in dogs and slugs. *Veterinary Record* **111**, 303–304.
- South, A.** (1992). *Terrestrial Slugs: Biology, Ecology and Control*. Chapman and Hall Ltd, London.
- Taylor, L.H., Latham, S.M. and Woolhouse, M.E.** (2001). Risk factors for disease emergence. *Philosophical Transactions of the Royal Society* **356**, 983–989.
- Tønsberg, H., Saeed, I. and Koch, J.** (2004). Parasitological examination of hunting dogs and foxes in Odsherred. *Danish Veterinary Journal* **87**, 14–18.
- Traversa, D.** (2013). Canine angiostrongylosis in Italy: occurrence of *Angiostrongylus vasorum* in dogs with compatible clinical pictures. *Parasitology Research* **112**, 2473–2480.
- Traversa, D., Di Cesare, A. and Conboy, G.** (2010). Canine and feline cardiopulmonary parasitic nematodes in Europe: emerging and underestimated. *Parasites and Vectors* **3**, 1–22.
- Ubelaker, J.E.** (1986). Systematics of species referred to the genus *Angiostrongylus*. *Journal of Parasitology* **72**, 237–244.
- Webbon, C., Baker, P. and Harris, S.** (2004). Faecal density counts for monitoring changes in red fox numbers in rural Britain. *Journal of Applied Ecology* **41**, 768–779.
- Yamakawa, Y., McGarry, J.W., Denk, D., Dukes-McEwan, J., McDonald, N., Mas, A., McConnell, F., Tatton, B., Valentine, E.G., Wayne, J., Williams, J.M. and Hetzel, U.** (2009). Emerging canine angiostrongylosis in northern England: five fatal cases. *Veterinary Record* **164**, 149–152.