

Case Report

Infliximab and nephrotic syndrome

George Chin¹, Grant Luxton¹ and Jennet M. Harvey²

¹Renal Unit, Sir Charles Gairdner Hospital, Nedlands and ²Department of Pathology, University of Western Australia and PathCentre, Western Australia, Australia

Abstract

Infliximab is a chimeric tumor necrosis factor- α (TNF- α) monoclonal antibody, which has been used extensively in patients with rheumatoid arthritis and inflammatory bowel disease. It also appears to be effective in other conditions such as psoriasis and ankylosing spondylitis. The major side effect of infliximab is infection. Renal complications are uncommon and not well recognized. This report describes a probable case of infliximab-induced membranous nephropathy.

Keywords: drug-induced; infliximab; nephrotic syndrome

Membranous nephropathy (MN) is a common cause of nephrotic syndrome in the adult population. It is conventionally classified into primary idiopathic and secondary forms. Drugs and toxins constitute an important aetiological subgroup of the latter. Drugs that are well known to be associated with MN include gold, penicillamine, captopril and non-steroidal anti-inflammatory agents (NSAIDs). This list will be expected to expand as increasing numbers of new drugs become available in the pharmaceutical market. Clinicians must be vigilant about the use of new therapeutic agents and the possibility of their potential side effects including MN. We describe a case of renal biopsy-proven MN in which infliximab is the suspected cause.

SJ is a 29-year-old Australia-born Vietnamese who presented with nephrotic syndrome. Her past medical history is significant for previous intravenous drug use, depression and severe psoriasis. She has had psoriasis for many years and her disease has been resistant to various topical therapies including glucocorticoids, tar, and coconut compound. Methotrexate and

mycophenolate mofetil were tried with minimal success. In March 2002, a single dose of infliximab was given, followed by a dramatic clinical improvement within 1 week. She became pregnant shortly after and no further infusion was given until November the same year, followed by infusions in January and April 2003. The doses administered averaged 8–12 mg/kg: 450, 500, 400 and 400 mg respectively.

When reviewed in the Dermatology outpatient clinic 1 month after her last dose of infliximab, she complained of a short history of dyspnoea associated with a non-productive cough, accompanied by increasing abdominal and periorbital swelling. There were no fevers, chills or rigors. She denied intravenous drug use and had no recent history of travel. She was on no other medications besides the infliximab.

On examination, she was tachycardiac with a pulse rate of 108, blood pressure 110/70, and oxygen saturation 100% on room air. Her temperature was 37.3°C. Physical findings were remarkable for extensive peripheral pitting oedema, ascites and a right-sided pleural effusion. Urinalysis showed the presence of proteinuria (+++) without haematuria. A spot urine protein:creatinine ratio (PCR) was 1330 mmol/mg, equivalent to approximately 13 g of proteinuria daily. Serum albumin was 10 g/l, total cholesterol was 12.3 mmol/l with LDL of 9.4 mmol/l. Serum creatinine was normal during the entire period. A diagnosis of acute nephrotic syndrome was made. Anti-nuclear factors, hepatitis B/C and HIV serology, as well as serum/urine electrophoresis were all negative.

A renal biopsy was performed. Light microscopy showed non-specific changes, the capillary loops somewhat rigid and minimally thickened. Silver staining confirmed patchy thickening of the glomeruli basement membrane, but neither spikes nor double contours were seen. There was no evidence of vasculitis. Immunofluorescence demonstrated strong membranous fine granular IgG and C3 deposition, and electron microscopy (Figure 1) showed small electron dense sub-epithelial deposits dispersed at intervals along the lamina rara externa, confirming the diagnosis of membranous glomerulopathy.

Correspondence and offprint requests to: Dr George Chin, Department of Nephrology, Derriford Hospital NHS Trust, Derriford, Plymouth, Devon PL6 8DH, UK.
Email: george.chin@phnt.swest.nhs.uk

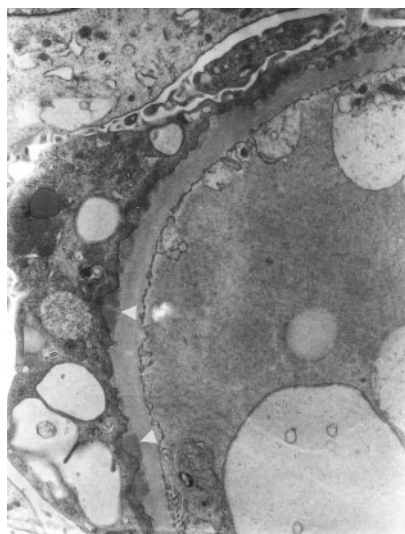


Fig. 1. Multiple small electron dense deposits are seen in the lamina rara externa beneath effaced podocytic processes. Arrowheads indicate two subepithelial deposits ($\times 9000$).

Prior to considering biopsy, the possibility of minimal change disease was considered, particularly because of the acute onset of symptoms. She was therefore commenced on 60 mg of prednisolone daily, along with diuretics, an ACE-inhibitor and a statin. A drug associated MN was not excluded, especially as there appeared to be a temporal relationship between the last dose of infliximab and the onset of nephrotic syndrome. Ten days after initiation of therapy, serum albumin increased to 16 g/l, although spot urine PCR remained elevated at 1115 mmol/mg. She was maintained on the same dose of prednisolone for a total of 3 weeks, after which the dose was slowly tapered. When reviewed at the Outpatient Clinic in September, 4 months after initial presentation, continued improvement of nephrotic syndrome was seen, with her urine PCR reduced to 48 mmol/mg and serum albumin returned to normal. Serum albumin is still within normal limits at 45 g/l in June 2005. Control of her psoriasis remains challenging despite taking methotrexate and cyclosporin. A re-challenge with infliximab was not undertaken.

Infliximab, a chimeric anti-tumor necrosis factor- α (TNF- α) monoclonal antibody, has been used in a number of inflammatory conditions. It has an established role in controlling disease activities in rheumatoid arthritis and inflammatory bowel disease. Its effectiveness appears to extend to the treatment of psoriasis, psoriatic arthropathy and ankylosing spondylitis [1–4]. The use of infliximab continues to grow. A number of case reports have been noted in the literature where the drug was used in patients with significant proteinuria secondary to AA amyloidosis [5,6]. This agent also appears to be safe in patients undergoing haemodialysis [7].

One of the more serious side effects of infliximab is infection, a not uncommon reason for temporary or permanent cessation of the therapy. Little is known

of renal complications that may result from its use. A lupus-like syndrome has been described in association with infliximab therapy [8,9]. The absence of the typical serological results and immunofluorescence findings on the renal biopsy in our patient exclude lupus nephritis. An unusual hypersensitivity vasculitis with leucocytoclastic vasculitis secondary to infliximab has been described in a case report by McIlwain *et al.* [10]. Our patient at no stage developed any vasculitic rash, nor did the renal biopsy demonstrate any features of a vasculitis.

The temporal relationship between the initiation of infliximab and the subsequent development of biopsy-proven MN, along with slow resolution upon withdrawal of infliximab, suggested the possibility of a drug related phenomenon. It is, however, difficult to exclude the possibility of idiopathic MN with spontaneous remission. Approximately 50% of patients with idiopathic MN enter remissions, half of which will have complete remission within 3–5 years. This has resulted in difficulty in selecting patients who would otherwise benefit from treatment. Various prognostic factors have been used to predict outcomes in patients with MN. Older age, male sex, the presence of hypertension, nephrotic syndrome, and hypoalbuminaemia are among the predictors of poor outcome [11].

When MN is drug induced, the disease almost always resolves, but can take years to do so [12]. The patient described received a total of four infusions of infliximab over 13 months. It took 5 months for the patient to enter remission after infliximab was ceased. The course of MN might have been altered by the use of glucocorticoids, though it is well known that high-dose oral steroids alone are usually ineffective in MN.

Understanding of the pathogenesis of idiopathic MN largely comes from studies of animal models of passive Heymann nephritis (PHN), which can be induced in rats by administering antibodies to antigens expressed on the membranes of the glomerular epithelial cells (GEC) [13]. The antigen has been identified as megalin-receptor associated protein complex in experimental MN [14]. The immune complexes then activate the complement cascade, which subsequently generates the terminal complement complex, C5b-9 or membrane attack complex (MAC), responsible for glomerular injury. Damage to glomeruli by C5b-9 is predominantly a non-lytic process. MAC induces activation of GEC with increased production of nephritogenic molecules such as oxidants, cytokines, vasoactive molecules, and extracellular matrix [12]. Tumor necrosis factor, has been demonstrated as a pro-inflammatory cytokine in the pathogenesis of a number of human and animal models of glomerulonephritis. Passive immunization of anti-TNF antibodies reduced levels of albuminuria in animals [15]. Theoretically, infliximab, being an antibody to TNF- α , would not be expected to induce significant proteinuria from glomerular injury. It may represent an idiosyncratic reaction, although the evidence for this is far from conclusive.

The pathogenesis of drug-induced MN is poorly understood, but is probably different from that of

idiopathic MN. Nagahama *et al.* [16] described renal biopsy findings in patients with Bucillamine induced MN. Immunofluorescence microscopy showed granular deposition of IgG2, IgG3 and IgG4 along the glomerular capillary walls, as compared with the predominant diffuse IgG4 deposition in idiopathic MN. In our patient, we did not analyse IgG subclass deposition with immunofluorescence microscopy.

Clinicians need to consider infliximab as a potential cause of renal injury in patients to whom it is given. This report describes a probable case of infliximab induced-membranous nephropathy which we believe to be the first case described in the literature.

Conflict of interest statement. None declared.

References

1. Reimold AM. TNFalpha as therapeutic target: new drugs, more applications. *Curr Drug Targets Inflamm Allergy* 2002; 1: 377–392
2. Al-Salem IH. Striking and rapid improvement of plaque psoriasis with infliximab. A report of two cases. *Dermatology* 2003; 207: 54–56
3. Salvarani C, Cantini F, Olivieri I *et al.* Efficacy of infliximab in resistant psoriatic arthritis. *Arthritis Care Res* 2003; 49: 541–545
4. Gottlieb AB. Infliximab for psoriasis. *J Am Acad Dermatol* 2003; 49: S112–S117
5. Gottenbary JE, Nerle-Vincent F, Bentaberry F *et al.* Anti-tumor necrosis factor alpha therapy in fifteen patients with AA amyloidosis secondary to inflammatory arthritides: a followup report of tolerability and efficacy. *Arthritis Rheum* 2003; 48: 2019–2024
6. Elkayam O, Hawkins PN, Lachmann H, Yaron M, Caspi D. Rapid and complete resolution of proteinuria due to renal amyloidosis in a patient with rheumatoid arthritis treated with infliximab. *Arthritis Rheum* 2002; 46: 2571–2573
7. Singh R, Cuchacovich R, Huang W, Espinoza LR. Infliximab treatment in a patient with rheumatoid arthritis on haemodialysis. *J Rheumatol* 2002; 29: 636–637
8. Klapman JB, Ene-Stroescu D, Becker MA, Hanauer SB. A lupus-like syndrome associated with infliximab therapy. *Inflamm Bowel Dis* 2003; 9: 176–178
9. Debandt M, Vittecoq O, Descamps V, Le Loet X, Meyer O. Anti-TNF-alpha-induced systemic lupus syndrome. *Clin Rheumatol* 2003; 22: 56–61
10. McIlwain L, Carter JD, Bin-Sagheer S, Vasey FB, Nord J. Hypersensitivity vasculitis with leukocytoclastic vasculitis secondary to infliximab. *J Clin Gastroenterol* 2003; 36: 411–413
11. Reichert LJM, Koene RAP, Wetzels JFM. Prognostic factors in idiopathic membranous nephropathy [editorial review]. *Am J Kidney Dis* 1998; 31: 1–11
12. Johnson RJ, Feehally J. *Comprehensive Clinical Nephrology*, 2nd Edition. Mosby/Elsevier: 2003; Chapter 22
13. Nangaku M, Alpers CE, Pippin J *et al.* Renal microvascular injury induced by antibody to glomerular endothelial cells is mediated by C5b-9. *Kidney Int* 1997; 52: 1570–1578
14. Orlando RA, Kerjaschki D, Farquhar MG *et al.* Megalin (gp330) possesses an antigenic epitope capable of inducing passive Heymann nephritis independent of the nephritogenic epitope in receptor-associated protein. *J Am Soc Nephrol* 1995; 6: 61–67
15. Kluth DC, Rees AJ. New approaches to modify glomerular inflammation. *J Nephrol* 1999; 12: 66–75
16. Nagahama K, Matsushita H, Hara M, Ubara Y, Hara S, Yamada A. Bucillamine induces membranous glomerulonephritis. *Am J Kidney Dis* 2002; 39: 706–712

Received for publication: 30.7.05

Accepted in revised form: 6.9.05