

Conclusion: DBBM utilized as sole grafting material in staged MSFA demonstrated to be clinically effective regardless of the healing period. Histomorphometrical and micro-CT assessments revealed that at later stages of healing (8 and 11 months) there is a higher proportion of newly-bone formation compared to earlier stages (5 months). Moreover, the longer the maturation period, the substantially lesser remaining biomaterial could be expected. Even though, these facts did not seem to negatively impact on the implant prognosis 1-year after loading.

Accepted Article

SCHOLARONE™
Manuscripts

This is the author manuscript accepted for publication and has undergone full peer review but has not been through the copyediting, typesetting, pagination and proofreading process, which may lead to differences between this version and the [Version record](#). Please cite this article as [doi:10.1111/cid.12463](https://doi.org/10.1111/cid.12463).

**Influence of Healing Period upon Bone Turn Over on Maxillary Sinus Floor
Augmentation Grafted Solely with Deproteinized Bovine Bone Mineral: A Prospective
Human Histological and Clinical Trial**

Feng Wang, M.D., D.D.S.[‡] Wenjie Zhou, M.S., D.D.S.* Alberto Monje, M.S., D.D.S.[&] Wei Huang,
M.S., D.D.S.[□] Yueping Wang, M.S., D.D.S.[§] Yiqun Wu, M.D., D.D.S.[□]

[‡] Assistant Professor, Department of Oral Implantology, Ninth People's Hospital, Shanghai Jiao Tong University, School of Medicine; Shanghai Key Laboratory of Stomatology, Shanghai, China 200011

* Resident, Second Dental Clinic, Ninth People's Hospital, Shanghai Jiao Tong University, School of Medicine; Shanghai Key Laboratory of Stomatology, Shanghai, China 200011

[&] Department of Periodontics and Oral Medicine, The University of Michigan, Ann Arbor, MI, USA; Department of Oral Surgery and Stomatology, ZMK University of Bern, Bern, CH (ITI Scholarship program)

[□] Professor, Department of Oral Implantology, Ninth People's Hospital, Shanghai Jiao Tong University, School of Medicine; Shanghai Key Laboratory of Stomatology, Shanghai, China 200011

[§] Professor, Second Dental Clinic, Ninth People's Hospital, Shanghai Jiao Tong University, School of Medicine; Shanghai Key Laboratory of Stomatology, Shanghai, China 200011

Word count: 3200

Tables and figures: 2 tables and 4 figures

Running title: Bone turn over on sinus augmentation with DBBM

Corresponding authors:

Yiqun Wu, M.D, D.D.S.

Department of Oral Implantology, Second Dental Clinic, Ninth People's Hospital, Shanghai Jiao Tong University, School of Medicine; Shanghai Key Laboratory of Stomatology

No. 639 Zhizaoju Road, Shanghai, China 200011

Email: yiqunwu@hotmail.com

Tel: 86-21-53315299

Fax: 86-21-53073068

and Yueping Wang, M.S, D.D.S.

Second Dental Clinic, Ninth People's Hospital, Shanghai Jiao Tong University, School of
Medicine; Shanghai Key Laboratory of Stomatology, Shanghai, China 200011

No. 639 Zhizaoju Road, Shanghai, China 200011

Email: wangyueping309@hotmail.com

Tel: 86-21-53315299

Fax: 86-21-53073068

These two authors contribute equally to the work.

Conflict of Interest Statement

The authors have no conflict of interest relevant to the content of the submission.

ACKNOWLEDGEMENTS

This study was supported by the project of the Combined Engineering and Medical Project of
Shanghai Jiao Tong University (YG2014QN01) and the National Natural Science Foundation
of China (81371190).

Authors' contribution:

Dr. Feng Wang: drafting article, concept/design, data analysis

Dr. Wenjie Zhou: data collection, data analysis

Dr. Alberto Monje: data analysis, critical revision of article

Pro. Wei Huang: surgery performance

Pro. Yueping Wang: concept/design, funding secured

Pro. Yiqun Wu: surgery performance, concept/design, funding secured, critical revision of
article

Influence of Healing Period upon Bone Turn Over on Maxillary Sinus Floor**Augmentation Grafted Solely with Deproteinized Bovine Bone Mineral: A Prospective Human Histological and Clinical Trial****Abstract**

Purpose: To investigate the influence of maturation timing upon histological, histomorphometric and clinical outcomes when deproteinized bovine bone mineral (DBBM) was used as a sole biomaterial for staged maxillary sinus floor augmentation (MSFA).

Materials and methods: Patients with a posterior edentulous maxillary situation and a vertical bone height ≤ 4 mm were included in this study. A staged MSFA was carried out. After MSFA with DBBM as a sole grafting material, biopsy cores were harvested with simultaneous implant placement followed by a healing period of 5, 8, and 11 months, respectively. Micro-CT, histologic and histomorphometric analyses were performed.

Results: Forty-one patients were enrolled and 38 bone core biopsies were harvested.

Significantly greater BV/TV was observed between 5- and 8-month healing from micro-CT analysis. Histomorphometric analyses showed the ratio of mineralized newly formed bone increased slightly from 5 to 11 months; however, no statistically significant difference was reached ($p=0.409$). Residual bone substitute decreased from $37.3 \pm 5.04\%$ to $20.6 \pm 7.45\%$, achieving a statistical significant difference from 5 up to 11 months ($p<0.01$). Moreover, no implant failure, biological or technical complication occurred after 12-month follow-up of functional loading.

Conclusion: DBBM utilized as sole grafting material in staged MSFA demonstrated to be clinically effective regardless of the healing period. Histomorphometrical and micro-CT assessments revealed that at later stages of healing (8 and 11 months) there is a higher proportion of newly-bone formation compared to earlier stages (5 months). Moreover, the longer the maturation period, the substantially lesser remaining biomaterial could be expected. Even though, these facts did not seem to negatively impact on the implant prognosis 1-year after loading.

KEY WORDS: deproteinized bovine bone mineral; histological analyses; implant survival rate; maxillary sinus floor augmentation

Introduction

Insufficient bone volume is a common finding encountered in the rehabilitation of the edentulous posterior maxillae with implant-supported prostheses. Bone volume is limited by the pneumatization of the maxillary sinus together with loss of alveolar bone height.^{1,2} Sinus lifting procedures aim at increasing bone volume by augmenting the sinus cavity with autogenous bone or bone grafting biomaterials, or a mixture of both for adequate implant placement.³

Maxillary sinus floor augmentation (MSFA) is performed as a one- or two- staged approach with simultaneous or delayed implant placement.⁴ Generally speaking, with a residual bone height of less than 5mm, staged augmentation and implantation is advised considering the requirement of adequate implant primary stability to achieve subsequent osseointegration.⁵

Nowadays, a wide variety of bone substitute materials have been clinically demonstrated to promote acceptable outcomes in MSFA.⁶⁻⁹ Deproteinized bovine bone mineral (DBBM) is a clinically broadly used bone substitute in sinus augmentation and other ridge augmentation procedures. It has the property of slow resorption rate and has shown to have the potential to be colonized by osteocytes CD-44 positive to promote neovascularization within the particles.^{10,11} The advantage of using bone substitutes as sole grafting material before implant surgery is evident, as no donor site for harvesting autogenous bone is necessary.¹² Questions remain as to whether there is a significant positive impact to mixing bone substitutes like DBBM with autogenous bone over using DBBM alone for sinus augmentation.

Several clinical human studies have reported on the efficacy of DBBM used alone in MSFA. Bassil et al. conducted a histological analysis of human bone cores, which were harvested from augmented sinus using DBBM (Bio-Oss®) alone. After 8 months of healing, an average

percentage of newly formed bone was $17.6\% \pm 2.8\%$ and a proportion of residual bone substitute material was $29.9\% \pm 4.9\%$.¹³ Similar results were also achieved from another human study by Lee et al. After a healing period of 9 months using again Bio-Oss® alone, the percentages of regenerated bone and residual graft material was 19% and 40%, respectively.¹⁴ Meanwhile, implant placed into this regenerated bone had survival rates of 100% in both studies.^{13,14} Hence, the evidence of the aforementioned studies showed that the use of DBBM alone in MSFA is a predictable method to gain vertical bone height in the posterior maxilla while adequate bone turn over occurs. Nevertheless, DBBM only has osteoconductive property and so whether *de novo* bone formation is decelerated without the autologous bone transplantation is still a matter of debate in such a contained cavity as it is the maxillary sinus.^{15,16} As such, in an animal study, when an equal proportion of Bio-Oss and autogenous iliac bone was used as grafting material, the proportion of newly formed bone increased to 52% after 6 weeks.¹⁷ It was considered that the addition of autogenous bone to DBBM might accelerate bone formation during the early healing events compared to DBBM alone. Therefore, the clinical and histological outcomes of implants inserted at different healing timings in augmented maxillary sinuses remain to be areas of further investigation.

The primary outcome of the study herein was to investigate the influence of maturation timing upon histological, histomorphometric and clinical outcomes when deproteinized bovine bone mineral (DBBM) was used as a sole biomaterial for staged maxillary sinus floor augmentation (MSFA).

Material and methods

Study design

This study was conducted from May 2014 to December 2015. The study design and clinical procedures were performed in accordance with Helsinki Declaration, and were approved by the Ethical Committee of Shanghai 9th People's Hospital, China (Approval number: 01578). All patients signed the informed consent form before treatment.

Inclusion and exclusion criteria

Patients were selected to participate whether their clinical condition met the following inclusion criteria:

- (1) Patients had to be over 18 years of age at the time of surgery
- (2) Implant therapy was required in the posterior maxilla to restore masticatory function
- (3) Systemic and local conditions compatible with implant placement and MSFA
- (4) Less than or equal to 4 mm alveolar vertical bone height from the crest of the residual alveolus to the sinus floor
- (5) A minimum of a 3-month healing period after tooth extraction was assumed
- (6) Adequate width of alveolar ridge (bone width > 7mm) without additional horizontal bone augmentation
- (7) Normal inter-arch relationship
- (8) Patients with chronic periodontitis had to have been treated as part of initial periodontal therapy

Patients were excluded from the study for one or more of the following conditions: history of autoimmune or bone diseases, smoking, uncontrolled diabetes, radiation therapy, medication with steroids or bisphosphonates, untreated periodontal disease, or sinus infection.

Conventional panoramic radiography and cone beam computed tomography (CBCT) (i-CAT FLX Cone Beam 3D system; Kavo, Biberach, Germany) were taken to evaluate the maxillary sinus cavity and its vicinity together with the vertical residual bone height in the edentulous areas. The residual bone height was measured at every pre-operatively planned implant site.

Allocation and concealment

Subjects eligible for this study were randomly assigned into three groups using the random numbers table by an assistant. Subjects were randomly assigned into three groups:

- Group 1: staged MSFA → maturation phase of 5 months → implant placement
- Group 2: staged MSFA → maturation phase of 8 months, → implant placement
- Group 3: staged MSFA → maturation phase of 11 months → implant placement

The outcome examiner was blinded to the assignment.

Surgical procedure

MSFA were performed with simultaneous bone grafting according to the technique described by Tatum.¹⁸ Briefly, a full-thickness mucoperiosteal crestal incision and flap was made with vertical extensions and the lateral aspect of the maxilla was exposed. A window osteotomy was then prepared on the lateral aspect of the maxilla to access the maxillary sinus cavity. The Schneiderian membrane of the sinus was then gently reflected from the floor of the sinus cavity. The sinus cavity was then grafted under the elevated membrane by placing DBBM (Bio-Oss, Geistlich AG, Wohlhusen, Switzerland alone with a 1:1 ratio of 0.25mm-1mm/1mm-2mm granules) and was gently packed over the bone into the sinus. After placement of the graft, the sinus access window opening was then covered with a collagen membrane (Bio-Gide®; Geistlich AG, Wohlhusen, Switzerland), and the flap was sutured to attain primary closure.

All patients received postoperative nose drops for 7 days (Xinya Co., Shanghai, China) and were instructed not to blow through the nose for 2 weeks. Amoxicillin (Xinya Co., Shanghai, China; 500 mg, 4 times a day for 7 days) and metronidazole (Xinyiwangxiang, Shanghai, China; 400 mg, 3 times a day for 7 days) were prescribed. A chlorhexidine oral rinse (0.12%) was also prescribed (60s, 5–6 times a day for 7 days). After 14 days, the sutures were removed.

Implant placement and biopsy core harvesting

For group 1 patients, after a healing of 5 months, implants were inserted into the augmented sinus according to implant system manufacturer instructions. A pre-operative CBCT served as an indicator for the augmented region prior implant insertion.

Bone biopsy cores were removed with a trephine drill (outer diameter 3.0 mm, inner diameter 2.0 mm, length 10 mm; Hager Meisinger, Germany) from areas corresponding to where the implants were going to be placed and the region of the previous sinus graft. Bone biopsy

cores of approximately 2 x 10 mm in dimension were retrieved with a trephine drill. If multiple implants were planned, the core was taken from the site with the least pretreatment height of bone. Thus, each patient contributed only one biopsy for analysis.

The bone biopsy cores were immediately fixed in 10% neutral-buffered formalin to enable micro-CT and histomorphometric analyses. Oral implants (Straumann, Straumann AG, Basel, Switzerland) of 10 to 12 mm in length were placed in the grafted sites. MSFA, bone core biopsy and implant installations were performed by two surgeons. For group 2 and group 3 patients, after a healing of 8 and 11 months respectively, the procedures including implantation and biopsies harvesting were performed by the same two surgeons.

Micro-CT analysis

Non-decalcified bone cores were scanned and the data quantified using Micro-CT (Scanco Medical AG, Fabrikweg 2, Bruttisellen, Switzerland). The specimens were fitted in a cylindrical sample holder (15.4 mm in diameter) with the longitudinal axis of the bone core in a horizontal position. Specimens were scanned with scanning direction parallel to the longitudinal axis of the core specimen. High-resolution scanning, with an in-plane pixel size and slice thickness of 25 μm was performed. Software was used to make 3-dimensional (3-D) reconstruction from the set of scans.

The grafted sites were demarcated visually as the region located superior (apical) to the dense, mature lamellar bone and remnant DBBM particles with high density. The mean threshold gray scale values for bone and residual scaffold material were used to calculate the bone mineral density (BMD). The other morphometric variables analyzed included:

- *Bone volumetric fraction (BV/TV)* refers to the total amount of bone present in relation to the analyzed bone volume.

- *Bone surface density (BS/TV)* is the relation between the overall trabecular bone surface and the bone volume analyzed of mineralized bone.

- *Bone-specific surface (BS/BV)* analyzed the relation between the trabecular bone surface and the mineralized bone.

Bone histomorphometry

Bone cores were processed for histological analysis. Histomorphometric analysis of decalcified, hematoxylin and eosin (H&E)-stained sections was performed to determine newly bone formation and residual particles. Using a light microscope (BX51 Microscope, Olympus, Tokyo, Japan), histologic sections from each sample at each time point were scanned and imported into the software program (Image Pro 5.0, Media Cybernetic, Silver Springs, MD, USA). Identification of bone was based on morphology of stained tissue and the identification of grafting material, cells lining (osteoblasts) and within (osteocytes) this tissue. Bone tissue area for each section was determined by dividing the total number of bone pixels by the total number of pixels in the tissue section. To verify the accuracy and consistency of tracing outlines, three random slides were selected. The average of the three tracings per sample was obtained. Evaluation parameters included mineralized new bone volume/tissue volume, residual bone substitute material volume/tissue volume and inter-trabecular volume (bone marrow and soft tissue components)/tissue volume.

Implant outcome assessment

The follow-up examination was performed according to a standardized protocol, which included a clinical radiographic evaluation after delivering of the final prosthesis and one year follow-up.

Peri-implant clinical parameters included bleeding on probing using the modified bleeding index; modified plaque index¹⁹ and probing depth. Peri-implant bone resorption was recorded by comparing standardized long cone peri-apical radiographs. All of the images were scanned and transferred to a computer with an image analysis program (GE Healthcare Centricity@ v3.0, Milwaukee, WI, USA). Marginal bone loss (MBL) was documented on the radiograph viewer with the aid of four-fold magnification. The radiographic linear distance from the implant shoulder to the first bone to implant contact was used to calculate the MBL. The location of the MBL in relation to the implant shoulder was assessed at the mesial and

the distal aspects at the time of prosthesis delivery and at 1-year follow-up radiograph. Two assistants conducted the radiographic assessment.

Statistical analysis

Statistical analysis was conducted with PASW Statistics 18.0 (SPSS Inc, Chicago, IL, USA). Plots represent means \pm standard deviation (SD). Differences in means from micro-CT and histomorphometry analysis between 3 groups were assessed with one-way ANOVA. For non-parametric clinical parameters, the Kruskal-Wallis test was used to analyze differences among groups. In all tests, a significance level of 0.05 was chosen. \square

Results

Subject demographics

After determination of study eligibility and enrollment, a total of 41 patients with 41 sinuses were treated and 70 implants were placed in the posterior maxilla as above described. The baseline demographic characteristics of all study participants are shown in Table 1. During MSFA, membrane perforation occurred in 5 of 41 sinuses. In the 5 cases, the perforation was patched with a portion of Bio-Gide membrane. The postoperative course after MSFA was uneventful in all cases.

Forty-one bone samples were taken from the augmented maxillary sinus before implant placement. Three samples were lost during the extraction and 2 samples were not intact. On the other hand, a total of 38 bone core biopsies were available for analysis (Fig 1). Implants were inserted with sufficient primary stability after implant site preparation.

Micro-CT analysis

From sagittal-sectional imaging, micro-CT showed newly formed bone in sinus at 5 months post-operation (Fig 2). The characteristics of the newly formed bone were calculated by morphometric analysis among groups. BMD of the regenerated bone were 1132.7 ± 102.28 , 1153.2 ± 116.79 , and 1053.2 ± 163.89 , meanwhile BV/TV were $43.8 \pm 18.69\%$, $64.15 \pm 5.71\%$, and $59.57 \pm 7.97\%$ in group 1, group 2 and group 3, respectively. Significance of BV/TV was

observed between group 1 and group 2 after staged MSFA from micro-CT analysis ($p=0.007$). However, there is no significant difference in BMD, BS/TV and BS/BV amongst the groups. Moreover, although a positive trend was found with regards to BS/BV for group 1 ($10.78\pm 3.05\%$) compared to group 2 and 3 ($6.78\pm 1.47\%$ and $7.92\pm 1.79\%$, respectively), no statistical significance was reached. Alike, no significant differences were noted in the other micro-ct parameters evaluated (Fig 3)

Histomorphometric analysis

For all 3 groups, DBBM displayed good tissue integrity and it was easy to distinguish between DBBM and *de novo* bone. Direct contact occurred between the substitutes and the superimposed newly formed bone. De novo bone formation around the bone substitute could be visualized as well (Figs 4). The ratio of mineralized new bone, residual bone substitute, bone marrow and soft tissue of 3 groups was listed in Table 2. While for the newly formed mineral tissue did not reach statistical significance ($p=0.409$), the residual bone substitute together with the bone marrow and soft tissue content demonstrated to significantly increase and decrease, respectively from group 1 up/down to 3.

Implant outcome assessment

Thirty-two implants were restored as 2–3 units fixed bridges, 6 as single-unit crowns. The average time to completion of the final prosthesis after implant placement was 4.3 months (3–6 months). No patient dropped out of the study at follow-up. There was no implant lost during healing period and after functional loading. The survival rate of implants was 100% during 1-year follow-up. No biological (i.e. mucositis or peri-implantitis) or technical complications occurred.

The mean mPI and mSBI was 0.3 and 0.5 at the 1-year follow-up. There was no statistical significant difference of mPI and mSBI among 3 groups. The kappa (κ) values were >0.8 showing good inter-examiner reliability. Upon analysis of the MBL obtained for mesial and distal peri-implant sites, no significant differences were detected between the values for the mesial and distal sites. The overall mean MBL of 38 implants was 0.8 ± 0.17 mm (median: 0.8

mm). For the implants in group 1, group 2 and group 3, the mean MBL was 0.7 ± 0.21 mm (median: 0.7 mm), 0.7 ± 0.14 mm (median: 0.7 mm), and 0.8 ± 0.15 mm (median: 0.8 mm), respectively. No significant difference was detected amongst the groups evaluated.

Discussion

Augmentation of maxillary sinus is a well-documented method for creating sufficient bone for the adequate placement of dental implants in the maxillary posterior region.³ Autogenous bone has long been considered the gold standard; nonetheless, bone harvesting increases surgical complexity and is associated with morbidity and scarring of the donor site.²⁰ Therefore, alternative grafting materials were developed to overcome above mentioned shortcomings. Xenografts such as the DBBM are derived from different species and its preservation process consists in the complete or partial thermo-chemical removal of the organic component eventually creating a mineral inert long-lasting scaffold.²¹

Galindo-Moreno et al. described the healing patterns and bone remodeling activity following the use of two different graft mixtures (50% autologous bone/50% DBBM and 20% autologous bone/80% DBBM) for MSFA. At 6-month post-grafting evaluation, no statistically significant differences were found between groups in regards to vital bone and non-mineralized tissue proportions. However, higher number of osteocyte was observed in specimens with 50% to 50% ratio.⁷ A recent literature review conducted by Jensen et al. compared the differences between the use of DBBM or DBBM mixed with autogenous bone as graft for MSFA in animal study. Fourteen studies using the lateral window technique for the MSFA were identified. It was found that the volumetric stability of the graft improved significantly with the increased proportion of DBBM in the graft.²²

Several recent studies have confirmed the effect of the Schneiderian membrane on the formation of bone after MSFA.²³⁻²⁶ It was certainly found that, *in vitro* the Schneiderian membrane possess osteogenic capability and participates in the formation of bone after MSFA. However, the regenerative/reparative potential of the Schneiderian membrane *in vivo* has not been extensively evidenced.²⁷⁻³² On the other side, understanding the maxillary sinus as a

contained defect, the adjacent walls are the major responsible for the nutrients and oxygen supply needed to achieve predictable regeneration at the early stages of healing.^{27,31,33}

From the clinical point of view, it is necessary to confirm the adequate healing timing for implant placement after MSFA with DBBM alone, and the clinical outcome of dental implants inserted in the 'healed sinus', since autogenous bone/DBBM ratio may dramatically impact on bone remodeling patterns and cell content following MSFA as shown in previous studies.^{8,17}

Nowadays, little information is available and mainly restricted to animal models on the use of DBBM alone. A rabbit study tested DBBM alone in the maxillary sinus. Animals were sacrificed at 1, 2, 4, 6, or 8 weeks after surgical procedure. New bone formation was revealed on the surface of DBBM particles from 2 weeks and continued up to 8 weeks. The newly formed bone was 4%, 14%, 22%, 23% at 2, 4, 6, 8 weeks respectively with histomorphometric analysis.³³ Caneva et al. investigated the pattern of the sequential healing at augmented sinus cavities with DBBM granules as sole grafting material in the rabbit. Newly-formed mineralized bone increased from 5.2% up to 28.3% in the occupying areas of the elevated space at 7 days and 40 days healing.³² Such findings concur with the outcomes obtained in our investigation, where histomorphometrical analyses showed that the proportion of newly formed mineralized bone increased slightly from $18.0 \pm 6.04\%$ to $21.3 \pm 7.08\%$ from 5 to 11 months of healing, although it did not reach statistical significance. In this sense, it must be emphasized that data obtained in animal models must be cautiously extrapolated to the human, since the healing duration widely varies.

In our study, residual bone substitute decreased from $37.3 \pm 5.04\%$ down to $20.6 \pm 7.45\%$ from 5 up to 11 months of healing reaching statistical significance. In the aspect of biodegradation of DBBM, at present, limited information was available and to the best of authors' knowledge no study included quantitation over time in clinical trials. In an animal study, no significant differences in the proportion of remaining DBBM particles were revealed after 7.5 months and 1.5 year after MSFA.³⁴ In Caneva et al. study, DBBM particles decreased from 56.8% down to 37.4% in 7 and 40 days of healing and it was further shown that DBBM was

beneficial since it efficiently assisted to preserve over time the space within the elevated mucosa.³² Nevertheless, it is still needed to investigate further to understand the performance of DBBM by means of newly bone formation and long-term volumetric stability of the graft in the human. In the present study without using autogenous bone, new bone regeneration seemed slower than the biodegradation of material, meaning that the percentage of soft tissue and void spaces increased during the healing phase.

In the clinical setting, volumetric stability of the grafted defects, survival rates of implants inserted into grafted sinus, as well as the prevalence of complications have been important considerations. In previous clinical human studies, high survival rate of dental implants placed in augmented sinus with DBBM alone have been reported.^{13,14} However, the healing timing before implant insertion was 8 and 9 months respectively.^{13,14} Furthermore, the addition of autogenous iliac bone to DBBM might accelerate not only bone regeneration, but also the bone-to-implant contact during the early events of healing compared to DBBM alone.^{17,35} That is to say, with absence of autogenous bone, the progress of osseointegration might be affected negatively. However, from our investigation, even if the healing period was shortened down to 5 months, the implants showed similar clinical performance compared to the ones inserted in the augmented sinuses with 8 and 11 months of healing. One interesting animal study studied the healing sequence of osseointegration at implant installed simultaneously in MSFA with DBBM. The authors considered that the osteoconductive properties of the implant surface contributed to the progression of the osseointegration for MSFA procedures with simultaneous implant placement.³¹ This has an important clinical implication in the duration of the therapy and it could provide actual benefits for the patients by shortening the treatment plan.

Conclusion

DBBM utilized as sole grafting material in staged MSFA demonstrated to be clinically effective regardless of the healing period. Histomorphometrical and micro-CT assessments revealed that at later stages of healing (8 and 11 months) there is a higher proportion of newly-bone formation compared to earlier stages (5 months). Moreover, the longer the

maturation period, the substantially lesser remaining biomaterial could be expected. Even though, these facts did not seem to negatively impact on the implant prognosis 1-year after loading.

References

1. Chanavaz M. Maxillary sinus: anatomy, physiology, surgery, and bone grafting related to implantology – eleven years of surgical experience (1979–1990). *J of Oral Implantol.* 1990; 16: 199–209.
2. Bergh van den JP, ten Bruggenkate CM, Disch FJM, et al. Anatomical aspects of sinus floor elevations. *Clin Oral Implants Res.* 2000; 11: 256–265.
3. Esposito M, Felice P, Worthington HV. Interventions for replacing missing teeth: augmentation procedures of the maxillary sinus. *Cochrane Database Syst Rev.* 2014 May 13; (5): CD008397.
4. Chao YL, Chen HH, Mei CC, et al. Meta-regression analysis of the initial bone height for predicting implant survival rates of two sinus elevation procedures. *J Clin Periodontol.* 2010; 37(5): 456-465.
5. Pjetursson BE, Tan WC, Zwahlen M, et al. A systematic review of the success of sinus floor elevation and survival of implants inserted in combination with sinus floor elevation. *J Clin Periodontol* 2008; 35: 216- 240.
6. Nkenke E, Stelzle F. Clinical outcomes of sinus floor augmentation for implant placement using autogenous bone or bone substitutes: a systematic review. *Clin Oral Implants Res* 2009; 20: 124-133.
7. Galindo-Moreno P, Moreno-Riestra I, Avila G, et al. Effect of anorganic bovine bone to autogenous cortical bone ratio upon bone remodeling patterns following maxillary sinus augmentation. *Clin Oral Implants Res* 2011; 22(8): 857-864.
8. Hallman M, Lundgren S, Sennerby L. Histologic analysis of clinical biopsies taken 6 months and 3 years after maxillary sinus floor augmentation with 80% bovine hydroxyapatite and 20% autogenous bone mixed with fibrin glue. *Clin Implant Dent Relat Res* 2001; 3: 87- 96.
9. Monje A, O'Valle F, Monje-Gil F, et al. Cellular, Vascular, and Histomorphometric Outcomes of Solvent-Dehydrated vs Freeze-Dried Allogeneic Graft for Maxillary Sinus Augmentation: A Randomized Case Series. *Int J Oral Maxillofac Implants.* 2016 Aug 15. doi: 10.11607/jomi.4801
10. Xu H, Shimizu Y, Asai S, et al. Grafting of deproteinized bone particles inhibits bone resorption after maxillary sinus floor elevation. *Clin Oral Implants Res* 2004; 15: 126-133.
11. Galindo-Moreno P, Hernandez-Cortes P, Aneiros-Fernandez J, et al. Morphological evidences of Bio-Oss(R) colonization by CD44-positive cells. *Clin Oral Implants Res* 2014; 25: 366-371.
12. Palmer W, Crawford-Sykes A, Rose RE. Donor site morbidity following iliac crest bone graft. *West Indian Med J* 2008 Nov; 57(5): 490-492.

13. Bassil J, Naaman N, Lattouf R, et al. Clinical, histological, and histomorphometrical analysis of maxillary sinus augmentation using inorganic bovine in humans: preliminary results. *J Oral Implantol* 2013; 39(1): 73-80.
14. Lee DZ, Chen ST, Darby IB. Maxillary sinus floor elevation and grafting with deproteinized bovine bone mineral: a clinical and histomorphometric study. *Clin Oral Implants Res* 2012; 23(8): 918-924.
15. Rong Q, Li X, Chen SL, et al. Effect of the Schneiderian membrane on the formation of bone after lifting the floor of the maxillary sinus: an experimental study in dogs. *Br J Oral Maxillofac Surg* 2015; 53(7): 607-612.
16. Hallman M, Sennerby L, Lundgren, S. A clinical and histologic evaluation of implant integration in the posterior maxilla after sinus floor augmentation with autogenous bone, bovine hydroxyapatite, or a 20:80 mixture. *Int J Oral Maxillofac Implants* 2002; 17: 635-643.
17. Roldan JC, Knueppel H, Schmidt C, et al. Single-stage sinus augmentation with cancellous iliac bone and anorganic bovine bone in the presence of platelet-rich plasma in the miniature pig. *Clin Oral Implants Res* 2008; 19: 373-378.
18. Tatum, H. Maxillary and sinus implant reconstructions. *Dental Clinics of North America* 1986; 30: 207-229.
19. Mombelli A, Lang NP. Clinical parameters for the evaluation of dental implants. *Periodontol* 2000 1994; 4: 81-86.
20. Nkenke E, Stelzle F. Clinical outcomes of sinus floor augmentation for implant placement using autogenous bone or bone substitutes: a systematic review. *Clin Oral Implants Res* 2009; 20: 124-133.
21. Hämmerle CH, Chiantella GC, Karring T, et al. The effect of a deproteinized bovine bone mineral on bone regeneration around titanium dental implants. *Clin Oral Implants Res* 1998 Jun; 9(3): 151-162.
22. Jensen T, Schou S, Stavropoulos A, et al. Maxillary sinus floor augmentation with Bio-Oss or Bio-Oss mixed with autogenous bone as graft in animals: a systematic review. *Int J Oral Maxillofac Surg* 2012; 41(1): 114-120.
23. Gruber R, Kandler B, Fuerst G, et al. Porcine sinus mucosa holds cells that respond to bone morphogenetic protein (BMP)-6 and BMP-7 with increased osteogenic differentiation in vitro. *Clin Oral Implants Res*. 2004 Oct;15(5):575-580.
24. Srouji S, Ben-David D, Lotan R, et al. The innate osteogenic potential of the maxillary sinus (Schneiderian) membrane: an ectopic tissue transplant model simulating sinus lifting. *Int J Oral Maxillofac Surg* 2010; 39(8): 793-801.
25. Srouji S, Ben-David D, Funari A, et al. Evaluation of the osteoconductive potential of bone substitutes embedded with schneiderian membrane- or maxillary bone marrow-derived osteoprogenitor cells. *Clin Oral Implants Res* 2013; 24(12): 1288-1294.
26. Srouji S, Kizhner T, Ben David D, et al. The Schneiderian membrane contains osteoprogenitor cells: in vivo and in vitro study. *Calcif Tissue Int* 2009; 84(2): 138-145.
27. Scala A, Botticelli D, Rangel IG Jr, et al. Early healing after elevation of the maxillary sinus floor applying a lateral access: a histological study in monkeys. *Clin Oral Implants Res*. 2010 Dec;21(12):1320-6.

28. Scala A, Botticelli D, Faeda RS, et al. Lack of influence of the Schneiderian membrane in forming new bone apical to implants simultaneously installed with sinus floor elevation: an experimental study in monkeys. *Clin Oral Implants Res.* 2012 Feb;23(2):175-81.
29. Jungner M, Cricchio G, Salata LA, et al. On the early mechanisms of bone formation after maxillary sinus membrane elevation: an experimental histological and immunohistochemical study. *clin implant dent relat res.* 2015 Dec;17(6):1092-1102.
30. Favero V, Lang NP, Canullo L, et al. Sinus floor elevation outcomes following perforation of the Schneiderian membrane. An experimental study in sheep. *Clin Oral Implants Res.* 2016 Feb;27(2):233-240.
31. De Santis E, Lang NP, Ferreira S, et al. Healing at implants installed concurrently to maxillary sinus floor elevation with Bio-Oss® or autologous bone grafts. A histomorphometric study in rabbits. *Clin Oral Implants Res.* 2016 Mar 10. doi: 10.1111/clr.12825.
32. Caneva M, Lang NP, Garcia Rangel IJ, et al. Sinus mucosa elevation using Bio-Oss® or Gingostat® collagen sponge: an experimental study in rabbits. *Clin Oral Implants Res.* 2016 Apr 15. doi: 10.1111/clr.12850.
33. Sohn DS, Kim WS, An KM, Song KJ, Lee JM, Mun YS. Comparative histomorphometric analysis of maxillary sinus augmentation with and without bone grafting in rabbit. *Implant Dent* 2010; 19(3): 259-270.
34. McAllister BS, Margolin MD, Cogan AG, et al. Eighteen-month radiographic and histologic evaluation of sinus grafting with anorganic bovine bone in the chimpanzee. *Int J Oral Maxillofac Implants* 1999; 14: 361-368. □
35. Furst G, Gruber R, Tangl S, et al. Sinus grafting with autogenous platelet-rich plasma and bovine hydroxyapatite. A histomorphometric study in minipigs. *Clin Oral Implants Res* 2003; 14: 500-508.

Figure 1. Depiction of an augmented maxillary sinus and the selected region of interest to be analyzed solely consisting on the grafted area excluding the native bone.

Figure 2. Micro-CT images of representative bone biopsies from group 1 patients clearly show residual grafted scaffold (DBBM) particles (red zone) in the grafted zone 5 months after grafting. The zone of regenerated bone is delineated from the native bone (yellow hashed line).

Figure 3. Graph of the parameters studied by micro-ct analysis for the three groups: group 1= 5-month healing; group 2= 7-month-healing; and group 3= 11-month healing.

Figure 4. The DBBM (Bio-Oss[®]) particles were primarily incorporated in newly formed bone, whilst connective tissue surrounded the particles within the central part.

DBBM; * Mineralized new bone; § Bone marrow and soft tissue

Accepted Article

Table 1. Patient demographic data

	Group 1	Group 2	Group 3
No. of patients enrolled	13	15	13
Females	6	4	5
Mean age \pm SD, years (range) \square	45.2 \pm 11.9 (22-61)	44.1 \pm 14.0 (23-60)	46.4 \pm 11.7 (23-62)
Right maxilla/left maxilla \square	5/8	7/8	7/6
Mean baseline alveolar bone height (range)	3.2(1.5-4)	2.0(1-4)	2.4(1-4)
DBBM (g) (range)	2.3(2.0-3)	2.7(2.0-3.0)	2.5(2.0-3.0)
Bone core sample No.	12	13	13

Accepted Article

Accepted Article

Table 2. Mean±SD (%) of different tissue proportions in staged MSFA with different healing period

	Group 1 (12)*	Group 2 (13)	Group 3 (13)
	Mean±SD (%)		
Mineralized new bone	18.0±6.04	20.6±5.17	21.3±7.08
Residual bone substitute	37.3±5.04 #	28.2±5.34 #	20.6±7.45 #
Bone marrow and soft tissue	44.6±6.09&	51.0±5.83	58.1±6.60&

* No. of samples; #& p<0.05

Accepted Article

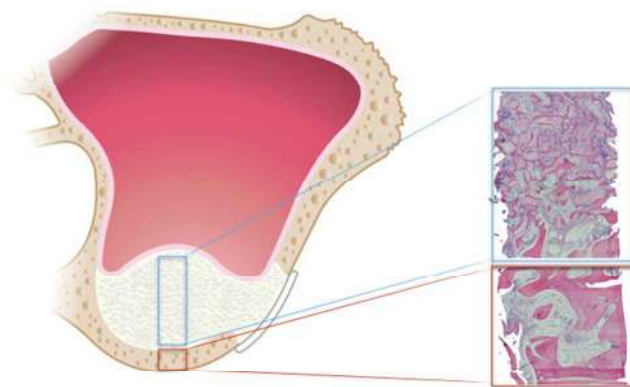


Figure 1. Depiction of an augmented maxillary sinus and the selected region of interest to be analyzed solely consisting on the grafted area excluding the native bone.

163x124mm (300 x 300 DPI)

Accepted

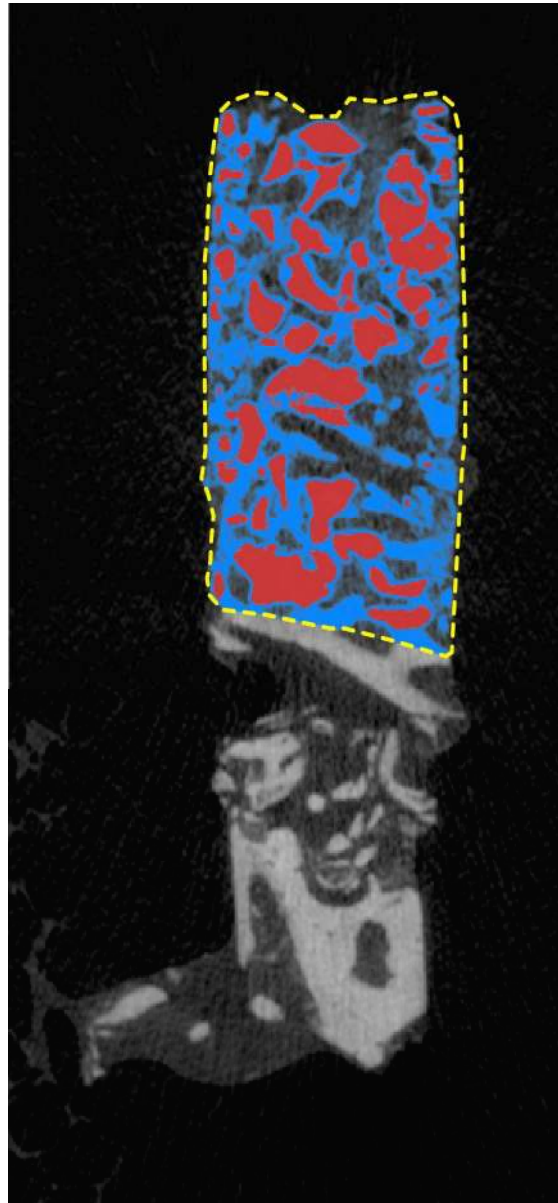


Figure 2. Micro-CT images of representative bone biopsies from group 1 patients clearly show residual grafted scaffold (DBBM) particles (red zone) in the grafted zone 5 months after grafting. The zone of regenerated bone is delineated from the native bone (yellow hashed line).

122x263mm (300 x 300 DPI)

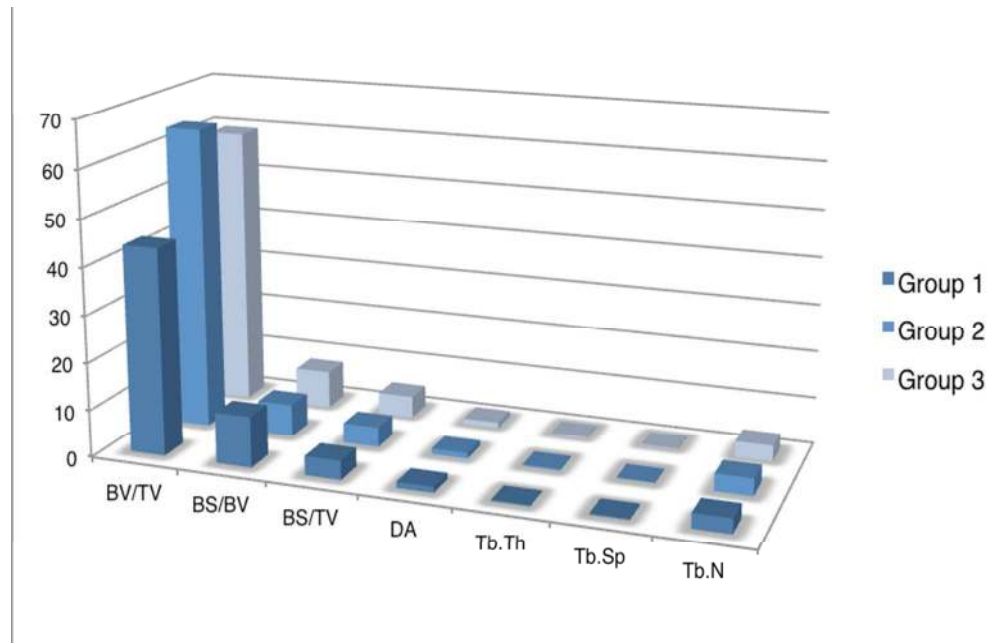


Figure 3. Graph of the parameters studied by micro-ct analysis for the three groups: group 1= 5-month healing; group 2= 7-month-healing; and group 3= 11-month healing.

194x124mm (300 x 300 DPI)

Accept

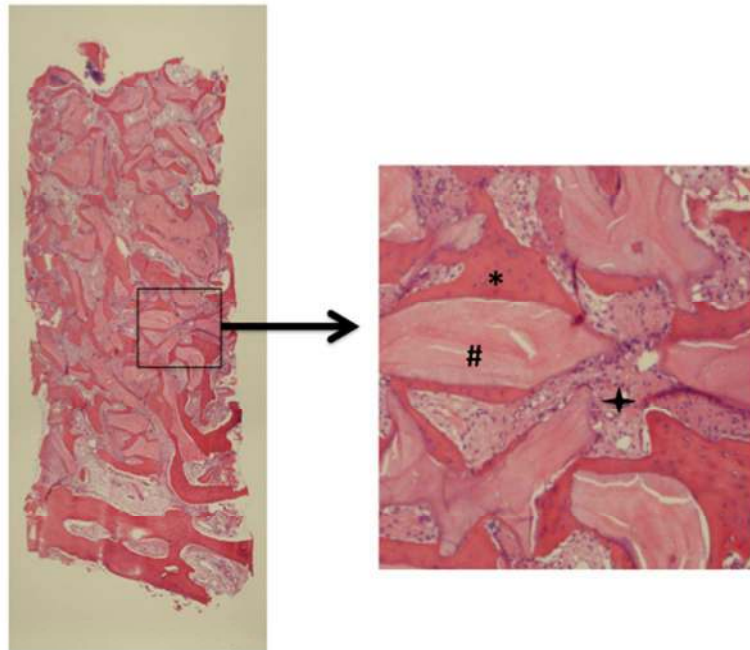


Figure 4. The DBBM (Bio-Oss®) particles were primarily incorporated in newly formed bone, whilst connective tissue surrounded the particles within the central part. # DBBM; * Mineralized new bone; § Bone marrow and soft tissue

167x124mm (300 x 300 DPI)

Accepted