

Influence of the interocclusal splint in condylar position of patients with tmd: a cone beam computed tomography study

Influência da placa interoclusal na posição condilar de indivíduos com dtm: um estudo por tomografia de feixe cônico

Deícola Coelho FILHO¹, Luís Antônio Nogueira dos SANTOS¹, Agnaldo Souza Rocha JÚNIOR¹, Laís Valencise MAGRI², Marcelo Oliveira MAZZETTO²

1 – Department of Dentistry – State University of Montes Claros – Montes Claros – Minas Gerais – Brazil.

2 – Department of Restorative Dentistry – School of Dentistry of Ribeirão Preto – São Paulo University – Ribeirão Preto – São Paulo – Brazil.

ABSTRACT

Objective: The aim of this study was to evaluate the condylar position in patients with intra-articular temporomandibular disorders (TMD) before, during and after treatment with interocclusal stabilization splint (ISS) through cone beam computed tomography (CBCT). **Material and Methods:** Twenty-two patients diagnosed with intra-articular TMD (Research Diagnostic Criteria for Temporomandibular Disorders - Group II) were submitted to the therapy with ISS during 90 days. Three CTCT exams were performed in three moments: T₁ (initial moment, before the ISS therapy, with the patient in dental occlusion), T₂ (after 90 days of treatment, in occlusion on the ISS) and T₃ (after 90 days of treatment, with the patient in dental occlusion). Afterwards the anterior (AS), superior (SS) and posterior articular spaces (PS) in sagittal sections were then measured and the data were statistically analyzed using the t-test. **Results:** There was a statistically significant increase in the comparison between T₁ and T₂ for the AS and PS (p < 0.0001), between T₃ and T₂ for AS (p = 0.0008) and PS (p < 0.0001). In comparison T₁/T₃ there was a significant increase in AS (p = 0.01) and SS (p = 0.04), and non-significant in PS (p = 0.89). **Conclusion:** The interocclusal splint provides temporary changes in condylar position, with a tendency to increase the joint space, varying in accordance with individual characteristics. Therefore, it should not be used as a single therapy, but combined with other strategies that include the TMD multidimensionality. The interocclusal splint has proved to be reversible and conservative therapeutic modality, as it does not generate permanent changes in joint tissues.

KEYWORDS

Mandibular condyle; Temporomandibular joint disorders; Occlusal splint; Cone-beam computed tomography.

RESUMO

Objetivo: O objetivo deste estudo foi avaliar a posição condilar em pacientes com disfunção temporomandibular (DTM) articular antes e após tratamento com placa oclusal estabilizadora (POE) por meio de tomografia computadorizada de feixes cônicos (TCFC). **Material e Métodos:** Vinte e dois pacientes diagnosticados com DTM articular (Research Diagnostic Criteria for Temporomandibular Disorders – Grupo II) foram submetidos à terapia com POE durante 90 dias. Foram realizados três exames de TCFC: T₁ (momento inicial, antes da terapia com POE, na posição de oclusão dental), T₂ (após 90 dias de tratamento em oclusão na POE) e T₃ (após 90 dias de tratamento, em oclusão dental). Foram então mensurados o espaço articular anterior (EAA), superior (EAS) e posterior (EAP) em cortes sagitais. Os dados foram analisados estatisticamente por meio do teste t. **Resultados:** Houve aumento estatisticamente significativo na comparação entre T₁ e T₂ para o EAS e EAP (p < 0,0001), entre T₃ e T₂ para EAS (p = 0,0008) e EAP (p < 0,0001). Na comparação entre T₁ e T₃ houve aumento significativo no EAA (p = 0,01) e EAS (p = 0,04), e não significativo no EAP (p = 0,89). **Conclusão:** A placa interoclusal promove alterações temporárias na posição condilar, com tendência de aumentar o espaço articular, variando de acordo com características individuais. Portanto, ela não deve ser utilizada como terapia única, e sim combinada com outras estratégias que abordem a multidimensionalidade da DTM. A placa interoclusal provou ser uma terapia reversível e conservadora, já que não gera alterações permanentes nos tecidos articulares.

PALAVRAS-CHAVE

Côndilo mandibular; Transtornos da articulação Temporomandibular; Placas oclusais; Tomografia computadorizada de feixe cônico.

INTRODUCTION

One of effective treatments for temporomandibular disorders (TMD) is repositioning the temporomandibular joint (TMJ) in an orthopedically stable position, which does not generate compression of the intra-articular structures. The interocclusal stabilization splint (ISS) provides a temporary change in the occlusal condition that allows the TMJ to remain in a position to articulate stably and it can reduce the signs and symptoms of TMD. It should be highlighted, also, that the therapy with ISS is reversible and non-invasive, indicating it for treating this clinical condition, which has a complex and multifactorial etiology [1].

Several hypotheses have been proposed to explain the effectiveness of ISS; however, there is no general consensus on why the treatment with ISS may have a beneficial effect [2]. Among the hypotheses about the action mechanism, the following can be indicated: amendment of occlusal condition and the condylar position; an increase in the vertical dimension; perception of cognitive activities functional and parafunctional; placebo effect; and increase of peripheral pulse to the central nervous system [1].

TMJ imaging modalities have evolved over the last decade. The advents of the latest techniques and developments in imaging have allowed better appreciation of the anatomy and function of this joint. The correlation of these exams with clinical results has led to a better understanding of the pathophysiology of disorders that involve the TMJ. They also have an increasing role at the level of research in the search for greater understanding of TMD [2,3]. The availability of cone beam computed tomography (CBCT) as a complementary resource for dental examinations became a reality able to supply deficiencies in other imaging methods. The image obtained with the CBCT is in actual size and with tomographic sections that eliminate the overlap of images of other anatomical structures on the structures of

interest in the exam. Thus, the CBCT is the exam for more reliable imaging to evaluate condylar position [4,5].

Our hypothesis is that the interocclusal stabilization splint promotes changes in condyle position on a temporary period, ie only during the use and that therefore this type of therapy needs to be complemented with other intervention strategies for patients with intra-articular disorders. The objective of this study was to evaluate, through CBCT, the condylar position in patients with articular TMD, before and after treatment with interocclusal stabilization splint. Therefore, the aim of this study was to evaluate the articular spaces changes between the condyle and the joint cavity with the patients under ISS treatment and whether there is an improvement on mandibular movements after the treatment with ISS.

MATERIAL AND METHODS

The Ethics Committee in Research of the State University of Montes Claros (UNIMONTES – Under protocol 173.442) has approved this research in accordance with the resolution 196/96 of the National Council of Health. Twenty-two patients with signs and symptoms of articular TMD were selected in the Clinical Course of Dentistry at UNIMONTES. Of this total, 3 were male (13.64%) and 19 female (86.36%), aged between 19 and 49 years (mean 33 ± 7.4).

Patients with pain were included in one or both TMJ during palpation of the lateral condyle pole and/or posterior ligament, associated with one or more of the following self-reported pain: pain in the TMJ region; pain during unassisted or assisted maximum mouth opening; and pain during lateral movements. Patients were excluded who had chronic use of analgesics, anti-inflammatory drugs or psychotropic substances or who had received any treatment for TMD or orthodontic treatment in the last six months. Patients with psychiatric disorders, systemic

diseases, infectious and inflammatory, epilepsy, articular diseases degenerative diseases, tumors, patients with signs and symptoms of fibromyalgia, and pregnant women were also excluded. The diagnosis of articular TMD was established based on the criteria of the Research Criteria for Temporomandibular Disorders RDC/TMD, including only patients classified in group II (disc displacement) [6]. The evaluations were performed by a single examiner, which was previously trained and calibrated.

The patients were treated with ISS and followed up for a period of 90 days. Splints were adjusted to obtain comfort and stable occlusal contacts in all teeth and disocclusion guides. The patients were instructed to use the splint for a period of 24 hours a day, except when eating, and guidance on the need for visits for revaluations. During the period of treatment, all patients attended the follow-ups regularly performed in the following sequence: installation of the splint; visits after 7, 15, 30, 60 and 90 days. The patients were instructed not to use analgesics and/or anti-inflammatory drugs during the evaluations. In each patient's visit for periodic reevaluation, they were evaluated, the occlusal contacts were readjusted and the disocclusion guides on the occlusal surface of the ISS.

The patients were submitted to three CBCT exams, being these examinations separated into three groups: T_1 - At the beginning of treatment, before placing the ISS with the patient in dental occlusion in the MHI. T_2 - After 90 days of treatment with the ISS (in occlusion on the splint). T_3 - After 90 days of treatment with the ISS, with the patient in dental occlusion in MHI. The tomography images were obtained in accordance with current rules of radioprotection and biosafety.

Linear measures of posterior space (PS), superior space (SS), and anterior space (AS) of the TMJ were evaluated to determine the condyle position for each joint, being 22 on the right side and 22 on the left side of each patient. The scans

were made with the tomography cone beam technology (Imaging Science International, Hatfield, PA, EUA), ICAT model. The imaging acquisition protocol was 120 KV, 3mA, field of view of 8.0 X 16.0 cm, scanning both right and left TMJ, and voxel of 0.25 mm.

The patients were fully informed about the procedures for the conduct of examinations and tomographic oriented, at the appropriate time, to remain in the proper position for each examination, as described in the first examination, at the beginning of the treatment, the patient was advised to keep with the mouth closed in dental occlusion in MHI; in the second examination, at the end of 90 days of treatment, the patient was advised to use the ISS at least an hour before they come to the Radiology Center and do the first tomography scan with the ISS in position in the mouth. At the time of the tomographic examination, the patient was advised to occlude the board maintaining contact bilateral lower teeth in the same; on the third examination, also at the end of 90 days, the patient was instructed to remove the ISS and wait for 10 minutes. Then, at the time of the tomography, the patient was advised to continue with the mouth closed in dental occlusion in the MHI.

The processing, obtaining images and measurements of joint spaces were performed using the software CS 3D Imaging version 3.3.9 (Carestream Health, NY, EUA). The images were exported to the DICOM format. First of all, in the coronal section it was identified the biggest distance between the lateral and the medial pole of the condyle, then the distance between the two poles was measured using a ruler. In half of this distance a vertical line was drawn. This line was used to determine the point for obtaining the sagittal section (the center parasagittal) used in measurements of the joint space (Figure 1).

The next step was to maximize the sagittal image window with the preview option 3x3, showing nine images with sagittal view of the

TMJ. The image of the center was set to perform the measurements of the space between the condyle and the joint cavity (Figure 2). Thus, it was possible to determine approximately the same position as the sagittal section in the three topographies performed on the same patient. This step was performed by only one professional examiner. Each sagittal section was recorded and saved in JPEG format, so that three examiners, a specialist in prosthodontics, a specialist in TMD and a specialist in radiology could make its measurements in the same sagittal view of this section, avoiding that the measures were made in sagittal sections in different sagittal sections on the shaft between the lateral pole and medial pole of the condyle.

The standardized linear measurements of the space between the condyle and the articular fossa were performed as proposed by Ikeda and Kawamura [7]. A true horizontal line obtained from the natural position of the head was used as reference. The distance from the uppermost point of the condyle (SC) to the uppermost articular fossa (SF) was measured as the superior joint space (SS). Tangent lines to the most prominent anterior and posterior borders of the condyle were traced from SF. The distance of the anterior (AC) and posterior (PC) tangents to points of the articular fossa were measured at right (Figure 3).

For inter-examiner reliability, the statistical analysis used was the Intraclass Correlation Coefficient (ICC, adopting a cutoff point ≥ 0.75) and after the normality assessment, t-test for independent samples was performed for comparison between the moments with and without ISS and between the intra-articular spaces, adopting 5% as a significant level.

RESULTS

The repeatability of the examination was excellent, confirming the statistical reliability of the data obtained in this study (Table 1) for AS, SS and PS. The cutoff point considered was ≥ 0.75 ,

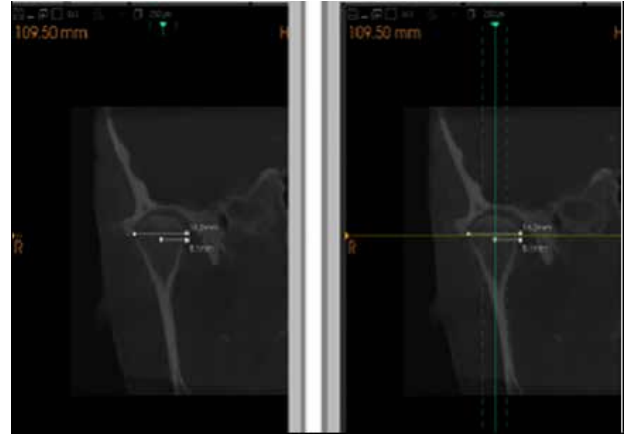


Figure 1 - Measurement of the biggest distance between the medial pole of the condyle and the half this distance. Vertical line drawn in the long axis of the condyle to determine the position of the sagittal section used in the measurements of joint spaces.

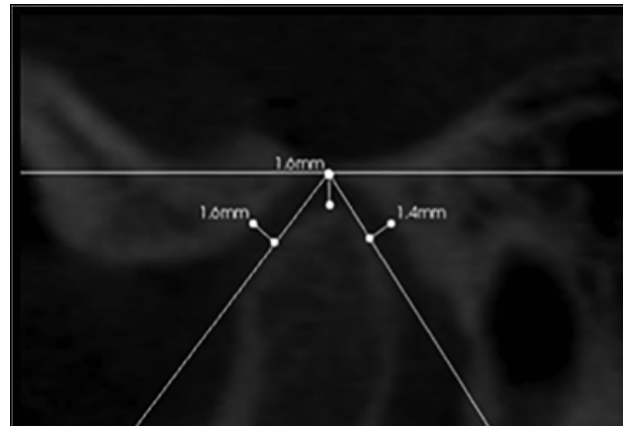


Figure 2 - Determination of the anterior, posterior and superior spaces performed with the software CS 3D imaging (Carestream Health - 3D CS imaging, Rochester - New York, version 3.3.9).

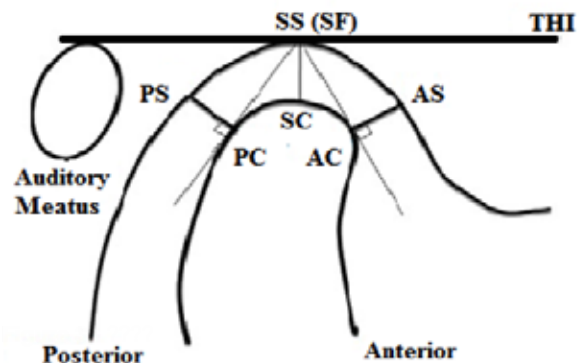


Figure 3 - Measures of the condyle position in the joint cavity proposed by Ikeda and Kawamura (2009).

so it is possible to assert that the three examiners have not shown differences in the measurements. In the statistical analysis for comparison between the measurements in the CBCT images between T_1 and T_2 there was a statistically significant difference for the SS and the PS ($p < 0.001$ for both). For the AS there was no statistically significant difference ($p = 0.24$) (Table 2).

For comparison between the measurements in the CBCT images between T_2 and T_3 there was a statistically significant difference for the SS ($p = 0.008$) and the PS ($p < 0.001$). For the AS there was no statistically significant difference ($p = 0.30$). In the statistical analysis for comparison between the measurements in the CBCT images between T_1 and T_3 there was a statistically significant difference for the AS ($p = 0.01$) and the SS ($p = 0.04$). For the PS there was no statistically significant difference (Table 2).

Table 1 - ICC measures of articular spaces between the three examiners.

Joint Spaces	1	2	3
AS	0.8799	0.7500	0.8919
SS	0.8717	0.8562	0.8689
PS	0.9000	0.8144	0.8793

*Cutoff Point ≥ 0.75 .

Table 2 - Mean and standard deviation of the measurements in the CTCTB images and comparison between times T_1 , T_2 and T_3

	Mean (SD) T_1	Mean (SD) T_2	Mean (SD) T_3	P-value T_1 vs. T_2	P-value T_2 vs. T_3	P-value T_1 vs. T_3
AS	215 (0.7)	219 (0.7)	223 (0.8)	ns	ns	0.01
SS	273 (0.6)	297 (0.7)	28 (0.7)	< 0.0001	0.0008	0.04
PS	187 (0.6)	227 (0.7)	187 (0.7)	< 0.0001	< 0.0001	ns

* Difference considered statistically significant (≤ 0.05); ns - no significance.

DISCUSSION

Recent studies have been performed in order to evaluate the condylar position and measure the joint spaces in patients without signs and TMD joint symptoms, through CBCT [7-9]. In patients with TMD the PS is slightly

reduced, while SS and AS is slightly increased [10]. Other studies have demonstrated that the average of AS was lower in relation to the PS in healthy patients [11, 12]. In our study, patients with signs and symptoms of articular TMD were found, the following average values of joint spaces with the patient in the MHI position: 2.15 mm in AS; 2.73 mm in SS; and 1.87 mm in PS. The proportion of these values for the AS, SS and PS, according to the ideal proportion determined by Ikeda and Kawamura [7], whereas 1.0 mm for the AS was, respectively, 1.0, 1.3 and 0.9. The results found in this study showed higher values for the AS in relation to the PS, however, it is important to consider that the patients participating in this study showed different signs and symptoms of articular TMD.

The effects of ISS treatment are not fully defined, especially in TMJ region. There is no general agreement about the splint therapeutic mechanisms, however the scientific literature has considered that it has a beneficial effect in TMD management [2,13]. There are several hypotheses to explain the apparent effectiveness of this occlusal device; however, none of these hypotheses are scientifically proven [14,15]. The Cochrane Database Syst. Rev. has suggested the development of new researches about occlusal splints because there was insufficient evidence either for or against the use of stabilization splint therapy for the TMD management [14].

One of the supposed effects of treatment with ISS is the amendment of condylar position to a more stable and functional position, favoring the joint decompression [1,11,15]. The results of this research showed, by comparing the measures of joint spaces between $T1/T2$ and $T2/T3$, that there was a significant increase in joint spaces when using the ISS. It is important to report that there was statistically significant increase of SS and PS, with no statistically significant difference in AS. The AS had higher values than the PS in moments without splint ($T1$ and $T3$), but in $T2$ there was a significant increase in PS, producing a better balance

between AS and PS and making the condyle assume a more central position at glenoid fossa. This new condyle position can contribute to a better positioning of articular disc and other TMJ structures.

As the results found in this research, some studies have shown the mandibular condyle position with ISS, as Hasegawa et al. (2011) that used magnetic resonance images to show differences in articular disc and condyle with splint in position and Kuboki et al. (1997) that have concluded that occlusal appliances induce an increase in joint space during clenching [11,12]. This is a desirable situation because it prevents the mandibular head to articulate with retrodiscal region, which is highly vascularized and innervated, with the anterior region more conducive to receive forces from the posterior region [1].

Thus, the results found in this study showed a statistically significant increase in SS and the PS, with no statistically significant difference in AS during use of the splint, it can be considered that the ISS therapy causes alteration of condylar position to a more stable and functional position. According to a study carried out, the use of ISS promoted the reduction of TMD signs and symptoms and increase in joint spaces observed through the TMJ transcranial radiograph, in patients with joint TMD [15]. This research found similar results, with improvement in signs and symptoms of the TMD joint associated with increased joint space when using the ISS, however, with the advantage of accuracy of the measurements obtained with the CTCB in relation to transcranial radiograph.

The ISS promotes the reduction of TMD signs and symptoms and other benefits in the management of parafunctions [16,17]. Some studies have demonstrated benefits in the use of the splint in both joint and muscle dysfunction [18,19]. However, some studies found no significant difference in improvement of patients treated with splint and placebo [16,19-21]. The

images exams should be indicated for TMD professionals in specific cases, only when these exams will change the therapy direction, in order to reduce the patient exposure to ionizing radiation.

To compare the joint measures between T1, performed before initiating therapy with ISS, and the T3, made after the therapy with ISS for a period of 90 days, it can be observed that there has been virtually no significant alteration of the joint spaces. This suggests that, even after the use of ISS for 90 days, when the teeth come into occlusal contact (MIH) the mandible head tends return the position targeted by dental contacts, and the splint temporarily eliminates the nociceptive information of oral region, periodontal and joint, allowing them to break all or part the engram (conditioned reflex) existing in the dental contacts and opening movements and mandibular closing, which can be altered by interference or existing occlusal prematurities [17,18,22]. It is important to consider that many other factors can influence the onset of TMD signs and symptoms and clinical management with intraoral devices: the patient's age, muscle condition, the commitment to use the occlusal splint and the placebo effect [2,23].

CONCLUSION

Considering the limitations of this study, the absence of control group, the method and the sample data, we can conclude that the interocclusal splint, despite having the thickness similar to the functional free space, provides changes in condylar position, with a tendency to increase the joint space, varying in accordance with individual characteristics. However, these joint changes occur only with the splint in position, therefore it should not be used as a single therapy, but combined with other strategies that include the TMD multidimensionality. The interocclusal splint has proved to be reversible and conservative therapeutic modality, as it does not generate changes in joint tissues.

REFERENCES

- Okeson JP. Management of temporomandibular disorders and occlusion. 6th Ed. St. Louis: Mosby; 2008.
- Yadav S, Karani JT. The essentials of occlusal splint therapy. *Int J Prosthodont*. 2011; 2(1):12-21.
- Lewis EL, Dolwick MF, Abramovics S, Reeder SL. Contemporary imaging of the temporomandibular joint. *Dent Clin N Am*. 2008;52:875-90.
- Barghan S, Tetradis S, Mallya SM. Application of cone beam computed tomography for assessment of the temporomandibular joints. *Aust Dent J* 2012; 57(1 Suppl): 109-18.
- Honey OB, Scarfe WC, Higers MJ, Klueber K, Silveira AM, Haskell BS, Farman AG. Accuracy of cone-beam computed tomography imaging of the temporomandibular joint: Comparisons with panoramic radiology and linear tomography. *Am J Orthod Dentofacial Orthop*. 2007; 132:429-38.
- Dworkin SF, LeResche L. Research diagnostic criteria for temporomandibular disorders: review, criteria, examinations and specifications, critique. *J Craniomand Disord*. 1992;6:301-55.
- Ikeda K, Kawamura A. Assessment of optimal condylar position with limited cone-beam computed tomography. *Am J Orthod Dentofacial Orthop*. 2009; 135:495-501.
- Vitral RWF, Campos MJS, Rodrigues AF, Fraga MR. Temporomandibular joint and normal occlusion: Is there anything singular about it? A computed tomographic evaluation. *Am J Orthod Dentofacial Orthop*. 2011; 140:18-24.
- Dalili Z, Khaki N, Kia SJ, Salamat F. Assessing joint space and condylar position in the people with normal function of temporomandibular joint with cone-beam computed tomography. *Dent Res J*. 2012; 9: 607-612.
- Mazzetto MO, Veneziani GC, Magri LV, Nasr MK, Paiva AF, Paiva G. Evaluation of the condylar position in subjects with signs and symptoms of functional disorders of the temporomandibular joint through images made with cone beam computed tomography on the sagittal plane. *Braz Dent Sci*. 2014 Apr/Jun;17(2):77-88.
- Hasegawa Y, Kakimoto N, Tomita S, Honda K, Tanaka Y, Yagi K, Kondo J, Nagashima T, Ono T, Maeda Y. Movement of the mandibular condyle and articular disc on placement of an occlusal splint. *Oral Surg Oral Med Oral Pathol Oral Radiol Endod*. 2011;112:640-7.
- Kuboki T, Azuma Y, Orsini MG, Hirooka T, Yatani H, Yamashita A. The effect of occlusal appliances and clenching on the temporomandibular joint space. *J Orofac Pain*. 1997;11:67-77.
- Dao TT, Lavigne GJ. Oral splint: the crutches for temporomandibular disorders and bruxism? *Crit Rev Oral Biol Med*. 1998; 9(3):345-61.
- Al-Ani MZ, Davies SJ, Gray RJ, Sloan P, Glenney AM. Stabilisation splint therapy for temporomandibular pain dysfunction syndrome. *Cochrane Database Syst Rev*. 2004;(1):CD002778.
- Ekberg E, Sabet ME, Petersson A, Nilner M. Occlusal appliance therapy in a short-term perspective in patients with temporomandibular disorders correlated to condyle position. *Int J Prosthodontic*. 1998;11: 263-8.
- Demling A, Fauska K, Ismail F, Stiesch M. A comparison of change in condylar position in asymptomatic volunteers utilizing a stabilization and a pivot appliance. *Cranio*. 2009 Jan;27(1):54-61.
- Kurita H, Kurashina K, Kotani A. Clinical effect of full coverage occlusal splint therapy for specific temporomandibular disorder conditions and symptoms. *J Prosthet Dent*. 1997;78:506-10
- Conti PCR, Santos CN, Kogawa EM. The treatment of painful temporomandibular joint clicking with oral splints. A randomized clinical trial. *JADA*. 2006;137(8):1008-14.
- Ekberg E, Vallon D, Nilner M. Occlusal appliance therapy in patients with temporomandibular disorders: a double-blind controlled study in a short-term perspective. *Acta Odontol Scand*. 1998;56:122-8.
- Ekberg E, Vallon D, Nilner M. The efficacy of appliance therapy in patients with temporomandibular disorders of mainly myogenous origin: a randomized, controlled, short-term trial. *J Orofac Pain*. 2003;17:133-139.
- Dao TT, Lavigne GT, Charbonneau A, Feine JS, Lund P. The efficacy of oral splints in the treatment of myofascial pain of the jaw muscles: a controlled clinical trial. *Pain*. 1994;56:85-94.
- Wassell RW, Adams N, Kelly PJ. Treatment of temporomandibular disorders by stabilizing splints in general dental practice: results after initial treatment. *Br Dent J*. 2004;197:35-41.
- Mazzetto MO, Rodrigues CA, Magri LV, Melchior MO, Paiva G. Severity of TMD related to age, sex and electromyographic analysis. *Braz Dent J*. 2014 Jan-Feb; 25(1):54-8.

Lais Valencise Magri
(Corresponding address)

Department of Restorative Dentistry, School of Dentistry of Ribeirão Preto, University of São Paulo (FORP-USP). Av. do Café (without number), Ribeirão Preto, SP, Brazil 14040-904.
E-mail: laismagri@gmail.com

Date submitted: 2016 Mar 31

Accept submission: 2016 Aug 07