

Inhibition of Human Mammary and Prostatic Cancers by Adrenalectomy*

CHARLES HUGGINS AND DELBERT M. BERGENSTAL

(Ben May Laboratory for Cancer Research and the Department of Medicine,
University of Chicago, Chicago 37, Ill.)

It is known that excision of the adrenal glands with maintenance of the animal on sodium chloride has two opposite effects on tumors. Adrenalectomy stimulates the growth of lymphoid tumors in the rat and mouse while retarding the growth rate of many other neoplasms in these species; a decrease in the size of established tumors has not been reported. It will be demonstrated in this paper that adrenalectomy with maintenance of the organism on cortisone acetate can cause some regression of neoplasms, namely, certain cancers of the breast and prostate of man.

The depression of the growth rate of transplantable tumors by adrenalectomy has been observed several times. Joannovics (23) observed that transplanted sarcomas in adrenalectomized mice were slightly over 20 per cent less in weight than in intact controls. Roffo (30) reported a decrease in the growth rate of a transplanted sarcoma and carcinoma of rats following excision of the adrenals. Bischoff and Maxwell (2) did not find that adrenalectomy significantly affected the growth behavior of Walker carcinoma 256 in rats. However, Ingle and Baker (21), with more precise methods, found that adrenalectomy significantly retarded the rate of tumor growth of Walker carcinoma 256 in force-fed ovariectomized rats and in intact males; in this laboratory we have been able to confirm these findings. Funk *et al.* (10) also found that the Walker tumor grows at a reduced rate in adrenalectomized rats. Ingle and Baker ascribed the retardation of neoplastic growth to the theory that rapidly growing tissues cannot attain a "peak

rate of anabolism" in adrenally insufficient animals.

Apart from rodents, the only observations on the growth of tumors in adrenalectomized creatures have been on a human neoplasm. Huggins and Scott (20) demonstrated retardation of growth in a man with prostatic cancer after total adrenalectomy, and Cox (4) later observed "a dramatic if temporary clinical improvement" in a patient with this tumor after subtotal removal of the adrenals.

Acceleration of the growth of neoplasms by adrenalectomy was discovered by Murphy and Sturm (27, 32), who found that the number of "takes" of a transplantable lymphatic leukemia was greatly increased and the length of life of successfully inoculated rats was less following adrenalectomy than in intact rats. Law *et al.* (25) observed that adrenalectomy considerably increased the incidence and the time of appearance of spontaneous lymphoid leukemia in C58 mice.

Heilman and Kendall (12) found that the administration of 11-dehydro-17-hydroxycorticosterone caused a rapid, profound, yet temporary regression of a transplanted lymphosarcoma in mice; furthermore, when injections of this compound were begun soon after inoculation of the tumor, its growth was delayed for as long as Compound E was given. The growth rate of the following transplantable tumors has been depressed after the injection of 11-oxygenated steroids: three types of lymphosarcoma (33, 7); two osteogenic sarcomas (33); rhabdomyosarcoma (13); ependymoma (3); and various other sarcomas (33). Ingle, Prestrud, and Baker (22) found that cortisone acetate caused a suppression of the growth rate of the Walker 256 tumor in tube-fed rats.

Pituitary adrenocorticotrophin (ACTH) and cortisone acetate have been administered to patients with malignant disease. Pearson *et al.* (28) observed a dramatic and progressive but temporary decrease in the size of enlarged lymph nodes

* This study was aided by grants from the Jane Coffin Childs Memorial Fund for Medical Research, the American Cancer Society on recommendation of the Committee on Growth of the National Research Council, and the Damon Runyon Memorial Fund for Cancer Research. The authors are grateful to Dr. Thomas L. Y. Dao, Donald F. Tapley, Mrs. Anne S. Cleveland, and Prof. Eleanor M. Humphreys for assistance. Cortisone acetate was generously provided by the Medical Division of Merck & Co., Rahway, N.J.

Received for publication November 6, 1951.

and the spleen of six patients with lymphomatous tumors after the administration of these agents; there was no obvious clinical response in two patients with metastatic cancer of the breast and prostate, respectively. Eliel *et al.* (6) reported no demonstrable shrinkage of tumors in seven patients with advanced carcinoma of various kinds following treatment with ACTH or cortisone acetate. Postlethwait *et al.* (29) found that the course of malignant disease appeared to be completely unaltered by cortisone in nine patients with advanced carcinoma of the digestive tract. Spies *et al.* (31) stated that there was a reduction in size and a decrease in pain in a patient with carcinoma of the lip following ACTH; no histologic modifications were detected in the tumor in this case. Taylor *et al.* (34) treated 26 patients who had advanced neoplastic diseases with cortisone acetate or ACTH and were able to confirm the finding of regressions of lymphomatous tumors observed earlier; most of the patients manifested striking temporary improvement in their general condition with lessening of fever, when present, increased appetite, and improved strength and sense of well-being, but no control of the carcinoma was observed.

METHODS

Bilateral adrenalectomy was carried out on eighteen patients with the following neoplasms: prostate, seven cases; breast, seven; miscellaneous cancers, four. All the patients had far advanced neoplasms with extensive metastases.

The gonads of all the patients with mammary or prostatic cancers had been excised prior to adrenalectomy except in one woman who was in the postmenopausal state. All the prostatic cases had had a clinical remission induced by orchietomy with a subsequent relapse; all had been treated in addition with estrogenic substances, mostly diethylstilbestrol, for long periods. These patients have been observed for 4–9 months after adrenalectomy. The miscellaneous cancers were squamous carcinoma of the urethra, melanosarcoma, chorionic epithelioma, and an undifferentiated carcinoma, presumably of pulmonary origin. These patients were studied over periods of 1–3 months after adrenal excision.

We have published (17) the medical and surgical methods involved in one-stage bilateral adrenalectomy in man and maintenance of these patients by medicines. These technics were followed precisely in this series. No substances with hormonal activity were administered except cortisone acetate and desoxycorticosterone acetate (DOCA).

The total protein content of the least thermo-coagulable percentage of serum (16, 18) was de-

termined twice each week. Acid and alkaline phosphatases were measured by the method of King and Armstrong (24); glucose tolerance and insulin tolerance (9) and the water diuresis test (26) were determined pre- and post-operatively in all cases.

RESULTS

Metabolic and clinical status of the adrenal-less man.—There were two post-operative deaths in this series of eighteen adrenalectomized patients with cancer. However, bilateral adrenalectomy has now been carried out by us for one or another reason in 29 consecutive cases without operative fatality.

Following the rather large replacement doses of cortisone acetate and DOCA required to insure the prevention of adrenal insufficiency during and after adrenalectomy, the patient within a week was placed on a hormonal substitution program which in most cases proved to be the future maintenance regimen. Criteria for adequate substitution were the prevention of any sign or symptom of adrenal insufficiency. The maintenance of electrolyte and carbohydrate balance and of adequate blood pressure without orthostatic hypotension were the best indicators.

Cortisone has made possible this satisfactory replacement regimen. In our experience 25 mg. of cortisone acetate by mouth twice daily and the oral ingestion of 3 gm. of sodium chloride in most cases gave excellent results. Some of our patients have been maintained on as low as 12.5 mg. cortisone acetate twice a day with 3 gm. of salt, while other patients have required 2–4 mg. of DOCA daily in addition to cortisone acetate and salt to prevent orthostatic hypotension. The orthostatic hypotension occasionally seen was not corrected by augmenting the sodium chloride intake or even raising cortisone acetate to above 75 mg. a day. To increase the cortisone acetate above 50 mg. a day does not seem wise, for at these levels the protein catabolic effect becomes too predominant. The majority of the cancer patients after operation have an excellent appetite and gain weight rapidly.

When the patient is on an adequate hormonal maintenance, the glucose tolerance test, insulin tolerance test, and water diuresis test are normal and similar to those in the pre-operative period. In two patients with diabetes mellitus there has been no significant change in the insulin requirement.

When maintained adequately, adrenalectomized patients have a healthy appearance, are not incapacitated, and they are able to engage in all their usual activities. Cutaneous pigmentation of the Addisonian type does not occur. Six of the pa-

tients, including four males and two females, had hot flushes, but these vasomotor changes disappeared within 3 months. The patients withstand well the common ordeals of life. Under severe emergencies, such as extreme heat and severe infections, signs of adrenal insufficiency develop occasionally, but these were easily eliminated by increasing the amount of cortisone acetate and DOCA.

On our hormonal maintenance schedule the total protein content and least thermocoagulable

ectomy. In five patients the hemoglobin concentration (Table 1) increased, and in three patients there was an increase in the total number of erythrocytes. In three patients there was an increase in the total protein concentration (Chart 1), and in four patients there was a decrease of the least coagulable percentage of serum.

A large increase of acid phosphatase in serum was present before adrenalectomy only in two patients; in both cases there was a significant decrease in the level of this enzyme (Chart 2), but

TABLE 1
WHOLE BLOOD AND BLOOD SERUM VALUES AFTER ADRENALECTOMY IN CANCER

Case		Days	Hemoglobin gm/100 ml	Erythrocytes ×10 ⁶ /c. mm	Total protein gm/100 ml	Least coagulable (per cent)	Serum phosphatases units/100 ml	
							acid	alkaline
PROSTATIC CANCER								
1. E.S.	Pre-operative		13	4.37	6.90	23	4.0	11.1
	Post-operative	251	12	3.82	7.47	20	6.9	11.6
2. C.F.	Pre-operative		13.4	4.19	6.40	26	18.9	26.2
	Post-operative	240	17.4	5.23	7.38	20	7.0	11.1
3. J.S.	Pre-operative		10.5	3.89	7.30	24	4.4	12.3
4. L.S.	Pre-operative		12.2	4.24	7.09	26	4.5	8.5
	Post-operative	47	13.5	4.12	6.31	25	3.4	4.6
5. W.M.	Pre-operative		11	3.16	6.13	30	92.8	30.6
	Post-operative	180	13	4.03	7.11	20	32.3	33.9
6. J.F.	Pre-operative		12.2	4.02	6.28	24	4.0	6.8
	Post-operative	158	13.3	4.13	7.13	18	3.0	7.0
7. G.H.	Pre-operative		8.0	3.26	6.92	32	4.3	22.5
	Post-operative	137	9.5	2.67	5.59	41	2.0	12.8
MAMMARY CANCER								
8. L.C.	Pre-operative		12.2	3.91	5.23	27	6.7	6.0
9. M.B.	Pre-operative		13	3.99	7.08	23	4.2	10.7
	Post-operative	168	13.5	4.13	5.99	24	6.4	12.6
10. R.B.	Pre-operative		11.5	4.0	6.22	28	0.8	7.2
	Post-operative	19	13.0	4.4	6.12	38	2.6	6.3
11. J.B.	Pre-operative		10.6	3.47	5.77	29	4.4	5.6
	Post-operative	156	12.0	4.02	5.91	30	1.7	9.6
12. G.N.	Pre-operative		12.9	4.41	6.21	26	4.6	9.9
	Post-operative	155	11.5	3.80	6.38	22	6.0	8.1
13. N.C.	Pre-operative		15	5.04	6.00	22	3.4	4.6
	Post-operative	117	12.4	4.01	6.65	20	4.2	6.0

protein percentage of serum can reach normal values and the erythrocyte number and hemoglobin content of whole blood as well.

Adrenalectomy for cancer of the prostate.—In this series of seven patients there was one post-operative death (Case 3), leaving six effective cases of prostatic cancer. Another patient (Case 4) died of acute pulmonary edema 49 days after adrenalectomy.

In four of the patients the primary tumor was large and nodular; the neoplasm decreased appreciably, as determined by palpation in two of these men, while in two other cases it was unaffected. In two cases in this series the prostate was atrophic at the time of adrenalectomy because of previous anti-androgenic control, and the gland underwent no further change; both of these patients were incapacitated because of metastatic lesions.

All the patients gained weight after adrenal-

the decrease was not so precipitous as usually occurs in a previously untreated case of prostatic cancer after orchiectomy.

Perhaps the most striking observation has been the immediate and persistent relief of crippling pain in the bones. All the six patients in this series suffered from this complaint, and the pain was of such severity that all of them had been treated by morphine or codeine prior to adrenalectomy. In one patient (Case 7) there was no diminution of pain; in five patients the pain was completely relieved within 2 days after adrenalectomy, and the relief has persisted during the observational period. We are of the opinion that three of the six patients (Cases 2, 5, 6) in this series have had a clinical remission of the disease of considerable magnitude.

Adrenalectomy for mammary cancer.—This procedure was carried out on seven patients in this

category. There was one post-operative death (Case 8) leaving six effective cases. One patient (Case 10) died 23 days after adrenalectomy.

Among the six effective cases, the course of the disease was not influenced favorably in two patients (Cases 10, 11); in one case there was minor improvement (Case 9); some regression of the lesions was observed in three cases (Cases 12, 13, 14).

In Case 10 there were extensive pulmonary metastases, and the patient suffered from dyspnea; the lesions seemed to be completely unaffected by adrenalectomy. In Case 11, there were large sloughing ulcerations of cancers of each breast; following adrenalectomy the ulcerative process advanced rapidly.

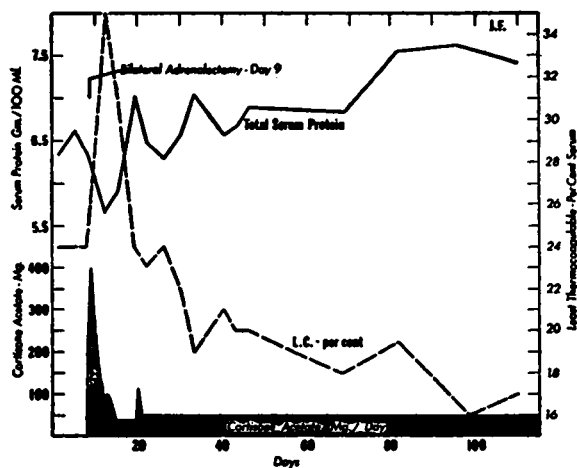


CHART 1.—Increase of total protein and decrease of least percentage of thermocoagulable protein of serum in a patient (Case 6) with metastatic cancer of the prostate. L.C.—Least thermocoagulable protein of serum.

One patient (Case 9) was moderately improved in that pain decreased and body weight increased after adrenalectomy and excision of the ovaries. The osseous metastases in this person had been advancing rapidly prior to adrenalectomy. Following removal of gonads and adrenals the advance seems to have been retarded, and there has been slight and partial recalcification of the lesions.

In two patients (Cases 12, 13), both with pulmonary metastases, there has been an increase in the total serum proteins together with a decrease in least coagulable percentage of serum and regression of pulmonary metastases as determined by radiography. In a man (Case 13) with evidence of intracranial metastases and large pulmonary metastases as well, there was a significant decrease (Figs. 1, 2) of both lesions within 3 weeks after adrenalectomy, and the gains are still maintained after 4 months.

In one woman (Case 14) there was a decrease (Figs. 3, 4) in the size of cutaneous metastases of mammary cancer in a post-mastectomy scar noted within 2 weeks after adrenalectomy and in a large tumor of the contralateral breast also. The regression was accompanied by evidence of involution as determined by cytologic methods on biopsy specimens (Figs. 5, 6).

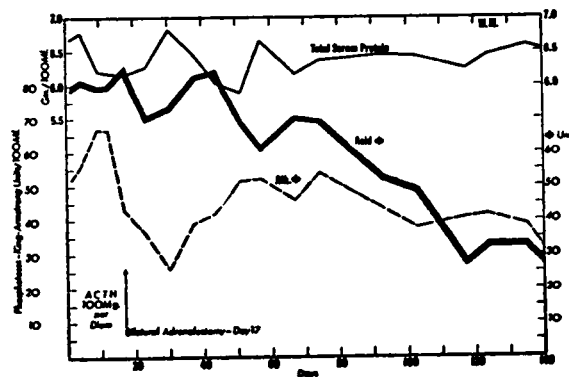


CHART 2.—Decrease of level of acid phosphatase of serum after adrenalectomy in a patient (Case 5) with metastatic cancer of the prostate.

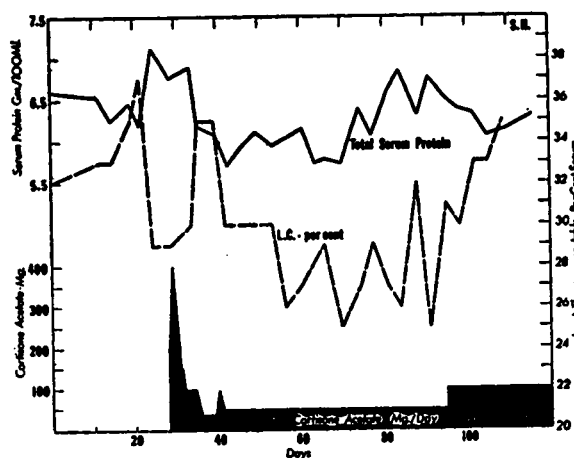


CHART 3.—Decrease of total protein and increase of least percentage of thermocoagulable protein of serum at cortisone acetate levels above 50 mg. daily in a patient with prostatic cancer.

Adrenalectomy for miscellaneous tumors.—There were four patients in this series with advanced cancer (squamous carcinoma, melanosaeroma, chorionic epithelioma, and an undifferentiated carcinoma) other than that of the breast and prostate. All had extensive metastases. They have been followed for 1–3 months after adrenalectomy. Adrenalectomy had no detectable effect in retarding the growth of these tumors. To the contrary, positive evidence was obtained of increase in size of the cancers in all of them.

Treatment of prostatic cancer by cortisone acetate and ACTH.—Pituitary adrenocorticotrophin (ACTH), 100 mg. daily for 14 days, was administered to three patients with advanced cancer of the prostate with metastases. Cortisone acetate was injected intramuscularly in four similar cases for periods up to 90 days, the dosage being exactly that used in the medical management of the patients subjected to bilateral adrenalectomy.

There was a considerable uniformity of response to ACTH and cortisone acetate. The findings of Taylor *et al.* (34) were confirmed in that the patients had an improved sense of well-being, an increase of appetite, but no decrease in the size or activity of the neoplasms. Bone pain was lessened by an estimated 50 per cent, but in no case was pain eliminated for more than 1 or 2 days. At a level of cortisone acetate, 100 mg. daily, or higher, there was in each person a decrease in total protein content and an increase in the least coagulable percentage of serum (Fig. 7).

Two of the patients who obtained partial relief of pain from administration of cortisone acetate were treated subsequently by adrenalectomy with complete relief of bone pain at maintenance levels of cortisone acetate of 37.5–50 mg. daily. In both of these patients there was detectable regression of the neoplasm after adrenalectomy.

DISCUSSION

In the earlier observations on the effect of adrenalectomy on neoplastic growth, a retardation of the rate of growth of some tumors had been reported. It is impossible to prove in any given single case that the growth of a human cancer has been merely slowed. However, regression is easy to demonstrate, and this occurs in some human neoplasms after adrenalectomy.

It is of interest that bilateral adrenalectomy can induce regression of certain malignant tumors and yet is unable to influence favorably other neoplasms having the same site of origin. Evidently the functional characteristics of neoplasms vary greatly.

It should be pointed out that in this small series of patients only prostatic and mammary carcinomas, and not all of them, underwent some regression after adrenalectomy. The "miscellaneous tumors"—squamous carcinoma, melanoma, chorionic epithelioma, and an undifferentiated carcinoma—were not affected. Now it is established that sex hormones of various kinds increase the activity or cause regression of certain far advanced tumors of the prostate (19) and the male (8) and female mammary glands (1, 11). The cases in which adrenalectomy induced re-

gression comprise tumors which already are known to be influenced in an important manner by sex hormones.

The mechanism whereby regression of some tumors occurs after adrenalectomy is not clearly established, largely because of uncertainty about normal adrenal function. For instance, there is no general agreement concerning what hormones the normal adrenal produces, in what quantity, or whether their number is few or many. We have shown (17) that the syndromes resulting from hyperfunctioning adrenal cortical tumors can be explained on the basis of androgenic, estrogenic, or corticoid effects, sometimes alone and other times in varying combinations and proportions.

Since regressions occur after adrenalectomy with maintenance of the patient on cortisone acetate, it may be inferred that steroids of this type are not responsible for continuing functional activity of the neoplasm. It is most reasonable to assume that the regressions are due at least in part to elimination of critical amounts of sex hormones. It must be pointed out, however, that adrenalectomy seems to have a nonspecific effect in retarding growth of several transplantable tumors of rodents, and this phenomenon may be partially operative in prostatic and mammary cancers.

It is known that the anti-androgenic treatment of prostatic cancer through estrogen administration or orchiectomy has three effects on prostatic cancer: (a) No retardation of the growth rate occurs in a small percentage of patients; (b) Extensive regression of primary and metastatic lesions is observed in something more than one-half of the cases; (c) Regression of the primary tumor with progression of the metastasis (14, 15). In category c, clearly there has been some control of the tumor by hormonal methods, but obviously the metastases are less susceptible to the control procedures than the primary tumor. We are of the opinion that adrenalectomy exerts more profound effects in this situation than in category a where there had been no retardation originally as a result of hormonal modification. However, as has been demonstrated, it was occasionally possible to induce regression of previously resistant primary prostatic cancer tissue.

Wilkins *et al.* (35) have shown that cortisone causes a decrease in the excretion of both 17-ketosteroids and "comb-growth" androgens in the urine of children with congenital adrenal hyperplasia. Our observations revealed that, although cortisone acetate produced a sense of euphoria, it did not significantly modify the course of prostatic cancer. It has been established that

the administration of cortisone acetate to the dog (5) is not followed by androgenic effects.

SUMMARY

Simultaneous bilateral adrenalectomy in man can now be done with comparative safety (29 consecutive cases without fatality.) The adrenal-less man on adequate hormonal substitution therapy presents the metabolic picture of excellent health, although adrenal insufficiency can develop rapidly when hormonal replacement is inadequate to meet the demands of the organism.

In four cases of advanced cancer of the prostate which became reactivated after previous anti-androgen control, some or all of the following effects were observed: relief of intractable bone pain, gain in body weight, reduction of considerably increased acid phosphatase levels and of the least percentage of thermocoagulable proteins, together with an increase of total protein content of serum, increased hemoglobin and erythrocyte content of whole blood, and shrinkage of the primary tumor. Two cases of prostatic cancer did not improve to any significant degree after adrenalectomy. The period of observation of these cases has been 4–9 months.

Of six cases of advanced mammary cancer with metastases, two cases were improved, one patient was moderately benefited, and there was no demonstrable evidence of regression in three cases.

In four advanced neoplasms, other than prostatic or mammary, adrenalectomy caused no detectable regression of the tumor.

CONCLUSION

Adrenalectomy with maintenance of the patient on cortisone acetate can cause some regression of far advanced mammary and prostatic cancers for which there has been no previous therapy available.

PROTOCOLS

PROSTATIC CANCER

Case 1.—E.S., age 63, atrophy of primary prostatic cancer with active osseous metastases. Orchiectomy May, 1947, with recurrence of pain in back and rectum in 1950. Complete relief of pain after adrenalectomy in February, 1951. Urinary retention October, 1951, treated by total perineal prostatectomy; no cytologic evidence of active cancer cells in excised prostate. Gained 8.4 kg. in 251 days.

Case 2.—C.F., age 47, extensive neoplastic involvement of prostate, bones, and lymph nodes. Orchiectomy, 1948. On admission, March, 1951, moribund with massive edema of both legs and external genitalia; large constricting peri-rectal and abdominal masses; uncontrollable bone pain; bed-ridden and emaciated. After adrenalectomy cessation of pain; shrinkage of neoplastic masses. Gained 16 kg. in 250 days.

Case 3.—J.S., age 59. Died 72 hours after operation.

Case 4.—L.S., age 62, active primary tumor and metastases.

Orchiectomy, 1946. For 2 years severe pain in legs requiring narcotics; urinary frequency and retention; large indurated neoplastic mass in seminal vesicle; extensive osseous metastasis. Following adrenalectomy no decrease in urinary retention; slight decrease in size of neoplastic mass; complete relief of pain. Died of pulmonary edema 49 days after adrenalectomy.

Case 5.—W.M., age 62, active primary prostatic neoplasm and osseous metastasis. Severe pain in back persisted after orchiectomy 60 days before. Prostate enlarged and indurated. Following adrenalectomy disappearance of pain, complete regression of prostatic enlargement as determined by palpation. Gained 13 kg. in 180 days.

Case 6.—J.F., age 59, active primary prostatic cancer with active osseous metastases. Orchiectomy April 3, 1950. In December, 1950, recurrence of severe sciatica poorly controlled by narcotics; osseous metastasis; prostate enlarged ++ and indurated; bed-ridden. Following adrenalectomy there was complete relief of pain and regression of the prostate to atrophic condition as determined by palpation. Returned to work. Gained 4 kg. in 158 days.

Case 7.—G.H., age 53, active primary prostatic cancer and osseous metastasis. Severe pain in shoulders, ribs, pelvis, and legs. Walnut-sized, hard nodule in prostate. No significant modification of neoplastic disease by adrenalectomy. Gained 4 kg. in 137 days.

MAMMARY CANCER

Case 8.—L.C., female, age 41. Died 48 hours after adrenalectomy.

Case 9.—M.B., female, age 47, extensive osteolytic metastases to pelvis and lymphedema of arm. Radical mastectomy in 1949; severe pain in pelvis and leg with osseous metastasis, November, 1950; rapid progression of the osteolytic lesion despite treatment with testosterone propionate and irradiation of pelvis. Following adrenalectomy partial relief of pain but continued advance of osseous lesions. Ovariectomy 56 days after adrenalectomy. Slight sclerosis of osteolytic lesions and considerable but not complete relief of pain. Gained 5 kg. in 168 days.

Case 10.—R.B., female, age 57, pulmonary metastases with dyspnea. No clinical improvement after adrenalectomy. Died 23 days after adrenalectomy.

Case 11.—J.B., female, age 40, large ulcerating mammary lesions with lymphedema of arm. Adrenalectomy followed by rapid advance of ulcerations.

Case 12.—G.N., female, age 43, hemothorax and metastasis to spine and pelvis. Radical mastectomy, 1945. Pain in spine with collapse of T₁₁ vertebra and extensive destructive lesions in pelvis in June, 1950. Treated with testosterone propionate with complete relief of symptoms until May, 1951, when massive accumulation of fluid in pleural cavity occurred requiring repeated thoracentesis. Right adrenalectomy and bilateral ovariectomy, 6/13/51; left adrenalectomy, 6/28/51. No recurrence of pleural fluid of magnitude sufficient to require tapping in 155 days (Figs. 7, 8). Complete relief of symptoms.

Case 13.—N.C., male, age 53, intracranial and pulmonary metastasis. Radical mastectomy, May, 1948. In June, 1950, metastases found in routine chest roentgenogram. Bilateral orchiectomy, 11/25/50, followed by further progression of pulmonary lesions. For 3 months, anorexia and vomiting; for 3 weeks, diplopia. Adrenalectomy was followed by disappearance of neurologic signs and double vision. Regression of pulmonary lesions on x-ray examination 39 days (Figs. 1, 2) after operation. Gained 10 kg. in 117 days.

Case 14.—L.M., female, age 65. Carcinoma of right breast with cutaneous metastases in scar of left radical mastectomy (12/2/48). A large indurated mass was found in the right breast with extensive, red infiltrations in mastectomy scar. Within

4 weeks after adrenalectomy flattening and pallor of cutaneous lesion (Figs. 3, 4) and decrease in size of unoperated tumor in right breast.

MISCELLANEOUS CANCERS

Case 15.—A.K., male, age 58. An extensive squamous carcinoma of the urethra with metastasis to lymph glands of both inguinal regions and the right tibia was not benefited by bilateral adrenalectomy. Died 93 days after operation.

Case 16.—M.S., female, age 53. A very widely spread melanosis with extensive pulmonary metastases was not improved after adrenalectomy. A great increase in size of pulmonary metastases was observed in roentgenograms made 4 weeks after operation.

Case 17.—J.S., male, age 41. Very large bilateral pulmonary metastases from a chorionic epithelioma of the testis was not affected favorably by bilateral adrenalectomy within 4 weeks after adrenalectomy.

Case 18.—M.N., female, age 22. An extensive undifferentiated carcinoma involving the right lung and left cervical lymph nodes continued to grow rapidly 4 weeks after adrenalectomy.

REFERENCES

1. ADAIR, F. E., and HERRMAN, J. B. The Use of Testosterone Propionate in the Treatment of Advanced Carcinoma of the Breast. *Ann. Surg.*, **123**:1023-35, 1946.
2. BISCHOFF, F., and MAXWELL, L. C. Hormones in Cancer. V. The Effect of Glandular Extirpation upon the Growth of Transplantable Tumors. *J. Pharm. & Exper. Therap.*, **46**:51-57, 1932.
3. BRZUSTOWICZ, R. J.; SVIEN, H. J.; BENNETT, W. A.; and HIGGINS, G. M. The Effect of Cortisone on the Growth of Transplanted Ependymomas in Mice. *Proc. Staff Meetings Mayo Clinic*, **26**:121-23, 1951.
4. COX, H. T. Adrenalectomy and Prostatic Cancer: Report of Three Cases. *Lancet*, **2**:425-26, 1947.
5. EBERSOLE, C. M., and HUGGINS, C. Effect of Cortisone Acetate on Prostatic Secretion in the Dog. Unpublished observations.
6. ELIEL, L. P., and PEARSON, O. H. The Clinical and Physiological Effects of Adrenocorticotrophic Hormone and Cortisone Acetate in Patients with Neoplastic Disease. *New York State J. Med.*, **51**:1839-43, 1951.
7. EMERSON, G. A.; WURTZ, E.; and ZANETTI, M. E. Regression of Lymphosarcoma Transplants Following the Administration of Cortisone to Riboflavin-deficient Mice. *Fed. Proc.*, **9**:357-58, 1950.
8. FARROW, J. H., and ADAIR, F. E. Effect of Orchidectomy on Skeletal Metastases from Cancer of the Male Breast. *Science*, **95**:654, 1942.
9. FRASER, R. W.; ALBRIGHT, F.; and SMITH, P. H. The Value of the Glucose Tolerance Test, the Insulin Tolerance Test, and Glucose-Insulin Tolerance Test in the Diagnosis of Endocrinologic Disorders of Glucose Metabolism. *J. Clin. Endocrinol.*, **1**:297-306, 1941.
10. FUNK, C.; TOMASHEFSKY, P.; SOUKUP, R.; and EHRlich, A. The Effect of Hormonal Factors and the Removal of Certain Organs upon the Growth of a Transplanted Rat Tumour. *Brit. J. Cancer*, **5**:280-87, 1951.
11. HADDOW, A.; WATKINSON, J. M.; PATERSON, E.; and KOLLER, P. C. Influence of Synthetic Oestrogens upon Advanced Malignant Disease. *Brit. M. J.*, **2**:393-98, 1944.
12. HEILMAN, F. R., and KENDALL, E. C. The Influence of 11-Dehydro-17-hydroxycorticosterone (Compound E) on the Growth of a Malignant Tumor in the Mouse. *Endocrinology*, **34**:416-20, 1944.
13. HIGGINS, G. M.; WOODS, K. A.; and BENNETT, W. A. The Influence of Cortisone (Compound E) upon the Growth of a Transplanted Rhabdomyosarcoma in C5H Mice. *Cancer Research*, **10**:203, 1950.
14. HUGGINS, C. Effect of Orchiectomy and Irradiation on Cancer of the Prostate. *Ann. Surg.*, **115**:1192-1200, 1942.
15. ———. Prostatic Cancer Treated by Orchiectomy: The Five Year Results. *J.A.M.A.*, **131**:576-81, 1946.
16. HUGGINS, C., and BAKER, R. Use of Serum Proteins in Measuring Activity of Prostatic Cancer. *Cancer Research*, **11**:428-31, 1951.
17. HUGGINS, C., and BERGENSTAL, D. M. Surgery of the Adrenals. *J.A.M.A.*, **147**:101-6, 1951.
18. HUGGINS, C.; CLEVELAND, A. S.; and JENSEN, E. V. Thermal Coagulation of Serum in Diagnosis. *J.A.M.A.*, **143**:11-15, 1950.
19. HUGGINS, C., and HODGES, C. V. Studies on Prostatic Cancer. I. The Effect of Castration, of Estrogen and of Androgen Injection on Serum Phosphatases in Metastatic Carcinoma of the Prostate. *Cancer Research*, **1**:293-97, 1941.
20. HUGGINS, C., and SCOTT, W. W. Bilateral Adrenalectomy in Prostatic Cancer: Clinical Features and Urinary Excretion of 17-Ketosteroids and Estrogen. *Ann. Surg.*, **123**:1031-41, 1945.
21. INGLE, D. J., and BAKER, B. L. The Effect of Adrenalectomy in the Rat upon the Rate of Growth of Transplantable Tumors. *Endocrinology*, **48**:313-15, 1951.
22. INGLE, D. J.; PRESTRUD, M. C.; and RICE, K. L. The Effect of Cortisone Acetate upon the Growth of the Walker Rat Carcinoma and upon Urinary Non-Protein Nitrogen, Sodium, Chloride and Potassium. *Endocrinology*, **46**:510-13, 1950.
23. JOANNOVIC, D. G. Über das Wachstum der transplantablen Mäusetumoren in kastrierten und in epinephrektomierten Tieren. *Beitr. path. Anat.*, **62**:194-203, 1916.
24. KING, E. J., and ARMSTRONG, A. R. Convenient Methods for Determining Serum and Bile Phosphatase Activity. *Canad. M. A. J.*, **31**:376-81, 1934.
25. LAW, L. W.; BUNKER, JR., L. E.; and NORRIS, B. A. Effect of Gonadectomy and Adrenalectomy on the Appearance and Incidence of Spontaneous Lymphoid Leukemia in C58 Mice. *J. Nat. Cancer Inst.*, **8**:157-59, 1947.
26. LEVY, M. S.; POWER, M. H.; and KEPLER, E. J. The Specificity of the "Water Test" as a Diagnostic Procedure in Addison's Disease. *J. Clin. Endocrinol.*, **6**:607-32, 1946.
27. MURPHY, J. B., and STURM, E. The Adrenals and Susceptibility to Transplanted Leukemia of Rats. *Science*, **98**:568, 1943.
28. PEARSON, O. H.; ELIEL, L. P.; RAWSON, R. W.; DOBBINER, K.; and RHOADS, C. P. ACTH- and Cortisone-Induced Regression of Lymphoid Tumors in Man. A Preliminary Report. *Cancer*, **2**:943-45, 1949.
29. POSTLETHWAIT, R. W.; MOSELEY, V.; MCKEE, K. T.; MURDOCH, J. H.; and McCORD, W. M. ACTH and Cortisone in Advanced Carcinoma of the Digestive Tract. *Cancer*, **4**:984-87, 1951.
30. ROFFO, A. H. L'influence de la capsule surrénale sur le développement des tumeurs chez les animaux privés de cette capsule et chez ceux traités avec des produits capsulaires. *Néoplasmes*, **9**:338-50, 1930.
31. SPIES, T. D.; STONE, R. E.; LOPEZ, G. G.; MILANES, F.; TOCA, R. L.; and REBOREDO, A. Response to Adrenocorticotrophic Hormone and Cortisone in Persons with Carcinoma, Leukaemia and Lymphosarcoma. *Lancet*, **2**:241-44, 1950.
32. STURM, E., and MURPHY, J. B. The Effect of Adrenalectomy on the Susceptibility of Rats to a Transplantable Leukemia. *Cancer Research*, **4**:334-88, 1944.

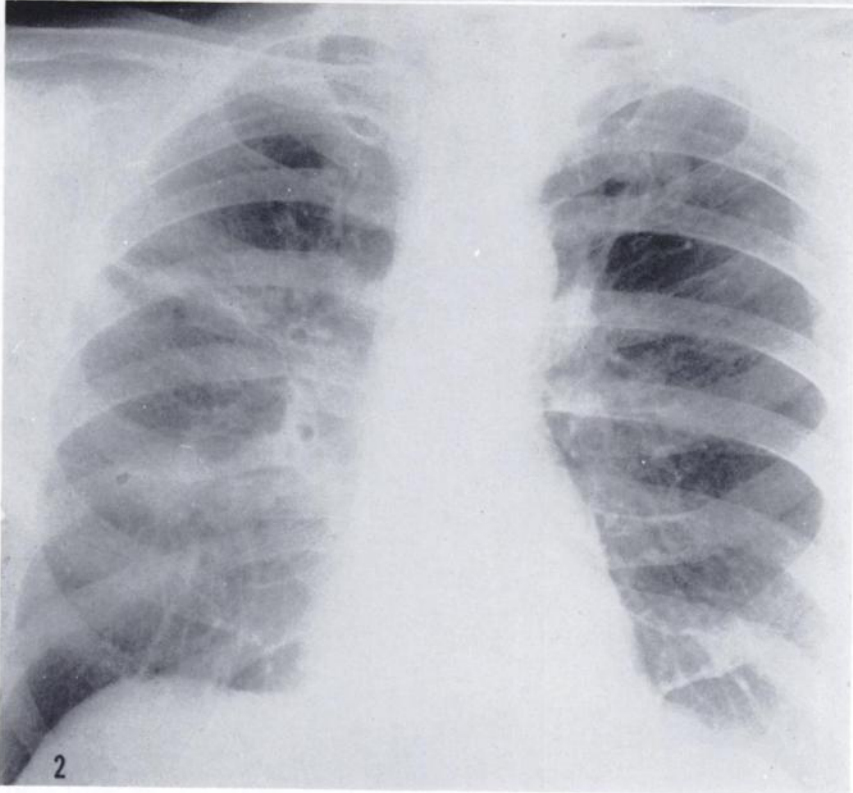
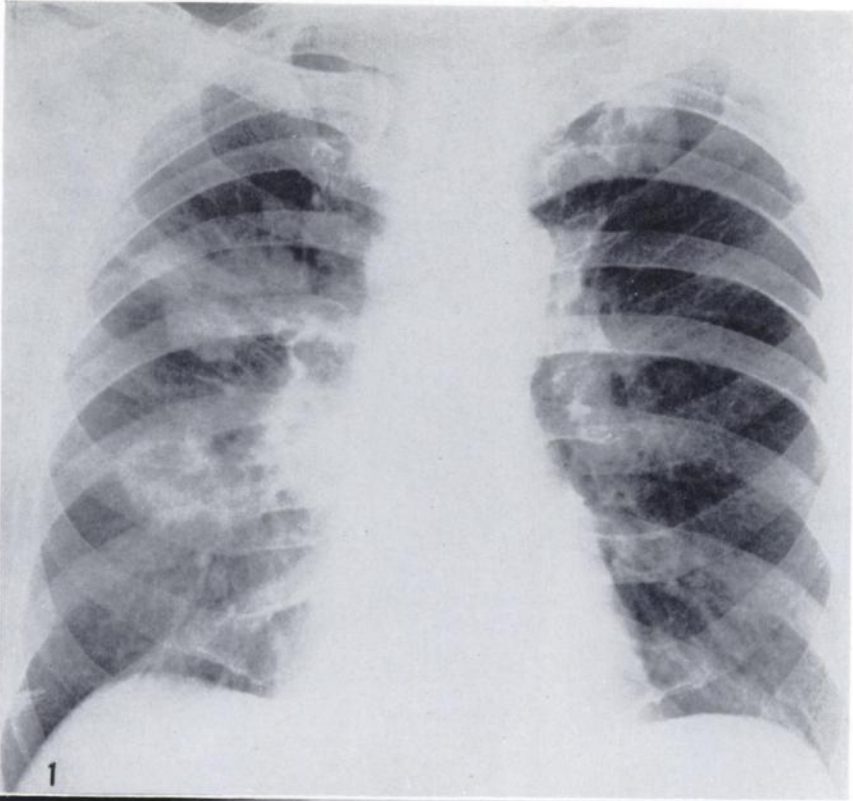


FIG. 1.—Metastases to both lungs from mammary cancer in a male (Case 13) before adrenalectomy.

FIG. 2.—Roentgenogram of chest of a male with mammary cancer (Case 13) 39 days after adrenalectomy.

FIG. 3.—Recurrent carcinoma in a mastectomy scar in a woman (Case 14) before adrenalectomy.

FIG. 4.—Appearance of mastectomy scar (Case 14) 40 days after adrenalectomy.

FIG. 5.—Biopsy from dermal plaque of recurrent mammary cancer in a mastectomy scar (cf. Fig. 3) showing adenocarcinoma. (Dr. E. M. Humphreys.) $\times 475$.

FIG. 6.—Biopsy from dermal plaque of recurrent mammary cancer in a mastectomy scar (cf. Fig. 4) 35 days after adrenalectomy showing an abundance of cancer cells which are shrunken with darkly stained nuclei. (Dr. E. M. Humphreys.) $\times 475$.

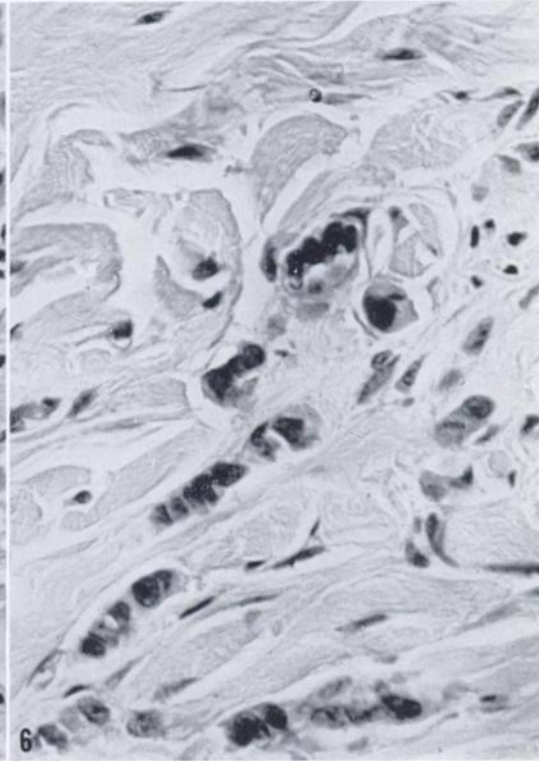
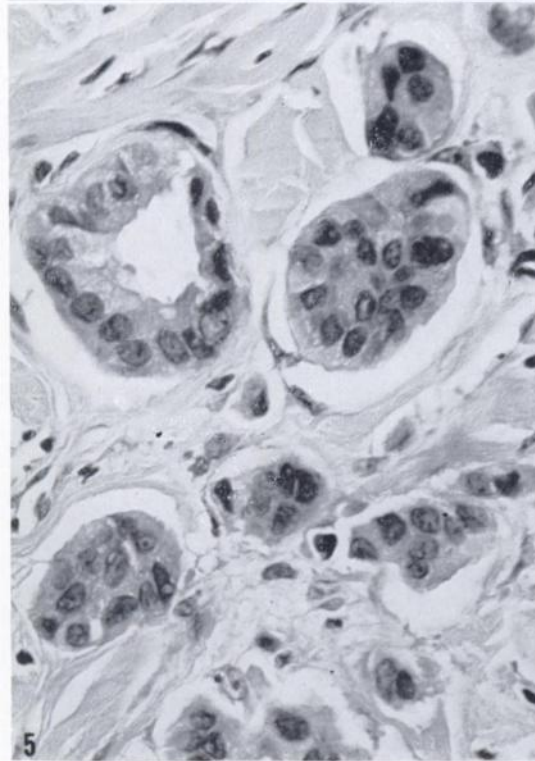
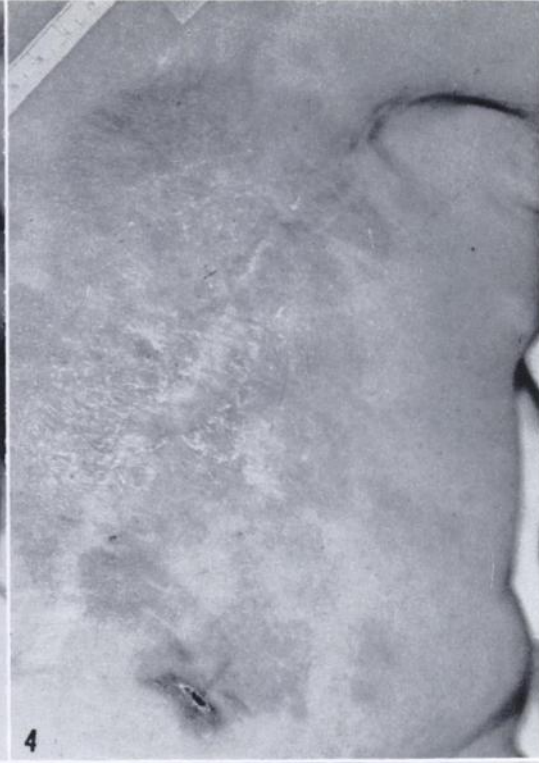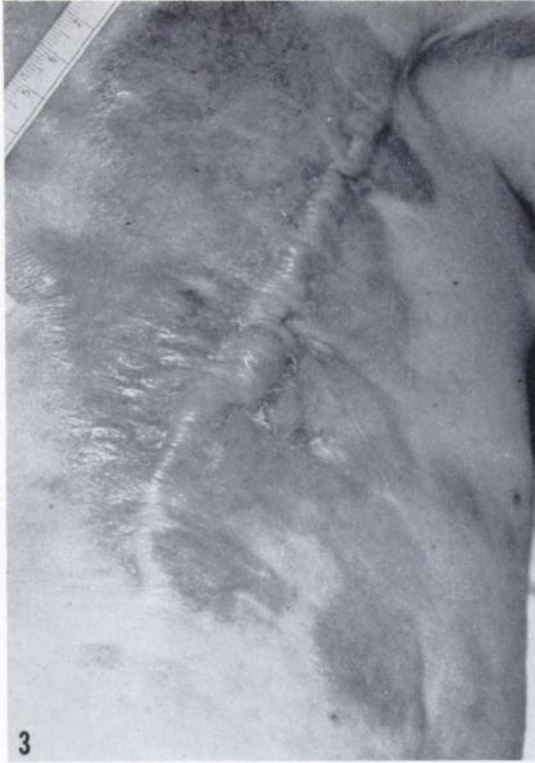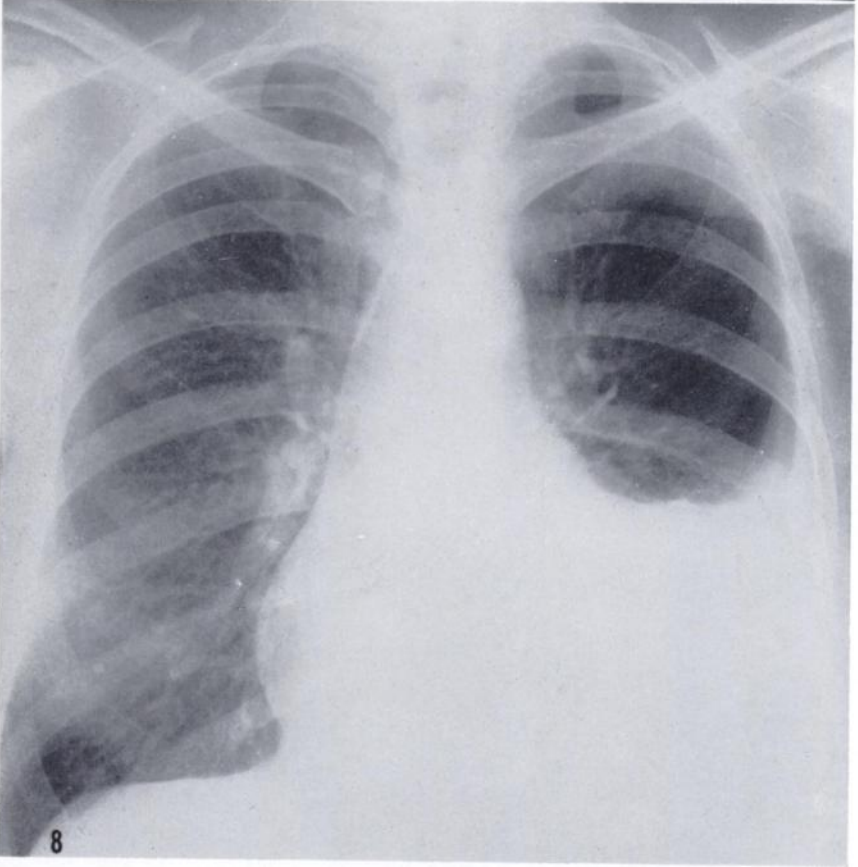
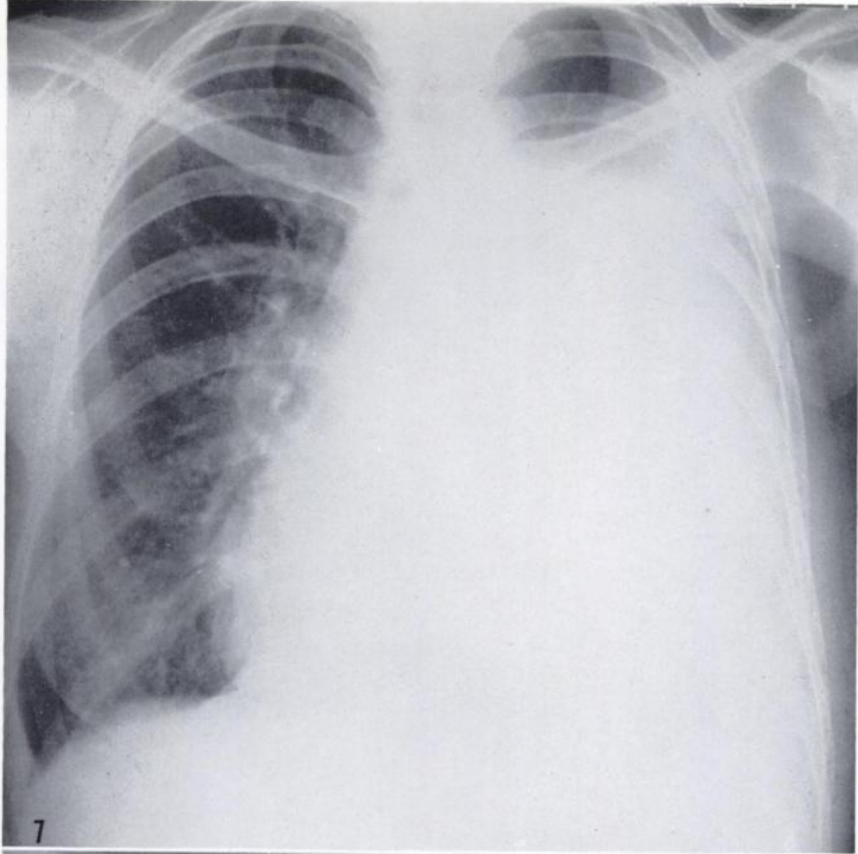


FIG. 7.—Metastatic carcinoma of the breast causing hemothorax in a woman (Case 12) before adrenalectomy.

FIG. 8.—Roentgenogram of the chest of a woman with metastatic mammary cancer (Case 12) 116 days after adrenalectomy. Thoracentesis has not been done since adrenalectomy.



33. SUGIURA, K.; STOCK, C. C.; DOBRINER, K.; and RHOADS, C. P. The Effect of Cortisone and Other Steroids on Experimental Tumors. *Cancer Research*, **10**:244-45, 1950.
34. TAYLOR, S. G., III; AYER, J. P.; and MORRIS, R. S. JR. Cortical Steroids in Treatment of Cancer. Observations on Effects of Pituitary Adrenocorticotropic Hormone (ACTH) and Cortisone in Far Advanced Cases. *J.A.M.A.*, **144**:1058-64, 1950.
35. WILKINS, L.; LEWIS, R. A.; KLEIN, R.; GARDNER, L. I.; CRIGLER, J. F.; ROSENBERG, E.; and MIGEON, C. J. Treatment of Congenital Adrenal Hyperplasia with Cortisone. *J. Clin. Endocrinol.*, **11**:1-25, 1951.