

# Inhibition of Osteoblastogenesis and Promotion of Apoptosis of Osteoblasts and Osteocytes by Glucocorticoids

## Potential Mechanisms of Their Deleterious Effects on Bone

Robert S. Weinstein, Robert L. Jilka, A. Michael Parfitt, and Stavros C. Manolagas

Division of Endocrinology/Metabolism, Center for Osteoporosis and Metabolic Bone Diseases, University of Arkansas for Medical Sciences, and the McClellan Veterans Affairs Medical Center GRECC, Little Rock, Arkansas 72205

### Abstract

Glucocorticoid-induced bone disease is characterized by decreased bone formation and in situ death of isolated segments of bone (osteonecrosis) suggesting that glucocorticoid excess, the third most common cause of osteoporosis, may affect the birth or death rate of bone cells, thus reducing their numbers. To test this hypothesis, we administered prednisolone to 7-mo-old mice for 27 d and found decreased bone density, serum osteocalcin, and cancellous bone area along with trabecular narrowing. These changes were accompanied by diminished bone formation and turnover, as determined by histomorphometric analysis of tetracycline-labeled vertebrae, and impaired osteoblastogenesis and osteoclastogenesis, as determined by ex vivo bone marrow cell cultures. In addition, the mice exhibited a threefold increase in osteoblast apoptosis in vertebrae and showed apoptosis in 28% of the osteocytes in metaphyseal cortical bone. As in mice, an increase in osteoblast and osteocyte apoptosis was documented in patients with glucocorticoid-induced osteoporosis. Decreased production of osteoclasts explains the reduction in bone turnover, whereas decreased production and apoptosis of osteoblasts would account for the decline in bone formation and trabecular width. Furthermore, accumulation of apoptotic osteocytes may contribute to osteonecrosis. These findings provide evidence that glucocorticoid-induced bone disease arises from changes in the numbers of bone cells. (*J. Clin. Invest.* 1998; 102:274–282.) Key words: bone marrow cells • remodeling • bone formation • osteoclasts • osteoporosis

### Introduction

The adverse effects of hypercortisolism on bone have been recognized for more than 60 yr (1), but the precise cellular and molecular basis of these changes has remained elusive. Today, the iatrogenic form of the disease has become far more common than Cushing's syndrome, and glucocorticoid-induced osteoporosis is now third in frequency after postmenopausal and senile osteoporosis (2).

---

Address correspondence to Robert S. Weinstein, M.D., Division of Endocrinology and Metabolism, Slot 587, University of Arkansas for Medical Sciences, 4301 W. Markham St., Little Rock, AR 72205-7199. Phone: 501-686-5130; FAX: 501-686-8148; E-mail: rweinstein@medlan.uams.edu

Received for publication 12 January 1998 and accepted in revised form 1 May 1998.

---

The Journal of Clinical Investigation  
Volume 102, Number 2, July 1998, 274–282  
<http://www.jci.org>

Bone loss due to glucocorticoid excess is diffuse, affecting both cortical and cancellous bone, but has a predilection for the axial skeleton. Therefore, spontaneous fractures of the vertebrae or ribs are often presenting manifestations of the disorder (3, 4). A cardinal feature of glucocorticoid-induced osteoporosis is decreased bone formation (5). In addition, patients receiving long-term glucocorticoid therapy sometimes develop collapse of the femoral head (osteonecrosis), but the mechanism underlying this is uncertain (6). Decreased bone formation and in situ death of isolated segments of the proximal femur suggest that glucocorticoid excess may alter the birth and death of bone cells. We have reported previously that defective osteoblastogenesis is linked to reduced bone formation and age-related osteopenia in the SAMP6 mouse (7). In addition to the relationship between aberrant osteoblast production and osteoporosis, we have shown recently that a significant proportion of osteoblasts undergoes apoptosis (8), which raises the possibility that the premature or more frequent occurrence of osteoblast apoptosis could contribute to incomplete repair of resorption cavities and loss of bone.

To test the hypothesis that glucocorticoid-induced bone disease is due to changes in the birth or death rate of bone cells, we used a murine model of glucocorticoid excess as well as bone biopsy specimens obtained from patients with glucocorticoid-induced osteoporosis. In this report, we demonstrate that glucocorticoid administration decreases bone formation rate and bone mineral density (BMD)<sup>1</sup> accompanied by defective osteoblastogenesis and osteoclastogenesis in the bone marrow and increases apoptosis of mature osteoblasts and osteocytes.

### Methods

**Animals.** Male Swiss Webster mice (Charles River Laboratories, Stone Ridge, NY) were electronically tagged (Biomedic Data System Inc., Maywood, NJ) and kept in plastic cages (3–5 animals per cage) under standard laboratory conditions with a 12-h dark, 12-h light cycle and a constant temperature of 20°C and humidity of 48%. All mice were fed a standard rodent diet (Agway RMH 3000, Arlington Heights, IL) containing 22% protein, 5% fat, 5% fiber, 6% ash, 3.5 kcal/g, 1.0 IU vitamin D<sub>3</sub>/g, 0.97% calcium, and 0.85% phosphorus with water ad libitum. The animals and food supply were weighed at 1-wk intervals throughout the experiment. Studies were approved by the UAMS Division of Laboratory and Animal Medicine.

**Glucocorticoid administration: experimental design.** BMD determinations were done at 2-wk intervals to identify the peak adult bone mass of the mice, which was reached between 5 and 6 mo of age (9). We used animals at peak bone mass to avoid obscuring the negative

---

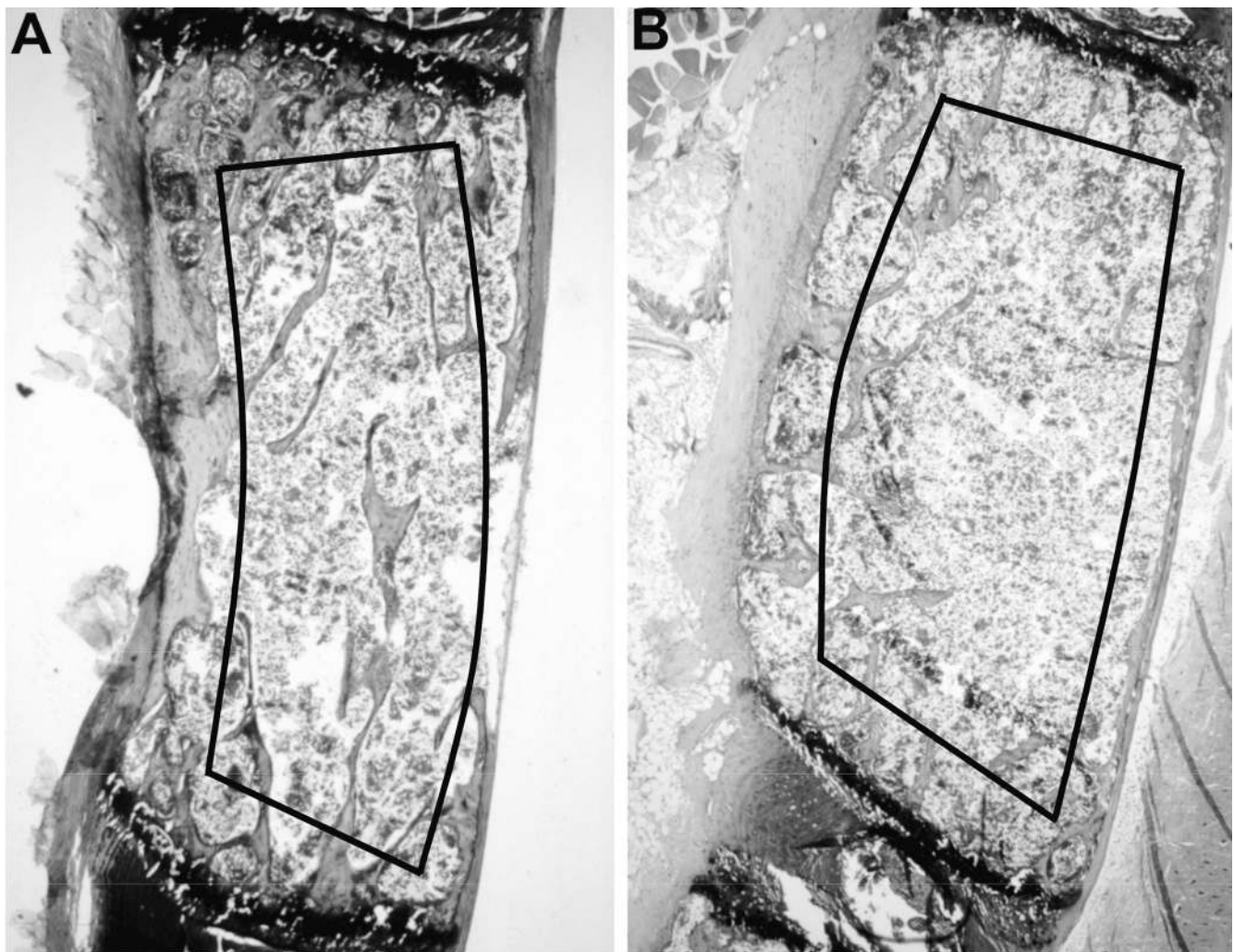
1. Abbreviations used in this paper: BMD, bone mineral density; CFU-F, CFU-fibroblast; CFU-OB, CFU-osteoblast; TRAPase, tartrate-resistant acid phosphatase; TUNEL, transferase-mediated biotin-dUTP nick end-labeling.

impact of glucocorticoid excess on BMD by the confounding effects of increased linear and radial growth. Before the experiment began, BMD measurements were repeated to allocate the animals into groups ( $n = 4-5$ ) with equivalent spinal density values. The mice (7 mo old) received placebo or prednisolone, a synthetic glucocorticoid analogue that does not require hepatic hydroxylation and has minimal mineralocorticoid activity, thus eliminating the need for potassium supplementation or sodium restriction (10, 11). It was found that implantation of pellets releasing 0.5 mg/kg/d of prednisolone (the no effect dose) did not decrease BMD (data not shown). Therefore, we used two doses, 0.7 (lower dose) and 2.1 mg/kg/d (higher dose), chosen from pilot studies to bracket the dose (1.4 mg/kg/d) that invariably causes loss of bone density. These doses were administered for 27 d by subcutaneous implantation of slow-release pellets (Innovative Research of America, Sarasota, FL). BMD measurements were obtained at the beginning of the experiment and 27 d after implantation. For dynamic histomorphometric measurements, tetracycline HCl (30 mg/kg body wt) was given intraperitoneally 17 and 23 d after implantation. After 27 d, the mice were killed, serum and urine specimens were taken, bone marrow aspirates were obtained from the right femur for ex vivo marrow cell cultures, and the left femur and lumbar vertebrae were prepared for histomorphometric analysis.

Livers were examined for fatty infiltration as a sign of prednisolone toxicity. The weight of the seminal vesicles (mg/100 g body wt) was used as an index of the androgen status of the animals (12). To help interpret these measurements, a separate group of animals was orchidectomized ( $n = 5$ ).

**Bone densitometry.** Dual-energy x-ray absorptiometry (DEXA) was used to determine global (whole body minus the head), spinal, and hindquarters BMD in live mice (7, 9). The scans done at 27 d after pellet implantation were analyzed using the "Compare" technique, in which the evaluation is based on the exact positioning and region of interest placement of the baseline scan. Accuracy of the DEXA measurements was demonstrated by the strong linear relationship between ash weight and bone mineral content at each region (7). Over 18 mo, the coefficient of variation for the BMD of a plastic-embedded whole mouse skeleton was 3.0% ( $n = 146$ ).

**Serum and urine biochemical measurements.** Serum osteocalcin was measured by radioimmunoassay using a goat anti-murine osteocalcin and murine osteocalcin as tracer and standard (Biomedical Technologies, Stoughton, MA). Urinary free deoxypyridinoline excretion was determined by a microtiter competitive enzyme immunoassay (Pyrilinks-D; Metra Biosystems, Mountain View, CA) and was expressed as a ratio to the urinary creatinine.



**Figure 1.** Photomicrographs of the effects of prednisolone on murine vertebral cancellous bone. (A) Longitudinal, panoramic section from a mouse receiving placebo and (B) section from a mouse receiving prednisone. The histomorphometric reading area is outlined. Toluidine blue stain, original magnification  $\times 25$ .

**Bone histomorphometric analysis.** The distal femora and lumbar vertebrae were fixed in 4°C Millonig's phosphate-buffered 10% formalin, pH 7.4, embedded undecalcified in methyl methacrylate, and stained as described previously (7, 9, 13). The histomorphometric examination was done with a computer and digitizer tablet (version 3.00; OsteoMetrics Inc., Atlanta, GA) interfaced to a Zeiss Axio-scope (Carl Zeiss, Inc., Thornwood, NY) with a drawing tube attachment. All cancellous measurements were two-dimensional, confined to the secondary spongiosa, and made at a magnification of 400 (numerical aperture 0.75) (Fig. 1). The terminology and units used are those recommended by the Histomorphometry Nomenclature Committee of the American Society for Bone and Mineral Research (14). The trabecular width and osteoid width were measured directly. Trabecular spacing and number were calculated (15). Only tartrate-resistant acid phosphatase (TRAPase)-positive cells were included in the osteoclast perimeter. The rate of bone formation ( $\mu\text{m}^2/\mu\text{m}/\text{d}$ ) and turnover (%/d) were calculated as described previously (7).

**Detection and quantification of osteoblasts and osteoclasts in ex vivo bone marrow cultures.** One femur from each mouse was flushed with 5 ml of phenol red-free  $\alpha$ MEM (GIBCO BRL, Gaithersburg, MD) containing 10% FBS (Hyclone, Logan, UT) to obtain marrow cells. After the cells were rinsed and resuspended to obtain a single cell suspension, the nucleated cell count was determined using a Coulter Counter (Coulter Corp., Miami, FL). Cells from each animal were cultured separately.

The number of CFU-fibroblast (CFU-F) and CFU-osteoblast (CFU-OB) present in the bone marrow preparations was determined as described previously (16–18). Briefly, cells were seeded at  $1.5 \times 10^6$  per 10  $\text{cm}^2$  well for the determination of CFU-F number and maintained for 10 d in phenol red-free  $\alpha$ MEM containing 15% preselected FBS, 50  $\mu\text{M}$  ascorbic acid, and 10 mM  $\beta$ -glycerophosphate (Sigma Chemical Co., St. Louis, MO) with one-half of the medium replaced after 5 d. After fixation in neutral buffered formalin and staining with hematoxylin, colonies containing a minimum of 20 fibroblastoid cells were enumerated. Cells were seeded at  $2.5 \times 10^6$  cells per 10- $\text{cm}^2$  well for the determination of CFU-OB number and cultured for 25–28 d as described above for CFU-F. After fixation in 50% ethanol and 18% formaldehyde, cultures were stained using Von Kossa's method to visualize and enumerate colonies containing mineralized bone matrix.

Osteoclast formation in bone marrow cultures was assessed in replicate cultures (4–6 from each animal) maintained for 9 d in the presence of  $\alpha$ MEM, 10% FBS, and 10 nM  $1,25(\text{OH})_2\text{D}_3$  as described previously (7). In brief, marrow cells were cultured at  $1.5 \times 10^6$  per 2- $\text{cm}^2$  well on 13-mm round Thermanox disks and maintained for 8 d in the presence of 10% FBS in  $\alpha$ MEM supplemented with  $10^{-8}$  M  $1,25(\text{OH})_2\text{D}_3$  (provided by Dr. Milan Uskokovic, Hoffman-LaRoche, Nutley, NJ). At the end of the experiment, cells were processed for the autoradiographic detection of bound  $^{125}\text{I}$ -calcitonin ( $^{125}\text{I}$ -CT) and stained for TRAPase. Because many osteoclasts in murine bone possess only one nucleus (7), it is impossible to distinguish between pre-osteoclasts and mononuclear osteoclasts in ex vivo cultures of murine bone marrow cells. Therefore, mononucleated and multinucleated cells that both bind  $^{125}\text{I}$ -CT and express TRAPase were designated as osteoclastic cells. The number of osteoclasts formed in this assay is a reflection of the number of osteoclast progenitors present in the bone marrow aspirate and the number of stromal/osteoblastic support cells that form during the culture period.

The number of CFU-F colonies, CFU-OB colonies, and osteoclastic cells formed from the marrow cells of each animal was expressed as the number per femur, which was calculated by multiplying the number of colonies or osteoclasts obtained per  $10^6$  cells seeded at the initiation of the cultures by the total number of marrow cells obtained from the animal.

**Measurement of apoptosis in undecalcified bone sections.** Sections were mounted on silane-coated glass slides (Scientific Device Lab, Inc., Des Plaines, IL), deplasticized, and incubated in 10 mM citrate buffer, pH 7.6, in a microwave oven at 98°C for 5 min. Slides were

**Table I. BMD and Serum and Urine Biochemical Measurements in Prednisolone-treated Mice**

| Measurement  | Placebo         | 0.7 mg/kg/d       | 2.1 mg/kg/d              |
|--|-----------------|-------------------|--------------------------|
| Global BMD (% change)                                    | $-2.7 \pm 2.1$  | $-5.0 \pm 2.2^*$  | $-6.6 \pm 1.9^\ddagger$  |
| Spinal BMD (% change)                                    | $-3.1 \pm 3.0$  | $-6.8 \pm 3.2$    | $-8.7 \pm 3.5^*$         |
| Hindquarters BMD (% change)                              | $0.4 \pm 10.4$  | $-3.8 \pm 8.0$    | $-3.4 \pm 6.9$           |
| Osteocalcin ( $\mu\text{g}/\text{liter}$ )               | $93.8 \pm 11.5$ | $63.0 \pm 27.7^*$ | $46.4 \pm 13.8^\ddagger$ |
| Deoxypyridinoline ( $\mu\text{M}/\text{mM creatinine}$ ) | $78.3 \pm 9.3$  | $63.6 \pm 14.7$   | $81.5 \pm 11.3$          |

Data shown are the mean  $\pm$  SD from five to seven animals. \* $P < 0.05$  vs. placebo;  $^\ddagger P < 0.005$  vs. placebo.

then incubated with 0.5% pepsin for 30 min at 37°C. Apoptotic cells were detected by the TUNEL reaction (transferase-mediated biotin-dUTP nick end-labeling) using Klenow terminal deoxynucleotidyl transferase (Oncogene Research Products, Cambridge, MA) in sections counterstained with 1% methyl green. The TUNEL reaction was noted within cell nuclei and the cells whose nuclei were clearly brown from the peroxidase-labeled antidigoxigenin antibody instead of the blue-green from the methyl green were interpreted as positive. Plastic-embedded sections of weaned rat mammary tissue were used as a positive control. Negative controls were made by omitting the transferase. Morphological changes characteristic of apoptosis were examined carefully to minimize ambiguity regarding the interpretation of results. With these precautions, TUNEL has been unequivocally associated with apoptosis (19). In addition, TUNEL has been used with DNA fragmentation and immunohistochemical studies to demonstrate apoptosis of osteoblastic cells and osteoblasts both in vitro and in vivo (8, 20). Apoptosis was also assessed in transiliac bone biopsy specimens taken from 2 patients with glucocorticoid-induced osteoporosis (22 and 36 yr old, receiving 15–25 mg/d of prednisone for 3–6 yr) and from 12 age-, sex-, and race-matched controls (13). Two longitudinal sections were examined from each patient and control subject. Osteoblasts were identified as cuboidal cells lining the osteoid-covered trabecular perimeter (7, 9, 13). Osteocytes were identified inside lacunae in mineralized bone.

**Statistics.** We tested for differences in the bone densitometry values using the percent change in BMD from baseline. Dose-response relations were tested by one-way ANOVA. To further evaluate changes in bone histomorphometry, we also used Student's *t* test to assess for significant differences between group means, after testing for equivalence of variances and normal distribution of data. The significance of the relative frequency of apoptotic cells was determined with the  $\chi^2$  statistic.  $P < 0.05$  was considered significant (21).

**Table II. Food Intake, Body Weight, and Seminal Vesicle Weight in Prednisolone-treated Mice**

| Measurement                                   | Placebo         | 0.7 mg/kg/d    | 2.1 mg/kg/d    |
|---|-----------------|----------------|----------------|
| Food intake (g/d)                             | $3.4 \pm 0.6$   | $3.6 \pm 0.2$  | $3.7 \pm 0.4$  |
| Body weight (g)                               | $37.9 \pm 6.0$  | $33.8 \pm 4.3$ | $32.2 \pm 4.2$ |
| Seminal vesicle weight (mg/100 g body weight) | $74.6 \pm 14.6$ | $92.7 \pm 8.7$ | $83.1 \pm 6.9$ |

Data shown are the mean  $\pm$  SD. Seminal vesicle weight in a separate orchidectomized control group was  $11.3 \pm 3.1$  mg/100 g body wt,  $P < 0.001$  vs. treated mice.

Table III. Vertebral Cancellous Bone Histomorphometry in Swiss Webster Mice after 27 d of Prednisolone Administration

| Histomorphometric determination                            | Placebo   | 0.7 mg/kg/d            | 2.1 mg/kg/d            |
|--|-----------|------------------------|------------------------|
| Bone area/tissue area (%)                                  | 10.4±1.4  | 6.9±2.1                | 6.3±1.7 <sup>‡</sup>   |
| Trabecular width (μm)                                      | 48.0±2.4  | 48.6±4.3               | 37.1±4.4 <sup>‡</sup>  |
| Trabecular spacing (μm)                                    | 423±69    | 712±302                | 546±125                |
| Trabecular number (per mm)                                 | 1.66±0.66 | 1.44±0.47              | 1.77±0.33              |
| Osteoid area/bone area (%)                                 | 2.1±0.2   | 2.2±0.8                | 1.5±0.2 <sup>‡</sup>   |
| Osteoid perimeter/bone perimeter (%)                       | 15.1±2.1  | 15.8±5.1               | 9.9±1.1 <sup>‡</sup>   |
| Osteoid width (μm)   | 2.6±0.4   | 2.0±0.3                | 1.9±0.3 <sup>*</sup>   |
| Osteoblast perimeter/bone perimeter (%)                    | 1.2±0.9   | 2.2±0.2                | 0.5±0.4                |
| Osteoclast perimeter/bone perimeter (%)                    | 2.7±1.1   | 2.6±0.5                | 1.1±1.7                |
| Reversal perimeter/bone perimeter (%)                      | 2.5±2.3   | 3.2±2.2                | 7.2±1.1 <sup>‡</sup>   |
| Mineralizing perimeter/bone perimeter (%)                  | 12.9±0.5  | 13.9±5.6               | 9.5±2.5 <sup>*</sup>   |
| Mineral appositional rate (μm/d)                           | 1.23±0.11 | 0.96±0.11 <sup>*</sup> | 0.74±0.20 <sup>‡</sup> |
| Bone formation rate/bone perimeter (μm <sup>2</sup> /μm/d) | 0.15±0.02 | 0.13±0.04              | 0.07±0.03 <sup>‡</sup> |
| Bone turnover (%/d)  | 0.68±0.09 | 0.46±0.12 <sup>*</sup> | 0.24±0.11 <sup>‡</sup> |

Data shown are the mean±SD. There are four to five animals per group. \**P* < 0.05 vs. placebo; <sup>‡</sup>*P* < 0.01 vs. placebo.

## Results

**Demonstration of bone loss in mice receiving prednisolone.** In mice implanted with the higher dose of prednisolone, global and spinal BMD at 27 d were significantly lower than those found in the mice that were implanted with placebo pellets (Table I). The decrease in global BMD was dose dependent (*P* < 0.05). Demonstrating the expected propensity for the axial skeleton, glucocorticoid-induced loss of BMD was less conspicuous at the hindquarters. The level of serum osteocalcin, a marker of osteoblast activity, was decreased > 50% when compared with placebo, whereas urinary deoxypyridinoline excretion was not significantly different between the groups (Table I). These effects were not due to changes in food intake, body weight, or androgen status (Table II). In addition, hepatic fatty infiltration was absent.

**Effects of glucocorticoid administration on vertebral bone histomorphometry.** Consistent with the BMD results, in the animals receiving the higher dose there was a 40% decline in the vertebral cancellous bone area (Fig. 1) and a 23% decline in trabecular width (*P* < 0.01) (Table III). In both prednisolone groups, there was a trend toward increased trabecular

spacing and, in the lower dose group, decreased trabecular number, indicating that some trabecular profiles were entirely resorbed. In the higher dose group, osteoid area decreased by 29%, osteoid perimeter by 34%, and osteoid width by 27% (*P* < 0.01). A trend toward decreased osteoblast and osteoclast perimeters was found in the animals receiving the higher dose. However, there was a threefold increase in the empty erosion cavities (devoid of osteoclasts) or reversal perimeter. The tetracycline-based histomorphometry showed that prednisolone administration caused a 26% decrease in the mineralizing perimeter (*P* < 0.05). In addition, a dose-dependent decrease in the mineral appositional rate was noted (*P* < 0.05); this decline was 22% with the lower dose and 40% with the higher dose. Furthermore, there was a 53% decrease in the rate of bone formation with the higher dose (*P* < 0.01), which correlated with the vertebral cancellous bone area (*r* = 0.57, *P* < 0.05), indicating that the glucocorticoid-induced decreases in bone area were associated with a reduction in the rate of bone formation. Bone turnover, expressed as a percentage of the bone area per day, also decreased in a dose-dependent manner (*P* < 0.05).

**Effects of glucocorticoid administration on osteoblastogen-**

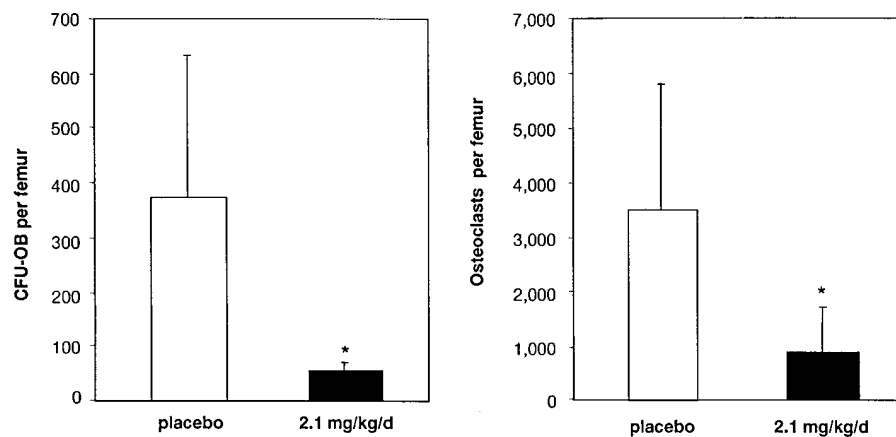
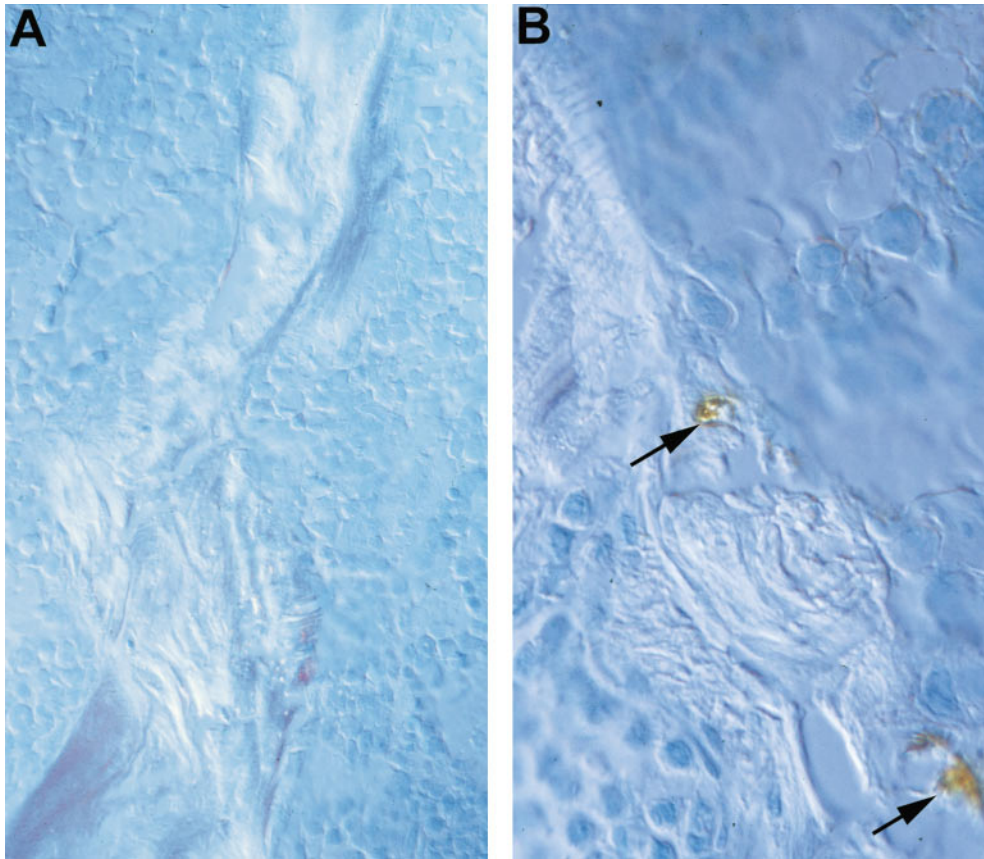


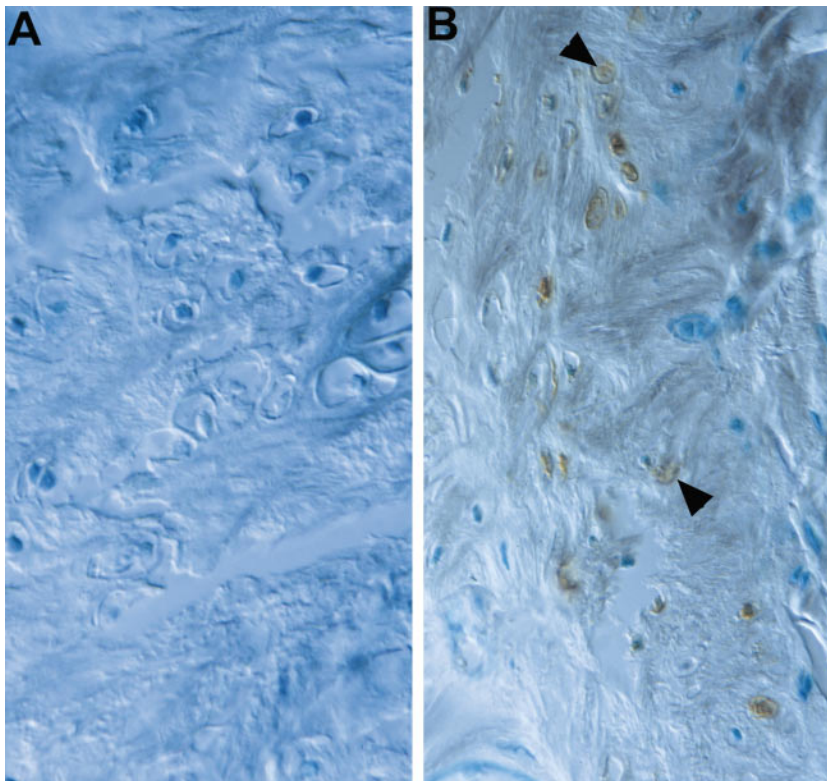
Figure 2. Quantification of CFU-OB and osteoclast progenitors formed in ex vivo bone marrow cell cultures. Marrow cells were obtained from the femurs of male mice after 27 d of exposure to placebo (white bars) or 2.1 mg/kg/d of prednisolone (black bars). Cells from each mouse were cultured separately as described in Methods.



**Figure 3.** Effect of prednisolone on murine osteoblast apoptosis. Osteoblasts were counted in undecalcified sections of cancellous bone from the vertebral secondary spongiosa. The placebo group is shown in *A* and the higher dose prednisolone group is shown in *B*. Apoptotic cells in this experiment were identified using TUNEL and morphometric features such as nuclear fragmentation and condensation of chromatin (*arrows*). Methyl green counterstain viewed with Nomarski differential interference microscopy, original magnification  $\times 400$ .

*esis and osteoclastogenesis.* In bone marrow cell cultures from the animals receiving the higher dose, there was no significant change in CFU-F colonies ( $1,250 \pm 374$  vs.  $698 \pm 104$ , NS). However, the number of CFU-OB colonies decreased by 86%

( $375 \pm 257$  SD vs.  $54 \pm 14$ ,  $P < 0.05$ ) and the number of osteoclastic cells formed in response to  $1,25(\text{OH})_2\text{D}_3$  in ex vivo marrow cultures decreased by 65% ( $1387 \pm 920$  vs.  $492 \pm 311$ ,  $P < 0.05$ ) (Fig. 2).



**Figure 4.** Effect of prednisolone on murine osteocyte apoptosis. The cells were counted in undecalcified sections of femoral metaphyseal cortical bone. The placebo group is shown in *A* and the higher dose prednisolone group is shown in *B*. Apoptotic osteocytes (*arrowheads*) are seen in close proximity to normal cells. Methyl green counterstain viewed with Nomarski differential interference microscopy, original magnification  $\times 630$ .

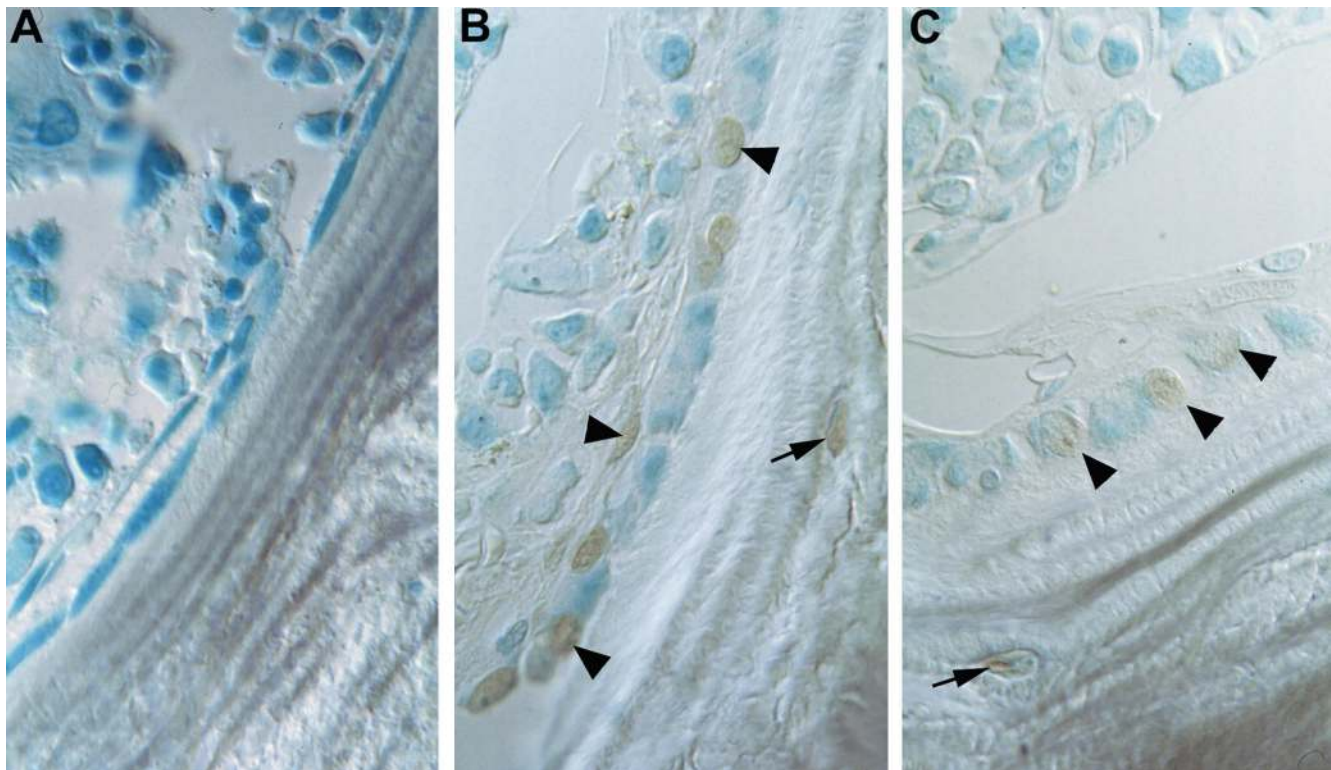
*Effects of glucocorticoid administration on apoptosis.* Counting a total of 973 osteoblasts, there was a threefold increase in osteoblast apoptosis in the vertebral cancellous bone of mice receiving the higher dose of prednisolone when compared with controls ( $2.03 \pm 0.34$  vs.  $0.66 \pm 0.07\%$ ,  $P < 0.05$ ). Morphological changes typical of apoptosis accompanied the TUNEL-positive osteoblasts and included sharply defined, condensed chromatin plastered against the nuclear membrane, nuclear fragmentation, and cell shrinkage (Fig. 3, A and B).

In addition, prednisolone caused the appearance of apoptotic osteocytes in cortical bone sections taken from femora (Fig. 4, A and B). Whereas none of the osteocytes exhibited apoptotic features in the control animals, 28% of 131 cortical osteocytes were apoptotic in the animals receiving the higher dose. Osteocyte apoptosis was restricted to small groups of cells in the center of the femoral metaphyseal cortex and were absent from vertebral cortical bone. The apoptotic osteocytes were identified in close proximity to normal osteocytes, in contrast to the large homogenous areas of dead and dying cells typical of cell necrosis. An increase in apoptotic hypertrophic chondrocytes and bone marrow cells was also noted in mice receiving either dose of prednisolone. Osteoclast apoptosis was not observed.

*Demonstration of apoptotic osteoblasts and osteocytes in patients with glucocorticoid-induced osteoporosis.* In transiliac bone biopsies taken from two patients, TUNEL-positive os-

teoblasts and osteocytes were clearly identified in both (Fig. 5, B and C) but were absent from specimens taken from 12 age-, sex-, and race-matched controls (Fig. 5A). As in our murine model, bone histomorphometry from these two patients showed the changes expected with chronic glucocorticoid therapy (5): reduced cancellous bone area (11.1 and 8.8%, normal is  $22.4 \pm 1.2$  SEM), decreased trabecular width (62 and  $118 \mu\text{m}$ , normal is  $161 \pm 9$ ), decreased osteoblast perimeter (2.1 and 2.3%, normal is  $7.6 \pm 0.4$ ), decreased osteoclast perimeter (0 and 0.4%, normal is  $0.9 \pm 0.2$ ), increased reversal perimeter (13.5 and 15.4%, normal is  $6.9 \pm 0.7$ ), and diminished bone formation rate ( $0.02$  and  $0.05 \mu\text{m}^2/\mu\text{m}/\text{d}$ , normal is  $0.095 \pm 0.012$ ). In the cancellous bone of these specimens,  $\sim 5\%$  of the osteocytes and 30% of the osteoblasts were apoptotic. Apoptosis of osteoclasts or cortical osteocytes was not observed. A transiliac bone biopsy represents a much smaller sample of the human skeleton than the murine femur and lumbar vertebrae represent of the mouse skeleton. Therefore, it is not surprising that the percentage of apoptotic osteoblasts and osteoclasts was different in the human and murine specimens.

*Early effects on bone resorption.* Finally, because of the evidence for decreased trabecular number, we investigated the possibility that glucocorticoids initially accelerate bone resorption in the mouse. To do this we examined the vertebral cancellous bone histology in an additional group of somewhat younger mice (5 mo old) after a 7-d administration of the higher dose of



**Figure 5.** Effect of chronic prednisone treatment on apoptosis in human bone. TUNEL-positive osteoblasts (arrowheads) and osteocytes (arrows) were absent from normal subjects (A) but were clearly identified in patients with prednisone-induced osteoporosis (B and C). Approximately 5% of the osteocytes and 30% of the osteoblasts were apoptotic. The photomicrographs are from transiliac bone biopsy specimens. Methyl green counterstain viewed with Nomarski differential interference microscopy, original magnification  $\times 630$ .

prednisolone or placebo ( $n = 5$ ). We found that whereas prednisolone caused a 59% decrease in the osteoblast perimeter ( $5.2\% \pm 1.5$  SD vs.  $2.1 \pm 1.1$ ,  $P < 0.005$ ), the osteoclast perimeter increased 96% ( $0.51\% \pm 0.34$  vs.  $1.00 \pm 0.41$ ,  $P < 0.05$ ).

## Discussion

Our choice of the mouse for these studies was based on our previous experience with its validity as a model of the bone loss associated with loss of sex steroids (9, 22) and with senescence (7), but we also found the mouse to have several advantages over previously used laboratory animals (Table IV). Only in the mouse does glucocorticoid administration consistently induce axial greater than appendicular bone loss without weight loss or hypogonadism, accompanied by histological indices of impaired osteoblast function, thus reproducing the major features of the human disease (2–5). Although the doses used in our studies were higher in relation to body weight than in humans, they were only mildly higher than the dose determined by serial bone densitometry to have no effect and were consistent with the much higher metabolic clearance of glucocorticoids and other compounds in small laboratory animals than in humans (35–37). Nonetheless, the similarity of the glucocorticoid-induced increases in apoptotic cells and bone histomorphometric features in mice and humans clearly indicates that our observations in the mouse cannot be due to pharmacological differences.

We examined the effects of glucocorticoids after 27 d, a period equivalent in the mouse to  $\sim 3$ –4 yr in humans. Thus, our findings represent long-term rather than acute effects. Although we found a significant correlation between the severity of the cancellous bone loss and the extent of reduction in bone formation, several other lines of evidence imply that some of the bone loss we observed was due to an early increase in bone resorption which had subsided by the time of examination. First, there was suggestive evidence of complete loss of some trabeculae (Table III). Second, based on the bone turnover measured in the placebo group, which must be close to the rate found in all the animals at the beginning of the study, even with total suppression of bone formation the initial rate of bone turnover could have accounted only for an exponential decline in cancellous bone area of 18%, whereas a 40% decrease was observed. Finally, we confirmed an early increase in osteoclast perimeter by histomorphometric examination of vertebral cancellous bone after 7 d of prednisolone administration.

By 27 d of prednisolone administration, bone resorption fell to or below normal, as indicated by the downward trend in

the osteoclast perimeter, normal urinary deoxypyridinoline excretion, and profound decrease in osteoclastogenesis. The persistent increase in erosion cavities devoid of osteoclasts, measured as the reversal perimeter, merely indicates delayed bone formation (38), and has been observed previously in glucocorticoid-treated patients (5, 39). Consequently, we will emphasize the relevance of our findings at 27 d to chronic, rather than short-term, glucocorticoid administration to humans.

We have demonstrated previously that vertebral cancellous bone in adult mice undergoes sequential, coupled bone remodeling that is qualitatively similar to that occurring in human bone (7, 9). Many of the changes in cellular, osteoid, and tetracycline-based histological indices induced by glucocorticoid administration can be accounted for by a reduction in the activation frequency of bone remodeling, the main determinant of the rate of bone turnover (40), which is an inevitable consequence of the substantial decrease in osteoclastogenesis that we observed. Although a reduction in bone turnover will not by itself cause bone loss, the decrease in trabecular width, which was the major structural change observed, is usually the result of incomplete cavity repair. This is, at least in part, due to inadequate osteoblast recruitment, either from diminished production or ineffective migration to the bone surface (40). The reduction in osteoblastogenesis was of sufficient magnitude to explain the decrease in bone formation rate, and would also have contributed to the inadequate osteoblast recruitment and consequent decline in trabecular width. Thus, the inhibitory effect of glucocorticoids on early bone cell progenitors in the bone marrow can account for many of the *in vivo* observations.

Our data also bear on recent ideas concerning the relationships between early osteoblast and osteoclast progenitors in the bone marrow. Although mature osteoclasts and osteoblasts are needed successively at each bone surface site that is being remodeled, these cells are needed simultaneously as the basic multicellular unit, which is the instrument of bone remodeling, progresses through or across the surface of bone (41). The necessary parallel production of executive cells is accomplished by signals that originate from early members of the stromal cell–osteoblast family, which support in various ways the production of mononuclear preosteoclasts in the bone marrow (42). Our demonstration of a marked reduction in the numbers of both CFU-OB and osteoclast progenitors derived from *ex vivo* bone marrow cell cultures makes it likely that glucocorticoid administration inhibits the proliferation and/or differentiation of the stromal cell–osteoblast family at an early stage, leading to a reduction in the number of mature, matrix-secreting osteoblasts as well as the osteoblastic cells

Table IV. Confounding Factors with Glucocorticoid Administration to Other Animals

| Animals                  | Factors   |
|--------------------------|---|
| Rats (23, 34)            | Paradoxical increase in cancellous bone mass,* decreased food intake and weight   |
| Rabbits and dogs (25–27) | Inconsistent changes in bone density and cancellous bone area, weight loss, hepatic fatty infiltration  |
| Ewes (28–30)             | Histological changes resemble glucocorticoid-treated patients but corresponding changes in bone density and cancellous bone area are inconsistent |

\*Glucocorticoids inhibit bone resorption and promote apoptosis in rat osteoclasts *in vitro* (31), whereas bone resorption is stimulated in neonatal mouse calvaria (32). An additional species difference is that glucocorticoids stimulate bone nodule formation from rat calvarial cells *in vitro* (33) but inhibit differentiation in a murine osteoblastic cell line (34).

that support osteoclast development. A direct inhibitory effect of glucocorticoids on osteoclast precursor proliferation is not excluded by our data, but would be less easy to reconcile with the finding of an early increase in the osteoclast perimeter.

It has long been known that some osteoblasts become osteocytes and some become lining cells, but these fates combined do not account for all the osteoblasts initially present. Although migration along or away from the bone surface is possible, death has always seemed the most likely alternative fate (43). Recently, we provided evidence for this possibility by demonstrating that osteoblasts in remodeling bone undergo apoptosis with a frequency sufficient to account for most or all of those missing (8). Based on the dynamic histomorphometry at the murine vertebral secondary spongiosa and a wall width of  $\sim 15 \mu\text{m}$  (7, 9, 14), we calculated the mean active life span of an osteoblast on cancellous bone by dividing wall width by the mineral appositional rate. From this calculation, we estimated that the mean active life span of a murine osteoblast is  $\sim 12$  d or 288 h. The prevalence of osteoblast apoptosis in this study was 0.0066 in the placebo group. We applied the following relationship:

$$t_{\text{Ap}}/288 = 0.0066/f_{\text{Ap}};$$

where  $t_{\text{Ap}}$  is the mean duration (in hours) of the DNA fragmentation phase of apoptosis that is detected by TUNEL, and  $f_{\text{Ap}}$  is the fraction of osteoblasts that undergoes apoptosis. Based on a value of  $t_{\text{Ap}}$  of  $\sim 3$  h, determined previously for regenerating liver (44), the corresponding value for  $f_{\text{Ap}}$  in the placebo group is 0.6. The calculation demonstrates that the low prevalence of apoptosis we observed in the placebo group is consistent with the conclusion drawn from studies of human bone that 50–70% of osteoblasts undergo apoptosis, and that only a minority become osteocytes or lining cells (43).

In the animals receiving the higher dose of prednisolone, the prevalence of apoptosis was 0.0203. With prednisolone administration, phagocytosis of the apoptotic cells would be suppressed and we estimated that  $t_{\text{Ap}}$  could be doubled (45). Wall width was reduced to  $\sim 8 \mu\text{m}$  and mineral appositional rate to  $0.74 \mu\text{m/d}$ , so that the active life span of an osteoblast is  $\sim 260$  h. In these circumstances, the corresponding value for  $f_{\text{Ap}}$  in the prednisolone group is 0.9. Although there is some uncertainty to the assumptions used for these estimates, the approach does help explain the data and disclose the devastating impact of glucocorticoid excess on osteoblast survival. The higher proportion of osteoblasts showing features of apoptosis in glucocorticoid-treated mice and human subjects could indicate no more than prolongation of the time needed for completion of the process, but we think it more likely that glucocorticoids induce apoptosis, either prematurely in cells already destined for this fate or in cells otherwise destined to become lining cells or osteocytes. In either case, the mean active life span of osteoblasts would be shortened and less bone formed. Thus, the demonstrated reduction in bone formation by glucocorticoids could be due to increased death as well as decreased birth of osteoblasts. Further support of this concept is given by the recent report of glucocorticoid-induced apoptosis of osteoblasts in calvariae of young mice given dexamethasone (46).

Osteocytes are long-lived but not immortal cells. In human rib cortical bone, their life span has been estimated at  $\sim 20$  yr (47); if bone remains unremodeled for a longer time, the osteocytes die, as revealed by empty lacunae and hypermineralized perilacunar bone, referred to as micropetrosis (48). Os-

teocyte death in cancellous bone, indicated by absence of lactic dehydrogenase activity, increases in prevalence with age in the upper femur but not in the vertebrae (49), probably because of the higher bone turnover in the spine. Empty lacunae and enzyme absence can reveal the fact but not the mode of death. Osteocyte apoptosis has been detected recently in human iliac cancellous bone and its prevalence was increased by pharmacological induction of estrogen deficiency (19). We have now demonstrated that chronic glucocorticoid administration, both to mice and to human patients, likewise increases the prevalence of osteocyte apoptosis. The proportion of apoptotic osteocytes was much higher than of osteoblasts, reflecting the unique unavailability of osteocytes for phagocytosis because of their anatomic isolation from scavenger cells, and the need for extensive degradation to small molecules to dispose of the cells through the narrow canaliculi. As a result, the process is prolonged and affected cells accumulate.

The contribution of osteocyte apoptosis to glucocorticoid-induced bone disease will remain uncertain until more is known about the function of these cells, but two possibilities merit discussion. First, the network of osteocytes probably participates in the detection of microdamage and the transmission of signals that lead to its repair by remodeling (50). Disruption of the network by osteocyte apoptosis could compromise this mechanism, leading to microdamage accumulation and increased bone fragility (51). Second, chronic glucocorticoid administration sometimes leads to so-called aseptic or avascular necrosis of bone, a painful and disabling complication (6). The name may be misleading, since it has not been demonstrated that the bone cells die by necrosis. Indeed, the cell swelling and tissue inflammation that characterize necrosis in soft tissues do not occur (6, 52). Glucocorticoid-induced osteocyte apoptosis, a cumulative and unreparable defect, would explain the correlation between total dose and incidence of avascular necrosis of bone (53) and its occurrence after glucocorticoid administration had ceased.

In conclusion, we have demonstrated that the mouse is a valid and informative model of glucocorticoid-induced bone disease, not confounded by weight loss or sex steroid deficiency, and that many of the effects of chronic glucocorticoid administration on bone can be explained by decreased birth of osteoblast and osteoclast precursors and increased apoptosis of mature osteoblasts and osteocytes.

*Note added in proof:* While our manuscript was in press, Reichardt et al. reported that glucocorticoid-induced apoptosis is mediated by a mechanism that requires the dimerization of the glucocorticoid receptor and direct binding of the receptor to GRE-response elements (1998. *Cell*. 93:531–541). Taken together with the development of synthetic glucocorticoids that exhibit antiinflammatory activity in vivo as potently as classical glucocorticoids, without requiring GR-DNA-binding and transactivation (1997. *Mol. Endocrinol.* 11: 1245–1255), the present demonstration of osteoblast and osteocyte apoptosis in animals and humans with glucocorticoid-induced osteoporosis predicts that these synthetic compounds will have bone sparing effects.

## Acknowledgments

The authors wish to acknowledge Julie Crawford, Frances Swain, Carman Young, James Kirchner, Randal Shelton, Sherry Rush, and Catherine Smith for their invaluable technical assistance in the conduct of these studies.



This work was supported by the National Institutes of Health (PO1AG13918 and RO1AR43003) and the Department of Veterans Affairs.

## References

1. Cushing, H. 1932. The basophil adenomas of the pituitary body and their clinical manifestations (pituitary basophilism). *Bull. Johns Hopkins Hosp.* 50: 137–195.
2. Lukert, B. 1996. Glucocorticoid-induced osteoporosis. In *Osteoporosis*. R. Marcus, D. Feldman, and J. Kelsey, editors. Academic Press, San Diego, CA. 801–820.
3. Fitzpatrick, L.A. 1994. Glucocorticoid-induced osteoporosis. In *Osteoporosis*. R. Marcus, editor. Blackwell Scientific Publications, Boston, MA. 202–226.
4. Reid, I.R. 1989. Pathogenesis and treatment of steroid osteoporosis. *Clin. Endocrinol.* 30:83–103.
5. Dempster, D. 1989. Bone histomorphometry in glucocorticoid-induced osteoporosis. *J. Bone Miner. Res.* 4:137–141.
6. Mankin, H.J. 1992. Nontraumatic necrosis of bone (osteonecrosis). *N. Engl. J. Med.* 326:1473–1479.
7. Jilka, R.L., R.S. Weinstein, K. Takahashi, A.M. Parfitt, and S.C. Manolagas. 1996. Linkage of decreased bone mass with impaired osteoblastogenesis in a murine model of accelerated senescence. *J. Clin. Invest.* 97:1732–1740.
8. Jilka, R.L., R.S. Weinstein, T. Bellido, A.M. Parfitt, and S.C. Manolagas. 1998. Osteoblast programmed cell death (apoptosis): modulation by growth factors and cytokines. *J. Bone Miner. Res.* 13:793–802.
9. Weinstein, R.S., R.L. Jilka, A.M. Parfitt, and S.C. Manolagas. 1997. The effects of androgen deficiency on murine bone remodeling and bone mineral density are mediated via cells of the osteoblastic lineage. *Endocrinology.* 138: 4013–4021.
10. Frey, F.J. 1987. Kinetics and dynamics of prednisolone. *Endocr. Rev.* 8: 453–473.
11. Cope, C.L. 1972. The synthetic analogues. In *Adrenal Steroids and Disease*. Lippincott, Philadelphia, PA. 488–491.
12. Broulik, P.D., and L. Stárka. 1997. Effect of antiandrogens casodex and epitestosterone on bone composition in mice. *Bone (Tarrytown)*. 20:473–475.
13. Weinstein, R.S., and N.H. Bell. 1988. Diminished rates of bone formation in normal black adults. *N. Engl. J. Med.* 319:1698–1701.
14. Parfitt, A.M., M.K. Drezner, F.H. Glorieux, J.A. Kanis, H. Malluche, P.J. Meunier, S.M. Ott, and R.R. Recker. 1987. Bone histomorphometry: standardization of nomenclature, symbols, and units. Report of the ASBMR Histomorphometry Nomenclature Committee. *J. Bone Miner. Res.* 2:595–610.
15. Parfitt, A.M., C.H.E. Mathews, A.R. Villanueva, M. Kleerekoper, B. Frame, and D.S. Rao. 1983. Relationships between surface, volume and thickness of iliac trabecular bone in aging and in osteoporosis. Implications for the microanatomic and cellular mechanism of bone loss. *J. Clin. Invest.* 72:1396–1409.
16. Bellows, C.G., J.E. Aubin, and J.N.M. Heersche. 1991. Initiation and progression of mineralization of bone nodules formed in vivo: the role of alkaline phosphatase and organic phosphate. *Bone Miner.* 14:27–40.
17. Owen, M. 1985. Lineage of osteogenic cells and their relationship to the stromal system. In *Bone and Mineral Research*. Volume 3. W.A. Peck, editor. Elsevier, Amsterdam. 1–25.
18. Falla, N., P. Van Vlasselaer, J. Bierkens, B. Borremans, G. Schoeters, and U. Van Gorp. 1993. Characterization of a 5-fluorouracil-enriched osteoprogenitor population of the murine bone marrow. *Blood.* 82:3580–3591.
19. Tomkinson, A., J. Reeve, R.W. Shaw, and B.S. Noble. 1997. The death of osteocytes via apoptosis accompanies estrogen withdrawal in human bone. *J. Clin. Endocrinol. Metab.* 82:3128–3135.
20. Lynch, M.P., C. Capparelli, J.L. Stein, G.S. Stein, and J.B. Lian. 1998. Apoptosis during bone-like tissue development in vitro. *J. Cell. Biochem.* 68: 31–49.
21. StatCorp. 1995. Stata Statistical Software Release 4.0. Stata Corporation, College Station, TX. 1–1601.
22. Jilka, R.L., G. Hangoc, G. Girasole, G. Passeri, D.C. Williams, J.S. Abrams, B. Boyce, H. Broxmeyer, and S.C. Manolagas. 1992. Increased osteoclast development after estrogen loss: mediation by interleukin-6. *Science.* 257: 88–91.
23. King, C.S., E.C. Weir, C.W. Gundberg, J. Fox, and K.L. Insogna. 1996. Effects of continuous glucocorticoid infusion on bone metabolism in the rat. *Calcif. Tissue Int.* 59:184–191.
24. Li, M., Y. Shen, B.P. Halloran, B.D. Baumann, K. Miller, and T.J. Wronski. 1996. Skeletal response to corticosteroid deficiency and excess in growing male rats. *Bone (Tarrytown)*. 19:81–88.
25. Quarles, L.D. 1992. Prednisone-induced osteopenia in beagles: variable effects mediated by differential suppression of bone formation. *Am. J. Physiol. (Endocrinol. Metab.)*. 263:E136–E141.
26. Gardel, B., B. Sutter, B. Flautre, E. Viguier, F. Lavaste, and P. Hardouin. 1994. Effects of glucocorticoids on skeletal growth in rabbits evaluated by dual-photon absorptiometry, microscopic connectivity and vertebral compressive strength. *Osteoporosis Int.* 4:204–210.
27. Kawai, K., A. Tamaki, and K. Hirohata. 1985. Steroid-induced accumulation of lipid in the osteocytes of the rabbit femoral head. *J. Bone Joint Surg.* 67A:755–762.
28. Deloffre, P., D. Hans, C. Rumelhart, D. Mitton, Y. Tsouderos, and P.J. Meunier. 1995. Comparison between bone-density and bone strength in glucocorticoid-treated aged ewes. *Bone (Tarrytown)*. 17:409S–414S.
29. Chavassieux, P., A. Buffet, P. Vergnaud, P. Garnero, and P.J. Meunier. 1997. Short-term effects of corticosteroids on trabecular bone remodeling in old ewes. *Bone (Tarrytown)*. 20:451–455.
30. Newman, E., A.S. Turner, and J.D. Wark. 1995. The potential of sheep for the study of osteopenia: current status and comparison with other animal models. *Bone (Tarrytown)*. 16:277S–284S.
31. Dempster, D.W., B.S. Moonga, L.S. Stein, W.R. Horbert, and T. Antakly. 1997. Glucocorticoids inhibit bone resorption by isolated osteoclasts by enhancing apoptosis. *J. Endocrinol.* 154:397–406.
32. Conaway, H.H., D. Grigorie, and U.H. Lerner. 1996. Stimulation of neonatal mouse calvarial bone resorption by the glucocorticoids hydrocortisone and dexamethasone. *J. Bone Miner. Metab.* 11:1419–1429.
33. Bellows, C.G., J.E. Aubin, and J.N.M. Heersche. 1987. Physiological concentrations of glucocorticoids stimulate formation of bone nodules from isolated rat calvarial cells in vitro. *Endocrinology.* 121:1985–1992.
34. Lian, J.B., V. Shalhoub, F. Aslam, B. Frenkel, J. Green, M. Hamrah, G.S. Stein, and J.L. Stein. 1997. Species-specific glucocorticoid and 1,25-dihydroxyvitamin D responsiveness in mouse MC3T3-E1 osteoblasts: dexamethasone inhibits osteoblast differentiation and vitamin D down-regulates osteocalcin gene expression. *Endocrinology.* 138:2117–2127.
35. Stanton, B., G. Giebisch, G. Klein-Robbenhaar, J. Wade, and R.A. DeFronzo. 1985. Effects of adrenalectomy and chronic corticosteroid replacement on potassium transport in rat kidney. *J. Clin. Invest.* 75:1317–1326.
36. Borchard, R.E., C.D. Barnes, and L.G. Eltherington. 1992. *Drug Dosage in Laboratory Animals: A Handbook*. CRC Press, Inc., Boca Raton, FL. 514–517.
37. Kleiber, M. 1961. *The Fire of Life: An Introduction to Animal Energetics*. John Wiley & Sons, Inc., New York. 177–230.
38. Klein, M., A.R. Villanueva, and H.M. Frost. 1965. A quantitative histological study of rib from 18 patients treated with adrenal cortical steroids. *Acta Orthop. Scand.* 35:171–184.
39. Bressot, C., P.J. Meunier, M.C. Chapuy, E. Lejeune, C. Edouard, and A.J. Darby. 1979. Histomorphometric profile, pathophysiology and reversibility of corticosteroid-induced osteoporosis. *Metab. Bone Dis. Relat. Res.* 1:303–311.
40. Parfitt, A.M., A.R. Villanueva, J. Foldes, and D.S. Rao. 1995. Relations between histologic indices of bone formation: implications for the pathogenesis of spinal osteoporosis. *J. Bone Miner. Res.* 10:466–473.
41. Parfitt, A.M. 1994. Osteonal and hemi-osteonal remodeling: the spatial and temporal framework for signal traffic in adult human bone. *J. Cell. Biochem.* 55:273–286.
42. Manolagas, S.C., R.L. Jilka, T. Bellido, C.A. O'Brien, and A.M. Parfitt. 1996. Interleukin-6-type cytokines and their receptors. In *Principles of Bone Biology*. J.P. Bilezikian, L.G. Raisz, and G.A. Rodan, editors. Academic Press, San Diego, CA. 701–713.
43. Parfitt, A.M. 1990. Bone-forming cells in clinical conditions. In *Bone: A Treatise*, Vol. 1. The Osteoblast and Osteocyte. B.K. Hall, editor. Telford and CRC Press, Boca Raton, FL. 351–429.
44. Bursch, W., S. Paffe, B. Putz, and R. Schulte-Hermann. 1990. Determination of the length of the histological stages of apoptosis in normal liver and in altered hepatic foci of rats. *Carcinogenesis.* 11:847–583.
45. Cline, M.J. 1974. Drugs and phagocytes. *N. Engl. J. Med.* 291:1187–1188.
46. Gohel, A., and G. Gronowicz. 1997. Glucocorticoids induce apoptosis in osteoblasts in mice by the regulation of BCL-2, BAX and other cell cycle factors. *J. Bone Miner. Res.* 12(Suppl. 1):S284. (Abstr.)
47. Frost, H.M. 1960. In vivo osteocyte cell death. *J. Bone Joint Surg.* 42A: 138–143.
48. Frost, H.M. 1960. Micropetrosis. *J. Bone Joint Surg.* 42A:144–150.
49. Dunstan, C.R., N.M. Somers, and R.A. Evans. 1993. Osteocyte death and hip fracture. *Calcif. Tissue Int.* 53:S113–S117.
50. Aarden, E.M., E.H. Burger, and P.J. Nijweide. 1994. Function of osteocytes in bone. *J. Cell. Biochem.* 55:287–299.
51. Noble, B.S., H. Stevens, N. Loveridge, and J. Reeve. 1997. Identification of apoptotic osteocytes in normal and pathological human bone. *Bone (Tarrytown)*. 20:273–282.
52. Ficat, R.P. 1985. Idiopathic necrosis of the femoral head. *J. Bone Joint Surg.* 67B:3–9.
53. Felson, D.T., and J.J. Anderson. 1987. Across-study evaluation of association between steroid dose and bolus steroids and avascular necrosis of bone. *Lancet.* i:902–905.