

## The heart and other organs

# Interactions of the heart and the liver

Søren Møller<sup>1\*</sup> and Mauro Bernardi<sup>2</sup>

<sup>1</sup>Centre of Functional and Diagnostic Imaging and Research, Department of Clinical Physiology and Nuclear Medicine, Hvidovre Hospital, The Faculty of Health Sciences, University of Copenhagen, Copenhagen, Denmark and <sup>2</sup>Dipartimento di Scienze Mediche e Chirurgiche, Alma Mater Studiorum, Università di Bologna, Semeiotica Medica, Policlinico S Orsola-Malpighi, Bologna, Italy

Received 18 September 2012; revised 20 March 2013; accepted 3 June 2013; online publish-ahead-of-print 12 July 2013

There is a mutual interaction between the function of the heart and the liver and a broad spectrum of acute and chronic entities that affect both the heart and the liver. These can be classified into heart diseases affecting the liver, liver diseases affecting the heart, and conditions affecting the heart and the liver at the same time. In chronic and acute cardiac hepatopathy, owing to cardiac failure, a combination of reduced arterial perfusion and passive congestion leads to cardiac cirrhosis and cardiogenic hypoxic hepatitis. These conditions may impair the liver function and treatment should be directed towards the primary heart disease and seek to secure perfusion of vital organs. In patients with advanced cirrhosis, physical and/or pharmacological stress may reveal a reduced cardiac performance with systolic and diastolic dysfunction and electrophysiological abnormalities termed cirrhotic cardiomyopathy. Electrophysiological abnormalities include prolonged QT interval, chronotropic incompetence, and electro-mechanical uncoupling. No specific therapy can be recommended, but it should be supportive and directed against the heart failure. Numerous conditions affect both the heart and the liver such as infections, inflammatory and systemic diseases, and chronic alcoholism. The risk and prevalence of coronary artery disease are increasing in cirrhotic patients and since the perioperative mortality is high, a careful cardiac evaluation of such patients is required prior to orthotopic liver transplantation.

### Keywords

Cirrhosis • Portal hypertension • Cardiac hepatopathy • Cirrhotic cardiomyopathy • Hyperdynamic circulation • Congestive hepatopathy • Alcoholic heart muscle disease • Portopulmonary hypertension • Hepatopulmonary syndrome • Liver transplantation

## Introduction

It has been known for many years that the heart and the liver are intimately related. Thus, patients with acute and chronic heart failure develop manifestations from the liver. Cardiac cirrhosis or congestive hepatopathy includes a spectrum of hepatic derangements occurring in the setting of right-sided heart failure.<sup>1,2</sup> Unlike cirrhosis caused by chronic alcohol use or viral hepatitis, the effect of cardiac cirrhosis on overall prognosis has not been clearly established,<sup>3</sup> but cardiac cirrhosis may be reversed after heart transplantation (HTx).<sup>4</sup> A sudden and dramatic serum hepatic transaminase elevation in relation to cardiogenic shock indicates massive hepatocellular necrosis named ischaemic hepatitis.<sup>5,6</sup> Contrarily, chronic liver disease *per se* may affect heart functions and electrophysiology in the absence of other cardiac disease.<sup>7–9</sup> The complex of these abnormalities is named *cirrhotic cardiomyopathy* that affect the patient prognosis and aggravate the course during invasive procedures such as surgery, insertion of a transjugular intrahepatic portosystemic shunt (TIPS), and orthotopic liver transplantation (OLT).<sup>7,8</sup> This review seeks to

highlight the heart as a cause of liver disease, the liver as a cause of heart disease, cardiac effects of liver-related pulmonary dysfunction, and finally, chronic alcoholism and systemic disorders, such as haemochromatosis and amyloidosis, that may affect the function of both the heart and the liver.

## The heart as a cause of liver disease

Heart failure often provokes liver damage, as it could be expected. In fact, the liver receives up to 25% of cardiac output, and is therefore highly sensitive to reduction in blood flow. Moreover, the lack of valves in hepatic veins allows increased inferior caval pressure to hit the sinusoidal bed without any attenuation. Indeed, the liver involvement in heart failure has long been recognized,<sup>9</sup> but the studies dealing with this matter are relatively few, not rarely with contradicting results. There are several potential reasons for variant results: heart failure aetiology has changed over the years, being mainly related to rheumatic valvular disease in the earliest studies<sup>9</sup> and to

\* Corresponding author. Tel: +45 3862 3568, Fax: +45 3862 3750, Email: [soeren.moeller@regionh.dk](mailto:soeren.moeller@regionh.dk)

Published on behalf of the European Society of Cardiology. All rights reserved. © The Author 2013. For permissions please email: [journals.permissions@oup.com](mailto:journals.permissions@oup.com)

ischaemic cardiomyopathy more recently;<sup>10</sup> the outcome of heart failure has dramatically improved, due to the increased efficiency of medical treatment, not to mention the widespread use of HTx. Thus, cardiac cirrhosis, once the paradigm of liver involvement in heart failure, is now rare.

Cardiac hepatopathy is classically described in the setting of either acute or chronic heart failure. However, clinical and pathogenetic factors related to both conditions often coexist, and a clear-cut partition between them is not always appropriate. The recognition and diagnosis of cardiac hepatopathy are important, as liver damage can influence the prognosis and outcome of the cardiac disease, and can only recover through measures improving cardiac function.

## Essential pathophysiology

The fundamental mechanisms underlying cardiac hepatopathy are reduced arterial perfusion, whose deleterious effects are amplified by concomitant hypoxia, and passive congestion secondary to increased systemic venous pressure. Arterial hypoperfusion predominates in acute heart failure leading to hypoxic hepatitis, while passive congestion prevails in congestive hepatopathy secondary to chronic heart failure. However, these forward and backward factors often coexist and potentiate each other.<sup>11</sup> Interestingly, hepatic steatosis, which is frequent in patients with cardiac hepatopathy because of comorbid conditions such as diabetes, obesity, and hyperlipaemia,<sup>9,12</sup> increases liver susceptibility to the ischaemia-reperfusion injury.<sup>13</sup>

The major damage occurs in Zone 3 of the Rappaport acinus, which surrounds the central vein of the hepatic lobule and physiologically receives poorly oxygenated blood with respect to the periportal region (Zone 1).<sup>11</sup> Centrilobular liver cell necrosis can extend to peripheral areas if heart failure persists and worsens, and is followed by the deposition and spread of connective tissue bridging one central vein to the other, ultimately leading to cirrhosis.<sup>9</sup>

The backward failure is also responsible for an enhanced hepatic lymph formation, leading to ascites when its production rate exceeds the draining capacity of the lymphatic system. Moreover, increased pressure within the hepatic sinusoid favours bile duct damage by disrupting endothelial cells and the interhepatocytic tight junctions that separate the extravascular space from the bile canaliculus.<sup>14</sup> At last, stagnant flow favours thrombosis within sinusoids, hepatic venules, and portal tracts; this contributes to liver fibrosis and may explain its uneven distribution.<sup>15</sup>

## Liver haemodynamics

Cardiac hepatopathy is associated with systemic haemodynamic changes that accompany heart failure,<sup>10,16</sup> including increased right atrial and inferior caval venous pressures. Hepatic blood flow can be variably impaired, even though a fully reliable method to assess this parameter in the context of cardiac hepatopathy is not available as yet.<sup>16</sup>

Liver vein catheterization evaluates portal pressure by the measurement of the hepatic venous pressure gradient (HVPG). In chronic heart failure, due to the caudad transmission of systemic venous hypertension, these are proportionally increased, so that the HVPG is not modified in most cases. This explains why, despite the presence of portal hypertension, oesophageal varices rarely develop in cardiac hepatopathy.<sup>10</sup> Contrariwise, in portal hypertension due to

cirrhosis the HVPG is increased and leads to porto-systemic collateral formation. An increased HVPG in a patient with presumed cardiac hepatopathy would mean that either a different cause or chronic congestion itself has led to frank cirrhosis.

## Clinical features—hypoxic hepatitis

The clinical presentation of hypoxic hepatitis in the setting of acute heart failure and/or severe arterial hypotension and shock is not unique, ranging from asymptomatic cases to conditions similar to acute viral hepatitis<sup>17</sup> or even acute liver failure (ALF): out of 1147 patients with ALF, 4.4% were affected by hypoxic hepatitis.<sup>18</sup> Therefore, encephalopathy can be present, but other mechanisms, such as cerebral hypoperfusion, likely contribute with those involved in hepatic encephalopathy.<sup>17</sup> Interestingly, the cardiac component may not be apparent at first evaluation<sup>18</sup> and hypoxic hepatitis can be undistinguishable from ALF from other causes.<sup>19</sup> Therefore, if the aetiology is uncertain, a simple cardiac evaluation by echocardiography is warranted.<sup>19</sup> The prognosis of ALF due to hypoxic hepatitis is less severe than with other causes: once the underlying cardio-circulatory event is corrected or attenuated the 3-week survival approximates 70%. Encephalopathy Grade 3–4 was an independent predictor of adverse outcomes.<sup>18</sup>

A striking increase of serum aminotransferases followed by a rapid decline once the causative event has been corrected is typical of hypoxic hepatitis.<sup>11,12</sup> Lactate dehydrogenase changes in parallel with transaminases, and this can help in differential diagnosis of acute viral or drug-induced hepatitis.<sup>20</sup> Jaundice is seldom severe, except in cases developing ALF. Prothrombin time international normalized ratio (INR) greater than two is an independent risk factor for all-cause mortality.<sup>20</sup>

## Clinical features—congestive hepatopathy

It is associated with right heart dysfunction, and is often asymptomatic. Signs on physical examination are jaundice, dependent oedema, ascites, hepatomegaly with hepatojugular reflux, and pulsatile liver in patients with tricuspid valve regurgitation.<sup>16</sup>

Laboratory features mainly show cholestasis,<sup>12,21,22</sup> with increased serum  $\gamma$ -glutamyl-transpeptidase, alkaline phosphatase, and bilirubin, while transaminases are often normal or moderately increased, unless severe heart failure with significant forward component coexists.

The degree of cholestasis is related to the severity of heart failure, as assessed by an increase in right atrial pressure, presence of tricuspid regurgitation,<sup>21</sup> and increase in serum pro-brain natriuretic peptide (BNP).<sup>22</sup> Cholestasis assumes prognostic relevance as increased serum alkaline phosphatase or bilirubin, which are marker of cholestasis, predict all-cause mortality,<sup>22</sup> cardiovascular death or hospitalization for heart failure.<sup>23</sup>

Chronic liver congestion also leads to synthetic function impairment, as shown by prolonged prothrombin time and reduced serum albumin concentration, which is also associated with all-cause mortality in patients with a reduced ejection fraction.<sup>24</sup>

Long-term survivors the Fontan operation can develop liver damage as a result of the interplay of central venous hypertension, due to the passive, nonpulsatile flow through the pulmonary arterial bed, and hypoxia resulting from left ventricular dysfunction.<sup>25</sup> Indeed, hepatomegaly and abnormal liver tests have been reported in

one-third to more than half of cases, being related to a reduced cardiac index and increased right atrial pressure.<sup>26</sup> After a mean of 11.5 years, the prevalence of cirrhosis was 25.9%, with the elapsed time being the only independent predictor.<sup>27</sup> Liver disease could contribute to adverse outcomes in this population. However, increased right atrial pressure and protein-losing enteropathy, also amenable to increased systemic venous pressure, but not liver dysfunction, were among the independent predictors of all-cause mortality or HTx in perioperative survivors.<sup>28</sup>

Another condition leading to a sustained elevation of systemic venous pressure and severe liver damage is chronic constrictive pericarditis.<sup>29</sup> As the usual physical signs of heart failure may be inconspicuous, patients presenting a clinical picture of liver cirrhosis, including ascites, but also distended jugular veins should induce to look for pericardial calcifications or thickening by echocardiography, computed tomography scan, or magnetic resonance imaging. Doppler echocardiography or right cardiac catheterization can be needed for the differential diagnosis of restrictive cardiomyopathy. Although this is not always easy, the recognition of chronic constrictive pericarditis is of paramount importance, as it can be cured by surgery.

## Liver dysfunction with ventricular assist devices

Pulsatile or continuous-flow liver dysfunction with ventricular assist devices (LVADs) improve liver function in patients with mild abnormalities in the pre-implant liver tests, and no deterioration in those with normal baseline values, up to 6 months.<sup>30,31</sup> This is likely due to a volume shift from the intrathoracic area to the systemic circulation improving liver blood flow, as assessed by indocyanine green clearance.<sup>32</sup>

However, pre-existing or post-LVAD severe liver dysfunction strikingly influences patients' prognosis and endangers their survival.<sup>33</sup> The model for end-stage liver disease (MELD), a scoring system assessing the severity of chronic liver disease based on serum bilirubin, creatinine and INR for prothrombin time<sup>34</sup> widely used for determining prognosis and prioritizing for receipt of a liver transplant, predicts mortality and morbidity following LVAD.<sup>35,36</sup>

Liver dysfunction can also occur or worsen after LVAD implantation. Pre-, peri-, and postoperative factors, such as large doses of vasopressors, prolonged cardiopulmonary bypass time, arterial hypotension, systemic inflammatory responses and, mainly, right ventricular failure predispose to liver damage, often presenting intrahepatic cholestasis.<sup>33</sup> The severity and course of post-ventricular assist devices (VADs) liver damage can be monitored by sequential assessment of MELD-XI, a modified MELD score excluding INR to overcome the problem posed by concomitant anticoagulation.<sup>37</sup>

## The liver as a cause of heart disease

The hyperdynamic circulation in patients with cirrhosis was described 60 years ago.<sup>38</sup> Successive experimental and clinical studies have lent support to an underlying cardiac dysfunction.<sup>39–41</sup> This syndrome that has been termed cirrhotic cardiomyopathy includes a combination of reduced cardiac contractility with systolic and diastolic dysfunction and electrophysiological abnormalities.<sup>8,42–44</sup> The results of diverse experimental studies suggest involvement of

several mechanisms in the pathophysiology, which will be shortly reviewed. Systolic incompetence can be demonstrated by pharmacological or physical stress and has recently been implicated in the development of renal failure in advanced disease.<sup>45</sup> Diastolic dysfunction in cirrhosis may reflect ventricular hypertrophy, altered collagen structure, and it seems related to prognosis.<sup>8,43</sup> The electrocardiographic QT interval (QT) interval is prolonged in about half of the cirrhotic patients and may be related to patient characteristics and survival.<sup>44</sup>

## Pathophysiological mechanisms

A number of pathogenetic mechanisms for the impaired contractility in cirrhotic cardiomyopathy have been described, including dysfunction or defects in the cardiac beta-adrenergic receptor system, plasma membrane fluidity, abnormalities in the membrane calcium channels, and pathological effects of many humoral factors such as nitric oxide, cytokines, carbon monoxide, and endocannabinoids. An exhaustive description is beyond the scope of this review, but the most important elements are briefly mentioned and reviewed in Figure 1.

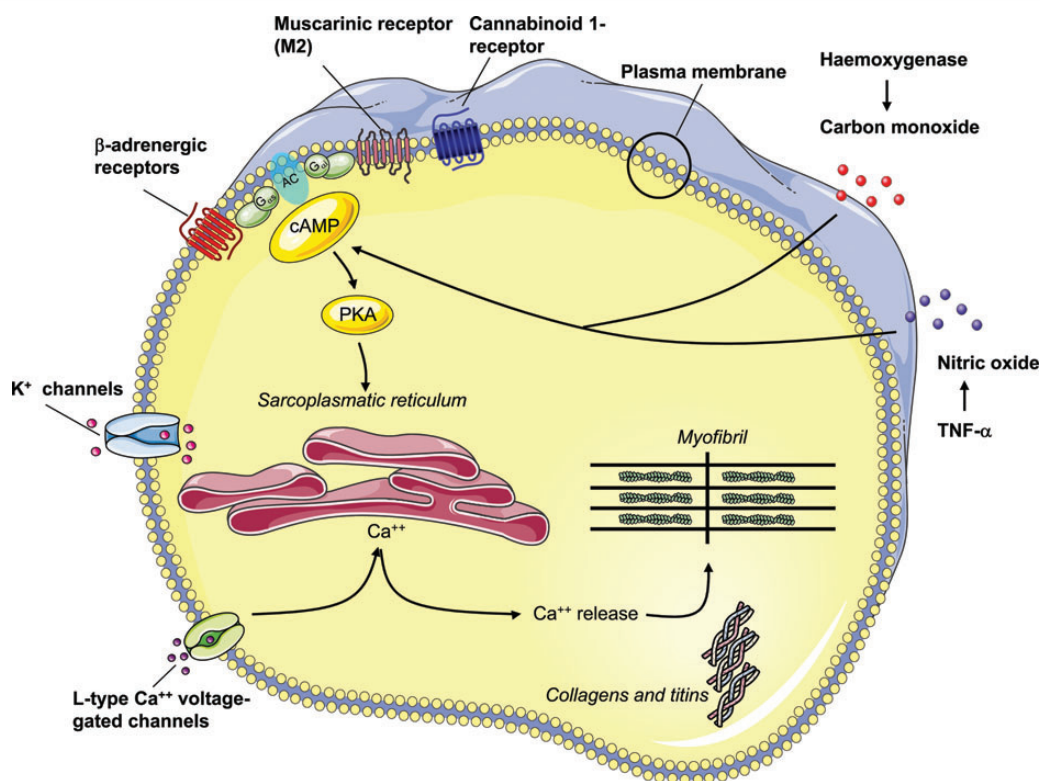
## Systolic dysfunction

The circulation in advanced cirrhosis is hyperdynamic with increased cardiac output. A hallmark in the pathogenesis is the pronounced splanchnic arterial vasodilatation and reduced systemic vascular resistance (SVR).<sup>41</sup> In this setting, cardiac pressures are largely normal, at least in part, because the reduced after-load protects systolic function. This circulatory state resembles certain high-output states resulting from increased blood volume and defined as a hyperdynamic unloaded failure of the heart.<sup>46</sup> The difference is that the hyperdynamic circulation in cirrhosis is secondary to the low SVR and increased arterial compliance.<sup>47,48</sup>

Despite the characteristic high cardiac output, systolic dysfunction is included in the working definition of the cirrhotic cardiomyopathy (see Table 1)<sup>41</sup> and relates to the inability of the heart to meet its demands with respect to generation of an adequate arterial blood pressure and cardiac output.<sup>49</sup> This can be unveiled by physical exercise that increases left ventricular pressure, volume, and left ventricular ejection fraction and heart rate in some cirrhotic patients.<sup>49–51</sup> Similarly, administration of vasoconstrictors, such as angiotensin II and terlipressin, increases the SVR and thereby the left ventricular afterload<sup>41,42,52</sup> unmasking a latent left ventricular dysfunction in cirrhosis. On the other hand, vasodilators, like angiotensin-converting enzyme inhibitors and other afterload-reducing agents, should be used with caution due to the risk of further aggravation of the vasodilatory state.

Recent studies using contemporary echocardiographic techniques have shown a reduced peak systolic tissue velocity and an increased peak systolic strain rate in cirrhotic patients compared with controls,<sup>53</sup> indicating that systolic dysfunction may be also present at rest.

Systolic dysfunction may have an impact on the development of complications, such as sodium and water-retention and ascites formation, and development of renal dysfunction, and prognosis.<sup>41,51,54,55</sup> Figure 2 suggests the relationship between the myocardial changes and development of complications to cirrhosis and the clinical course.



**Figure 1** The figure reviews the most important mechanisms involved in the impaired contractile function of the cardiomyocyte in experimental cirrhotic cardiomyopathy: Desensitization and downregulation of β-adrenergic receptors with a decreased content of G-protein ( $G_{\alpha i}$ : inhibitory G protein;  $G_{\alpha s}$ : stimulatory G protein) and following impaired intracellular signalling; alterations in particular in M1 muscarinic receptors; upregulation of cannabinoid 1-receptor stimulation; altered plasma membrane cholesterol/phospholipid ratio; increased inhibitory effects of haemoxygenase, carbon monoxide, nitric oxide, and tumour necrosis factor-α; reduced density of potassium channels; changed function and fluxes through L-type calcium channels; altered ratio and function of collagens and titins. Many post-receptor effects are mediated by adenylyclase inhibition or stimulation. PKA, protein kinase A).

## Diastolic dysfunction

In cirrhosis, the background for diastolic dysfunction is an increased stiffness of the myocardial wall owing to myocardial hypertrophy, fibrosis, and subendothelial oedema.<sup>54,56,57</sup> In bile duct ligated rats, eccentric hypertrophy of the left ventricle develops along with aggravation of the hyperdynamic circulation.<sup>58</sup> From a physiological standpoint, diastolic dysfunction is characterized by a changed transmitral blood flow, which is seen in about half of cirrhotic patients.<sup>41,53,59</sup> The prevalence of diastolic dysfunction is reported from 45 to 56%.<sup>59</sup> As assessed by tissue-Doppler imaging, there seems to be an association between diastolic dysfunction and circulatory dysfunction, development of ascites, hepatorenal syndrome, and survival.<sup>59</sup> Thus, diastolic dysfunction is most prominent in patients with severe decompensation, where the combination of myocardial hypertrophy, contractile dysfunction, changes in heart volumes, and diastolic dysfunction may represent an essential element in the cirrhotic cardiomyopathy.<sup>51,59</sup> An E/A ratio below one is furthermore associated with a higher mortality during the first year after TIPS and reduced ascites mobilization,<sup>8,60</sup> and it seems to be associated with an increased need for OLT or death over a 5-year period.<sup>61</sup>

It can be concluded that diastolic dysfunction may adversely affect prognosis in patients with cirrhosis, by favouring the occurrence of complications and impairing the outcome of manoeuvres leading to rapid increases in preload, such as TIPS insertion.

## Electrophysiological disturbances

Electrophysiological disturbances are not related to the aetiology of the underlying cirrhosis and worsen in parallel with its severity.

### Chronotropic incompetence

A defective cardioacceleration under physiological and pharmacological stimuli has long been recognized under different experimental and clinical conditions.<sup>62</sup> Alterations at the β-receptor and/or post-receptor level are likely involved, as suggested by the need for increased β-agonist doses to achieve heart rate increase.<sup>63</sup>

Patients with advanced cirrhosis usually exhibit tachycardia. The inability to increase the heart rate further contributes to the impaired ability to keep cardiac output adequate to the needs of systemic circulation when effective volaemia suddenly worsens, as it occurs in post-paracentesis circulatory dysfunction (PPCD)<sup>64</sup> and hepatorenal syndrome.<sup>65,66</sup> Awareness of chronotropic incompetence should



**Table 1** Proposal for diagnostic and supportive criteria for cirrhotic cardiomyopathy agreed upon at a working party held at the 2005 World Congress of Gastroenterology in Montreal [Adapted from<sup>41</sup>]

A working definition of cirrhotic cardiomyopathy	
A cardiac dysfunction in patients with cirrhosis characterized by impaired contractile responsiveness to stress and/or altered diastolic relaxation with electrophysiological abnormalities in the absence of other known cardiac disease	
Diagnostic criteria	
Systolic dysfunction	
• Blunted increase in CO with exercise, volume challenge, or pharmacological stimuli	
• Resting EF < 55%	
Diastolic dysfunction	
• E/A ratio < 1.0 (age-corrected)	
• Prolonged deceleration time (>200 ms)	
• Prolonged isovolumetric relaxation time (>80 ms)	
Supportive criteria	
• Electrophysiological abnormalities	
• Abnormal chronotropic response	
• Electromechanical uncoupling/dyssynchrony	
• Prolonged Q–Tc interval	
• Enlarged left atrium	
• Increased myocardial mass	
• Increased BNP and pro-BNP	
• Increased troponin I	

BNP, brain natriuretic peptide; CO, cardiac output; E/A, early diastolic/atrial filling ratio; EF, left ventricular ejection fraction.

lead to a cautious administration of  $\beta$ -blockers in patients with refractory ascites, as their use may affect survival<sup>67</sup> and favour the occurrence of PPCD.<sup>68,69</sup>

**Electromechanical uncoupling**

A desynchronization between electrical and mechanical systole in cirrhosis has been ascertain through the evaluation of systolic time intervals<sup>70</sup> or the simultaneous measurement of the aortic pressure curve and ECG tracing.<sup>71</sup> This abnormality, whose potential clinical relevance has not been clearly focused, is likely sustained by receptor and post-receptor defects.<sup>62</sup>

**QT interval prolongation**

The prolongation of the electrocardiographic QT interval (QT) is common in cirrhosis, with a prevalence that exceeds 60% in patients with an advanced disease.<sup>72</sup> Variant prevalence may result from different methods to correct QT by heart rate (QTc): Bazett's formula is widely employed, but it does not completely suppress the relationship between QT and heart rate. This is relevant in cirrhosis, where sinus tachycardia is usually present. A specific 'cirrhosis formula' has been derived, which is very close to the Fridericia's one.<sup>73</sup> Thus, the latter can be confidently used in this setting.

The pathophysiology of QT prolongation in cirrhosis has not been defined; portal hypertension and porto-systemic shunts, however, have to be present.<sup>74,75</sup> Along with heart exposure to potential cardiotoxins, such as endotoxins, cytokines, and bile salts,<sup>62</sup> the increased sympatho-adrenergic tone that often characterizes cirrhosis likely plays a major role. In fact, an increased adrenergic drive would prolong QT in the setting of impaired function of K<sup>+</sup> channels, as described in experimental cirrhosis.<sup>76</sup> Coherent with this, both acute<sup>77</sup> and chronic<sup>78</sup>  $\beta$ -blockade shorten a prolonged QTc in cirrhosis, and a stressful event such as gastrointestinal bleeding further prolongs QTc.<sup>79</sup>

The clinical relevance of long QT in cirrhosis is unclear. Sudden deaths and ventricular arrhythmias associated with QT prolongation have been reported,<sup>72,80</sup> but, in general, are thought to be rare. QT prolongation is also associated with a poorer survival,<sup>72</sup> especially in the setting of acute gastrointestinal bleeding.<sup>79</sup> Whether prolonged QT not only predicts, but also contributes to mortality because of its arrhythmogenic potential is unknown. In any case, drugs affecting QT should be avoided or used with caution and under close ECG monitoring.<sup>44</sup>

**Conditions affecting both the liver and the heart**

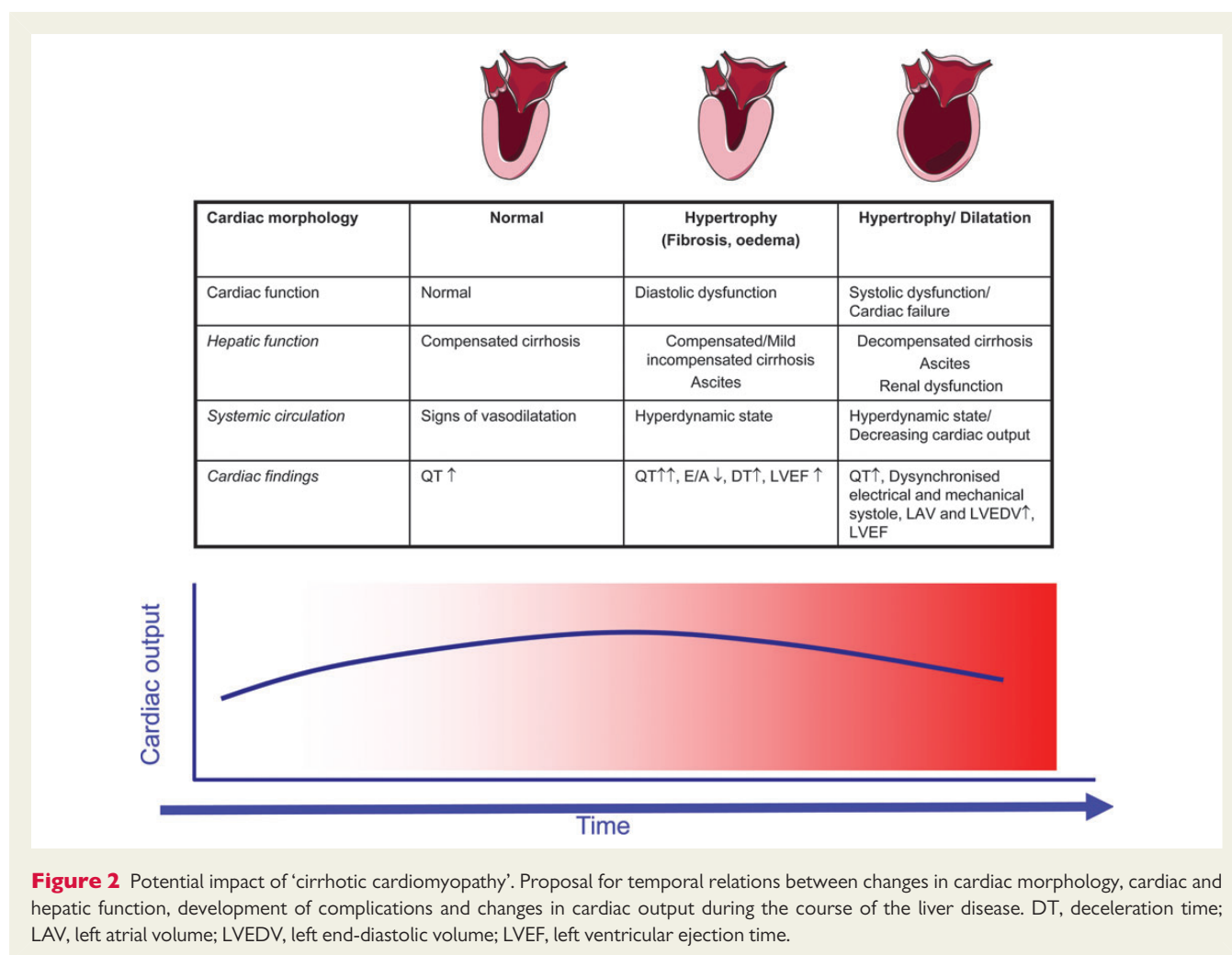
A number of systemic conditions simultaneously affect both the liver and the heart. This list is very long and it is beyond the scope of this paper to mention other than the most important ones. These can be divided into infections, inflammatory, and systemic disorders. A paragraph is devoted to alcoholic heart muscle disease.

**Infections**

Both the liver and the heart may be involved in multiorgan failure in relation to sepsis.<sup>81</sup> Hepatitis C virus infection may in addition to hepatic involvement affect the heart as myocarditis.<sup>82</sup> Human immunodeficiency virus (HIV) is known to cause hepatitis, hepatic granulomas, myocarditis, and HIV-associated cardiomyopathy.<sup>83</sup> A variety of tropical diseases also affect both the organs. For example, Dengue fever may lead to hepatic necroses combined with myocarditis<sup>84</sup> and malaria may apart from massive hepatic involvement lead to cardiac failure.<sup>85</sup>

**Inflammatory disorders**

Several inflammatory conditions affect a variety of organs including the heart and the liver. Systemic lupus erythematosus (SLE) is a condition that involves multiple immunological mechanisms. However, clinically significant liver disease is rare. Hepatic manifestations include hepatomegaly and liver enzyme elevations based on histological changes where steatosis is the most common finding. Centrilobular necroses and fibrosis are seldom seen. Cardiac manifestations of SLE include endocarditis, non-septic pericarditis, myocarditis, and coronary angiopathia.<sup>86</sup> Sarcoidosis is a systemic disease characterized by non-caseating granulomas and is the most frequent aetiology of hepatic granuloma. The liver is the third most affected organ in sarcoidosis. From a clinical standpoint, hepatic sarcoidosis may lead to cholestasis and portal hypertension and its associated complications.<sup>87</sup>



## Systemic disorders

Haemochromatosis is an autosomal recessive disorder of iron metabolism characterized by tissue iron overload. It may lead to multi-organ disease with cirrhosis, endocrine disorders like diabetes, and cardiomyopathy. Electrocardiographic changes are frequent in haemochromatosis, but although hypertrophy and increases in end-diastolic and end-systolic volumes are seen, overt heart failure is rare.<sup>88</sup> Nevertheless, patients with haemochromatosis have a 14-fold increase in mortality due to heart disease.<sup>88</sup> In Wilson's disease, the pathophysiological substrate is abnormal accumulation of copper. Hepatic manifestations include a broad clinical picture from asymptomatic biochemical dysfunction to chronic hepatitis and cirrhosis. In addition, neurological and psychiatric diseases prevail. Cardiac involvement in Wilson's disease is mild with a modest increase in concentric left ventricular remodelling, but a relatively high frequency of benign supraventricular extrasystolic beats.<sup>89</sup> Both haemochromatosis and Wilson's disease may lead to diastolic dysfunction.<sup>88,89</sup> There are several forms of amyloidosis where the liver is involved in ~20% of the patients and hepatic amyloid deposition leads to elevation of liver enzymes in early stages and later increased serum bilirubin and jaundice. Amyloidosis may lead to a restrictive cardiomyopathy.<sup>87</sup> Amyloid light-chain (AL) amyloidosis

primarily infiltrates the liver and transthyretin amyloidosis (TTR) mainly affects the heart. However, cardiac TTR amyloidosis is associated with a better prognosis than cardiac AL.<sup>90</sup>

## Alcoholic heart muscle and liver disease

Alcohol abuse can harm both the liver and the heart. Even though genetic and environmental factors, types of beverages, and drinking patterns play a role, the amount of alcohol consumed is crucial in leading to disease.<sup>91,92</sup> While chronic (10–12 years) consumption of amounts of ethanol as low as 25 g/day in males and 12 g/day in females is associated with an increased risk of cirrhosis, >90 g/day for at least 5 years appear to be needed for inducing detectable changes in cardiac structure and function.<sup>93</sup> In contrast, a moderate alcohol consumption (about 25 g/day) may protect against cardiovascular events.<sup>94</sup> Therefore, patients with alcoholic cirrhosis do not necessarily exhibit alcoholic heart muscle disease; conversely, heavy drinkers may suffer from heart failure before a significant liver damage has occurred, taking also into account that only 10–20% of heavy drinkers develop cirrhosis.<sup>92</sup> In any case, there is a correlation between development of alcoholic heart muscle disease and alcoholic cirrhosis,<sup>95</sup> a combination carrying a worse prognosis than either disease alone.<sup>91</sup> Patients with alcoholic

cirrhosis should be screened for cardiomyopathy for at least three reasons: (i) asymptomatic systolic and diastolic dysfunctions can precede the overt manifestation of cardiomyopathy; (ii) hyperdynamic circulatory syndrome may disguise the clinical expression of initial heart failure; (iii) prevention or treatment of some complications of cirrhosis, such as PPCD and hepatorenal syndrome, is based on plasma expansion with albumin and the administration of vasoconstrictors.<sup>96</sup> This would lead to deleterious effects if latent heart failure goes unrecognized.

In conclusion, a huge number of systemic diseases and chronic alcoholism affect both the liver and the heart. This may have important implications, since the heart and the liver also interact during surgical procedures, OLT, and TIPS insertion and therefore may influence the outcome.<sup>88</sup>

## Heart dysfunction in the setting of liver transplantation

OLT imposes a severe challenge to the cardiovascular system and cardiovascular complications are common either perioperatively, because of haemorrhage, clamping of major vessels reducing venous return, reperfusion syndrome, aggressive fluid replacement, electrolyte and acid–base disturbances, or after surgery, because fluid administration, infections, graft production of cardiac-depressant cytokines such as TNF- $\alpha$ , restoration of peripheral vascular resistance, and the hypertensive effect of calcineurin inhibitors.<sup>12</sup> Indeed, heart failure, myocardial infarction, and arrhythmias represent a major cause of OLT-related morbidity and mortality, cumulatively occurring in up to half of recipients<sup>97</sup> and being a leading cause of death (23.8% of all mortality).<sup>52</sup> These complications mainly occur in the perioperative and postoperative periods. Later on, cardiac function and systemic haemodynamics improve, and reversal of the cardiovascular abnormalities associated with advanced cirrhosis has been reported.

## Impact of liver transplantation on cirrhotic cardiomyopathy

The systemic vasodilation that underlies the hyperdynamic circulatory syndrome can improve in the immediate postoperative period, leading to an abrupt rise of left ventricular afterload.<sup>98</sup> This, along the fluid load inevitably brought about by surgery, is the main reason for acute left ventricular failure. However, most episodes resolve with therapy and severe dilated cardiopathy are seldom seen.<sup>99</sup> Once the postoperative period is over, and up to 3 months, a deterioration of diastolic dysfunction associated with modest ventricular hypertrophy has been reported. Whether this reflects cardiotoxicity of calcineurin inhibitors or a deterioration of cirrhotic cardiomyopathy is not clear, but both likely contribute.<sup>100</sup> At last, from 6 to 12 months after transplantation, almost all cardiovascular abnormalities reverse. Namely, indices of both systolic and diastolic function, cardiac workload, and exercise capacity substantially improve or normalize.<sup>101</sup>

QT interval prolongation can also revert after OLT, even though this occurs in about half of cases,<sup>7,102</sup> suggesting that liver disease may not be the only pathogenetic factor. It is worth noting that QT, irrespective of the baseline value, undergoes a substantial prolongation in the

anhepatic phases of surgery, up to values associated with a high risk of ventricular arrhythmias, in ~50% of patients.<sup>103</sup>

## Cardiac evaluation prior to liver transplantation

Because of the reasons reported above, careful evaluation and selection of OLT candidates is needed, taking also into account that patients with advanced cirrhosis, due to reduced physical activity, symptoms related to their liver disease, as fatigue, and concurrent morbidity, as anaemia, may present a clinical picture disguising the presence of cardiac disease.

### Coronary artery disease

Contrary to what is generally perceived, the prevalence of coronary artery disease (CAD) in OLT candidates can reach up to 26%<sup>104</sup>. In turn, CAD is associated with an increased post-OLT mortality and a greater incidence of new cardiovascular morbidity.<sup>105</sup> The age of OLT candidates and the proportion of cirrhosis related to non-alcoholic steatohepatitis (NASH) are increasing, thus contributing to these findings. Indeed, NASH patients are at increased risk of cardiovascular complications following OLT, independent of traditional cardiac risk factors.<sup>106</sup>

The predictive value of noninvasive functional testing for ischaemia is hampered in OLT candidates: most cannot undergo exercise testing and Dobutamine stress echocardiography has a poor sensitivity and negative predictive value in this setting,<sup>107</sup> likely because patients with advanced cirrhosis often show chronotropic incompetence and reduced vascular responsiveness to vasoconstrictors. Thus, either an abnormal noninvasive test or a high pre-test probability of CAD based on the presence of two or more classical risk factors, such as age >50, diabetes mellitus, smoking, family history of CAD, arterial hypertension, and hyperlipidaemia, should prompt consideration for coronary angiography.<sup>108</sup> Moreover, specific risk factors such as NASH-related cirrhosis, concomitant renal dysfunction and coronary calcium should also be exploited.<sup>109</sup> Coronary angiography is acceptably safe in these patients and successful coronary revascularization for obstructive CAD has been used before transplantation.<sup>110</sup> However, reports on the outcomes of coronary interventions in OLT candidates are few, and a perioperative death rate of >50% has been reported in the past.<sup>111</sup> Therefore, further studies are needed to establish to what extent coronary revascularization can be safely proposed in this setting.

### Cardiomyopathy

The boundaries of cirrhotic cardiomyopathy are still ill defined, and limits of cardiac dysfunction beyond which OLT is not advisable have not been identified. The same applies to cases with a known cause of cardiomyopathy. The incidence of post-OLT cardiac depression and pulmonary oedema is extremely variable in different studies, ranging from 1 to 47%,<sup>99,112</sup> likely because of different diagnostic criteria employed. Early cardiac depression, within 12 h from surgery, is associated with multiorgan failure and death.<sup>113</sup> Interestingly, post-OLT systolic heart failure can occur in the absence of traditional risk factors; elevated preoperative mean pulmonary arterial and right ventricular systolic pressure were the unique features heralding this complication.<sup>114</sup>

Echocardiography is recommended in all OLT candidates to assess ventricular and valvular functions and left ventricular outflow tract

obstruction. The latter has been reported in up to 40% OLT candidates, and an outflow gradient  $>36$  mmHg was associated with intraoperative hypotension.<sup>115</sup> Pulmonary artery pressure and right ventricular function should also be evaluated, given the high prevalence (20%) of pulmonary hypertension, defined as pulmonary artery systolic pressure (PASP)  $>30$  mmHg,<sup>116</sup> which is associated with a reduced survival among OLT candidates and recipients, especially with values  $>60$  mmHg.<sup>117</sup> Therefore, right ventricular dysfunction or, taking into account the margin of error of echocardiographic measurement, an estimated PASP  $>45$  mmHg should induce right-hand side heart catheterization.<sup>118</sup>

## Liver dysfunction in the setting of heart transplantation

Chronic cardiac hepatopathy is common in patients evaluated for HTx, and liver dysfunction predicts an adverse outcome following transplantation.<sup>119</sup> At the same time, altered pre-HTx liver tests can significantly improve after surgery, suggesting that chronic cardiac hepatopathy is a potentially reversible disease.

### Impact of heart transplantation on cardiac hepatopathy

A retrospective analysis showed that cholestatic parameters and bilirubin significantly improved 3 months after HTx, while LDH and transaminases did so over a longer time frame, up to 12 months.<sup>120</sup> However, patients with severe liver disease and cirrhosis were not included in this study. These favourable results have been confirmed in a larger cohort of patients followed up to 10 years from surgery.<sup>121</sup> In addition to the standard liver test, a modified MELD score, computing serum albumin concentration instead of INR, was also longitudinally assessed: a decrease in the score already occurred after 2 months, especially in those patients with the highest scores, continued up to 6 months and stabilized thereafter. Even though patients with elevated MELD scores were included in this study, the exact prevalence of cirrhosis was not reported. Nevertheless successful HTx has been described in a small series of patients with cirrhosis, even though high postoperative mortality and morbidity were recorded.<sup>122</sup> Interestingly, not all patients had cardiac cirrhosis that may have taken benefit by relieving heart failure. In fact, the complete reversal of cardiac cirrhosis 10 years after HTx has been reported.<sup>4</sup>

### Liver evaluation prior to heart transplantation

As reported above, severe liver disease often predicts an adverse outcome of HTx. Therefore, a careful assessment of liver function in candidates to HTx is warranted, with an emphasis on the ascertainment of liver cirrhosis. As standard liver tests can be insensitive for detecting cardiac cirrhosis, echography of the abdomen with an echo-Doppler study of portal and tributary veins should be performed. When signs of portal hypertension were seen, endoscopy is needed to assess the presence of gastro-esophageal varices and congestive gastropathy. In case of doubt, additional evaluation may include HVPG assessment and transjugular liver biopsy.

MELD or modified MELD scores should be calculated, as patients with higher MELD scores ( $>20$ ) suffer from higher postoperative complication rates, including reoperation for bleeding, increased susceptibility to bacterial infections, and in-hospital death.<sup>121</sup>

In candidates to HTx with evidence of liver disease, its cause should be ascertained. In fact, while improvement in cardiac hepatopathy can be expected after transplantation, irreversible hepatic dysfunction would have a negative prognostic impact and limit survival independent of heart disease. This is especially true in hepatitis C virus-related chronic liver disease, as pre-transplant HCV positivity associates with decreased post-transplant survival.<sup>123</sup> This adverse outcome is likely related to the lack of effective and, mainly, safe treatment, as post-HTx Interferon therapy may be associated with an increased risk of graft rejection.<sup>124</sup> In contrast, pre-emptive or long-term antiviral therapy of chronic hepatitis B with nucleoside or nucleotide analogues can lead to regression of cirrhosis after HTx, unless viral resistance occurs.<sup>125</sup> Patients with heart failure and irreversible cirrhosis could be offered combined heart and liver transplantation, whose main current indication is represented by amyloidosis.<sup>126</sup>

## Summary and conclusion

In addition to many inflammatory and systemic conditions, including chronic alcoholism, which can simultaneously affect both the heart and the liver, during the last few decades it has become evident that the heart and the liver interact and may influence their individual function. Cardiac hepatopathy encompasses acute and chronic heart failure where a combination of acutely or sustained reduction in arterial perfusion and passive congestion leads to hypoxic hepatitis, hepatic congestion, and cardiac cirrhosis. These conditions may impair the liver function and the recognition, and diagnosis of cardiac hepatopathy is important since it can affect the prognosis and the outcome of the heart disease. There is experimental and clinical evidence that impaired liver function *per se* aggravates cardiac function. The term *cirrhotic cardiomyopathy* denotes systolic and diastolic dysfunction and presence of electrophysiological abnormalities with chronotropic incompetence, electromechanical uncoupling, and prolonged QT. Although there are clinical associations and relation to mortality, the clinical relevance of cirrhotic cardiomyopathy in terms of specific treatment needs to be clarified. Future longitudinal follow-up studies and studies on cardiovascular effects of OLT and shunt insertion should reveal the impact of normalization of cardiac function on cirrhosis. The risk and prevalence of CAD in cirrhosis are increasing due to the growing incidence of chronic liver disease related to NASH. A careful cardiac evaluation is therefore important prior to surgical procedures, TIPS insertion, or OLT in order to reduce the perioperative mortality. In turn, a careful liver assessment is warranted in candidates to HTx, as severe hepatic dysfunction often predicts an adverse outcome.

## Funding

S.M. was supported by the NovoNordisk Foundation.

## References

1. Dunn GD, Hayes P, Breen KJ, Schenker S. The liver in congestive heart failure: a review. *Am J Med Sci* 1973;**265**:174–189.



2. Kubo SH, Walter BA, John DH, Clark M, Cody RJ. Liver function abnormalities in chronic heart failure. Influence of systemic hemodynamics. *Arch Intern Med* 1987; **147**:1227–1230.
3. Batin P, Wickens M, McEntegart D, Fullwood L, Cowley AJ. The importance of abnormalities of liver function tests in predicting mortality in chronic heart failure. *Eur Heart J* 1995; **16**:1613–1618.
4. Crespo-Leiro MG, Robles O, Paniagua MJ, Marzoa R, Naya C, Flores X, Suarez F, Gomez M, Grille Z, Cuenca JJ, Castro-Beiras A, Arnal F. Reversal of cardiac cirrhosis following orthotopic heart transplantation. *Am J Transplant* 2008; **8**:1336–1339.
5. Seeto RK, Fenn B, Rockey DC. Ischemic hepatitis: clinical presentation and pathogenesis. *Am J Med* 2000; **109**:109–113.
6. Henrion J, Schapira M, Luwaert R, Colin L, Delannoy A, Heller FR. Hypoxic hepatitis: clinical and hemodynamic study in 142 consecutive cases. *Medicine (Baltimore)* 2003; **82**:392–406.
7. Mohamed R, Forsey PR, Davies MK, Neuberger JM. Effect of liver transplantation on QT interval prolongation and autonomic dysfunction in end-stage liver disease. *Hepatology* 1996; **23**:1128–1134.
8. Cazzaniga M, Salerno F, Pagnozzi G, Dionigi E, Visentin S, Cirello I, Meregaglia D, Nicolini A. Diastolic dysfunction is associated with poor survival in cirrhotic patients with transjugular intrahepatic portosystemic shunt. *Gut* 2007; **56**:869–875.
9. Sherlock S. The liver in heart failure; relation of anatomical, functional, and circulatory changes. *Br Heart J* 1951; **13**:273–293.
10. Myers RP, Cerini R, Sayegh R, Moreau R, Degott C, Lebrec D, Lee SS. Cardiac hepatopathy: clinical, hemodynamic, and histologic characteristics and correlations. *Hepatology* 2003; **37**:393–400.
11. Birrer R, Takuda Y, Takara T. Hypoxic hepatopathy: pathophysiology and prognosis. *Intern Med* 2007; **46**:1063–1070.
12. Myers RP, Lee SS. Cirrhotic cardiomyopathy and liver transplantation. *Liver Transpl* 2000; **6**:S44–S52.
13. Caraceni P, Bianchi C, Domenicali M, Maria PA, Maiolini E, Parenti CG, Nardo B, Trevisani F, Lenaz G, Bernardi M. Impairment of mitochondrial oxidative phosphorylation in rat fatty liver exposed to preservation–reperfusion injury. *J Hepatol* 2004; **41**:82–88.
14. Cogger VC, Fraser R, Le Couteur DG. Liver dysfunction and heart failure. *Am J Cardiol* 2003; **91**:1399.
15. Wanless IR, Liu JJ, Butany J. Role of thrombosis in the pathogenesis of congestive hepatic fibrosis (cardiac cirrhosis). *Hepatology* 1995; **21**:1232–1237.
16. Kavolunienė A, Vaitiekienė A, Cesnaite G. Congestive hepatopathy and hypoxic hepatitis in heart failure: A cardiologist's point of view. *Int J Cardiol* 2013; **166**: 554–558.
17. Weisberg IS, Jacobson IM. Cardiovascular diseases and the liver. *Clin Liver Dis* 2011; **15**:1–20.
18. Taylor RM, Tujios S, Jinjavadia K, Davern T, Shaikh OS, Han S, Chung RT, Lee WM, Fontana RJ. Short and long-term outcomes in patients with acute liver failure due to ischemic hepatitis. *Dig Dis Sci* 2012; **57**:777–785.
19. de Leeuw K, Meertens JH, van dH I, van der Berg AP, Ligtenberg JJ, Tulleken JE, Zijlstra JG. 'Acute liver failure': the heart may be the matter. *Acta Clin Belg* 2011; **66**:236–239.
20. Fuhrmann V, Kneidinger N, Herkner H, Heinz G, Nikfardjam M, Bojic A, Schellongowski P, Angermayr B, Kitzberger R, Warszawski J, Holzinger U, Schenk P, Madl C. Hypoxic hepatitis: underlying conditions and risk factors for mortality in critically ill patients. *Intensive Care Med* 2009; **35**:1397–1405.
21. Lau GT, Tan HC, Kritharides L. Type of liver dysfunction in heart failure and its relation to the severity of tricuspid regurgitation. *Am J Cardiol* 2002; **90**:1405–1409.
22. Poelzl G, Ess M, Mussner-Seeber C, Pachinger O, Frick M, Ulmer H. Liver dysfunction in chronic heart failure: prevalence, characteristics and prognostic significance. *Eur J Clin Invest* 2012; **42**:153–163.
23. Allen LA, Felker GM, Pocock S, McMurray JJ, Pfeffer MA, Swedberg K, Wang D, Yusuf S, Michelson EL, Granger CB. Liver function abnormalities and outcome in patients with chronic heart failure: data from the Candesartan in heart failure: Assessment of Reduction in Mortality and Morbidity (CHARM) program. *Eur J Heart Fail* 2009; **11**:170–177.
24. Ambrosy AP, Vaduganathan M, Huffman MD, Khan S, Kwasny MJ, Fought AJ, Maggioni AP, Swedberg K, Konstam MA, Zannad F, Gheorghiade M. Clinical course and predictive value of liver function tests in patients hospitalized for worsening heart failure with reduced ejection fraction: an analysis of the EVEREST trial. *Eur J Heart Fail* 2012; **14**:302–311.
25. Asrani SK, Asrani NS, Freese DK, Phillips SD, Warnes CA, Heimbach J, Kamath PS. Congenital heart disease and the liver. *Hepatology* 2012; **56**:1160–1169.
26. Wu FM, Ukomadu C, Odze RD, Valente AM, Mayer JE Jr, Earing MG. Liver disease in the patient with Fontan circulation. *Congenit Heart Dis* 2011; **6**:190–201.
27. Baek JS, Bae EJ, Ko JS, Kim GB, Kwon BS, Lee SY, Noh CI, Park EA, Lee W. Late hepatic complications after Fontan operation; non-invasive markers of hepatic fibrosis and risk factors. *Heart* 2010; **96**:1750–1755.
28. Khairy P, Fernandes SM, Mayer JE Jr, Friedman JK, Walsh EP, Lock JE, Landberg MJ. Long-term survival, modes of death, and predictors of mortality in patients with Fontan surgery. *Circulation* 2008; **117**:85–92.
29. Bergman M, Vitrai J, Salman H. Constrictive pericarditis: a reminder of a not so rare disease. *Eur J Intern Med* 2006; **17**:457–464.
30. Rose EA, Moskowitz AJ, Packer M, Sollano JA, Williams DL, Tierney AR, Heitjan DF, Meier P, Ascheim DD, Levitan RG, Weinberg AD, Stevenson LW, Shapiro PA, Lazar RM, Watson JT, Goldstein DJ, Gelijns AC. The REMATCH trial: rationale, design, and end points. Randomized evaluation of mechanical assistance for the treatment of congestive heart failure. *Ann Thorac Surg* 1999; **67**:723–730.
31. Russell SD, Rogers JG, Milano CA, Dyke DB, Pagani FD, Aranda JM, Klodell CT Jr, Boyle AJ, John R, Chen L, Massey HT, Farrar DJ, Conte JV. Renal and hepatic function improve in advanced heart failure patients during continuous-flow support with the HeartMate II left ventricular assist device. *Circulation* 2009; **120**:2352–2357.
32. Roell W, Goedje O, Vetter HO, Schmitz C, Dewald O, Reichart B. Improvement of heart-, lung-, and liver-performance during mechanical circulatory support by the Novacor-system. *Eur J Cardiothorac Surg* 1997; **11**:1045–1051.
33. Wadia Y, Etheridge W, Smart F, Wood RP, Frazier OH. Pathophysiology of hepatic dysfunction and intrahepatic cholestasis in heart failure and after left ventricular assist device support. *J Heart Lung Transplant* 2005; **24**:361–370.
34. Kamath PS, Wiesner RH, Malinchoc M, Kremers W, Therneau TM, Kosberg CL, D'Amico G, Dickson ER, Kim WR. A model to predict survival in patients with end-stage liver disease. *Hepatology* 2001; **33**:464–470.
35. Matthews JC, Pagani FD, Haft JW, Koelling TM, Naftel DC, Aaronson KD. Model for end-stage liver disease score predicts left ventricular assist device operative transfusion requirements, morbidity, and mortality. *Circulation* 2010; **121**:214–220.
36. Bonde P, Ku NC, Genovese EA, Bermudez CA, Bhama JK, Ciarleglio MM, Cong X, Teuteberg JJ, Kormos RL. Model for end-stage liver disease score predicts adverse events related to ventricular assist device therapy. *Ann Thorac Surg* 2012; **93**:1541–1547.
37. Yang JA, Kato TS, Shulman BP, Takayama H, Farr M, Jorde UP, Mancini DM, Naka Y, Schulze PC. Liver dysfunction as a predictor of outcomes in patients with advanced heart failure requiring ventricular assist device support: use of the Model of End-stage Liver Disease (MELD) and MELD eXcluding INR (MELD-XI) scoring system. *J Heart Lung Transplant* 2012; **31**:601–610.
38. Kowalski HJ, Abelman WH. The cardiac output at rest in Laennec's cirrhosis. *J Clin Invest* 1953; **32**:1025–1033.
39. Lee RF, Glenn TK, Lee SS. Cardiac dysfunction in cirrhosis. *Best Pract Res Clin Gastroenterol* 2007; **21**:125–140.
40. Liu H, Lee SS. Nuclear factor-kappaB inhibition improves myocardial contractility in rats with cirrhotic cardiomyopathy. *Liver Int* 2008; **28**:640–648.
41. Møller S, Henriksen JH. Cardiovascular complications of cirrhosis. *Gut* 2008; **57**:268–278.
42. Krag A, Bendtsen F, Mortensen C, Henriksen JH, Møller S. Effects of a single terlipressin administration on cardiac function and perfusion in cirrhosis. *Eur J Gastroenterol Hepatol* 2010; **22**:1085–1092.
43. Glenn TK, Honar H, Liu H, ter Keurs HE, Lee SS. Role of cardiac myofilament proteins titin and collagen in the pathogenesis of diastolic dysfunction in cirrhotic rats. *J Hepatol* 2011; **55**:1249–1255.
44. Bernardi M, Maggioli C, Dibra V, Zaccherini G. QT interval prolongation in liver cirrhosis: innocent bystander or serious threat? *Expert Rev Gastroenterol Hepatol* 2012; **6**:57–66.
45. Krag A, Bendtsen F, Burroughs AK, Møller S. The cardiorenal link in advanced cirrhosis. *Med Hypotheses* 2012; **79**:53–55.
46. Schrier RW. Decreased effective blood volume in edematous disorders: what does this mean? *J Am Soc Nephrol* 2007; **18**:2028–2031.
47. Henriksen JH, Fuglsang S, Bendtsen F, Christensen E, Møller S. Arterial compliance in patients with cirrhosis. High stroke volume/pulse pressure ratio as an index of elevated arterial compliance. *Am J Physiol* 2001; **280**:G584–G594.
48. Timoh T, Protano MA, Wagman G, Bloom M, Vittorio TJ. A perspective on cirrhotic cardiomyopathy. *Transplant Proc* 2011; **43**:1649–1653.
49. Møller S, Henriksen JH. Cirrhotic cardiomyopathy. *J Hepatol* 2010; **53**:179–190.
50. Wong F, Girgrah N, Graba J, Allidina Y, Liu P, Blendis L. The cardiac response to exercise in cirrhosis. *Gut* 2001; **49**:268–275.
51. Wong F. Cirrhotic cardiomyopathy. *Hepatol Int* 2009; **3**:294–304.
52. Fouad TR, Abdel-Razek WM, Burak KW, Bain VG, Lee SS. Prediction of cardiac complications after liver transplantation. *Transplantation* 2009; **87**:763–770.
53. Kazankov K, Holland-Fischer P, Andersen NH, Torp P, Sloth E, Aagaard NK, Vilstrup H. Resting myocardial dysfunction in cirrhosis quantified by tissue Doppler imaging. *Liver Int* 2011; **31**:534–540.
54. Gaskari SA, Honar H, Lee SS. Therapy insight: cirrhotic cardiomyopathy. *Nat Clin Pract Gastroenterol Hepatol* 2006; **3**:329–337.
55. Sola E, Gines P. Renal and circulatory dysfunction in cirrhosis: current management and future perspectives. *J Hepatol* 2010; **53**:1135–1145.

56. Saner FH, Neumann T, Canbay A, Treckmann JW, Hartmann M, Goerlinger K, Bertram S, Beckebaum S, Cicinnati V, Paul A. High brain-natriuretic peptide level predicts cirrhotic cardiomyopathy in liver transplant patients. *Transpl Int* 2011;**24**: 425–432.
57. Heuer AJ, Gehl A, Püschel K, Sydow K, Lohse AW, Lüth S. High rate of cardiac abnormalities in a post-mortem analysis of patients suffering from liver cirrhosis. *J Hepatol* 2011;**54**(Suppl 1),S69.
58. Inserte J, Perello A, Agullo L, Ruiz-Meana M, Schluter KD, Escalona N, Graupera M, Bosch J, Garcia-Dorado D. Left ventricular hypertrophy in rats with biliary cirrhosis. *Hepatology* 2003;**38**:589–598.
59. Wong F, Villamil A, Merli M, Romero G, Angeli P, Caraceni P, Steib CJ, Baik SK, Spinzi G, Colombato LA, Salerno F. Prevalence of diastolic dysfunction in cirrhosis and its clinical significance. *Hepatology* 2011;**54**(Suppl 1),A475–476.
60. Rabie RN, Cazzaniga M, Salerno F, Wong F. The use of E/A ratio as a predictor of outcome in cirrhotic patients treated with transjugular intrahepatic portosystemic shunt. *Am J Gastroenterol* 2009;**104**:2458–2466.
61. Holt EV, Woo G, Triletskaya M, Haeusslein EA, Shaw RE, Frederick RT. Diastolic Dysfunction Defined by E/A ratio, 1 on 2-D echo is an Independent Predictor of Liver Transplantation or Death in Patient with Cirrhosis. *J Hepatol* 2011;**54**(Suppl 1), S245–246.
62. Zambruni A, Trevisani F, Caraceni P, Bernardi M. Cardiac electrophysiological abnormalities in patients with cirrhosis. *J Hepatol* 2006;**44**:994–1002.
63. Ramond MJ, Comoy E, Lebre C. Alterations in isoprenaline sensitivity in patients with cirrhosis: evidence of abnormality of the sympathetic nervous activity. *Br J Clin Pharmacol* 1986;**21**:191–196.
64. Ruiz-Del-Arbol L, Monescillo A, Jimenez W, Garcia-Plaza A, Arroyo V, Rodes J. Paracetamol-induced circulatory dysfunction: mechanism and effect on hepatic hemodynamics in cirrhosis. *Gastroenterology* 1997;**113**:579–586.
65. Ruiz-Del-Arbol L, Uрман J, Fernandez J, Gonzalez M, Navasa M, Monescillo A, Albillos A, Jimenez W, Arroyo V. Systemic, renal, and hepatic hemodynamic derangement in cirrhotic patients with spontaneous bacterial peritonitis. *Hepatology* 2003;**38**:1210–1218.
66. Ruiz-Del-Arbol L, Monescillo A, Arocena C, Valer P, Gines P, Moreira V, Maria MJ, Jimenez W, Arroyo V. Circulatory function and hepatorenal syndrome in cirrhosis. *Hepatology* 2005;**42**:439–447.
67. Serste T, Melot C, Francoz C, Durand F, Rautou PE, Valla D, Moreau R, Lebre C. Deleterious effects of beta-blockers on survival in patients with cirrhosis and refractory ascites. *Hepatology* 2010;**52**:1017–1022.
68. Serste T, Francoz C, Durand F, Rautou PE, Melot C, Valla D, Moreau R, Lebre C. Beta-blockers cause paracetamol-induced circulatory dysfunction in patients with cirrhosis and refractory ascites: A cross-over study. *J Hepatol* 2011;**55**:794–799.
69. Krag A, Møller S, Burroughs AK, Bendtsen F. Beta-blockers induce cardiac chronotropic incompetence. *J Hepatol* 2012;**56**:298–299.
70. Bernardi M, Rubboli A, Trevisani F, Cancellieri C, Ligabue A, Baradini M, Gasbarrini G. Reduced cardiovascular responsiveness to exercise-induced sympathoadrenergic stimulation in patients with cirrhosis. *J Hepatol* 1991;**12**:207–216.
71. Henriksen JH, Fuglsang S, Bendtsen F, Christensen E, Møller S. Dyssynchronous electrical and mechanical systole in patients with cirrhosis. *J Hepatol* 2002;**36**: 513–520.
72. Bernardi M, Calandra S, Colantoni A, Trevisani F, Raimondo ML, Sica G, Schepis F, Mandini M, Simoni P, Contin M, Raimondo G. Q–T interval prolongation in cirrhosis: prevalence, relationship with severity, and etiology of the disease and possible pathogenetic factors. *Hepatology* 1998;**27**:28–34.
73. Zambruni A, Di Micoli A, Lubisco A, Domenicali M, Trevisani F, Bernardi M. QT interval correction in patients with cirrhosis. *J Cardiovasc Electrophysiol* 2007;**18**:77–82.
74. Ytting H, Henriksen JH, Fuglsang S, Bendtsen F, Møller S. Prolonged Q–T(c) interval in mild portal hypertensive cirrhosis. *J Hepatol* 2005;**43**:637–644.
75. Trevisani F, Merli M, Savelli F, Valeriano V, Zambruni A, Riggio O, Caraceni P, Domenicali M, Bernardi M. QT interval in patients with non-cirrhotic portal hypertension and in cirrhotic patients treated with transjugular intrahepatic portosystemic shunt. *J Hepatol* 2003;**38**:461–467.
76. Ward CA, Ma Z, Lee SS, Giles WR. Potassium currents in atrial and ventricular myocytes from a rat model of cirrhosis. *Am J Physiol* 1997;**273**:G537–G544.
77. Henriksen JH, Bendtsen F, Hansen EF, Møller S. Acute non-selective beta-adrenergic blockade reduces prolonged frequency-adjusted Q–T interval (QTc) in patients with cirrhosis. *J Hepatol* 2004;**40**:239–246.
78. Zambruni A, Trevisani F, Di Micoli A, Savelli F, Berzigotti A, Bracci E, Caraceni P, Domenicali M, Felline P, Zoli M, Bernardi M. Effect of chronic beta-blockade on QT interval in patients with liver cirrhosis. *J Hepatol* 2008;**48**:415–421.
79. Trevisani F, Di Micoli A, Zambruni A, Biselli M, Santi V, Erroi V, Lenzi B, Caraceni P, Domenicali M, Cavazza M, Bernardi M. QT interval prolongation by acute gastrointestinal bleeding in patients with cirrhosis. *Liver Int* 2012;**10**–3231.
80. Day PC, James FWO, Butler JT, Campbell RWF. Q–T prolongation and sudden cardiac death in patients with alcoholic liver disease. *Lancet* 1993;**341**:1423–1428.
81. Liu H, Lee SS. Acute-on-chronic liver failure: the heart and systemic hemodynamics. *Curr Opin Crit Care* 2011;**17**:190–194.
82. Matsumori A, Shimada T, Chapman NM, Tracy SM, Mason JW. Myocarditis and heart failure associated with hepatitis C virus infection. *J Card Fail* 2006;**12**:293–298.
83. Patane S, Marte F, Sturiale M, Dattilo G, Albanese A. Myocarditis and cardiomyopathy HIV associated. *Int J Cardiol* 2011;**146**:e56–e57.
84. Malavigne GN, Fernando S, Fernando DJ, Seneviratne SL. Dengue viral infections. *Postgrad Med J* 2004;**80**:588–601.
85. Herr J, Mehrfar P, Schmiedel S, Wichmann D, Brattig NW, Burchard GD, Cramer JP. Reduced cardiac output in imported plasmodium falciparum malaria. *Malar J* 2011;**10**:160.
86. Guanabens N, Bogaerde Jvd, Beynon HLC. Musculoskeletal diseases and the liver. In: Rodes J, Benhamou JP, Blei A, Reichen J, Rizzetto M, Dufour JF, Friedman SL, Gines P, Valla DC, Zoulim F (eds), *Textbook of Hepatology*, 3rd ed. Malden: Blackwell; 2007, p1694–1701.
87. Kitamura Y, Motoi M, Terada T. An autopsy case of ancient sarcoidosis associated with severe fibrosis in the liver and heart. *Pathol Int* 1998;**48**:536–541.
88. Ripoll C, Yotti R, Bermejo J, Banares R. The heart in liver transplantation. *J Hepatol* 2010;**54**:810–822.
89. Hlubocka Z, Marecek Z, Linhart A, Kejkova E, Pospisilova L, Martasek P, Aschermann M. Cardiac involvement in Wilson disease. *J Inher Metab Dis* 2002;**25**:269–277.
90. Dzung JN, Anderson LJ, Whelan CJ, Hawkins PN. Cardiac transthyretin amyloidosis. *Heart* 2012;**98**:1546–1554.
91. George A, Figueredo VM. Alcoholic cardiomyopathy: a review. *J Card Fail* 2011;**17**:844–849.
92. Gramenzi A, Caputo F, Biselli M, Kuria F, Loggi E, Andreone P, Bernardi M. Review article: alcoholic liver disease—pathophysiological aspects and risk factors. *Aliment Pharmacol Ther* 2006;**24**:1151–1161.
93. European Association for the Study of the Liver. EASL clinical practical guidelines: management of alcoholic liver disease. *J Hepatol* 2012;**57**:399–420.
94. Costanzo S, Di Castelnuovo A, Donati MB, Iacoviello L, de Gaetano G. Wine, beer or spirit drinking in relation to fatal and non-fatal cardiovascular events: a meta-analysis. *Eur J Epidemiol* 2011;**26**:833–850.
95. Estruch R, Fernandez-Sola J, Sacanella E, Pare C, Rubin E, Urbano-Marquez A. Relationship between cardiomyopathy and liver disease in chronic alcoholism. *Hepatology* 1995;**22**:532–538.
96. Gines P, Angeli P, Lenz K, Möller S, Moore K, Moreau R, Merkel C, Ring-Larsen H, Bernardi M, Garcia-Tsao G, Hayes P. EASL clinical practice guidelines on the management of ascites, spontaneous bacterial peritonitis, and hepatorenal syndrome in cirrhosis. *J Hepatol* 2010;**53**:397–417.
97. Mandell MS, Lindenfeld J, Tsou MY, Zimmerman M. Cardiac evaluation of liver transplant candidates. *World J Gastroenterol* 2008;**14**:3445–3451.
98. Therapondos G, Flapan AD, Plevris JN, Hayes PC. Cardiac morbidity and mortality related to orthotopic liver transplantation. *Liver Transpl* 2004;**10**:1441–1453.
99. Sampathkumar P, Lerman A, Kim BY, Narr BJ, Poterucha JJ, Torsher LC, Plevak DJ. Post-liver transplantation myocardial dysfunction. *Liver Transpl Surg* 1998;**4**:399–403.
100. Therapondos G, Flapan AD, Dollinger MM, Garden OJ, Plevris JN, Hayes PC. Cardiac function after orthotopic liver transplantation and the effects of immunosuppression: a prospective randomized trial comparing cyclosporin (Neoral) and tacrolimus. *Liver Transpl* 2002;**8**:690–700.
101. Torregrosa M, Aguade S, Dos L, Segura R, Gonzalez A, Evangelista A, Castell J, Margarit C, Esteban R, Guardia J, Ginesa J. Cardiac alterations in cirrhosis: reversibility after liver transplantation. *J Hepatol* 2005;**42**:68–74.
102. Adigun AQ, Pinto AG, Flockhart DA, Gorski JC, Li L, Hall SD, Chalasani N. Effect of cirrhosis and liver transplantation on the gender difference in QT interval. *Am J Cardiol* 2005;**95**:691–694.
103. Shin WJ, Kim YK, Song JG, Kim SH, Choi SS, Song JH, Hwang GS. Alterations in QT interval in patients undergoing living donor liver transplantation. *Transplant Proc* 2011;**43**:170–173.
104. Tiukinhoy-Laing SD, Rossi JS, Bayram M, De Luca L, Gafoor S, Blei A, Flamm S, Davidson CJ, Gheorghiadu M. Cardiac hemodynamic and coronary angiographic characteristics of patients being evaluated for liver transplantation. *Am J Cardiol* 2006;**98**:178–181.
105. Diedrich DA, Findlay JY, Harrison BA, Rosen CB. Influence of coronary artery disease on outcomes after liver transplantation. *Transplant Proc* 2008;**40**:3554–3557.
106. Vanwagner LB, Bhawe M, Te HS, Feinglass J, Alvarez L, Rinella ME. Patients transplanted for nonalcoholic steatohepatitis (NASH) are at increased risk for post-operative cardiovascular events. *Hepatology* 2012;**56**:1741–1750.
107. Harinstein ME, Flaherty JD, Ansari AH, Robin J, Davidson CJ, Rossi JS, Flamm SL, Blei AT, Bonow RO, Abecassis M, Gheorghiadu M. Predictive value of dobutamine

- stress echocardiography for coronary artery disease detection in liver transplant candidates. *Am J Transplant* 2008;**8**:1523–1528.
108. Raval Z, Harinstein ME, Skaro AI, Erdogan A, Dewolf AM, Shah SJ, Fix OK, Kay N, Abecassis M, Gheorghiade M, Flaherty JD. Cardiovascular risk assessment of the liver transplant candidate. *J Am Coll Cardiol* 2011;**58**:223–231.
  109. Targher G, Day CP, Bonora E. Risk of cardiovascular disease in patients with non-alcoholic fatty liver disease. *N Engl J Med* 2010;**363**:1341–1350.
  110. Axelrod D, Koffron A, Dewolf A, Baker A, Fryer J, Baker T, Frederiksen J, Horvath K, Abecassis M. Safety and efficacy of combined orthotopic liver transplantation and coronary artery bypass grafting. *Liver Transpl* 2004;**10**:1386–1390.
  111. Plotkin JS, Scott VL, Pinna A, Dobsch BP, De Wolf AM, Kang Y. Morbidity and mortality in patients with coronary artery disease undergoing orthotopic liver transplantation. *Liver Transpl Surg* 1996;**2**:426–430.
  112. Snowden CP, Hughes T, Rose J, Roberts DR. Pulmonary edema in patients after liver transplantation. *Liver Transpl* 2000;**6**:466–470.
  113. Eimer MJ, Wright JM, Wang EC, Kulik L, Blei A, Flamm S, Beahan M, Bonow RO, Abecassis M, Gheorghiade M. Frequency and significance of acute heart failure following liver transplantation. *Am J Cardiol* 2008;**101**:242–244.
  114. Nasraway SA, Klein RD, Spanier TB, Rohrer RJ, Freeman RB, Rand WM, Benotti PN. Hemodynamic correlates of outcome in patients undergoing orthotopic liver transplantation. Evidence for early postoperative myocardial depression. *Chest* 1995;**107**:218–224.
  115. Maraj S, Jacobs LE, Maraj R, Contreras R, Rerkpattanapit P, Malik TA, Manzarbeitia C, Munoz S, Rothstein K, Kotler MN. Inducible left ventricular outflow tract gradient during dobutamine stress echocardiography: an association with intraoperative hypotension but not a contraindication to liver transplantation. *Echocardiography* 2004;**21**:681–685.
  116. Auletta M, Oliviero U, Iasiuolo L, Scherillo G, Antonello S. Pulmonary hypertension associated with liver cirrhosis: an echocardiographic study. [In Process Citation]. *Angiology* 2000;**51**:1013–1020.
  117. Swanson KL, Krowka MJ. Screen for portopulmonary hypertension, especially in liver transplant candidates. *Cleve Clin J Med* 2008;**75**:121–130. 133.
  118. Lentine KL, Costa SP, Weir MR, Robb JF, Fleisher LA, Kasiske BL, Carithers RL, Ragosta M, Bolton K, Auerbach AD, Eagle KA. Cardiac disease evaluation and management among kidney and liver transplantation candidates: a scientific statement from the American Heart Association and the American College of Cardiology Foundation: endorsed by the American Society of Transplant Surgeons, American Society of Transplantation, and National Kidney Foundation. *Circulation* 2012;**126**:617–663.
  119. Christie JD, Edwards LB, Aurora P, Dobbels F, Kirk R, Rahmel AO, Stehlik J, Taylor DO, Kucheryavaya AY, Hertz MI. The Registry of the International Society for Heart and Lung Transplantation: Twenty-sixth Official Adult Lung and Heart-Lung Transplantation Report-2009. *J Heart Lung Transplant* 2009;**28**:1031–1049.
  120. Dichtl W, Vogel W, Dunst KM, Grander W, Alber HF, Frick M, Antretter H, Laufer G, Pachinger O, Polzl G. Cardiac hepatopathy before and after heart transplantation. *Transpl Int* 2005;**18**:697–702.
  121. Chokshi A, Cheema FH, Schaeffe KJ, Jiang J, Collado E, Shahzad K, Khawaja T, Farr M, Takayama H, Naka Y, Mancini DM, Schulze PC. Hepatic dysfunction and survival after orthotopic heart transplantation: application of the MELD scoring system for outcome prediction. *J Heart Lung Transplant* 2012;**31**:591–600.
  122. Hsu RB, Chang CI, Lin FY, Chou NK, Chi NH, Wang SS, Chu SH. Heart transplantation in patients with liver cirrhosis. *Eur J Cardiothorac Surg* 2008;**34**:307–312.
  123. Lee I, Localio R, Brensinger CM, Blumberg EA, Lautenbach E, Gasink L, Amorosa VK, Lo RV III. Decreased post-transplant survival among heart transplant recipients with pre-transplant hepatitis C virus positivity. *J Heart Lung Transplant* 2011;**30**:1266–1274.
  124. Kim EY, Ko HH, Yoshida EM. A concise review of hepatitis C in heart and lung transplantation. *Can J Gastroenterol* 2011;**25**:445–448.
  125. Potthoff A, Tillmann HL, Bara C, Deterding K, Pethig K, Meyer S, Haverich A, Boker KH, Manns MP, Wedemeyer H. Improved outcome of chronic hepatitis B after heart transplantation by long-term antiviral therapy. *J Viral Hepat* 2006;**13**:734–741.
  126. Te HS, Anderson AS, Millis JM, Jeevanandam V, Jensen DM. Current state of combined heart-liver transplantation in the United States. *J Heart Lung Transplant* 2008;**27**:753–759.