

# Internal Aberrations and Optical Quality After Femtosecond Laser Anterior Capsulotomy in Cataract Surgery

Kata Miháltz, MD; Michael C. Knorz, MD; Jorge L. Alió, MD, PhD; Ágnes I. Takács, MD; Kinga Kránitz, MD; Illés Kovács, MD, PhD; Zoltán Z. Nagy, MD, DSc

## ABSTRACT

**PURPOSE:** To compare ocular and internal aberrations after femtosecond laser anterior capsulotomy and continuous curvilinear capsulorrhexis in cataract surgery.

**METHODS:** In this prospective study, anterior capsulotomy was performed during cataract surgery with an intraocular femtosecond (FS) laser (Alcon LenSx Inc) in 48 eyes. As a control group, continuous curvilinear capsulorrhexis (CCC) was performed in 51 eyes. Wavefront aberrometry, corneal topography, and objective visual quality were measured using the OPD-Scan (NIDEK Co Ltd). Vertical and horizontal tilt, coma, and visual quality metrics were evaluated separately to determine whether the source of aberrations was ocular or internal. Main outcome measures included postoperative residual refraction, uncorrected and corrected visual acuities, ocular and internal aberrations, Strehl ratio, and modulation transfer function (MTF).

**RESULTS:** No statistically significant differences were noted between the FS and CCC groups, respectively, in postoperative sphere ( $-0.60 \pm 1.50$  vs  $-0.50 \pm 1.40$  diopters [D]), postoperative cylinder ( $1.30 \pm 1.01$  vs  $1.10 \pm 1.10$  D), uncorrected distance visual acuity ( $0.86 \pm 0.15$  vs  $0.88 \pm 0.08$ ), or corrected distance visual acuity ( $0.97 \pm 0.08$  vs  $0.97 \pm 0.06$ ). The FS group had significantly lower values of intraocular vertical tilt ( $-0.05 \pm 0.36$  vs  $0.27 \pm 0.57$ ) and coma ( $-0.003 \pm 0.11$  vs  $0.1 \pm 0.15$ ), and significantly higher Strehl ratios ( $0.02 \pm 0.02$  vs  $0.01 \pm 0.01$ ) and MTF values at all measured cycles per degree, compared to the CCC group.

**CONCLUSIONS:** Capsulotomy performed with an intraocular FS laser induced significantly less internal aberrations measured by the NIDEK OPD-Scan aberrometer compared to eyes that underwent CCC, which may result in better optical quality after the procedure. [*J Refract Surg.* 2011;27(10):711-716.]  
doi:10.3928/1081597X-20110913-01

Performing a precise anterior capsulorrhexis is crucial in cataract surgery. A capsulorrhexis with a 360° overlapping capsular edge prevents optic decentration, tilt, myopic shift, posterior and anterior capsular opacification due to symmetric contractile forces of the capsular bag, and shrink wrap effect.<sup>1-6</sup> In earlier reports from our research group, we have demonstrated higher precision capsulorrhexis creation and reduced lens decentration with the intraocular femtosecond laser.<sup>7,8</sup> This technology also has the potential to reduce the risk of capsular tear and intraoperative complications during cataract surgery and reduced phacoemulsification power.<sup>9</sup>

Optical quality is a subjective entity and can currently only be described indirectly by objective metrics, such as wavefront error measurements, and visual quality metrics or functional data, such as visual acuity and contrast sensitivity.<sup>10-13</sup> Wavefront analysis isolates the effect of lower order aberrations (defocus, astigmatism) and higher order aberrations, as well as the contribution of individual aberrations on optical quality. Strehl ratio, point spread function (PSF), and modulation transfer function (MTF) are parameters of the quality of an optical system including a human eye. The PSF of an optical system is the intensity distribution of light from a point source projected onto the retina and indicates the extent of blurring of the retinal image. Modulation transfer function is defined as the amplitude of the image contrast divided by the amplitude of the object contrast and is a function of spatial frequency, which could describe the reduction in contrast of sine wave stimuli by the optical medium. Modulation transfer function can be measured by directly imaging the PSF on

*From Semmelweis University Budapest, Faculty of Medicine, Department of Ophthalmology, Budapest, Hungary (Miháltz, Takács, Kránitz, Kovács, Nagy); FreeVis LASIK Center, Medical Faculty Mannheim, University of Heidelberg, Mannheim, Germany (Knorz); and the Division of Ophthalmology, Instituto Oftalmológico de Alicante, Vissum Corporation, Universidad Miguel Hernández, Alicante, Spain (Alió).*

*Drs Knorz, Alió, and Nagy are consultants for Alcon LenSx Inc. The remaining authors have no financial interest in the materials presented herein.*

*Correspondence: Kata Miháltz, MD, 1085 Budapest, Mária u. 39, Hungary. Tel: 36 70 940 8296; Fax: 36 1 317 9061; E-mail: mihaltzkata@yahoo.com*

*Received: July 13, 2011; Accepted: September 9, 2011*

the retinal surface or by calculating from wavefront aberrations.<sup>14,15</sup>

The purpose of this study was to evaluate optical and visual effects of capsulorrhexis performed by an intraocular femtosecond laser during cataract surgery compared to manually performed continuous curvilinear capsulorrhexis (CCC).

## **PATIENTS AND METHODS**

### **PATIENT POPULATION**

Femtosecond capsulotomies were performed in 48 eyes of 43 patients with cataract for IOL implantation (FS group). Continuous curvilinear capsulorrhexis by forceps was performed on 51 eyes of 38 patients, which served as a control group (CCC group). All surgeries were performed by the same surgeon (Z.Z.N.). For comparison of postoperative results, all patients were examined 6 months after surgery. Each patient underwent a complete ophthalmological evaluation. Patients with previous ocular surgery, trauma, active ocular disease, poorly dilated pupils, or known zonular weakness were excluded from the study.

The study was conducted in compliance with the Declaration of Helsinki, as well as with applicable country and local requirements regarding ethics committee/institutional review boards, informed consent, and other statutes or regulations regarding protection of the rights and welfare of human subjects participating in biomedical research.

### **SURGERY**

The surgical technique was standardized in each patient, except for the method of capsulorrhexis.

After pupillary dilation (one drop of tropicamide 0.5% every 15 minutes  $\times$  3) and instillation of topical anesthesia (proparacaine HCl 0.5%), the following procedures were performed by the femtosecond laser system: the LenSx laser system (Alcon LenSx Inc, Aliso Viejo, California) uses a curved patient interface to applanate the cornea. The location of the crystalline lens surface is determined following applanation using proprietary optical methodology. A 4.5-mm diameter capsulotomy procedure was performed by scanning a cylindrical pattern starting at least 100  $\mu$ m below the anterior capsule and ending at least 100  $\mu$ m above the capsule. Proprietary energy and spot separation parameters, which had been optimized in previous studies, were used for all laser procedures.

Following the laser procedure, a 2.8-mm biplanar clear corneal incision was created with a trapezoid knife and the cut capsule was removed with a rhexis forceps under a standard ophthalmic operating micro-

scope. The clear corneal incision was always placed at the 11-o'clock position; the side-port incision was created with a 15° steel blade at the 1-o'clock position. Corneal incision and side-port were created with the same technique in the CCC group as well. For manual capsulorrhexis procedures, a 4.5-mm diameter round corneal marker was initially used to aid the surgeon in creating the correct size and shape capsulorrhexis. Continuous curvilinear capsulorrhexis was performed with the aid of a cystotome and capsular forceps. After hydrodissection, phacoemulsification of the nucleus and aspiration of the residual cortex were performed using the Accurus (Alcon Laboratories Inc, Ft Worth, Texas) phacoemulsification machine.

All intraocular lenses (IOL) were folded and implanted in the capsular bag with the aid of an injection cartridge; the haptics were placed at the 3- and 9-o'clock positions. In all eyes in the FS and CCC groups, AcrySof MA60AC three-piece acrylic spherical IOLs (Alcon Laboratories Inc) were implanted. The IOL power was calculated using the SRK/T formula. After IOL implantation, the viscoelastic material was removed from the anterior chamber and capsular bag by irrigation/aspiration. Stromal hydration of the paracentesis and main incision ended the procedure. All incisions were left sutureless. No intra- or postoperative complications occurred. Within the first month, all patients received a combination of antibiotic and steroid eye drops (dexamethasone and tobramycin).

### **ABERROMETRY MEASUREMENTS**

Total, corneal, and internal optical aberrations were measured using the NIDEK OPD-Scan II (NIDEK Co Ltd, Gamagori, Japan). This device measures the autorefractometry, keratometry, photopic and mesopic pupil diameters, corneal topography, and wavefront aberrations simultaneously on the same axis. All wavefront aberrations were calculated and plotted with respect to the corneal vertex. The corneal topography was measured using Placido-disk technology, and the ocular wavefront was measured using the principle of skiascopic phase difference.<sup>16,17</sup> Wavefront measurements were performed in a dark room and were standardized to a 4.5-mm pupil. No dilating drop was used to assess the aberration profile of the natural view normally experienced by the patient. We chose to perform aberrometry measurements without applying mydriatic drops as we believe that results of a natural aberrometry profile are more representative for optical performances of the eye than results of a 6- or 7-mm dilated pupil. In the eye, wavefront errors typically increase with pupil size, but also a smaller aperture causes greater diffraction.<sup>14,15,18</sup>

TABLE 1

**Demographics of Patients Who Underwent Manual Continuous Curvilinear Capsulorrhexis or Femtosecond Laser Capsulotomy**

Demographic	Mean ± Standard Deviation		P Value*
	CCC Group (n=51)	FS Group (n=48)	
Age (y)	70.7±14.3	75.0±10.4	>.05
Sex (M:F)	7:31	9:34	>.05
Spherical refractive error (D)	-0.50±1.40	-0.60±1.50	>.05
Cylindrical refractive error (D)	1.10±1.10	1.30±1.01	>.05

CCC = continuous curvilinear capsulorrhexis, FS = femtosecond  
\*Unpaired t test.

Total, corneal, and internal wavefront aberrations were reconstructed using a 6th order Zernike polynomial decomposition. Visual quality was described by uncorrected (UDVA) and corrected distance visual acuity (CDVA), and by MTF and Strehl ratio. Images of PSF were depicted to demonstrate characteristic image degradation in the two groups. Point spread function is represented by a figure displaying how a point is reproduced on the retina by the eye's optical system. Strehl ratio was used to compare image quality metrics in the two groups. The Strehl ratio is defined as the ratio between the PSF of an eye and the PSF of that eye when optical quality is limited only by diffraction. It is a number between 0 and 1. The OPD-Scan provides the MTF curves from 0 to 60 cycles per degree (cpd), obtained from aberrations for the 4.5-mm optical zone. The spatial frequencies selected as landmarks were 5, 10, 15, 20, 25, 30, 35, 40, 45, 50, 55, and 60 cpd.

#### STATISTICAL ANALYSES

Statistical analyses were performed with SPSS 16.0 (SPSS Inc, Chicago, Illinois). Departure from normal distribution assumption was tested by the Shapiro-Wilks W test. Due to normality of data, descriptive statistics show mean and standard deviation. Statistical analysis was performed by comparing two samples at a time using the Student *t* test for analysis of mean visual and refractive values and intraocular optical quality parameters in both study groups. To determine predictors of Strehl ratio, multiple regression analysis was performed. Among all tested models, the best fitting model was used,<sup>19</sup> and model fit was assessed by pseudo  $r^2$  as goodness-of-fit statistics.

TABLE 2

**Ocular, Corneal, and Internal Aberrometry Parameters 6 Months After Surgery in Eyes That Underwent Continuous Curvilinear Capsulorrhexis or Femtosecond Laser Capsulotomy**

Parameter	Mean ± Standard Deviation		P Value*
	CCC Group (n=51)	FS Group (n=48)	
<b>Ocular</b>			
Vertical tilt	0.09±0.44	-0.08±0.35	>.05
Horizontal tilt	0.10±0.49	0.16±0.39	>.05
Vertical coma	0.04±0.19	-0.02±0.16	>.05
Horizontal coma	-0.01±0.16	0.02±0.14	>.05
<b>Corneal</b>			
Vertical tilt	-0.11±0.49	-0.06±0.38	>.05
Horizontal tilt	-0.05±0.41	-0.04±0.32	>.05
Vertical coma	-0.04±0.17	-0.04±0.11	>.05
Horizontal coma	-0.03±0.11	-0.02±0.12	>.05
<b>Internal</b>			
Vertical tilt	0.27±0.57	-0.05±0.36	.006
Horizontal tilt	0.15±0.59	0.16±0.63	>.05
Vertical coma	0.10±0.15	0.003±0.11	.006
Horizontal coma	0.03±0.18	0.06±0.11	>.05

CCC = continuous curvilinear capsulorrhexis, FS = femtosecond  
\*Unpaired t test.

## RESULTS

#### PATIENT CHARACTERISTICS

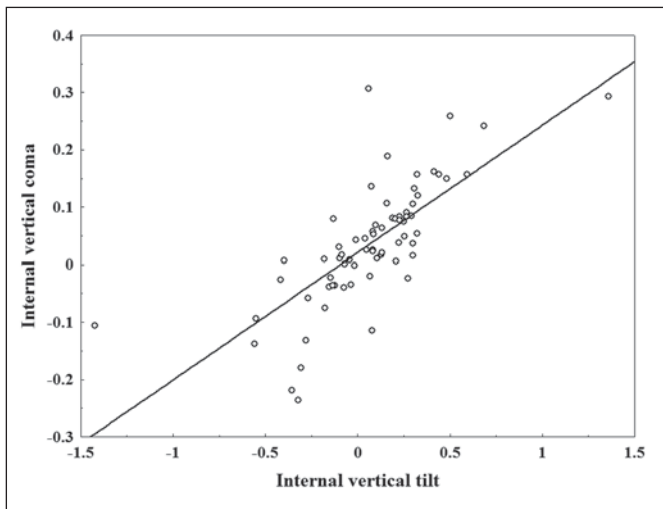
All patients were evaluated 6 months after surgery. Table 1 shows the patient demographic data and post-operative refractive error values. No statistically significant differences were noted in any variable.

#### ZERNIKE POLYNOMIALS

The FS group had significantly lower values of intraocular vertical tilt ( $Z_1^{-1}$ ) and coma ( $Z_3^{-1}$ ) aberrations compared with the CCC group ( $P=.006$ ) (Table 2). No statistically significant differences were noted in any ocular, corneal, or other internal aberrations between the two groups. Linear regression analysis showed a strong correlation ( $P<.001$ ,  $r=0.73$ ) between internal vertical coma and internal vertical tilt in both groups (Fig 1).

#### IMAGE QUALITY

Although no significant difference in UDVA or



**Figure 1.** Linear regression for internal vertical tilt and coma. Correlation is significant ( $P<.001$ ),  $r=0.73$ .

CDVA could be detected between groups, the FS group had a statistically significantly higher Strehl ratio. The MTF value was also significantly increased in the FS group at all studied cpds; the differences were statistically significant ( $P<.05$ ) for all values (Table 3).

To determine predictors of Strehl ratio, multivariable regression analysis was performed. In this model, Zernike terms that showed significant differences between groups and the most important confounders (lower order aberrations) were included. The model was fitted not only to test the additive effects of data but also included interaction terms. This model showed that after adjustment for lower order aberrations (astigmatism and defocus), the amount of internal vertical tilt had significant influence on Strehl ratio with a significant interaction between vertical tilt and coma (Table 4).

Figure 2 demonstrates PSF images of two patients, representative of the two study groups, whose visual performance, measured by Strehl ratio, was closest to the average value of the given group. The PSF plot of the CCC eye shows more astigmatic and coma-like degradation of the retinal image (see Fig 2B). On the contrary, PSF of the FS eye is smaller and round (see Fig 2A). On average, FS eyes had higher MTF performance than CCC eyes across all spatial frequencies (Fig 3).

**DISCUSSION**

Although no significant difference could be demonstrated in any ocular aberrations, the FS group had a statistically significant reduction in intraocular vertical tilt and coma aberrations. A statistically significant increase in Strehl ratio and MTF values at all studied cpds could be detected in the FS group as well, suggesting a better image quality in these patients. Aside

TABLE 3

**Visual Quality Characteristics in Eyes That Underwent Continuous Curvilinear Capsulorrhexis or Femtosecond Laser Capsulotomy**

Characteristic	CCC Group (n=51)	FS Group (n=48)	P Value*
UDVA	0.88±0.08	0.86±0.15	>.05
CDVA	0.97±0.06	0.97±0.08	>.05
Strehl ratio	0.01±0.007	0.02±0.024	.001
MTF (cpd)			
5	0.25±0.15	0.32±0.19	.04
10	0.10±0.06	0.17±0.12	.001
15	0.07±0.04	0.11±0.08	.001
20	0.05±0.04	0.08±0.07	.008
25	0.04±0.03	0.06±0.06	.003
30	0.03±0.02	0.05±0.05	.002
35	0.02±0.02	0.04±0.04	.006
40	0.02±0.02	0.04±0.04	.003
45	0.02±0.01	0.03±0.03	.005
50	0.02±0.01	0.03±0.03	.002
55	0.01±0.01	0.03±0.02	.002
60	0.01±0.01	0.02±0.02	.006

CCC = continuous curvilinear capsulorrhexis, FS = femtosecond, UDVA = uncorrected distance visual acuity, CDVA = corrected distance visual acuity, MTF = modulation transfer function, cpd = cycles per degree  
\*Unpaired t test.

from vertical tilt and coma, FS group or CCC group was also a significant predictor of Strehl ratio, confirming our hypothesis, that the type of surgery has a significant effect on the visual outcome of cataract surgery. During analysis of OPD-Scan tilt, coma, and Strehl ratio results, we excluded the influence of implanted IOL type on optical aberrations and visual quality metrics. As all implanted IOLs were of spherical design, their influence on ocular spherical aberration was equal and therefore not analyzed separately.

Tilt is a prismatic error that is not a true optical aberration because it does not induce distortion of the image, rather a shift in its position. Coma aberration is a higher order aberration, which may occur either due to the incident wavefront being tilted or decentered with respect to the optical surface. It may originate from the axial misalignment of optical surfaces.<sup>13,20-22</sup> Comatic wavefront deviation forms a blurred spot image with a comet-shaped tail, similar to the PSF image demonstrated in Figure 2B. As demonstrated



TABLE 4

**Regression Beta Coefficients for Significant Predictors of Strehl Ratio After Adjustment For Astigmatism and Defocus in Multiple Regression Modeling**

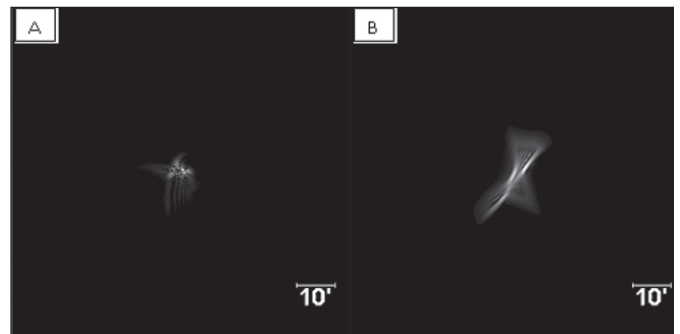
Parameters	$\beta$	95% CL	P Value
Internal vertical tilt	0.38	0.03-0.72	<.05
Interaction of internal vertical tilt and coma	1.55	0.67-2.42	<.05

CL = confidence limit

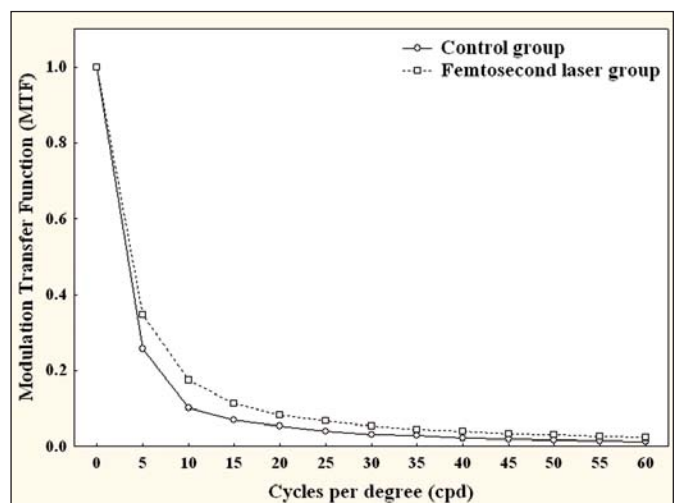
by Applegate et al,<sup>23</sup> when combined, Zernike modes can interact. A decentration of an aberration mode induces aberration of another order. For example, the translation of spherical aberration generates coma. With an increasing amount of decentration, an increasing amount of coma is introduced.<sup>24,25</sup> Thibos et al<sup>26</sup> demonstrated an existing positive correlation between modes of the same frequency, eg, between vertical coma and vertical tilt. Our results also prove a strong positive correlation between vertical tilt and coma, which according to previous theories, is due to the decentration of the IOL.

Femtosecond lasers represent an important technological advance in ophthalmic surgery. Combined with computer-controlled optical delivery systems, femtosecond lasers can produce precise surgical incisions without collateral damage to surrounding tissues.<sup>27,28</sup> A potential benefit of this new technology is that it will provide a better capsulotomy prior to implantation of aspheric or multifocal IOLs.<sup>7-9</sup> A tilted or decentered multifocal IOL or an IOL with a negative spherical aberration can induce higher asymmetrical aberrations; thus, the desired effect on the optical quality could be impaired by IOL displacement.<sup>29,30</sup>

In the present study, femtosecond laser capsulotomy resulted in decreased internal tilt and coma aberrations; however, internal aberrations may originate not only from the lens, but also from the posterior surface of the cornea. The separation of these different sources is not possible with the OPD-Scan. Dubbelman et al<sup>31,32</sup> have isolated aberrations resulting from the posterior corneal surface from those of the anterior corneal surface with the use of a Scheimpflug camera. They found a strong relationship between anterior and posterior corneal surface asphericity. They stated that the posterior corneal surface compensates approximately 3.5% of the coma of the anterior surface and that for the coma aberration of the whole eye, only the anterior corneal surface and crystalline lens play a role.<sup>31,32</sup>



**Figure 2.** Representative point spread function images in the **A**) femtosecond laser and **B**) manual continuous curvilinear capsulorrhexis (control) groups.



**Figure 3.** Modulation transfer function (MTF) in the **A**) femtosecond laser and **B**) manual continuous curvilinear capsulorrhexis (control) groups representing the average of MTF values in the sagittal and meridional directions at different spatial frequencies.

According to these findings, we can conclude that the decreased internal aberrations measured in the current study are resultant of the better IOL position due to better sizing of the capsulorrhexis performed by the femtosecond laser.

#### AUTHOR CONTRIBUTIONS

Study concept and design (K.M., J.L.A.); data collection (K.M., J.L.A., K.K., I.K.); analysis and interpretation of data (K.M., M.C.K., J.L.A., A.T., I.K., Z.Z.N.); drafting of the manuscript (K.M., I.K.); critical revision of the manuscript (K.M., M.C.K., J.L.A., A.T., K.K., I.K., Z.Z.N.); statistical expertise (I.K.); obtained funding (J.L.A., Z.Z.N.); administrative, technical, or material support (J.L.A., A.T., K.K.); supervision (J.L.A., Z.Z.N.)

#### REFERENCES

1. Dick HB, Pena-Aceves A, Manns A, Krummenauer F. New technology for sizing the continuous curvilinear capsulorrhexis: prospective trial. *J Cataract Refract Surg*. 2008;34(7):1136-1144.

2. Tan JC. Capsulotomy. *Curr Opin Ophthalmol.* 2001;12(1):82-85.
3. Ravalico G, Tognetto D, Palomba M, Busatto P, Baccara F. Capsulorrhexis size and posterior capsule opacification. *J Cataract Refract Surg.* 1996;22(1):98-103.
4. Aykan U, Bilge AH, Karadayi K. The effect of capsulorrhexis size on development of posterior capsule opacification: small (4.5 to 5.0 mm) versus large (6.0 to 7.0 mm). *Eur J Ophthalmol.* 2003;13(6):541-545.
5. Hollick EJ, Spalton DJ, Meacock WR. The effect of capsulorrhexis size on posterior capsular opacification: one-year results of a randomized prospective trial. *Am J Ophthalmol.* 1999;128(3):271-279.
6. Krueger RR, Kuszak J, Lubatschowski H, Myers RI, Ripken T, Heisterkamp A. First safety study of femtosecond laser photodisruption in animal lenses: tissue morphology and cataractogenesis. *J Cataract Refract Surg.* 2005;31(12):2386-2394.
7. Kránitz K, Takacs A, Miháltz K, Kovács I, Knorz MC, Nagy ZZ. Femtosecond laser capsulotomy and manual continuous curvilinear capsulorrhexis parameters and their effects on intraocular lens centration. *J Refract Surg.* 2011;27(8):558-563.
8. Nagy ZZ, Kránitz K, Takacs AI, Miháltz K, Kovács I, Knorz MC. Comparison of intraocular lens decentration parameters after femtosecond and manual capsulotomies. *J Refract Surg.* 2011;27(8):564-569.
9. Nagy Z, Takacs A, Filkorn T, Sarayba M. Initial clinical evaluation of an intraocular femtosecond laser in cataract surgery. *J Refract Surg.* 2009;25(12):1053-1060.
10. Baumeister M, Bühren J, Kohnen T. Tilt and decentration of spherical and aspheric intraocular lenses: effect on higher-order aberrations. *J Cataract Refract Surg.* 2009;35(6):1006-1012.
11. Mester U, Sauer T, Kaymak H. Decentration and tilt of a single-piece aspheric intraocular lens compared with the lens position in young phakic eyes. *J Cataract Refract Surg.* 2009;35(3):485-490.
12. Pieh S, Fiala W, Malz A, Stork W. In vitro strehl ratios with spherical, aberration-free, average, and customized spherical aberration-correcting intraocular lenses. *Invest Ophthalmol Vis Sci.* 2009;50(3):1264-1270.
13. Rohart C, Lemarinel B, Thanh HX, Gatinel D. Ocular aberrations after cataract surgery with hydrophobic and hydrophilic acrylic intraocular lenses: comparative study. *J Cataract Refract Surg.* 2006;32(7):1201-1205.
14. Liang J, Grimm B, Goelz S, Bille JF. Objective measurement of wave aberrations of the human eye with the use of the Hartmann-Shack wave front sensor. *J Opt Soc Am A.* 1994;11(7):1949-1957.
15. Walsh G, Charman WN, Howland HC. Objective technique for the determination of monochromatic aberrations of the eye. *J Opt Soc Am A.* 1984;1(9):987-992.
16. Gatinel D, Hoang-Xuan T. Objective assessment of the quality of vision before and after repositioning of a dislocated iris-fixated aphakic anterior chamber lens. *J Refract Surg.* 2007;23(9 Suppl):S1005-S1010.
17. Levy J, Lifshitz T, Klemperer I, et al. The effect of Nd:YAG laser posterior capsulotomy on ocular wave front aberrations. *Can J Ophthalmol.* 2009;44(5):529-533.
18. Tutt R, Bradley A, Begley C, Thibos LN. Optical and visual impact of tear break-up in human eyes. *Invest Ophthalmol Vis Sci.* 2000;41(13):4117-4123.
19. Lu M, Tilley BC; NINDS t-PA Stroke Trial Study Group. Use of odds ratio or relative risk to measure a treatment effect in clinical trials with multiple correlated binary outcomes: data from the NINDS t-PA stroke trial. *Stat Med.* 2001;20(13):1891-1901.
20. Taketani F, Matuura T, Yukawa E, Hara Y. Influence of intraocular lens tilt and decentration on wavefront aberrations. *J Cataract Refract Surg.* 2004;30(10):2158-2162.
21. Korynta J, Bok J, Cendelin J, Michalova K. Computer modeling of visual impairment caused by intraocular lens misalignment. *J Cataract Refract Surg.* 1999;25(1):100-105.
22. Dai GM. Ocular wavefront presentation. In: *Wavefront Optics for Vision Correction.* Bellingham, WA: SPIE; 2008:33-96.
23. Applegate RA, Marsack JD, Ramos R, Sarver EJ. Interaction between aberrations to improve or reduce visual performance. *J Cataract Refract Surg.* 2003;29(8):1487-1495.
24. Miháltz K, Kránitz K, Kovács I, Takács, Németh J, Nagy ZZ. Shifting of the line of sight in keratoconus measured by a Hartmann-Shack sensor. *Ophthalmology.* 2010;117(1):41-48.
25. Guirao A, Williams DR. Effect of rotation and translation on the expected benefit of an ideal method to correct the eye's higher-order aberrations. *J Opt Soc Am A Opt Image Sci Vis.* 2001;18(5):1003-1015.
26. Thibos LN, Hong X, Bradley A, Cheng X. Statistical variation of aberration structure and image quality in a normal population of healthy eyes. *J Opt Soc Am A Opt Image Sci Vis.* 2002;19(1):2329-2348.
27. Soong HK, Malta JB. Femtosecond lasers in ophthalmology. *Am J Ophthalmol.* 2009;147(2):189-197.
28. Chung SH, Mazur E. Surgical applications of femtosecond lasers. *J Biophotonics.* 2009;2(10):557-572.
29. Kohnen T, Klaproth OK, Bühren J. Effect of intraocular lens asphericity on quality of vision after cataract removal: an intra-individual comparison. *Ophthalmology.* 2009;116(9):1697-1706.
30. Holladay JT, Piers PA, Koranyi G, et al. A new intraocular lens design to reduce spherical aberration of pseudophakic eyes. *J Refract Surg.* 2002;18(6):683-691.
31. Dubbelman M, Weeber HA, van der Heijde RG, Völker-Dieben HJ. Radius and asphericity of the posterior corneal surface determined by corrected Scheimpflug photography. *Acta Ophthalmol Scand.* 2002;80(4):379-383.
32. Dubbelman M, Sicam VA, van der Heijde RG. The contribution of the posterior surface to the coma aberration of the human cornea. *J Vis.* 2007;7(7):10.1-8.