

INTERSTITIAL PNEUMONITIS IN CANINE VISCERAL LEISHMANIASIS

M. I. S. DUARTE (1), M. D. LAURENTI (2), V. L. BRANDÃO NUNES (3), A. F. REGO JR. (4),
E. T. OSHIRO (5) & C. E. P. CORBETT (1)

S U M M A R Y

Forty-one naturally infected dogs with visceral leishmaniasis from an urban area of Corumbá (Mato Grosso do Sul-BRAZIL) were studied and three types of lung involvement due to visceral leishmaniasis were characterized; a cellular, a cellular-fibrotic and a fibrotic type. These types seem to represent a sequential evolutive process. Visceral leishmaniasis frequently causes an interstitial pneumonitis in naturally infected dogs (80.5%) as well as in man and experimentally infected hamsters

KEY WORDS: Visceral leishmaniasis; Interstitial pneumonitis;
Canine pathology.

I N T R O D U C T I O N

Foci of canine visceral leishmaniasis in Brazil, together with human cases, suggest that the dog is an important host of this protozoan disease. In the Northeast of Brazil the disease is endemic (ALENCAR, 1959³; ALENCAR & CUNHA, 1983⁴; BRENER, 1957¹⁰; DEANE & DEANE, 1954¹⁶; DEANE & DEANE, 1955¹⁷; ESPINOLA GUEDES et al., 1974²² and SHERLOCK & ALMEIDA, 1969³³). Nevertheless, outbreaks of the disease have also been well characterized in other regions (I Reunião Nacional sobre Pesquisa em Leishmaniose, 1984³²). Nowadays new human cases have been reported in Brazil. New cases have been reported in São Luis (Maranhão), in the outskirts of Maceió (Alagoas), in Paraíba, in Rio de Janeiro and in Corumbá (Mato Grosso do Sul) (I Reunião Nacional sobre Pesquisa em Leishmaniose, 1984³⁴).

The histopathology of canine visceral leishmaniasis has not been well characterized so far. Few references have been reported on the identification of parasites in the tissue along with infiltrates of mononuclear inflammatory cells in different organs (ADLER & TCHERMONORETZ, 1946²; ALENCAR, 1959³; ALVARENGA, 1960⁵; ANDERSON et al. 1980⁶; BRENER, 1957¹⁰; CORBIEL et al, 1976¹³; GEORGE et al, 1976²⁴). Interstitial pneumonitis and considered to be highly suggestive of visceral leishmaniasis (DUARTE et al, 1985²¹) described in man (ANDRADE, 1959⁸ and RASO & SIQUEIRA, 1964³¹) has been found in 62.5% of the autopsy material (CHASSOT et al, 1983¹¹).

The histopathology of the lung has not been characterized so far in canine visceral

- (1) Professor Assistente Doutor do Departamento de Patologia da Faculdade de Medicina da Universidade de São Paulo, Av. Dr. Arnaldo, 455, 01246, São Paulo, Brasil
- (2) Biomédica — Laboratório de Patologia de Moléstias Infecciosas da Faculdade de Medicina da Universidade de São Paulo
- (3) Professora Titular de Parasitologia e Parasitologia Clínica do Departamento de Patologia do Centro de Ciências Biológicas e da Saúde da Universidade Federal do Mato Grosso do Sul.
- (4) Médico Veterinário — IAGRO — Departamento de Vigilância Agropecuária de Corumbá, Mato Grosso do Sul, Brasil
- (5) Médica Veterinária da Universidade Federal do Mato Grosso do Sul, Brasil

leishmaniasis. Rare cases of lung involvement were described stressing mainly the parasite's identification and concomitant secondary infections. TRYPHONAS, 1977³⁴, described a marked septal thickening characterizing an interstitial pneumonitis in the lungs of a dog living in Spain for two years together with other visceral changes. In this case no parasites were found. In 1980, ANDERSON⁶, found a diffuse multifocal septal thickening in the lungs of a dog from Texas with infiltration of plasma cells and histiocytes, some of which containing leishmania.

An outbreak of visceral leishmaniasis in Corumbá involving both men and dogs stimulated us to study the lungs of naturally infected dogs in order to characterize the histopathological changes due to the disease. Efforts were also directed to identify a possible relation between lesions found in dogs and those seen in man and hamsters.

MATERIAL AND METHODS

Forty-one dogs from Corumbá, presenting the usual clinical picture of the chronic phase of visceral leishmaniasis (ADLER & THEODOR, 1931¹; ALENCAR, 1959³; ANOSA, 1983²; BRENER, 1957¹⁰; COVALEDA, HIVES & SOLER DURALL, 1951¹⁴; CUNHA, 1938¹⁵; DONATIEN & LESTOQUARD, 1935¹⁸; FAURE-BROC, 1936²³; JOYEX & SANDET, 1938²⁵; KEENAN et al, 1984²⁶; LANNOTTE et al, 1979²⁷; LENNOX, SMART & LITTLE, 1972²⁸; MENDONZA et al, 1983²⁹; QUEIROZ, 1959³⁰ and SHERLOCK & ALMEIDA, 1969³³) were studied. The animals presented wide-spread alopecia and furfuraeous scaling mainly around the nose and eyes, cutaneous ulcers, keratitis, long nails, low weight, high body temperatures, adenomegaly, arthritis and sometimes paralysis of the hind-legs. Identification of the agent was done by examination of skin lesions, spleen and liver smears; by parasite isolation in culture medium (NNN); by inoculation in hamsters followed in some cases by leishmania typing (isoenzymes and monoclonal antibodies — J. J. SHAW — The Wellcome Parasitology Unit, Belém, Pará, BR). Parasites were also found in histopathological specimens from liver, spleen, lymph nodes and skin. All organs showed histopathological changes compatible with visceral leishmaniasis.

Fragments from lungs and other organs were collected through autopsy of the dogs and fixed in phosphate buffered saline containing 10% formalin.

Lung fragments (4 μ thick) were stained by the hematoxylin-eosin, Masson's and Picrosirius methods (CONSTANTINE & MOURAY, 1968¹²). The picro-sirius stained slides were observed under polarized light in an optical microscope.

Four dogs from the same place, without clinical signs of visceral leishmaniasis, showed neither lung nor any other organ changes which could be related to the infection. These dogs were used as controls.

RESULTS

Histopathological pulmonary changes were found in 33 out of 41 cases. The main lesion was septal thickening which intensity and distribution varied from case to case with no preference for any specific area of the lung.

Based on the characteristics of the septal thickening changes were classified in three types:

1. "Cellular" (Figure 1): in which the septal thickening was due mainly to a mononuclear cells infiltrate (lymphocytes, plasma cells, macrophages and cells with fat-containing vacuolated cytoplasm). The septal capillaries showed congestion with no endothelial changes. Pneumocytes I and II of the alveolar lining were preserved. The intensity of the mononuclear cell infiltrate varied from area to area in the same cases and no correlation with any region was seen. There was at least one area of preserved parenchyma in all cases even in those with large involvement. Vicariant emphysema was found in the most severe cases.
2. "Fibrotic-cellular" (Figure 2): in which septal changes resulted from infiltration of mononuclear cells, as in the cellular type, associated with small bands of fibrous tissue. Septal capillaries and alveolar lining showed no changes. Vicariant emphysema was present in areas of higher involvement.

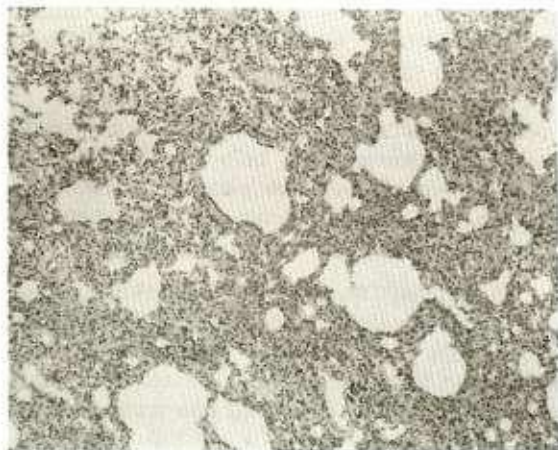

Fig. 1 — Cellular type: septal thickening by mononuclear cell infiltrate. HE X 100.

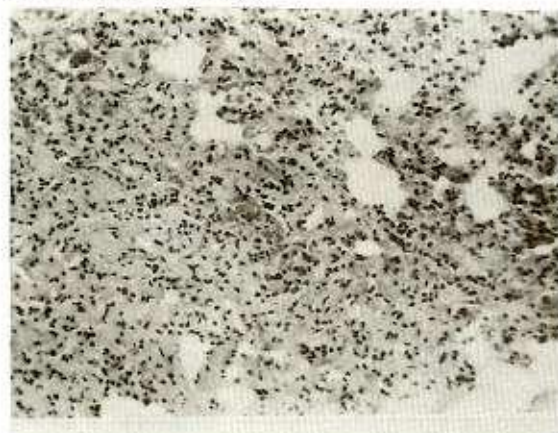

Fig. 2 — Cellular-fibrotic type: detail of the mononuclear cells infiltrate together with delicate bands of fibrous tissue within the septum. HE X 400.

3. "Fibrotic": bands of fibrous tissue thickening the intra-alveolar septum and involving large areas of the lung parenchyma were characteristic of this type. The alveolar lumen was preserved. Fibrosis was accompanied by discrete mononuclear cell infiltrate without alterations of capillaries and pneumocytes. Vicariant emphysema was related with the more fibrotic areas. Fibrosis, even thinner ones, could be demonstrated through the Picrosirius stain method when examined under polarized light (Figure 3 and 4).

In the whole there were no epithelial bronchial changes but in 2 cases there were discrete mononuclear cells infiltrate in the corium.

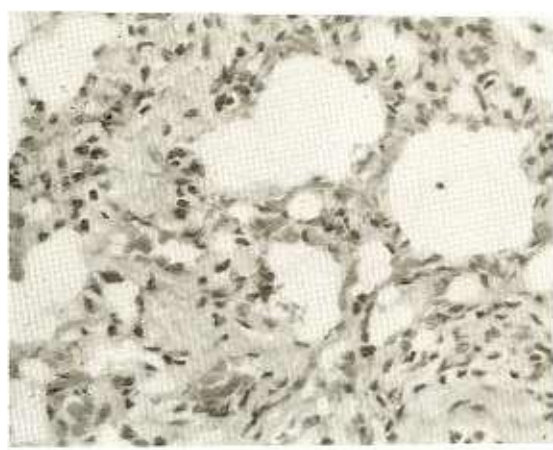


Fig. 3 — Fibrotic type: the fibrous tissue is much more evident than the mononuclear cell infiltrate. HE X 600.



Fig. 4 — Lung tissue treated with Picro-sirius stain and observed under polarized light, showing septal thickening due to collagen fibers. X 100.

The alveolar lumen had neither edema or exudation.

Amastigotes were found within the cytoplasm of either septal or alveolar macrophages only in the lungs of 3 of the cases with interstitial pneumonitis. However, numerous amastigotes were found in other tissues examined (skin, lymph nodes, spleen and liver). Eight of the cases showed no pulmonary histopathological changes.

DISCUSSION

No systematical reference on the pulmonary involvement in dogs with visceral leishmaniasis was found in the literature. There

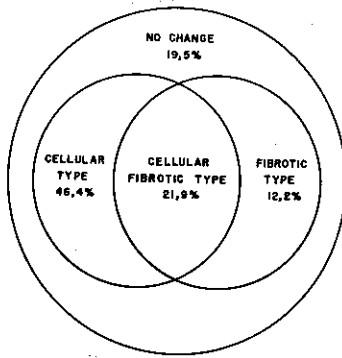


Fig. 5 — Distribution of the histopathological types of the septal thickening of the lung in 41 visceral leishmaniasis dogs.

are few reports describing bronchopneumonia as secondary infections and also few references on other pulmonary changes concurrent with this protozoan disease. GEORGE, in 1976²⁴, related "focal interstitial thickening" in one dog, TRYPHONAS, in 1977³⁴ and ANDERSON in 1980⁶, also described an "interstitial pneumonitis" in a dog, evading to suggest any relation to visceral leishmaniasis in spite of the identification of *leishmania* done by Anderson in the lung.

In this work we tried to define the pulmonary changes possible to occur in visceral leishmaniasis by studying naturally infected dogs, caught during an urban epidemic outbreak of visceral leishmaniasis in Corumbá (Mato Grosso do Sul, BR). All animals had clinical signs of the disease and parasites were identified either in smears and histological tissue sections from their organs, by isolation in culture medium or by inoculation in hamsters.

It is important to point out that all animals had histopathological characteristics of visceral leishmaniasis showing no other pulmonary changes as bronchopneumonia or any other alveolar lumen involvement.

The pulmonary changes found in naturally infected dogs were frequent (80,5%) and characterized by an interstitial pneumonitis which we believe to be related to visceral leishmaniasis.

The different patterns of septal thickening were described according to the prominence of elements participating in each case. The cellular

type (46,49%) is due mainly to a mononuclear cell infiltrate in the septum. The cellular-fibrotic type (21,9%) presents both mononuclear cell infiltrate and fibrosis. Finally, in the fibrotic type (12,2%), the septal changes originate from fibrosis. We believe that all three types represent evolutive phases of the same process. The fibrotic phase is subsequent to a previous septal inflammatory process.

In man, ANDRADE, 1958⁷ and 1959⁸, found interstitial pneumonitis in 3 out of 5 autopsies of patients with visceral leishmaniasis and considered it as part of the disease. RASO and SIQUEIRA, 1964³¹, described one more case of interstitial pneumonitis. Interstitial pneumonitis was found in 62,5% of autopsies and foci of septal fibrosis in 30% (DUARTE, M.I.S. -unpublished data). Amastigotes were rarely found (CHASSOT et al, 1983¹¹) in lungs. Using an immunoenzymatic method (PAP- peroxidase anti-peroxidase) and specific antibodies, particulate antigenic material and/or amastigotes was found in the interalveolar septum, whenever interstitial pneumonitis was present (DUARTE et al, 1985²¹). This fact confirms that septal changes are due to the disease. A few PAP tests in dog lung performed in our laboratory, showed the same results.

We have already demonstrated an interstitial pneumonitis developing in distinct stages in hamsters experimentally infected with *L. donovani* (DUARTE, 1979¹⁹; DUARTE e CORBETT, 1984²⁰). There was a exsudative stage of short duration followed by cellular proliferation and later on, by fibrosis. All sequential changes between cellular proliferation and fibrosis could be characterized as part of the same process.

Therefore visceral leishmaniasis often determines an interstitial pneumonitis, either in man, or in naturally infected dogs, or even experimentally infected hamsters. The histopathological changes seen in each case depend on the evolution of the process. There is also a similarity of histopathological changes in the three species: man, dog and hamster. Interstitial pneumonitis seems to be the pulmonary representation of an interstitial pathology of visceral leishmaniasis, also seen in others organs with interstitial lesions such as liver and kidneys.

RESUMO

Pneumonia intersticial na leishmaniose visceral canina

Estudamos 41 cães naturalmente infectados com leishmaniose visceral, provenientes da área urbana de Corumbá (Mato Grosso do Sul, BR) e caracterizamos 3 tipos de acometimento pulmonar devido à leishmaniose visceral: celular, fibrótico-celular e fibrótico. Estes tipos podem representar um processo evolutivo seqüencial. A leishmaniose visceral causa uma pneumonite intersticial em 80.5% dos cães naturalmente infectados à semelhança do que ocorre no homem e em hamsters experimentalmente infectados.

ACKNOWLEDGEMENTS

This work was supported by FINEP: 43/83/0006/00.

REFERENCES

- ADLER, S. & THEODOR, O. — Skin infection in canine visceral leishmaniasis. *Brit. med. J.*, 2: 1179, 1931
- ADLER, S. & TCHERNOMRETZ, I. — Failure to cure natural canine visceral leishmaniasis. *Ann. trop. Med. Parasit.*, 40: 320-324, 1946.
- ALENCAR, I. E. — Calazar canino. Contribuição para o estudo da epidemiologia do calazar no Brasil. Fortaleza. Imprensa Oficial, 1959.
- ALENCAR, J. E. & CUNHA, R. B. — Survey of canine Kala-azar in Ceará. Latest results. *Rev. bras. Malar.*, 15: 391-403, 1983.
- ALVARENGA, R. J. — Histopathology of Chagas disease and of Kala-azar in naturally infected dogs. *Hospital (Rio de J.)*, 57: 23-40, 1960.
- ANDERSON, D. C.; BUCKNER, R. G.; GLENN, B. L. & MACVEAN, D. W. — Endemic canine leishmaniasis. *Vet. Path.*, 17: 94-96, 1980.
- ANDRADE, Z. A. — A patologia da leishmaniose visceral (Kala-azar). Salvador, 1958. (Tese — Faculdade de Medicina da Universidade da Bahia).
- ANDRADE, Z. A. — Pneumonite intersticial no calazar. *Hospital (Rio de J.)*, 55: 71, 1959.
- ANOSA, V. O. & IDOWU, A. L. — The clinico-haematological features and pathology of leishmaniasis in a dog in Nigeria. *Zbl. Vet. Med. B.*, 30: 600-608, 1983.
- BRENER, Z. — Calazar canino em Minas Gerais. Belo Horizonte, 1957. (Tese de doutoramento — Faculdade de Medicina da Universidade de Minas Gerais).
- CHASSOT, C. A.; MORAIS, C. F.; DUARTE, M. I. S. & AMATO NETO, V. — Pneumonite intersticial da leishmaniose visceral: estudo histopatológico em necrópsias. In: CONGRESSO DA SOCIEDADE BRASILEIRA DE MEDICINA TROPICAL, 19., Rio de Janeiro, 1983. Programa e resumos. Rio de Janeiro, Imprima, 1983. p. 63.
- CONSTANTINE, V. S. & MOWRY, R. W. — Selective staining of human dermal collagen. II. The use of picosirius red F3BA with polarization microscopy. *J. invest. Derm.*, 50: 419-423, 1968.
- CORBIEL, L. B.; WRIGHT-GEORGE, J.; SHIVELY, J. N.; DUNCAN, J. R.; LA MOTTE, G. B. & SCHULTZ, E. D. — Canine visceral leishmaniasis with amyloidosis: an immunopathological case study. *Clin. Immunol. Immunopath.*, 6: 165-173, 1976.
- COVALEDA, J.; HIVES, J. & SOLER DURALL, C. — Canine leishmaniasis in Barcelona; preliminary report. *Rev. Sanid. Hig. Públ.*, 25: 710-712, 1951.
- CUNHA, A. M. — Infecção da pele na leishmaniose visceral experimental do cão. *Brasil-méd.*, 52: 1071-1072, 1936.
- DEANE, L. M. & DEANE, M. P. — Finding of dogs naturally infected with *Leishmania donovani* in Ceará. *Hospital (Rio de J.)*, 45: 703-707, 1954.
- DEANE, L. M. & DEANE, M. P. — Urban visceral leishmaniasis in dog and man in Sobral, Ceará. *Hospital (Rio de J.)*, 47: 75-87, 1955.
- DONATIEN, A. & LESTOQUARD, F. — Notes sur la leishmaniose viscérale canine. *Bull. Soc. Path. exot.*, 6: 426-431, 1935.
- DUARTE, M. I. S. — Pneumonite intersticial no calazar. São Paulo, 1979. (Tese de doutoramento — Faculdade de Medicina da Universidade de São Paulo).
- DUARTE, M. I. S. & CORBETT, C. E. P. — Histopathological and ultrastructural aspects of interstitial pneumonitis of experimental visceral leishmaniasis. *Trans. roy. Soc. trop. Med. Hyg.*, 78: 683-688, 1984.
- DUARTE, M. I. S.; MATTA, V. L. R.; GOTO, H.; ALVES, V. A. F. & CORBETT, C. E. P. — Pneumopatia na leishmaniose visceral humana: detecção de amastigotas e seus produtos em pulmão por método imunoenzimático. In: CONGRESSO DA SOCIEDADE BRASILEIRA DE MEDICINA TROPICAL, 21., São Paulo, 1985. Programa e resumos. São Paulo, Balieiro Editores, 1985. p. 106-107.
- ESPINOLA GUEDES, G.; MAROYA, A.; CHAVES, E.; ESTÉLIO, J.; CUNHA, M. J. & ARCOVERDE, S. — Calazar no litoral do Estado da Paraíba, Brasil. Encontro de 70 casos humanos e 16 caninos. *Rev. Inst. Med. trop. S. Paulo*, 18: 265-269, 1974.

23. FAURE, B. G. — La Leishmaniose canine (Sa fréquence son diagnostic clinique et biologique, son traitement). *Biol. méd. (Paris)*, 26: 113-158, 1936.
24. GEORGE, J. W.; NIELSEN, S. W.; SHIVELY, J. N.; HOPES, S. & MROZ, S. — Canine leishmaniasis with amyloidosis. *Vet. Path.*, 13: 365-373, 1976.
25. JOYEUX, C. & SANDET, J. — Observations sur la leishmaniose canine méditerranéenne. *Bull. Soc. Path. exot.*, 31: 487, 1938.
26. KEENA, C. M.; HENRICKS, L. D.; LIGHTNER, L.; WEBSTER, J. K. & JOHNSON, A. J. — Visceral leishmaniasis in the german shepherd dog. I — Infection clinical disease and clinical pathology. II — Pathology. *Vet. Path.*, 21: 74-86, 1984.
27. LANNOSTTE, G.; RIOUX, J. A.; PERIERES, J. & VOLLHARDT, Y. — Developmental stages and clinical characterization of canine leishmaniasis in relation to epidemiology. *Ann. Parasit. hum. comp.*, 54: 277-295, 1979.
28. LENNOX, W. J.; SMART, M. E. & LITTLE, P. B. — Case report. Canine leishmaniasis in Canada. *Canad. vet. J.*, 13: 188-190, 1972.
29. MENDONZA, L.; PODETTI, M.; CHAVEZ, F. & ZELLEDÓN, R. — Visceral leishmaniasis in a dog introduced into Rosta Rica. *Trans. roy. Soc. trop. Med. Hyg.*, 77: 283-284, 1983.
30. QUEIROZ, J. M. — Lesions of the eyeball and adnexa in canine Kala-azar. *Rev. Ass. med. bras.*, 5: 304-309, 1959.
31. RASO, P. & SIQUEIRA, J. T. — Subsídio ao conhecimento da anatomia patológica da leishmaniose visceral, com especial referência às lesões pulmonares e cardíacas. *Hospital (Rio de J.)*, 65: 144-163, 1964.
32. REUNIÃO NACIONAL SOBRE PESQUISA EM LEISHMANIOSE, I. — Faculdade de Medicina da Universidade de São Paulo, Departamento de Patologia, São Paulo, Brasil, 1984.
33. SHERLOCK, J. A. & ALMEIDA, S. P. — Findings on Kala-azar in Jacobina, Bahia. II — Canine leishmaniasis. *Rev. bras. Malar.*, 21: 535-539, 1969.
34. TRYPHONAS, L.; ZAWDZKA, Z.; BERNARD, M. A. & JANZEN, E. A. — Visceral leishmaniasis in a dog: clinical hematological and pathological observations. *Canad. J. comp. Med.*, 41: 1-12, 1977.

Recebido para publicação em 4/12/85.