

Intranasal Bone Gain with the Osteotome Sinus Floor Elevation Technique: A Review of the Literature

Marcello Santoro, DDS, PhD¹/Roberto Pippi, MD, DDS²

Purpose: To evaluate the mean amount of intranasal bone obtainable with the osteotome technique for transcrestal maxillary sinus elevation combined with simultaneous implant insertion, with and without the use of grafting materials. **Materials and Methods:** A review was conducted on PubMed, Scopus, and Cochrane central databases. Only human studies in which implant placement was contextual to the sinus elevation procedure, without additional crestal regenerative procedures and with a minimum 1-year follow-up, were selected. Seventeen studies were found to meet the selection criteria. **Results:** No statistically significant difference between the two procedures was detected. The mean intranasal bone gain at 3 years after surgery was 2.99 mm in cases where no grafting material was used and 4.24 mm in cases in which grafting materials were used. The mean percentage of crestal height increase at the implant site at 3 years after surgery, referring to a selection of studies with initial bone height > 4 mm, was 47.28% in procedures without grafting material and 62.68% in procedures with grafting material. A different dimensional behavior of the newly formed bone during the first 3 years after surgery was found: a slight volumetric shrinkage in grafting procedures and a slight bone increase in procedures without grafting material. No statistically significant difference in implant survival rate was found. **Conclusion:** Both osteotome transcrestal sinus elevation procedures seem to guarantee predictable short- and medium-term results with reference to the intranasal bone gain. However, the use of grafting materials, compared with their nonuse, does not seem to have substantial advantages in the short and medium term as far as mean intranasal bone gain is concerned. INT J ORAL MAXILLOFAC IMPLANTS 2018;33:995–1002. doi: 10.11607/jomi.6334

Keywords: bone substitute, dental implant, maxillary sinus floor augmentation

The crestal osteotome technique was first introduced by Tatum¹ and subsequently modified by Summers^{2,3} by elevation of the maxillary sinus floor through the alveolar ridge. It is one of the most commonly used procedures in implant practice since it allows increasing of insufficient residual bone height, which is necessary for a fixed rehabilitation on implants. This technique ensures high short- and long-term predictability of results, and it is considered less invasive, quicker, and cheaper than the lateral approach.^{4–6} Although this type of approach was first recommended in the case of residual ridges with a bone height ≥ 6 mm, it is also currently increasingly

used in considerably resorbed jaws.^{7–11} However, the use of bone substitutes in such a procedure remains an open question and is still a subject of discussion. Actually, the literature provides scarce data on the extent of the expected mean intranasal bone gain with and without bone substitutes, and data are lacking on the medium- to long-term stability of the outcomes of such procedures, all factors that may have considerable importance in the choice of the most appropriate procedure for a specific patient.¹²

The main aim of the present review was therefore to evaluate the mean amount of intranasal bone obtainable with the osteotome technique for transcrestal maxillary sinus elevation combined with simultaneous implant insertion, with and without the use of bone substitutes.

MATERIALS AND METHODS

Internet-based research was conducted on PubMed, Scopus, and Cochrane central databases without any time limit until February 2017 only for articles published in English. The search included the following

¹Specialist in Oral Surgery, Department of Odontostomatological and Maxillo Facial Sciences, “Sapienza” University of Rome, Rome, Italy.

²Associate Professor, Department of Odontostomatological and Maxillo Facial Sciences, “Sapienza” University of Rome.

Correspondence to: Dr Marcello Santoro, Department of Odontostomatological and Maxillo Facial Sciences, Via Caserta 6, 00161 Rome (Italy). Email: marcello.santoro@uniroma1.it

©2018 by Quintessence Publishing Co Inc.

keywords: osteotome and sinus lift, osteotome and sinus augmentation, osteotome and graft, crestal and sinus lift, crestal and sinus augmentation, crestal and sinus graft, crestal and membrane elevation, osteotome and sinus elevation, osteotome sinus floor elevation with graft, and osteotome sinus floor elevation without graft.

Research was conducted independently by both authors. For each keyword item, the abstract was viewed, and the articles that were considered relevant to the search criteria of this study were downloaded. Only studies that met the following criteria were selected:

- Maxillary sinus membrane elevation was performed with the crestal osteotome technique with or without application of grafting materials.^{2,3}
- Additional procedures for vertical or horizontal crestal regeneration were not performed.
- Implant placement was contextual to the sinus elevation procedure.
- The study was carried out on humans.
- The implant prosthetic loading was performed within 6 months from implant placement.
- The minimum follow-up was at least 1 year from implant placement.

The following studies were excluded:

- Studies in which the sinus elevation was performed using a technique different from the crestal osteotome technique or in which the performed technique was not described in detail
- Studies in which more types of regenerative or bone substitute materials were used, without reporting clearly distinguishable results for each material
- Studies in which the crestal elevation of the maxillary sinus floor was contextual to post-extraction implants (immediate implants) or studies in which implant placement was delayed
- Studies on cadavers and animals
- Studies in which immediate loading prosthetic procedures were used
- Studies with less than 1-year follow-up
- Technical reports and case series

Out of the total selected studies, only those from which all the following data were retrievable were included in the present review:

- The number of implants
- Both mean and standard deviation of the residual bone height before the sinus elevation procedure and implant placement were performed
- The mean follow-up
- The type of bone substitute, if used

- Both mean and standard deviation of intrasinus bone gain, at least 1 year after the procedure
- The implant survival rate
- The mean time of submerged implant healing, before implant uncovering and prosthetic rehabilitation
- The radiographic method used for comparative evaluations between preoperative and postoperative conditions

In the selected studies, additional information was analyzed regarding:

- Both the mean and standard deviation of the crestal bone loss at different intervals from the first year of follow-up
- Incidence of maxillary sinus membrane perforation during surgery
- Any kind of antibiotic therapy possibly associated with the procedure
- Type and mean length of the implant used

A cross check was also performed on the references of the selected articles, and all missing studies that met the pre-set search criteria were added. No exclusion criteria were adopted regarding the type of study conducted, with the exception of technical reports and case series. No attempt was made to identify unpublished material or to contact the authors of the excluded studies to obtain more information or missing data. Multiple studies on the same cohort of patients with assessment of the same parameters at different time intervals were not excluded from the present review. However, the results of these studies were gathered and considered part of a single investigation.

For intrasinus bone gain assessment, a descriptive analysis of the collected data was first performed by subdividing all selected articles into two different groups: sinus elevation with and without grafting material. Only randomized controlled trials (RCTs) in which it was possible to collect data relating to the comparison of the two different techniques, that is, osteotome sinus elevation with or without grafting, were subsequently selected. The possible statistical difference between their results was verified through the continuous random effect model test. To this end, the variables of interest were selected so as to enable a comparative assessment at multiple time intervals. Further evaluation was performed, without applying any exclusion criteria regarding the type of study, by comparing the results of all studies in which the sinus elevation procedure was performed without grafting material with those of the studies in which grafting materials were used, all in relation to a specific follow-up time interval and by making a direct comparison of the mean value

of intrasinus bone gain and the standard error (SE) of the mean, by using the Welch *t* test. This double statistical evaluation was performed in order to identify any large discrepancies between the results of the analysis conducted on RCTs and those of the free analysis performed on retrospective studies, prospective studies, and RCTs, without considering the type of study.

RESULTS

Out of the 337 studies found through the electronic research, 46 studies were completely downloaded and only 17 studies were selected for the present review.^{10,11,13–27} Twenty-nine studies, however, were excluded since they did not meet the inclusion criteria of the present study.^{28–56}

Data relating to each of the selected studies are summarized in Table 1.

The initial residual bone height (RBH) in the selected implant site was on average 5.73 mm (min = 2.6; max = 8.1; SE = 0.54) in procedures without grafting and 5.59 mm (min = 2.20; max = 8.20; SE = 1.10) for those with grafting. It was not possible to compare the incidence of sinus membrane perforation between procedures with and without grafting due to the frequent choice on behalf of the authors to stop the procedure or not to use any grafting materials in the case of evident perforation during surgery.

The mean follow-up and healing times before implant uncovering and prosthetic rehabilitation were 48.68 months (min = 12; max = 120; SE = 12.23) and 3.78 months (min = 2; max = 6; SE = 0.43), respectively, in procedures without grafting, and 37.12 months (min = 12; max = 60; SE = 7.62) and 3.53 months (min = 2; max = 6; SE = 1.24), respectively, in procedures with grafting.

Comparative evaluation of intrasinus bone gain between the two techniques (with and without grafting material) was possible only in relation to two time periods: 1 year and 3 years. No statistically significant difference between the two procedures was detected in relation to the crestal bone loss at 1 year ($P = .06$; 95% CI: -0.21 to 0.77) and 3 years ($P = .86$; 95% CI: -1 to 0.84).

The mean intrasinus bone gain at 1 year after surgery was 2.89 mm (SE = 0.27; min = 2.5 mm; max = 3.9 mm; 5 studies for a total number of 137 implants) in cases in which no grafting material was used,^{10,11,16,17,24} and 3.92 mm (SE = 0.55; min = 3.2 mm; max = 5 mm; 3 studies for a total number of 76 implants) in cases in which grafting materials were used^{10,11,27} ($P = .09$; 95% CI: -2.24 to 0.18).

The mean intrasinus bone gain at 3 years after surgery was 2.99 mm (SE = 0.49; min = 1.7 mm; max = 4.1 mm; 4 studies for a total number of 226

implants) in cases where no grafting material was used,^{10,11,16,19} and 4.24 mm (SE = 0.41; min = 3.2 mm; max = 5 mm; 4 studies for a total number of 169 implants) in cases in which grafting materials were used ($P = .05$; 95% CI: -2.51 to 0.01).^{10,11,19,26}

The mean intrasinus bone gain at 5 and 9 to 10 years after surgery was 3.61 mm (SE = 0.34; min = 2.95 mm; max = 4.5 mm; 4 studies^{10,16,22,23} for a total number of 371 implants) and 2.58 mm (SE = 0.42; min = 2.16 mm; max = 3 mm; 2 studies^{16,23} for a total number of 121 implants), respectively, in cases in which no grafting material was used. For these time intervals, it was not possible to assess a statistical difference with procedures in which, instead, a grafting material was used due to the lack of studies with a 9- to 10-year follow-up and because in the present analysis a single study¹⁰ with a 5-year follow-up was included, which, however, reported an extremely limited number of cases (20 implants, mean intrasinus bone gain = 4.8 ± 1.2 mm).

It was possible to compare only two RCTs^{10,11} concerning intrasinus bone gain obtained with and without grafting material at two different time intervals, without any statistically positive difference: 1 year ($P = .98$; 95% CI: -1.67 to -0.05 ; $I^2 = 0\%$); 3 years ($P = .18$; 95% CI: -1.51 to 0.20 ; $I^2 = 44\%$).

Data concerning the percentage change of intrasinus bone gain over time are summarized in Fig 1 and Table 2.^{11,13,16} Between the first and third year after surgery, sinus elevation procedures without grafting led only to positive dimensional variations and to a relative intrasinus bone gain greater than that of grafting procedures. The latter, in relation to the difference between the first and the last follow-up year, showed only negative percentage changes.

The mean percentage of crestal height increase at the implant site at 1 year after surgery was 74.35% (min = 46.30%; max = 150%; SE = 19.25) in procedures without grafting material^{10,11,16,17,24} and 117.57% (min = 49.23%; max = 227.27%; SE = 55.4) in procedures with grafting material,^{10,11,27} without any statistically significant difference ($P = .45$; 95% CI: -160.70 to 72.24).

The mean percentage of crestal height increase at the implant site at 3 years after surgery was 69.36% (min = 20.98%; max = 157.69%; SE = 23.40) in procedures without grafting material^{10,11,16,19} and 104.96% (min = 56.51%; max = 231.82%; SE = 42.35) in procedures with grafting material,^{10,11,19,26} without any statistically significant difference ($P = .46$; 95% CI: -130.86 to 59.66).

However, with a selection of only studies with initial RBH > 4 mm, the mean percentage crestal height increase at the implant site at 1 year was 51.12% (min = 46.30%; max = 53.57%; SE = 4.17) in procedures without grafting material^{11,16,17,24} and 62.73% (min = 49.23%; max = 76.23%; SE = 13.50) in procedures with grafting material,^{11,27} again without any statistically

Table 1 Overall Features of Selected Studies

	Study type	Implant n, (patient, n)	RBH (mean) ^a	Follow-up	Graft	Intra-sinus bone gain ^a (follow-up)	Crestal bone loss ^a (follow-up)	Implant survival rate
Nedir et al ¹³⁻¹⁶	PS	25 (17)	5.4 ± 2.3	12 mo 36 mo 5 y 10 y	No	2.5 ± 1.2 (1 y) 3.1 ± 1.5 (3 y) 3.2 ± 1.3 (5 y) 3.0 ± 1.4 (10 y)	1.2 ± 0.7 (1 y) 0.9 ± 0.8 (3 y) 0.8 ± 0.8 (3 y) 1.0 ± 0.9 (10 y)	100%
Nedir et al ¹⁷	PS	54 (32)	3.8 ± 1.2	12 mo	No	2.6 ± 1.7	0.2 ± 0.8	100%
Brizuela et al ¹⁸	PS	36 (36)	7.4 ± 0.4	24 mo	No	1.8 ± 0.3	0.7 ± 0.1	91.6%
Pjetursson et al ¹⁹	PS	164 88	8.1 ± 2.1 6.4 ± 1.9	38.4 mo	No Yes	1.7 ± 2 4.1 ± 2.4	– –	97.4%
Nedir et al ^{10,20,21}	RCT	17 20	2.6 ± 0.9 2.2 ± 0.8	12, 36, and 60 mo	No Yes	3.9 ± 1 (1 y) 4.1 ± 1 (3 y) 3.8 ± 1 (5 y) 5 ± 1.3 (1 y) 5.1 ± 1.2 (3 y) 4.8 ± 1.2 (5 y)	0.6 ± 0.8 (1 y) 0.6 ± 1.1 (3 y) 0.6 ± 0.9 (5 y) 0.4 ± 0.7 (1 y) 0.5 ± 0.1 (3 y) 0.7 ± 1.4 (5 y)	94.1% 90%
Zill et al ²²	RS	233 (113)	5.9 ± 1.7	5 y	No	4.5 ± 1.4	0.5 ± 0.8	93.8%
Si et al ²³	RS	96 (80)	6.75 ± 1.91	4 y to 9 y	No	2.95 ± 1.25 (4 y) 2.16 ± 1.13 (9 y)	0.46 ± 0.88 (4 y) 0.50 ± 1.69 (9 y)	90.6%
Fornell et al ²⁴	PS	21 (14)	5.6 ± 2.1	1 y	No	3 ± 2.1	Not comparable, flapless	100%
Volpe et al ²⁵	RS	29 (20)	7.2 ± 1.5	16.4 mo	No	2.8 ± 1.1	0.7 ± 0.3	100%
Chen et al ²⁶	RS	40 (37)	8.2 ± 1.7	39.2 mo	Yes	4.6 ± 1.9	–	100%
Diss et al ²⁷	PS	35 (20)	6.5 ± 1.7	12 mo	Yes	3.2 ± 1.5	–	97.1%
Si et al ¹¹	RCT	21 (21) 20 (20)	4.67 ± 1.18 4.58 ± 1.47	36 mo	Yes No	5.66 ± 0.99 (6 mo) 3.56 ± 1.82 (1 y) 3.02 ± 0.48 (2 y) 3.17 ± 1.95 (3 y) 2.06 ± 1.01 (6 mo) 2.45 ± 0.98 (1 y) 3.12 ± 0.7 (2 y) 3.07 ± 1.68 (3 y)	0.21 ± 0.23 (6 mo) 0.44 ± 0.16 (1 y) 0.65 ± 0.3 (2 y) 1.33 ± 0.46 (3 y) 0.67 ± 0.92 (6 mo) 1.28 ± 0.05 (1 y) 1.32 ± 0.45 (2 y) 1.38 ± 0.23 (3 y)	95.2% 95%

CBCT = cone beam computed tomography; mo = months; OPG = ortopantomography; P = periapical; PS = prospective study; RBH = residual bone height; RS = retrospective study; y = years; ^ain mm.

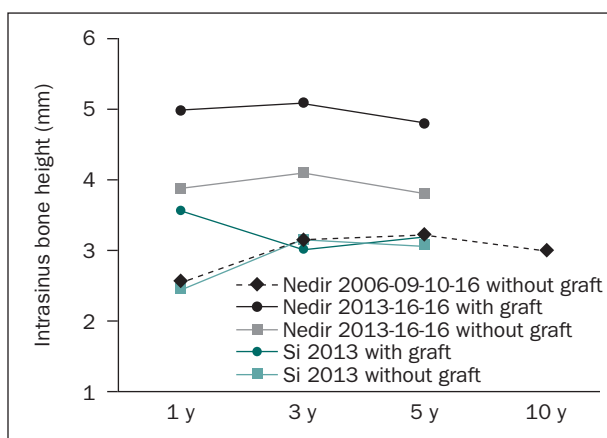


Fig 1 Intrasinus bone gain changes over time.

significant difference ($P = .41$; 95% CI: -39.83 to 16.61). The mean percentage of crestal height increase at the implant site at 3 years after surgery was 47.28%

(min = 20.98%; max = 67.03%; SE = 9.99) in procedures without grafting material^{11,16,19} and 62.68% (min = 56.51%; max = 67.88%; SE = 6.01) in procedures with grafting material,^{11,19,26} without any statistically significant difference ($P = .18$; 95% CI: -38.31 to 7.51).

Four out of five studies^{10,11,16,23} (80%) involving procedures without grafting had a 2- to 3-mm mean intrasinus bone gain at 3 years after surgery, and three studies^{10,11,16} (60%) showed a bone gain ≥ 3 mm. However, all four studies^{10,11,19,26} with grafting material (100%) found a > 3 mm bone gain.

As far as implant survival rate is concerned, out of the total number of selected studies, only two RCTs,^{10,11} with an initial mean crestal height < 5 mm, allowed the comparison of the results of both techniques (with and without grafting). Although the study of Nedir et al¹⁰ was characterized by an overall follow-up longer than that of Si et al¹¹ (5 and 3 years, respectively), no statistically significant difference in implant survival rate was found between the

Implant type	Sinus membrane perforation	Healing time	Antibiotic prophylaxis	X-rays	Implant length ^a , n
ITI-SLA	16%	3–4	Yes	P	10/21 out of 25
Straumann TE	9.5%	4.2 ± 1.6	Yes	P	8–10
Straumann AG, Klockner Implant	0%	–	Yes	P	10/32; 8/4
Straumann AG	16.6%	–	Yes	P	–
Straumann TE SLActive	0%	2.6 ± 0.9	Yes	P	8
Straumann transmucosal implant SLA	12.4%	3	Not always	P	10/201 12/27 8/4 6/1
Straumann AG	0%	3–4	–	OPG	≤ 10/41 > 10/55
Straumann SLActive	0%	2–3	Yes	CBCT	10
Neoss Ltd	0%	5	Yes	P	–
Osseotite BIOMET, TiUnite Nobel, SLA Straumann	0%	–	Yes	P	10–12/13 13–15/27
Astra Tech (micro-threaded)	–	2	Yes	P	–
SLA	0%	6	–	P	6/3 8/8 10/10 6/2 8/9 10/9

Table 2 Percentage Change of Intrasinus Bone Gain

Study	Percentage change								Overall % (from the first to the last year)	
	1 y from RBH		3 y		5 y		10 y		Graft	No graft
	Graft	No graft	Graft	No graft	Graft	No graft	Graft	No graft		
Nedir et al ^{13–16}	–	+46.30	–	+24	–	+3.23	–	–9.38	–	+20
Nedir et al ^{10,20,21}	+227.27	+150	+2	+5.13	–5.88	–7.32	–	–	–4	–2.56
Si et al ¹¹	+76.23	+53.49	–15	+27.35	+4.97	–1.60	–	–	–10.96	+25.31

RBH = residual bone height.

sinus elevation procedures with and without grafting ($P = .75$; 95% CI: 0.13 to 4.35; $I^2 = 0\%$).

DISCUSSION

The present review is the first in the literature that primarily analyzes, in the short and medium term, the

amount of intrasinus bone gain after sinus elevation by means of the transcrestal osteotome technique, with and without grafting materials, with contextual implant placement.

The need of bone substitutes in osteotome elevation of the maxillary sinus floor is still debated.

The new bone formation mechanism in cases in which any regenerative material is applied still

remains partially known and may be largely due to the sinus membrane osteoinductive action on the clot formed in the space created by the sinus membrane elevation.⁵⁷⁻⁶⁰

Several studies, however, suggest that the use of bone substitutes may play a prominent role in intrasinus bone gain promotion, acting as a scaffold and/or as a space maintainer, which prevents collapsing of the sinus membrane.^{4,61,62} However, animal studies did not show histologic advantages in relation to intrasinus bone gain using bone substitutes during the sinus elevation procedure.⁶³

The type of implant surface and the degree of implant penetration into the maxillary sinus, above the RBH, could influence the study results. Actually, a specific type of implant surface may be more advantageous in promoting bone neo-apposition than another surface. Furthermore, the amount of space created beneath the sinus membrane by the implant could affect the amount of new bone formation.^{11,63}

In addition, most of the available investigations are based on a two-dimensional radiographic comparison of intrasinus bone changes, and the reported follow-up appears to be often too short to perform long-term evaluations.

Furthermore, based on the currently available data, it is not possible to evaluate whether the intrasinus bone gain varies between single, double, or multiple adjacent sinus elevation procedures, or between intermediate and non-intermediate implants inserted with the osteotome technique. It is also impossible to evaluate if the type of final implant rehabilitation (single vs full-arch rehabilitation) could influence both the amount and the long-term stability of the intrasinus bone gain. Therefore, RCTs should be performed to assess whether all these parameters may influence short- to long-term intrasinus bone gain.

Based on the results of the present analysis, intrasinus bone gain is on average 1 mm greater in procedures with grafting compared to those without grafting, although there is no statistically significant difference both at 1 and 3 years. Actually, the mean intrasinus bone gain at 1 year after surgery is 2.89 mm in cases without grafting material, whereas it is 3.92 mm in cases with grafting. At 3 years, the mean intrasinus bone gain is 2.99 mm in cases without grafting material, whereas it is 4.24 mm in cases with grafting.

In the case of a RBH > 4 mm, after 3 years, a 47.28% mean bone intrasinus gain can be expected compared with initial bone height in procedures without grafting, and a 62.68% mean bone intrasinus gain in procedures with grafting. Although these results are not statistically significant, they may be useful in selecting the most appropriate implant length for the initial available crestal height. Actually, on the basis of a 2- to

3-mm expected bone gain in the presence of a 4- to 5-mm RBH, an 8-mm-length implant could represent the most reasonable choice, whereas in the presence of a 6- to 7-mm RBH, a 10- or 12-mm-length implant could also be used.^{12,38,40}

After 3 years, the mean intrasinus bone gain is > 2 mm in approximately 80% of the procedures without grafting and in almost 100% of the procedures with grafting, although these results resemble those of Nedir et al,²¹ who found an intrasinus bone gain > 2 mm in 93.8% of the procedures without grafting and in 100% of those with grafting. However, they are in contrast with those of Pjetursson et al,¹⁹ who found 2 or more mm of new bone in only 39.1% of procedures without grafting and in only 77.9% of those with grafting.

These differences can be explained considering that the results of the present analysis arise from a comparison of mean values of intrasinus bone gain reported by the selected studies. Out of five studies,^{10,11,16,19,23} only that of Pjetursson et al¹⁹ showed a mean intrasinus bone gain < 2 mm in procedures without grafting (1.7 mm), which is much lower than the mean of the other analyzed studies.

The present analysis also identified a different dimensional behavior of the newly formed bone during the first 3 years after surgery in procedures with and without grafting. Actually, a slight volumetric shrinkage of the grafting material always occurred between the postsurgical first and third year in grafting procedures, while a slight bone increase occurred in the same time interval in procedures without grafting material, the latter possibly due to the progressive increase of bone tissue radiopacity during its maturation. In fact, in sinus elevation procedures without grafting, only positive dimensional variations were recorded with a relative intrasinus bone gain greater than that obtained by the procedures with grafting material. In the latter, on the contrary, only negative percentage changes were recorded between the first and the last follow-up visit. These conclusions, however, arise from a rather small number of studies due to the very low availability of studies with longer follow-up periods. In 2016, Nedir et al¹⁶ analyzed 25 sinus elevation procedures without grafting and recorded a 20% intrasinus bone gain between the first and 10th follow-up year. Similarly, Si et al²³ reported a 25.31% increase in procedures without grafting and a 10.96% decrease in procedures with grafting between the first and fifth follow-up year. In a more recent RCT on significantly atrophic ridges, Nedir et al¹⁰ recorded a dimensional 4% and 2.5% decrease, respectively, in procedures with and without grafting between the first and fifth follow-up year.

Although the main aim of the present study was not to compare the survival rate of implant procedures with and without grafting, the results seem to agree

with the findings of the most recent reviews on this issue, since no statistically significant difference between the two techniques has been recorded, thus inferring a rather similar predictability rate in the short term.^{6,64}

Out of the selected studies, only two RCTs^{10,11} with an initial mean crestal height < 5 mm allowed a comparison between the results of the two techniques, without any statistically significant difference, also showing high implant survival rates up to 3 years after surgery (90.0% to 94.1% and 95.0% to 95.2%, respectively).

These results seem to support those of other studies and those of a recent meta-regression analysis,^{45,65–67} suggesting that the residual crestal height cannot decisively influence the short- and medium-term implant success, although other authors propose the use of the sinus elevation osteotome technique in cases with at least 6-mm RBH.^{7–9} However, the presence of a very small number of RCTs, their rather short follow-up, and often the lack of local bone density assessment, prevent pronounced/definite conclusions on the long-term implant success of the osteotome technique applied to greatly atrophic residual ridges.

CONCLUSIONS

The results of this study must be interpreted with great caution, due to the availability of an extremely limited number of RCTs that meet the predetermined/pre-established inclusion criteria and, consequently, due to the necessity to include prospective and retrospective studies, thus altering the level of evidence. Moreover, follow-up periods were, for the most part, unsatisfactory for a long-term evaluation of results. Both osteotome transcresal sinus elevation procedures, with and without grafting, seem to guarantee predictable short- and medium-term results with reference to the intrasinus bone gain. The use of grafting materials seems to allow approximately 1 mm more bone gain than procedures without grafting, and > 4 mm in the case of RBH. In procedures without bone grafting, a mean 47.28% bone intrasinus increase at 3 years can be expected compared with initial bone height, and a mean 62.68% bone increase in procedures with grafting, without statistically significant differences between the two techniques. Therefore, the use of grafting materials in the sinus elevation osteotome technique, compared with their nonuse, does not seem to have substantial advantages in the short and medium term as far as mean intrasinus bone gain is concerned.

ACKNOWLEDGMENTS

The authors reported no conflicts of interest related to this study.

REFERENCES

1. Tatum H Jr. Maxillary and sinus implant reconstructions. *Dent Clin North Am* 1986;30:207–229.
2. Summers RB. A new concept in maxillary implant surgery: The osteotome technique. *Compendium* 1994;15:152–160.
3. Summers RB. The osteotome technique: Part 3—Less invasive methods of elevating the sinus floor. *Compendium* 1994;15:698–708.
4. Emmerich D, Att W, Stappert C. Sinus floor elevation using osteotomes: A systematic review and meta-analysis. *J Periodontol* 2005;76:1237–1251.
5. Simon BI, Greenfield JL. Alternative to the gold standard for sinus augmentation: Osteotome sinus elevation. *Quintessence Int* 2011;42:863–871.
6. Chen MH, Shi JY. Clinical and radiological outcomes of implants in osteotome sinus floor elevation with and without grafting: A systematic review and a meta-analysis. *J Prosthodont* 2018;27:394–401.
7. Tan WC, Lang NP, Zwahlen M, Pjetursson BE. A systematic review of the success of sinus floor elevation and survival of implants inserted in combination with sinus floor elevation. Part II: Transalveolar technique. *J Clin Periodontol* 2008;35(suppl):241–254.
8. Weber HP, Morton D, Gallucci GO, Rocuzzo M, Cordaro L, Grutter L. Consensus statements and recommended clinical procedures regarding loading protocols. *Int J Oral Maxillofac Implants* 2009;24(suppl):180–183.
9. Zitzmann NU, Schärer P. Sinus elevation procedures in the resorbed posterior maxilla. Comparison of the crestal and lateral approaches. *Oral Surg Oral Med Oral Pathol Oral Radiol Endod* 1998;85:8–17.
10. Nedir R, Nurdin N, Abi Najm S, El Hage M, Bischof M. Short implants placed with or without grafting into atrophic sinuses: The 5-year results of a prospective randomized controlled study. *Clin Oral Implants Res* 2017;28:877–886.
11. Si MS, Zhuang LF, Gu YX, Mo JJ, Qiao SC, Lai HC. Osteotome sinus floor elevation with or without grafting: A 3-year randomized controlled clinical trial. *J Clin Periodontol* 2013;40:396–403.
12. Călin C, Petre A, Drafta S. Osteotome-mediated sinus floor elevation: A systematic review and meta-analysis. *Int J Oral Maxillofac Implants* 2014;29:558–576.
13. Nedir R, Bischof M, Vazquez L, Szmukler-Moncler S, Bernard JP. Osteotome sinus floor elevation without grafting material: A 1-year prospective pilot study with ITI implants. *Clin Oral Implants Res* 2006;17:679–686.
14. Nedir R, Bischof M, Vazquez L, Nurdin N, Szmukler-Moncler S, Bernard JP. Osteotome sinus floor elevation technique without grafting material: 3-year results of a prospective pilot study. *Clin Oral Implants Res* 2009;20:701–707.
15. Nedir R, Nurdin N, Vazquez L, Szmukler-Moncler S, Bischof M, Bernard JP. Osteotome sinus floor elevation technique without grafting: A 5-year prospective study. *J Clin Periodontol* 2010;37:1023–1028.
16. Nedir R, Nurdin N, Vazquez L, Abi Najm S, Bischof M. Osteotome sinus floor elevation without grafting: A 10-year prospective study. *Clin Implant Dent Relat Res* 2016;18:609–617.
17. Nedir R, Nurdin N, Szmukler-Moncler S, Bischof M. Placement of tapered implants using an osteotome sinus floor elevation technique without bone grafting: 1-year results. *Int J Oral Maxillofac Implants* 2009;24:727–733.
18. Brizuela A, Martín N, Fernández-Gonzalez FJ, Larrazábal C, Anta A. Osteotome sinus floor elevation without grafting material: Results of a 2-year prospective study. *J Clin Exp Dent* 2014;6:e479–e484.
19. Pjetursson BE, Ignjatovic D, Matuliene G, Brägger U, Schmidlin K, Lang NP. Transalveolar maxillary sinus floor elevation using osteotomes with or without grafting material. Part II: Radiographic tissue remodeling. *Clin Oral Implants Res* 2009;20:677–683.
20. Nedir R, Nurdin N, Khoury P, et al. Osteotome sinus floor elevation with and without grafting material in the severely atrophic maxilla. A 1-year prospective randomized controlled study. *Clin Oral Implants Res* 2013;24:1257–1264.
21. Nedir R, Nurdin N, Khoury P, Bischof M. Short implants placed with or without grafting in atrophic sinuses: The 3-year results of a prospective randomized controlled study. *Clin Implant Dent Relat Res* 2016;18:10–18.
22. Zill A, Precht C, Beck-Broichsitter B, et al. Implants inserted with graftless osteotome sinus floor elevation - A 5-year post-loading retrospective study. *Eur J Oral Implantol* 2016;9:277–289.
23. Si MS, Shou YW, Shi YT, Yang GL, Wang HM, He FM. Long-term outcomes of osteotome sinus floor elevation without bone grafts: A clinical retrospective study of 4–9 years. *Clin Oral Implants Res* 2016;27:1392–1400.

24. Fornell J, Johansson LÅ, Bolin A, Isaksson S, Sennerby L. Flapless, CBCT-guided osteotome sinus floor elevation with simultaneous implant installation. I: Radiographic examination and surgical technique. A prospective 1-year follow-up. *Clin Oral Implants Res* 2012;23:28–34.
25. Volpe S, Lanza M, Verrocchi D, Sennerby L. Clinical outcomes of an osteotome technique and simultaneous placement of Neoss implants in the posterior maxilla. *Clin Implant Dent Relat Res* 2013;15:22–28.
26. Chen HH, Lin YC, Lee SY, Chang LY, Chen BJ, Lai YL. Influence of sinus floor configuration on grafted bone remodeling after osteotome sinus floor elevation. *J Periodontol* 2017;88:10–16.
27. Diss A, Dohan DM, Mouhyi J, Mahler P. Osteotome sinus floor elevation using Choukroun's platelet-rich fibrin as grafting material: A 1-year prospective pilot study with microthreaded implants. *Oral Surg Oral Med Oral Pathol Oral Radiol Endod* 2008;105:572–579.
28. Spinelli D, De Vico G, Condò R, Ottria L, Arcuri C. Transcrestal guided sinus lift without grafting materials: A 36 months clinical prospective study. *Oral Implantol (Rome)* 2016;8:74–86.
29. French D, Nadji N, Shariati B, Hatzimanolakis P, Larjava H. Survival and success rates of dental implants placed using osteotome sinus floor elevation without added bone grafting: A retrospective study with a follow-up of up to 10 years. *Int J Periodontics Restorative Dent* 2016;36(suppl):s89–s97.
30. Senyilmaz DP, Kasaboglu O. Osteotome sinus floor elevation without bone grafting and simultaneous implant placement in the atrophic maxilla: A pilot study. *Indian J Dent Res* 2011;22:786–789.
31. Lindgren C, Mordenfeld A, Hallman M. A prospective 1-year clinical and radiographic study of implants placed after maxillary sinus floor augmentation with synthetic biphasic calcium phosphate or deproteinized bovine bone. *Clin Implant Dent Relat Res* 2012;14:41–50.
32. Rajkumar GC, Aher V, Ramaiya S, Manjunath GS, Kumar DV. Implant placement in the atrophic posterior maxilla with sinus elevation without bone grafting: A 2-year prospective study. *Int J Oral Maxillofac Implants* 2013;28:526–530.
33. Kolhatkar S, Cabanilla L, Bhola M. Bone-added osteotome sinus floor elevation for the deficient maxillary posterior implant site: Case series. *Compend Contin Educ Dent* 2011;32:e95–e100.
34. Diserens V, Mericske E, Mericske-Stern R. Radiographic analysis of the transcrestal sinus floor elevation: Short-term observations. *Clin Implant Dent Relat Res* 2005;7:70–78.
35. Diserens V, Mericske E, Schäppi P, Mericske-Stern R. Transcrestal sinus floor elevation: Report of a case series. *Int J Periodontics Restorative Dent* 2006;26:151–159.
36. Calvo-Guirado JL, Saez-Yuguero R, Pardo-Zamora G. Compressive osteotomes for expansion and maxilla sinus floor lifting. *Med Oral Patol Oral Cir Bucal* 2006;11:e52–e55.
37. Kim SM, Park JW, Suh JY, Sohn DS, Lee JM. Bone-added osteotome technique versus lateral approach for sinus floor elevation: A comparative radiographic study. *Implant Dent* 2011;20:465–470.
38. Ferrigno N, Laureti M, Fanali S. Dental implant placement in conjunction with osteotome sinus floor elevation: A 12-year life-table analysis from a prospective study on 588 ITI implants. *Clin Oral Implants Res* 2006;17:194–205. Erratum in: *Clin Oral Implants Res* 2006;17:479.
39. Sforza NM, Marzadori M, Zucchelli G. Simplified osteotome sinus augmentation technique with simultaneous implant placement: A clinical study. *Int J Periodontics Restorative Dent* 2008;28:291–299.
40. Pjetursson BE, Rast C, Brägger U, Schmidlin K, Zwahlen M, Lang NP. Maxillary sinus floor elevation using the (transalveolar) osteotome technique with or without grafting material. Part I: Implant survival and patients' perception. *Clin Oral Implants Res* 2009;20:667–676.
41. Leblebicioglu B, Ersanli S, Karabuda C, Tosun T, Gokdeniz H. Radiographic evaluation of dental implants placed using an osteotome technique. *J Periodontol* 2005;76:385–390.
42. Toffler M, Toscano N, Holtzclaw D. Osteotome-mediated sinus floor elevation using only platelet-rich fibrin: An early report on 110 patients. *Implant Dent* 2010;19:447–456.
43. Toffler M. Osteotome-mediated sinus floor elevation: A clinical report. *Int J Oral Maxillofac Implants* 2004;19:266–273.
44. Brägger U, Gerber C, Joss A, Haenni S, Meier A, Hashorva E, Lang NP. Patterns of tissue remodeling after placement of ITI dental implants using an osteotome technique: A longitudinal radiographic case cohort study. *Clin Oral Implants Res* 2004;15:158–166.
45. Lai HC, Zhuang LF, Lv XF, Zhang ZY, Zhang YX, Zhang ZY. Osteotome sinus floor elevation with or without grafting: A preliminary clinical trial. *Clin Oral Implants Res* 2010;21:520–526.
46. Marković A, Mišić T, Calvo-Guirado JL, Delgado-Ruiz RA, Janjić B, Abboud M. Two-center prospective, randomized, clinical, and radiographic study comparing osteotome sinus floor elevation with or without bone grafting and simultaneous implant placement. *Clin Implant Dent Relat Res* 2016;18:873–882.
47. Qin L, Lin SX, Guo ZZ, et al. Influences of Schneiderian membrane conditions on the early outcomes of osteotome sinus floor elevation technique: A prospective cohort study in the healing period. *Clin Oral Implants Res* 2017;28:1074–1081.
48. AlGhamdi AS. Osteotome maxillary sinus lift using bovine bone and calcium sulfate: A case series. *Clin Implant Dent Relat Res* 2013;15:153–159.
49. Crespi R, Capparè P, Gherlone E. Osteotome sinus floor elevation and simultaneous implant placement in grafted biomaterial sockets: 3 years of follow-up. *J Periodontol* 2010;81:344–349.
50. Nakajima K, Kusama Y. Cone beam computed tomography evaluation of bone remodeling following the osteotome sinus floor elevation technique for future site development. *Int J Periodontics Restorative Dent* 2016;36:497–505.
51. He L, Chang X, Liu Y. Sinus floor elevation using osteotome technique without grafting materials: A 2-year retrospective study. *Clin Oral Implants Res* 2013;24(suppl):s63–s67.
52. Ahn SH, Park EJ, Kim ES. Reamer-mediated transalveolar sinus floor elevation without osteotome and simultaneous implant placement in the maxillary molar area: Clinical outcomes of 391 implants in 380 patients. *Clin Oral Implants Res* 2012;23:866–872.
53. Nishida T, Takenouchi Y, Mori K, Arijii M, Nishida K, Ito K. Remodeling of autogenous bone grafts after osteotome sinus floor elevation assessed by limited cone beam computed tomography. *Int J Dent* 2013;2013:931708.
54. Fermergård R, Åstrand P. Osteotome sinus floor elevation and simultaneous placement of implants—a 1-year retrospective study with Astra Tech implants. *Clin Implant Dent Relat Res* 2008;10:62–69.
55. Fermergård R, Åstrand P. Osteotome sinus floor elevation without bone grafts—a 3-year retrospective study with Astra Tech implants. *Clin Implant Dent Relat Res* 2012;14:198–205.
56. Schmidlin PR, Müller J, Bindl A, Imfeld H. Sinus floor elevation using an osteotome technique without grafting materials or membranes. *Int J Periodontics Restorative Dent* 2008;28:401–409.
57. Lundgren S, Andersson S, Gualini F, Sennerby L. Bone reformation with sinus membrane elevation: A new surgical technique for maxillary sinus floor augmentation. *Clin Implant Dent Relat Res* 2004;6:165–173.
58. Palma VC, Magro-Filho O, de Oliveria JA, Lundgren S, Salata LA, Sennerby L. Bone reformation and implant integration following maxillary sinus membrane elevation: An experimental study in primates. *Clin Implant Dent Relat Res* 2006;8:11–24.
59. Cricchio G, Sennerby L, Lundgren S. Sinus bone formation and implant survival after sinus membrane elevation and implant placement: A 1- to 6-year follow-up study. *Clin Oral Implants Res* 2011;22:1200–1212.
60. Lundgren S, Cricchio G, Palma VC, Salata LA, Sennerby L. Sinus membrane elevation and simultaneous insertion of dental implants: A new surgical technique in maxillary sinus floor augmentation. *Periodontol* 2000 2008;47:193–205.
61. de Melo WM, de Oliveira FS, Marcantonio E Jr, Beloti MM, de Oliveira PT, Rosa AL. Autogenous bone combined with anorganic bovine bone for maxillary sinus augmentation: Analysis of the osteogenic potential of cells derived from the donor and the grafted sites. *Clin Oral Implants Res* 2014;25:603–609.
62. Yamada Y, Nakamura S, Ueda M, Ito K. Osteotome technique with injectable tissue-engineered bone and simultaneous implant placement by cell therapy. *Clin Oral Implants Res* 2013;24:468–474.
63. Si MS, Mo JJ, Zhuang LF, Gu YX, Qiao SC, Lai HC. Osteotome sinus floor elevation with and without grafting: An animal study in Labrador dogs. *Clin Oral Implants Res* 2015;26:197–203.
64. Del Fabbro M, Corbella S, Weinstein T, Ceresoli V, Taschieri S. Implant survival rates after osteotome-mediated maxillary sinus augmentation: A systematic review. *Clin Implant Dent Relat Res* 2012;14(suppl 1):e159–e168.
65. Chao YL, Chen HH, Mei CC, Tu YK, Lu HK. Meta-regression analysis of the initial bone height for predicting implant survival rates of two sinus elevation procedures. *J Clin Periodontol* 2010;37:456–465.
66. Stavropoulos A, Karring T, Kostopoulos L. Fully vs. partially rough implants in maxillary sinus floor augmentation: A randomized-controlled clinical trial. *Clin Oral Implants Res* 2007;18:95–102.
67. Pommer B, Hof M, Fädler A, Gahleitner A, Watzek G, Watzak G. Primary implant stability in the atrophic sinus floor of human cadaver maxillae: Impact of residual ridge height, bone density, and implant diameter. *Clin Oral Implants Res* 2014;25:e109–e113.