

# INTRATHORACIC KIDNEY: A CT-SCANNING VIEW

GHOLAMREZA KHAKPOUR, M.D. AND  
HAMID SOHRABPOUR, M.D.

*From the Department of Urology and Medicine, Shahid Labbaji-Nejad Medical Center, Shahid Beheshti University of Medical Sciences, Tehran, Islamic Republic of Iran.*

## ABSTRACT

We report a patient who was admitted to the department of medicine with palpitation, dyspnea and left flank pain. Chest X-ray revealed a mass in the left lung. The lesion was evaluated as a pulmonary tumor, with a high suspicion of malignancy. Intravenous urography, sonography, and CT-scanning revealed a thoracic kidney at the location previously thought to be a lung mass.

This is the first report of a CT-scanning evaluation of thoracic kidney.

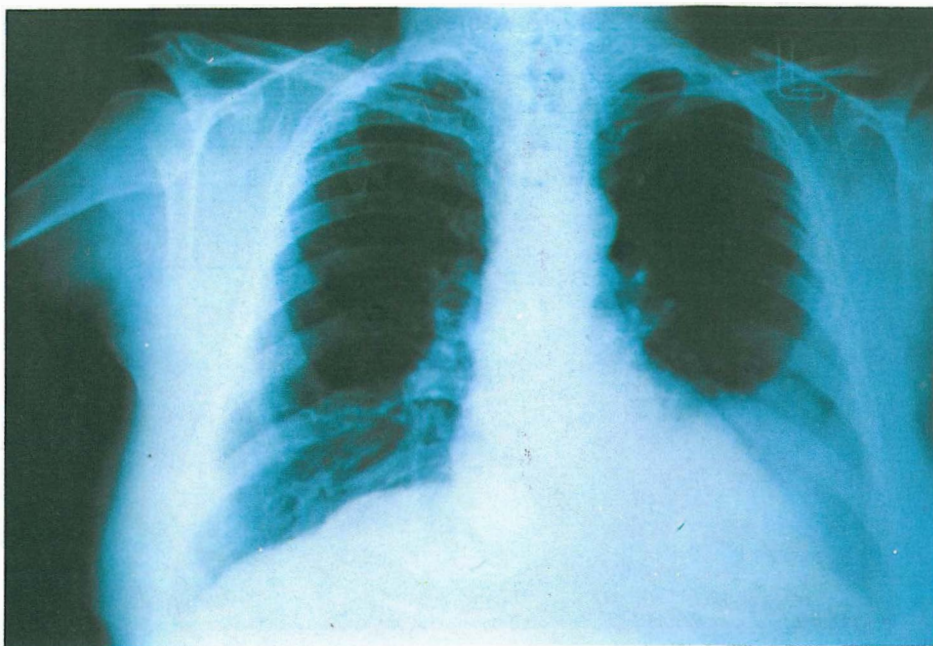
*MJIRI, Vol.2, No.2, 161-163, 1988*

## INTRODUCTION

Thoracic kidney is a very rare form of renal ectopia, in which the kidney is positioned very much higher than normal.<sup>1</sup> Diagnosis is usually made by intravenous urography (IVP). We report a CT-scanning view of this anomaly. This was performed to evaluate the flank pain and vague border of the kidney in sonography.

## CASE REPORT

A 45 year old female was referred to us because of dyspnea, palpitation and left flank pain. All symptoms began after an asthmatic attack 6 years ago. On routine workup, a chest X-ray revealed a mass in the left pulmonary cavity (Fig.1). The lesion was evaluated as a lung tumor and suspected of malignancy. IVP revealed



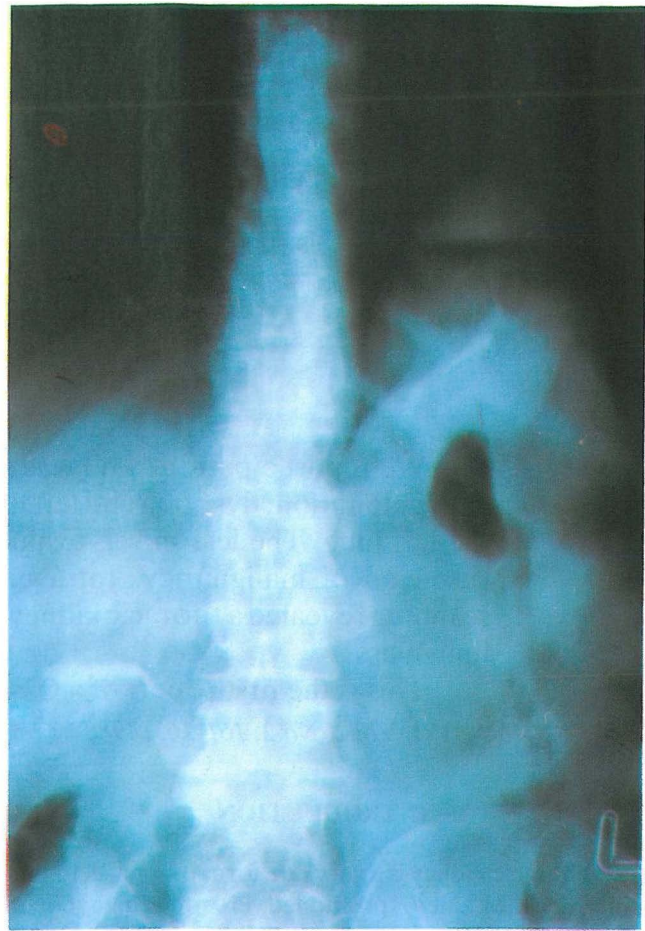
**Figure 1:** Chest X Ray reveals a mass in left lower area of the left thoracic cavity.

a thoracic kidney at the site of the suspected lung mass (Fig.2). Because of left flank pain, renal sonography was performed in which the border of the left kidney was reported as suspicious. CT-scanning revealed the left kidney to be surrounded by lung tissue, separated from it by perirenal fat. No kidney existed in the left retroperitoneal area in the normal location of the left kidney Fig 3.

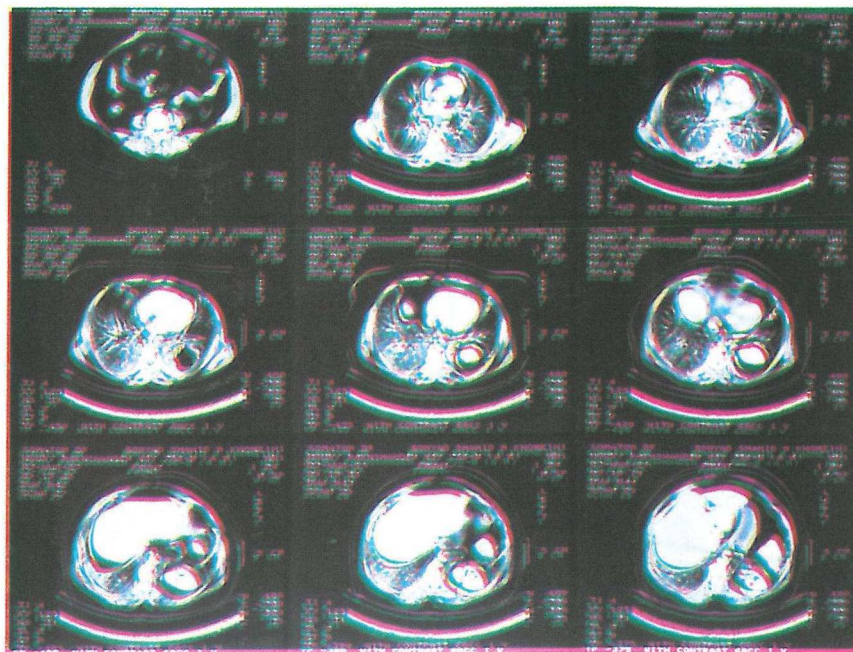
### DISCUSSION

Thoracic kidney is a very rare form of renal ectopia in which the kidney is positioned very much higher than normal. This condition is to be differentiated from a congenital or traumatic diaphragmatic hernia in which other abdominal organs with or without kidney have protruded into the chest cavity. Before 1940, all reports of this anomaly involved only autopsy findings.<sup>2</sup> Since 1940 however, almost 83 cases have been reported in the literature, three of which have involved bilateral kidneys.<sup>3</sup>

There appears to be a slight left-sided predominance (1.05/1), and it is three times more common in males.<sup>4</sup> This condition has been found in all age groups.<sup>5</sup> Embryologically, the kidney reaches the adult location at the end of eight weeks of gestation. At this time, the diaphragmatic membrane is formed as the pleuro-peritoneal membrane separates the pleural cavity from the peritoneal cavity. Delayed closure of the diaphragmatic membrane allows for accentuated



**Figure 2:** IVU reveals thoracic kidney in the left chest cavity. this was first assumed as a possible lung tumor (Fig 1).



**Figure 3:** C.T. Scanning view of the thoracic kidney. The kidney is surrounded by perinephric fat and lung tissue.

renal ascent above the level of the future diaphragm.<sup>6</sup>

Renal angiography has demonstrated a normal site of origin of the renal artery from the aorta, supplying the thoracic kidney.<sup>7</sup>

The kidney is situated in the posterior mediastinum and usually has completed normal rotation.

There are anomalies associated with intrathoracic kidney. The ureter is elongated to accommodate the excessive distance to the bladder. The adrenal gland is below the kidney in its normal location in the majority of the patients. The adrenal gland has been mentioned in only two reports. In one case it accompanied the kidney in the chest cavity and in the other it was placed just higher than normal position.<sup>9</sup>

The contralateral kidney was normal. One child had trisomy 18, and another patient had multiple pulmonary and cardiac anomalies.<sup>10</sup>

The vast majority of patients with this anomaly have remained asymptomatic. Pulmonary symptoms are exceedingly rare. Most cases are discovered on routine chest X-rays or at the time of thoracotomy for a suspected mediastinal mass.<sup>11</sup>

The diagnosis is most commonly made following a routine chest X-ray, IVP, retrograde pyelography, and sonography.<sup>10</sup> Prognosis is good and no treatment is necessary.

## REFERENCES

- 1- Campbell MF: Renal ectopy. *J Urol* 24:187, 1930.
- 2- De Castro FJ, Schumacher J: Asymptomatic thoracic kidney. *Clin Pediatr (Phila)* 8: 274-80, 1969.
- 3- Berlin HS, Stein J, Poppel MH: Congenital superior ectopia of the kidney. *Am J Roentgenol Radium Ther Nucl Med* 78 (3): 508-17, 1957.
- 4- Lozano RH, Rodriguez C: Intrathoracic ectopic kidney: report of a case. *J Urol* 114:601-2, 1975.
- 5- Shapira E, Fishel E, Levin S: Intrathoracic kidney in a premature infant. *Arch Dis Child* 40: 86-8, 1965.
- 6- Burke EC, Wenzl JE, Utz D C. The intrathoracic kidney. Report of a case, *Am J Dis Child*.
- 7- Lundius B: Intrathoracic kidney, *Am J Roentgenol Radium Ther Nucl Med.* 125 (3): 678-81, 1975.
- 8- N'Guessen G, Stephens FD, Pick J: Congenital superior ectopic (thoracic) kidney. *Urology* 24 (3): 219-28, 1984.
- 9- Barloon JW, Goodwin WF: Thoracic kidney: Case reports. *J Urol* 78 (4): 356-8, 1957.
- 10- Fusonie D, Molnar W: Anomalous pulmonary venous return, pulmonary sequestration, bronchial atresia, aplastic right upper lobe, pericardial defect and intrathoracic kidney. An unusual complex of congenital anomalies in one patient. *Amer J Roentgen* 97: 350-4, 1966.
- 11- De Noronha LL, Costa MFE, Godinho MTM: Thoracic kidney. *Am Rev Respir Dis* 109 (6): 678-81, 1974.