

Intravascular Ultrasound-Derived Minimal Lumen Area Criteria for Functionally Significant Left Main Coronary Artery Stenosis

Seung-Jung Park, MD, PhD,* Jung-Min Ahn, MD,* Soo-Jin Kang, MD,* Sung-Han Yoon, MD,*
Bon-Kwon Koo, MD,† Jong-Young Lee, MD,* Won-Jang Kim, MD,* Duk-Woo Park, MD,*
Seung-Whan Lee, MD,* Young-Hak Kim, MD,* Cheol Whan Lee, MD,* Seong-Wook Park, MD, PhD*

ABSTRACT

OBJECTIVES This study sought to evaluate the intravascular ultrasound (IVUS) minimal lumen area (MLA) for functionally significant left main coronary artery (LMCA) stenosis using fractional flow reserve (FFR) as the standard.

BACKGROUND The evaluation of significant LMCA stenosis remains challenging.

METHODS We identified 112 patients with isolated ostial and shaft intermediate LMCA stenosis (angiographic diameter stenosis of 30% to 80%) who underwent IVUS and FFR measurement.

RESULTS The FFR was ≤ 0.80 in 66 LMCA lesions (59%); these exhibited smaller reference vessels, smaller minimal lumen diameter, greater diameter of stenosis, longer lesion length, smaller MLA, larger plaque burden, and more frequent plaque rupture. The independent factors of an FFR of ≤ 0.80 were plaque rupture (odds ratio [OR]: 4.47; 95% Confidence Interval [CI]: 1.35 to 14.8; $p = 0.014$); body mass index (OR: 1.19; 95% CI: 1.00 to 1.41; $p = 0.05$), age (OR: 0.95; 95% CI: 0.90 to 1.00; $p = 0.031$), and IVUS MLA (OR: 0.37; 95% CI: 0.25 to 0.56; $p < 0.001$). The optimal IVUS MLA cutoff value for an FFR of ≤ 0.80 was 4.5 mm^2 (77% sensitivity, 82% specificity, 84% positive predictive value, 75% negative predictive value, area under the curve: 0.83, 95% CI: 0.76 to 0.96; $p < 0.001$) overall and 4.1 to 4.5 mm^2 in various subgroups. Adjustment for the body surface area, body mass index, and left ventricular mass did not improve the diagnostic accuracy of the IVUS MLA.

CONCLUSIONS In patients with isolated ostial and shaft intermediate LMCA stenosis, an IVUS-derived MLA of $\leq 4.5 \text{ mm}^2$ is a useful index of an FFR of ≤ 0.80 . (J Am Coll Cardiol Intv 2014;7:868-74) © 2014 by the American College of Cardiology Foundation.

Because of the limitations on the assessment of the severity of left main coronary artery (LMCA) stenosis, the intravascular ultrasound (IVUS)-derived minimal lumen area (MLA) has frequently been used as a surrogate marker of significant

LMCA stenosis. An IVUS MLA of 6 mm^2 has conventionally been considered an indication for revascularization, and this criterion was supported by a recent prospective registry study (1,2). However, this cutoff value may overestimate the actual

From the *Department of Cardiology, University of Ulsan College of Medicine, Asan Medical Center, Seoul, South Korea; and the †Department of Internal Medicine and Cardiovascular Center, Seoul National University Hospital, Seoul, South Korea. The study is supported by the Korea Healthcare Technology Research and Development Project, Ministry of Health and Welfare (#A120711), and CardioVascular Research Foundation, Seoul, Republic of Korea. Dr. Koo has received lecture fees and a research grant from St. Jude Medical. All other authors have reported that they have no relationships relevant to the contents of this paper to disclose. Dr. S.-J. Park and Dr. Ahn contributed equally to this paper.

Manuscript received June 25, 2013; revised manuscript received February 7, 2014, accepted February 13, 2014.

functional significance of stenosis and thereby increase the rate of unnecessary percutaneous coronary intervention.

Recently, we reported that a more stringent IVUS MLA cutoff value of 4.8 mm² better corresponded to a fractional flow reserve (FFR) of ≤ 0.80 in patients with isolated LMCA stenosis (3). However, that study was limited by its small sample population. Therefore, we expanded the study population and re-evaluated the optimal IVUS-derived parameters for the functional significance of isolated LMCA stenosis. In addition, we performed various subgroup analyses and adjustments of the IVUS MLA for several anthropometric measurements to determine how patient characteristics affected the optimal cutoff value.

METHODS

STUDY POPULATION. Between January 1, 2010 and December 31, 2012, 112 patients with isolated ostial and shaft LMCA stenosis that had been evaluated by FFR and IVUS before intervention were identified from an IVUS and FFR database. Patients with abnormal regional wall motion, significant distal lesions (angiographic diameter stenosis of $>50\%$ within the left anterior descending artery or left circumflex artery), myocardial infarction, angiographic evidence of thrombi-containing lesions, and those in whom the IVUS-imaging catheter failed to cross the lesion due to severe stenosis or tortuosity were excluded. The treatment strategy was left to the operator's discretion. This study was approved by the institutional review board, and all patients provided written informed consent.

ANGIOGRAPHIC ANALYSIS. Quantitative coronary angiographic (QCA) measurements, including the percentage of diameter stenosis, reference vessel diameter, and minimal luminal diameter, were acquired using standard techniques with automated edge-detection algorithms (CAAS-5, Pie-Medical, Maastricht, the Netherlands) in the angiographic analysis center of the CardioVascular Research Foundation (Seoul, Korea). Angiographic image acquisition was performed at target sites using ≥ 2 angiographic projections of the coronary narrowing. The reference diameter was determined by interpolation outside the obstructions boundaries but within LMCA (4).

FFR MEASUREMENT. Equalization was performed with the guidewire sensor positioned at the tip of the guiding catheter. Then, a 0.014-inch pressure guidewire (Radi, St. Jude Medical, Uppsala, Sweden) was advanced into the coronary artery and positioned

≥ 3 cm distal to the LM lesion in either the left anterior descending or left circumflex artery, depending on which was least diseased distally. The FFR was measured under maximal hyperemia induced by an intravenous adenosine infusion administered through a central vein at 140 to 280 $\mu\text{g}/\text{kg}/\text{min}$. Hyperemic pressure pull-back recordings were performed as previously described (3). In patients with an ostial LM stenosis, care was taken to withdraw the guiding catheter from the LM during FFR assessment.

IVUS IMAGING AND ANALYSIS. After FFR assessment, IVUS imaging was performed after intracoronary administration of 0.2 mg nitroglycerin using motorized transducer pullback (0.5 mm/s) and a commercial scanner (Boston Scientific/SCIMED, Minneapolis, Minnesota) consisting of a rotating 40-MHz transducer within a 3.2-F imaging sheath. Off-line quantitative IVUS analysis was performed in a core laboratory at the Asan Medical Center using computerized planimetry (EchoPlaque 3.0, Indec Systems, Mountain View, California) as previously described (5). The MLA and external elastic membrane area were measured at the site within the LM coronary segment above the carina at which the lumen was smallest. The plaque burden at the MLA site was calculated as (external elastic membrane area - lumen area) / external elastic membrane area $\times 100$ (%). To determine the reproducibility of the measurements, MLA in 20 randomly selected patients were analyzed at different times by 2 independent blinded observers and by the same observer. Inter- and intraobserver variability were assessed using the 2-way random single measure intraclass correlation coefficient and the 1-way random 2-measure intraclass correlation coefficient, respectively. The inter- and intraobserver agreements regarding MLA measured by IVUS was excellent, with intraclass correlation coefficient values of 0.986 (95% Confidence Interval [CI]: 0.953 to 0.995; $p < 0.001$) and 0.978 (95% CI: 0.945 to 0.991; $p < 0.001$), respectively.

STATISTICAL ANALYSIS. Continuous variables are presented as the mean \pm SD, and they were compared using the Student *t* test. Categorical variables are presented as counts or percentages, and they were compared using the chi-square or Fisher exact tests. Receiver-operating curve analysis was performed to assess the discriminative powers of the IVUS and QCA parameters for an FFR of ≤ 0.80 using MedCalc (MedCalc Software, Mariakerke, Belgium) to define the sensitivity, specificity, positive predictive value,

ABBREVIATIONS AND ACRONYMS

CI	= confidence interval
FFR	= fractional flow reserve
IVUS	= intravascular ultrasound
LMCA	= left main coronary artery
LV	= left ventricular
MLA	= minimal lumen area
OR	= odds ratio
QCA	= quantitative coronary angiogram

TABLE 1 Baseline Characteristics

	All Patients (N = 112)	Fractional Flow Reserve		p Value
		≤0.80 (n = 66)	>0.80 (n = 46)	
Age, yrs	60.1 ± 10.8	58.8 ± 9.9	63.8 ± 11.6	0.015
Male	82 (73.9)	49 (74.2)	33 (73.3)	0.92
Weight, kg	65.5 ± 10.7	66.1 ± 11.3	64.6 ± 9.8	0.78
Height, m	163.4 ± 8.1	163.6 ± 8.4	163.1 ± 7.7	0.49
Body mass index, kg/m ²	24.5 ± 3.2	24.6 ± 3.2	24.3 ± 3.2	0.59
Body surface area, m ²	1.72 ± 0.17	1.73 ± 0.18	1.71 ± 0.16	0.53
Hypertension	62 (55.9)	40 (60.6)	22 (48.9)	0.22
Diabetes	32 (28.8)	21 (31.8)	11 (24.4)	0.40
Chronic renal failure	3 (2.7)	1 (1.5)	2 (4.4)	0.57
Smoking	55 (49.5)	33 (50.0)	22 (48.9)	0.91
Hypercholesterolemia	80 (72.1)	51 (77.3)	29 (64.4)	0.14
Previous coronary intervention	20 (18.0)	12 (18.2)	8 (17.8)	0.96
Previous myocardial infarction	6 (5.4)	3 (4.5)	3 (6.7)	0.63
Previous stroke	6 (5.4)	2 (3.0)	4 (8.9)	0.18
Acute coronary syndrome	40 (36.0)	23 (34.8)	17 (37.8)	0.75

Values are n (%) or mean ± SD.

and negative predictive value with 95% confidence intervals (CI). The optimal cutoff values of the IVUS and QCA parameters for an FFR of ≤0.80 were identified as the values for which the sum of the sensitivity and specificity was greatest.

Multivariate logistic regression analysis was performed to identify the independent factors of an

TABLE 2 Coronary Angiographic, IVUS, and Echocardiographic Characteristics

	All Patients (N = 112)	Fractional Flow Reserve		p Value
		≤0.80 (n = 66)	>0.80 (n = 46)	
Fractional flow reserve	0.78 ± 0.09	0.72 ± 0.06	0.87 ± 0.05	<0.001
Coronary angiographic parameters				
Reference vessel diameter, mm	3.8 ± 0.5	3.7 ± 0.5	3.9 ± 0.4	0.018
Minimal lumen diameter, mm	2.0 ± 0.5	1.9 ± 0.4	2.2 ± 0.5	<0.001
Diameter stenosis, %	46.9 ± 11.4	49.4 ± 11.2	43.3 ± 10.8	0.006
Lesion length, mm	10.4 ± 5.0	11.4 ± 5.4	9.0 ± 3.9	0.012
Right dominance	103 (92.8)	63 (95.5)	40 (88.9)	0.27
Intravascular ultrasound parameters				
Minimal lumen area, mm ²	4.8 ± 2.2	4.0 ± 1.6	5.9 ± 2.5	<0.001
EEM area, mm ²	18.9 ± 5.9	18.9 ± 5.5	18.9 ± 6.5	0.95
Plaque burden, %	72.6 ± 13.9	76.8 ± 11.9	66.3 ± 14.3	<0.001
Plaque rupture	34 (30.6)	26 (39.4)	8 (17.8)	0.015
Thrombi	30 (27.0)	22 (33.3)	8 (17.8)	0.07
Echocardiographic parameters, n = 98				
Ejection fraction, %	60.6 ± 6.1	61.3 ± 5.6	59.4 ± 6.6	0.14
Left ventricle mass, g	163.3 ± 43.7	166.9 ± 44.3	157.4 ± 42.6	0.30
Left ventricle mass index, g/mm ²	95.1 ± 21.1	97.0 ± 21.6	92.1 ± 20.1	0.27

Values are n (%) or mean ± SD.
EEM = external elastic membrane; IVUS = intravascular ultrasound.

FFR of ≤0.80. We constructed 2 models. Model 1 included the clinical, IVUS, and QCA variables, and model 2 included the variables in model 1 plus additional echocardiographic variables. Variables were chosen by backward stepwise multivariate logistic regression analysis using a threshold of 0.05 for variable elimination. Variables that significantly associated with an FFR of ≤0.80 in univariate analyses were entered into final model. The variables entered in final models were rupture, body mass index, age, and MLA in model 1 and rupture, body mass index, age, MLA, and left ventricular (LV) mass in model 2. We computed the shrinkage factor to measure the overfitting using the likelihood ratio of the fitted model. Shrinkage factor was 0.93 and 0.94 for model 1 and model 2, respectively. The shrinkage factor quantifies the overfitting of a model where values >0.85 might not be of concern (6).

All statistical analyses were performed using SPSS (version 12.0, SPSS, Inc., Chicago, Illinois). A p value of < 0.05 was considered indicative of statistical significance.

RESULTS

BASILINE CHARACTERISTICS. The clinical characteristics of the 112 patients with isolated LMCA stenosis are summarized in **Table 1**. Their mean age was 60 years of age, 74% were men, 29% had a history of diabetes, 5% had a history of previous myocardial infarction, and 36% presented with acute coronary syndrome. **Table 2** shows their coronary angiography, IVUS, and echocardiographic results. The mean FFR was 0.78 ± 0.09, the mean diameter stenosis 46.9 ± 11.4%, and the mean minimal lumen area 4.8 ± 2.2 mm². Overall, 66 lesions (59%) had an FFR of ≤0.80 at maximum hyperemia. The LMCA lesions with an FFR of ≤0.80 exhibited smaller reference vessels, smaller minimal lumen diameter, greater diameter stenosis, longer lesion length, smaller minimal lumen area, larger plaque burden, and more frequent plaque rupture.

PARAMETERS OF THE FUNCTIONAL SIGNIFICANCE OF LMCA. Multivariable linear and logistic regression analysis including clinical, angiographic, and IVUS variables identified plaque rupture (odds ratio [OR]: 4.47; 95% CI: 1.356 to 14.8; p = 0.014), body mass index (OR: 1.19; 95% CI: 1.00 to 1.41; p = 0.05), age (OR: 0.95; 95% CI: 0.90 to 1.00; p = 0.031), and IVUS MLA (OR: 0.37; 95% CI: 0.25 to 0.56; p < 0.001) as independent factors of an FFR of ≤0.80. In addition, when the echocardiographic variable of LV mass was

TABLE 3 Independent Factors of Functionally Significant LMCA Stenosis*

	Odds Ratio	95% CI	p Value
Model 1†			
Plaque rupture	4.47	1.35-14.8	0.014
BMI, kg/m ²	1.19	1.00-1.41	0.05
Age, yrs	0.95	0.90-1.00	0.031
MLA, mm ²	0.37	0.25-0.56	<0.001
Model 2‡			
LV mass, g	1.01	1.00-1.03	0.03
Age, yrs	0.94	0.90-0.99	0.021
MLA, mm ²	0.34	0.21-0.54	<0.001

*Functional significance was defined as an FFR of ≤ 0.80 . †Model 1 included clinical, QCA, and IVUS variables. ‡Model 2 included model 1 plus the LV mass assessed by echocardiography.

BMI = body mass index; CI = confidence interval; FFR = fractional flow reserve; IVUS = intravascular ultrasound; LMCA = left main coronary artery; MLA = minimal lumen area; LV = left ventricular; QCA = quantitative coronary angiogram.

included in the preceding model, LV mass (OR: 1.01; 95% CI: 1.00 to 1.03; p = 0.03), age (OR: 0.94; 95% CI: 0.90 to 0.99; p = 0.021), and IVUS MLA (OR: 0.34; 95% CI: 0.21 to 0.54; p < 0.001) were independent factors of an FFR of ≤ 0.80 (Table 3).

CUTOFF VALUES OF PARAMETER. The best cutoff value of IVUS MLA within the LM (minimizing the distance between the curve and the upper corner of the graph) for an FFR of ≤ 0.80 was 4.5 mm² (77% sensitivity, 82% specificity, area under the curve = 0.83; 95% CI: 0.759 to 0.960; p < 0.001) (Fig. 1). The FFR was >0.80 in only 10 (17.2%) of 58 lesions with an MLA of ≤ 4.5 mm² (“mismatch”). Among the 54 lesions with an MLA of >4.5 mm², only 13 (24.1%) had an FFR of ≤ 0.80 (“reverse mismatch”) (Fig. 2). Table 4 shows the optimal cutoff values of the IVUS MLA for various subgroups; these ranged between

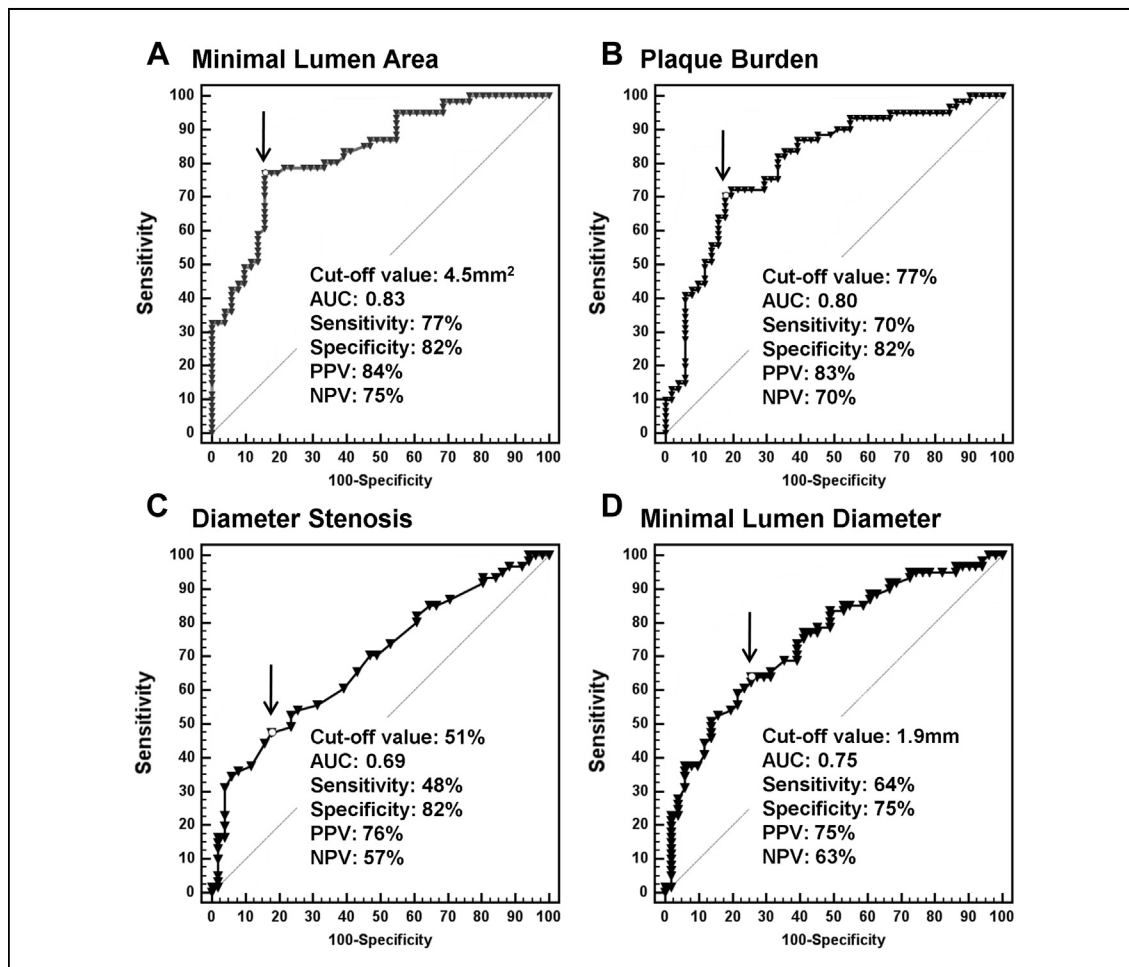
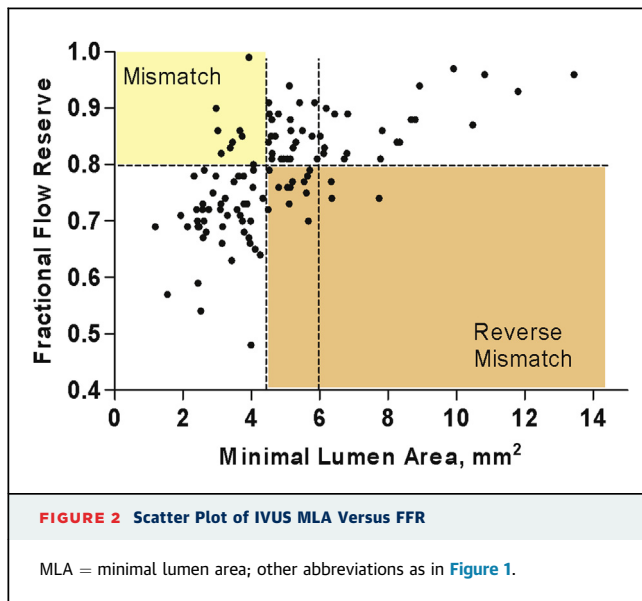


FIGURE 1 Cutoff Values and Corresponding Diagnostic Accuracies of IVUS-Derived Parameters of an FFR of ≤ 0.80

(A) Minimal lumen area; (B) plaque burden; (C) diameter stenosis, and (D) minimal lumen diameter. AUC = area under the curve; FFR = fractional flow reserve; IVUS = intravascular ultrasound; NPV = negative predictive value; PPV = positive predictive value.



4.1 mm² and 4.5 mm². In addition, we adjusted the MLA for the body mass index, body surface area, and LV mass assessed by echocardiography. However, these adjustments did not improve the diagnostic

accuracy over that of the unadjusted IVUS MLA (Fig. 3).

The optimal cutoff values for plaque burden, diameter stenosis, and minimal lumen diameter were 77%, 51%, and 1.9 mm, respectively (Fig. 1).

DISCUSSION

In this study, we found several clinical and anatomical factors that could be associated with the functional significance of LMCA stenosis. The presence of plaque rupture was a strong factor of functionally significant stenosis in diseased LMCA (3). The body mass index and LV mass assessed by echocardiography were also identified, possibly because these factors may be associated with the extent of the myocardium supplied by the LMCA.

An IVUS MLA of ≤ 4.5 mm² was an independent factor of an FFR of ≤ 0.80 . In subgroup analyses, the cutoff values of IVUS MLA associated with an FFR of ≤ 0.80 ranged between 4.1 and 4.5 mm². In addition, adjustment for the body mass index, body surface area, or LV mass assessed by echocardiography did not improve the accuracy of the IVUS MLA for an FFR of ≤ 0.80 . Traditionally, an MLA of 6.0 mm² was considered to represent functionally significant LMCA stenosis. This value was derived primarily from Murray law, with an MLA of 4.0 mm², considered to represent the ischemic threshold of the left anterior descending artery or left circumflex artery, and was supported by a clinical study comparing the IVUS MLA and FFR values (1,2). However, the IVUS MLA value corresponding to ischemia-producing lesions of non-LM epicardial coronary arteries was recently reported to be < 3 mm² (between 2.1 mm² and 3.07 mm²) (7-10). The application of Murray law to these values suggests that the IVUS MLA of a stenotic LM coronary artery that corresponds to an FFR of ≤ 0.80 should be < 5 mm², which is similar to our finding of an IVUS MLA cutoff value of 4.5 mm² (Fig. 4). In addition, the previous study enrolled a smaller number of patients (55 patients) with less-significant LMCA stenosis (mean FFR: 0.86) than our study population did (mean FFR: 0.78, N = 112), which may explain the larger cutoff value identified in the earlier study (1).

The accuracy of the IVUS MLA for functional significance is higher for LMCA stenosis than for non-LMCA stenosis (3,7). This was previously attributed to the simplicity of the morphologic characteristics of isolated ostial and shaft LMCA stenosis, including the uniformly large vessel size, short lesion length, and lack of side branches and other anatomical

TABLE 4 Optimal Cutoff Values of the MLA for the Detection of Functionally Significant LMCA Stenosis for Various Subgroups

	AUC (95% CI)	Cutoff Value	Sensitivity	Specificity	PPV	NPV
All patients (N = 112)	0.83 (0.75-0.90)	4.5	78.7	80.4	82.8	75.9
Sex						
Male (n = 83)	0.86 (0.77-0.93)	4.5	78.7	86.1	88.1	75.6
Female (n = 29)	0.75 (0.55-0.89)	4.1	78.6	66.7	68.8	76.9
Age, yrs						
≥ 65 yrs (n = 39)	0.91 (0.77-0.98)	4.1	81.3	95.7	92.9	88.0
< 65 yrs (n = 73)	0.78 (0.67-0.87)	4.5	77.8	75.0	83.3	67.7
Dominancy						
Right (n = 104)	0.83 (0.75-0.90)	4.5	77.6	80.4	83.3	74.0
Left (n = 8)	0.90 (0.50-0.99)	4.0	100	80.0	75.0	100
Rupture						
Yes (n = 34)	0.82 (0.66-0.93)	4.5	76.0	88.9	95.0	57.1
No (n = 78)	0.84 (0.74-0.91)	4.5	80.6	78.6	76.3	82.5
BMI, kg/m ²						
> 24 (n = 57)	0.84 (0.72-0.93)	4.5	78.1	80.0	83.3	74.1
≤ 24 (n = 55)	0.82 (0.69-0.91)	4.1	75.9	84.6	84.6	75.9
BSA, m ²						
> 1.7 (n = 58)	0.83 (0.71-0.92)	4.5	77.1	82.6	87.1	70.4
≤ 1.7 (n = 54)	0.84 (0.72-0.93)	4.1	80.8	82.1	80.8	82.1
LV mass, g						
> 156 (n = 50)	0.83 (0.69-0.92)	4.5	74.2	84.2	88.5	66.7
≤ 156 (n = 49)	0.89 (0.76-0.96)	4.1	84.6	82.6	84.6	82.6

AUC = area under the curve; BSA = body surface area; NPV = negative predictive value; PPV = positive predictive value; other abbreviations as in Table 3.

factors that could potentially affect FFR (3). Considering the prognostic importance of detection of significant LMCA stenosis, this greater accuracy may not justify the decision to treat or not to treat on the basis of an IVUS MLA alone because the cutoff value identified in the current study still yielded a 16% rate of mismatch and a 25% rate of reverse mismatch. In addition, relative to non-LMCA epicardial coronary artery stenosis, LMCA stenosis produced a higher frequency of “reverse mismatch” (11). This finding could be attributed to the greater amount of myocardium supplied and high frequency of plaque rupture in LMCA disease. Therefore, especially in cases of intermediate ostial and shaft LMCA stenosis, direct FFR measurement remains crucial to reduce the risk of overtreatment or undertreatment. However, in cases of complex LMCA stenosis in which FFR or noninvasive functional evaluation would be inaccurate, an IVUS MLA of 4.5 mm² could be a useful criterion for revascularization.

We found that plaque rupture was identified as an independent factor of functionally significant LMCA stenosis, which was consistent with the findings of previous studies (3,11). Theoretically, a complex or irregular lumen made by plaque rupture could produce greater flow resistance and energy loss of fluid, thus resulting in a greater pressure drop and reduction of FFR. In addition, thrombotic material superimposed on a ruptured site may increase the roughness of the vessel surface, resulting in the further increase of the flow resistance. Therefore, among lesions with the same degree of angiographic stenosis, the various shapes of a ruptured plaque could reduce the FFR value (11).

STUDY LIMITATIONS. First, the current study included only Asian subjects, who may have relatively small hearts. In an attempt to overcome this limitation, we tried to adjust the IVUS MLA with respect to various anthropometric measurements, including the body surface area, body mass index, and LV mass. However, none of these adjustments improved the diagnostic accuracy, which suggested that these factors might not significantly affect the optimal cutoff value of the IVUS MLA for identifying functionally significant stenosis. Further larger studies or inter-racial studies will be necessary to evaluate the impact of ethnicity and/or body size. Second, we excluded patients with significant left anterior descending artery disease or left circumflex artery stenosis. However, isolated LMCA stenoses are very rare, with most stenoses associated with disease in the left anterior descending artery and/or left

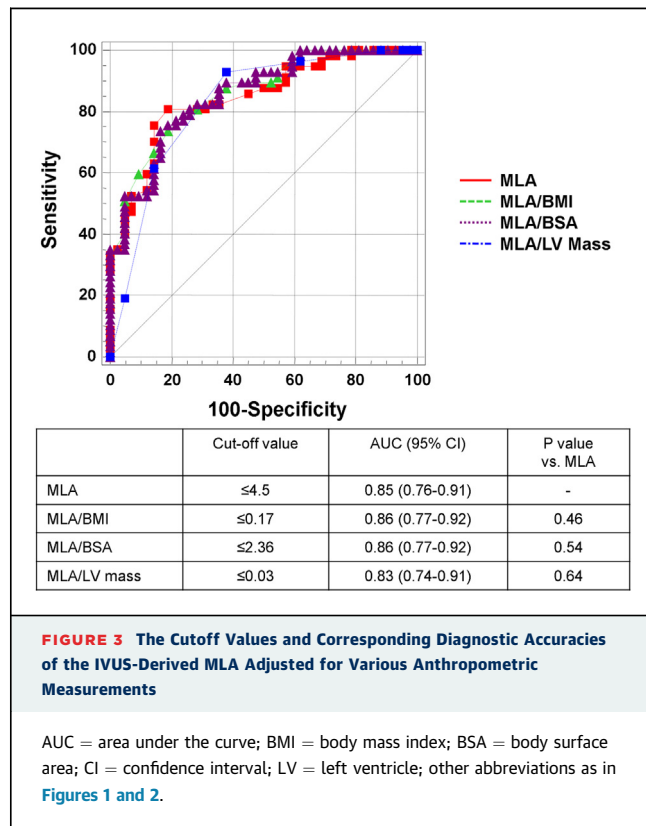


FIGURE 3 The Cutoff Values and Corresponding Diagnostic Accuracies of the IVUS-Derived MLA Adjusted for Various Anthropometric Measurements

AUC = area under the curve; BMI = body mass index; BSA = body surface area; CI = confidence interval; LV = left ventricle; other abbreviations as in Figures 1 and 2.

circumflex artery, both of which tend to increase FFR measured across the LMCA stenosis. Therefore, in this case, the reassessment for the functional significance of intermediate LMCA stenosis was recommended after the correction of distal coronary artery stenosis (12).

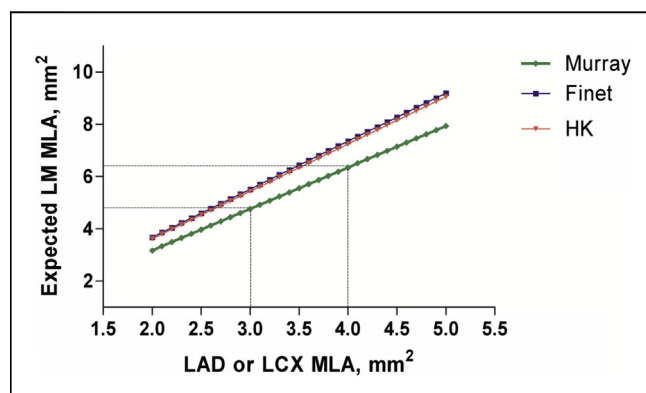


FIGURE 4 Geometric Abstractions

Geometric abstractions from Murray law, Finet law, and H-K law. H-K = Huo and Kassab; LAD = left anterior descending; LCX = left circumflex; LM = left main.

CONCLUSIONS

In patients with isolated ostial and shaft LMCA stenosis, an IVUS-derived MLA of ≤ 4.5 mm² is a useful index of an FFR of ≤ 0.80 .

REPRINT REQUESTS AND CORRESPONDENCE: Dr. Seung-Jung Park, Professor of Medicine, Asan Medical Center, 388-1 Poongnap-dong, Songpa-gu, Seoul 138-736, South Korea. E-mail: sjpark@amc.seoul.kr OR sjpark@summitmd.com.

REFERENCES

- Jasti V, Ivan E, Yalamanchili V, Wongpraparut N, Leesar MA. Correlations between fractional flow reserve and intravascular ultrasound in patients with an ambiguous left main coronary artery stenosis. *Circulation* 2004;110:2831-6.
- de la Torre Hernandez JM, Hernandez Hernandez F, Alfonso F, et al., for the LITRO Study Group. Prospective application of pre-defined intravascular ultrasound criteria for assessment of intermediate left main coronary artery lesions results from the multicenter LITRO study. *J Am Coll Cardiol* 2011;58:351-8.
- Kang SJ, Lee JY, Ahn JM, et al. Intravascular ultrasound-derived predictors for fractional flow reserve in intermediate left main disease. *J Am Coll Cardiol Intv* 2011;4:1168-74.
- Girasis C, van Geuns RJ, Onuma Y, Serruys PW. Essentials of quantitative angiography for bifurcation lesions. *EuroIntervention* 2010;6 Suppl J: J36-43.
- Mintz GS, Nissen SE, Anderson WD, et al. American College of Cardiology Clinical Expert Consensus Document on Standards for Acquisition, Measurement and Reporting of Intravascular Ultrasound Studies (IVUS): a report of the American College of Cardiology Task Force on Clinical Expert Consensus Documents. *J Am Coll Cardiol* 2001;37: 1478-92.
- Harrell FE, Lee KL, Mark DB. Multivariable prognostic models: issues in developing models, evaluating assumptions and adequacy, and measuring and reducing errors. *Stat Med* 1996;15: 361-87.
- Kang SJ, Lee JY, Ahn JM, et al. Validation of intravascular ultrasound-derived parameters with fractional flow reserve for assessment of coronary stenosis severity. *Circ Cardiovasc Interv* 2011;4: 65-71.
- Lee CH, Tai BC, Soon CY, et al. New set of intravascular ultrasound-derived anatomic criteria for defining functionally significant stenoses in small coronary arteries (results from Intravascular Ultrasound Diagnostic Evaluation of Atherosclerosis in Singapore [IDEAS] study). *Am J Cardiol* 2010;105:1378-84.
- Waksman R, Legutko J, Singh J, et al. FIRST: Fractional Flow Reserve and Intravascular Ultrasound Relationship Study. *J Am Coll Cardiol* 2013; 61:917-23.
- Koo BK, Yang HM, Doh JH, et al. Optimal intravascular ultrasound criteria and their accuracy for defining the functional significance of intermediate coronary stenoses of different locations. *J Am Coll Cardiol Intv* 2011;4:803-11.
- Park SJ, Kang SJ, Ahn JM, et al. Visual-functional mismatch between coronary angiography and fractional flow reserve. *J Am Coll Cardiol Intv* 2012;5:1029-36.
- Park SJ, Ahn JM, Kang SJ. Unprotected left main percutaneous coronary intervention: integrated use of fractional flow reserve and intravascular ultrasound. *J Am Heart Assoc* 2012;1: e004556.

KEY WORDS coronary disease, fractional flow reserve, intravascular ultrasound, left main coronary artery