

Intravascular ultrasound predictors of angiographic restenosis after sirolimus-eluting stent implantation

Myeong-Ki Hong¹, Gary S. Mintz², Cheol Whan Lee¹, Duk-Woo Park¹, Bong-Ryong Choi¹, Kyoung-Ha Park¹, Young-Hak Kim¹, Sang-Sig Cheong³, Jae-Kwan Song¹, Jae-Joong Kim¹, Seong-Wook Park¹, and Seung-Jung Park^{1*}

¹ Department of Medicine, University of Ulsan College of Medicine, Asan Medical Center, 388-1 Poongnap-dong, Songpa-gu, Seoul, 138-736, Korea; ² Cardiovascular Research Foundation, New York, NY, USA; and ³ Department of Medicine, University of Ulsan College of Medicine, Asan Medical Center, GangNeung, Korea

Received 13 November 2005; revised 2 March 2006; accepted 23 March 2006; online publish-ahead-of-print 27 April 2006

KEYWORDS

Ultrasonics;
Stent;
Coronary disease

Aims In many countries, drug-eluting stent implantation is the dominant interventional strategy. We evaluated the clinical, angiographic, procedural, and intravascular ultrasound (IVUS) predictors of angiographic restenosis after sirolimus-eluting stent (SES) implantation.

Methods and results SES implantation was successfully performed in 550 patients with 670 native coronary lesions. Six-month follow-up angiography was performed in 449 patients (81.6%) with 543 lesions (81.1%). Clinical, angiographic, procedural, and IVUS predictors of restenosis were determined. Using multivariable logistic regression analysis, the only independent predictors of angiographic restenosis were post-procedural final minimum stent area by IVUS [odds ratio (OR) = 0.586, 95% confidence interval (CI) 0.387–0.888, $P = 0.012$] and IVUS-measured stent length (OR = 1.029, 95% CI 1.002–1.056, $P = 0.035$). Final minimum stent area by IVUS and IVUS-measured stent length that best separated restenosis from non-restenosis were 5.5 mm² and 40 mm, respectively. Lesions with final minimum stent area <5.5 mm² and stent length >40 mm had the highest rate of angiographic restenosis [17.7% (11/62)], $P < 0.001$ compared with other groups.

Conclusion Independent predictors of angiographic restenosis after SES implantation were post-procedural final minimum stent area by IVUS and IVUS-measured stent length. The angiographic restenosis rate was highest in lesions with stent area <5.5 mm² and stent length >40 mm.

Sirolimus-eluting stents (SESs, Cypher, Cordis/Johson and Johnson, Miami, FL, USA) have reduced the rate of restenosis as compared with bare metal stents (BMS).^{1,2} However, in-stent restenosis after SES implantation still occurs.^{3,4} In SIRIUS, the predictors of in-segment restenosis and target lesion revascularization (TLR) were diabetes mellitus, smaller reference lumen diameter, and longer lesion length.² In the RESEARCH registry, the predictors of angiographic restenosis were the treatment of in-stent restenosis, ostial lesion location, diabetes mellitus, longer stent length, and smaller reference lumen diameter.⁴ However, intravascular ultrasound (IVUS) data was not included in either of these two models of restenosis. In a recently published IVUS sub-study of SIRIUS, the importance of the IVUS minimum SES cross-sectional area (CSA) in predicting an adequate follow-up IVUS lumen CSA was emphasized.⁵ In the current study, we extended these previous observations by investigating the clinical, angiographic, and IVUS predictors of angiographic restenosis in a large series of patients treated with SES implantation.

Methods

Study population

IVUS-guided SES implantation was successfully performed in 550 non-consecutive patients with 670 native coronary lesions from November 2003 to September 2004. During the same study period, SES implantation without IVUS-guidance ($n = 125$ patients) and other stents (i.e. bare-metal stent or paclitaxel-eluting stent) implantation ($n = 513$ patients) were performed in 638 patients with 852 native coronary lesions. Exclusion criteria were saphenous vein graft disease, in-stent restenosis, and bifurcation lesions. Clinical follow-up was requested at 1, 3, and 6 months post-intervention; and angiographic follow-up was requested at 6 months. Six-month follow-up angiography was performed in 449 patients (81.6%) with 543 lesions (81.1%). Follow-up angiography was not performed in 101 patients with 127 lesions: refusal of follow-up angiography in 51 patients with 63 lesions, 18 elderly patients (>75 years old) with 22 lesions, poor renal function (serum creatinine level >2.0 mg/dL) in 12 patients with 17 lesions, and combined other serious systemic disease or malignancy in 20 patients with 25 lesions. All patients gave their written informed consent to participate in the study. This study was approved by our clinical study Institutional Review Board.

Details of the stenting technique have been described previously.^{2,6,7} During the procedure, patients received intravenous

* Corresponding author. Fax: +82 2 475 6898.
E-mail address: sjpark@amc.seoul.kr

heparin to maintain the activated clotting time >300 s. Operators were not blinded to the IVUS findings. Stent length was selected to ensure full lesion coverage from proximal to distal reference segments; the target IVUS criteria for stent expansion was post-procedural final minimum stent CSA ≥ 5.0 mm² or more than the distal reference segment lumen CSA.^{5,8,9} When stent under-expansion that the optimal stent expansion was not achieved based on the IVUS criteria occurred, adjunct balloon angioplasty was performed. All patients received a 300 mg loading dose of clopidogrel followed by clopidogrel 75 mg/day for at least 6 months and aspirin 200 mg/day indefinitely.

Quantitative coronary angiographic analysis

Coronary angiography was performed after the administration of 0.2 mg intracoronary nitroglycerin. Angiographic results were analysed by two independent angiographers. Using the guiding catheter for magnification-calibration and an on-line system (ANCOR V2.0, Siemens, Germany), minimal luminal diameter (MLD) and diameters of the reference segments were measured before and after stenting and at 6-month follow-up from diastolic frames in a single, matched view showing the smallest MLD. The in-lesion MLD included the stent as well as 5 mm margins proximal and distal to the stent. Acute gain was defined as the difference in MLD before and after stenting. Late loss was calculated as the difference in MLD immediately after stenting and at 6-month follow-up. The reference vessel diameter was the average of the proximal and distal reference lumen diameters. Lesion length was determined by the 'shoulder-to-shoulder' extent of narrowing in the view with the least amount of foreshortening. Angiographic restenosis was defined as a diameter stenosis $\geq 50\%$ at follow-up. The patterns of angiographic in-stent restenosis were classified as suggested by Mehran *et al.*¹⁰

Post-intervention IVUS imaging

Post-intervention IVUS imaging was obtained after intracoronary administration of 0.2 mg nitroglycerin using a motorized transducer pullback system (0.5 mm/s) and a commercial scanner (Boston Scientific/SCIMED, Minneapolis, MN, USA) consisting of a rotating 30 or 40 MHz rotating transducer. The ultrasound catheter was advanced ~ 10 mm beyond the target lesion, and an imaging run was performed from beyond the target lesion to the aorto-ostial junction. Ultrasound studies were recorded on 1/2-in high-resolutions-VHS tape for off-line analysis.

Quantitative IVUS measurements

Quantitative analyses were performed according to the criteria of the clinical expert consensus document on IVUS¹¹ using computerized planimetry (TapeMeasure, Indec System, MountainView, CA, USA). Quantitative measurements at the stented segment and the proximal and distal reference segments included external elastic membrane (EEM), lumen, and stent CSA. Final minimum stent CSA was the smallest stent CSA post-procedure. Reference segments were defined as the most normal-looking cross-sections within 10 mm proximal and distal to the lesions. Stent length in lesions with multiple overlapping stents was measured using automatic transducer pullback system. Nominal stent length was used in single stent implantation.

Statistical analysis

Statistical analysis was performed with SPSS software (SPSS Inc., Chicago, IL, USA). Categorical data were presented as frequencies and compared with χ^2 statistics or Fisher's exact test. Continuous data were presented as mean \pm SD and compared with Student's *t*-test. Multivariable logistic regression analysis using backward, stepwise variable-selection process was performed to determine the independent predictors of angiographic restenosis. The criterion

for the entry and removal of variables were set at 0.05 and 0.10, respectively. Continuous and ordinal variables were fit using restricted cubic splines to relax the linearity assumptions.¹² Model goodness-of-fit was assessed using the Hosmer-Lemeshow test and fit considered adequate if computed $P > 0.05$. Receiver operator characteristic (ROC) analysis or the *c*-statistic was performed to determine the model discrimination and the best cut-off value for predicting the angiographic restenosis. We also performed an internal validation process to test model adequacy and quantify overfitting.¹³ To investigate the stability of the stepwise selection process of the regression models and assess the robustness of the variables, the bootstrap resampling procedure was used.¹⁴ Stepwise selection was performed in 1000 bootstrap samples, and the predictors that were selected in $>50\%$ were retained in the multivariable regression models. All *P* values are 2-sided, and an *a* value <0.05 was considered statistically significant.

Results

Of the 449 patients with 543 lesions who underwent angiographic follow-up, 21 patients had 21 lesions (3.9%) with angiographic restenosis and 12 of the 21 patients had symptomatic angina. Revascularization was performed in nine of 21 restenotic lesions [overall TLR rate = 1.7% (9/543)]. Revascularization strategies for nine restenotic lesions were: additional drug-eluting stent implantation in four lesions, cutting balloon angioplasty in two lesions, intracoronary brachytherapy in two lesions, and coronary artery bypass surgery in one lesion. In the other 12 restenotic lesions in which revascularization was not performed, medical treatment was selected either because the results of a treadmill exercise test were negative ($n = 8$ lesions) or because the restenosis was only moderate in severity ($n = 4$ lesions).

There were no significant differences in baseline clinical characteristics between the 21 patients with restenosis vs. the 428 patients without restenosis (Table 1).

The angiographic and IVUS findings comparing 21 restenotic vs. 522 non-restenotic lesions are shown in Table 2. In the overall cohort of 543 lesions,

Table 1 Baseline clinical characteristics

| | Restenosis (<i>n</i> = 21) | Non-restenosis (<i>n</i> = 428) | <i>P</i> -value |
|-----------------------------|--------------------------------|-------------------------------------|-----------------|
| Age (years) | 59 \pm 8 | 58 \pm 10 | 0.7 |
| Male gender | 13 (62%) | 308 (72%) | 0.3 |
| Hypertension | 10 (48%) | 206 (48%) | 1.0 |
| Diabetes mellitus | 6 (29%) | 109 (26%) | 0.8 |
| Cigarette smoking | 6 (29%) | 136 (32%) | 0.8 |
| Lipid profile | | | |
| Total cholesterol (mg/dL) | 176 \pm 36 | 180 \pm 36 | 0.6 |
| Triglyceride (mg/dL) | 129 \pm 60 | 145 \pm 108 | 0.3 |
| HDL-cholesterol (mg/dL) | 53 \pm 35 | 44 \pm 14 | 0.3 |
| Clinical manifestations | | | 0.5 |
| Stable angina | 9 (43%) | 200 (47%) | |
| Unstable angina | 11 (52%) | 181 (42%) | |
| Acute myocardial infarction | 1 (5%) | 47 (11%) | |
| Multi-vessel stenting | 8 (38%) | 137 (32%) | 0.7 |
| Number of diseased vessels | | | 0.5 |
| 1 | 8 (38%) | 194 (45%) | |
| 2 | 6 (29%) | 141 (33%) | |
| 3 | 7 (33%) | 93 (22%) | |

Table 2 Angiographic and post-intervention IVUS findings

| | Restenosis (n = 21) | Non-restenosis (n = 522) | P-value |
|--|------------------------|-----------------------------|---------|
| Stented coronary segments | | | 0.185 |
| LM coronary artery | | 20 (4%) | |
| LAD | 11 (52%) | 312 (60%) | |
| Left CX | 2 (10%) | 86 (16%) | |
| RCA | 8 (38%) | 104 (20%) | |
| Chronic total occlusion lesion | 2 (10%) | 37 (7%) | 0.7 |
| Reference vessel diameter (mm) | 2.7 ± 0.4 | 3.0 ± 0.5 | 0.016 |
| Minimal lumen diameter (mm) | | | |
| Pre-intervention | 0.7 ± 0.5 | 1.0 ± 0.6 | 0.045 |
| Post-intervention | 2.6 ± 0.4 | 2.9 ± 0.5 | 0.015 |
| Follow-up | 1.1 ± 0.5 | 2.7 ± 0.5 | <0.001 |
| Acute gain (mm) | 1.9 ± 0.7 | 1.9 ± 0.6 | 1.0 |
| Late loss (mm) | 1.6 ± 0.6 | 0.2 ± 0.4 | <0.001 |
| Lesion length (mm) | 40.5 ± 12.7 | 24.9 ± 14.3 | <0.001 |
| Stent: lesion length ratio | 1.2 ± 0.1 | 1.3 ± 0.3 | <0.001 |
| Maximum inflation pressure (atm) | 16.1 ± 2.7 | 16.4 ± 3.3 | 0.7 |
| Number of stent used | 2.0 ± 0.8 | 1.3 ± 0.6 | <0.001 |
| Post-intervention IVUS findings | | | |
| Stent length (mm) | 50.7 ± 22.7 | 30.9 ± 16.0 | <0.001 |
| Stent under-expansion | 9 (43%) | 70 (13%) | 0.001 |
| Adjunct balloon angioplasty | 3 (14%) | 99 (19%) | 0.8 |
| Proximal reference segment | | | |
| EEM CSA (mm ²) | 14.1 ± 3.1 | 14.7 ± 3.8 | 0.6 |
| Lumen CSA (mm ²) | 7.7 ± 1.9 | 8.5 ± 2.6 | 0.3 |
| Lesion segment | | | |
| Final minimum stent CSA (mm ²) | 5.1 ± 1.5 | 6.5 ± 1.9 | 0.001 |
| Distal reference segment | | | |
| EEM CSA (mm ²) | 9.3 ± 3.0 | 11.1 ± 3.7 | 0.038 |
| Lumen CSA (mm ²) | 5.7 ± 1.8 | 6.8 ± 2.5 | 0.047 |

post-implantation reference vessel size was 2.9 ± 0.5 mm, post-stent MLD was 2.9 ± 0.5 mm, stent length was 31.7 ± 16.8 mm, and final minimum stent CSA was 6.4 ± 1.9 mm². Compared with the 522 non-restenotic lesions, in the 21 restenotic lesions, stent and lesion length was significantly longer, reference vessel diameter and pre- and post-stent MLD by quantitative coronary angiographic (QCA) analysis were significantly smaller, and distal reference EEM and lumen CSA and minimum stent CSA by IVUS analysis were significantly smaller.

Predictors of angiographic restenosis

The overall angiographic restenosis rate was 3.9% (21/543). All clinical, angiographic, procedural, and IVUS univariate predictors of angiographic restenosis at a *P* level <0.2 were entered into the multivariable model. The following variables were tested

(all with *P* < 0.2 in univariate analysis): stented coronary segments, reference vessel diameter, pre- and post-intervention QCA MLD, lesion length; stent: lesion length ratio, number of stent, IVUS-measured stent length, stent under-expansion, final minimum stent CSA, distal reference EEM CSA and distal reference lumen CSA (Table 3). Using multivariable stepwise logistic regression analysis, the only independent predictors of angiographic restenosis were the post-procedural final minimum stent CSA [odds ratio (OR) = 0.586, 95% CI 0.387–0.888, *P* = 0.012] and the stent length measured by IVUS (OR = 1.029, 95% CI 1.002–1.056, *P* = 0.035). The c-statistics for the multivariable logistic regression model was 0.81, indicating excellent discrimination. The area under the curve on ROC curve of IVUS-measured stent length (0.80) was larger than that of the final minimum stent CSA by IVUS (0.73) for predicting development of angiographic restenosis. All but three SES restenosis were intra-stent.

Sensitivity and specificity curves were used to identify optimal cut-off values of the final minimum stent CSA and IVUS-measured stent length that best predicted angiographic restenosis after SES implantation (Figure 1): 5.5 mm² for final minimum stent CSA and 40 mm for stent length. The diagnostic accuracy of the cut-off threshold for final minimum stent CSA and stent length is as follows. The sensitivity and specificity for IVUS-measured stent length >40 mm to predict the angiographic restenosis were 81% (17/21) and 78% (407/522), respectively. The positive and negative predictive values were 13% (17/132) and 99% (407/411), respectively. The sensitivity and specificity for IVUS-measured final minimum stent CSA <5.5 mm² to predict the angiographic restenosis were 67% (14/21) and 67% (347/522), respectively. The positive and negative predictive values were 7% (14/189) and 98% (347/354), respectively. The angiographic restenosis rate was 7.4% (14/189) and 2.0% (7/354) in final minimum stent CSA <5.5 vs. ≥5.5 mm², respectively (*P* = 0.002), and 1.0% (4/411) and 12.9% (17/132) in stent length ≤40 vs. >40 mm, respectively (*P* < 0.001). As shown in Table 4, the angiographic restenosis rate according to the final minimum stent CSA and the stent length were then determined. The relationship between the final minimum stent CSA and the stent length is shown in Figure 2 (*r* = −0.273, *P* < 0.001). Lesions with final minimum stent CSA <5.5 mm² and stent length >40 mm had the highest rate of angiographic restenosis [17.7% (11/62)], *P* < 0.001 compared with the other groups.

Patterns of restenosis

The angiographic pattern of restenosis was focal in 17 lesions, diffuse in 2 lesions, and total occlusions in 2 lesions. Details are shown in Table 5. The distribution of angiographic late loss is shown in Figure 3. Final minimum stent CSA tended to be smaller in diffuse/total occlusion in-stent restenosis lesions (3.9 ± 0.8 mm²) vs. focal in-stent restenosis lesions (5.4 ± 1.5 mm², *P* = 0.08). In one of the total occlusions, the stent length was 121 mm and the final minimum stent CSA was 3.0 mm². In the other total occlusion, the stent length was 55 mm and the final minimum stent CSA was 4.1 mm². Both these patients were asymptomatic. The three edge restenosis were associated with post-stent adjunct balloon dilation that extended into the contiguous reference segments without stent coverage. The two distal and one proximal edge restenosis lesions

Table 3 Univariate and multivariable predictors of angiographic restenosis

| Variables | Univariate analysis | | | Multivariable analysis | | |
|------------------------------------|---------------------|--------------|---------|------------------------|-------------|---------|
| | OR | 95% CI | P-value | OR | 95% CI | P-value |
| Reference vessel diameter | 0.230 | 0.069–0.769 | 0.017 | | | |
| Pre-intervention QCA MLD | 0.416 | 0.178–0.970 | 0.042 | | | |
| Post-intervention QCA MLD | 0.209 | 0.065–0.667 | 0.008 | | | |
| Lesion length | 1.053 | 1.026–1.081 | <0.001 | | | |
| Stent: lesion length ratio | 0.162 | 0.012–2.147 | 0.167 | | | |
| Number of stent | 3.325 | 1.978–5.592 | <0.001 | | | |
| IVUS stent length | 1.046 | 1.026–1.067 | <0.001 | 1.029 | 1.002–1.056 | 0.035 |
| Stent under-expansion | 4.843 | 1.969–11.914 | 0.001 | | | |
| Final minimum stent CSA | 0.569 | 0.407–0.795 | 0.001 | 0.586 | 0.387–0.888 | 0.012 |
| Distal reference segment EEM CSA | 0.838 | 0.708–0.993 | 0.041 | | | |
| Distal reference segment lumen CSA | 0.766 | 0.590–0.996 | 0.047 | | | |

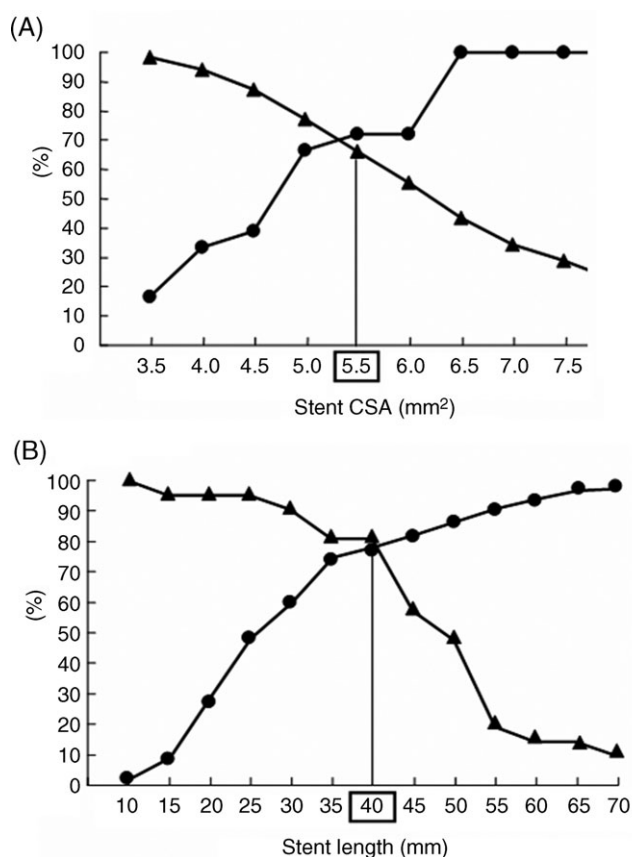


Figure 1 The sensitivity and specificity curves identified optimal cut-off values of final minimum stent CSA (A) and stent length (B) that predicted angiographic restenosis after SES implantation: 5.5 mm² for final minimum stent CSA and 40 mm for IVUS-measured stent length. Triangles, sensitivity; circles, specificity.

had final minimum stent CSAs of 5.5, 6.7, and 9.5 mm² and stent lengths of 18, 41, and 42 mm.

Discussion

In this retrospective analysis of 543 native coronary lesions treated with IVUS-guided SES implantation, the overall angiographic restenosis and TLR rates were 3.9% and 1.7%,

respectively. The only independent predictors of angiographic restenosis after SES implantation were the final minimum stent CSA by IVUS and IVUS-measured stent length. The highest angiographic restenosis rates were in lesions with final minimum stent area <5.5 mm² in stents >40 mm. The predominant pattern of angiographic restenosis was focal (81.0%, 17/21) with most angiographic restenosis located intra-stent (85.7%, 18/21).

Compared with the BMS implantation, the randomized SIRIUS and TAXUS-IV trials showed a significant reduction in restenosis and TLR in patients with coronary artery disease after SES and paclitaxel-eluting stent implantation, respectively.^{2,7} The current study's angiographic restenosis and TLR rates were lower than those in these previous studies.^{2,7} However, patients who were included in this current study represented a more complex lesion subsets that included very long lesions, thrombotic lesions, chronic total occlusions, ostial lesions, and heavily calcific lesions; only vein graft lesions, in-stent restenosis, and bifurcations were excluded. For example, the stent length was 21.5 ± 6.7 mm in SIRIUS and 21.9 ± 8.1 mm in TAXUS-IV; but it was 31.7 ± 16.8 mm in this current study. Furthermore, unlike SIRIUS and TAXUS-IV, IVUS-guidance was used routinely in the current study.

Traditionally, final minimum stent CSA by IVUS as well as stent length were significant independent predictors of angiographic restenosis in the era of BMS.^{8,9,15–17} In the drug-eluting stent era the significance of the final minimum stent CSA and the stent length were reduced because of the profound anti-restenosis effect of drug.^{1,2,7,18,19} For example, in the IVUS sub-study of the SIRIUS trial, the criteria for optimal SES expansion (the minimum stent CSA that separated adequate from inadequate IVUS lumen dimensions at follow-up) was lower in SES (5.0 mm²) than in BMS (6.5 mm²).⁵ This cut-off was supported by findings from Takebayashi *et al.*²⁰ and Cheneau *et al.*²¹ and is very similar to the current study. Similarly, the findings in the current study that the angiographic restenosis rate is dependent on SES length were also similar to a previous study.²² In particular, the current study highlighted the interaction between stent length and final minimum stent CSA; when implanting long or overlapping SES (total length >40 mm), it is incrementally important to achieve adequate stent expansion; angiographic restenosis was 8.6% if the final minimum stent

Table 4 Angiographic restenosis rate according to post-intervention IVUS stent CSA and IVUS-measured stent length

| Stent length (mm) | Stent CSA (mm ²) | Restenosis rates | P trend |
|-------------------|------------------------------|------------------|---------|
| ≤40 | ≥5.5 | 1/284 (0.4%) | <0.001 |
| ≤40 | <5.5 | 3/127 (2.4%) | |
| >40 | ≥5.5 | 6/70 (8.6%) | |
| >40 | <5.5 | 11/62 (17.7%) | |

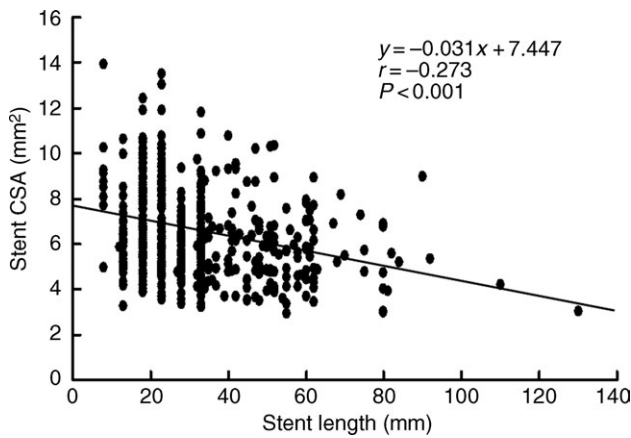


Figure 2 Relationship between the final minimum stent CSA and the stent length.

CSA was >5.5 mm² and 17.7% if <5.5 mm². It is possible that an even larger minimum stent CSA would have reduced the restenosis rate further as has been reported in the BMS era.²³ Although the importance of theory that the bigger is the better has been much reduced in drug-eluting stent era than in the era of BMS, the current study showed that the previous theory might be still valid even in the era of drug-eluting stent. The current IVUS study showed that the roles of IVUS in clinical practice to reduce angiographic restenosis may be greater in the complex lesions (i.e. very long lesions in small vessel) than in the simple lesions (i.e. discrete lesions in large vessel).

The result of the current study that the predominant pattern of angiographic restenosis was focal (81.0%) and located in intra-stent segments (85.7%) was similar to a previous study.³ This was true even though diffuse or long lesions were treated with multiple overlapping SES implantations.

As shown in one previous study, QCA had a limited ability to measure lumen dimensions accurately after stent placement; the correlation between QCA and IVUS measurements of MLD was only fair.¹⁵ Although both IVUS stent CSA and post-intervention QCA MLD were significant predictors of angiographic restenosis in the univariate analysis, post-intervention QCA MLD was excluded in multivariable analysis in both previous BMS analyses¹⁵ and in the current SES study. The IVUS predictors of in-stent restenosis were more powerful than the angiographic predictors of in-stent restenosis after SES implantation.

Limitations

Pre-intervention IVUS was performed in some, but not all patients. Therefore, the impact of pre-intervention IVUS

Table 5 Angiographic pattern of in-stent restenosis

| | Intra-stent (n = 18) | Edge (n = 3) |
|--------------------------|----------------------|--------------|
| Focal (n = 17) | 14 | 3 |
| Body of stent | 11 | |
| Distal margin of stent | 2 | |
| Multi-focal | 1 | |
| Diffuse (n = 2) | 2 | |
| Total occlusions (n = 2) | 2 | |

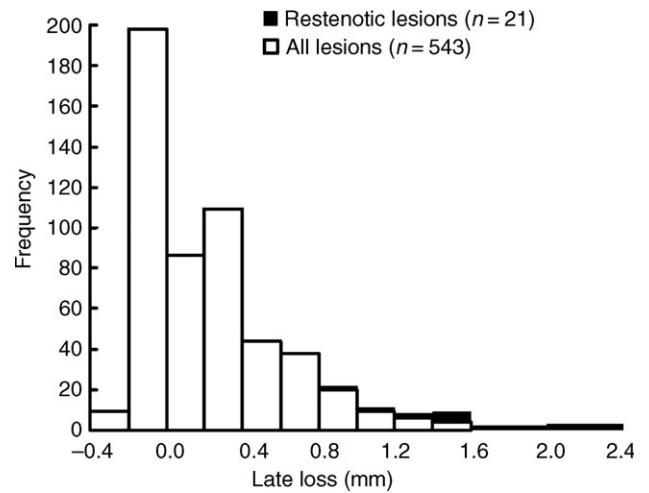


Figure 3 Distribution of angiographic late loss.

on angiographic restenosis could not be adequately evaluated. Because this was a retrospective single center study and 18% of all patients did not have angiographic follow-up, the possibility of selection bias might not be definitely excluded. Prospective, multicenter and randomized studies are needed to confirm the beneficial roles of IVUS in SES implantation. The rate of angiographic restenosis was low and this might have affected the results.

Conclusions

This retrospective IVUS analysis in 449 patients showed that the overall angiographic restenosis and TLR rates in 543 lesions treated with IVUS-guided SES implantation were 3.9% and 1.7%, respectively. The only independent predictors of angiographic restenosis after SES implantation were the final minimum stent CSA and IVUS-measured stent length. The optimal cut-off values of final minimum IVUS stent area and IVUS-measured stent length that predicted angiographic restenosis were 5.5 mm² and 40 mm, respectively.

Acknowledgements

This study was partly supported by Cardiovascular Research Foundation, Seoul, Korea and a grant of the Korea Health 21 R&D Project, Ministry of Health & Welfare, Korea (0412-CR02-0704-0001).

Conflict of interest: none declared.

References

- Morice MC, Serruys PW, Sousa JE, Fajadet J, Ban Hayashi E, Perin M, Colombo A, Schuler G, Barragan P, Guagliumi G, Molnar F, Falotico R, RAVEL study group. Randomized study with the sirolimus-coated Bx velocity balloon-expandable stent in the treatment of patients with *de novo* native coronary artery lesions: a randomized comparison of a sirolimus-eluting stent with a standard stent for coronary revascularization. *N Engl J Med* 2002;**346**:1773–1780.
- Moses JW, Leon MB, Popma JJ, Fitzgerald PJ, Holmes DR, O'Shaughnessy C, Caputo RP, Kereiakes DJ, Williams DO, Teirstein PS, Jaeger JL, Kuntz RE, SIRIUS investigators. Sirolimus-eluting stents vs. standard stents in patients with stenosis in a native coronary artery. *N Engl J Med* 2003;**349**:1315–1323.
- Colombo A, Orlic D, Stankovic G, Corvaja N, Spanos V, Montorfano M, Liistro F, Carlino M, Airolidi F, Chieffo A, Di Mario C. Preliminary observations regarding angiographic pattern of restenosis after rapamycin-eluting stent implantation. *Circulation* 2003;**107**:2178–2180.
- Lemos PA, Hoye A, Goedhart D, Arampatzis CA, Saia F, van der Giessen WJ, McFadden E, Sianos G, Smits PC, Hofma SH, de Feyter PJ, van Domburg RT, Serruys PW. Clinical, angiographic, and procedural predictors of angiographic restenosis after sirolimus-eluting stent implantation in complex patients: an evaluation from the Rapamycin-Eluting Stent Evaluated at Rotterdam Cardiology Hospital (RESEARCH) study. *Circulation* 2004;**109**:1366–1370.
- Sonoda S, Morino Y, Ako J, Terashima M, Hassan AHM, Bonneau HN, Leon MB, Moses JW, Yock PG, Honda Y, Kuntz RE, Fitzgerald PJ, for the SIRIUS investigators. Impact of final stent dimensions on long-term results following sirolimus-eluting stent implantation: serial intravascular ultrasound analysis from the SIRIUS trial. *J Am Coll Cardiol* 2004;**43**:1959–1963.
- Park SJ, Kim YH, Lee BK, Lee SW, Lee CW, Hong MK, Kim JJ, Mintz GS, Park SW. Sirolimus-eluting stent implantation for unprotected left main coronary artery stenosis: comparison with bare metal stent implantation. *J Am Coll Cardiol* 2005;**45**:351–356.
- Stone GW, Ellis SG, Cox DA, Hermiller J, O'Shaughnessy C, Mann JT, Turco M, Caputo R, Bergin P, Greenberg J, Popma JJ, Russell ME, for the TAXUS-IV investigators. A polymer-based, paclitaxel-eluting stent in patients with coronary artery disease. *N Engl J Med* 2004;**350**:221–231.
- Hong MK, Park SW, Mintz GS, Lee NH, Lee CW, Kim JJ, Park SJ. Intravascular ultrasonic predictors of angiographic restenosis after long coronary stenting. *Am J Cardiol* 2000;**85**:441–445.
- Ziada KM, Kapadia SR, Belli G, Houghtaling PL, De Franco AC, Ellis SG, Whitlow PL, Franco I, Nissen SE, Tuzcu EM. Prognostic value of absolute vs. relative measures of the procedural result after successful coronary stenting: importance of vessel size in predicting long-term freedom from target vessel revascularization. *Am Heart J* 2001;**141**:823–831.
- Mehran R, Dangas G, Abizaid AS, Mintz GS, Lansky AJ, Satler LF, Pichard AD, Kent KM, Stone GW, Leon MB. Angiographic patterns of in-stent restenosis: classification and implications for long-term outcome. *Circulation* 1999;**100**:1872–1878.
- Mintz GS, Nissen SE, Anderson WD, Bailey SR, Erbel R, Fitzgerald PJ, Pinto FJ, Rosenfield K, Siegel RJ, Tuzcu EM, Yock PG. American College of Cardiology clinical expert consensus document on standards for acquisition, measurement and reporting of intravascular ultrasound studies (IVUS): a report of the American College of Cardiology task force on clinical expert consensus documents. *J Am Coll Cardiol* 2001;**37**:1478–1492.
- Durrleman S, Simon R. Flexible regression models with cubic splines. *Stat Med* 1989;**8**:551–561.
- Harrell FE Jr, Lee KL. Multivariable prognostic models: issues in developing models, evaluating assumptions and adequacy, and measuring and reducing errors. *Stat Med* 1996;**15**:361–387.
- Sauerbrei W, Schumacher M. A bootstrap resampling procedure for model building: application to the Cox regression model. *Stat Med* 1992;**11**:2093–2109.
- Hoffmann R, Mintz GS, Mehran R, Pichard AD, Kent KM, Satler LF, Popma JJ, Hongsheng W, Leon MB. Intravascular ultrasound predictors of angiographic restenosis in lesions treated with Palmaz-Schatz stents. *J Am Coll Cardiol* 1998;**31**:43–49.
- Bertram OF, De Larochelliere R, Joyal M, Bonan R, Mongrain R, Tardif JC. Incidence of stent under-deployment as a cause of in-stent restenosis in long stents. *Int J Cardiovasc Imaging* 2004;**20**:279–284.
- Castagna MT, Mintz GS, Leiboff BO, Ahmed JM, Mehran R, Satler LF, Kent KM, Pichard AD, Weissman NJ. The contribution of 'mechanical' problems to in-stent restenosis: an intravascular ultrasonographic analysis of 1090 consecutive in-stent restenosis lesions. *Am Heart J* 2001;**142**:970–974.
- Takebayashi H, Mintz GS, Cartier SG, Kobayashi Y, Fujii K, Yasuda T, Costa RA, Moussa I, Dangas G, Mehran R, Lansky AJ, Kreps E, Collins MB, Colombo A, Stone GW, Leon MB, Moses JW. Nonuniform strut distribution correlates with more neointimal hyperplasia after sirolimus-eluting stent implantation. *Circulation* 2004;**110**:3430–3434.
- Fujii K, Mintz GS, Kobayashi Y, Carlier SG, Takebayashi H, Yasuda T, Moussa I, Dangas G, Mehran R, Lansky AJ, Reyes A, Kreps E, Collins M, Colombo A, Stone GW, Teirstein PS, Leon MB, Moses JW. Contribution of stent underexpansion to recurrence after sirolimus-eluting stent implantation for in-stent restenosis. *Circulation* 2004;**109**:1085–1088.
- Takebayashi H, Kobayashi Y, Mintz GS, Carlier SG, Fujii K, Yasuda T, Moussa I, Mehran R, Dangas GD, Collins MB, Kreps E, Lansky AJ, Stone GW, Leon MB, Moses JW. Intravascular ultrasound assessment of lesions with target vessel failure after sirolimus-eluting stent implantation. *Am J Cardiol* 2005;**95**:498–502.
- Cheneau E, Pichard AD, Satler LF, Suddath WO, Weissman NJ, Waksman R. Intravascular ultrasound stent area of sirolimus-eluting stents and its impact on late outcome. *Am J Cardiol* 2005;**95**:1240–1242.
- Popma JJ, Leon MB, Moses JW, Holmes DR, Cox N, Fitzpatrick M, Douglas J, Lambert C, Mooney M, Yakubov S, Kuntz RE, for the SIRIUS investigators. Quantitative assessment of angiographic restenosis after sirolimus-eluting stent implantation in native coronary arteries. *Circulation* 2004;**110**:3773–3780.
- de Feyter PJ, Kay P, Disco C, Serruys PW. Reference chart derived from post-stent-implantation intravascular ultrasound predictors of 6-month expected restenosis on quantitative coronary angiography. *Circulation* 1999;**100**:1777–1783.