

Intravitreal Injection of Triamcinolone for Diffuse Diabetic Macular Edema

Jost B. Jonas, MD; Ingrid Kreissig, MD; Antje Söfker, MD; Robert F. Degenring, MD

Objective: To evaluate the clinical outcome of an intravitreal injection of triamcinolone acetonide as treatment of diffuse diabetic macular edema.

Participants: This prospective, interventional, clinical case series study included 20 patients (26 eyes) who received an intravitreal injection of 25 mg of triamcinolone acetonide for treatment of diffuse diabetic macular edema. Mean \pm SD follow-up time was 6.64 \pm 6.10 months. The study group was compared with a control group of 16 patients who underwent macular grid laser coagulation.

Main Outcome Measures: Visual acuity and intraocular pressure.

Results: In the study group, visual acuity improved sig-

nificantly ($P < .001$), from 0.12 \pm 0.08 at baseline to a maximum of 0.19 \pm 0.14 during follow-up. Seventeen (81%) of 21 eyes with a follow-up period of more than 1 month had improved visual acuity. In the control group, visual acuity did not change significantly. In the study group, intraocular pressure increased significantly ($P < .001$), from 16.9 \pm 2.5 mm Hg to a mean maximal value of 21.3 \pm 4.7 mm Hg, and decreased significantly ($P = .03$) to 17.7 \pm 4.7 mm Hg at the study's end.

Conclusion: Intravitreal injection of 25 mg of triamcinolone acetonide may be beneficial for improving visual acuity in patients with clinically significant diffuse diabetic macular edema.

Arch Ophthalmol. 2003;121:57-61

DIABETIC MACULAR edema is one of the main reasons for reduced visual acuity in patients with diabetic retinopathy. According to the results of the study on the early treatment of diabetic retinopathy, diabetic macular edema has usually been treated by focal laser coagulation of leaking circumscribed retinal areas, unless the whole macular region is diffusely affected.¹ In eyes with diffuse macular edema, laser treatment cannot be focused on localized retinal leakage spots since the entire macula is involved. A recommendation for grid laser treatment covering the whole macular region with a fine net of small laser coagulation spots has been controversial, since randomized prospective studies proving the efficacy of this treatment have not yet been published.

In view of the uncertainties in the treatment of diffuse diabetic macular edema, we undertook the present study to assess whether an intravitreal injection of crystalline cortisone might be effective in reducing macular edema and improving visual acuity.

From the Department of Ophthalmology and the Eye Hospital, Faculty for Clinical Medicine—Mannheim, Ruprecht Karls University, Heidelberg, Germany. The authors have no proprietary interest in the products or companies mentioned in this article.

METHODS

The study included the 20 patients (26 eyes) who received an intravitreal injection of crystalline triamcinolone acetonide as treatment of clinically significant diffuse macular edema. All of the patients were fully informed about the experimental character of the therapy. All of the patients signed an informed consent. The ethics committee of the university had approved the study following the tenets of the Declaration of Helsinki. Mean \pm SD age of the patients was 66.9 \pm 8.9 years (median, 67.6 years; range, 49.4-79.6 years), and mean \pm SD refractive error was +0.40 \pm 1.62 diopters (D) (median, 0.00 D; range, -1.75 to +6.0 D). Mean \pm SD visual acuity was reduced to 0.12 \pm 0.08 (median, 0.10; range, 0.03-0.32). Visual acuity was measured as best-corrected visual acuity. The patients had experienced a loss of vision for at least 1 year, and visual acuity had been constant for at least 3 months prior to inclusion in the study. Fluorescein angiography showed diffuse macular edema. We used digital fluorescein angiograms, on which the size of the area with fluorescein leakage was measured for the late phase of the angiography. Additionally, the preinjection angiograms and the postinjection angiograms were graded in a masked fashion to address the ques-

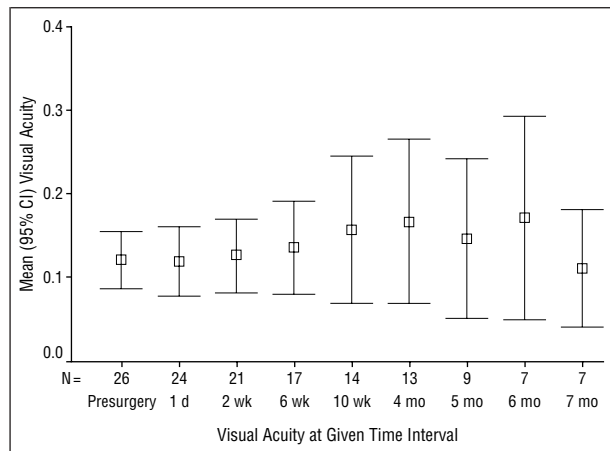


Figure 1. Diagram showing the mean \pm SD and the 95% confidence interval (CI) of visual acuity prior to and after the first intravitreal injection of 25 mg of triamcinolone acetonide.

tion on which angiogram the fluorescein leakage was more marked. For 5 eyes (19.2%), fluorescein angiograms after the injection of triamcinolone were not available. Grid laser coagulation of the macular region had been performed in 9 eyes (35%) prior to inclusion in the study. Peripheral and macular focal laser coagulation, if any, had been carried out more than 6 months prior to inclusion in the study.

Eight eyes (30.8%) were pseudophakic, for which cataract surgery had been performed at least 5 months prior to the intravitreal injection of triamcinolone. For the 18 remaining eyes, the degree of opacification of the lens was determined using slitlamp biomicroscopy and a scale ranging from 0 for "very clear lens" to 5 for "very pronounced," in the posterior subcapsular layer, the cortical layer, and the nuclear layer of the lens. Since it was an ongoing study, and because all patients who received an intravitreal cortisone injection were consecutively included in the study, the follow-up period ranged between 1 week and 18.2 months. Mean \pm SD follow-up time was 6.64 ± 6.10 months (median, 4.82 months; range, 1 week to 18.2 months).

The intravitreal injection of triamcinolone was carried out under sterile conditions in the operation theater with topical anesthesia. After a paralimbal paracentesis to puncture the anterior chamber and to reduce the intraocular volume, 0.2 mL of Ringer's solution containing 25 mg of triamcinolone acetonide was transconjunctivally injected in a distance to the limbus of 3 mm to 3.5 mm, through the pars plana into the vitreous cavity. We used a 27-gauge needle, and the injection was usually performed in the temporal inferior quadrant. Care was taken to inject triamcinolone with most of the vehicle removed. An ointment containing neomycin and polymyxin was topically applied. After the injection, the patients were asked to sit up and to keep an upright position for at least 2 hours to prevent the cortisone crystals from settling onto the macular region. All patients were reexamined on the first day after the intravitreal injection.

The patients of the study group were compared with the 16 control group patients, who also had diffuse diabetic macular edema, and who did not receive an intravitreal injection of crystalline cortisone. Mean \pm SD age was 70.54 ± 4.70 years, mean \pm SD refractive error was $+0.58 \pm 1.31$ D. Visual acuity had reduced to 0.16 ± 0.08 . As with the patients of the study group, the control group patients experienced a loss of vision for at least 1 year, and visual acuity had remained low for at least 3 months prior to inclusion in the study. Fluorescein angiography performed for all these patients showed diffuse macular edema. For all patients of the control group, we performed

grid laser coagulation of the macula. Mean \pm SD follow-up time was 7.04 ± 3.51 months (median, 6.20 months; range, 0.73-11.57 months). The control group was retrospectively formed by including all patients who had received a macular grid laser treatment within a period of 6 months preceding the start of the study, and who were matched with the study group with respect to age, sex, refractive error, and preoperative visual acuity. No macular grid laser treatment was performed in this study.

RESULTS

In the triamcinolone group, mean \pm SD visual acuity improved significantly ($P < .001$) from 0.12 ± 0.08 at baseline of the study to a maximum of 0.19 ± 0.14 during the follow-up period (**Figure 1**). Seventeen (81%) of 21 eyes that had completed a minimal follow-up period of 1 month achieved better visual acuity. Improvement in visual acuity was statistically significant at the examinations performed 6 weeks ($P = .003$), 10 weeks ($P = .01$), 5 months ($P = .03$), and 6 months ($P = .02$) after the injection (**Table**). Three to approximately 6 months after the injection, the triamcinolone crystals were resolved, and completely disappeared out of the vitreous cavity.

For the 21 patients for whom fluorescein angiograms were available during the preinjection and postinjection periods, mean \pm SD fluorescein leakage on the angiograms decreased significantly ($P < .001$), from 32.3 ± 13.6 mm^2 (range, 7.28-50.0 mm^2) at baseline, to a minimal value of 26.8 ± 15.3 mm^2 (range, 0.52-50.0 mm^2) during the follow-up period. Evaluated subjectively in a masked fashion, the postinjection angiograms of all 21 patients were graded to show less fluorescein leakage than on the preinjection angiograms.

One patient received a second intravitreal injection of 25 mg of triamcinolone acetonide, repeatedly showing an improvement in visual acuity, with intraocular pressure remaining unchanged.

In the control group, visual acuity did not change significantly during the follow-up period. At the end of the follow-up period, mean \pm SD visual acuity measured 0.15 ± 0.17 , which was not significantly different ($P = .35$) from 0.16 ± 0.08 , as determined at baseline.

In the study group, mean \pm SD intraocular pressure increased significantly ($P < .001$), from 16.9 ± 2.5 mm Hg at baseline, to a maximal value of 21.3 ± 4.7 mm Hg (median, 19.0 mm Hg; range, 16-35 mm Hg) during the follow-up period, and decreased again significantly ($P = .03$) to 17.7 ± 3.6 mm Hg at 5 months after the injection (**Table**). The intraocular pressure measurements taken at the end of the follow-up period did not vary significantly ($P = .31$) from those measured at baseline. During the study period, intraocular pressure was higher than 21 mm Hg in 9 (34.6%) of the 26 study eyes. In all these eyes, intraocular pressure could be normalized by topical antiglaucomatous medication. Glaucomatous damage to the optic nerve, as determined by biomorphometry of the optic nerve head,² was not detected in any eye.

In none of the patients did cortisone crystals settle on the macular region. They were located preretinally in the vitreous cortex at the 6-o'clock position, and they did not optically interfere with vision. In none of the eyes included in the study did postoperative infectious en-

Visual Acuity and Intraocular Pressure Prior to and After the First Intravitreal Injection of 25 mg of Triamcinolone*

	No. of Eyes	Visual Acuity, Mean ± SD	P Value	IOP, Mean ± SD, mm Hg	P Value
Baseline	26	0.12 ± 0.08		16.9 ± 2.5	
Follow-up					
1 d	24	0.12 ± 0.10	.33	16.1 ± 3.2	.09
2 wk	21	0.13 ± 0.10	.29	16.3 ± 3.8	.81
6 wk	17	0.13 ± 0.11	.003	19.0 ± 4.6	.06
2.5 mo	14	0.16 ± 0.15	.01	17.7 ± 4.5	.17
4 mo	13	0.17 ± 0.16	.08	17.7 ± 5.3	.69
5 mo	9	0.15 ± 0.12	.03	17.7 ± 3.6	.26
6 mo	7	0.17 ± 0.13	.02	18.7 ± 4.6	.03
7 mo	7	0.11 ± 0.08	.35	18.3 ± 7.3	.31

Abbreviation: IOP, intraocular pressure.

*Triamcinolone was administered as triamcinolone acetonide.

dophthalmitis or proliferative vitreoretinopathy occur. In none of the eyes was a progression of diabetic retinopathy detected.

For the 18 phakic eyes, the degree of lens opacification (mean ± SD) increased slightly, from 0.11 ± 0.32 relative units to 0.33 ± 0.67 relative units in the subcapsular layer of the lens; however, this change was not significant ($P = .16$). Lens opacification was mostly unchanged in the nuclear lens region (1.39 ± 0.50 vs 1.44 ± 0.51; $P = .56$) and in the cortical layer of the lens (1.39 ± 0.70 relative units vs 1.44 ± 0.70 relative units; $P = .32$).

COMMENT

For decades, corticosteroids have been used in ophthalmology to suppress intraocular inflammation and to reduce extravasation from leaking blood vessels. In an attempt to avoid the systemic adverse effects of steroids, and to have simultaneously high concentrations of cortisone at the site of action, Machemer, Graham, Peyman, and other researchers studied the possibility of injecting cortisone directly into the vitreous cavity in experimental settings in animals, as well as in selected clinical situations in patients.³⁻⁸ They found that crystalline cortisone may not have a toxic effect on intraocular tissue. It is in agreement with clinical observations of eyes into which cortisone was accidentally injected, and in which no major toxic reactions were detected.⁹⁻¹² Correspondingly, clinical or experimental studies have not yet shown any direct toxic reaction from cortisone that is intravitreally injected in clinical treatment trials.¹³⁻²⁸ These studies revealed that a single intravitreal injection of triamcinolone may be an adjunctive treatment for exudative age-related macular degeneration,^{14,15,17} diabetic macular edema,^{20,28} proliferative diabetic retinopathy,¹⁹ uveitic cystoid macular edema²⁶ and severe uveitis,²³ prephthical ocular hypotony,²¹ and neovascular glaucoma.¹⁸ Since cortisone is washed out of the eye within approximately 24 hours after a single intravitreal injection,²⁹ Machemer has suggested using a depot form of steroids, which, owing to an intravitreal absorption time of about 2 to 5 months, provides cortisone for a considerably longer period of time than the single injection of soluble cortisone.³⁰

The results of the present study suggest that the intravitreal injection of triamcinolone may be beneficial as a

treatment for diffuse diabetic macular edema. The patients of the study group showed a significant improvement in visual acuity compared with that seen at baseline (Figure 1 and **Figure 2**). In contrast, the visual acuity of patients receiving macular grid laser therapy did not improve. Parallel to the improvement in visual acuity, fluorescein leakage on the angiograms decreased significantly among the patients of the study group during the follow-up period (Figure 2). The results of the present study confirm previous reports showing that the intravitreal application of crystalline cortisone can improve visual acuity in patients with diffuse macular edema due to diabetic retinopathy.^{20,31} In a recent, prospective, noncomparative, interventional case series study on 16 eyes with clinically significant diabetic macular edema that had failed to respond to at least 2 previous sessions of laser photocoagulation, Martidis et al³¹ evaluated the safety and effectiveness of intravitreal injections of 4 mg of triamcinolone acetonide. They found a mean improvement in visual acuity of 2.4, 2.4, and 1.3 Snellen lines at the 1-month, 3-month, and 6-month follow-up intervals, respectively. Central macular thickness, as measured by optical coherence tomography, decreased by 55%, 57.5%, and 38%, respectively, during these same intervals, from an initial pretreatment mean of 540.3 μm. Intraocular pressure exceeded 21 mm Hg in 5, 3, and 1 eye(s), respectively, during these intervals. One eye exhibited cataract progression at 6 months. No other complications were noted during a mean follow-up of 6.2 months. As we did in the present study, Martidis et al³¹ concluded that the intravitreal injection of triamcinolone may be a promising therapeutic method for diabetic macular edema. The improvement in visual acuity in the patients of the present study was not constant for the entire follow-up period of the study. Approximately 5 months after the triamcinolone injection, visual acuity showed a tendency to decline (Figure 1). Compared with the baseline values, however, visual acuity measurements taken 6 months and 12 months after the triamcinolone injection were still slightly higher ($P = .07$; and $P = .07$), respectively. For patients who show an initial improvement in visual acuity after an intravitreal injection of triamcinolone, and who eventually experience a second decline in visual acuity some time after the injection, an intravitreal reinjection of triamcinolone may be considered.³²

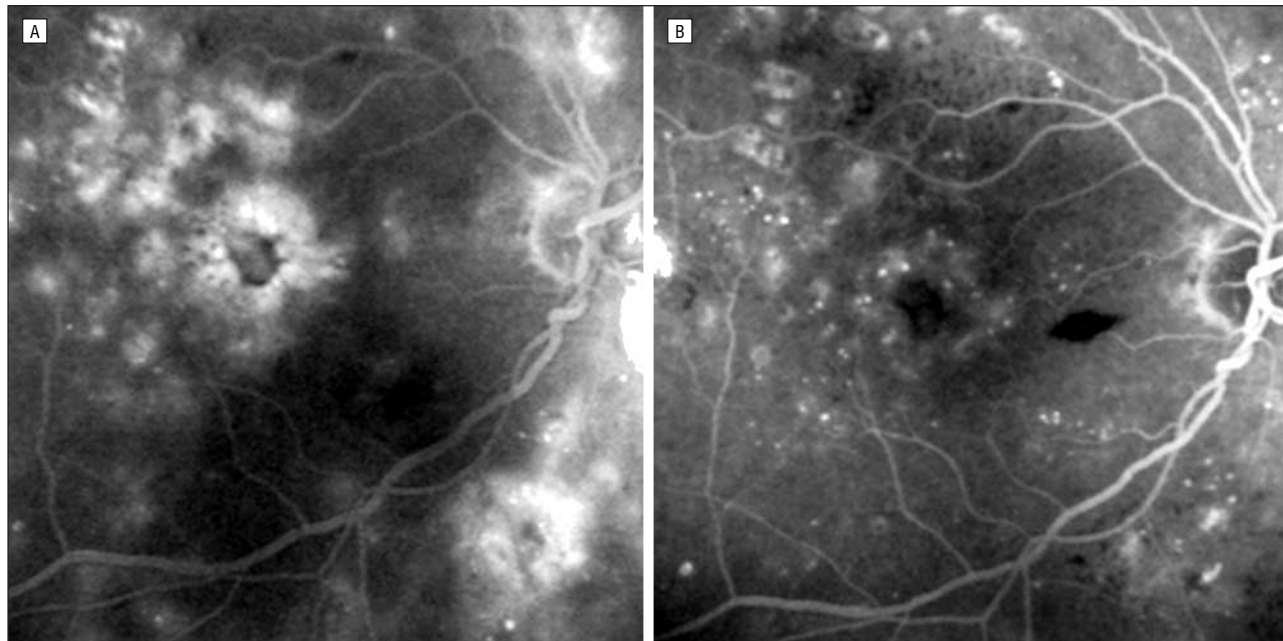


Figure 2. Late phase of a fluorescein angiogram prior to (A), and 3 months after (B), an intravitreal injection of triamcinolone acetate. Note the decrease in fluorescein leakage after the injection.

Direct toxic effects of triamcinolone on the retina and optic nerve were not observed in this study, as confirmed by other studies on eyes in which the same dosage of triamcinolone was injected for various reasons.^{16,18-21} This is confirmed by a recent safety and efficacy study of intravitreal triamcinolone for treatment of cystoid macular edema in patients with uveitis.³³ In the present study, the elevation of intraocular pressure above 21 mm Hg that occurred in 9 eyes (34.6%) was not a major problem. In all these eyes, intraocular pressure could be controlled by topical antiglaucomatous treatment until the triamcinolone crystals had disappeared. Glaucomatous changes in the appearance of the optic nerve head were not detected. Similar observations were made by Wingate and Beaumont¹⁵ and Martidis et al³¹ using a dosage of 4 mg of triamcinolone acetate, as well as in other previous studies using a dosage of 25 mg of triamcinolone.^{16,18-21,34}

A major difference between previous studies on the intravitreal application of triamcinolone and this investigation is the dosage of triamcinolone intravitreally injected. In all previous descriptions of intravitreal triamcinolone for cystoid macular edema, diabetic macular edema, and macular degeneration,^{14,15,17,26,28,31} a dosage of 4 mg of triamcinolone was used. We used 25 mg of triamcinolone acetate instead of 4 mg because from the beginning of our ongoing triamcinolone studies, now involving more than 300 patients with various diseases, we have used the same dosage of 25 mg, and we have not yet seen adverse effects that may be attributed to that high dosage.^{16,18-21,32,34-38} It also holds true for repeated intravitreal injections of 25 mg of triamcinolone acetate.³²

The most important limitation of the present study is that it is not a randomized prospective investigation in which the patients were randomly distributed between the study group and the control group. The control group and the study groups, however, were matched for general and ocular parameters, including preopera-

tive visual acuity. Yet, in 17 of the 21 eyes with a follow-up period of more than 1 month, visual acuity improved after the injection of triamcinolone, whereas in the control group, visual acuity did not change significantly. Other limitations of the study are the relatively small number of patients included in the study group and the control group, and the relatively short follow-up period in the study group.

In conclusion, in the present study, with a prospective, noncomparative, interventional case series study design, an intravitreal injection of triamcinolone resulted in an improvement in visual acuity in patients with diffuse diabetic macular edema. In agreement with previous studies, major adverse effects, such as an untreatable high increase in intraocular pressure, were not observed. Future randomized studies with a larger number of patients, may show whether the results of the present study, as well as of previous investigations,³¹ can be confirmed, suggesting that the intravitreal application of crystalline steroids may be an additional tool in the armamentarium of treating clinically significant diffuse diabetic macular edema.

Submitted for publication March 19, 2002; final revision received August 30, 2002; accepted September 17, 2002.

This study was presented as a poster at the Annual Meeting of the American Academy of Ophthalmology, New Orleans, La, November 11-14, 2001.

Corresponding author: Jost B. Jonas, MD, Universitäts-Augenklinik, Theodor-Kutzer-Ufer 1-3, 68167 Mannheim, Germany (e-mail: jost.jonas@augen.ma.uni-heidelberg.de).

REFERENCES

1. Early Treatment Diabetic Retinopathy Study Research Group. Photocoagulation for diabetic macular edema: Early Treatment Diabetic Retinopathy Study report number 1. *Arch Ophthalmol.* 1985;103:1796-1806.

2. Jonas JB, Budde WM, Panda-Jonas S. Ophthalmoscopic evaluation of the optic nerve head. *Surv Ophthalmol*. 1999;43:293-320.
3. Machemer R, Sugita G, Tano Y. Treatment of intraocular proliferations with intravitreal steroids. *Trans Am Ophthalmol Soc*. 1979;77:171-180.
4. Graham RO, Peyman GA. Intravitreal injection of dexamethasone: treatment of experimentally induced endophthalmitis. *Arch Ophthalmol*. 1974;92:149-154.
5. Tano Y, Sugita G, Abrams G, Machemer R. Inhibition of intraocular proliferation with intravitreal corticosteroid. *Am J Ophthalmol*. 1980;89:131-136.
6. Tano Y, Chandler D, Machemer R. Treatment of intraocular proliferation with intravitreal injection of triamcinolone acetonide. *Am J Ophthalmol*. 1980;90:810-816.
7. McCuen BW II, Bessler M, Tano Y, et al. The lack of toxicity of intravitreally administered triamcinolone acetonide. *Am J Ophthalmol*. 1981;91:785-788.
8. Hida T, Chandler D, Arena JE, Machemer R. Experimental and clinical observations of the intraocular toxicity of commercial corticosteroid preparations. *Am J Ophthalmol*. 1986;101:190-195.
9. Giles CL. Bulbar perforation during periocular injection of corticosteroids. *Am J Ophthalmol*. 1974;77:438-441.
10. McLean EB. Inadvertent injection of corticosteroid into the choroidal vasculature. *Am J Ophthalmol*. 1975;80:835-837.
11. Zinn KM. Iatrogenic intraocular injection of depot corticosteroids and its surgical removal using the pars plana approach. *Ophthalmology*. 1981;88:13-17.
12. Ghopal L, Bhende M, Sharma T. Vitrectomy for accidental intraocular steroid injection. *Retina*. 1995;15:295-299.
13. Coats ML, Peyman GA. Intravitreal corticosteroids in the treatment of exogenous fungal endophthalmitis. *Retina*. 1992;12:46-51.
14. Challa JK, Gillies MC, Penfold PL, et al. Exudative macular degeneration and intravitreal triamcinolone: 18 month follow up. *Aust N Z J Ophthalmol*. 1998;26:277-281.
15. Wingate RJ, Beaumont PE. Intravitreal triamcinolone and elevated intraocular pressure. *Aust N Z J Ophthalmol*. 1999;27:431-432.
16. Jonas JB, Hayler JK, Panda-Jonas S. Intravitreal injection of crystalline cortisone as adjunctive treatment of proliferative vitreoretinopathy. *Br J Ophthalmol*. 2000;84:1064-1067.
17. Danis RP, Ciulla TA, Pratt LM, Anliker W. Intravitreal triamcinolone acetonide in exudative age-related macular degeneration. *Retina*. 2000;20:244-250.
18. Jonas JB, Hayler JK, Söfker A, Panda-Jonas S. Regression of neovascular iris vessels by intravitreal injection of crystalline cortisone. *J Glaucoma*. 2001;10:284-287.
19. Jonas JB, Hayler JK, Söfker A, Panda-Jonas S. Intravitreal injection of crystalline cortisone as adjunctive treatment of proliferative diabetic retinopathy. *Am J Ophthalmol*. 2001;131:468-471.
20. Jonas JB, Söfker A. Intraocular injection of crystalline cortisone as adjunctive treatment of diabetic macular edema. *Am J Ophthalmol*. 2001;132:425-427.
21. Jonas JB, Hayler JK, Panda-Jonas S. Intravitreal injection of crystalline cortisone as treatment of pre-phthisical ocular hypotony. *Graefes Arch Clin Exp Ophthalmol*. 2001;239:464-465.
22. Peyman GA, Cheema R, Conway MD, Fang T. Triamcinolone acetonide as an aid to visualization of the vitreous and the posterior hyaloid during pars plana vitrectomy. *Retina*. 2000;20:554-555.
23. Jaffe GJ, Ben-nun J, Guo H, et al. Fluocinolone acetonide sustained drug delivery device to treat severe uveitis. *Ophthalmology*. 2000;107:2024-2033.
24. Kivilcim M, Peyman GA, El-Dessouky ES, et al. Retinal toxicity of triamcinolone acetonide in silicone-filled eyes. *Ophthalmic Surg Lasers*. 2000;31:474-478.
25. Reinhard T, Sundmacher R. Adjunctive intracameral application of corticosteroids in patients with endothelial immune reactions after penetrating keratoplasty: a pilot study. *Transpl Int*. 2002;15:81-88.
26. Antcliff RJ, Spalton DJ, Stanford MR, Graham EM, Ffytche TJ, Marshall J. Intravitreal triamcinolone for uveitic cystoid macular edema: an optical coherence tomography study. *Ophthalmology*. 2001;108:765-772.
27. Martidis A, Duker JS, Puliafito CA. Intravitreal triamcinolone for refractory cystoid macular edema secondary to birdshot retinochoroidopathy. *Arch Ophthalmol*. 2001;119:1380-1383.
28. Greenberg PB, Martidis A, Rogers AH, Duker JS, Reichel E. Intravitreal triamcinolone acetonide for macular oedema due to central retinal vein occlusion. *Br J Ophthalmol*. 2002;86:247-248.
29. Schindler RH, Chandler DB, Thresher R, Machemer R. The clearance of intravitreal triamcinolone acetonide. *Am J Ophthalmol*. 1982;93:415-417.
30. Machemer R. Five cases in which a depot steroid (hydrocortisone acetate and methylprednisolone acetate) was injected into the eye. *Retina*. 1996;16:166-167.
31. Martidis A, Duker JS, Greenberg PB, et al. Intravitreal triamcinolone for refractory diabetic macular edema. *Ophthalmology*. 2002;109:920-927.
32. Jonas JB, Kreissig I, Degenring RF. Repeated intravitreal injections of triamcinolone acetonide as treatment of progressive exudative age-related macular degeneration: brief report. *Graefes Arch Clin Exp Ophthalmol*. 2002;240:872-873.
33. Young S, Larkin G, Branley M, Lightman S. Safety and efficacy of intravitreal triamcinolone for cystoid macular oedema in uveitis. *Clin Exp Ophthalmol*. 2001;29:2-6.
34. Jonas JB, Kreissig I, Degenring R. Intraocular pressure after intravitreal injection of triamcinolone acetonide. *Br J Ophthalmol*. In press.
35. Jonas JB, Kreissig I, Degenring RF. Intravitreal triamcinolone acetonide as treatment of macular edema in central retinal vein occlusion. *Graefes Arch Clin Exp Ophthalmol*. 2002;240:782-783.
36. Jonas JB, Söfker A. Intravitreal triamcinolone acetonide for cataract surgery with iris neovascularisation. *J Cataract Refract Surg*. In press.
37. Degenring RF, Jonas JB. Intravitreal injection of triamcinolone acetonide as treatment of chronic uveitis: brief report. *Br J Ophthalmol*. In press.
38. Jonas JB, Kreissig I, Hugger P, Sauder G, Panda-Jonas S, Degenring R. Intravitreal triamcinolone acetonide for exudative age-related macular degeneration. *Br J Ophthalmol*. In press.

Notice to the Authors of Reports From Clinical Trials

The *Journal of the American Medical Association (JAMA)* and the *Archives of Ophthalmology* function as an editorial consortium.

With one submission and one set of reviews, your clinical trial manuscript will be considered for publication in both *JAMA* and the *Archives of Ophthalmology*.

Submit your paper to the journal of your choice according to the appropriate "Instructions for Authors" and the following guidelines will apply:

1. If your manuscript is accepted by *JAMA*, it will be considered for an editorial or commentary in *JAMA*. Your abstract will also be published in the *Archives of Ophthalmology* with a commentary or editorial.
2. If your manuscript is accepted by the *Archives of Ophthalmology*, it will be considered for an editorial or commentary in the *Archives of Ophthalmology*. Your abstract will also be considered for publication in *JAMA*.