

This is an Open Access article licensed under the terms of the Creative Commons Attribution-NonCommercial-NoDerivs 3.0 License (www.karger.com/OA-license), applicable to the online version of the article only. Distribution for non-commercial purposes only.

Intravitreal Ranibizumab and Laser Photocoagulation in the Management of Idiopathic Juxtafoveolar Retinal Telangiectasia Type 1: A Case Report

Angela Ciarnella Sara Verrilli Vito Fenicia
Cristina Mannino Alessandro Cutini Andrea Perdicchi
Santi Maria Recupero

Ophthalmology Unit, NESMOS Department, S. Andrea Hospital, Faculty of Medicine and Psychology, 'Sapienza' University of Rome, Rome, Italy

Key Words

Idiopathic juxtafoveolar retinal telangiectasia · Intravitreal injection · Laser photocoagulation · Ranibizumab

Abstract

Background: Idiopathic juxtafoveolar retinal telangiectasia (IJRT) type 1 represents an uncommon cause of congenital unilateral visual loss and it typically affects males. Decrease in visual acuity is caused by serous and lipid exudation into the fovea with cystoid macular edema. In some cases, spontaneous resolution may be observed, but when there is a progressive loss of visual acuity, laser photocoagulation is often necessary. This treatment is not always successful and therapy for this condition is still controversial.

Case Presentation: A 57-year-old man referred a 2-month history of blurred and distorted vision in the right eye. Best-corrected visual acuity was 20/50 in the right eye and 20/20 in the left eye. Fundus examination showed temporal macular edema, confirmed by optical coherence tomography. Fluorescein angiography showed a localized area of hyperfluorescence probably due to telangiectasia type 1 located below the inferior temporal area of the fovea. A combined therapy of intravitreal ranibizumab injection and laser photocoagulation was performed. Visual acuity improved from 20/50 to 20/32 and the therapy was well tolerated by the patient. After 3 years of follow-up, both visual acuity and fundus examination were stable.

Conclusions: This case suggests that the combined use of ranibizumab and laser photocoagulation may be considered an effective treatment for JRT type 1, leading to an

improvement in both visual acuity and macular edema. We believe that intravitreal ranibizumab injection associated with laser photocoagulation should be considered as treatment for IJRT type 1.

Introduction

Idiopathic juxtafoveolar retinal telangiectasia (IJRT) is an uncommon cause of unilateral or bilateral visual loss. IJRT may occur as a primary disorder, either congenital or acquired, or may be involved in other systemic or ocular diseases. Dilation and incompetence of juxtafoveolar capillaries lead to the development of intraretinal edema and/or choroidal neovascularization (CNV) [1]. Idiopathic juxtafoveolar telangiectasia is a condition of unknown etiology, characterized by abnormal retinal vessels usually located temporally to the fovea. This condition should be differentiated from similar patterns such as venous occlusive diseases, diabetic retinopathy, Eales disease and radiation retinopathy. It should also be differentiated from dilation of perifoveal capillaries associated with vitreous cellular infiltration, secondary to inflammatory diseases or tapetoretinal dystrophies [2, 3]. IJRT is commonly underdiagnosed and ancillary tests could be useful. Optical coherence tomography (OCT) can help to identify abnormal vessels, pigment plaques, retinal crystals, foveal atrophy and associated retinal cysts. The use of fluorescein angiography (FA) is controversial. Some authors consider FA necessary to identify abnormalities in vascular vessels while others affirm that the diagnosis can be carried out using less invasive exams.

Fundus findings in IJRT involve a focal area of reduced retinal transparency and/or small retinal hemorrhages temporally to the fovea. Dilated perifoveal capillaries can be hardly observed during biomicroscopic examination but they can be identified through the use of FA [2, 4]. Gass and Blodi [2] classified IJRT in three groups. Group 1 shows congenital or acquired unilateral parafoveal telangiectasia. It typically occurs in males and resembles a macular variant of Coats' disease with a circinate type of exudates. Group 2 has occult bilateral perifoveal telangiectasia in both males and females, usually with bilateral thickening. Intralesional retinal pigment epithelium migration is often present and CNV may subsequently develop. Group 3 includes patients presenting clinically visible bilateral perifoveal telangiectasia with capillary obliteration [5]. The visual prognosis and the efficacy of therapy are strictly related to the etiology of retinal telangiectasia. While only few therapies (mostly laser photocoagulation) have been used for IJRT type 1, several treatments have been proposed for IJRT type 2, including focal/grid laser [6], surgical removal of the subretinal neovascular membrane [7], photodynamic therapy [8] and intravitreal injection of triamcinolone acetonide [9] or antiangiogenic drugs (bevacizumab, ranibizumab) [10]. We report on a male patient affected by IJRT type 1 who was treated with an intravitreal injection of ranibizumab followed by laser photocoagulation.

Case Presentation

In October 2007, we examined a 57-year-old man complaining of blurred and distorted vision in the right eye (RE). He had been reporting these symptoms for 2 months. His past medical history was

significant only for mild hypertension. Best-corrected visual acuity (BCVA) was 20/50 in the RE and 20/20 in the left eye (LE). Amsler grid test demonstrated metamorphopsia in the RE and normal findings in the LE. Biomicroscopic fundus examination revealed foveal thickening with macular edema and inferior temporal parafoveal exudates in the RE. The macular area appeared to be within normal limits in the LE. Optic nerve, peripheral retina and vitreous body were normal in both eyes. OCT showed an alteration of the choriocapillary pigment epithelium barrier, a temporal macular edema and an increased foveal thickness (ft 280 μm) in the RE (fig. 1). FA revealed a localized area of hyperfluorescence with telangiectasia of capillaries located inferiorly temporally to the fovea in the RE. These features increased during late stages of FA due to active leakage of dilated juxtafoveal capillaries (fig. 2). The patient also underwent an automated visual field examination (Humphrey 10/2 SITA Standard) that revealed a defect in the superior nasal field of the RE (fig. 3); no alterations were detected in the LE.

The presence of a unilateral lesion with these features led us to the diagnosis of idiopathic juxtafoveal telangiectasia type 1. One intravitreal injection of ranibizumab (dose 0.5 mg/0.05 ml) was performed in the RE. Two weeks after the injection, BCVA was 20/40 in the RE. OCT revealed a mild reduction of the macular edema (ft 240 μm), and a focal Argon laser photocoagulation was performed on the perifoveal area respecting the central avascular area of the fovea. Argon laser photocoagulation of the telangiectatic malformations was done with these parameters: 200 spots, 500 μm of diameter, 700 mW of power and 0.2 s of time. After 7 days, BCVA was 20/32 in the RE and FA showed hypofluorescence in those areas where laser treatment was performed. Furthermore, improvement in the inferior temporal macular area was highlighted by decreased hyperfluorescence. OCT showed resolution of the macular edema (ft 220 μm), although an alteration of the choriocapillary pigment epithelium barrier, temporally to the macula, could still be observed. One month later, both BCVA and OCT were still stable. A complete ophthalmic examination (including BCVA, OCT, FA) was carried out every 6 months and, after three years, BCVA remained 20/32 in the RE. OCT showed no macular edema (fig. 1). FA showed hypofluorescence in the area of the laser treatment associated with light hyperfluorescence due to dye staining in the inferior temporal perimacular area (fig. 2). The automated visual field examination was within normal limits (fig. 3).

Written informed consent was obtained from the patient for publication of this case report and any accompanying images. A copy of the consent is available for review.

Discussion

The natural history of IJRT commonly shows a slowly progressive decay of visual function, and a regular follow-up is necessary due to the risk of associated macular edema or CNV. In these cases, an appropriate therapy should be started as soon as possible. Several treatments have been reported mainly for IJRT type 2. Among them, antiangiogenic drugs such as bevacizumab or ranibizumab have been successfully applied in the treatment of CNV [11]; moreover bevacizumab has been used to treat idiopathic macular telangiectasia type 1. It is known that the use of antiangiogenic drugs may prove useful to reduce neovascularization and edema. In our case of IJRT type 1, one intravitreal injection of ranibizumab was performed followed by laser treatment of the exudates. The effect of ranibizumab led to an improvement of visual acuity and a reduction of macular edema. Additionally, laser photocoagulation appeared to be effective in the treatment of exudative retinopathy which is typical of IJRT type 1. In fact, IJRT type 1 is mostly exudative and nonfamilial, while types 2 and 3 are primarily non-exudative, obstructive and only occasionally familial. In our case, regular controls performed every 6 months for about 3 years demonstrated a stable clinical condition of the patient's eye without any side effects.

This case report is, to our knowledge, the first in which intravitreal ranibizumab injection followed by laser photocoagulation have been used to treat JRT type 1. The anti-edema and anti-angiogenic properties of ranibizumab could reduce the exudation typically present in IJRT type 1 allowing also a better effect of the laser photocoagulation. In our case, the laser photocoagulation could not be performed at the diagnosis because the presence of macular edema would have reduced the efficacy of the laser treatment. One ranibizumab injection was sufficient to induce a decrease of the macular edema after 15 days, allowing the subsequent laser photocoagulation

This case suggests that the combined use of ranibizumab and laser photocoagulation may be considered an effective treatment for JRT type 1, leading to an improvement in both visual acuity and macular edema.

Disclosure Statement

The authors have no commercial or conflict of interest to declare.

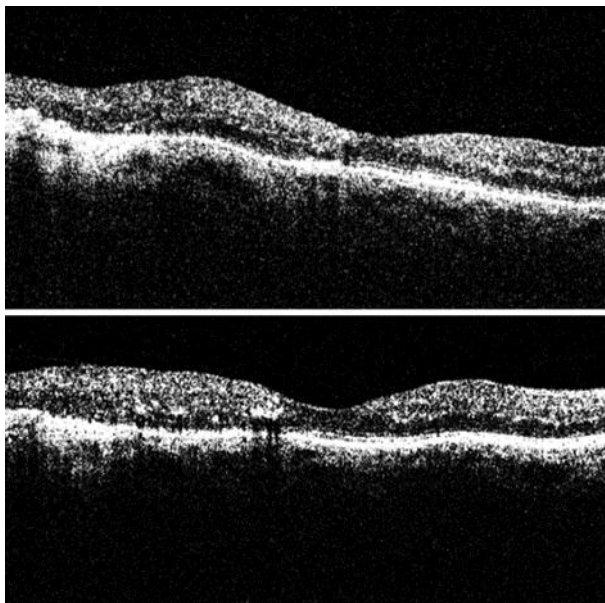


Fig. 1. Pre- and post-treatment OCT of the RE. The upper panel shows an increase of retinal thickness temporally to the macula and an alteration of the choriocapillary pigment epithelium barrier. The lower panel shows reduction of the macular edema with persistence of an alteration of the choriocapillary pigment epithelium barrier.

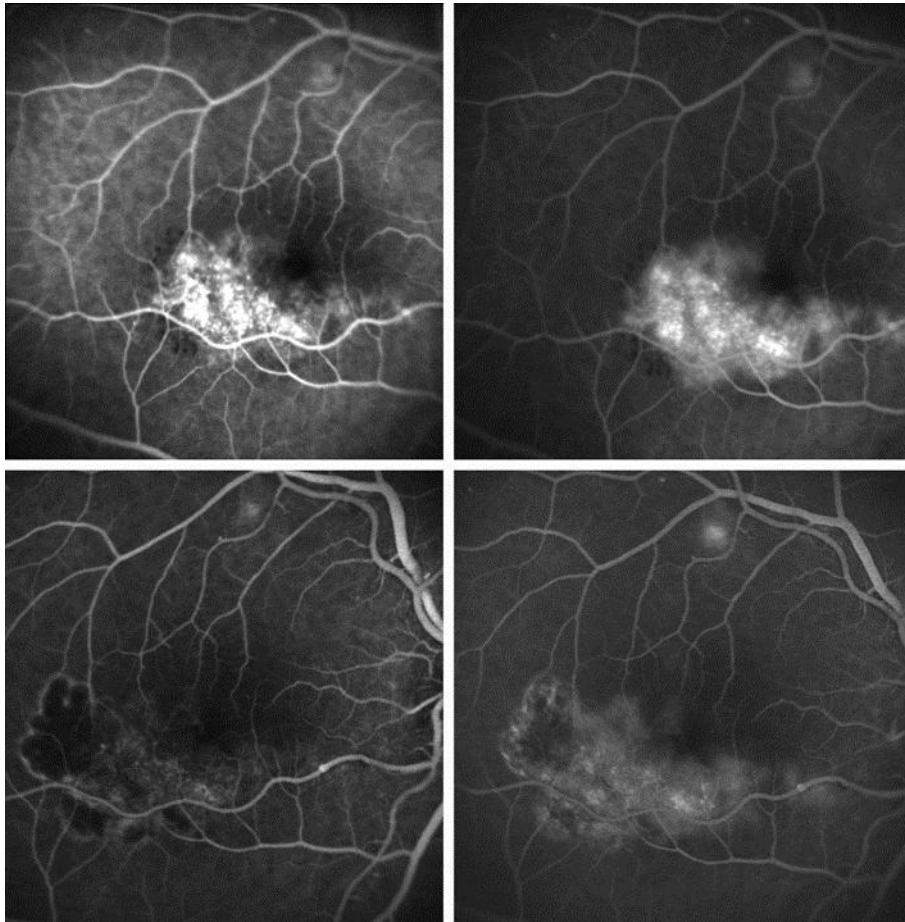


Fig. 2. Pre- and post-treatment FA of the RE. Upper panels: early and late frames showing leakage of juxtafoveal capillaries. Lower panels: early and late frames showing a hypofluorescent area corresponding to laser treatment and dye staining in the inferior temporal macular area.

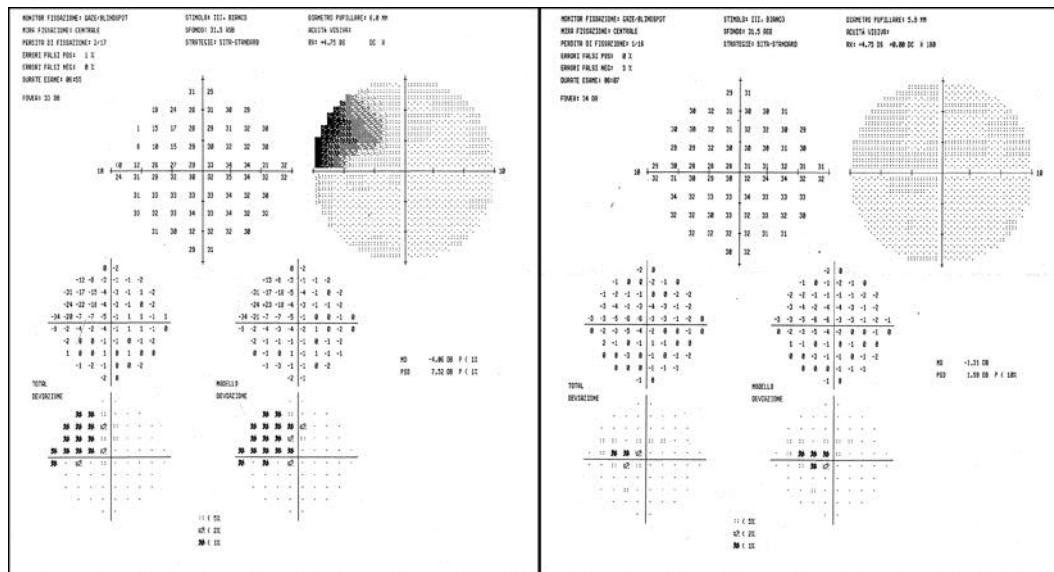


Fig. 3. Automated computerized perimetry of the RE pre- and post-treatment. The left panel shows the visual field of the RE revealing a defect in the superior nasal field. The right panel shows a visual field within normal limits.

References

- 1 Tasca J, Grogg JA: Idiopathic juxtafoveolar retinal telangiectasia: a review and case report. *Clin Eye Vis Care* 2000;12:79–87.
- 2 Gass JD, Blodi BA: Idiopathic juxtafoveolar retinal telangiectasia. Update of classification and follow-up study. *Ophthalmology* 1993;100:1536–1546.
- 3 Gass JD, Oyakawa RT: Idiopathic juxtafoveolar retinal telangiectasia. *Arch Ophthalmol* 1982;10:769–780.
- 4 Abujarra S, Bonanomi MT, Cresta FB, Machado CG, Pimentel SL, Caramelli CB: Idiopathic juxtafoveolar retinal telangiectasia: Clinical pattern in 19 cases. *Ophthalmologica* 2000;214:406–411.
- 5 Issacs TW, McAllister IL: Familial idiopathic juxtafoveolar retinal telangiectasia. *Eye* 1996;10:639–642.
- 6 Park DM, Schatz H, Mc Donald HR, Johnson RN: Grid laser photocoagulation for macular edema in bilateral juxtafoveal retinal telangiectasia. *Ophthalmology* 1997;104:1838–1846.
- 7 Berger AS, McCuen BW 2nd, Brown GC, Brownlow RL Jr: Surgical removal of subfoveal neovascularization in idiopathic juxtafoveal telangiectasia. *Retina* 1997;17:94–98.
- 8 Snyers B, Verougstraete C, Postelmans L, Leys A, Hykin P: Photodynamic therapy of subfoveal neovascular membrane in type 2A idiopathic juxtafoveal retinal telangiectasia. *Am J Ophthalmol* 2004;137:812–819.
- 9 Alldredge CD, Garreston BR: Intravitreal triamcinolone for the treatment of idiopathic juxtafoveal telangiectasia. *Retina* 2003;23:113–116.
- 10 Mavranakas N, Mendrinos E, Pournaras CJ, Salzmann J: Intravitreal ranibizumab and bevacizumab for bilateral subretinal neovascularization secondary to idiopathic juxtafoveal telangiectasia type 2A. *Acta Ophthalmol* 2009;87:930–932.
- 11 Kovach JL, Rosenfeld PJ: Bevacizumab (avastin) therapy for idiopathic macular telangiectasia type II. *Retina* 2009;29:27–32.