

Intravitreal Triamcinolone for the Treatment of Macular Edema Associated With Central Retinal Vein Occlusion

Michael S. Ip, MD; Justin L. Gottlieb, MD; Alon Kahana, MD, PhD; Ingrid U. Scott, MD, MPH; Michael M. Altaweel, MD; Barbara A. Blodi, MD; Ronald E. Gangnon, PhD; Carmen A. Puliafito, MD, MBA

Objective: To investigate the safety and efficacy of intravitreal triamcinolone acetonide as treatment for macular edema associated with central retinal vein occlusion (CRVO).

Methods: We reviewed the medical records of 13 consecutive patients (13 eyes) with macular edema associated with CRVO who were treated with an injection of intravitreal triamcinolone acetonide (4 mg) at the University of Wisconsin and the Bascom Palmer Eye Institute. Each intravitreal injection was delivered through the pars plana using a 27- or 30-gauge needle.

Main Outcome Measures: Change in Snellen visual acuity, clinical appearance of macular edema, measurement of foveal thickening with optical coherence tomography (OCT), and frequency of complications.

Results: The median age of the 13 patients was 67 years (interquartile range, 57-77 years), and the median duration of symptoms before injection was 8 months (interquartile range, 4-9 months). Mean baseline visual acuity was 20/500 in the affected eye. Mean visual acuity at the 6-month follow-up examination was 20/180 in the affected eye. All 13 patients completed the 6-month examination. Eyes with nonischemic CRVO (n=5) demonstrated a significant improvement in visual acuity, whereas eyes with ischemic CRVO (n=8) demonstrated a nonsignificant visual acuity improvement. No patient had a de-

crease in visual acuity. Mean baseline foveal thickness as measured by OCT was 590 μm (retinal thickening=416 μm). Mean foveal thickness as measured by OCT at the 1-month follow-up examination in 12 patients was 212 μm (retinal thickening=38 μm). At the 3-month follow-up examination, mean foveal thickness as measured by OCT for 13 patients was 193 μm (retinal thickening=19 μm). Between the 3- and 6-month follow-up examinations, 4 patients developed a recurrence of macular edema. Three of the 4 patients were retreated with a second injection of triamcinolone. Two of these 3 patients experienced an improvement in visual acuity following retreatment. At the 6-month follow-up examination, mean foveal thickness as measured by OCT for 13 patients was 281 μm (retinal thickening=107 μm). No adverse effects such as retinal detachment or endophthalmitis occurred. One patient experienced an increase in intraocular pressure that was controlled with 2 aqueous suppressants.

Conclusions: Intravitreal injection of triamcinolone appears to be a possibly effective treatment in some patients with macular edema associated with CRVO. Patients with nonischemic CRVO may respond more favorably than patients with ischemic CRVO, and retreatment may be necessary in some patients. In this case series, severe complications were not noted.

Arch Ophthalmol. 2004;122:1131-1136

From the Department of Ophthalmology and Visual Science (Drs Ip, Gottlieb, Kahana, Altaweel, and Blodi) and Department of Biostatistics and Medical Informatics (Dr Gangnon), University of Wisconsin, Madison; and the Bascom Palmer Eye Institute, Department of Ophthalmology, University of Miami School of Medicine, Miami, Fla (Drs Scott and Puliafito). The authors have no relevant financial interest in this article.

CENTRAL RETINAL VEIN OCCLUSION (CRVO) is a common retinal vascular disorder. It has a characteristic clinical appearance with intraretinal hemorrhage, tortuous and dilated retinal veins, and in some cases optic disc edema. Macular edema is a frequent cause of visual acuity loss in patients with CRVO.¹⁻⁴

Macular edema from venous occlusive disease is caused by the initial occurrence of thrombus formation at the lamina cribrosa or an arteriovenous crossing. Green et al,⁵ in a histopathologic study of 29 eyes with CRVO, documented a new or recanalized thrombus of the central reti-

nal vein in the area of the lamina cribrosa as a common pathologic finding. Experimental studies in animals have demonstrated that a hypoxic environment in the retina is produced after venous occlusion.⁶ This is followed by functional and later structural changes in the retinal capillaries. These changes cause an immediate increase in retinal capillary permeability and accompanying retinal edema.

The increase in retinal capillary permeability and subsequent retinal edema may be the result of a breakdown of the blood-retinal barrier, possibly mediated in part by vascular endothelial growth factor (VEGF), a 45-kDa glycoprotein.⁷ Antonetti et al⁸ demon-

strated that VEGF may regulate vessel permeability by increasing phosphorylation of tight junction proteins such as occludin and zonula occluden 1. This model provides, at the molecular level, a potential mechanism for VEGF-mediated vascular permeability in the eye. The normal human retina contains little or no VEGF; however, hypoxia causes up-regulation of VEGF production.⁹ Disease states characterized by hypoxia-induced VEGF up-regulation include CRVO.^{7,9,10}

Attenuation of the effects of VEGF introduces a rationale for the treatment of macular edema from CRVO. Corticosteroids, a class of substances with anti-inflammatory properties, have been demonstrated to inhibit the expression of the VEGF gene.¹¹ Additionally, corticosteroids have been demonstrated to abolish the induction of VEGF by the pro-inflammatory mediators platelet-derived growth factor and platelet-activating factor in a time- and dose-dependent manner.¹²

This retrospective review of intravitreal triamcinolone acetonide as a treatment for macular edema associated with CRVO was initiated because of the potential for corticosteroids to attenuate VEGF-mediated retinal capillary permeability as well as early reports of efficacy with this treatment. Intravitreal triamcinolone as a treatment for macular edema from CRVO has previously been reported in small case series.¹³⁻¹⁶ In this article, we describe a larger series of patients with longer follow-up than that reported previously.¹⁶

METHODS

PATIENT SELECTION

Informed consent was obtained from each patient. All patients had clinical evidence of CRVO with intraretinal hemorrhage and dilated, tortuous veins in all 4 quadrants in addition to macular edema. At baseline, none of the patients had retinal or anterior segment neovascularization. All eyes with 10 or more optic disc areas of nonperfusion on fluorescein angiography were judged to have ischemic CRVO. Eyes with fewer than 10 optic disc areas of nonperfusion on fluorescein angiography or eyes without an afferent pupillary defect were judged to have nonischemic CRVO. All patients were observed for at least 1 month prior to undergoing this investigative treatment.

Patients underwent clinical examination including a non-masked Snellen visual acuity test, intraocular pressure measurement, stereoscopic fundus photography, and optical coherence tomography (OCT) prior to the injection of triamcinolone. Patients underwent postoperative follow-up with repeated clinical examination including nonmasked Snellen visual acuity testing, intraocular pressure measurement, stereoscopic fundus photography, and OCT. Patients were assessed for adverse events including (but not limited to) retinal detachment, infectious endophthalmitis, noninfectious endophthalmitis, vitreous hemorrhage, cataract, and elevated intraocular pressure.

OPTICAL COHERENCE TOMOGRAPHY

We performed OCT using the Optical Coherence Tomograph 2 or 3 (Carl Zeiss Ophthalmic Systems Inc, Dublin, Calif). The same model was used for each patient throughout the study. Readings for central retinal thickness were obtained either by measuring retinal thickness directly from the axial scan with the largest thickness measurement or from the mean retinal thickness in the central subfield (500- μ m radius). The measurement from the central subfield was used whenever possible; in patient 1, patient 4, and patient 5, only the retinal thickness measurement from the axial

scan was available. In these patients, the axial scan measurements were used in place of the central subfield measurement to derive retinal thickening values, determined at baseline and follow-up.

For the purpose of this study, retinal thickening was calculated as follows: retinal thickening = actual retinal thickness – normal retinal thickness. The actual retinal thickness was the value measured by the Optical Coherence Tomograph 2 or 3. In all patients (except patient 1, patient 4, and patient 5), the actual retinal thickness value was derived from the mean retinal thickness in the central subfield (500- μ m radius). Normal retinal thickness was the retinal thickness expected in a normal eye without evidence of diabetes. Normal retinal thickness was estimated according to a study by Hee et al¹⁷ in which the mean \pm SD thickness in the central subfield (500- μ m radius) was 174 \pm 18 μ m. A separate study by Muscat et al¹⁸ showed similar estimates of normal retinal thickness using a central subfield with an 800- μ m radius.

TREATMENT TECHNIQUE

In all patients, the intravitreal injection of triamcinolone was performed in the outpatient setting. Topical 0.5% proparacaine hydrochloride (Bausch & Lomb, Tampa, Fla) was applied to the ocular surface followed by preparation of the eyelids and conjunctiva with 5% povidone iodine. An eyelid speculum was used to stabilize the eyelids, and a cotton-tipped applicator soaked in the anesthetic was then applied over the inferotemporal injection site for 1 minute. Triamcinolone acetonide was injected slowly through the inferior pars plana at a dose of 4 mg (0.1 mL). No attempt was made to remove or dilute the vehicle. A 27-gauge or 30-gauge needle was used for the injection. The inferior pars plana was preferred to minimize postprocedural floaters because the injected triamcinolone rapidly localizes to dependent areas of the vitreous cavity following treatment. Indirect ophthalmoscopy was performed following the injection to confirm proper intravitreal localization of the suspension and perfusion of the optic nerve head. An aqueous tap using a 30-gauge needle through a corneal paracentesis was performed, if necessary, to decrease the intraocular pressure to normal levels following the injection.

STATISTICAL ANALYSIS

Visual acuity and retinal thickening at the baseline and follow-up visits were summarized using mean \pm SD. Changes from baseline to follow-up were assessed using the paired *t* test. Analyses of visual acuity were performed by converting Snellen visual acuity measurements to logMAR equivalents. Results are presented in both logMAR units, which were used for analysis, and the equivalent Snellen visual acuity notation. Analyses are presented for the entire series as well as for ischemic and nonischemic subgroups.

RESULTS

Patients were assessed at baseline and at 1, 3, and 6 months following initial intravitreal triamcinolone injection. The baseline and follow-up patient data are included in **Table 1**. The median age of patients included in this study was 67 years (interquartile range, 57-77 years). The median duration of symptoms (according to patient history) prior to treatment was 8 months with an interquartile range of 4 to 9 months. Eight eyes had ischemic CRVO, and 5 eyes had nonischemic CRVO.

Visual acuity measurements are summarized in **Table 2**. The baseline mean visual acuity was 20/500 in the affected eye. For the 13 eyes included in this study, there was a significant improvement in visual acuity at 1, 3, and 6 months of follow-up. The mean visual acuity values at these

Table 1. Baseline and Follow-up Data for 13 Patients Treated With Intravitreal Injection(s) of Triamcinolone

Patient/Eye/Age, y	Duration of ME	Type of CRVO	Visual Acuity				Lines Gained	Retinal Thickness, μm			
			Initial	1 mo	3 mo	6 mo		Initial	1 mo	3 mo	6 mo
1/L/67	8	I	20/400	20/100	20/100	20/200	1	600	100	100	500
2/R/57	9	N	20/200	20/25	20/25	20/25	8	600	100	100	100
3/R/69	8	N	CF	20/50	20/50	20/70	5	500	180	180	180
4/L/81	8	N	20/800	20/200	20/200	20/100	3	500	220	220	220
5/L/77	9	I	CF	CF	20/400	20/400	1	500	200	200	200
6/R/67	36	I	20/400	20/400	20/400	20/400	0	400	150	150	150
7/L/50	6	N	20/400	20/40	20/20	20/30	8	600	200	200	200
8/L/83	9	I	20/800	20/800	20/800	20/800	0	600	300	200	200
9/R/83	4	I	20/400	20/400	20/200	20/200	1	620	NA	150	500
10/R/56	4	N	20/200	20/60	20/80	20/80	2	600	150	300	600
11/L/40	3	I	20/300	20/300	20/200	20/200	1	600	380	260	260
12/L/75	>12	I	8/200	8/200	2/200	20/400	1	600	340	240	230
13/R/58	0.5	I	2/200	20/60	20/60	3/200	0	570	230	200	320

Patient	IOP, mm Hg				Time to Recurrence, mo	Reinjection (Mo)
	Initial	1 mo	3 mo	6 mo		
1	10	9	17	11	4	No
2	17	18	16	23	0	No
3	15	14	24	20	0	No
4	17	19	20	22	0	No
5	14	18	17	18	0	No
6	22	20	18	20	0	No
7	20	20	20	23	5.5	Yes (5.5)
8	18	23	21	20	0	No
9	10	15	18	20	0	No
10	18	28	38	16	4	Yes (4)
11	17	24	26	22	0	No
12	14	12	11	12	0	No
13	17	19	16	15	6	Yes (6)

Abbreviations: CF, counting fingers; CRVO, central retinal vein occlusion; I, ischemic; IOP, intraocular pressure; L, left; ME, macular edema; N, nonischemic; NA, not applicable; R, right.

*Eyes were phakic in all patients.

time points were 20/160 ($P = .007$), 20/150 ($P = .008$), and 20/180 ($P = .002$), respectively, in the affected eye.

These grouped visual acuity results appear to be influenced primarily by the nonischemic eyes. Nonischemic eyes benefited with a statistically significant visual acuity improvement at each time point: the mean visual acuity at baseline was 20/400 compared with 20/60 at 1 month ($P = .004$), 20/50 at 3 months ($P = .008$), and 20/50 at 6 months ($P = .003$). The ischemic eyes also demonstrated improvement in visual acuity, but the improvement was statistically significant only at the 6-month follow-up examination; the mean visual acuity at baseline was 20/600 compared with 20/325 at 1 month ($P = .21$), 20/300 at 3 months ($P = .21$), and 20/400 at 6 months ($P = .01$).

We assessed gain or loss of lines of Snellen visual acuity. The mean gain in visual acuity was 2.2 lines (range, 0 to +8). Four of the 13 patients experienced a visual acuity gain of 3 or more lines at the 6-month follow-up visit. The CRVO in each of these 4 patients was nonischemic. Visual acuity in 9 of 13 patients was unchanged (<3 lines of improvement). Eight of these 9 eyes had ischemic CRVO. No patient experienced a loss of visual acuity following treatment.

All eyes had a reduction in retinal thickening as demonstrated by OCT (**Table 3**). The mean baseline retinal

thickening for all eyes was 386 μm . At 1 month there was an 89% reduction with a mean retinal thickening of 38 μm ($P < .001$), at 3 months there was a 95% reduction with a mean retinal thickening of 18 μm ($P < .001$), and at 6 months the retinal thickening remained reduced at 72% of baseline with a mean retinal thickening of 108 μm ($P < .001$).

Both nonischemic and ischemic eyes with CRVO demonstrated a statistically significant reduction in retinal thickening. Mean baseline retinal thickening of the ischemic eyes measured 385 μm and was reduced to 69, 14, and 121 μm at 1, 3, and 6 months, respectively. Mean baseline retinal thickening of the nonischemic eyes was 386 μm and measured -4, 26, and 86 μm at 1, 3, and 6 months, respectively. A comparison of the reduction in thickening between the ischemic and nonischemic eyes was nonsignificant at each time point.

Figure 1 is an illustrative case of a patient with nonischemic CRVO who showed a good anatomical and functional response to treatment (patient 10). This patient demonstrated a decrease in retinal thickness from greater than 600 μm to 150 μm at 1 month with a corresponding improvement in visual acuity from 20/200 to 20/60 in the affected eye. During the next several months, this patient's macular edema recurred, necessitating retreatment (Table 1).

Table 2. Summary of Visual Acuity Changes

Time Point	Visual Acuity		P Value
	logMAR, Mean ± SD	Snellen	
All eyes (N = 13)			
Baseline	1.41 ± 0.29	20/500	NA
Mo 1	0.92 ± 0.53	20/160	.007
Mo 3	0.88 ± 0.53	20/150	.008
Mo 6	0.96 ± 0.96	20/180	.002
Ischemic (n = 8)			
Baseline	1.47 ± 0.27	20/600	NA
Mo 1	1.21 ± 0.42	20/325	.21
Mo 3	1.17 ± 0.49	20/300	.21
Mo 6	1.29 ± 0.30	20/400	.01
Nonischemic (n = 5)			
Baseline	1.32 ± 0.33	20/400	NA
Mo 1	0.46 ± 0.44	20/60	.004
Mo 3	0.42 ± 0.40	20/50	.008
Mo 6	0.42 ± 0.27	20/50	.003

Abbreviation: NA, not applicable.

Table 3. Summary of Changes in Retinal Thickening*

Time Point	Retinal Thickening, Mean ± SD, μm	Mean Change, μm	Change, %
All eyes (N = 13)			
Baseline	386 ± 64	NA	NA
Mo 1	38 ± 89	-343	-89
Mo 3	18 ± 58	-367	-95
Mo 6	108 ± 154	-278	-72
Ischemic (n = 8)			
Baseline	385 ± 73	NA	NA
Mo 1	69 ± 102	-310	-81
Mo 3	14 ± 52	-371	-96
Mo 6	121 ± 136	-264	-72
Nonischemic (n = 5)			
Baseline	386 ± 55	NA	NA
Mo 1	-4 ± 47	-390	-101
Mo 3	26 ± 72	-360	-93
Mo 6	86 ± 195	-300	-78

Abbreviation: NA, not applicable.

* $P < .001$ for all groups and at all time points except nonischemic eyes at month 6, for which $P = .02$.

Figure 2 is an illustrative case of a patient with long-standing (>12 months) ischemic CRVO who did not show a good functional response to treatment although anatomically there was a reduction in retinal thickening (patient 12). This patient demonstrated a decrease in retinal thickness from 600 to 230 μm during a 6-month period. However, visual acuity throughout that period remained stable between 2/200 and 20/400 in the affected eye (Table 1). Hence, intravitreal triamcinolone injection resulted in anatomical improvement in this patient without corresponding functional improvement.

The mean increase in intraocular pressure was 2.3 mm Hg at 1 month ($P = .04$), 4.1 mm Hg at 3 months ($P = .04$), and 2.5 mm Hg at 6 months ($P = .03$). There was no statistically significant difference in intraocular pressure elevation between ischemic and nonischemic eyes. Only patient 10 required aqueous suppressants for an increase in intraocular pressure judged to be clinically significant. This

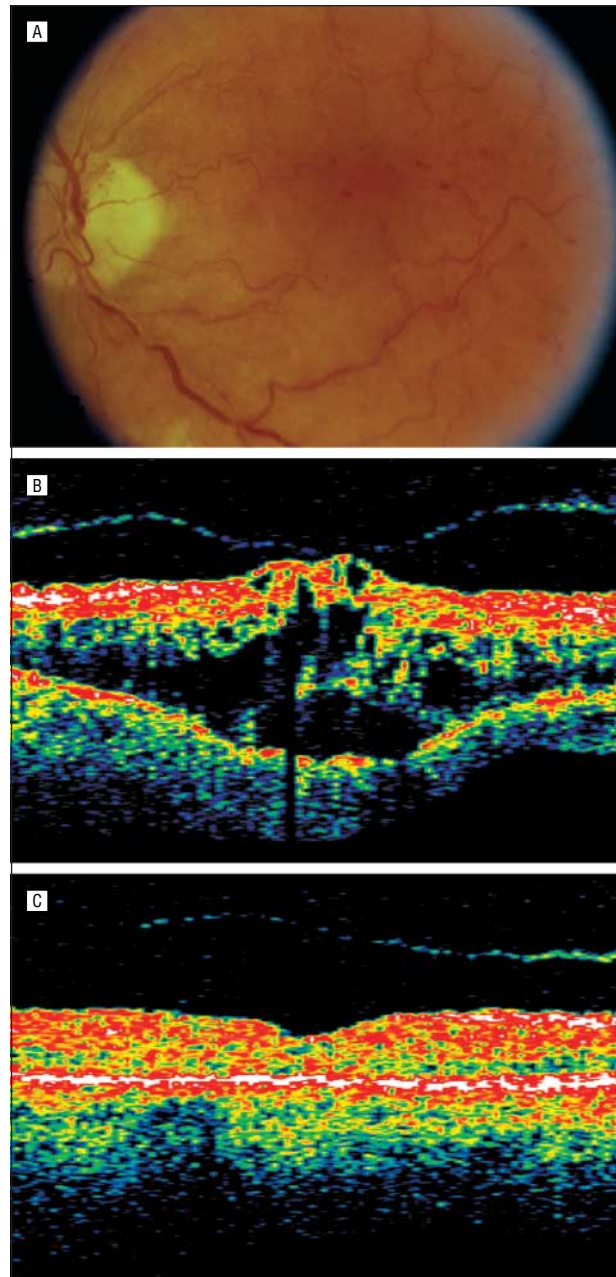


Figure 1. Patient 10. Nonischemic central retinal vein occlusion treated with intravitreal triamcinolone. A, Fundus photograph obtained prior to the initiation of therapy. B, Optical coherence tomogram obtained before therapy. C, Optical coherence tomogram obtained 1 month after triamcinolone injection. The visual acuity improved along with the resolution of macular edema.

elevation peaked at 20 mm Hg higher than baseline at the 3-month visit, and treatment with 2 aqueous suppressants was then initiated. The intraocular pressure normalized after 1 month of treatment, and aqueous suppressant therapy was subsequently discontinued. No patient developed infectious or noninfectious endophthalmitis or retinal detachment or required cataract extraction for progression to visually significant cataract during the follow-up period. One patient (patient 10) developed iris neovascularization at the 4-month follow-up visit. This was successfully treated with panretinal photocoagulation.

Between the 3-month and 6-month follow-up examinations, 4 patients developed a recurrence of macu-

lar edema. Three of the 4 patients underwent intravitreal reinjection with 4 mg of triamcinolone acetonide. Two of these 3 patients experienced improvement in visual acuity following retreatment.

COMMENT

At present, there is no proven effective treatment for patients with macular edema from CRVO. The safety and efficacy of grid laser photocoagulation for macular edema associated with CRVO was evaluated as part of the Central Vein Occlusion Study.⁴ That study demonstrated that although there was a definite decrease in macular edema on fluorescein angiography in the grid laser photocoagulation treatment group compared with the control group, this did not translate to a visual acuity improvement. Therefore, currently no therapy has proved effective for decreased vision due to macular edema associated with CRVO.

Other avenues for treating this common cause of vision loss have been investigated, including laser-induced chorioretinal venous anastomosis. In a pilot series, successful chorioretinal venous anastomosis with reduction of macular edema and improvement in visual acuity was noted in some patients.¹⁹ Potential complications include intravitreal neovascularization and subsequent vitreous hemorrhage as well as choroidal neovascularization at the anastomosis site. More recently, surgical decompression of the scleral ring around the optic nerve (radial optic neurotomy) has been investigated in patients with CRVO.²⁰ However, this is a significant surgical intervention with inherent risks, recovery time, and expense. Several other surgical and pharmacologic treatment modalities have also been studied.²¹⁻²⁴

The triamcinolone used in this study is a commercially available corticosteroid (Bristol-Myers-Squibb, Princeton, NJ). Intravitreal injection of pure triamcinolone was shown to be nontoxic in animal studies,²⁵⁻²⁷ as was the vehicle used in the commercial preparation.²⁸ Intravitreal triamcinolone acetonide at a dose of 4 mg or higher has been used clinically for a variety of conditions including choroidal neovascularization from age-related macular degeneration, diabetic macular edema, and proliferative vitreoretinopathy.²⁹⁻³⁴ As a result of the safety profile demonstrated in animal models, the prior use of intravitreal triamcinolone in the clinical setting, and the potential for corticosteroids to attenuate VEGF-mediated vascular leakage, we investigated the use of intravitreal triamcinolone in patients with macular edema associated with CRVO.

Treatment of macular edema from CRVO with intravitreal triamcinolone has been reported previously. Greenberg et al¹³ studied both eyes of a patient with bilateral macular edema from CRVO. Similarly, Jonas et al¹⁵ evaluated a patient with bilateral macular edema from CRVO. We previously reported shorter-term results in a subset of the 13 patients in our current study.¹⁶ These studies show that although many patients have a rapid anatomical response to treatment, some of these patients do not experience improvement in visual acuity. The results from our present study suggest that patients with nonischemic CRVO have a high likelihood of both an anatomical and functional response to intravitreal triamcinolone injection. Patients with ischemic CRVO also have a high likelihood of anatomical

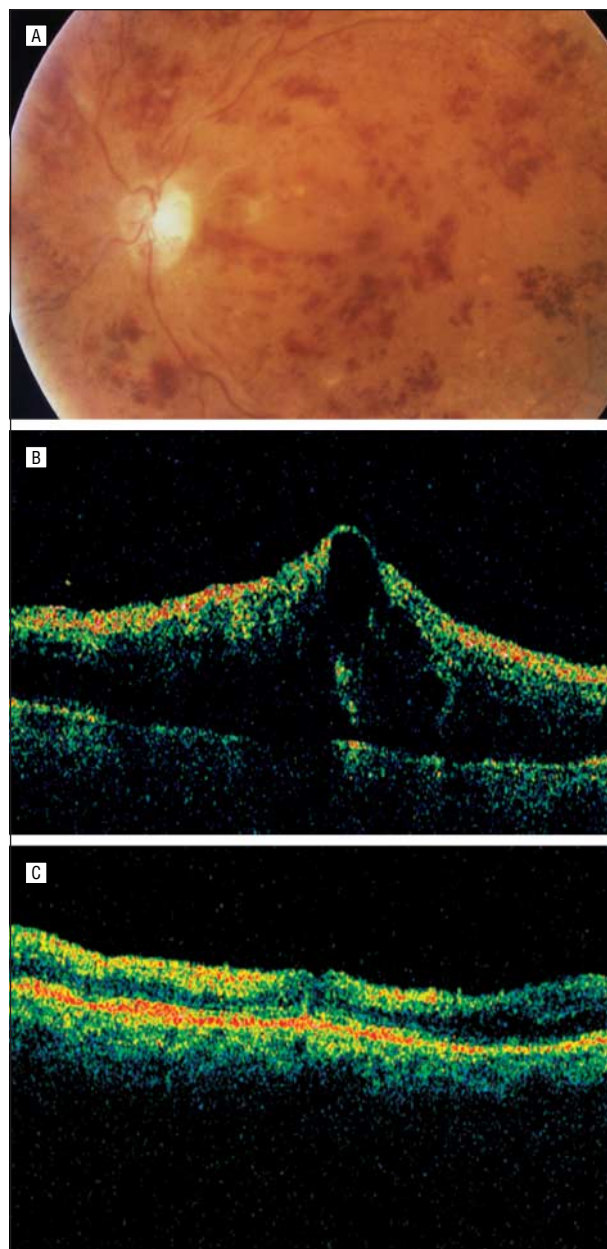


Figure 2. Patient 12. Ischemic central retinal vein occlusion treated with intravitreal triamcinolone. A, Fundus photograph obtained prior to the initiation of therapy. B, Optical coherence tomogram obtained before therapy. C, Optical coherence tomogram obtained 6 months after triamcinolone injection. Although retinal edema resolved following treatment, visual acuity remained unchanged.

response. However, these patients do not appear to respond as well functionally. In this study, all 5 patients with nonischemic CRVO responded anatomically, and 4 of these 5 patients had significant visual acuity improvement ($P = .003$). Even though all patients with ischemic CRVO ($n = 8$) responded anatomically, the magnitude of visual acuity change was not as great as for those with nonischemic CRVO. None of the 8 patients with ischemic CRVO lost visual acuity.

Retreatment due to recurrence of macular edema with a concomitant reduction in visual acuity occurred in 3 of 4 patients between the 3- and 6-month follow-up examinations. One of these 3 patients (patient 7) had both

a reduction in foveal thickness and improvement in visual acuity following retreatment. The second patient (patient 13) did not demonstrate an anatomical or functional response following retreatment. Interestingly, the third patient (patient 10) had an improvement in visual acuity following retreatment but did not experience a reduction in foveal thickness as measured with OCT.

The results of this series indicate that intravitreal injection of triamcinolone may be an effective treatment for some patients with macular edema from CRVO. Four (31%) of 13 patients gained 3 or more lines of visual acuity at the 6-month follow-up visit. This compares favorably with data from the Central Vein Occlusion Study,⁴ in which 6% of patients in both the treated and untreated groups gained 3 or more lines of visual acuity at the 12-month follow-up visit and 5% of patients in the treated group and 1% of patients in the untreated group gained 3 or more lines of visual acuity at the 4-month follow-up visit.

Most patients with CRVO, both ischemic and nonischemic, may have a favorable anatomical response to this treatment. However, a favorable visual acuity response appears more likely in patients with nonischemic CRVO. This study also suggests that retreatment may be necessary in some patients owing to the recurrence of macular edema. Four of 13 patients in this series experienced a recurrence of macular edema between the 3- and 6-month follow-up examinations; with a longer follow-up period, even more patients might have experienced recurrence. Retreatments may be effective in reducing retinal thickening and/or improving visual acuity in some patients.

In this study, the mean intraocular pressure was higher than the mean at baseline at all follow-up time points. One patient had an increase in intraocular pressure that required transient treatment with topical aqueous suppressants. No other adverse events were noted. However, the potential adverse effects of corticosteroids include glaucoma and cataract and may increase in frequency with longer follow-up and repeated injections. Administration of corticosteroids via intravitreal injection would add other potential risks such as retinal detachment, vitreous hemorrhage, and infectious endophthalmitis. Therefore, further investigation is warranted to balance the risks of this treatment modality against the potential benefits. Additional investigation may also answer issues not addressed in this article, such as the duration of treatment effect and the need for repeated injection.

Submitted for publication June 23, 2003; final revision received January 20, 2004; accepted January 20, 2004.

Correspondence: Michael S. Ip, MD, Department of Ophthalmology, University of Wisconsin, Park West One, 406 Science Dr, Suite 400, Madison, WI 53711-1068 (msip@wisc.edu).

REFERENCES

- Klein ML, Finkelstein D. Macular grid photocoagulation for macular edema in central retinal vein occlusion. *Arch Ophthalmol*. 1989;107:1297-1302.
- Central Vein Occlusion Study Group. Baseline and early natural history report: the Central Vein Occlusion Study. *Arch Ophthalmol*. 1993;111:1087-1095.
- The Central Vein Occlusion Study Group. Natural history and clinical management of central retinal vein occlusion. *Arch Ophthalmol*. 1997;115:486-491.
- The Central Vein Occlusion Study Group. Evaluation of grid pattern photocoagulation for macular edema in central vein occlusion: the Central Vein Occlusion Study Group M Report. *Ophthalmology*. 1995;102:1425-1433.
- Green WR, Chan CC, Hutchins GM, Terry JM. Central Retinal Vein Occlusion: a prospective histopathologic study of 29 eyes in 28 cases. *Trans Am Ophthalmol Soc*. 1981;79:371-422.
- Hockley DJ, Tripathi RC, Ashton N. Experimental branch vein occlusion in rhesus monkeys, III. *Br J Ophthalmol*. 1979;63:393-411.
- Aiello LP, Bursell SE, Clermont A, et al. Vascular endothelial growth factor-induced retinal permeability is mediated by protein kinase C in vivo and suppressed by an orally effective beta-isoform-selective inhibitor. *Diabetes*. 1997;46:1473-1480.
- Antonetti DA, Barber AJ, Hollinger LA, Wolpert EB, Gardner TW. Vascular endothelial growth factor induces rapid phosphorylation of tight junction proteins occludin and zonula occludens 1. *J Biol Chem*. 1999;274:23463-23467.
- Vinore SA, Youssri AI, Luna JD, et al. Upregulation of vascular endothelial growth factor in ischemic and non-ischemic human and experimental retinal disease. *Histol Histopathol*. 1997;12:99-109.
- Pe'er J, Folberg R, Itin A, Gnessin H, Hemo I, Keshet E. Vascular endothelial growth factor upregulation in human central retinal vein occlusion. *Ophthalmology*. 1998;105:412-416.
- Nauck M, Karakiulakis G, Perruchoud AP, Papakonstantinou E, Roth M. Corticosteroids inhibit the expression of the vascular endothelial growth factor gene in human vascular smooth muscle cells. *Eur J Pharmacol*. 1998;341:309-315.
- Nauck M, Roth M, Tamm M, et al. Induction of vascular endothelial growth factor by platelet-activating factor and platelet-derived growth factor is downregulated by corticosteroids. *Am J Respir Cell Mol Biol*. 1997;16:398-406.
- Greenberg PB, Martidis A, Rogers AH, Duker JS, Reichel E. Intravitreal triamcinolone acetonide for macular oedema due to central vein occlusion. *Br J Ophthalmol*. 2002;86:247-248.
- Ip MS, Kumar KS. Intravitreal triamcinolone acetonide as treatment for macular edema from central retinal vein occlusion. *Arch Ophthalmol*. 2002;120:1217-1219.
- Jonas JB, Kreissig I, Degenring RF. Intravitreal triamcinolone acetonide as treatment of macular edema in central retinal vein occlusion. *Graefes Arch Clin Exp Ophthalmol*. 2002;240:782-783.
- Ip MS, Kahana A, Altaweel MA. Treatment of central retinal vein occlusion with triamcinolone acetonide. *Semin Ophthalmol*. 2003;18:67-73.
- Hee MR, Puliafito CA, Duker JS, et al. Topography of diabetic macular edema with optical coherence tomography. *Ophthalmology*. 1998;105:360-370.
- Muscat S, Parks S, Kemp E, Keating D. Repeatability and reproducibility of macular thickness measurements with the Humphrey OCT system. *Invest Ophthalmol Vis Sci*. 2002;43:490-495.
- McAllister IL, Constable IJ. Laser-induced chorioretinal venous anastomosis for treatment of nonischemic central retinal vein occlusion. *Arch Ophthalmol*. 1995;113:456-462.
- Opremcak EM, Bruce RA, Lomeo MD, Ridenour CD, Letson AD, Rehmar AJ. Radial optic neurotomy for central retinal vein occlusion. *Retina*. 2001;21:408-415.
- Glacet-Bernard A, Coscas G, Chabanel A, Zourhani A, Lelong F, Samama MM. A randomized, double-masked study on the treatment of retinal vein occlusion with troxerutin. *Am J Ophthalmol*. 1994;118:421-429.
- Wolf S, Arendt O, Bertram B, et al. Hemodilution therapy in central retinal vein occlusion. *Graefes Arch Clin Exp Ophthalmol*. 1994;232:33-39.
- Weiss JN. Treatment of central retinal vein occlusion by injection of tissue plasminogen activator into a retinal vein. *Am J Ophthalmol*. 1998;126:142-144.
- Lit ES, Tsilimbaris M, Gotzardis E, D'Amico DJ. Lamina puncture: pars plana optic disc surgery for central retinal vein occlusion. *Arch Ophthalmol*. 2002;120:495-499.
- McCuen BW, Bessler M, Tano Y, Chandler D, Machermer R. The lack of toxicity of intravitreally administered triamcinolone acetonide. *Am J Ophthalmol*. 1981;91:785-788.
- Schindler RH, Chandler D, Thresher R, Machermer R. The clearance of intravitreal triamcinolone acetonide. *Am J Ophthalmol*. 1982;93:415-417.
- Scholes GN, O'Brien WJ, Abrams GW, Kubicek MF. Clearance of triamcinolone from vitreous. *Arch Ophthalmol*. 1985;103:1567-1569.
- Hida T, Chandler D, Arena JE, Machermer R. Experimental and clinical observations of the intraocular toxicity of commercial corticosteroid preparations. *Am J Ophthalmol*. 1986;101:190-195.
- Penfold PL, Gyory JF, Hunyor AB, Billson FA. Exudative macular degeneration and intravitreal triamcinolone: a pilot study. *Aust N Z J Ophthalmol*. 1995;23:293-298.
- Challa JK, Gillies MC, Penfold PL, Gyory JF, Hunyor ABL, Billson FA. Exudative macular degeneration and intravitreal triamcinolone: 18 month follow up. *Aust N Z J Ophthalmol*. 1998;26:277-281.
- Danis RP, Ciulla TA, Pratt LM, Anliker W. Intravitreal triamcinolone acetonide in exudative age-related macular degeneration. *Retina*. 2000;20:244-250.
- Jonas JB, Hayler JK, Panda-Jonas S. Intravitreal injection of crystalline cortisone as adjunctive treatment of proliferative vitreoretinopathy. *Br J Ophthalmol*. 2000;84:1064-1067.
- Jonas JB, Sofker A. Intraocular injection of crystalline cortisone as adjunctive treatment of diabetic macular edema. *Am J Ophthalmol*. 2001;132:425-427.
- Martidis A, Duker JS, Greenberg PB, et al. Intravitreal triamcinolone for refractory diabetic macular edema. *Ophthalmology*. 2002;109:920-927.