
Editorial

Intubation through supraglottic airways: Are we on target, or just passing through?

*"In any given moment, we have two options:
to step forward into growth, or to step back into safety."*

Abraham Maslow

Psychologist Abraham Maslow may have fared well as an anaesthesiologist, recognising the hierarchy of human needs as commencing with maintenance of essential physiological homeostasis, followed by promoting safety of the individual, and later providing for psychological needs. Although addressing the concept of self-actualisation, his dichotomous choice between growth and safety applies equally to our pursuit of excellence in anaesthesia: Do we safely stick with what we know, or grow the discipline by developing new knowledge, techniques and devices?

Airway management is indubitably embedded into anaesthetic practice, and has seen relentless growth. The dramatic proliferation of new devices such as supraglottic airways (SGAs) and video laryngoscopes (VLs) has largely outstripped the pace of the literature: many have no robust (if any) studies comparing efficacy and safety to existing standards.¹ The myriad confounding factors and difficulties of controlling for individual practitioner skill/experience make 'big data' studies of airway devices very challenging. Nonetheless, some developments have brought about dramatic changes in airway management and become enshrined into protocols and guidelines.^{2,3}

The ideal airway device would be reliably fast and easy to insert, cause no adverse haemodynamic effects, allow ventilation at adequate pressures to support patients with lung pathology, guarantee protection against aspiration of gastric contents, provide simple access to the airway for interventional procedures, and have no risk of harm or complication. Clearly, this device has not yet emerged. In the interim, we continuously strive to improve our 'safe standard' techniques of intubation and SGA use. Although considered the gold standard, intubation is fraught with difficulty and complications. Rapid first-pass success remains unreliable (particularly in the most critically ill patients, outside of the operating theatre) despite the increasing adoption of VL,⁴ and protection against aspiration is not guaranteed.⁵ SGAs are simple to use and of great value as rescue devices in the case of failure to intubate or oxygenate,⁶⁻⁸ but concern remains regarding the attainable ventilatory pressures and aspiration protection. With later-generation SGAs providing steady improvements in both factors, a time may come in which we reach equipoise between intubation and SGA.

In this edition, Saini et al. describe using the Intubating Laryngeal Mask Airway® (ILMA) as a primary strategy for intubation in patients with limited/fixed cervical spine movement, simulated by a cervical collar. (Vol 23(2): 24-28). Although this is a small study and the concept of using an SGA as a primary strategy is not novel, it is worthy of discussion. Several earlier studies have examined the ILMA with spinal immobilisation, with conflicting results. In a small study (n=10), Wakeling et al. succeeded in intubating only 40% in semi-rigid collars and failed to ventilate 40% of patients.⁹ They recommended that the ILMA should not be used when the patient is in a semi-rigid collar. However, Ferson et al. repeated the study in 70 patients, with intubation success of 92.6% on the first and

7.8% on the second attempt.¹⁰ Goutcher et al. examined interincisor distances in patients with and without rigid/semi-rigid collars, and found the distances to be 41 mm and 29 mm respectively.¹¹ As the maximum external diameter of the ILMA is 20 mm, they also recommended that an ILMA not be used with a neck collar. This is in keeping with Saini et al., who identified further difficulty in this setting due to limited mouth opening imposed by the collars. Currently accepted practice worldwide would be to remove cervical collars for intubation, while providing manual in-line stabilisation (MILS).

Intubation of patients with an unstable cervical spine is exemplified by the metaphor 'between a rock and a hard place'. These patients frequently present as emergencies with multiple injuries, poor physiological reserves and a considerable risk of aspiration. During intubation, the neck must be maintained in a neutral position with minimal movement.¹² Traditionally, the suggested approach is awake flexible endoscopic intubation, but this discounts the very real practical considerations of coughing during topicalization or intubation, the inability to position the patient ideally, risks of sedation and requirement for endoscopic skills and equipment. Recent work in the South African context suggests that skills/equipment may be lacking in nearly half of cases, even in an academic centre.¹³

Supraglottic devices are now used in some settings for the majority of elective general anaesthesia,¹⁴ as immediate adjuncts during resuscitation,^{15, 16} and modern guidelines encourage their early use if intubation fails.^{2, 17} The Difficult Airway Society's latest (2015) guidelines explicitly suggest which actions could be taken after placement of an SGA in a problematic airway in their algorithm's 'Stop and Think' box: waking the patient, intubation through the supraglottic, proceeding without intubation, or surgical airway. Clearly, for many procedures (including prone spinal and other orthopaedic surgeries as might be encountered in the patients of Sahin et al.), proceeding to intubation is not only logical but necessary. The ILMA is a well-established choice for this role,^{18, 19} but their study reflects significant reservations with regards to the overall utility of the approach. Further concerns exist. Keller et al. cautioned that the ILMA exerted up to 394 cmH₂O pressure against the cervical vertebrae during insertion.²⁰ Using cinefluoroscopy to enable real-time observation of cervical spine movement during intubation, Sahin et al. showed that the ILMA caused more cervical displacement than awake fiberoptic bronchoscopy, but less than traditional direct laryngoscopy.^{21, 22} Patients with spinal cord injury are known to have gastroparesis due to autonomic insufficiency, which is worsened if the cervical cord is involved. It is therefore advisable to place the endotracheal tube as rapidly as possible.²³ Geetanijali et al. describe a case with unstable C-spine who aspirated during the insertion of the ILMA and intubation, and question whether an ILMA should be contemplated in these circumstances.²⁴ Shung et al. showed that awake intubation with an ILMA is possible in patients with an unstable C-spine.²⁵ The patients were cooperative and maintained their own neck tone, with no neurological fallout.

Intubation through SGAs can be achieved through endoscopic guidance or blind techniques (Figure 1). The blind use of introducers

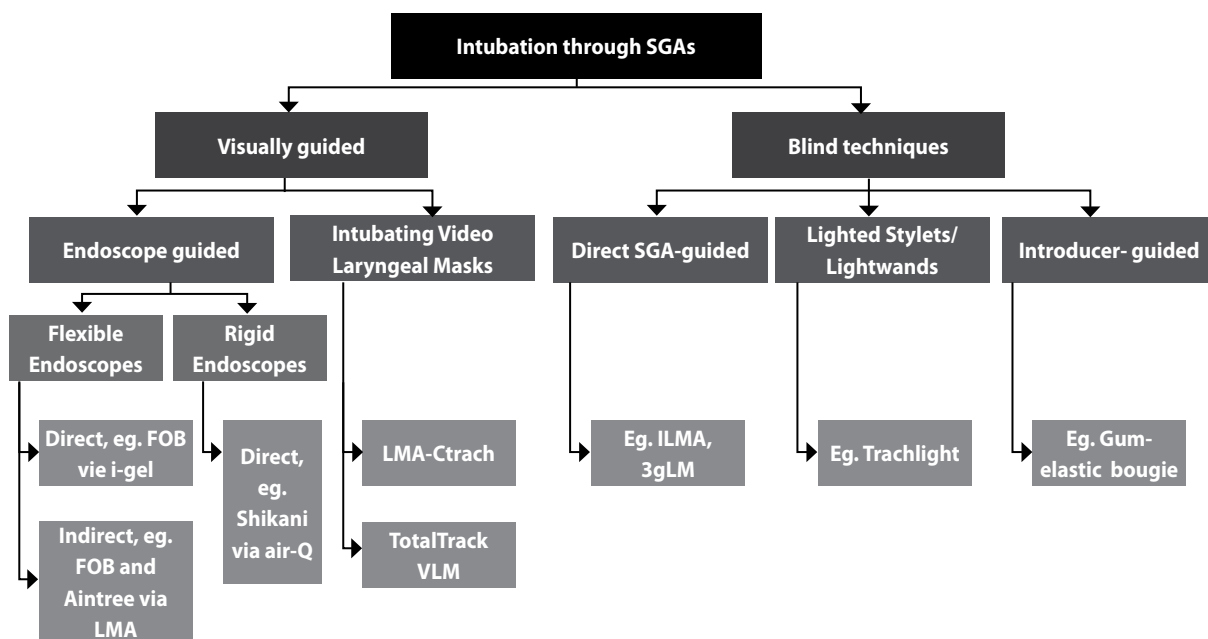


Figure 1. Strategies for intubation through supraglottic airways. Used with permission from Hofmeyr R, "Blind Intubation Through the 3gLM Supraglottic Airway: A Randomised Comparison of Two Endotracheal Tubes," (MMed dissertation), University of Cape Town, 2015. The Ctrach and 3gLM are not currently available in clinical practice.

is not considered reliable in most studies,²⁶ although lighted stylets might offer a feasible alternative.²⁷ While the majority of SGAs perform poorly for blind intubation, the ILMA was created for this purpose and has a proven track record.^{18, 28-30} As described by Saini and colleagues, ultimate success may require multiple attempts. In contrast, many studies demonstrate high success rates for flexible endoscopic intubation through SGAs. Indeed, the Aintree Intubation Catheter (AIC) was developed for this specific purpose.³¹ Earlier efforts at developing integrated fibreoptics into an intubating supraglottic were met with some success,³²⁻³⁴ but limited uptake into clinical practice. Recent improvements and reductions in cost of camera technology have seen the appearance of new video intubating laryngeal masks,^{35, 36} but the capability of these devices to replace flexible endoscopes remains to be seen, and more thorough assessment of their role is necessary.

In light of these developments, many airway experts and societies consider that blind intubation should no longer be attempted. The DAS guidelines no longer specifically mention the ILMA, instead advocating that a flexible endoscope should always be used to intubate through an SGA.² However, it is incumbent upon Southern African practitioners to consider the practicality of these recommendations within our context. Anaesthesia in Africa and other low- to middle-income countries is subject to significant fiscal constraint. Flexible bronchoscopes are rare rather than ubiquitous, and the requisite skills may also be lacking where junior staff are responsible for emergency care in remote areas. Faced with two options – advocating blind use of dedicated devices such as the ILMA, or following the guidance of our well-resourced colleagues and only performing endoscopically-guided intubations – in which direction do we step?

In anaesthesia, we are always guided by an ethos of safety, through cognisant balancing of the comparative risks. Clearly, SGAs can and must be used as rescue devices where intubation fails. They should be considered as a primary strategy in difficult airways where aspiration risk is modest, and ventilation not too challenging. Blind intubation

through devices such as the ILMA remains a valuable skill in low-resource settings, and should be practiced in training and simulation to optimise success rates. Decisions regarding selection of the technique and device for intubation of patients with unstable cervical spines should take cognisance of clinical context, operator skill and available resources. Finally, we must continue to step forward into growth, critically examining new devices and techniques within our context through well-conducted research.¹

Ross Hofmeyr,¹ Analee Milner,² Ellen P. O'Sullivan³

¹ *Consultant Anaesthesiologist & inaugural UCT-Storz African Fellow in Airway & Thoracic Anaesthesia, Department of Anaesthesia & Perioperative Medicine, University of Cape Town;*

² *Professor, Department of Anaesthesia, University of the Witwatersrand, Johannesburg;*

³ *Professor, Department of Anaesthesia, St James's Hospital, Dublin.*

References

- Pandit JJ, Popat MT, Cook TM, et al. The Difficult Airway Society 'ADEPT' guidance on selecting airway devices: the basis of a strategy for equipment evaluation. *Anaesthesia*. 2011;66:726-37.
- Frerk C, Mitchell VS, McNarry AF, et al. Difficult Airway Society 2015 guidelines for management of unanticipated difficult intubation in adults. *Br J Anaesth*. 2015.
- Cook TM, Woodall N, Frerk C. A national survey of the impact of NAP4 on airway management practice in United Kingdom hospitals: closing the safety gap in anaesthesia, intensive care and the emergency department. *Br J Anaesth*. 2016;117:182-90.
- Lewis SR, Butler AR, Parker J, Cook TM, Smith AF. Videolaryngoscopy versus direct laryngoscopy for adult patients requiring tracheal intubation. *Cochrane Database of Systematic Reviews*. 2016.
- Cook TM, Woodall N, Frerk C, Fourth National Audit P. Major complications of airway management in the UK: results of the Fourth National Audit Project of the Royal College of Anaesthetists and the Difficult Airway Society. Part 1: Anaesthesia. *Br J Anaesth*. 2011;106:617-31.
- Parment JL, Colonna-Romano P, Horrow JC, Miller F, Gonzales J, Rosenberg H. The laryngeal mask airway reliably provides rescue ventilation in cases

- of unanticipated difficult tracheal intubation along with difficult mask ventilation. *Anesth Analg*. 1998;87:661-5.
7. Timmermann A. Supraglottic airways in difficult airway management: successes, failures, use and misuse. *Anaesthesia*. 2011;66 Suppl 2:45-56.
 8. Timmermann A, Russo SG, Crozier TA, Ph D. Novices Ventilate and Intubate Quicker and Safer via Intubating Laryngeal Mask Than by Conventional Bag – Mask Ventilation and Laryngoscopy. 2007:570-6.
 9. Wakeling H, Nightingale J. The intubating laryngeal mask airway does not facilitate tracheal intubation in the presence of a neck collar in simulated trauma. *BJA*. 2000;84:254-6.
 10. Ferson D, Rosenblatt W, Johansen M, Osborn I. Use of Intubating LMA-Fastrach in 254 Patients with Difficult-to-manage Airways. *Anesthesiology*. 2001;95:1175-81.
 11. Goutcher C, Lochhead V. Reduction in mouth opening with a semi-rigid cervical collar. *BJA*. 2005;95:344-8.
 12. Farag E. Airway management for cervical spine surgery. *Best Pract Res Clin Anaesthesiol*. 2016;30:13-25.
 13. van Rooy E, Perrie H, Scribante JM, A. Thesis: Anaesthetists' practice of awake fiberoptic intubation in adult patients. Department of Anaesthesia: University of the Witwatersrand, 2017.
 14. Cook TM, Woodall N, Harper J, Benger J. Major complications of airway management in the UK: results of the Fourth National Audit Project of the Royal College of Anaesthetists and the Difficult Airway Society. Part 2: intensive care and emergency departments. *Br J Anaesth*. 2011;106:632-42.
 15. Neumar RW, Otto CW, Link MS, et al. Part 8: Adult Advanced Cardiovascular Life Support: 2010 American Heart Association Guidelines for Cardiopulmonary Resuscitation and Emergency Cardiovascular Care. *Circulation*. 2010;122:S729-S767.
 16. Deakin CD, Nolan JP, Soar J, et al. European Resuscitation Council Guidelines for Resuscitation 2010 Section 4. Adult advanced life support. *Resuscitation*. 2010;81:1305-52.
 17. Chrimes N. The Vortex: a universal 'high-acuity implementation tool' for emergency airway management. *Br J Anaesth*. 2016;117 Suppl 1:i20-i27.
 18. Ferson DZ, Rosenblatt WH, Johansen MJ, Osborn I, Ovassapian A. Use of the intubating LMA-Fastrach in 254 patients with difficult-to-manage airways. *Anesthesiology*. 2001;95:1175-81.
 19. Waltl B, Melischek M, Schuschnig C, et al. Tracheal intubation and cervical spine excursion: direct laryngoscopy vs. intubating laryngeal mask. *Anaesthesia*. 2001;56:221-6.
 20. Keller C, Brimacombe J, Keller K. Pressures exerted on the Cervical Vertebrae by the Standard and Intubating Laryngeal Mask Airways: A Randomized, Controlled, CrossOver Study in Fresh Cadavers. *Anesth Analg*. 1999;89:1296-300.
 21. Swain A, Sahu S, Swain B. Cervical spine movement during intubation. *J Neuroanaesth Crit Care*. 2017;4:S76-80.
 22. Sahin A, Salman M, Erden I, Aypar U. Upper cervical vertebral movement during intubating laryngeal mask, fibre-optic and direct laryngoscopy: A video-fluoroscopic study. *Eur J Anaesthesiol*. 2004;21:819-23.
 23. Karlson A-K. Overview: Autonomic dysfunction in spinal cord injury: clinical presentation of symptoms and signs. *Progress in Brain Research*. 2006;152:1-6.
 24. Geetanjali T, Saxena A. Anesthetic Management of Unstable Cervical Spines: Is the Intubating LMA CTrach a Right Choice? A Case Report. *AANA*. 2016;84:280-1.
 25. Shung J, Avidan M, Ing R, Klein D, Pott L. Awake intubation of difficult airway with the intubating laryngeal mask airway. *Anaesthesia*. 1998;53:645-9.
 26. Wong DT, Yang JJ, Mak HY, Jagannathan N. Use of intubation introducers through a supraglottic airway to facilitate tracheal intubation: a brief review. *Canadian Journal of Anaesthesia*. 2012;59:704-15.
 27. Agro F, Brimacombe J, Carassiti M, Morelli A, Giampalmo M, Cataldo R. Use of a lighted stylet for intubation via the laryngeal mask airway. *Can J Anaesth*. 1998;45:556-60.
 28. Ferson DZ, Brimacombe J, Brain AI, Vergheze C. The intubating laryngeal mask airway. *Int Anesthesiol Clin*. 1998;36:183-209.
 29. Brain AI, Vergheze C, Addy EV, Kapila A. The intubating laryngeal mask. I: Development of a new device for intubation of the trachea. *Br J Anaesth*. 1997;79:699-703.
 30. Brain AI, Vergheze C, Addy EV, Kapila A, Brimacombe J. The intubating laryngeal mask. II: A preliminary clinical report of a new means of intubating the trachea. *Br J Anaesth*. 1997;79:704-9.
 31. Atherton DP, O'Sullivan E, Lowe D, Charters P. A ventilation-exchange bougie for fiberoptic intubations with the laryngeal mask airway. *Anaesthesia*. 1996;51:1123-6.
 32. Liu EH, Wender R, Ph D, Goldman AJ. The LMA CTrach™ in Patients with Difficult Airways. 2009:941-3.
 33. Liu EHC, Goy RWL, Chen FG. The LMA CTrach, a new laryngeal mask airway for endotracheal intubation under vision: evaluation in 100 patients. *Br J Anaesth*. 2006;96:396-400.
 34. Dhonneur G, Ndoko SK, Yavchitz a, et al. Tracheal intubation of morbidly obese patients: LMA CTrach vs direct laryngoscopy. *Br J Anaesth*. 2006;97:742-5.
 35. Gomez-Rios MA, Freire-Vila E, Vizcaino-Martinez L, Estevez-Gonzalez E. The TotalTrack: an initial evaluation. *Br J Anaesth*. 2015;115:798-9.
 36. Choonoo JO, Hofmeyr R, Evans NR, James MF, Meyersfeld N. A new option in airway management: evaluation of the TotalTrack® video laryngeal mask. *SAJAA*. 2016;22:52-6.