

 Open access • Journal Article • DOI:10.1097/QCO.0000000000000504

Invasive pulmonary aspergillosis complicating severe influenza: epidemiology, diagnosis and treatment. — Source link

Lore Vanderbeke, Isabel Spriet, Christine Breynaert, Bart J. A. Rijnders ...+2 more authors

Institutions: Katholieke Universiteit Leuven, Erasmus University Medical Center, Radboud University Nijmegen

Published on: 01 Dec 2018 - Current Opinion in Infectious Diseases (Curr Opin Infect Dis)

Topics: Aspergillosis

Related papers:

- [Invasive aspergillosis in patients admitted to the intensive care unit with severe influenza: a retrospective cohort study.](#)
- [A Clinical Algorithm to Diagnose Invasive Pulmonary Aspergillosis in Critically Ill Patients](#)
- [Invasive pulmonary aspergillosis is a frequent complication of critically ill H1N1 patients: a retrospective study](#)
- [COVID-19 associated pulmonary aspergillosis.](#)
- [Influenza-Associated Aspergillosis in Critically Ill Patients.](#)

Share this paper:    

View more about this paper here: <https://typeset.io/papers/invasive-pulmonary-aspergillosis-complicating-severe-2noqlo8fte>

Invasive pulmonary aspergillosis complicating severe influenza: epidemiology, diagnosis and treatment

Lore Vanderbeke^{1,2}, Isabel Spriet^{3,4}, Christine Breynaert⁵, Bart J.A. Rijnders⁸, Paul E. Verweij^{9,10}, Joost Wauters^{2,11}

¹KU Leuven Department of Microbiology and Immunology, Laboratory of Clinical Bacteriology and Mycology, Leuven, Belgium

²University Hospitals Leuven, Department of General Internal Medicine, Medical Intensive Care Unit, Leuven, Belgium

³KU Leuven Department of Pharmaceutical and Pharmacological Sciences, Laboratory of Clinical Pharmacology and Pharmacotherapy, Leuven, Belgium

⁴University Hospitals Leuven, Department of Pharmacy, Leuven, Belgium

⁵KU Leuven Department of Microbiology and Immunology, Laboratory of Clinical Immunology, Leuven, Belgium

⁶University Hospitals Leuven, Department of Hematology, Leuven, Belgium

⁷University Hospitals Leuven, Department of Laboratory Medicine and National Reference Center for Mycosis, Leuven, Belgium.

⁸Department of Internal Medicine, section of Infectious Diseases, Erasmus University Medical Center, Rotterdam, The Netherlands.

⁹Department of Medical Microbiology, Radboud University Medical Centre, Nijmegen, The Netherlands

¹⁰Centre of Expertise in Mycology, Radboudumc/CWZ, Nijmegen, The Netherlands

¹¹KU Leuven Department of Microbiology and Immunology, Laboratory for Clinical Infectious and Inflammatory Disorders, Leuven, Belgium

Correspondence to

Lore Vanderbeke, MD, Department of General Internal Medicine, University Hospitals Leuven, Herestraat 49, Leuven, Belgium. Tel: +3216 345 145; e-mail: lore.vanderbeke@uzleuven.be

Purpose of review

Bacterial superinfection of critically ill influenza patients is well-known, but in recent years, more and more reports describe invasive aspergillosis as a frequent complication as well. This review summarizes the available literature on the association of invasive pulmonary aspergillosis (IPA) with severe influenza (influenza-associated aspergillosis, IAA), including epidemiology, diagnostic approaches and treatment options.

Recent findings

Though IPA typically develops in immunodeficient patients, non-classically immunocompromised patients such as critically ill influenza patients are at high-risk for IPA as well. The morbidity and mortality of IPA in these patients is high and in the majority of them, the onset occurs early after intensive care unit admission. Currently, standard of care (SOC) consists of close follow-up of these critically ill influenza patients with high diagnostic awareness for IPA. As soon as there is clinical, mycological or radiological suspicion for IAA, antifungal azole-based therapy (e.g. voriconazole) is initiated, in combination with therapeutic drug monitoring (TDM). Antifungal treatment regimens should reflect local epidemiology of azole-resistant *Aspergillus* species and should be adjusted to clinical evolution. TDM is necessary as azoles like voriconazole are characterized by nonlinear pharmacokinetics, especially in critically ill patients.

Summary

In light of the frequency, morbidity and mortality associated with influenza-associated aspergillosis in the intensive care unit (ICU), a high awareness of the diagnosis and prompt initiation of antifungal therapy is required. Further studies are needed to evaluate the incidence of IAA in a prospective multi-centric manner, to elucidate contributing host-derived factors to the pathogenesis of this superinfection, to further delineate the population at risk and to identify the preferred diagnostic and management strategy as well as the role of prophylaxis.

Key words

influenza, ICU, aspergillosis, antifungals, *Aspergillus fumigatus*

Introduction

Worldwide, 3-5 million people develop severe influenza infection every year, leading to 50,000-100,000 deaths annually in the European Union and the USA. Of the hospitalised patients 5-10% need ICU admission. These patients initially present with typical influenza symptoms, but develop rapidly evolving respiratory deterioration potentially leading to acute respiratory distress syndrome (ARDS) associated with high mortality [1,2]. Bacterial superinfection, mainly with *Streptococcus pneumoniae* and *Staphylococcus aureus*, is a well-known complication of severe influenza and its pathophysiology has been widely studied [3]. In recent years however an increasing number of publications on influenza-associated aspergillosis is reported and the largest retrospective case study on the subject was recently published [4[■]]. This review will focus on epidemiological data from published cases of IAA up to June 2018 as well as on new insights related to the diagnosis and treatment of this infection in the ICU-admitted patient. A brief note on the pathogenesis and suggested topics for further research are presented as well. References were identified using PubMed and Embase searches (January 1950 – June 2018) of both English and foreign language literature using the search terms “influenza” and “aspergillus”, “aspergillosis” or “invasive aspergillosis”. References of identified case reports and case series were reviewed to identify additional articles for inclusion.

Epidemiology

There is a remarkable increase in published cases over time: the first report of probable IAA dates back to 1952, with up to 6 case reports per decade thereafter. A sharp increase in reported cases occurred after the 2009 H1N1 influenza pandemic (Figure 1). Whether this is associated with an increasing trend of *Aspergillus* superinfection or with improved diagnostics remains unclear though the latter is much more likely. Up to June 2018 128 IAA cases have been published, which are summarized in table 1 [5-34,35[■],36-50,51[■],52[■],53-54]. Most cases had at least one underlying medical condition, yet 28% were reported as previously healthy. The most frequently observed underlying conditions were the use of one or more immunosuppressive drugs for a variety of underlying diseases (n=32, 25%),

haematological malignancy (n=19, 15%) and diabetes (n=19, 15%). Only 9% (n=11) of patients were reported to take corticosteroid (CS) therapy before influenza diagnosis, while 48% (n=61) were treated with CS during hospitalisation. Antiviral and antifungal therapy was administered in the majority of cases (69% and 89% respectively). Most IAA cases were found in patients with influenza A infection (n=111, 87%), predominantly associated with H1N1 virus. IAA diagnosis was frequently made early after ICU admission (median of 5 days after admission; IQR: 2 – 11.5). Diagnosis of IAA was largely based on culture (n=89, 70%). Galactomannan (GM) antigen was reported positive in serum in half of the patients (n=60, 47%) and in bronchoalveolar lavage (BAL) fluid in one third of the patients (n=39, 31%). Bronchoscopy revealed fungal tracheobronchitis in 19 patients (15%). These results need to be interpreted with caution, because not all diagnostic techniques were available in every medical centre and case definitions differed. Therefore, these numbers in no way reflect the sensitivity or specificity of these tests. IAA was proven through pathological examination in 40 patients (31%), of which 19 (48%) were proven only at autopsy. Most patients required mechanical ventilation (n=100, 78%) and overall mortality was 57% (n=73). Though there may be regional differences in prevalence, reports have occurred in all world continents, except South-America and Antarctica (Table 2).

Additionally, four recent large retrospective studies in ICU-patients need to be mentioned. In the first of these four reports, Martin-Loeches et al studied the occurrence of superinfection in 2901 critically ill influenza patients from a large number of ICUs in Spain between 2009 and 2015. In this dataset, 16.6% (n=482) had a superinfection and of those *Aspergillus* was found in 7.2% (n=35) in the two days after ICU admission [55]. The second report is a retrospective cohort of 134 patients on extracorporeal membrane oxygenation (ECMO) in a tertiary care centre in the UK during 2012-2016. Ten of them had evidence of an invasive *Aspergillus* infection and influenza A was an independent risk factor for IPA (HR 11.4, 95% CI 1.97 – 65.86) [56]. In the third report, Cavayas et al. studied the risk factors for fungal infection in an international database of 2,129 ECMO patients. Here again, influenza was an independent risk factor for IAA in ECMO patients (OR 2.48)[57]. Finally, in a paper on 432 patients with influenza admitted to seven ICUs in the Netherlands and Belgium over a period of 7 years, 19%

(n=83) were diagnosed with invasive aspergillosis. Of the 315 influenza patients without a typical host factor that would put them at risk for invasive aspergillosis, the incidence remained high at 14%. A comparison of influenza patients with severe non-influenza pneumonia patients allowed for the identification of influenza as an independent risk factor for IPA (aOR 5.2, 95% CI 2.6-10.3). Moreover, IAA was diagnosed very early after ICU admission (median of 3 days after admission), which highlights the need for a structured and prompt diagnostic approach [4[■]].

Diagnosis

Microbiological detection of influenza can be performed on nasopharyngeal or lower respiratory tract samples. Nucleic acid testing is both rapid and highly sensitive, making it the preferential detection method in most hospitals. Viral culture has similar sensitivity, yet is time- and labour intensive. Direct antibody testing, though clearly less sensitive, is rapid and does not require specialised skills [58]. Sampling of the lower respiratory tract (LRT) has a higher diagnostic yield and positivity in LRT is associated with worse outcome in critically ill influenza patients [59].

Diagnosing IPA is less straightforward. Histological identification of acute-angle branching septated hyphae invading lung tissue is needed to prove a diagnosis of IPA. Lung biopsy is however rarely performed in critically ill patients because of the risk of respiratory complications and bleeding.

A recent national survey in the Netherlands showed a hospital mortality of 61% in 23 ICU patients with IAA. Patients that survived had received antifungal therapy at a median of two days after influenza diagnosis, compared with nine days in patients that had died, indicating that early diagnosis and treatment are critical [51[■]]. Awareness of invasive aspergillosis as a potential cause of secondary infection is important as IAA occurs in non-typical host groups and characteristic CT images such as 'halo-sign' might be absent. Therefore any respiratory specimen harbouring *Aspergillus* species in culture or a positive GM should not be disregarded in ICU-patients with severe influenza. A bronchoscopy with BAL appears the preferred diagnostic approach as the performance of GM detection and culture showed good sensitivity in IAA, i.e. 94% and 78% respectively [51[■]]. As up to 15%

of patients may develop *Aspergillus* tracheobronchitis, the presence of plaques in the trachea or bronchi should be noted during bronchoscopy, which is recommended by the IDSA [60]. As radiological manifestations of tracheobronchitis are subtle or may be absent, visualization of plaques is regarded the best way to diagnose this condition [61].

In addition to GM detection in BAL, serum GM was also positive in 64 to 71% of IAA-patients, which is a high sensitivity considering that most patients were non-neutropenic [4[■],51[■]]. A positive serum GM increases the probability of IAA and helps to distinguish invasive infection from respiratory colonization. Any positive serum GM in a patient with severe influenza therefore should prompt immediate antifungal treatment, even if pre-existing risk factors are absent. The logistics of GM detection however might cause diagnostic delay as in many centres GM-testing is performed only once or twice a week. Recently lateral flow device (LFD) tests became available for detection of *Aspergillus* antigens in serum and BAL. The main advantage of the LFD assay is that results are available within 30 minutes, although the concentration of the antigen is not quantified [62].

In geographical regions in which azole resistance has been described, the detection of resistance should be pursued in clinically relevant isolates [63]. As mixed infections (e.g. azole-susceptible and azole-resistant co-infection) have been reported in patients with IAA, multiple colonies should be investigated in culture-positive patients. Screening through agar-based systems such as the VIPcheck™ test enables detection of resistance within 24 to 48hrs. If the screening test indicates resistance, MIC-testing can be performed [64]. Culture and phenotypic resistance screening and MIC-testing can take up to a week or longer and therefore may be too late to guide antifungal therapy. Indeed a recent study in culture-positive patients with invasive aspergillosis indicated that initial voriconazole therapy corresponded with a 27% higher mortality in patients with voriconazole-resistant *A. fumigatus* compared with patients with voriconazole-susceptible infection. Despite resistance screening and MIC-testing the median time to change to appropriate antifungal therapy was 10 days, indicating that resistance information should be available earlier to prevent mortality [65]. In culture negative patients resistance-PCR can be performed directly on clinical specimens. Two commercial PCR-tests

are available (MycoGenie and AsperGenius), which detect one or two common resistance markers. Generally, the assays show acceptable sensitivity when done on BAL fluid and results are available within a working day [66,67]. In culture positive patients, these PCR-tests can also be performed directly on a suspension of multiple colonies with excellent sensitivity and with additional advantage that, compared with phenotypic resistance testings, the PCR result will be available the same day. The limitation is that resistance mechanisms other than the mutations included in the PCR will go unnoticed.

Given the rapid disease progression in IAA a diagnostic pathway could include early BAL, followed by LFD and, if positive, *Aspergillus* and resistance PCR. Although such a strategy still needs to be validated, IAA diagnosis could be made within 48 hours including information regarding the presence of resistance markers.

Treatment

In this section, an overview of current knowledge on the pharmacological treatment, comprising antivirals, antifungals and corticosteroid therapy is given. Respiratory organ support techniques, such as prone positioning and ECMO contribute to improved survival, but fall outside the scope of this review [68].

Antiviral therapy

Neuraminidase inhibitors (NAIs) (oseltamivir, zanamivir and very recently peramivir) form the only drug class that are licensed and recommended for the treatment of influenza infection in Europe [69,70]. Current evidence supports the use of oseltamivir in severe influenza, if administered early. Timely administration has indeed shown reduced ICU length of stay, reduced mechanical ventilation days and improved survival in several cohorts of ICU patients [71-73]. During the pandemic 2009 H1N1 infection, the World Health Organization listed oseltamivir as a 'core drug' and advised to treat with oseltamivir at a higher dose (150 mg twice daily instead of 75 mg twice daily) and for longer duration (standard treatment duration being 5 days) in severely ill patients (1). These recommendations are

based on animal models, with only limited evidence for benefit in human cohorts [74]. No prospective studies on optimal duration of treatment in critically ill influenza patients exist, yet extended treatment duration with oseltamivir was associated with a trend towards improved mortality in a retrospective analysis of 19,892 adult ICU patients [75]. Regarding the optimal dosing of oseltamivir in severe influenza patients, the evidence is inconclusive as well. The only three prospective studies comparing standard and high-dose oseltamivir in hospitalised patients show conflicting evidence on improved virological clearance without obvious clinical benefit of high-dose therapy [76-78]. Additional retrospective studies corroborate the absence of effect on clinical outcome such as ICU length-of-stay or mortality [79,80]. In light of this conflicting data, the World Health Organisation downgraded oseltamivir on its drug list [81]. Furthermore, pharmacokinetic analysis in critically ill pandemic H1N1 influenza virus patients showed that enteric absorption of oseltamivir at standard dose was adequate, resulting in trough levels and area under the curve of the active carboxylate metabolite well above the 50% maximal inhibitory concentration of the influenza virus [82].

Dosing of oseltamivir in critically ill patients should be adapted to the provided organ-support. Despite the fact that ECMO can alter pharmacokinetics, by increasing the volume of distribution and sequestration of drugs in the circuit among others, no dose adjustment for oseltamivir seems warranted based on current reports [83-85]. Dose reduction to 75 mg once daily is however recommended in patients on renal replacement therapy (RRT), depending on type of RRT and patient characteristics [83,84,86-88]. Recommendations are based on limited available evidence in small patient populations, thus better evidence is clearly required. Current research is focusing on new NAIs (such as peramivir), new antiviral drug classes (e.g. endonuclease inhibitors) and the role of combination therapy [89,90].

Antifungal therapy

Voriconazole, the current gold standard therapy for IPA according to ECIL/ESCMID-ECMM-ERS/IDSA guidelines, led to a higher overall survival compared to conventional amphotericin B [60,63,91]. The intravenous formulation is used in ICU setting, to avoid erratic absorption and to warrant therapeutic

plasma levels. Although voriconazole has earned its merit, its use is hindered by non-linear pharmacokinetics, risk for neuro- and hepatotoxicity and frequent involvement in drug-drug interactions. These factors underscore the need for therapeutic drug monitoring (TDM), aiming at trough levels of 2-5.5 mg/L [60,63]. Especially during ECMO, TDM is warranted since voriconazole sequestration and subsequent saturation of binding sites of the ECMO circuit can significantly alter drug levels [92,93]. Moreover, multiple drugs are known to interact with voriconazole based at the level of cytochrome P450 metabolizing enzymes [94,95]. Next to these classic CYP450 mediated interactions, also other interactions have been described in literature. A new and clinically relevant interaction was described between flucloxacillin and voriconazole showing subtherapeutic levels of voriconazole in 11 of 20 patients treated simultaneously with both drugs [96[■]].

Isavuconazole is a new extended-spectrum triazole that can be administered as a prodrug via oral or intravenous formulation. Its longer half-life compared to voriconazole allows for once daily dosing after an initial two-day period of three times daily loading. Compared to voriconazole, isavuconazole has a more favourable profile, regarding safety and spectrum (including some of the Mucorales) while being non-inferior for primary treatment of suspected invasive mould disease [97-99]. This is reflected in current treatment guidelines; isavuconazole has the same level of evidence as voriconazole [60,63]. More clinical data are needed to provide insight in the efficacy and safety of isavuconazole at the ICU, the need for therapeutic drug monitoring and optimal dosing in patients on ECMO [100,101].

For many years, the polyene conventional amphotericin B was the mainstay therapy for invasive mould infection and its liposomal formulations have been associated with a better safety profile. However, its use is currently limited to patients in which voriconazole is contra-indicated, e.g. in case of hepatic insufficiency or in cases of suspected or proven azole-resistance. Importantly, with the widespread use of azoles in the environment, resistance has been observed worldwide, with resistance rates of up to 26% in certain Dutch ICUs [102[■],103]. Recent guidelines recommend to start voriconazole-echinocandin combination or liposomal amphotericin B as initial therapy in regions with environmental resistance rates of >10% [63]. If susceptibility testing demonstrates azole-susceptible *Aspergillus*

(voriconazole MIC \leq 1mg/L) voriconazole monotherapy is recommended, while in azole-resistant *Aspergillus* (voriconazole MIC >2 mg/L) ongoing therapy should consist of an antifungal drug to which the recovered species is susceptible [104,105]. Furthermore, combination therapy is recommended in IDSA guidelines for salvage therapy [60]. Regardless of the initial treatment regimen, timely administration of appropriate antifungal therapy is the single most crucial intervention to improve outcome, therefore initiation of treatment at suspicion of aspergillosis is advocated [60,106]. Primary prophylaxis with posaconazole is currently only recommended in high-risk patient groups (i.e. acute myelogenous leukaemia or myelodysplastic syndrome receiving induction chemotherapy) [63]. The effect of prophylactic antifungal administration in critically ill influenza patients requires further investigation.

Corticosteroids

CS treatment is frequently used in the ICU, both as adjunctive treatment in septic shock and in the late phase of ARDS, although its value in septic shock remains a matter of debate [107-109]. Moreover, guidelines on treatment of severe pneumonia are being reviewed, considering CS treatment early in the disease course to improve morbidity and mortality [110[■],111]. Influenza pneumonia is however deemed an exception, based on low quality evidence showing an association between CS and prolonged viral shedding with increased risk of mortality [1,112-114]. The available evidence on the value of CS in patients with influenza argues against its use as long as data from a prospective randomized clinical trial are lacking. Additionally, CS were an independent risk factor for the development of IPA in ICU patients in general but very recently also in patients admitted with influenza [4[■],35[■],115-116,117[■]].

Pathogenesis

The underlying mechanisms that render influenza-patients prone to develop IAA remain to be elucidated and is mainly derived from studies regarding influenza-bacterial superinfection. Influenza induces damage to the respiratory tract epithelial lining, interferes with normal mucociliary clearing and in this way can provide a gateway for *Aspergillus* infection. Moreover, immunological host

responses are altered in the setting of severe influenza, with dysregulation of Th cell differentiation and impaired cell-mediated immunity [3,118]. Additionally, treatment strategies in the ICU may enhance susceptibility to secondary aspergillosis. CS are well-known to downregulate innate and more importantly adaptive immunity, contributing to IPA development. In vitro, neuraminidase inhibitors are able to diminish viral-bacterial synergism that may contribute to severe influenza lethality [119]. The opposite might be true for the influenza-aspergillosis association as initial *in vivo* experiments in immunodeficient mice show more severe IPA development in cortisone-treated animals exposed to oseltamivir compared to controls, a difference that was not observed in neutropenic mice [120[■]]. Further research is needed to clarify the multiple contributing factors in the pathophysiology of this disease.

Conclusion and perspectives

IAA is a frequent and severe complication of influenza in ICU, occurring early after admission. High diagnostic awareness, incorporating a multiple biomarker-diagnostic strategy, and prompt initiation of antifungal treatment are crucial to improve outcome. We recommend considering *Aspergillus* infection in all ICU-patients with severe influenza, irrespective of previous medical history. Although the optimal diagnostic work-up remains to be validated, early bronchoscopy and BAL with the use of biomarkers appears to be important to diagnose IAA as early as possible. If initial assessments are negative for aspergillosis, this strategy should be repeated in case of respiratory deterioration. Further studies are needed to provide better epidemiological insights, currently a multi-centre observation trial is ongoing (NCT03391492), to investigate the potential of antifungal prophylaxis (NCT03378479) and to elucidate the pathophysiology of this superinfection.

Bullet points

- Influenza associated aspergillosis is a frequent and severe superinfection in the intensive care unit.
- IAA may occur in any patient and shows a rapid disease progression with a high mortality.
- A broader awareness of this complication and prompt antifungal treatment initiation are crucial.
- Detailed knowledge about the underlying pathophysiological mechanisms and better risk assessment scores are urgently needed.

Acknowledgements

Lore Vanderbeke received internal funding from KU Leuven while working on the present review article, and at the time of publication is a PhD fellow of the Research Foundation – Flanders (FWO).

Isabel Spriet and Christine Breynaert are supported by the Clinical Research Fund, University Hospitals Leuven.

Joost Wauters is a senior clinical investigator, Research Foundation – Flanders (FWO).

Figure 1: Overview of IAA cases and publications in literature over time (1952-2017 period) [5-

34,35,36-50,51,52,53-54].

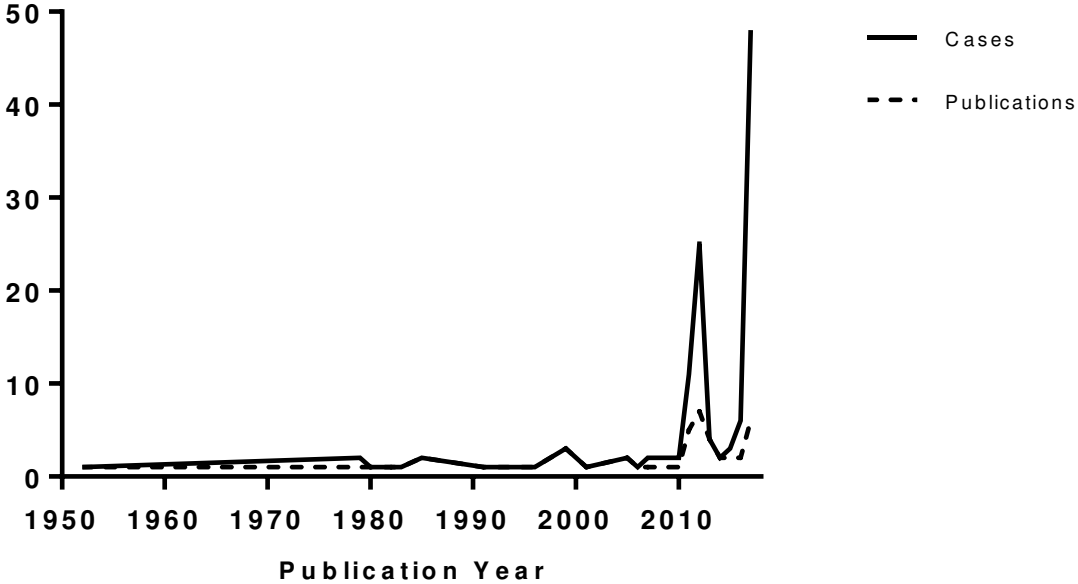


Table 1: Summary of 128 cases of influenza-associated aspergillosis: literature review of cases and case series [5-34,35[■],36-50,51[■],52[■],53-54].

BAL: bronchoalveolar lavage; COPD: chronic obstructive pulmonary disease; CT: computed tomography; ECMO: extracorporeal membrane oxygenation; EORTC: European organisation for research and treatment of cancer; IQR: interquartile range; PCR: polymerase chain reaction.

*Since multiple diagnostic techniques were employed in a majority of reported cases, the total percentage in the diagnosis category adds up to more than a 100%. All subcategories are listed relative to the total number of 128 cases, even though not every technique was employed in every case.

^aPercentages relative to total number of influenza A cases reported.

^bPercentages relative to total number of CT scans reported.

^cTime from influenza diagnosis to aspergillosis diagnosis only reported in 70 reports.

^dPercentages relative to total number of antiviral use.

^eTime from admission to death only reported in 44 reports.

CHARACTERISTIC	NUMBER (%) OR MEDIAN (IQR RANGE)
Demographics	
Age	59 (IQR: 51-63)
Male	79 (62%)
Risk factors	
Cirrhosis	6 (5%)
COPD	10 (8%)
Corticosteroids before hospitalisation	11 (9%)
Diabetes mellitus	19 (15%)
Haematological malignancy	19 (15%)
Haematological transplant	5 (4%)
Immunosuppression	32 (25%)
Neutropenia	12 (9%)
Previously healthy	36 (28%)
Solid organ malignancy	11 (9%)
Solid organ transplant	10 (8%)
Aspergillosis classification	
Proven	40 (31%)
EORTC Probable	31 (24%)
AspICU Putative	31 (24%)
Unclassifiable	47 (37%)
Influenza type	
Influenza A	111 (87%)
A, H1N1	65 (59%) ^a
A, H3	5 (4%) ^a
A, not specified	41 (37%) ^a
Influenza B	12 (9%)
Not specified	5 (4%)
Aspergillosis diagnostics*	
BAL culture positive	46 (36%)
1-3-β-D-glucan positive	5 (4%)
Computed Tomography	37 (29%)
EORTC defined lesions	13 (35%) ^b

Atypical lesions	24 (65%) ^b
Galactomannan BAL positive	39 (31%)
Galactomannan serum positive	60 (47%)
Lung biopsy	20 (17%)
Necropsy	23 (18%)
PCR positive	4 (3%)
Sputum culture positive	43 (34%)
Tracheobronchitis	19 (15%)
Time from influenza diagnosis to <i>Aspergillus</i> diagnosis (days) ^c	5 (IQR: 2-11.5)
Therapy	
Antiviral treatment	88 (69%)
Not specified	1 (1%) ^d
Oseltamivir only	82 (93%) ^d
Oseltamivir and peramivir	3 (3%) ^d
Oseltamivir and zanamivir	2 (2%) ^d
Antifungal treatment	114 (89%)
Corticosteroids during hospitalisation	61 (48%)
Outcome	
Mechanical ventilation	100 (78%)
ECMO	14 (11%)
Mortality	73 (57%)
Time to death (days) ^e	21 (IQR: 13-26.5)

Table 2: Overview of published IAA cases from case reports and case series in the period 1952 – June 2018, listed per country [5-34,35[■],36-50,51[■],52[■],53-54].

CONTINENT	COUNTRY	PUBLICATIONS (n=50)	YEAR OF PUBLICATION	IAA CASES PER COUNTRY
Africa				n=1
	South-Africa	1	1985	1
Asia				n=36
	Japan	6	1992, 1999, 2001, 2005-2007	7
	Korea	5	2012-2014	5
	Taiwan	4	2013, 2017	24
Australia				n=1
	Australia	1	1999	1
Europe				n=68
	Belgium	2	2012, 2017	10
	France	3	1999, 2011, 2012	7
	Germany	2	2012, 2013	6
	Ireland	1	2018	2
	Italy	1	2011	1
	Poland	1	2011	1
	Spain	3	1996, 2011, 2012	8
	Switzerland	2	1985, 2016	2
	The Netherlands	3	2012, 2015, 2017	26
	United Kingdom	5	1952, 1980, 1982, 1983, 1991	5
North America				n=22
	United States of America	10	1979, 2005, 2010-2012, 2015-2018	22

1. World Health Organization. WHO guidelines for pharmacological management of pandemic (H1N1) 2009 influenza and other influenza viruses. Geneva, Switzerland, 2010.
2. W.I.V. Influenza [Internet]. Wetenschappelijk Instituut Volksgezondheid; 2017 [Available from: <https://www.wiv-isp.be/nl/gezondheidsonderwerpen/influenza-0>].
3. McCullers JA. The co-pathogenesis of influenza viruses with bacteria in the lung. *Nat Rev Microbiol* 2014; 12:252-262
4. Schauwvlieghe AFAD, Rijnders BJ, Philips N, et al. Invasive aspergillosis in patients admitted to the ICU with severe influenza. Article accepted for publication in *Lancet Resp Med*. 2018; (in press).
 - Largest retrospective study showing that influenza is an independent risk factor for invasive aspergillosis.
5. Abbott JD, Fernando HV, Gurling K, Meade BW. Pulmonary aspergillosis following post-influenzal bronchopneumonia treated with antibiotics. *Br Med J* 1952; 1:523-525.
6. Fischer JJ, Walker DH. Invasive pulmonary aspergillosis associated with influenza. *JAMA* 1979; 241:1493-1494.
7. Jariwalla AG, Smith AP, Melville-Jones G. Necrotising aspergillosis complicating fulminating viral pneumonia. *Thorax* 1980; 35:215-216.
8. McLeod DT, Milne LJ, Seaton A. Successful treatment of invasive pulmonary aspergillosis complicating influenza A. *Br Med J* 1982; 285:1166-1167.
9. Horn CR, Wood NC, Hughes JA. Invasive aspergillosis following post-influenzal pneumonia. *Br J Dis Chest* 1983; 77:407-410.
10. Urban P, Chevrolet JC, Schifferli J, et al. [Invasive pulmonary aspergillosis associated with an acute influenza virus infection]. *Rev Mal Respir* 1985; 2:255-257.
11. Lewis M, Kallenbach J, Ruff P, et al. Invasive pulmonary aspergillosis complicating influenza A pneumonia in a previously healthy patient. *Chest* 1985; 87:691-693.
12. Hovenden JL, Nicklason F, Barnes RA. Invasive pulmonary aspergillosis in non-immunocompromised patients. *Br Med J* 1991; 302:583-584.
13. Kobayashi O, Sekiya M, Saitoh H. [A case of invasive broncho-pulmonary aspergillosis associated with influenza A (H3N2) infection]. *Nihon Kyobu Shikkan Gakkai Zasshi* 1992; 30:1338-1344.
14. Alba D, Gomez-Cerezo J, Cobo J, et al. [Invasive pulmonary aspergillosis associated with influenza virus]. *An Med Interna* 1996; 13:34-36.
15. Boots RJ, Paterson DL, Allworth AM, Faoagali JL. Successful treatment of post-influenza pseudomembranous necrotising bronchial aspergillosis with liposomal amphotericin, inhaled amphotericin B, gamma interferon and GM-CSF. *Thorax* 1999; 54:1047-1049.
16. Funabiki Y, Ishii K, Kusaka S, et al. [Aspergillosis following influenza A infection]. *Nihon Ronen Igakkai Zasshi* 1999; 36:274-278.
17. Vandebos F, Mondain-Miton V, Roger PM, et al. [Invasive pulmonary aspergillosis during influenza: a fortuitous association?]. *Presse Med* 1999; 28:1755.
18. Matsushima H, Takayanagi N, Ubukata M, et al. [Invasive pulmonary aspergillosis following influenza A infection]. *Nihon Kokyuki Gakkai Zasshi* 2001; 39:672-677.
19. Hasejima N, Yamato K, Takezawa S, et al. Invasive pulmonary aspergillosis associated with influenza B. *Respirol* 2005; 10:116-119.
20. Lee FE, Daigle CC, Urban MA, et al. Fever and progressive respiratory failure in three elderly family members. *Chest* 2005; 128:1863-1867.
21. Sugino K, Homma S, Takaya H, et al. [Fatal invasive pulmonary aspergillosis triggered by influenza B virus infection in an individual with idiopathic pulmonary fibrosis]. *Nihon Kokyuki Gakkai Zasshi* 2006; 44:207-214.
22. Ohnishi T, Andou K, Kusumoto S, et al. [Two cases of successfully treated invasive pulmonary aspergillosis following influenza virus infection]. *Nihon Kokyuki Gakkai Zasshi* 2007; 45:349-355.
23. Lat A, Bhadelia N, Miko B, et al. Invasive aspergillosis after pandemic (H1N1) 2009. *Emerg Infect Dis* 2010; 16:971-973.

24. Helbig G, Wozniczka K, Wieczorkiewicz A, et al. Irreversible marrow aplasia after single course of 2-chlorodeoxyadenosine for hairy cell leukaemia preceding by A pandemic 2009-H1N1-associated pneumonia. *Med Oncol* 2011; 28:1601-1603.
25. Adalja AA, Sappington PL, Harris SP, et al. Isolation of *Aspergillus* in three 2009 H1N1 influenza patients. *Influenza Other Respir Viruses* 2011; 5:225-229.
26. Carfagna P, Brandimarte F, Caccese R, et al. Occurrence of influenza A(H1N1)v infection and concomitant invasive pulmonary aspergillosis in a patient with chronic obstructive pulmonary disease. *Mycoses* 2011; 54:549-525.
27. Garcia-Vidal C, Barba P, Arnan M, et al. Invasive aspergillosis complicating pandemic influenza A (H1N1) infection in severely immunocompromised patients. *Clin Infect Dis* 2011; 53:e16-19.
28. Passouant O, Mateu P, Commandini M, et al. Pulmonary aspergillosis in non-immunocompromised patient with acute respiratory distress syndrome during A (H1N1) infection. *Ann Fr Anesth Réanim* 2011; 30:e75-e76.
29. Kim SH, Kim MN, Lee SO, et al. Fatal pandemic influenza A/H1N1 infection complicated by probable invasive pulmonary aspergillosis. *Mycoses* 2012; 55:189-192.
30. Bagdasarian N, Smith J, Chenoweth C. Invasive pulmonary aspergillosis in patients with 2009 H1N1 influenza infection. *Infect Dis Clin Pract* 2012; 20:422-424.
31. Guervilly C, Roch A, Ranque S, et al. A strategy based on galactomannan antigen detection and PCR for invasive pulmonary aspergillosis following influenza A (H1N1) pneumonia. *J Infect* 2012; 65:470-473.
32. Hoyo-Ulloa I, Cobos-Trigueros N, Puig-de la Bellacasa J, Martinez-Martinez JA. Influenza A (H1N1) complicated by invasive aspergillosis in non-severely immunocompromised patients. *Enferm Infecc Microbiol Clin* 2012; 30:583-584.
33. Vehreschild JJ, Brockelmann PJ, Bangard C, et al. Pandemic 2009 influenza A(H1N1) virus infection coinciding with invasive pulmonary aspergillosis in neutropenic patients. *Epidemiol Infect* 2012; 140:1848-1852.
34. Otterspoor LC, Smit FH, van Laar TJ, et al. Prolonged use of extracorporeal membrane oxygenation combined with prone positioning in patients with acute respiratory distress syndrome and invasive aspergillosis. *Perfusion* 2012; 27:335-337.
35. Wauters J, Baar I, Meersseman P, et al. Invasive pulmonary aspergillosis is a frequent complication of critically ill H1N1 patients: a retrospective study. *Intensive Care Med* 2012; 38:1761-1768.
 - First case series indicating that invasive aspergillosis is a frequent complication of severe influenza
36. Kim MJ, Kim MK, Kang CK, et al. A case of acute cerebral aspergillosis complicating influenza A/H1N1pdm 2009. *Infect Chemother* 2013; 45:225-229.
37. Kwon OK, Lee MG, Kim HS, et al. Invasive pulmonary aspergillosis after influenza a infection in an immunocompetent patient. *Tuberc Respir Dis (Seoul)* 2013; 75:260-263.
38. Toh H-S, Jiang M-Y, Tay H-T. Invasive pulmonary aspergillosis in severe complicated influenza A. *J Formos Med Assoc* 2013; 112:810-811.
39. Yildirim Y, Pecha S, Sill B, et al. Severe bacterial superinfection based on influenza A (H1N1) pneumonia in a heart-lung transplant recipient. *Thorac Cardiovasc Surg* 2013; 61:255-257.
40. Lee JY, Joo EJ, Yeom JS, et al. *Aspergillus* tracheobronchitis and influenza A co-infection in a patient with AIDS and neutropenia. *Infect Chemother* 2014; 46:209-215.
41. Park DW, Yhi JY, Koo G, et al. Fatal clinical course of probable invasive pulmonary aspergillosis with influenza B infection in an immunocompetent patient. *Tuberc Respir Dis (Seoul)* 2014; 77:141-144.
42. Alshabani K, Haq A, Miyakawa R, et al. Invasive pulmonary aspergillosis in patients with influenza infection: report of two cases and systematic review of the literature. *Expert Rev Respir Med* 2015; 9:89-96.
43. Kolwijck E, Scheper H, Beuving J, et al. [Invasive pulmonary aspergillosis in influenza]. *Ned Tijdschr Geneesk* 2015; 159:A7431.
44. Pietsch U, Muller-Hocker C,ENZLER-Tschudy A, Filipovic M. Severe ARDS in a critically ill influenza patient with invasive pulmonary aspergillosis. *Intens Care Med* 2016; 42:1632-1633.

45. Crum-Cianflone NF. Invasive aspergillosis associated with severe influenza infections. *Open Forum Infect Dis* 2016; 3:ofw171.
46. Nulens EF, Bourgeois MJ, Reynders MB. Post-influenza aspergillosis, do not underestimate influenza B. *Infect Drug Resist* 2017; 10:61-67.
47. Su P-A, Yu W-L. Failure of extracorporeal membrane oxygenation to rescue acute respiratory distress syndrome caused by dual infection of influenza A (H1N1) and invasive pulmonary aspergillosis. *J Formos Med Assoc* 2017; 116:563-564.
48. Hou K, Sutherland A. Bacterial pneumonia with influenza coinfection complicated by aspergillosis, ARDS, and septic shock in a cirrhotic. *Am J Respir Crit Care Med* 2017;195.
49. Ku YH, Chuang YC, Yu WL. Postinfluenza A(H3N2) refractory invasive pulmonary aspergillosis. *J Formos Med Assoc* 2017; 116:404-405.
50. Ku YH, Chan KS, Yang CC, et al. Higher mortality of severe influenza patients with probable aspergillosis than those with and without other coinfections. *J Formos Med Assoc* 2017; 116:660-670.
51. van de Veerdonk FL, Kolwijck E, Lestrade PP, et al. Influenza-associated aspergillosis in critically ill patients. *Am J Respir Crit Care Med* 2017.
 - Large case series showing high incidence and mortality of critically ill influenza patients with secondary aspergillosis.
52. Shah MM, Hsiao EI, Kirsch CM, et al. Invasive pulmonary aspergillosis and influenza co-infection in immunocompetent hosts: case reports and review of the literature. *Diagn Microbiol Infect Dis* 2018; 91:147-152.
 - Review of epidemiology and risk factors for influenza-associated aspergillosis.
53. Talento AF, Dunne K, Murphy N, et al. Post-influenza triazole-resistant aspergillosis following allogeneic stem cell transplantation. *Mycoses* 2018; Mar 23. doi: 10.1111/myc.12770. [Epub ahead of print].
54. Ajmal S, Mahmood M, Abu Saleh O, et al. Invasive fungal infections associated with prior respiratory viral infections in immunocompromised hosts. *Infection* 2018; Apr 7. doi: 10.1007/s15010-018-1138-0. [Epub ahead of print].
55. Martin-Loeches I, J Schultz M, Vincent JL, et al. Increased incidence of co-infection in critically ill patients with influenza. *Intensive Care Med* 2017; 43:48-58.
56. Rodriguez-Goncer I, Thomas S, Foden P, et al. Invasive pulmonary aspergillosis is associated with adverse clinical outcomes in critically ill patients receiving veno-venous extracorporeal membrane oxygenation. *Eur J Clin Microbiol Infect Dis* 2018; 37:1251-1257.
57. Cavayas YA, Yusuff H, Porter R. Fungal infections in adult patients on extracorporeal life support. *Crit Care* 2018; 22:98.
 - Large retrospective analysis of an international ECMO database identifying influenza as a risk factor for positive *Aspergillus* cultures in ECMO patients.
58. Paules C, Subbarao K. Influenza. *Lancet* 2017; 390:697-708.
59. Reddy KP, Bajwa EK, Parker RA, et al. Relationship between upper respiratory tract influenza test result and clinical outcomes among critically ill influenza patients. *Open Forum Infect Dis* 2016; 3:ofw023.
60. Patterson TF, Thompson GR, 3rd, Denning DW, et al. Practice guidelines for the diagnosis and management of aspergillosis: 2016 Update by the Infectious Diseases Society of America. *Clin Infect Dis* 2016; 63:e1-e60.
61. Krenke R, Grabczak EM. Tracheobronchial manifestations of *Aspergillus* infections. *ScientificWorldJournal* 2011; 11:2310-2329.
62. Eigl S, Prattes J, Lackner M, et al. Multicenter evaluation of a lateral-flow device test for diagnosing invasive pulmonary aspergillosis in ICU patients. *Crit Care* 2015; 19:178.
63. Ullmann AJ, Aguado JM, Arikan-Akdagli S, et al. Diagnosis and management of *Aspergillus* diseases: executive summary of the 2017 ESCMID-ECMM-ERS guideline. *Eur J Clin Microbiol Infect Dis* 2018; 24 Suppl 1:e1-e38.

64. Buil JB, van der Lee HAL, Rijs A, et al. Single-center evaluation of an agar-based screening for azole resistance in *Aspergillus fumigatus* by using VIPcheck. *Antimicrob Agents Chemother* 2017; 61: pii:e01250-17.
65. Lestrade P, Bentvelsen RG, Schauwvlieghe AFAD, et al. Voriconazole resistance and mortality in invasive aspergillosis: a multicenter retrospective cohort study. *Clin Infect Dis* 2018; (in press).
66. Buil JB, Zoll J, Verweij PE, et al. Molecular detection of azole-resistant *Aspergillus fumigatus* in clinical samples. *Front Microbiol* 2018; 9:515.
67. Chong GM, van der Beek MT, von dem Borne PA, et al. PCR-based detection of *Aspergillus fumigatus* Cyp51A mutations on bronchoalveolar lavage: a multicentre validation of the AsperGenius assay® in 201 patients with haematological disease suspected for invasive aspergillosis. *J Antimicrob Chemother* 2016; 71:3528-3535.
68. Buchner J, Mazzeffi M, Kon Z, et al. Single-center experience with venovenous ECMO for influenza-related ARDS. *J Cardiothorac Vasc Anesth* 2018; 32:1154-1159.
69. Pasi P, Mike C. ECDC expert opinion on efficacy and effectiveness of neuraminidase inhibitors published for public consultation. *Influenza Other Respir Viruses* 2016; 10:152-153.
70. European Medical Agency. Alpivab : EPAR - Public assessment report. London: European Medicines Agency; 2018. p. 108.
71. Rodriguez A, Diaz E, Martin-Loeches I, et al. Impact of early oseltamivir treatment on outcome in critically ill patients with 2009 pandemic influenza A. *J Antimicrob Chemother* 2011; 66:1140-1149.
72. Richard F, Mahieu R, Gullou-Guillemette HL, et al. Prognosis factors of severe influenza in ICU and introduction delay of oseltamivir. *Annals of Intensive Care* 2017; 7:21-22.
73. Hernu R, Chroboczek T, Madelaine T, et al. Early oseltamivir therapy improves the outcome in critically ill patients with influenza: a propensity analysis. *Intensive Care Med* 2018; 44:257-260.
74. Flannery AH, Thompson Bastin ML. Oseltamivir dosing in critically ill patients with severe influenza. *Ann Pharmacother* 2014; 48:1011-1018.
75. Kiser T, Burnham E, Ho M, et al. 660: Extended-duration versus standard-duration oseltamivir in critically ill patients with influenza. *Crit Care Med* 2018; 46:316.
76. Network SEAIDCR. Effect of double dose oseltamivir on clinical and virological outcomes in children and adults admitted to hospital with severe influenza: double blind randomised controlled trial. *Br Med J* 2013; 346:f3039.
77. Lee N, Hui DS, Zuo Z, et al. A prospective intervention study on higher-dose oseltamivir treatment in adults hospitalized with influenza a and B infections. *Clin Infect Dis* 2013; 57:1511-1519.
78. Kumar A. Viral clearance with standard or triple dose oseltamivir therapy in critically ill patients with pandemic (H1N1) 2009 influenza. 53rd Interscience Conference on Antimicrobial Agents and Chemotherapy; September 10-13; Denver, CO 2013. p. B-1470.
79. Kiser T, Burnham E, Ho M, et al. 656: Evaluation of high-dose versus standard-dose oseltamivir in critically ill patients with influenza. *Crit Care Med* 2018; 46:314.
- Retrospective analysis of 19,892 critically ill influenza patients receiving either high-dose or standard-dose oseltamivir, showing no clinical benefit of high-dose therapy.
80. Welch SC, Lam SW, Neuner EA, et al. High-dose versus standard dose oseltamivir for treatment of severe influenza in adult intensive care unit patients. *Intensive Care Med* 2015; 41:1365-1366.
81. Kmietowicz Z. WHO downgrades oseltamivir on drugs list after reviewing evidence. *BMJ* 2017; 357:j2841.
82. Ariano RE, Sitar DS, Zelenitsky SA, et al. Enteric absorption and pharmacokinetics of oseltamivir in critically ill patients with pandemic (H1N1) influenza. *CMAJ* 2010; 182:357-363.
83. Eyler RF, Heung M, Pleva M, et al. Pharmacokinetics of oseltamivir and oseltamivir carboxylate in critically ill patients receiving continuous venovenous hemodialysis and/or extracorporeal membrane oxygenation. *Pharmacotherapy* 2012; 32:1061-1069.
84. Mulla H, Peek GJ, Harvey C, et al. Oseltamivir pharmacokinetics in critically ill adults receiving extracorporeal membrane oxygenation support. *Anaesth Intensive Care* 2013; 41:66-73.

85. Lemaitre F, Luyt CE, Rouillet-Renoleau F, et al. Impact of extracorporeal membrane oxygenation and continuous venovenous hemodiafiltration on the pharmacokinetics of oseltamivir carboxylate in critically ill patients with pandemic (H1N1) influenza. *Ther Drug Monit* 2012; 34:171-175.
86. 39th ESCP European symposium on clinical pharmacy & 13th SFPC congress: clinical pharmacy at the front line of innovations. 21–23 October 2010, Lyon, France. *Int J Clin Pharm* 2011; 33:285-467.
87. Kromdijk W, Sikma MA, van den Broek MPH, et al. Pharmacokinetics of oseltamivir carboxylate in critically ill patients: each patient is unique. *Intensive Care Med* 2013; 39:977-978.
88. Eschenauer GA, Lam SW. Supratherapeutic oseltamivir levels during continuous dialysis: an expected risk. *Intensive Care Med* 2011; 37:371.
89. Ison MG. Antiviral Treatments. *Clin Chest Med* 2017; 38:139-153.
90. Naesens L, Stevaert A, Vanderlinden E. Antiviral therapies on the horizon for influenza. *Curr Opin Pharmacol* 2016; 30:106-115.
91. Herbrecht R, Denning DW, Patterson TF, et al. Voriconazole versus amphotericin B for primary therapy of invasive aspergillosis. *N Engl J Med* 2002; 347:408-415.
92. Spriet I, Annaert P, Meersseman P, et al. Pharmacokinetics of caspofungin and voriconazole in critically ill patients during extracorporeal membrane oxygenation. *J Antimicrob Chemother* 2009; 63:767-770.
93. Ruiz S, Papy E, Da Silva D, et al. Potential voriconazole and caspofungin sequestration during extracorporeal membrane oxygenation. *Intensive Care Med* 2009; 35:183-184.
94. Li TY, Liu W, Chen K, et al. The influence of combination use of CYP450 inducers on the pharmacokinetics of voriconazole: a systematic review. *J Clin Pharm Ther* 2017; 42:135-146.
95. Andes D, Azie N, Yang H, et al. Drug-drug interaction associated with mold-active triazoles among hospitalized patients. *Antimicrob Agents Chemother* 2016; 60:3398-3406.
96. Muilwijk EW, Dekkers BGJ, Henriët SSV, et al. Flucloxacillin results in suboptimal plasma voriconazole concentrations. *Antimicrob Agents Chemother* 2017; 61.pii: e00915-17
 - Small case series highlighting the need for therapeutic drug monitoring when coadministering flucloxacillin and voriconazole.
97. Maertens JA, Raad II, Marr KA, et al. Isavuconazole versus voriconazole for primary treatment of invasive mould disease caused by *Aspergillus* and other filamentous fungi (SECURE): a phase 3, randomised-controlled, non-inferiority trial. *Lancet* 2016; 387:760-769.
98. Ledoux MP, Toussaint E, Denis J, Herbrecht R. New pharmacological opportunities for the treatment of invasive mould diseases. *J Antimicrob Chemother* 2017; 72(suppl_1):i48-i58.
99. Marty FM, Ostrosky-Zeichner L, Cornely OA, et al. Isavuconazole treatment for mucormycosis: a single-arm open-label trial and case-control analysis. *Lancet Infect Dis* 2016; 16:828-837.
100. Stott KE, Hope WW. Therapeutic drug monitoring for invasive mould infections and disease: pharmacokinetic and pharmacodynamic considerations. *J Antimicrob Chemother* 2017; 72(suppl_1):i12-i8.
101. Bassetti M, Carnelutti A, Righi E. Issues in the management of invasive pulmonary aspergillosis in non-neutropenic patients in the intensive care unit: A role for isavuconazole. *IDCases* 2018; 12:7-9.
102. Resendiz Sharpe A, Lagrou K, Meis JF, Chowdhary A, Lockhart SR, Verweij PE. Triazole resistance surveillance in *Aspergillus fumigatus*. *Med Mycol* 2018; 56(suppl_1):83-92.
 - Review of current knowledge on triazole resistance, including worldwide epidemiology and expert opinion.
103. van Paassen J, Russcher A, In 't Veld-van Wingerden AW, et al. Emerging aspergillosis by azole-resistant *Aspergillus fumigatus* at an intensive care unit in the Netherlands, 2010 to 2013. *Euro Surveill* 2016; 21.
104. Verweij PE, Ananda-Rajah M, Andes D, et al. International expert opinion on the management of infection caused by azole-resistant *Aspergillus fumigatus*. *Drug Resist Updat* 2015; 21-22:30-40.
105. Bassetti M, Garnacho-Montero J, Calandra T, et al. Intensive care medicine research agenda on invasive fungal infection in critically ill patients. *Intens Care Med* 2017; 43:1225-1238.
106. Nivoix Y, Velten M, Letscher-Bru V, et al. Factors associated with overall and attributable mortality in invasive aspergillosis. *Clin Infect Dis* 2008; 47:1176-1184.

107. Thompson BT, Chambers RC, Liu KD. Acute Respiratory Distress Syndrome. *N Engl J Med* 2017; 377:1904-1905.
108. Cooper MS, Stewart PM. Corticosteroid insufficiency in acutely ill patients. *N Engl J Med* 2003; 348:727-734.
109. Venkatesh B, Finfer S, Avni T, et al. Adjunctive glucocorticoid therapy in patients with septic shock. *N Engl J Med* 2018; 378:797-808.
110. Stern A, Skalsky K, Avni T, et al. Corticosteroids for pneumonia. *Cochrane database Syst Rev* 2017; 12:Cd007720.
- Systematic review on the use of systemic corticosteroids in pneumonia-patients, showing improved morbidity and mortality with hyperglycemia as major side-effect.
111. Prina E, Ceccato A, Torres A. New aspects in the management of pneumonia. *Crit Care* 2016; 20:267.
112. Giannella M, Alonso M, Garcia de Viedma D, et al. Prolonged viral shedding in pandemic influenza A(H1N1): clinical significance and viral load analysis in hospitalized patients. *Eur J Clin Microbiol Infect Dis* 2011; 17:1160-1165.
113. Nedel WL, Nora DG, Salluh JIF, et al. Corticosteroids for severe influenza pneumonia: A critical appraisal. *World J Crit Care Med* 2016; 5:89-95.
114. Delaney JW, Pinto R, Long J, et al. The influence of corticosteroid treatment on the outcome of influenza A(H1N1pdm09)-related critical illness. *Crit Care* 2016; 20:75.
115. Meersseman W, Lagrou K, Maertens J, Van Wijngaerden E. Invasive aspergillosis in the intensive care unit. *Clin Infect Dis* 2007; 45:205-216.
116. Lionakis MS, Kontoyiannis DP. Glucocorticoids and invasive fungal infections. *Lancet* 2003; 362:1828-1838.
117. Bassetti M, Bouza E. Invasive mould infections in the ICU setting: complexities and solutions. *J Antimicrob Chemother* 2017; 72(suppl_1):i39-i47.
- Review addressing the problems of diagnosing and treating IPA in the intensive care unit.
118. Bermejo-Martin JF, Martin-Loeches I, Rello J, et al. Host adaptive immunity deficiency in severe pandemic influenza. *Crit Care* 2010; 14:R167.
119. Walther E, Xu Z, Richter M, et al. Dual acting neuraminidase inhibitors open new opportunities to disrupt the lethal synergism between *Streptococcus pneumoniae* and influenza virus. *Front Microbiol* 2016; 7:357.
120. Dewi IMW, Cunha C, Vanderbeke L, et al. Oseltamivir affects host defense against invasive pulmonary aspergillosis. Abstract presented at ECCMID 2018; 2018 April 2018; Madrid.
- Conference abstract showing effect of oseltamivir on host susceptibility to *Aspergillus* in vivo and in vitro.