

Received: 2018.02.18
Accepted: 2019.04.04
Published: 2019.06.05

Isolated Trapezoid Fracture in a Boxer

Authors' Contribution:
Study Design A
Data Collection B
Statistical Analysis C
Data Interpretation D
Manuscript Preparation E
Literature Search F
Funds Collection G

ABCDE 1 **Luís Mata Ribeiro**
ABDEF 2 **Miguel Alves Botton**

1 Department of Plastic and Reconstructive Surgery, Hospital São José, Lisbon, Portugal
2 Hand and Wrist Unit (Center of Orthopedics and Traumatology), Hospital CUF Descobertas, Lisbon, Portugal

Corresponding Author: Luís Mata Ribeiro, e-mail: Luis1989ribeiro@gmail.com
Conflict of interest: None declared

Patient: Male, 33
Final Diagnosis: Trapezoid fracture
Symptoms: Pain during active flexion/extension of the wrist tenderness at the base of the second metacarpal
Medication: —
Clinical Procedure: Cast immobilisation
Specialty: Orthopedics and Traumatology





Objective: Challenging differential diagnosis
Background: Trapezoid fractures are very uncommon, accounting for less than 1% of all wrist fractures. Isolated fractures of this bone are even more rare, with just a few reports in the literature. The trapezoid bone has a very stable position within the wrist, forming a relatively immobile joint with the second metacarpal base distally. It is also connected by very strong ligaments to the trapezium, capitate and, scaphoid. Trapezoid fractures occur when a strong bending or axial force is applied to the second metacarpal base.

Case Report: We present a clinical case of an isolated, non-displaced, trapezoid fracture in a young white male, which was treated with cast immobilization for 4 weeks and physical therapy. Complete functional recovery was achieved 3 months after the injury, without any pain or tenderness.

Conclusions: Fractures of the trapezoid bone usually have a good clinical outcome. Nonetheless, we need to be very suspicious about this diagnosis since radiography is apparently normal in almost all such cases and clinical examination results may not be entirely clear.

MeSH Keywords: Carpal Bones • Tomography, X-Ray Computed • Trapezoid Bone • Wrist Injuries

Full-text PDF: <https://www.amjcaserep.com/abstract/index/idArt/915757>

 834  1  2  14



Background

The carpus is a complex biomechanical, tridimensional, unit that links the forearm with the hand. This bony framework is held together by strong ligaments that provide stability and protect them from damage. Of all carpal bone fractures, the scaphoid is by far the most frequently affected bone, and is involved in roughly two-thirds of all such fractures [1]. This usually happens when the patient falls with an outstretched arm and hand.

Trapezoid fractures are very uncommon, comprising less than 1% of all wrist fractures. The trapezoid bone has a very stable position within the wrist, forming a relatively immobile joint with the second metacarpal base distally. It is also connected by very strong ligaments to the trapezium, capitate, and scaphoid. Due to its well-protected location, isolated lesions of the trapezoid are even more uncommon [2], with only a few published reports in the literature.

We present a case of an isolated, non-displaced, trapezoid fracture in a young white male, which was successfully treated with cast immobilization, achieving complete functional recovery.

Case Report

A 33-year-old male engineer presented to us the day after suffering a heavy impact on his right hand during a boxing training class. He finished his boxing lesson, and he did not notice that his hand was slightly swollen until he arrived home. This condition got progressively worse, and the following morning he decided to seek medical evaluation. He did not take any medication or apply any topical substance on the hand after the event. His past history was unremarkable.

Clinically, he had a significant swelling of the dorsum of the hand, tenderness at the base of the second metacarpal, and pain during active flexion/extension of the wrist, but finger mobility was unaffected. The palpation of the distal radius and ulna and of the remaining metacarpals did not elicit any pain. There were no apparent signs of active infection, bleeding, or compartment syndrome. The radiography (antero-posterior and lateral) did not show any apparent injury. Due to persistent doubts in the diagnosis, a computed tomography (CT) scan was ordered. It demonstrated a linear, non-displaced (step-off inferior to 1 mm) fracture of the trapezoid bone, affecting the intra-articular surface with the second metacarpal, without evidence of any other fracture or associated injury (Figures 1, 2).

Since it was a non-displaced fracture without a significant gap between the bone fragments and without migration of the 2nd metacarpal bone, we opted to treat conservatively.

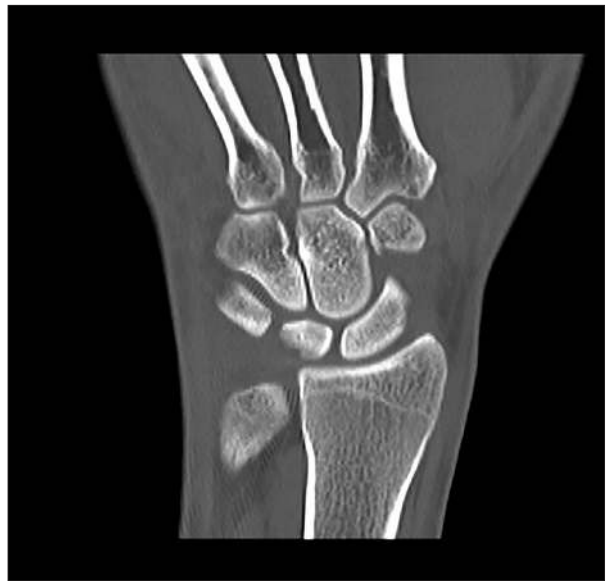

Figure 1. Coronal view computed tomography of the wrist.

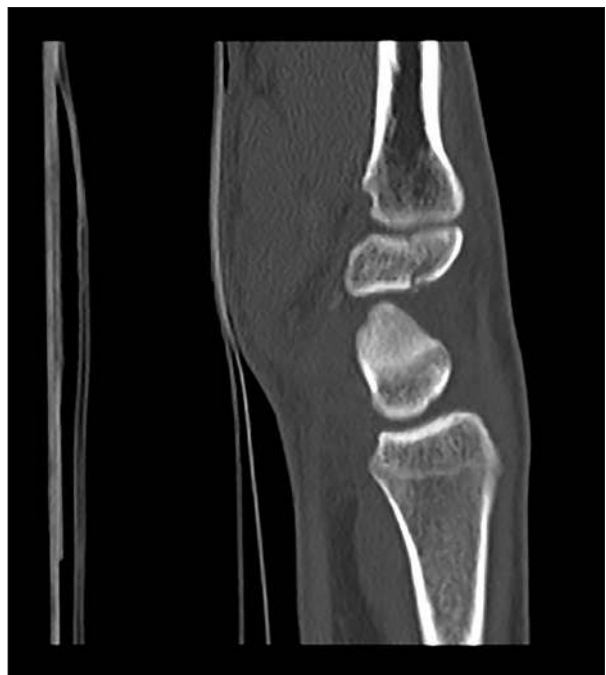

Figure 2. Sagittal view computed tomography of the wrist.

The wrist was immobilized in a short arm-thumb spica and the patient started analgesic and anti-inflammatory medication. After 4 weeks of immobilization, the cast was removed, and the patient began physical therapy. Two months after the initial injury, the patient had regained complete and painless mobility of the wrist, without any edema or tenderness. By 3 months after the injury, the patient had returned to work and was performing intense physical exercise using the affected hand without complaints. The patient was very satisfied with the results of the treatment.

Table 1. List of previous reports on isolated trapezoid fractures.

Authors	Number of patients	Diagnostic modality	Treatment	Outcome
Miyawaki et al. [2] (2000)	1	CT scan	Conservative (6 weeks)	Pain free and no limitations
Nagumo et al. [6] (2002)	1	Technetium bone scan and MRI	Surgery (removal of a dorsal fragment)	Pain free and no limitations
Nijs et al. [9] (2004)	2	MRI/CT Scan	Conservative (4 weeks; 8 weeks)	Pain free and no limitations
Sadowski et al. [1] (2008)	1	CT Scan	Conservative (6 weeks)	Pain free and no limitations
Gruson et al. [3] (2008)	1	CT Scan	Conservative (6 weeks)	Pain free and no limitations
Jacoulet et al. [5] (2009)	1	MRI and CT Scan	Conservative (2 months)	Pain free and no limitations
Kam, et al. [8] (2010)	1	X-ray and CT Scan	Surgery (bone graft and 2 nd carpometacarpal arthrodesis)	Pain free and no limitations
Afifi et al. [4] (2011)	1	CT Scan	–	–
Kain et al. [10] (2012)	11 (only 5 with isolated fractures)	CT Scan (8 patients); X-ray (2 patients); MRI (1 patient); Does not discriminate which diagnostic modality in the isolated fractures	Conservative (9 patients) – no information regarding time of immobilization Surgery (2 patients)	–
Heron et al. [11] (2012)	1	CT Scan and Technetium bone scan	Conservative (8 weeks)	Pain free and no limitations
Blomqvist et al. [12] (2013)	3	MR arthrogram (2×); CT Scan (1×)	Conservative (1 patient 6 weeks; the other no information) Surgery (screw fixation)	Pain free and no limitations
Papadakis et al. [13] (2014)	1	CT Scan	Conservative (6 weeks)	Pain free and no limitations
Ault et al. [14] (2018)	1	Ultrasound	–	–

Sign (–) – no information available. The time periods stated in the conservative treatment refer to the immobilization period.

Discussion

The initial diagnosis of this lesion relies heavily on clinical suspicion based on the symptoms and the mechanism/circumstance of injury. The mechanism of trapezoid injury seems to be an axial or bending force applied to the second metacarpal base [3]. Patients with this injury frequently have pain or tenderness of the second metacarpal base and in the anatomic snuffbox, as well as wrist edema and limited wrist mobility [1,4]. Sports injuries, heavy falls, and fist fights are the main causes of trapezoid fracture.

Standard antero-posterior and lateral radiographies of the hand are mandatory for wrist evaluation but they usually

cannot detect trapezoid fractures. Magnetic resonance imaging, technetium bone scans and specially CT scans are much more sensitive and specific for this particular diagnosis. [3,5].

Several treatment options have been reported in the literature, from conservative management to open reduction and internal fixation, percutaneous fixation, or excision of the fragment [6–8]. Despite this, no single specific therapy has been validated for the treatment of this injury. Most authors agree that cast immobilization for 3 to 6 weeks is adequate treatment for non-displaced or minimally displaced (<2 mm) isolated trapezoid fractures. Internal fixation, usually through a dorsal direct approach, is advocated for fractures with larger displacement and for those with additional metacarpal/carpal fractures [9].

Most authors report a very good outcome, regardless of the type of treatment (Table 1), but long-term outcomes of untreated trapezoid fractures are not as good even though they are not as thoroughly documented. There is a possibility of delayed union, symptomatic non-union, or malunion and osteonecrosis, and these can lead to long-term functional impairment with chronic pain and reduced grip strength [14].

References:

1. Sadowski RM, Montilla RD: Rare isolated trapezoid fracture: A case report. *Hand (NY)*, 2008; 3(4): 372–74
2. Miyawaki T, Kobayashi M, Matsuura S et al: Trapezoid bone fracture. *Ann Plast Surg*, 2000; 44(4): 444–46
3. Gruson KI, Kaplan KM, Paksima N: Isolated trapezoid fractures: A case report with compilation of the literature. *Bull NYU Hosp Jt Dis*, 2008; 66(1): 57–60
4. Afifi N, Lu JJ: A rare isolated trapezoid fracture. *West J Emerg Med*, 2011; 12(4): 523–24
5. Jacoulet P, Lautman S, Mraovic T: [Isolated trapezoid fracture: A case report]. *Chir Main*, 2009; 28(6): 378–80 [in French]
6. Nagumo A, Toh S, Tsubo K et al: An occult fracture of the trapezoid bone: A case report. *JBJS*, 2002; 84(6): 1025–27
7. Watanabe H, Hamada Y, Yamamoto Y: A case of old trapezoid fracture. *Arch Orthop Trauma Surg*, 1999; 119(5–6): 356–57
8. Kam MLW, Sreedharan S, Teoh LC, Chew WYC: Severe isolated trapezoid fracture: A case report. *Hand Surg*, 2011; 16(02): 185–87
9. Nijs S, Mulier T, Broos P: Occult fracture of the trapezoid bone: A report on 2 cases. *Acta Orthop Belg*, 2004; 70(2): 177–79
10. Kain N, Heras-Palou C: Trapezoid fractures: Report of 11 cases. *J Hand Surg Am*, 2012; 37(6): 1159–62
11. Heron N, Verdugo F, Turmo A, Perez LT: Trapezoid stress fracture in an international shot-putter: A case report. *J Sports Sci Med*, 2012; 11(4): 768–70
12. Blomquist GA, Hunt TR III, Lopez-Ben RR: Isolated fractures of the trapezoid as a sports injury. *Skeletal Radiol*, 2013; 42(5): 735–39
13. Papadakis M, Lianou A, Nikolaou VS: Isolated fracture of the trapezoid. A rare injury. *J Hand Microsurg*, 2015; 7(1): 104–5
14. Ault DL, Jokerst AR, Kettner NW: Occult isolated fracture of the trapezoid diagnosed by ultrasonography. *J Ultrasound*, 2018 [Epub ahead of print]

Conclusions

We present this case to highlight the need to be very suspicious in traumatic wrist injuries in young patients when the radiography is apparently normal and physical examination is not definitive. We recommend additional imaging tests and a close follow-up to avoid missing a trapezoid fracture in the acute phase and preventing possible complications such as avascular necrosis or non-union.

Conflict of interest

None.