

## Joint Preservation of the Osteoarthritic Ankle Using Distraction Arthroplasty

Nazzar Tellisi, MD; Austin T. Fragomen, MD; Dawn Kleinman, BS; Martin J. O'Malley, MD; S. Robert Rozbruch, MD  
New York, NY

### ABSTRACT

**Background:** In recent years ankle distraction arthroplasty has gained popularity in the treatment of ankle arthritis as a means of both maintaining range of motion and avoiding fusion. We present a retrospective review of 25 patients who have undergone ankle distraction from 1999 to 2006. **Materials and Methods:** The mean age was 43 years; 16 were male, and 7 were female. Followup was 30 months after frame removal (range, 12 to 60 months). We were able to obtain followup on 23 of 25 patients. Adjuvant procedures were performed in some cases including Achilles tendon lengthening (5), ankle arthroscopy (4), open arthrotomy (1), and supramalleolar tibial and distal fibular osteotomy to correct distal tibial deformity (6). **Results:** Twenty-one patients (91%) reported improved pain with those furthest post-op experiencing the best results. The average preoperative AOFAS score was 55 (range, 29 to 82), and the average postoperative score was 74 (range, 47 to 96). The difference between pre- and postoperative scores was significant ( $p = 0.005$ ). SF-36 scores showed modest improvement in all components. Only two of the patients in the study underwent fusion after ankle distraction. Total ankle motion was maintained in all patients with improvement in the functional arc of motion in five patients who started with mild equinus contractures. **Conclusion:** We feel that ankle distraction offers a promising solution for many people with ankle arthritis.

### Level of Evidence: IV, Retrospective Case Series

**Key Words:** Ankle Distraction; Ankle Arthritis; Ilizarov; Taylor Spatial Frame

No benefits in any form have been received or will be received from a commercial party related directly or indirectly to the subject of this article.

Corresponding Author:  
Nazzar Tellisi, MD  
Hospital for Special Surgery  
Limb Lengthening and Deformity Service  
Foot and Ankle Service  
535 East 70th Street  
New York, NY 10021  
E-mail: ntellisi@yahoo.co.uk  
For information on pricings and availability of reprints, call 410-494-4994, x232.

### INTRODUCTION

Ankle arthritis and its management remain a challenge. Ankle fusion continues to be a mainstay of treatment for ankle arthritis. However, fusion is not an optimal solution due to the loss of joint motion and subsequent development of degenerative arthritis of adjacent joints. Other disadvantages of arthrodesis include a substantial rate of malunion, nonunion, wound healing problems, loss of function, abnormal gait, and increased energy expenditures with ambulation.<sup>9</sup> Ankle arthritis is most commonly seen in patients as a post-traumatic sequelae.<sup>8</sup> Many patients were highly functional prior to their injuries and are reluctant to sacrifice the ankle motion following ankle arthrodesis. With the lack of encouraging long-term results from prosthetic ankle arthroplasty, other treatment modalities are sought.

Joint distraction arthroplasty, using a circular external fixator, is not a new approach in the treatment of arthrosis. Distraction arthroplasty was first implemented in the management of hip arthritis by Judet.<sup>2</sup> Van Valburg, et al.<sup>11-13</sup> later applied this concept to the arthritic ankle joint. The theory behind the success of distraction is contingent upon the mechanical unloading of the joint and the intermittent flow of intra-articular synovial fluid. It is thought that mechanical stress upon the joint surface inhibits the ability of articular cartilage to undergo a reparative process. When the mechanical stress is unloaded by means of distraction the cartilage will have the opportunity to undergo a healing phase undisturbed by axial loading and shear forces. The intermittent flow or cyclical changes in joint fluid pressure is facilitated by allowing the patient to weight bear with the frame in place causing fluctuations in intra-articular hydrostatic pressure between swing phase and heel strike. This movement of joint fluid is thought to improve the local environment for cartilage healing.<sup>11</sup> We believe that intermittent flow is further enhanced by incorporating articulated distraction which allows for ankle joint range of motion while in the frame. This study presents a series of patients treated with distraction arthroplasty at our center.

## MATERIALS AND METHODS

### Patient selection

A total of 25 patients were identified (23 with complete data) who underwent ankle distraction arthroplasty using a circular external fixator between 1999 and 2006. The mean patient age was 43 (range, 16 to 73) years. Patient sex was 16 males and 7 females. The etiology for the development of ankle arthritis in all patients was post traumatic. These patients were selected to have this procedure for a combination of reasons.

All patients had painful ankle arthritis, and had significant ankle joint mobility (greater than 20 degrees). These patients had failed conservative measures and had all been recommended to undergo ankle arthrodesis to relieve their pain. All patients were unwilling to sacrifice ankle mobility and all had refused arthrodesis. Not all patients that presented to our institution were thought to be good candidates for distraction arthroplasty. Patients with very limited ankle mobility and patients with severely distorted intra-articular geometry (e.g. flatfoot talus) were not considered for this procedure. These patients were thought to be better served with an ankle arthrodesis. Patients with limited ankle motion and pain were considered poor candidates for distraction as they effectively had a painful fusion already. The adjacent joints were already compensating and were at risk for arthritic degeneration. A formal fusion in these patients did not sacrifice any significant motion and provided pain relief. Patients with periarticular deformity, including angular deformities of the distal tibia and hindfoot deformities, were evaluated, and six patients underwent combined deformity correction and joint distraction procedures.

### Preoperative planning

Preoperative work-up started with weightbearing views of the ankles and feet. The tibiotalar joint space was measured and degree of arthritis noted. All patients had less than 2 mm of joint space with the majority having bone-on-bone arthritis of the tibiotalar joint. Severity of arthritis was not a criterion for exclusion. The subtalar joint was evaluated for arthritis, and there were no cases of significant subtalar joint arthritis in this series. Osteophytes were identified. Anterior osteophytes that were thought to be sources of pain or blocked dorsiflexion were planned for removal using either open or arthroscopic techniques. Quantity and location of hardware was noted. No hardware needed to be removed to perform the ankle distraction. In most cases the hardware had been removed previously at an outside institution in an attempt to relieve pain. Periarticular deformity was assessed. In cases with associated tibial deformity, a supramalleolar tibial osteotomy and distal fibular osteotomy was performed in the same surgical setting. These deformities included varus, valgus, recurvatum or external rotation malalignment. In some cases computed tomography scans were obtained to further delineate the extent of

arthritis, the integrity of the subtalar joint, and to identify osteochondritis dissecans lesions. MRI was used in cases of osteonecrosis or suspected infection to further understand the extent of bony involvement. MRI was also very helpful in evaluating tendon and ligamentous integrity and in evaluating the articular cartilage with specific sequencing. In most cases, MRI had already been obtained by the referring physician. Although they were not needed here, diagnostic injections can be used in cases of combined arthritis of the tibiotalar and subtalar joints to help isolate the primary source of pain.

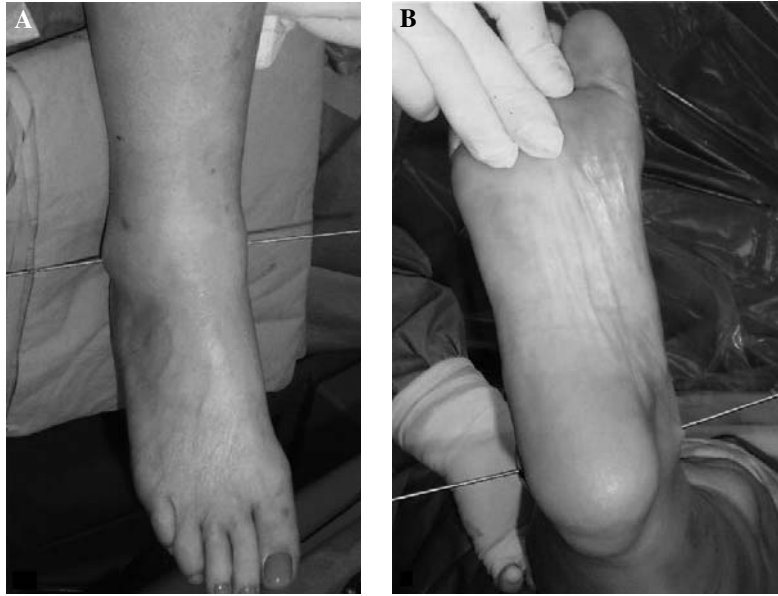
### Outcome measures

Outcome was measured using preoperative and postoperative AOFAS ankle scores and the SF-36 scores, and ankle range of motion. Average preoperative AOFAS score was 55 (range, 29 to 82). Average preoperative ankle range of motion was 7 degrees dorsiflexion (range, -5 to 15 degrees) and 32 degrees plantarflexion (range, 15 to 50 degrees). Pre operative pain as measured on the AOFAS score was 15 (range, 0 to 20). Preoperative and postdistraction values were compared with a paired t-test.

### Technique

All external fixator application surgery was performed by one surgeon (SRR) at one institution using a set protocol.<sup>1</sup> Adjuvant procedures were performed in some cases including Achilles tendon lengthening (five), ankle arthroscopy (four), open arthrotomy (one), and supramalleolar osteotomy to correct distal tibial deformity (six). Other orthopaedic surgeons with fellowship training in foot and ankle surgery assisted with arthroscopy and arthrotomy procedures. The remaining adjuvant surgical procedures were performed by SRR. Spinal anesthesia was given in all cases. In five cases, arthroscopic or open ankle arthrotomy was performed under tourniquet. Anterior osteophytes from the distal tibia or talus were removed, and subchondral drilling was performed in areas of eburnated bone. There were five cases where the heel cord was felt to be tight irrespective of the position of the knee and tendo Achilles lengthening was performed using a percutaneous technique. This was then followed by placement of the circular frame. A tourniquet was not used during frame application as normal osseous and periosteal blood flow was needed to help cool passing wires and drills to avoid thermal necrosis. In all cases a distal tibial ring and a foot ring were used with articulating hinges placed along the ankle joint axis between the rings. In cases of supramalleolar osteotomy a three-ring frame was used. In these cases an additional ring was mounted to the distal third tibial diaphysis proximal to the osteotomy. Taylor Spatial Struts (Smith & Nephew, Memphis, TN) were used to connect the two tibial rings and guide the bony correction. As the majority of cases were done using the two-ring fixator the application of that frame will be reviewed.

The proximal ring was mounted to the distal tibia using two half-pins and one tensioned wire. The fixation was placed



**Fig. 1:** A temporary smooth Kirschner wire is inserted from the tip of the lateral malleolus to the tip of the medial malleolus. The direction is posterolateral to anteromedial. This represents the axis of the ankle joint.

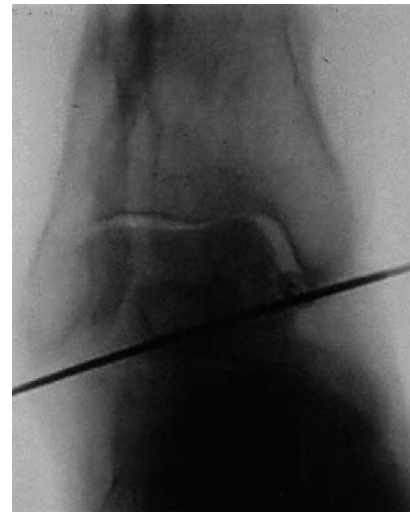in different planes to ensure adequate stability. The wire was a medial-face wire inserted from lateral to medial. It helped to orient the ring and was tensioned.

The half-pins were predrilled with a 4.8-mm drill bit, and then inserted by hand bi-cortically. Half-pins were 6.0 mm, tapered, and hydroxyapatite-coated. Pre-existing internal hardware was retained as it was asymptomatic and did not interfere with pin placement.

Hinges were then placed along the axis of the ankle motion. A temporary smooth Kirschner wire was inserted immediately beneath the tip of the fibula to immediately beneath the tip of the medial malleolus (Figure 1). This was then checked with fluoroscopy to ensure proper placement on AP and lateral images (Figure 2). Two universal hinges were then attached on either side of the tibial ring using threaded rods. The hinges were placed along the reference wire to approximate the true axis of rotation of the ankle joint (Figure 3). Hinge placement was then checked under fluoroscopy to ensure proper placement.

The hinges were then secured to a foot ring which was aligned to the foot. A total of four foot wires were used. A transverse midfoot wire was inserted through the cuneiform bones and tensioned to the ring to establish the alignment. Two additional wires were placed into the calcaneus and then tensioned. A talus wire was inserted, attached to the foot ring, and gently tensioned. This wire prevented inadvertent distraction of the subtalar joint.

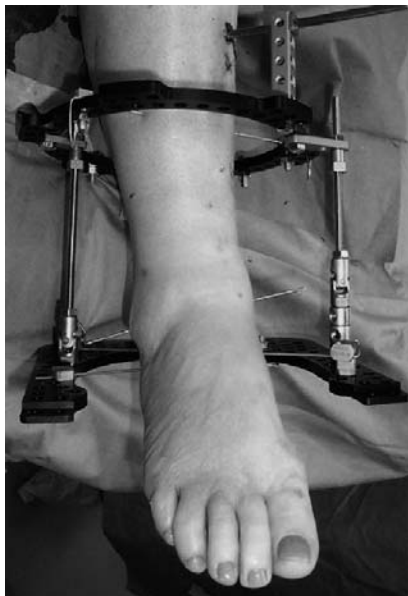An anterior flexion/extension rod was placed to control ankle motion (Figure 4). The ankle was distracted approximately 5 mm acutely in the operating room. The ankle was placed through a range of motion under fluoroscopy to check the amount of distraction as well as to double check the



**Fig. 2:** Fluoroscopic view of the temporary ankle joint axis wire. Note that this wire travels through the center of the talus.

alignment (Figure 5). Sterile dressings were placed on the wounds.

The patients were admitted to the hospital post operatively for pain control and 24 hours of IV antibiotics. Prophylactic oral antibiotics were started once IV antibiotics had completed and were continued for 10 days. Patients started weightbearing as tolerated immediately postoperatively. Deep vein thrombosis (DVT) prophylaxis was implemented after 24 hours and continued for three weeks or until patients were very mobile. There is a small but real incidence of pulmonary embolism (PE) among patients wearing external fixators. No patients in this series developed a DVT or PE. Pin care was started on postoperative day 2 and



**Fig. 3:** Hinge placement along the axis of the ankle joint. Note the use of the temporary joint axis wire.

consisted of cleaning the pin sites once daily with diluted hydrogen peroxide. Patients were allowed to shower and wet the frame and wounds after 4 days. Patient followup included a 2-week visit where sutures were removed and X-rays were obtained to measure the amount of distraction in the joint. The goal was to obtain 5 mm of joint distraction on weightbearing radiographs. If the joint space was less than 5 mm then additional distraction was applied acutely in the office. Additional followup included a 6- and 10-weeks visit. The frames were removed after 12 weeks in the operating room under sedation. After frame removal a cam walker boot was applied and weightbearing as tolerated ambulation was again encouraged. In cases of adjuvant supramalleolar osteotomy the foot ring was removed after 12 weeks in the office if the osteotomy had not fully healed. This ended the distraction period. The remainder of the fixator was removed in the operating room when adequate healing was obtained at 16 (range, 12 to 18) weeks.

## RESULTS

Followup was 30.5 (range, 12 to 60) months measured from the time the external fixator was removed. The average postoperative AOFAS score was 74 (range, 47 to 96). The difference between pre- and postoperative scores was 19 ( $p = .005$ ). Pain improved from an average of 15 (0 to 20) preoperatively to 31 (20 to 40) at latest followup. Twenty-one of the 23 (91%) patients reported improved pain. Individual AOFAS scores showed significant improvement in 17 of the 23 patients. Of the remaining six people, four patients trended towards improvement, but it was not significant. Two of the 23 scored worse at latest followup, but both maintained ankle

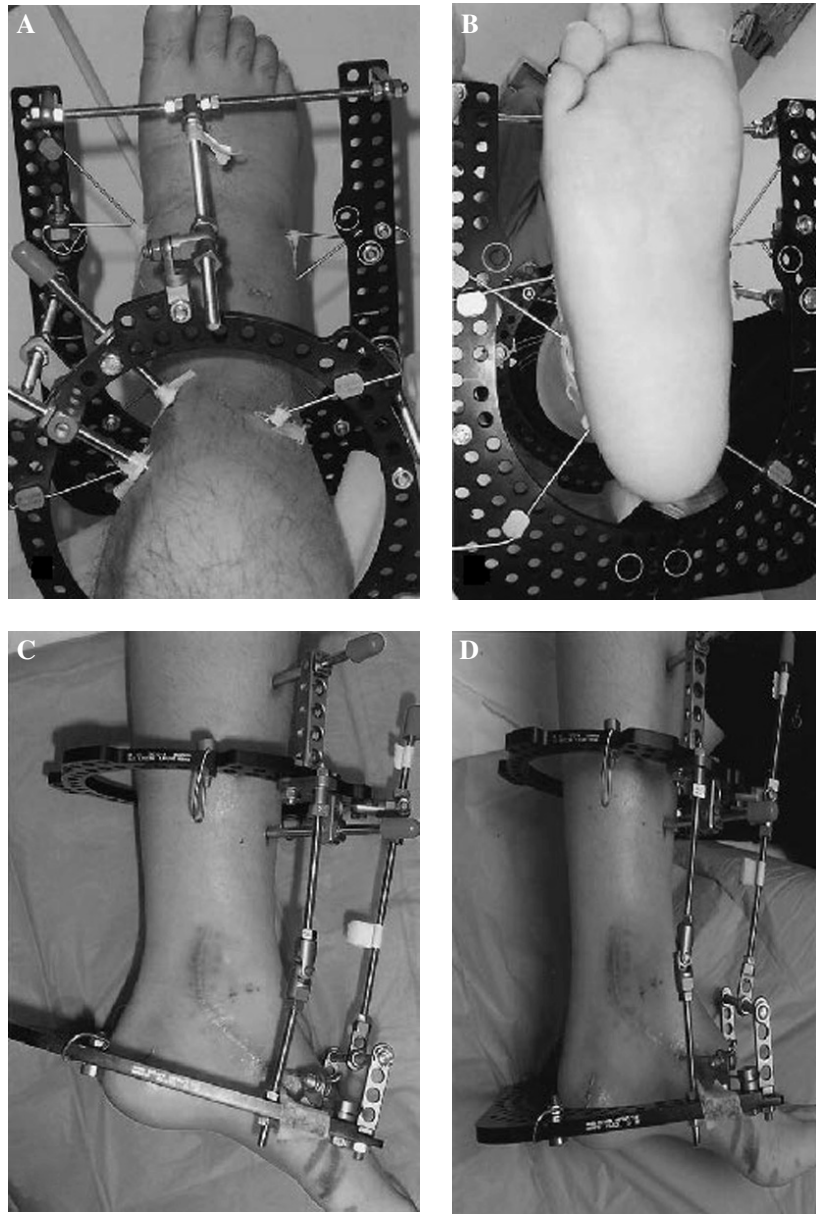
mobility. These two patients went onto ankle fusion. One of these patients had 15 degrees of valgus hindfoot deformity that was not corrected at the time of surgery. This poor result may be due to underlying malalignment and further support the role for deformity correction at the time of distraction surgery. Age was looked at as a predictor of result. AOFAS scores were analyzed for ages less than 30, 30 to 60, and more than 60 years old. Average improvement for patients age less than 30 was 18 points, for patients aged 30 to 60 was 20 points, and for patients aged more than 60 was 36 points. When the scores were analyzed for age there was no significant difference between age groups although the patients older than 60 trended toward more improvement than younger patients. SF-36 scores showed modest improvement in all components most notably in the pain and mental well-being sections ( $p = 0.23$ ). At the time of latest followup only two of these patients elected to undergo fusion. None of the patients showed a loss of motion after distraction. Preoperative ankle range of movement on average was 7 degrees dorsiflexion (range,  $-5$  to 15 degrees) to 32 degrees plantarflexion (range, 15 to 50 degrees). Postoperative ankle range of motion on average was 4.3 degrees dorsiflexion (0 to 10 degrees) to 33 degrees plantarflexion (20 to 40 degrees). The arc of movement improved an average of 10 degrees in the patients who had preoperative mild equinus contractures. When comparing pre operative and post operative (latest followup) radiographs of the ankle, most cases (21/23) showed no difference in ankle joint space (Figure 6).

Complications included superficial pin infections experienced by 100% of patients but were easily controlled with a single course of oral antibiotics. No patients developed deep infection or needed to return to the OR for pin removal or exchange. No cases of septic arthritis were seen. There were no cases of neurovascular injury, RSD, arthrofibrosis, or fracturing.

## DISCUSSION

Ankle distraction arthroplasty is a relatively new method of arthritis treatment in the United States. It is designed to help patients with advanced osteoarthritis of the ankle and preserved joint mobility. It is a promising treatment modality for this difficult group of patients that are unwilling to sacrifice their ankle motion. Van Valburg and Van Roermund<sup>5,7,10-14</sup> have demonstrated the success of non-articulating ankle joint distraction with medium term followup. Ploegmakers, et al.<sup>7</sup> found that 73% of patients experienced significant clinical benefit from ankle distraction that was maintained over 7 years after the procedure. Paley<sup>6</sup> has advocated the use of articulated ankle distraction. His clinical series has yielded a good to excellent results in 18 of 20 ankles.

The biology behind the success of distraction arthroplasty remains not entirely clear. Kajiwarra et al.<sup>3</sup> published a compelling study supporting a cartilage repair model as

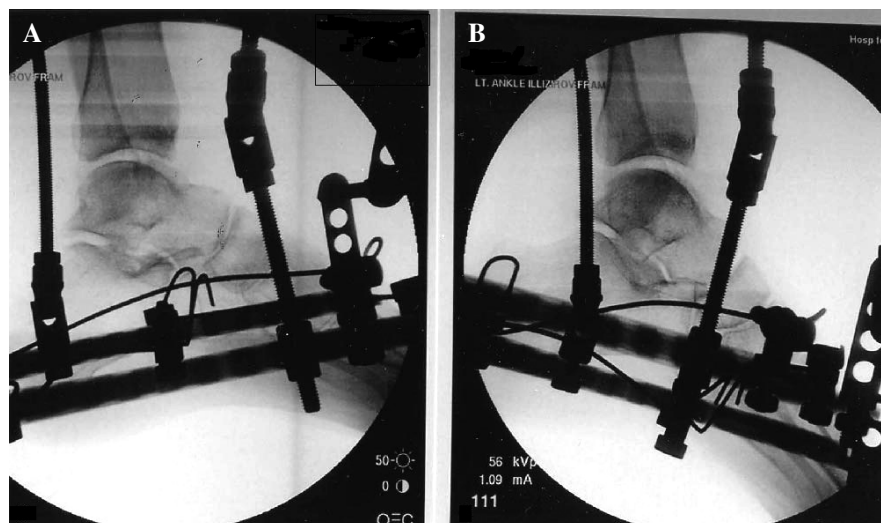


**Fig. 4:** A and B, Completed frame showing pin and wire placement. C and D, Note anterior distraction/compression rod used to move the ankle into plantarflexion and dorsiflexion respectively.

a direct result of distraction arthroplasty. He compared the repair process of full thickness defects in rabbit knees with and without distraction. In his experiment a full thickness defect was created in the cartilage of the femoral condyle of bilateral knees. A mini external fixator was applied to the experimental knee and was distracted. The control knee had no distraction. The distracted knee produced significant amounts of hyaline cartilage that filled the defect area between 8 to 12 weeks after distraction. The control knee filled in with fibrocartilage. Van Valburg et al.<sup>14</sup> used a canine model to show that distraction helped to re-establish normal cartilage proteoglycan metabolism and decrease inflammation when applied to arthritic knee joints. Joint distraction

was also studied on rabbits by Karadam, et al.<sup>4</sup> The results showed no histological evidence of cartilage repair after 6 weeks of joint distraction. This finding may be consistent with those of Kajiwarra who found that a minimum distraction period of 8 weeks was needed to see cartilage repair.

The clinical standard has been set by Von Valburg and Van Roermund, et al.<sup>5,7,10-14</sup> Their protocol includes a 12-week period of joint distraction with 5 mm of joint space maintained during that time. They believe that chondrocytes may need a full 12 to 22 weeks of mechanical unloading to be able to repair the cartilage matrix, and they have found that several months are needed after distraction to see the full clinical benefits. These authors have also found that



**Fig. 5:** A and B, Fluoroscopic view showing ankle distraction and congruent ankle movement in dorsiflexion and plantarflexion. This confirms correct hinge placement.

joint distraction resulted in diminished subchondral sclerosis about the ankle joint presumably because the axial loading is transferred through the frame instead of the joint. This revascularization phenomena may have a beneficial influence on osteoarthritis and is thought to contribute to the successful results. Most authors feel that stable fibrous tissue forms in the joint space which may be instrumental in providing pain relief. This may act as an autologous interpositional arthroplasty. There may be some hyaline cartilage repair as well, as seen in Kajiwara's work. We feel that hinged distraction aids in the molding of this repair tissue and helps prevent joint stiffness.

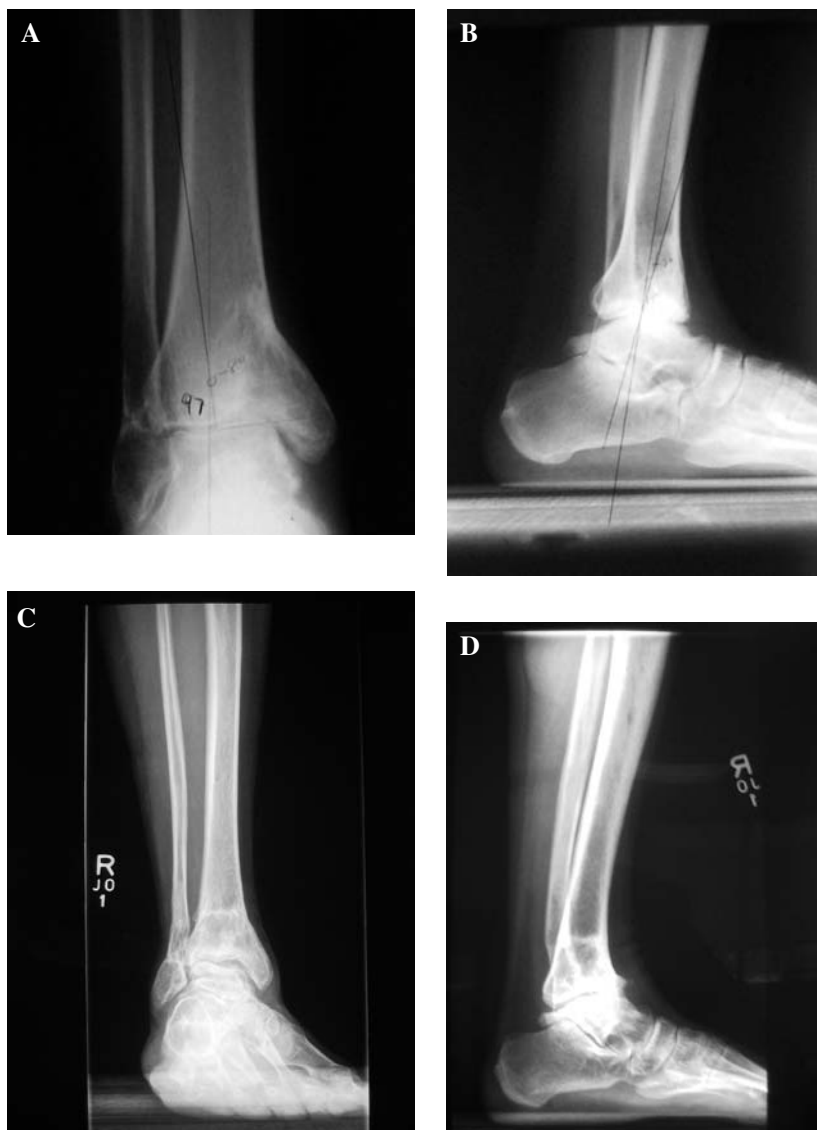Despite the lack of clarity on the exact mechanism behind the improved results after ankle distraction arthroplasty, the clinical improvement seen in our study and that of other published series is significant. Although it has been shown that patients with ankle arthritis can obtain function and pain improvement from non-articulated ankle distraction, our approach has been to implement a combination of techniques for managing ankle arthrosis to provide the patient with the best possible outcome. The procedures included arthrotomy, arthroscopy, TAL, and supramalleolar osteotomy, done in conjunction with the joint distraction. The benefit of such a combined treatment approach was to tailor treatment to each individual patient's needs instead of treating all patients with the same modality. Six patients had a distal tibial deformity from a malunion of a fracture that led to osteoarthritis of the ankle years later. These patients were treated with joint realignment via supramalleolar osteotomy to re-distribute the weightbearing forces to healthier areas of cartilage (a concept that has been used extensively for hip and knee arthritis). This was combined with joint distraction in an effort to optimize the cartilage in the damaged area. Patients who had an anterior osteophyte from the distal tibia and/or talar neck that was thought to be painful or blocking dorsiflexion were treated

with arthroscopic or open resection of osteophytes followed by distraction. Patients who had mechanical symptoms were treated with arthroscopic debridement of the joint followed by distraction arthroplasty. Patients who were found to have limited dorsiflexion and a tight heel cord underwent percutaneous tendo-Achilles lengthening followed by distraction. By combining all of these treatment modalities we believe optimal care was delivered to this group of patients. Every effort was made to improve the patients function and provide the optimal environment for cartilage repair. However, we are unable to separate the effect of the distraction from the additional procedures.

As a result of this combined treatment approach, significant improvement was seen in the average AOFAS scores. Some improvement was also seen in the SF-36 scores. These findings are encouraging for patients with ankle arthritis who were highly functional pre-injury and suggest that ankle distraction, when combined with other appropriate modalities, may obtain significant functional improvement. Our study results are similar to those previously published (Table 1). We have observed in nearly all cases that the positive effects of distraction are not immediate and tend to be realized over a long period of time ranging from 6 months to 2 years. It is only possible to speculate that time plays a large role in providing a stable soft tissue interposition.

We have observed a lasting increase in joint space in a few patients. While those patients have done well, others that did not have an increased joint space have also done well (Figure 6).

The importance of demonstrating a persistently distracted joint space after frame removal appears minimal. In addition, the results suggest that the range of movement of the ankle joint is not increased overall. Patients maintained the range



**Fig. 6:** Preoperative AP (A) and lateral (B) X-rays of ankle. AP (C) and lateral (D) X-rays at 5 years following distraction arthroplasty. X-rays show mild improvement in the joint space at 5 years postoperative.

**Table 1:** Literature review

Investigators	Study Design	Number	Gender	Age (y)	Followup	Outcome
van Valburg et al. (1995)	Retrospective	$n = 11$	4F/7 M	$35 \pm 13$	$20 \pm 6$ months	Pain decreased in all. Five were pain-free. ROM increased 55%. Joint width widening in 3 of 6.
van Valburg et al. (1999)	Prospective	$n = 17$	7F/10 M	$39.6 \pm 11.4$	2 years minimum	13/17 improved physical examination, function, pain score; 4/17 not improved.
Marijnissen et al. (2002)	Prospective	$n = 57$	32F/42 M	$44 \pm 11$	$2.8 \pm 0.3$ year	75% showed significant improvement in physical examination, function, and pain score

of movement they had preoperatively, but what changed was the arc of motion. All patients with equinus contracture were able to shift the arc of motion to a new and more functional starting point. Undoubtedly, the Achilles tendon lengthening improved the arc of motion acutely, but the frame was able to preserve this enhanced dorsiflexion over time and prevent recurrence.

It was hypothesized that younger patients would benefit more from ankle distraction than older patients. After careful analysis of the data age does not seem to be a significant factor in outcome. Somewhat surprisingly, the older patients (more than 60 years old) tended to have better outcomes than younger patients.

The results of this study confirm that ankle distraction is a promising treatment for severe ankle arthrosis, and helps to delay or obviate the need for fusion. To date only two of our patients in this series have needed to be revised to fusion. During the first 6 months after fixator removal those patients that were experiencing continued pain were encouraged to not despair as in most cases benefits from the procedure are not experienced for the first 6 months. After reaching 12 months, most were improved clinically and none were interested in arthrodesis. With the absence of successful disease modifying treatment and a predictable joint replacement prosthesis, distraction may prove to be a popular treatment in patients who wish to preserve the ankle joint movement and improve their function.

We feel that ankle distraction is a low-risk procedure that offers a promising solution to a very complex problem. The procedure is relatively simple and should be suitable for all foot and ankle surgeons who are familiar with Ilizarov fixator application. There are a few key elements of the procedure and aftercare that may improve function: The hinges need to be placed along Inman's axis to prevent uneven joint distraction through a range of motion and to preserve joint motion by evenly stretching the capsule. Avoid the use of a forefoot wire as this is very uncomfortable and discourages weightbearing. We do not place more than 5 to 6 mm of acute distraction across the ankle in the operating room. The remainder of the distraction, if needed, can be applied gradually during the short post-operative hospital stay. Start early range of motion exercises of the ankle to preserve mobility. A circular fixator may be superior to a monolateral frame as the latter delivers uneven distraction through cantilever mechanics, and the simple hinge of the monolateral frame is difficult to place along the ankle axis.

We are currently engaged in the prospective study looking at pre- and post-1-year MRI. Future developments in distraction arthroplasty may involve the use of adjuvant therapy

including the injection of iliac crest aspirate, platelet rich plasma, growth hormone, or viscosupplementation into the ankle joint during treatment.

## REFERENCES

1. **Inda, D; Blyakher, A; O'Malley, M; Rozbruch SR:** Distraction Arthroplasty for the Ankle Using the Ilizarov Frame. *Techniques in Foot and Ankle Surgery* 2(4):249–253, 2003. <http://dx.doi.org/10.1097/00132587-200312000-00005>
2. **Judet, R; Judet, T:** Arthrolyse et arthroplastie sous distracteur articulaire. *Rev. de chirurgie. Orthopedique*.64:353, 1978.
3. **Kajiwara, R; Ishida, O; Kawasaki, K; et al.:** Effective repair of a fresh osteochondral defect in the rabbit knee joint by articulated joint distraction following subchondral drilling. *J Orthop Res.* 23(4):909–15, 2005. <http://dx.doi.org/10.1016/j.orthres.2004.12.003>
4. **Karadam, B; Karatasun, V; Murat, N; Ozkal, S; Gunal, I:** No beneficial effects of joint distraction on early microscopical changes in osteoarthrotic knees. A study in rabbits. *Acta Orthop Scand.* 76(1):95–98, 2005. <http://dx.doi.org/10.1080/00016470510030391>
5. **Marijnissen AC, Van Roermund PM, Van Melkebeek J, Lafeber FP:** Clinical benefit of joint distraction in the treatment of ankleosteoarthritis. *Foot Ankle Clin.* 8(2):335–46, 2003. [http://dx.doi.org/10.1016/S1083-7515\(03\)00044-5](http://dx.doi.org/10.1016/S1083-7515(03)00044-5)
6. **Paley, D; Lamm, BM:** Ankle joint distraction. *Foot Ankle Clin.* 10(4):685–98, 2005. <http://dx.doi.org/10.1016/j.fcl.2005.06.010>
7. **Ploegmakers JJW, van Roermund PM, van Melkebeek J, et al.:** Prolonged clinical benefit from joint distraction in the treatment of ankle osteoarthritis. *J Osteoarthritis and Cartilage.* 13: 582–588, 2005. <http://dx.doi.org/10.1016/j.joca.2005.03.002>
8. **Saltzman, C; Buckwalter, J; Ankle arthritis:** emerging concepts and management strategies. *AAOS ICL.* 48:233–240, 1999.
9. **Thomas, R; Daniels, TR; Parker, K:** Gait analysis and functional outcomes following ankle arthrodesis for isolated ankle arthritis. *J Bone Joint Surg Am.* 88(3):526–35, 2006. <http://dx.doi.org/10.2106/JBJS.E.00521>
10. **Van Roermund, P; Lafeber, F; Marijnissen, A:** Joint distraction in the treatment of ankle osteoarthritis in: Rozbruch SR, Ilizarov S: *Limb Lengthening and Reconstruction Surgery*, Informa Healthcare, New York, 2007.
11. **Van Roermund, P; Lafeber, F; Marijnissen, A:** Joint distraction as an alternative for the treatment of osteoarthritis. *Foot Ankle Clinics* 7(3):515–27, 2002. [http://dx.doi.org/10.1016/S1083-7515\(02\)00027-X](http://dx.doi.org/10.1016/S1083-7515(02)00027-X)
12. **Van Valburg, A; van Roermund, P; Lammens, J:** Can Ilizarov joint distraction delay the need for an arthrodesis of the ankle? A preliminary report. *J Bone Joint Surg Br.* 77:720–725, 1995.
13. **Van Valburg, A, Van Roermund, P, Marijnissen, A:** Joint distraction in treatment of osteoarthritis: a two year followup of the ankle. *Osteoarthritis Cartilage.* 7:474–479, 1999. <http://dx.doi.org/10.1053/joca.1998.0242>
14. **Van Valburg, A; Van Roermund, P; Marijnissen, A; et al.:** Joint distraction in treatment of osteoarthritis (II): effects on cartilage in a canine model. *Osteoarthritis Cartilage* 8(1):1–8, 2000. <http://dx.doi.org/10.1053/joca.1999.0263>