Nephrol Dial Transplant (2002) 17: 1914–1920

Nephrology
Dialysis
Transplantation

Original Article

Karyomegalic nephropathy: an uncommon cause of progressive renal failure

Sunil Bhandari[1], Steven Kalowski[1], Paul Collett[1], Bridget E. Cooke[3], Peter Kerr[4], Ronald Newland[2], John Dowling[5] and John Horvath[1]

[1]Statewide Renal Services and [2]Department of Anatomical Pathology, Royal Prince Alfred and Concord Repatriation Hospitals, [3]Department Anatomical Pathology, Prince of Wales Hospital, Sydney, NSW, Department of Pathology [4]Alfred Hospital and [5]Monash Medical Centre, Melbourne, Victoria, Australia

Abstract

Background. Karyomegalic nephropathy, first identified in 1974, represents an increasingly recognized, but perhaps underdiagnosed condition associated with interstitial nephritis. It undoubtedly leads to end-stage renal disease requiring renal support.

Methods and results. We present a series of six cases of karyomegalic nephropathy. The age at diagnosis was 9–51 years, median 33 years. Impaired renal function, proteinuria, and haematuria were present in the majority of cases. Non-specific elevated liver enzymes were present in three cases. Two patients died soon after transplantation from overwhelming respiratory sepsis. The classical histological features of large, abnormal hyperchromatic nuclei with irregular outlines within epithelial cells were present in renal epithelial cells. Abnormality of DNA ploidy distributions compared with age- and sex-matched controls, and characterized by the presence of significant numbers of cells with high ploidy values was present in cases but not in controls. Mitotic figures were absent. Proliferation markers, Ki-67 and proliferating cell nuclear antigen/cyclin were not significantly elevated in those cases examined. Human leukocyte antigen analysis did not support the clustering of A9 or B35, in the cases or their families.

Conclusions. The presence of significant renal impairment, positive urine sediment, abnormal liver enzymes, and early age of onset should alert one to the presence of karyomegalic nephropathy. It represents an underdiagnosed disorder with a high degree of ploidy indicative of karyotypic abnormality.

Keywords: haematuria; interstitial nephritis; karyomegaly; nephropathy; ploidy; proteinuria

Correspondence and offprint requests to: Dr S. Bhandari, Hull and East Yorkshire Hospitals NHS Trust, Department of Renal Medicine, Hull Royal Infirmary, Kingston upon Hull, East Yorkshire HU3 2JZ, UK. Email: sunil.bhandari@medix-uk.com

Introduction

Karyomegalic nephropathy was first identified in 1974 by Burry [1] in a 22-year-old female who died from liver-cell carcinoma. Mihatsch *et al.* [2] subsequently described the disorder in 1979 when they reported three patients with similar clinical and pathological findings. From these observations, he proposed a new disease syndrome. Reports of eight additional cases with similar findings have been cited in the literature [3–7]. Classically patients present with a history of recurrent upper respiratory infections and progressive renal failure. Extra-renal manifestations are, however, clinically uncommon, although karyomegalic cells have been identified in numerous tissues including brain astrocytes, intestinal smooth muscle, Schwann cells of peripheral nerves, and bile duct epithelium. Transient elevations in liver enzymes are also seen [7]. Histologically, the presence of interstitial nephritis in conjunction with atypical epithelial cell and nuclear polymorphism, predominantly of tubular cells, is characteristic. The absence of other environmental factors associated with interstitial nephritis (non-steroidal anti-inflammatory agents and heavy metals) and other glomerular disorders, are suggestive of karyomegalic nephropathy.

We report here a further six cases of renal failure due to karyomegalic nephropathy. Two of the patients are siblings, who received cadaveric renal transplants.

Case 1

A 50-year-old woman was referred with asymptomatic proteinuria and glomerular haematuria. There was no notable past medical history; in particular there was no history suggestive of recurrent upper-respiratory-tract infections during infancy. There was a family

© 2002 European Renal Association–European Dialysis and Transplant Association

Downloaded from https://academic.oup.com/ndt/article/17/11/1914/1896612 by guest on 21 August 2022

history of renal disease (see case 3). The patient's renal function began to decline at the age of 30 years. There was no known exposure to heavy metals, including lead or bismuth.

Results of urinalysis revealed 1.0–1.5 g/day of proteinuria with approximately 50 000 glomerular red blood cells/ml of urine with a moderate number of granular casts. Blood pressure was 160/100 mmHg, creatinine was 250 μmol/l, urea 24.3 mmol/l, and creatinine clearance 45 ml/min. Antinuclear antibodies (ANA), anti-double stranded DNA antibodies were not detected and antineutrophilic cytoplasmic antibody (ANCA) titre was negative. Complement concentrations were within normal limits. A renal ultrasound revealed two kidneys of 10 cm in length with smooth cortical outlines. Percutaneous renal biopsy was performed and the results are detailed below. Serology for hepatitis B (hepatitis surface antigen) and C (hepatitis antibody), HIV, Epstein–Barr virus (EBV), and cytomegalovirus (CMV) was negative.

The patient progressed to end-stage renal failure and received a cadaveric renal transplant at the age of 55 years. Her post-transplantation course was complicated by severe haemolytic–uraemic syndrome (HUS) presumed to be secondary to cyclosporin administration. Cyclosporin was discontinued and plasma exchange commenced, with subsequent recovery from the HUS. Unfortunately, the patient later died from overwhelming Legionella pneumonia. At autopsy, except for the native kidneys, there was no evidence of karyomegalic changes in any organs, including the transplanted kidney.

Case 2

A 21-year-old man was referred because of impaired renal function that was discovered after he had suffered a viral illness with an associated elevation of liver enzymes, the latter of which resolved spontaneously after 2 weeks. He had a complex childhood history consisting of chronic right leg lymphoedema secondary to absent lymphatics, petit mal epilepsy from the age of 5 to 7 years, pneumonia at the age of 6 years, and congenital fusion of two spinal vertebrae. Interestingly one of his three brothers was found to have a similar spinal vertebral fusion, but there was no family history of overt renal disease.

Urinalysis indicated proteinuria but no haematuria. The patient had 0.71 g/day of proteinuria. His blood pressure was 125/75 mmHg. Serum creatinine was 190 μmol/l with a creatinine clearance of 35 ml/min. Immunological tests, including ANA, anti-double-stranded DNA antibodies, immunoglobulins, and complements (C3 and C4) were all within normal limits. Serology for toxoplasmosis, EBV, CMV, hepatitis B and C, and HIV were negative. Renal ultrasound scan revealed reduced renal size with echogenic cortices. Percutaneous renal biopsy was performed and the results are detailed below.

Case 3

A 38-year-old male, the brother of case 1, was referred for evaluation of end-stage renal failure in 1976. Blood pressure was 145/90 mmHg on no medication. Investigations revealed proteinuria and haematuria and small kidneys. Immunology was negative. Hepatitis B, C, and HIV serology was negative. Cytomegalovirus serology was consistent with past infection. Renal biopsy was not performed and a presumptive diagnosis of chronic glomerulonephritis was made.

The patient underwent cadaveric renal transplantation 1 year later. Two weeks after transplantation he died from overwhelming bronchopneumonia. An autopsy of the transplanted kidney did not reveal any evidence of rejection or karyomegaly, but histology of the native kidneys, which were shrunken, confirmed a primary diagnosis of karyomegalic interstitial nephritis as the cause of the renal failure (see Results section).

Case 4

A 29-year-old Melanesian man presented with proteinuria, microscopic haematuria, and a creatinine of 200 μmol/l. He had a history of childhood asthma and had developed a spontaneous left pneumothorax following an upper-respiratory-tract infection. There was no family history of renal disease. He was normotensive 125/70 mmHg. Urine analysis had 5 red cells/μl, with 0.1 g/day of protein and a creatinine clearance of 60 ml/min. Immunology was negative. Serology results were not available. Renal ultrasound scan showed thinning of the right renal cortex. Renal biopsy confirmed karyomegalic nephropathy. He was, however, lost to follow-up.

Case 5

A 9-year-old girl presented with asymptomatic microscopic haematuria (45 red cells/μl) and normal renal function. There was no known family history of renal disease. She had mild asthma, and blood pressure was 100/60 mmHg. Ultrasound scan indicated normal kidneys. Renal biopsy indicated karyomegalic nephropathy. Unfortunately, she was lost to follow-up.

Case 6

A 37-year-old woman presented with haematuria (20 glomerular red cells/μl), proteinuria (0.25 g/day), and renal impairment (creatinine 193 μmol/l and creatinine clearance of 47 ml/min). Her brother had died at the age of 18 years from renal disease and her sister had died at the age of 35 years from nephritis. A cousin also had renal disease. The patient was normotensive, 125/85 mmHg. Immunology including complement levels, C-reactive protein, ANA, ANCA,

Downloaded from https://academic.oup.com/ndt/article/17/11/1914/1896612 by guest on 21 August 2022

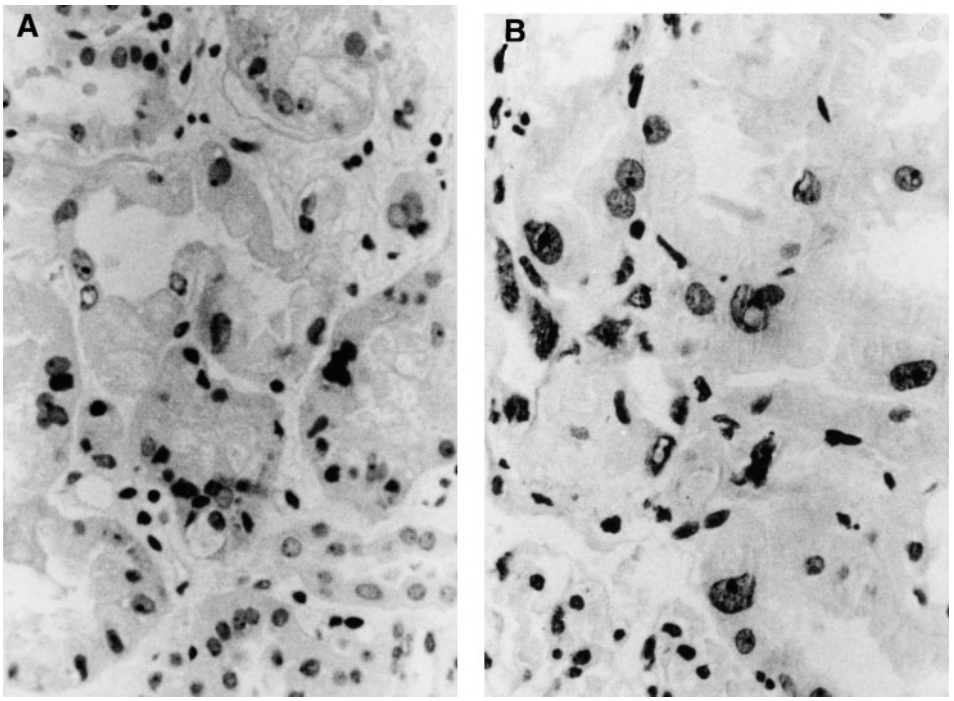

Fig. 1. Cortical tubules from two of the cases with epithelial cells containing enlarged and pleomorphic nuclei (×420).

anti-glomerular basement membrane antibody, and protein electrophoresis were negative. Renal ultrasound showed kidneys of 8 and 7 cm. Biopsy confirmed karyomegalic nephropathy. The patient's renal function continued to deteriorate, but at present she remains pre-dialytic.

Methods

Diagnostic criteria for karyomegalic nephropathy were the presence of enlarged or multiple nuclei within tubular cells without tubular necrosis, and an overall reduction in tubular cells with tubular atrophy and interstitial fibrosis. Conventional staining methods were used. Haematoxylin and eosin (H&E) sections, 3 μm thick, were prepared from formalin-fixed, paraffin-embedded tissue in all cases. Immunofluorescence studies for IgA, IgG, IgM, C3, and fibrin were performed using fluorescence-labelled antisera applied to 6-μm cryostat sections.

Ploidy studies were performed on cases 1, 3, 4, and 5 using image analysis cytometry. Sections of paraffin-embedded tissue were cut at 6 μm and were stained for DNA analysis using a Feulgen stain technique [8,9]. The corrected diploid (2c) nuclear integrated optical density (IOD) was measured and used to determine the relative DNA content of the individual mononuclear diagnostic cells, from which DNA distribution histograms were constructed. Three age- and sex-matched adult renal biopsies, which were within normal limits by light-microscopy, were analysed as case controls, demonstrating normal ploidy patterns. DNA histograms were generated for these cases [9,10].

Nuclear-proliferation-associated antigens Ki-67 and proliferating cell nuclear antigen (PCNA) were estimated. The monoclonal antibodies PC10 (Dako, Copenhagen, Denmark) and MIB-1 (Dianova, Hamburg, Germany) were used for PCNA and Ki-67 detection respectively, from immunostaining using streptavidin–biotin peroxidase. Results were compared with controls from normal kidney biopsies.

Results

Light microscopy

Biopsies from native kidney tissue displayed changes typical of karyomegalic nephropathy. There was no evidence of amyloid or crescentic changes in glomeruli. Some glomeruli were completely sclerosed but no enlarged nuclei were visible in glomeruli. A significant number of epithelial cells lining the tubules in both cortex and medulla showed nuclear enlargement (Figures 1, 2). Coincidentally some of the tubular epithelial cells had more than one nucleus. The nuclei were hyperchromatic and had irregular outlines. There was no evidence of tubular necrosis (attenuated epithelium or mitotic activity). There was patchy interstitial fibrosis around atrophic tubules. Blood vessels were essentially normal in most of the biopsies, while others showed hypertensive changes. Presence of interstitial fibrosis and numerous abnormal cells were suggestive of an adverse renal prognosis in this case series.

Immunofluorescence

Immunofluorescence staining of glomeruli for IgG, IgA, and IgM was negative, as was staining for C1q, C3, C4, fibrinogen, and kappa and lambda light chains

Downloaded from https://academic.oup.com/ndt/article/17/11/1914/1896612 by guest on 21 August 2022

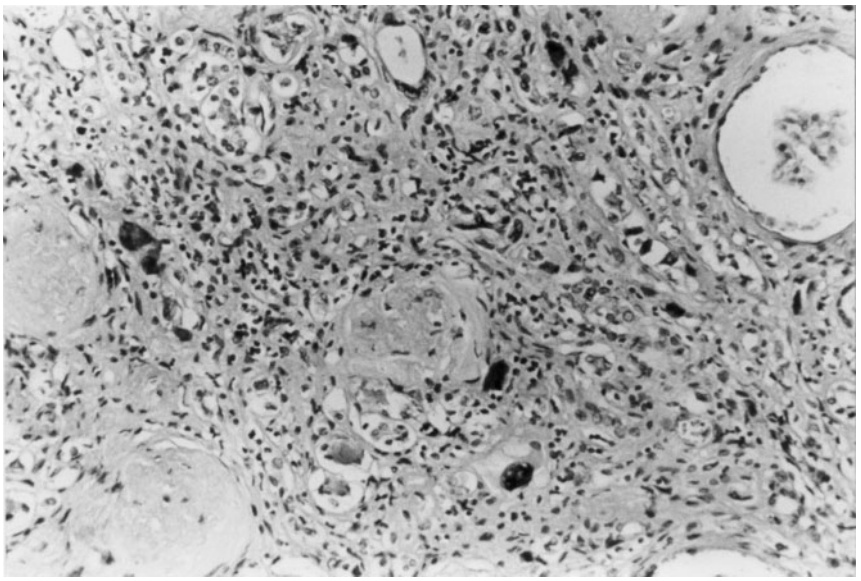

Fig. 2. Cortical tubules containing enlarged and pleomorphic nuclei. Several glomeruli within frame showing sclerosis (×500).

for cases 2, 4, 5, and 6. For case 1, IgA and C3 were weakly positive. No data were available for case 3. Nuclear-proliferation-associated antigens Ki-67 and PCNA were performed on cases 1, 2 and 5. There was positive staining in tubular epithelial cells only. This was, however, similar to control samples and therefore not suggestive of mitosis or cytomegaly.

Electron microscopy

Electron microscopy was performed on cases 1, 2, 4 and 6. In cases 1, 2 and 6, the glomeruli showed mild mesangial thickening. Again, abnormally large nuclei, often with deep notches, were present in epithelial cells lining Bowman's capsule and many tubules. There was an irregular distribution of chromatin within the enlarged nuclei. Tubular epithelial nuclei (12–26 μm) were larger than those seen in normal renal biopsy samples (4–7 μm). No evidence of cytomegaly was seen in the tubular epithelium. Patchy fibrosis was again demonstrated. No intranuclear inclusions or virus-like particles were identified and no electron-dense deposits were seen. In particular, no changes suggestive of Alport's syndrome were present. Case 4 consisted of medulla only.

Ploidy analysis

Cases 1, 3, 4 and 5 (all of those tested) showed abnormality of their DNA ploidy distributions characterized by significant numbers of cells with very high ploidy values (up to 81c in case one, Figures 3–6). In contrast, three normal case controls analysed simultaneously were characterized by diploid DNA distribution patterns (Figure 7). The analysis indicated that the enlarged hyperchromatic nuclei were polyploid.

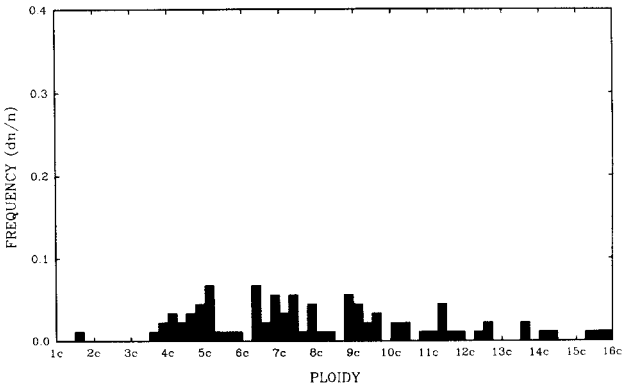

Fig. 3. Case 1. DNA ploidy histogram demonstrating extreme abnormality with variation in ploidy values. The x-axis represents ploidy with 2c being the normal dipoid point. The y-axis is a proportional frequency of cells measured, i.e. the number of cells with a particular ploidy value is expressed as a percentage of the total number of cells examined. Thirteen cells had ploidy >16c with a highest ploidy of 81c (data not shown).

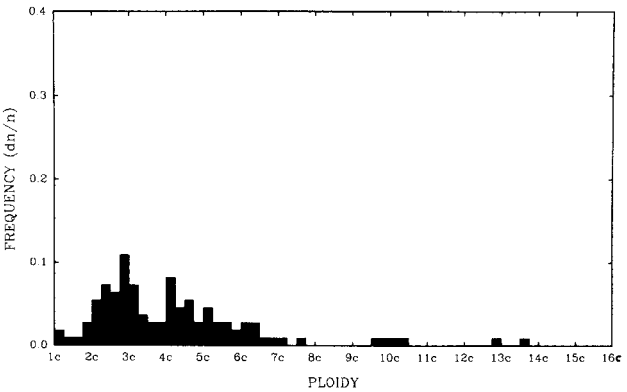

Fig. 4. Case 3. DNA ploidy histogram demonstrating extreme abnormality with variation in ploidy values.

Downloaded from https://academic.oup.com/ndt/article/17/11/1914/1896612 by guest on 21 August 2022

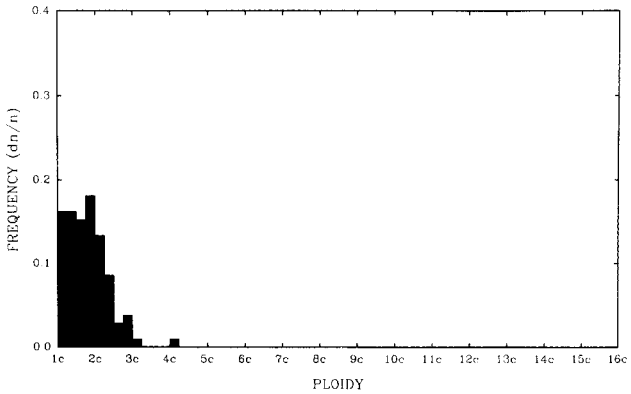

Fig. 5. Case 4. DNA ploidy histogram demonstrating extreme abnormality with variation in ploidy values. The majority of the cells are within the normal range (2c–4c); however, there are significant numbers of cells which are aneuploid (3c) and a few with higher ploidy values (data not shown).

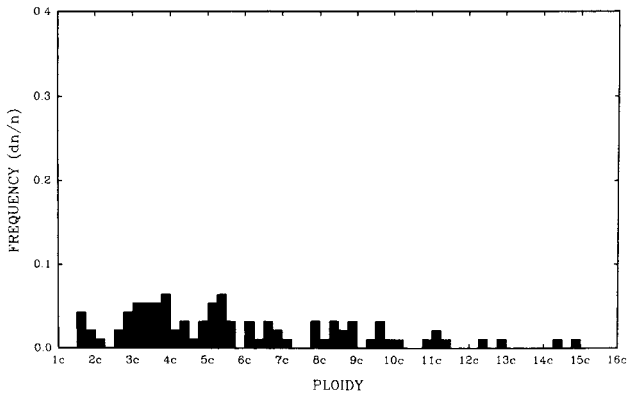

Fig. 6. Case 5. DNA ploidy histogram demonstrating extreme abnormality with variation in ploidy values. Seven cells had ploidy >16c with a highest ploidy of 63c (data not shown).

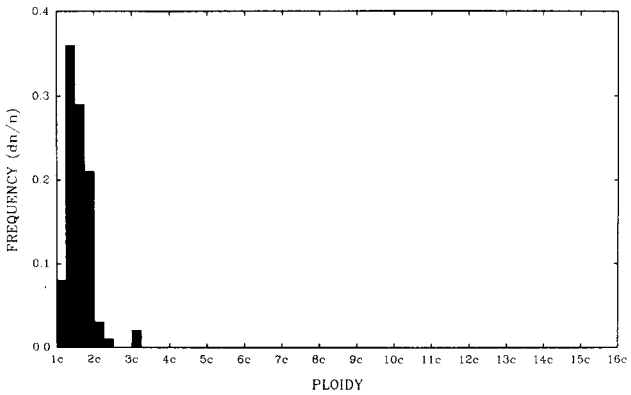

Fig. 7. Control case histogram demonstrating a normal diploid population.

Family investigations and HLA typing

Examination of the human leukocyte antigen (HLA) subtypes of cases 1 and 3 from transplantation data was negative for both A9 and B35. There was no clinical history suggestive of karyomegaly in the other three siblings or parents of case 2 (Figure 8). One other sibling had a trace of proteinuria, and one had slightly deranged liver function tests (AST 43 U/l, normal 0–40; ALT 115 U/l, normal 0–40; GGT 49 U/l, normal 0–45). The father also had slight deranged liver function tests (AST 25 U/l, ALT 57 U/l, GGT 49 U/l). All except the patient had normal serum creatinine values and normal urine cytology. HLA analysis did not reveal the presence of A9 and B35 in these parents or siblings (Table 1); however, interestingly, they were all HLA identical, with A2, B57, and DR4 being similar to the parent with slightly deranged liver function tests.

DT	A29	A30	B18	B44	DR7	DR11
RT	A1	A2	B37	B57	DR4	DR10
DT_j	**A2**	**A29**	**B44**	**B57**	**DR4**	**DR7**
CT	A1	A30	B18	B37	DR10	DR11
MT	A2	A29	B44	B57	DR4	DR7
JT	A2	A29	B44	B57	DR4	DR7

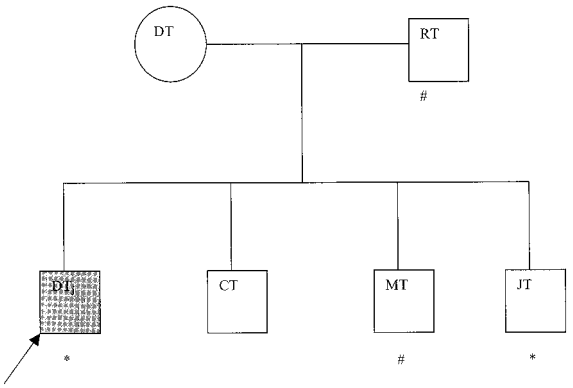

Fig. 8. Pedigree of the family of case no. 2. *Those with abnormal enzymes; #those with abnormal urine sediment. HLA analysis is detailed according to patient initials (top).

Discussion

Although we present a relatively large case series, the prevalence of this disorder remains less than 1% of all biopsies examined. This however may be an underestimate of the true prevalence as biopsies may have failed to identify or recognize this pathology as a distinct unique entity. These six additional cases of karyomegalic nephropathy, five with significant renal impairment on presentation, and certainly four with progressive renal dysfunction highlight further this uncommon condition. The histological changes in the kidney biopsies in all patients consisted of marked enlargement and hyperchromatic nuclei in tubular cells of the nephron with associated interstitial fibrosis surrounding atrophic tubules. No history of exposure to toxins, irradiation, or alkylating agents was evident.

Downloaded from https://academic.oup.com/ndt/article/17/11/1914/1896612 by guest on 21 August 2022

Table 1. HLA typing of cases identified to date from the available published data

Burry 1974 [1] (1 case)							
No data available							
Sclare 1976 [3] (1 case)							
No data available							
Mihatsch *et al.* 1979 [2] (3 cases)							
A2	A9	B21	B35				
A2	A9	B21	B35				
A9		B35					
Spoendlin *et al.* 1995 [5] (4 cases)							
A9		B35					
A9		B35					
A2	A26	B39	B39	DR2	DR4		
A9	A11	B7	B52	DR2	DR13		
Godin *et al.* [6] 1996 (2 cases)							
A9	A24		B35				
A9	A24		B35				
Vadiaka 1998 [7] (1 case)							
A1	A19	B49	B52	DR4	DR4		
Bhandari *et al.*, this paper (6 cases)							
A24	A32	B14	B18	DR7	DR15	DRW51	DRW53
A2	A29	B44	B57	DR4	DR7		
A1	A2	B8	B15				
Cases 4, 5 and 6—no data							

The clinical picture of karyomegalic interstitial nephritis has been associated with recurrent upper-respiratory infections in addition to symptoms of chronic renal impairment beginning in the third decade of life. However, in three of our patients there was no history of recurrent infections, although two died of pneumonia post-transplantation. There was also, to the best of our knowledge, no evidence of karyomegaly in organs other than the native kidney. Sclare [3], who described a pneumopathy in a patient, failed to identify pulmonary karyomegalic changes at autopsy. Vadiaka *et al.* [7] noted a transient rise in liver enzymes but no specific pathology on liver biopsy. The significance of these cells, therefore, in other tissues including brain astrocytes, intestinal smooth-muscle cells, Schwann cells of peripheral nerves, and bile-duct epithelium, when present, remains undetermined, considering no clinical sequelae have been identified.

The major changes of chronic interstitial nephritis that occur in association with karyomegaly were seen, but no other specific causes of interstitial nephritis could be detected. No abnormal changes were seen in the glomerular basement membranes to suggest Alport's syndrome, and exogenous factors causing karyomegaly, such as heavy metals (busulphan and lead), non-steroidal anti-inflammatory agents, and lithium were ruled out by the patients' histories and two of the six patients' biochemical analyses. Lead nephropathy although prevalent in Northern Australia is uncommon in South and Eastern Australia. Mycotoxins such as ochratoxin were as far as possible ruled out from case histories (patients denied Chinese herb ingestion) and in some cases blood measurement, but this potential aetiology remains difficult to completely exclude.

Two of the patients died from respiratory infections soon after renal transplantation. Immunodeficiency, which was clearly caused by the immunosuppression used following transplantation, may have been compounded by the underlying renal disease, but it is not known if an immunodeficiency responsible for increased susceptibility to infections is part of the defect. Karyomegaly has been associated with impairment of cell division. Examination of the nuclear proliferation structures Ki-67 and PCNA/cyclin, if increased, suggest inhibition of mitosis of these cells. Some have found the presence of Ki-67 [5], while more recently others have not [7]. We were unable to identify significant increased levels of the proliferation markers in those cases examined. The high ploidy values are indicative of an increased degree of karyotypic abnormality, and are recognized as markers of malignant potential and/or poor prognosis in a number of disease states. Only one case appears to have has been associated with carcinoma [1]. In all the cases examined and in particular cases 3 and 4 there was an extremely uncommon distribution of cell ploidy values. This occurrence of polyploidy may be due to mitotic polyploidization as suggested previously, a G2 block, or cell fusion [12]. A G2 block would, however, appear to be the most likely explanation of the histological findings in our case series, as it would account for the absence of mitotic figures and multinucleation, which is evident in cell fusion. However, data are incomplete for the nuclear proliferation structures and possibly more than one mechanism is occurring either simultaneously or independently.

Examination of the HLA subtypes from previous cases identifies A9 and B35 as potential candidate sites for polymorphic variation leading to the disorder. HLA A9 has been identified in eight of the cases reported, while B35 was present in seven. In the three families reported A2, A24, and B21 also seem to be common HLA subtypes. Indeed the prevalence of A9 and B35 in association is uncommon and may present

Downloaded from https://academic.oup.com/ndt/article/17/11/1914/1896612 by guest on 21 August 2022

strong evidence of an inherited defect. Our data on HLA analysis and family history was limited. HLA analysis of those examined in our cases do not lend support to the clustering of cases with the presence of A9 and B35 but suggests that these haplotypes may not in fact confer increased susceptibility. The occurrence of this rare disease in two siblings suggests an inherited basis to this disorder although the HLA association was absent as also noted by Vadiaka *et al.* [7]. A sporadic form in those lacking the HLA subtype may exist. However, the report of two cases in siblings with ochratoxin toxicity and a similar HLA subtype suggests that the HLA findings may merely be coincidental in other cases [6]. Exposure to an exogenous toxin in addition to an inherited susceptibility (a two-hit model of disease) may lead to the activation of the disease process in some of the cases. Alternatively, various polymorphisms of alleles on certain chromosomes may be responsible.

The pathophysiology of this rare disorder remains obscure. In the present series as in others, chronic interstitial nephritis occurred in association with karyomegaly, while other non-specific causes of interstitial nephritis were as far as possible excluded. A history of analgesic, heavy metal, and herbal exposure was absent in those patients asked. Mycotoxins (ochratoxin), which are prevalent in the Balkan region, are rare in Australia. It is prevalent as a contaminant in many foodstuffs including green coffee, fish, and pigs and remains very stable even during refinement processes like brewing or roasting. It tends to affect the collecting ducts, leading to a reduction in urine-concentrating ability and subsequent reduced renal blood flow. This aetiology, however, cannot be entirely ruled out as a primary inducing event. Advanced glomerulopathy is unlikely in view of the negative immunology and non-specific immunohistological findings, and the negative electron microscopy for glomerular basement membrane disease. We believe that the morphological alterations in the renal epithelia could result from in initial insult, either chemical or viral, which in susceptible individuals leads to disruption of the cells. Such viruses could cause transient changes in liver enzymes and immunodeficiency, as noted in several cases, and perhaps lead to cellular defects from production of aberrant mutations, leading to a G2 block and cell disruption. The lack of a relationship of this disease entity to age may reinforce the possibility of an environmental influence within the family causing clustering. The increased ploidy analysis with no obvious inhibition of mitosis would also lend towards a mutational or genetic defect. Sporadic cases may also occur.

Acknowledgements. This paper has been presented at the Australian and New Zealand Renal Society.

References

1. Burry AF. Extreme dysplasia in renal epithelium of a young woman dying from hepatocarcinoma. *J Pathol* 1974; 113: 147–150
2. Mihatsch MJ, Gudat F, Zollinger HU *et al.* Systemic karyomegaly associated with chronic interstitial nephritis. A new disease entity. *Clin Nephrol* 1979; 12: 54–62
3. Sclare G. A case of unexplained karyomegaly. *Beitr Pathol Bd* 1976; 157: 301–306
4. Moch H, Spoendlin M, Schmassmann A, Mihatsch MJ. Systemic karyomegaly with chronic interstitial nephritis. Discussion of the disease picture based on an autopsy case. *Pathologe* 1994; 15: 44–48
5. Spoendlin M, Moch H, Brunner F *et al.* Karyomegalic interstitial nephritis: further support for a distinct entity and evidence for a genetic defect. *Am J Kidney Dis* 1995; 25: 242–252
6. Godin M, Francois A, Roy FL *et al.* Karyomegalic interstitial nephritis. *Am J Kidney Dis* 1996; 27: 166
7. Vadiaka M, Sotsiou F, Koufos C. A case of systemic karyomegaly associated with interstitial nephritis. *Ann Med Interne (Paris)* 1998; 149: 291–294
8. Shulte E. Haematoxylin and the Feulgen reagent in nuclear staining. In: Boon ME, Kok LP, eds. *Standardization and Quantification of Diagnostic Staining in Cytology*. Coulomb Press, Leyden, Netherlands, 1986: 15–26
9. Lockart RZ, Pezzella KM, Toy ST. Features independent of stain intensity for evaluation Feulgen-stained cells. *Anal Quant Cytol Histol* 1984; 6: 105–111
10. Weid GL, Bartels PH, Bibbo M, Dytch HE. Image analysis in quantitative cytopathology and histopathology. *Hum Pathol* 1984; 20: 549–571
11. Mantle PG, McHugh KM, Adatia R *et al.* Persistent karyomegaly caused by Penicillium nephrotoxins in the rat. *Proc R Soc Lond B Biol Sci* 1991; 246: 251–259
12. Fujimoto Y, Oyamada M, Hattori A *et al.* Accumulation of abnormality high ploid nuclei in the liver of LEC rats developing spontaneous hepatitis. *Jpn J Cancer Res* 1989; 80: 45–50

Received for publication: 28.8.01
Accepted in revised form: 12.6.02

Downloaded from https://academic.oup.com/ndt/article/17/11/1914/1896612 by guest on 21 August 2022