



FIGURE 1. Photomicrograph of the myocardium of an elephant with diffuse acute myocarditis. There is edema of the interstitium and a mixed infiltration of polymorphonuclear leucocytes, lymphocytes and histiocytes. H&E, $\times 200$.

al., 1977, *J. Am. Vet. Med. Assoc.* 171: 902–904). That incident also involved African elephants, but the lesions described were more of a nonsuppurative myocar-

ditis typical of the subacute to chronic disease associated with EMCV infection in grower pigs (Acland and Littlejohns, 1975, *Aust. Vet. J.* 51: 409–415).

Journal of Wildlife Diseases, 23(1), 1987, pp. 171–172
© Wildlife Disease Association 1987

Kyphosis in the Marsh Rice Rat (*Oryzomys palustris*)

W. David Webster, Department of Biological Sciences, University of North Carolina at Wilmington, Wilmington, North Carolina 28403, USA

Genetic kyphosis is an autosomal recessive abnormality of the spine first described in domestic laboratory mice (*Mus musculus*) by Dickinson and Meikle (1973, *Lancet* 1: 1186). Mice homozygous for the condition exhibit progressive erosion of the

thoracic vertebrae, resulting in an S-shaped dorsal kyphosis commonly known as “hunchback” or “humpback.” The defect worsens with age; respiration is impaired, feeding is hindered, adult body weight is reduced by as much as 30%, and fecundity decreases. Recessive homozygosity can be detected in mice not yet weaned by their defective “placing re-

Received for publication 13 August 1985.

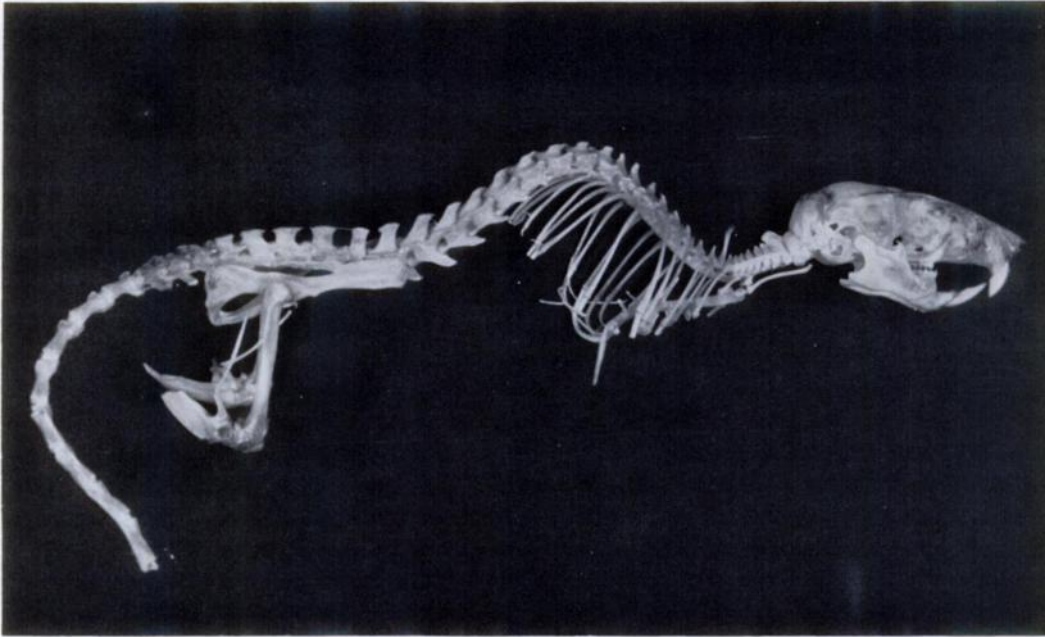


FIGURE 1. Lateral view of skeleton of a marsh rice rat from Baldhead Island, North Carolina, with kyphosis of the spine.

flex." When held vertically by the tail and lowered to a horizontal surface, affected mice land on their noses rather than on outstretched forelimbs since they cannot retroflex their heads.

A marsh rice rat (*Oryzomys p. palustris*) was collected on Baldhead Island, Brunswick County, North Carolina, on 13 December 1980, which had a moderately-developed kyphosis in thoracic vertebrae 4-9 (Fig. 1). This specimen, aged as a subadult by its partially obliterated basisphenoid-basioccipital suture but relatively unworn postcanine teeth, did not have scoliosis of the vertebral column. The weight of this individual did not differ significantly from that of other subadults, indicating that the defect had not reached the stage of seriously debilitating the animal.

Vertebral deformities such as kyphosis and scoliosis can be inherited or result from collagenic abnormalities or mechanical alterations (Woodward and Mont-

gomery, 1978, *In Pathology of Laboratory Animals*, Benirschke et al. (eds.), Springer-Verlag, New York, pp. 663-887). The kyphosis reported herein did not result from trauma; osteophytosis of the intervertebral discs, spondylosis of the vertebrae, and collagen deformities (such as Ehlers-Danlos and Marfan's syndromes) were not evident. Seventeen additional *Oryzomys* were collected on Baldhead Island in the months of December (1980), March (1981), June (1981), and September (1981), and none exhibited kyphosis of the spine. Regardless of its etiology, kyphosis definitely occurs in free-ranging rodents as well as domesticated, lab-reared ones.

Funding was provided, in part, by a grant to Paul E. Hosier (Sea Grant No. NA 79AA-D-00048). This specimen (UNC-W 824) is deposited in the Vertebrate Collections of the University of North Carolina at Wilmington.