

## Large Bowel Obstruction Caused by Adhesions without Previous Abdominal Surgery: Two Case Reports

A.A. Munyika, E. Muguti, D. Muchuweti.

Parirenyatwa Group of Hospitals, Department of surgery, University of Zimbabwe, Harare

*Correspondence to:* Dr. A.A. Munyika, Email: mbwale@yahoo.com

**Background:** Large bowel obstruction is rarely caused by adhesions. To our knowledge, the few cases reported in literature are secondary to previous abdomino-pelvic surgery, and are in female patients.

**Case Reports:** We report two cases of large bowel obstruction due to adhesions in males with no previous abdominal surgery. The first case was a 73 years old male previously well, who presented with a one week history of abdominal colicky pain with nausea. Initially this patient was thought to have symptomatic gallstones as a result of an ultrasound scan report. Consequently, a decision to take the patient for laparoscopic cholecystectomy was reached. Due to difficulties in achieving pneumoperitoneum, a laparotomy was done; the patient was found to have a fibrous band across transverse colon causing obstruction. The second case was a 61 years old male, known diabetic and hypertensive, who presented with epigastric pain, nausea, vomiting and constipation. Abdominal X-rays demonstrated large bowel obstruction. At laparotomy, this patient was found to have adhesions causing sigmoid colon obstruction.

**Conclusion:** In this paper, we demonstrate the rarity of large bowel obstruction secondary to adhesions especially in a virgin abdomen, emphasize the importance of good radiological expertise, and highlight the need to consider adhesions as a very rare but possible cause of large bowel obstruction.

### Introduction

About a century ago, the commonest causes of small bowel obstruction were incarcerated hernia in the United States, accounting for more than half of the cases<sup>1</sup>. With the discovery of anaesthesia and antiseptic techniques, elective repair of hernias became the norm, and post-operative adhesion became the commonest cause of small bowel obstruction<sup>1</sup>. The causes of large bowel obstruction have remained the same over the decades, being sigmoid volvulus and malignancy<sup>2</sup>. Other causes include diverticulitis, Inflammatory Bowel Disease, hernias, strictures, intussusceptions and impaction<sup>2</sup>. Large bowel obstruction caused by adhesions is a very rare occurrence, with only a few cases reported in literature. Large bowel obstruction due to adhesions have been reported in patients who previously had intra-abdominal operations, especially in women who had pelvic surgery<sup>2</sup>, but to our knowledge no case have been reported in patients without antecedent abdominal-pelvic surgery. We report two cases of large bowel obstruction secondary to adhesions in two male patients without previous abdominal surgery.

### Case Reports

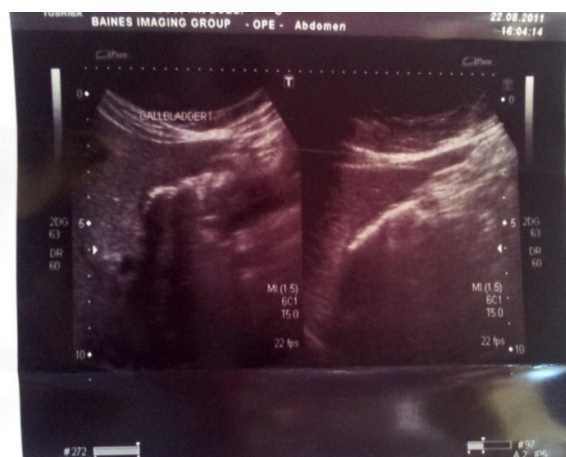#### Case 1.

A 73-years-old male presented with 1 week history of colicky lower abdominal pain and nausea with no vomiting. The pain was worse after taking meals and he would often feel epigastric fullness after meals. He reported normal stool pattern. He was previously well, with no reported history of using chronic medications such as NSAIDs, and also no previous surgical history. He did not smoke and did not drink alcohol. He did not have any known allergies.

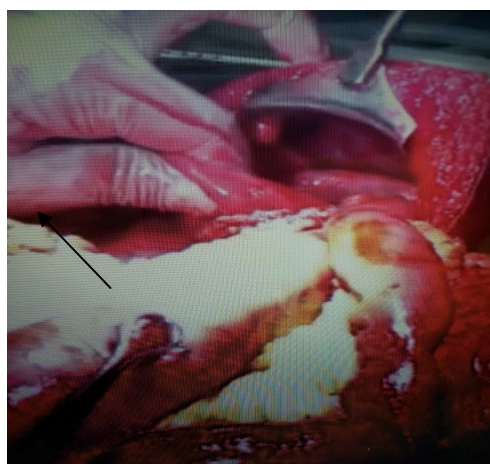
On physical examination, he was ill looking with a blood pressure of 140/95, pulse of 100 and low grade pyrexia of 37.6 degrees. He was not in any respiratory distress, and he had good heart sounds. His abdomen was soft, moderately distended with localized epigastric tenderness on palpation and slightly increased bowel sounds. The hernia sites were normal. There was no peritonism, and the rectal examination revealed stools present in the rectum and normal tone with no palpable masses.

The complete blood count was normal, so were the urea and electrolytes and liver function tests. Abdominal X-rays revealed gaseous distension of small and large bowel, with air present in the rectum. An abdominal ultrasound scan showed multiple gall stones, suggestive of cholelithiasis, but with normal wall thickness and no pericholecystic fluid collection (Figure 1). Intra and extra-hepatic ducts were normal.

A diagnosis of symptomatic gallstones was made, and the patient was taken for a laparoscopic cholecystectomy. Upon introducing the camera port, the abdomen was noted to be filled with distended loops of large bowel and pneumoperitoneum could not be achieved. An intraoperative decision to convert to a laparotomy was made. The gall bladder was normal with no calculi. There was an omental adhesive band crossing mid transverse colon attaching to the anterior abdominal wall and causing transverse colon obstruction (photo 2). The hepatic flexure was found to be filled with stool, and the colon distal to the obstructive band was small in comparison to the proximal colon. Further exploration revealed normal intra-abdominal organs. The obstructive adhesive band was divided, a biopsy taken, and the abdomen closed in layers. Histology confirmed it was adhesions. The patient had an uneventful post-operative recovery and was discharged home on day 5. An upper esophago-gastro-duodenoscopy done 2 months later revealed mild gastritis with random biopsies which showed *Helicobacter* gastritis and duodenitis. The patient was successfully treated with triple therapy ( Omeprazole, amoxicillin, metronidazole).



**Figure 1.** Ultrasound scan reported to be showing gallstones in the gall bladder



**Figure 2.** Laparotomy showing an adhesive band across transverse colon.

**Case 2**

A 61-years-old male presented with a 5 days history of epigastric pain, abdominal distension, nausea and vomiting, and constipation. He had reported altered bowel habits for the past year with episodes of constipation but no reports on the use of laxatives. He was a known diabetic on metformin 500mg tds and glibenclamide 2.5mg qid. He is also hypertensive on nifedipine 20mg daily. He had no previous surgical history and he didn't smoke or drink alcohol. On examination, the patient was obese, afebrile and had a blood pressure of 195/108 and pulse of 95. He was in mild respiratory distress indicated by a tachypnea of 20 breaths per minute, but good air entry bilaterally, and his heart sounds were normal. His abdomen was distended, soft and tympanic. There was no guarding, rigidity or rebound tenderness. The bowel sounds were increased and high pitched and rectal examination revealed normal tone with no masses and presence of pellet stools. Laboratory blood values were normal.

Abdominal X-rays showed large bowel obstruction with no air in the rectum. Based on the diagnosis of large bowel obstruction, the patient was taken for a colonoscopy to identify the cause of the obstruction. The colonoscopy was advanced to the caecum with ease. No twisting of bowel or mass lesions was noted. The patient slightly improved after colonoscopy, but two days after the colonoscopy the patient developed abdominal distension, vomiting and constipation again. A decision was made to take the patient to the operating room for an exploratory laparotomy. At laparotomy, multiple large bowel adhesions were noted. The sigmoid colon was tethered to the small bowel mesentery and the omentum was adherent to the caecum. The rest of the abdomen was inspected and found to be unremarkable. Adhesiolysis was done, biopsy taken and the abdomen closed in layers. Histology results confirmed adhesions. The patient had uneventful recovery and discharged home on day 5.

## Discussion

Intra-abdominal adhesions are divided into congenital or acquired adhesions. Acquired adhesions may be either post-operative or as a result of intra-abdominal inflammation. By far the commonest adhesions are those that occur after surgery, and they occur after 50%-100% of all abdomino-pelvic surgeries<sup>3</sup>. Congenital adhesions form either during organogenesis or abnormal embryological development of the abdominal cavity, and they are usually asymptomatic<sup>4</sup>. Intra-abdominal inflammation due to endometriosis, peritonitis, radiotherapy, or long-term peritoneal dialysis may cause adhesions<sup>4,5,6</sup>. About 28% of post-mortem studies have revealed intra-abdominal adhesions in no antecedent surgery bodies<sup>7</sup>. In the two cases presented, both patients had no previous surgery. Large bowel obstruction due to adhesions is rare in comparison to small bowel obstruction. In a case report by Nirupama Anne et al. a 58 years old woman developed a mid-sigmoid obstruction secondary to adhesive band, 15 years after she had a hysterectomy<sup>2</sup>.

In a review of 388 cases of intestinal obstruction caused by adhesions at the University of Minnesota hospital during the period of January 1, 1942 and September 1, 1953, 79.4% of obstructions were due to postoperative adhesions, 17.8% due to inflammatory adhesions, and only 2.8% caused by congenital adhesive bands<sup>8</sup>. In their review, 88.4% of obstructions occurred in the small intestine, 8% in the large intestine and 3.6% involved both small and large intestine<sup>8</sup>.

To our knowledge, there are no reported cases of large bowel obstruction caused by adhesions in male patients without a previous history of abdominal surgery. In both our patients, the intra-operative diagnosis was adhesions causing large bowel obstruction. In the first case, the patient is previously well with no co-morbid conditions and no previous surgery, presenting with a single adhesive band causing obstruction to the transverse colon. This could be a congenital adhesive band presenting with symptoms at the age of 73, or an inflammatory adhesion band! We could not tell for sure which one it is. The use of ultrasound is user depended, and in the first case the impacted stool in the hepatic flexure was viewed by the ultrasonographer as stones, as indicated by what appear to be acoustic shadows and multiple multi-echoic shadows in the right abdominal upper quadrant (photo 1). In the second case, the patient also had no previous abdominal surgery, but known with diabetes and hypertension. It is our opinion that perhaps the obstructions around his sigmoid were caused by an

inflammatory process. Again it is not easy to confirm this as there was no evidence of any inflammatory process such as diverticulitis or inflammatory bowel disease. Both patients were treated with adhesiolysis and recovered well.

### Conclusion

There are very few reported causes of large bowel obstruction caused by adhesions, and the reported case have had previous gynaecological surgery. Although other diagnosis like peptic ulcer disease and cholelithiasis were suspected in our first case and sigmoid volvulus and malignancy in the second case, it is perhaps worthwhile to have in our differential diagnosis adhesions as a very rare cause of large bowel obstruction, in an elderly patient who present with large bowel obstructive symptoms. The uses of ultrasound scan in diagnosing abdominal pathology is very user dependent, and require experience.

In both our cases, both patients were males, with no previous history of abdominal surgery, and turned out to have adhesions causing large bowel obstruction. Both patients were managed with adhesiolysis at laparotomy.

### References

1. Courtney M. Townsend Jr, R. Daniel Beachamp, B. Mark Evers, Kenneth L. Mattox. Sabiston textbook of surgery: The biological basis of modern surgical practices 17<sup>th</sup> edition. 2004 Elsevier.
2. Nirupama Anne, WasefAbuJaish, RatnakishorePallapothu, James O'Connor. Mid-sigmoid obstruction secondary to an adhesive band. Published Online: 2007,7.
3. DortheBruggmann, GrriTchartchian, Markus Wallwiener, KarstenMunstedt, Hans-Rudolf Tinneberg, Andreas Hackelthal: Intra-abdominal adhesions: definition, Origin, Sifnificance in Surgical Practice, and Treatment Options. DtschArzteblint 2010;107(44): 769-75. DOI: 10.3238/arztebl.2010.0769.
4. Liakakos T, Thomakos N, Fine PM, Dervenis C, Young RL: Peritoneal adhesions: etiology, pathophysiology, and clinical significanace. Dig Surg 2001, 18:260-73.
5. Cheong YC, Laird SM, Li TC, Shelton JB, Ledger WL, Cooke ID: Peritoneal healing and adhesion formation/reformation. Human Reprod Update 2001; 7: 556-66.
6. Monk BJ, Berman ML, Montz FJ: Adhesions after extensive gynecologic surgery: clinical significance, etiology and prevention. Am J ObstetGynecol 1994; 170: 1396-1403.
7. Weibel MA, mayno G: Peritoneal adhesions and their relationship to abdominal surgery. A postmortem study. Am J Surg 1973; 126:345-53.
8. Perry JF jr, Smith GA, Yonehiro EG. Intestinal obstruction caused by adhesions; a review of 388 cases. Ann Surg. 1955; 142 (5): 810-816.