

## Large ovarian endometriomas

Jacques Donnez<sup>1</sup>, Michelle Nisolle, Nadine Gillet, Mireille Smets, Salim Bassil and Françoise Casanas-Roux

Department of Gynecology, Catholic University of Louvain, Cliniques Universitaires St Luc, Avenue Hippocrate 10, B-1200 Brussels, Belgium

<sup>1</sup>To whom correspondence should be addressed

The management of large endometriomas was described in a series of 814 patients. Combined therapy using gonadotrophin-releasing hormone agonist (GnRHa) and carbon dioxide laser laparoscopy was proposed. Drainage and GnRHa for 12 weeks provoked a reduction of the endometrioma size up to 50% of the initial value. After vaporization of the internal wall, a cumulative pregnancy of 51% after 1 year was achieved. A recurrence rate of 8% was observed for a follow-up of 2–11 years. Histological data demonstrated that the epithelium covering the ovary which is the mesothelium can invaginate in the ovarian cortex. Some of the invaginations were seen to be continuous with endometrial tissue, strongly suggesting the metaplasia theory in the pathogenesis of ovarian endometrioma.

**Key words:** endometrioma/endometriosis/ovarian cyst/ovary

### Introduction

The pathogenesis of typical ovarian endometriosis is a source of controversy. The original papers of Sampson (1921, 1927) on this condition reported that perforation of the so-called chocolate cyst led to spillage of adhesions and the spread of peritoneal endometriosis. The findings of Hughesdon (1957) contradicted Sampson's hypothesis and suggested that adhesions are not the consequence but the cause of endometriomas (Hughesdon, 1957). In 93% of typical endometriomas, the pseudocyst is formed by an accumulation of menstrual debris from the shedding and bleeding of active implants located by ovarioscopy (Brosens *et al.*, 1994; Brosens, 1995a, b) at the site of inversion, resulting in a progressive invagination of the ovarian cortex. Other authors (Nezhat *et al.*, 1992, 1994) have suggested that large endometriomas may develop as a result of secondary involvement of functional ovarian cysts in the endometriotic process. According to our classification (Brosens *et al.*, 1993), there are three different types of ovarian endometriosis: (i) superficial haemorrhagic lesions; (ii) haemorrhagic cysts (endometriomas); and (iii) deep-infiltrating ovarian endometriosis. The presence of active foci deeply infiltrating the ovarian cortex led us to suggest that different pathogeneses must be considered as such a development from epithelial

inclusions in the ovary. The aim of this article is to describe the management and the histological data from a series of 814 patients with endometriomas >3 cm in size.

### Materials and methods

From January 1982 to March 1994, 3980 patients underwent laparoscopy for endometriosis. In this series of endometriosis patients, 814 had ovarian cysts >3 cm in size. Bilateral endometriomas were found in 639 cases (79%). The largest endometriomas were >15 cm ( $n = 8$ ). All peritoneal lesions were noted and the ovarian endometriomas often adherent to the ovarian fossa were mobilized. During laparoscopy, the degree of endometriosis was assessed according to the revised American Fertility Society (AFS) classification system (1985) and the ovarian cyst diameter was measured with a probe introduced through a second-puncture incision. After careful examination of the pelvic cavity, the ovarian cyst was incised to a length of 2–3 cm, rinsed, and flushed out. All the chocolate-coloured fluid was aspirated and the internal wall of the cyst was inspected to ensure the absence of any intracystic polypoid projection. The ovarian endometrial cyst wall was biopsied with a biopsy punch forceps (26–175 DH; Storz, Tuttlingen, Germany) to ascertain the diagnosis of endometriosis. Patients received a s.c. injection of gosereline (Zoladex<sup>®</sup>; Zeneca, Cambridge, UK) implant at 0, 4, 8 and 12 weeks. The initial pituitary stimulation phase, associated with a rise in oestrogens, was curtailed in our study by injecting the implant during the luteal phase.

In 93 cases, large biopsies of >1 cm in size were taken in order to allow the evaluation of different parameters, including the three-dimensional (3-D) architecture evaluation; biopsies from eutopic endometrium were taken simultaneously. Serial sections (6  $\mu\text{m}$ ) were stained with Gomori's trichrome (Gabe, 1968) and then examined on a blind basis. In all cases, the mitotic index and the epithelial height were calculated as previously described (Nisolle *et al.*, 1988).

The vimentin and cytokeratin content was determined by histochemistry, using the technique previously described for peritoneal endometriosis and the H-score and the percentage of positive-staining surface area were determined by a recently described computerized technique (Nisolle *et al.*, 1995). The results were compared with the results obtained from eutopic endometrium and peritoneal endometriosis.

The 3-D architecture evaluation was made whenever reconstruction was possible (Donnez *et al.*, 1992) in order to evaluate histologically the underlying ovarian cortex. After the first-look laparoscopy, another laparoscopy was performed 12 weeks later. The degree of endometriosis was assessed by the same two observers (J.D. and M.N.) according to the revised AFS classification system. The size of the ovarian cyst was measured. Ovarian biopsy specimens were taken from the endometrial cyst wall in 48 cases in order to compare the histological data before and after therapy. After biopsy, the internal wall of the ovarian cyst was vaporized with the help of the CO<sub>2</sub> laser (Donnez, 1987; Donnez *et al.*, 1991) equipped since 1990 with the Swiftlase<sup>®</sup> (Sharplan, Laser Industries, Tel Aviv, Israel). Patients were followed-up for a maximum of 13 years.

**Table I.** Scores (revised American Fertility Society classification) and ovarian cyst diameter after drainage and gonadotrophin-releasing hormone analogue. Incidence of 'active' endometriosis and tubal metaplasia. Mitotic index and epithelial height in active endometriosis ovarian foci

	First look	Second look
<b>Laparoscopic findings (n = 814)</b>		
Scores		
Total	43.4 ± 2.1	33.2 ± 2.1*
Implants	27.1 ± 1.8	16.9 ± 1.7*
Adhesions	16.3 ± 1.7	16.3 ± 1.7
Cyst diameter (mm)	47.3 ± 4.2	21.7 ± 3.8*
<b>Histological findings (n = 48)</b>		
Active endometriosis (%)	84	41*
Tubal metaplasia (%)	62	51
Mitotic index (‰)	0.2	0.06
Epithelial height (µm)	16.0 ± 4.9	17.2 ± 4.8

\*Significantly different ( $P < 0.001$ ) from other values.

### Statistical analysis

The  $\chi^2$  test, the median test and Student's *t*-test were used to analyse the data.

## Results

### Modification of scores

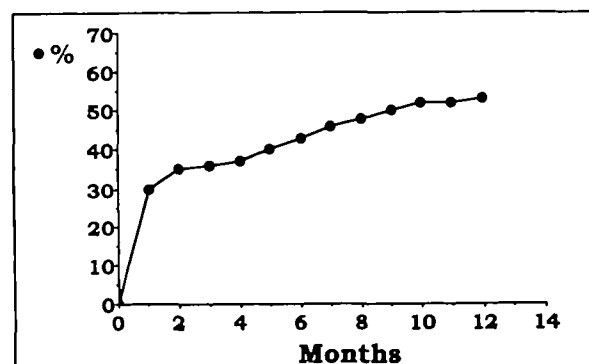
The mean laparoscopic scores found before and at the end of treatment are compared in Table I. The mean score decreased from  $43.4 \pm 2.1$  to  $33.2 \pm 2.1$ . The difference was statistically significant ( $P < 0.001$ ). Laparoscopic scoring was done separately for implants and adhesions. In the case of implants, the score decreased from  $27.1 \pm 1.8$  to  $16.9 \pm 1.7$ . The difference was statistically significant ( $P < 0.005$ ). The initial adhesion score did not decrease.

### Modification of cyst diameter

In all cases, a residual cyst was present. Complete disappearance of the cyst was never observed. The response of the ovarian disease was evaluated by measuring the modifications of the ovarian cyst diameter (Table I). After drainage and a 12-week gonadotrophin-releasing hormone agonist (GnRHa) therapy, a significant decrease ( $P < 0.001$ ) was observed from  $47.3 \pm 6.2$  to  $21.7 \pm 3.8$  mm. In eight cases, the endometrioma was  $>15$  cm (mean  $17.5 \pm 2.8$  cm). The ovarian cortex was evaluated by echography as being  $<2$  mm in thickness. Eight weeks after drainage and GnRHa, the size was  $8.8 \pm 4.2$  cm. Aspiration of the remaining chocolate-coloured fluid and flushing out were then performed by vaginal puncture under echography. The diameter was  $4.6 \pm 2.4$  cm 4 weeks later. It was obvious that the remaining ovarian cortex surrounding the endometrioma became significantly ( $P < 0.001$ ) thicker (8–100 mm) when compared with the values obtained before drainage. In all cases, vaporization of the internal lining of the cyst was easily performed at week 12.

### Pregnancy rate and recurrence rate

The cumulative pregnancy rate was evaluated from the first post-operative menstruations. A total of 42 patients who did not menstruate (because they had become pregnant after the first ovulation) were included in the 'first cycle'. A pregnancy



**Figure 1.** Cumulative pregnancy rate during the first year after surgery.

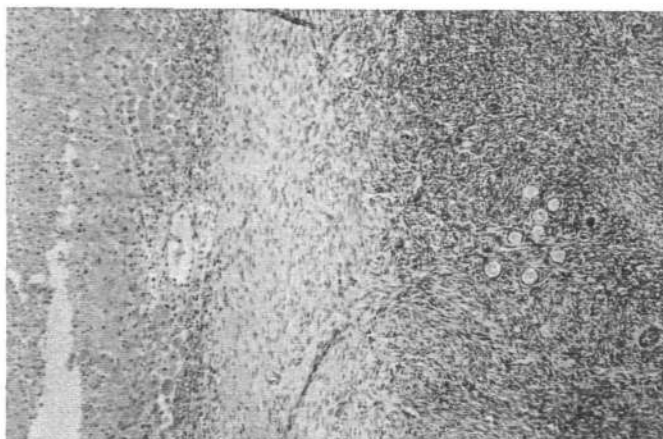
rate of  $>51\%$  was achieved (Figure 1). The majority of pregnancies occurred during the first 10 months following surgery. In our series of 814 patients with ovarian endometriomas treated with combined GnRHa and laser surgery therapy, 607 patients were followed-up for 2–13 years. A recurrence of ovarian endometriomas was suspected by vaginal echography and then confirmed by laparoscopy in 51 cases (8%). Among the 51 cases, previous laparoscopy had revealed a unilateral endometrioma in 15 cases (30%). The recurrence was observed in eight cases in the heterolateral ovary, and in seven cases in the previously treated ovary.

### Ovarian cyst histology

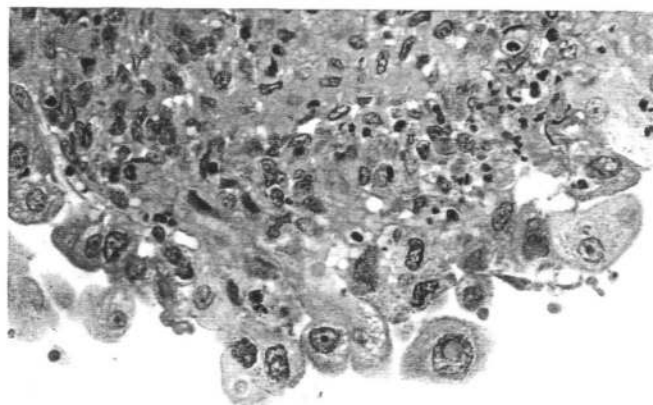
The diagnosis of ovarian endometriosis was confirmed morphologically in all cases except two in which glandular epithelium and stroma were absent and replaced by fibrous tissue.

Serial sections were carried out in a series of 93 large biopsies in order to observe endometrial epithelium which is often very thin and flattened. Biopsies of the endometrioma wall often reveal flattened columnar epithelium with a stroma of endometrial type, often surrounded by fibroreactive tissue with haemosiderin-laden macrophages. There is no real plane of 'cleavage' between the endometrial-type stroma and the ovarian cortex and it is not unusual to find oocytes in the vicinity of the endometrial stroma (Figure 2). In some areas, mucosal endometrium can be seen. In other areas, the epithelium is very thin, often detached from the subepithelial layers. The epithelial and stromal lining of an endometriotic cyst frequently becomes attenuated and the former may be reduced to a single layer of cuboidal cells which is frequently devoid of specific features. In such circumstances, recognition of the cyst as endometriotic may only be possible if a rim of subadjacent endometrial stroma persists. Commonly, the cyst lining of endometrial epithelium and stroma is totally lost and replaced by granulation tissue, dense fibrous and numerous pigmented macrophages. In this case, diagnosis of endometriosis can be difficult because similar findings can be seen in an old corpus luteum cyst.

In our series, serial sections allowed us to diagnose endometriosis in all cases ( $n = 93$ ). Nuclear atypia (Figure 3) was seen in 12% of cases. Metaplastic changes similar to those occurring in eutopic endometrial glands were observed. These included tubal (ciliated cells) metaplasia and hobnail meta-

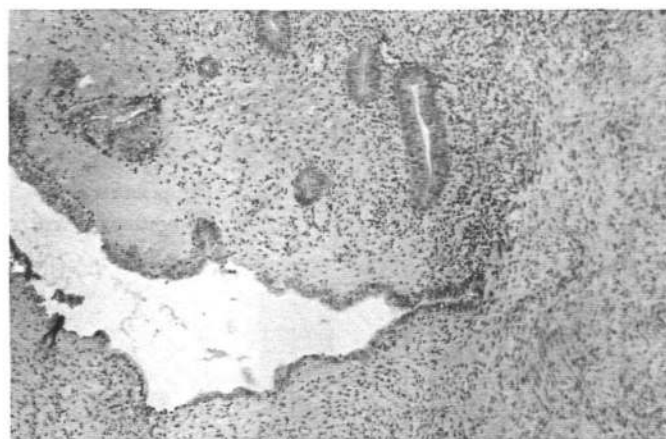

**Figure 2.** Ovarian endometrioma wall biopsy: endometrial glands and stroma (left). Note the presence of numerous oocytes in the vicinity (original magnification  $\times 25$ ).

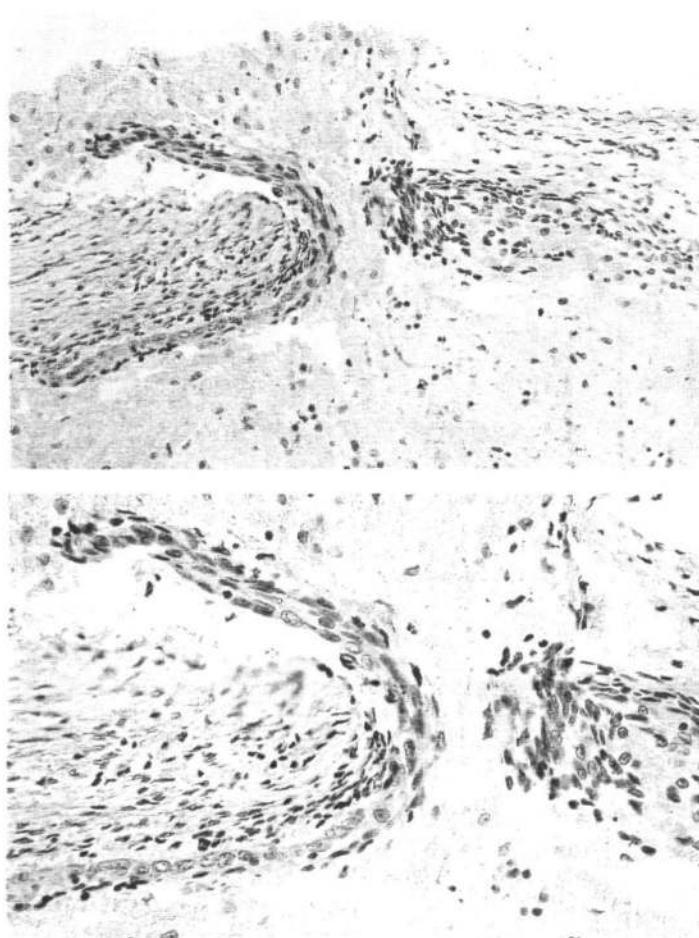


**Figure 3.** Ovarian endometrioma: glandular epithelium with nuclear atypia (original magnification  $\times 110$ ).

plasia. Ciliated cells were demonstrated in  $>62\%$  of cases. When biopsies were obtained from the site of adhesions (inversion stigma according to Hughesdon's hypothesis) and from the deepest area of the endometrioma, histology revealed the same data in both areas: areas of fibrosis covered by flattened epithelium surrounded by stroma with haemosiderin-laden macrophages were observed and small foci of full-thickness endometrial tissue were found with the same incidence close to the inversion stigma as well as in the other parts. Flattened epithelium was continuous with active glandular epithelium. During the luteal phase, in areas with non-flattened glandular epithelium as well as in the flattened epithelium, the endometrium was never found to be in phase with eutopic endometrium. Extracystic endometriotic lesions (Figure 4) were observed in the endometriotic stroma or deeper in the ovarian cortex in 33% of cases. These endometriotic lesions were considered as invagination of the ovarian cortex by epithelium surrounded by endometrial-type stroma. The 3-D architecture revealed this process of invagination. The multifocal appearance of these lesions in 2-D was not confirmed by the 3-D reconstruction. Indeed, these 'extracystic' endometriotic inclusions were clearly defined as ramified invaginations by the

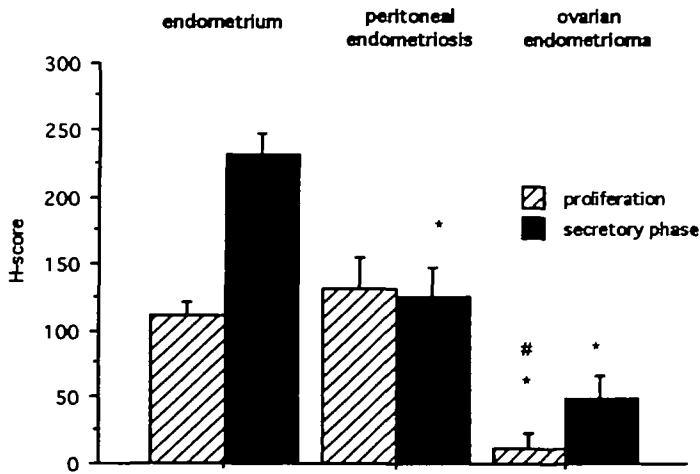


**Figure 4.** 'Extracystic' endometriotic lesions. Serial sections demonstrated that these lesions must be considered as invagination of the endometrial glands (original magnification  $\times 56$ ).



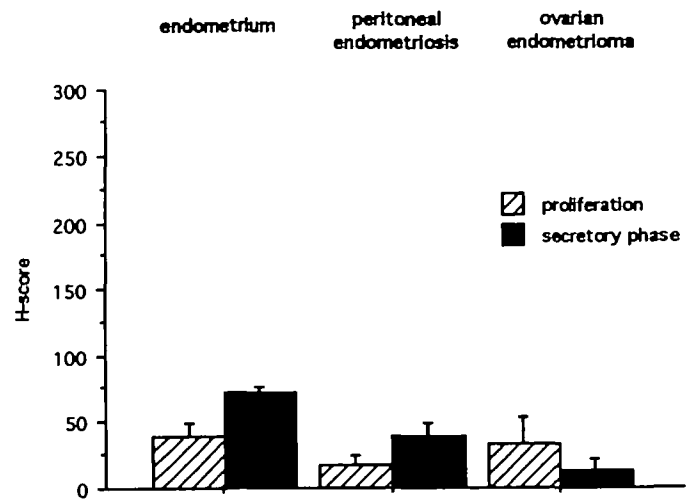
**Figure 5.** Clear continuum between the invaginated mesothelium and endometriotic tissue at the site of invagination (endometrioma ostium). The endometrioma ostium is clearly visible as well as the cyst with the chocolate coloured fluid (original magnification upper  $\times 25$ ; lower  $\times 110$ ).

glandular epithelium and stroma. In some cases, invagination of the mesothelial cells covering the ovary was clearly demonstrated and metaplasia into endometrial tissue could be observed. A continuum between the invaginated mesothelium



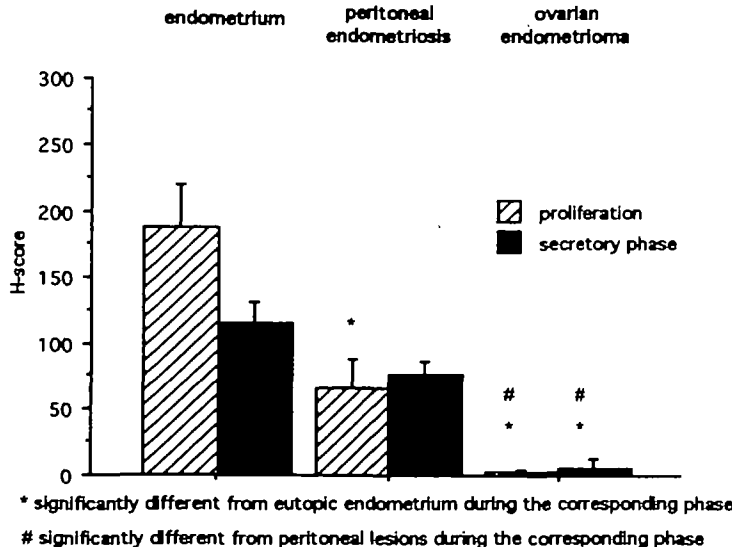
\* significantly different from eutopic endometrium during the corresponding phase  
# significantly different from peritoneal lesions during the corresponding phase

**Figure 6.** Cytokeratin content in the glandular epithelium of endometrioma during the cycle and compared to the content observed in eutopic and peritoneal ectopic endometrium.



\* significantly different from eutopic endometrium during the corresponding phase  
# significantly different from peritoneal lesions during the corresponding phase

**Figure 8.** Vimentin content in the stroma of endometrioma during the cycle and compared to the content observed in eutopic and peritoneal ectopic endometrium.



\* significantly different from eutopic endometrium during the corresponding phase  
# significantly different from peritoneal lesions during the corresponding phase

**Figure 7.** Vimentin content in the glandular epithelium of endometrioma during the cycle and compared to the content observed in eutopic and peritoneal ectopic endometrium.

and the endometriotic tissue was observed in some serial sections (Figure 5A, B).

The cytokeratin and vimentin content was evaluated by an H-score, using a new computerized evaluation method (Nisolle *et al.*, 1995). The cytokeratin (Figure 6) and vimentin content (Figure 7) of glandular epithelium was significantly lower when compared to eutopic and peritoneal ectopic endometrium. The H-score for cytokeratin content in the glandular epithelium cytoplasm was significantly lower ( $P < 0.001$ ) in comparison with eutopic and peritoneal ectopic endometrium. The vimentin content of the glandular epithelium of endometrioma was extremely low. In the stroma, cytokeratin was never expressed and the vimentin content (Figure 8) was not different from that observed in peritoneal ectopic endometrium.

In 48 cases, biopsies before and after therapy were available

and comparison was then possible in order to evaluate the influence of GnRHa therapy. An endometriotic lesion was considered 'active' when typical glandular epithelium that appeared either proliferative or completely unresponsive to hormones was found with typical stroma. 'Active' endometriosis was found in 84 and 41% of cases before and after GnRHa therapy respectively, which is significantly different ( $P < 0.001$ ). The mitotic index was calculated in typical glandular epithelium. Its value was 0.2‰ before and 0.06‰ after GnRHa therapy respectively. The value observed after GnRHa therapy was significantly lower than that observed before GnRHa therapy ( $P < 0.001$ ). No difference was observed in the epithelial height after therapy. No decrease in nuclear atypia and hyperplasia was observed after GnRHa therapy. Some areas revealed the presence of cells showing no signs of degeneration.

**Discussion**

Since 1992, different proposals (Nezhat *et al.*, 1992; Brosens *et al.*, 1993; Brosens, 1995b) have been made in order to improve our knowledge of the physiopathology of endometriomas (chocolate cysts). The term 'chocolate cyst' was applied by Sampson (1921, 1927) to describe the endometrial cyst of the ovary. According to Hughesdon (1957), the internal surface of a chocolate cyst is really the external surface of the ovary; the ovarian cortex is identifiable by the presence of primordial follicles. The endometrial cyst may be lined with free endometrial tissue similar histologically and functionally to eutopic endometrium (Brosens *et al.*, 1994). It was thus suggested (Hughesdon, 1957; Brosens, 1995b) that the endometrioma is a pseudocyst formed by an accumulation of menstrual debris from endometrial implants adherent to the peritoneal layer. The adhesions are the cause of the endometrioma by shedding of active superficial implants. We have focused our study on the evaluation of endometriomas (>3 cm) in order to analyse the histological data and the clinical implications. Ovarian endometriomas do not respond very well to medical therapy

(Buttram *et al.*, 1985; Nisolle *et al.*, 1988; Donnez *et al.*, 1990, 1994; Shaw, 1992). After drainage alone, a quick recurrence of the cyst size proved that drainage is completely ineffective in the management of large endometriomas (Donnez *et al.*, 1994), although some authors (Fayez and Vogel, 1991) have suggested its efficacy. However, 3 months after drainage of the endometrioma and GnRHa therapy (which provokes amenorrhea), a significant reduction (from  $47.3 \pm 4.2$  to  $21.7 \pm 3.8 \mu\text{m}$ ) was observed. However, the reformation of chocolate-coloured fluid during an amenorrhoeic period suggests that endometrial shedding is not responsible, by itself, for chocolate-coloured fluid formation. In our opinion, its origin could be: (i) cyst wall exudation; (ii) congested blood vessels of the cyst wall; (iii) inflammation around persistent intracystic endometrial foci which are resistant to medical therapy. The persistence of a chocolate cyst at laparoscopy after GnRHa therapy was confirmed by the histological study. Indeed, in all cases, histological examination of residual ovarian endometriotic lesions after hormonal therapy revealed glandular epithelium and stroma. In >40% of cases, areas with persistent active endometriosis were observed after GnRHa. The precise reason why a number of endometrial cells of endometrial cysts do not respond to hormonal therapy is unknown but five hypotheses may be proposed: (i) the drug does not gain access to the ovarian endometriotic foci because fibrosis surrounding the foci prevents access locally; (ii) endometriotic cells may have their own genetic programming, while an endocrine influence appears to be only secondary and dependent on the degree of differentiation of the individual cell; (iii) the low number of endometriotic steroid receptors and their different regulatory mechanisms in ectopic and eutopic endometrium may result in deficient endocrine dependency (Nisolle *et al.*, 1994); (iv) the absence of control by the steroid receptors which are biologically inactive (unable to induce typical secretory changes); (v) the intra-ovarian environment with paracrine-stimulating growth factors.

The persistence of active endometriotic tissue after GnRHa suggests the need for the surgical removal of invasive endometriosis (Buttram *et al.*, 1985; Donnez, 1987, 1993; Donnez *et al.*, 1989a,b, 1990; Nezhat *et al.*, 1992, 1994; Brosens, 1995a). The cumulative pregnancy rate achieved after combined GnRHa and endoscopy therapy was similar to that obtained after microsurgery (Gordts *et al.*, 1984), and allows us to propose this form of therapy in the management of large endometriomas. Indeed, the reduction of both cyst size and internal wall thickness observed in our study after GnRHa therapy facilitates the laparoscopic management of large endometrial cysts. In our series of large cysts (>15 cm), an echoguided puncture was performed after an 8-week GnRHa therapy and the size of the cyst decreased to a diameter of  $4.6 \pm 2.4$  cm. The recurrence rate of ovarian endometriomas was low (8%), similar to the rate observed after microsurgery (Gordts *et al.*, 1984) or after a laparoscopic procedure (cystectomy) (Canis *et al.*, 1992a,b, 1993). We recommend the vaporization of the internal wall of the endometrioma because the active implants are located on the internal surface of the cyst. The incidence of endometriotic lesions found deep in the stroma in our study (33%) cannot be considered as an

argument in favour of cystectomy because deep-infiltrating intra-ovarian endometriosis was found with the same incidence. Another argument in favour of vaporization is the frequent absence of a thickened capsule around the endometrial cyst which makes capsule removal difficult and is responsible for the simultaneous removal of numerous oocytes. In large cysts, the remaining ovarian cortex surrounding the endometrioma is often thinner than 5 mm. There is a risk of removing the normal ovarian cortex containing oocytes during the attempt at endometrioma wall removal.

We do not agree with a recent paper (Dubuisson and Chapron, 1994) which recommended cystectomy in every case because histological analysis of endometriotic lesions of the ovary showed that 4% of cases were atypical (Czernobilsky and Norris, 1979). This incidence was interpreted by Dubuisson and Chapron (1994) as a risk factor for the development of cancer. It has never been proved that atypical cells can lead to ovarian cancer. We encountered no cases of ovarian cancer in our series of 814 patients, although we observed atypical areas in 12% of cases. As reported by Czernobilsky and Morris (1979) and by our group (Nisolle *et al.*, 1988), hyperplasia and atypia have to be considered as endometriotic tissue completely unresponsive to hormones and not as a potential for ovarian cancer. Although two recent papers and debates (Brosens, 1995b; Nezhat *et al.*, 1994) have tried to classify endometriomas, considerable doubt still exists. Indeed, in our series, we found 12% of endometriomas not fixed to the broad ligament. The theory of Hughesdon cannot explain the formation of the endometrioma in these cases. In our opinion, the epithelium covering the ovary, which is the mesothelium able to form any type of tissue, can invaginate in the ovarian cortex. Indeed, invaginations of the mesothelial layer covering the ovarian tissue were described by Motta *et al.* (1980) in animals and fetal ovaries, and this was also seen in our study in human adult ovaries. Moreover, mesothelial inclusions were frequently seen in our serial sections of the ovary. Under the influence of so-far unknown growth factors, these inclusions could be transformed into intra-ovarian endometriosis by metaplasia. Our main argument is the demonstration in our study of the capacity of the tissue to invaginate secondarily from the endometrial wall itself. Our second argument is the presence of epithelial invaginations in continuum with endometrial tissue, proving the metaplasia theory (Figure 5).

The expression of cytokeratin indicates a close relationship with the mesodermal Müllerian origin. The absence of vimentin expression in epithelial cells can reveal either an absence of glandular function or a characteristic of metaplastic origin. Indeed, a similar low expression of vimentin was also observed in rectovaginal adenomyotic nodules of which the origin seems to be metaplasia of Müllerian rests, present in the rectovaginal septum (Donnez *et al.*, 1995). Our theory is thus different from the theory of Hughesdon (1957) and Brosens (1993, 1995b) who consider that the pathogenesis of the typical ovarian endometrioma has now been clarified as a process originating from a free superficial implant which is in contact with the ovarian surface and is sealed-off by adhesions, the menstrual shedding and bleeding of this small implant resulting in a progressive invagination of the ovarian cortex and the formation of the pseudocyst.

Our theory contradicts Hughesdon's and Brosens's hypotheses. The endometrioma must indeed be considered as an invagination, but not as the result of the bleeding of a superficial implant. Indeed, metaplasia of the coelomic epithelium invaginated in the ovarian cortex was proved in our study and explains the endometrioma formation. The 'deep-infiltrating ovarian endometriosis', described by Donnez *et al.* (1992) is, in fact, invagination of the ovary by the endometriotic tissue and is probably responsible for the recurrence of ovarian endometriosis after cyst excision or vaporization.

## References

- American Fertility Society (1985) Revised American Fertility Society classification of endometriosis. *Fertil. Steril.*, **58**, 351–362.
- Brosens, I., Puttemans, P. and Deprest, J. (1994) The endoscopic localization of endometrial implants in the ovarian chocolate cyst. *Fertil. Steril.*, **61**, 1034–1038.
- Brosens, I. (1995a) Ovarian endometriosis. In Shaw, R. (ed.), *Endometriosis*. Parthenon Publishing, London, Carnforth, p. 97.
- Brosens, I. (1995b) Endoscopic exploration and classification of the chocolate cyst. *Hum. Reprod.*, **9**, 2213–2214.
- Brosens, I., Donnez, J. and Benagiano, G. (1993) Improving the classification of endometriosis. *Hum. Reprod.*, **8**, 1792–1795.
- Buttram, V., Reiter, R. and Ward, S. (1985) Treatment of endometriosis with danazol: report of a 6-year prospective study. *Fertil. Steril.*, **43**, 353.
- Canis, M., Mage, G., Wattiez, A. *et al.* (1992a) Second look laparoscopy after laparoscopic cystectomy of large endometriomas. *Fertil. Steril.*, **58**, 617–619.
- Canis, M., Pouly, J.L. and Wattiez, A. (1992b) Incidence of bilateral adnexal disease in severe endometriosis (revised American Fertility Society (AFS), stage IV): should a stage V be included in the AFS classification. *Fertil. Steril.*, **57**, 601–602.
- Canis, M., Wattiez, A., Pouly, J.L. *et al.* (1993) Laparoscopic treatment of endometriosis. In Brosens, I. and Donnez, J. (eds), *The Current Status of Endometriosis. Research and Management*. Parthenon Publishing, Carnforth, UK, pp. 407–417.
- Czernobilsky, O. and Morris, W.J. (1979) A histologic study of ovarian endometriosis with emphasis on hyperplastic and atypical changes. *Obstet. Gynecol.*, **53**, 318–323.
- Donnez, J. (1987) CO<sub>2</sub> laser laparoscopy in infertile women with adhesions or endometriosis. *Fertil. Steril.*, **48**, 390–394.
- Donnez, J. (1993) Rationale for surgery. In Brosens, I. and Donnez, J. (eds), *Current Status of Endometriosis. Research and Management*, Vol. I. Parthenon Publishing, Carnforth, UK, pp. 385–395.
- Donnez, J. and Nisolle, M. (1991) Laparoscopic management of large ovarian endometrial cyst: use of fibrin sealant. *J. Gyn. Surg.*, **7**, 163–167.
- Donnez, J., Nisolle, M. and Casanas-Roux, F. (1989a) Administration of nasal buserelin as compared with subcutaneous buserelin implant for endometriosis. *Fertil. Steril.*, **52**, 27–30.
- Donnez, J., Nisolle, M. and Casanas-Roux, F. (1989b) CO<sub>2</sub> laser laparoscopy in infertile women with adnexal adhesions and women with tubal occlusion. *J. Gyn. Surg.*, **5**, 47–53.
- Donnez, J., Nisolle, M. and Casanas-Roux, F. (1990) Endometriosis-associated infertility: evaluation of preoperative use of danazol, gestrinone and buserelin. *Int. J. Fertil.*, **42**, 128.
- Donnez, J., Nisolle, M. and Casanas-Roux, F. (1992) Three-dimensional architectures of peritoneal endometriosis. *Fertil. Steril.*, **57**, 980–983.
- Donnez, J., Nisolle, M., Gillerot, S. *et al.* (1994) Ovarian endometrial cyst: the role of gonadotropin-releasing hormone agonist and/or drainage. *Fertil. Steril.*, **62**, 63–66.
- Donnez, J., Nisolle, M., Casanas-Roux, F. *et al.* (1995) Rectovaginal septum, endometriosis or adenomyosis: laparoscopic management in a series of 231 patients. *Hum. Reprod.*, **10**, 630–635.
- Dubuisson, J.B. and Chapron, C. (1994) Classification of endometriosis. The need for modification. *Hum. Reprod.*, **9**, 2214–2215.
- Fayez, J.A. and Vogel, M.S. (1991) Comparison of different treatment methods of endometriosis by laparoscopy. *Obstet. Gynecol.*, **78**, 660–665.
- Gabe, M. (1968) Les colorations topographiques. In Masson and Co. (eds), *Techniques Histologiques*, Paris, pp. 203–256.
- Gordts, S., Boeckx, W. and Brosens, I. (1994) Microsurgery of endometriosis in infertile patients. *Fertil. Steril.*, **42**, 520–525.
- Hughesdon, P.E. (1957) The structure of endometrial cysts of the ovary. *J. Obstet. Gynaecol. Nr. Emp.*, **44**, 481–487.
- Motta, P.M., Van Blerkom, J. and Makabe, S. (1980) Changes to the surface morphology of ovarian germinal epithelium during the reproductive life and in some pathological conditions. *J. Sub. Cytol.*, **12**, 407–425.
- Nezhat, F., Nezhat, C., Allan, C.J. *et al.* (1992) A clinical and histologic classification of endometriomas: implications for a mechanism of pathogenesis. *J. Reprod. Med.*, **37**, 771–776.
- Nezhat, F., Nezhat, C., Nezhat, C. and Admon, D. (1994) A fresh look at ovarian endometriomas. *Contemporary Ob/Gyn.*, 81–94.
- Nezhat, C., Nezhat, F., Nezhat, C. and Siedman, D. (1994) Classification of endometriosis. Improving the classification of endometriotic ovarian cysts. *Hum. Reprod.*, **9**, 2212–2213.
- Nisolle, M., Casanas-Roux, F. and Donnez, J. (1988) Histologic study of ovarian endometriosis after hormonal therapy. *Fertil. Steril.*, **49**, 423–426.
- Nisolle, M., Casanas-Roux, F., Wyns, Ch. *et al.* (1994) Immunohistochemical analysis of estrogen and progesterone receptors in endometrium and peritoneal endometriosis: a new quantitative method. *Fertil. Steril.*, **62**, 751–759.
- Nisolle, M., Casanas-Roux, F. and Donnez, J. (1995) Coexpression of cytokeratin and vimentin in eutopic endometrium and endometriosis throughout the menstrual cycle: evaluation by a computerized method. *Fertil. Steril.*, **64**, 69–75.
- Sampson, J.A. (1921) Perforating haemorrhagic (chocolate) cysts of the ovary. *Arch. Surg.*, **3**, 245–323.
- Sampson, J.A. (1927) Peritoneal endometriosis due to the menstrual dissemination of endometrial tissue into the peritoneal cavity. *Am. J. Obstet. Gynecol.*, **14**, 422–469.
- Shaw, R.W. (1992) The role of GnRH analogues in the treatment of endometriosis. *Br. J. Obstet. Gynaecol.*, **99**, 9–12.

Received on August 1, 1995; accepted on January 11, 1996