

# Le Fort III osteotomy for severe dentofacial deformity correction associated with hypoplasia of the midface

*Osteotomia Le Fort III para correção de deformidade dentofacial severa associada a hipoplasia de terço médio da face*

Aline Monise SEBASTIANI<sup>1</sup>  
Nelson Luis Barbosa REBELATTO<sup>2</sup>  
Leandro Eduardo KLÜPPEL<sup>3</sup>  
Delson João da COSTA<sup>3</sup>  
Fernando ANTONINI<sup>4</sup>  
Rafaela Scariot de MORAES<sup>5</sup>

## ABSTRACT

*The combination of orthodontic therapy and orthognathic surgery is a well-established treatment modality for the correction of dentofacial deformities. When these deformities are more severe, involving hypoplastic midface, surgical techniques not used routinely in the treatment of facial changes are required, such as the Le Fort III osteotomy or variations of this technique. Few studies have reported the use of this technique or its modifications in non-syndromic patients. This paper demonstrates the orthodontic-surgical resolution of a patient with dentofacial deformity with severe malocclusion Class III, involving midface hypoplasia, with a modification technique of a Le Fort III osteotomy associated with Le Fort I and sagittal of the rami osteotomies. After three years of postoperative follow-up, the patient demonstrates significant improvement in chewing ability, no functional complaints, and high satisfaction with the aesthetics and improved quality of life.*

**Indexing terms:** Face. Malocclusion. Orthognathic surgery.

## RESUMO

A combinação da terapia ortodôntica com a cirurgia ortognática é uma modalidade de tratamento bem estabelecida para a correção de deformidades dentofaciais. Quando estas deformidades apresentam maior severidade, envolvendo a hipoplasia do terço médio da face, exigem técnicas cirúrgicas não utilizadas como rotina no tratamento das alterações faciais, como a osteotomias Le Fort III ou as variações destas técnicas. Poucos estudos relatam o uso desta técnica ou de suas modificações em pacientes não sindrômicos. Este trabalho tem como objetivo demonstrar uma resolução ortodôntica-cirúrgica de um paciente apresentando deformidade de face com má-oclusão Classe III severa, envolvendo hipoplasia do terço médio facial, com a realização de uma técnica modificada da osteotomia Le Fort III, associada as osteotomias Le Fort I e osteotomia sagital dos ramos mandibulares. O paciente encontra-se com três anos de acompanhamento pós-operatório, com melhora significativa na sua habilidade mastigatória, sem queixas funcionais, relatando alta satisfação com a estética e melhora na qualidade de vida.

**Termos de indexação:** Face. Má oclusão. Cirurgia ortognática.

## INTRODUCTION

The combination of orthodontic and orthognathic surgery therapy is a well-established treatment modality to correct moderate and severe dentofacial deformities<sup>1</sup>. The most common surgery techniques are the bilateral sagittal split osteotomy (BSSO) in mandible surgeries and the Le Fort I osteotomy in surgeries involving the maxilla.

The correction in patients with Class III malocclusion is usually performed with these two osteotomy techniques, either isolated or combined. However, severe deformities involving midface hypoplasia represent a more challenging treatment for the surgeon, requiring surgery techniques that are not routinely performed to treat facial alterations, like the Le Fort II and Le Fort III<sup>2</sup> osteotomies and variations of these techniques.

<sup>1</sup> Universidade Federal do Paraná, Faculdade de Odontologia, Departamento de Estomatologia. Av. Lothário Meissner, 632, 80210-170, Jd. Botânico, Curitiba, PR, Brasil. Correspondência para / Correspondence to: AM SEBASTIANI. E-mail: <sebastiani.aline@gmail.com>.

<sup>2</sup> Universidade Federal do Paraná, Programa de Residência em Cirurgia e Traumatologia Buco-maxilo-faciais. Curitiba, PR, Brasil.

<sup>3</sup> Universidade Federal do Paraná, Programa de Mestrado em Odontologia, Programa de Residência em Cirurgia e Traumatologia Buco-maxilo-faciais. Curitiba, PR, Brasil.

<sup>4</sup> Universidade do Extremo Sul Catarinense, Curso de Odontologia. Criciúma, SC, Brasil.

<sup>5</sup> Universidade Positivo, Curso de Odontologia. Curitiba, PR, Brasil.

The Le Fort III osteotomy has been widely used in dentofacial deformity treatment, primarily in syndromic patients<sup>2-5</sup>. It was first reported in 1950 by Gilles and Harrison<sup>6</sup>, and after this, Tessier<sup>7</sup> described the technique in more refined way, making it more applicable and predictable in craniofacial deformity treatment and revolutionizing the management in patients with total deficiency of the midface.

Several modifications of the technique were realized with osteotomy alterations<sup>8</sup> or Le Fort I osteotomy association<sup>9-10</sup>. Fewer studies related the use of the technique or one of its modifications in non-syndromic patients with midface hypoplasia<sup>10</sup>.

This paper reports the orthodontic-surgical resolution in one non-syndromic patient with dentofacial

deformity and severe Class III malocclusion on which a Le Fort III modified osteotomy associated with the Le Fort I and BSSO osteotomies was performed.

### CASE REPORT

A 23-year-old male patient with extensive mandible prognathism associated with midface hypoplasia was referred due to a functional complaint with restriction in feeding, esthetic complaints and bad quality of life. In the facial analysis, he exhibited a concave profile with midface depression, a wide chin-cervical distance and his lower face extended. The patient had a mandible asymmetry and deviated septum, both on the right side (Figure 1A, B).

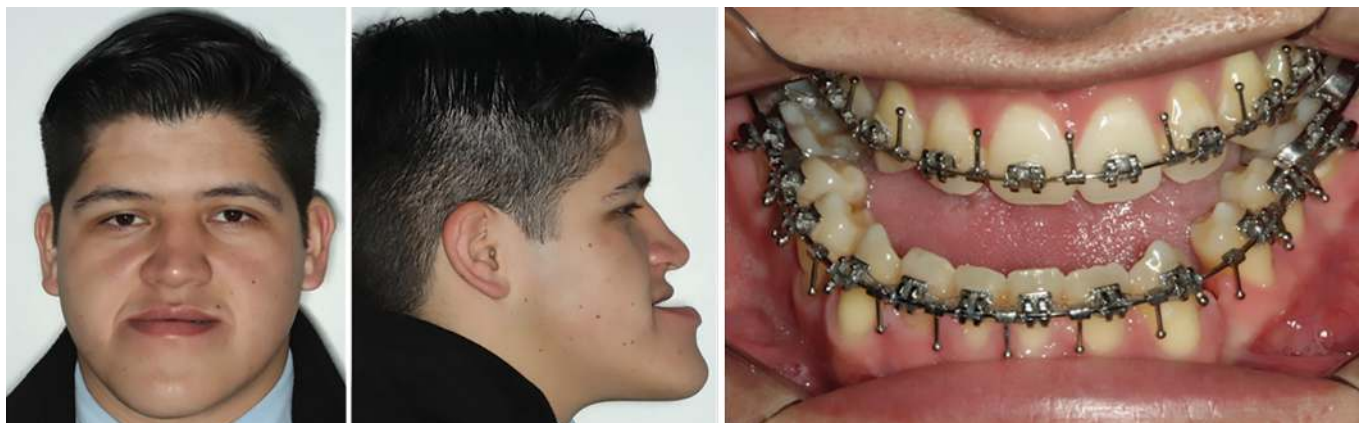

Figure 1. Figure 1. Photos in the preoperative period. A) Front view. B) Profile view. C) Occlusal view.

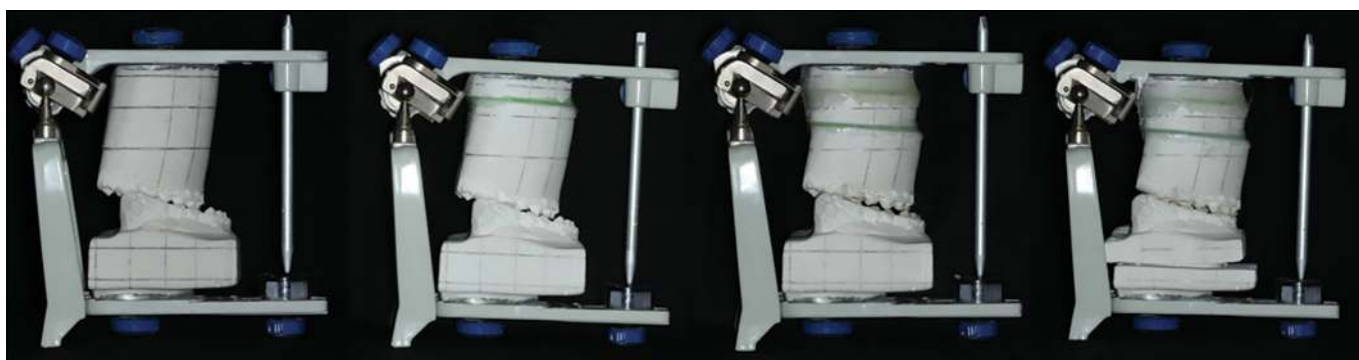


Figure 2. Planning in semi-adjustable articulator and model surgery. A) Initial occlusion. B) Simulation of the midface advance. C) Simulation with the maxilla advancement. D) Simulation with the mandibular setback.

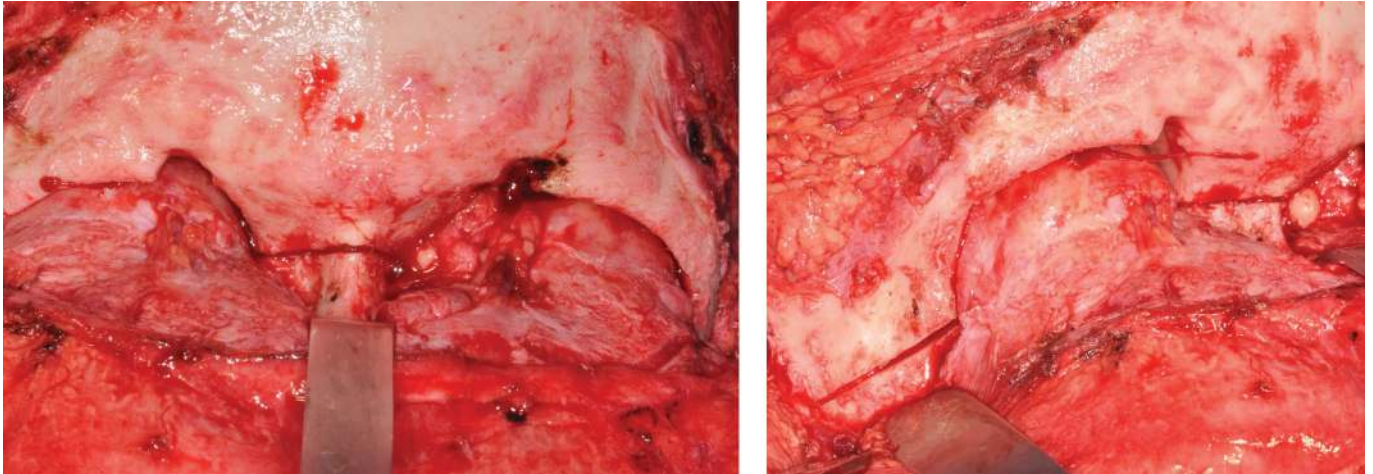
After the orthodontic-surgical planning, teeth 14 and 24 were extracted to enable the maxillary teeth decompensation. After two years of orthodontic treatment, he showed a 15-mm maxillo-mandible discrepancy (Figure

1C).

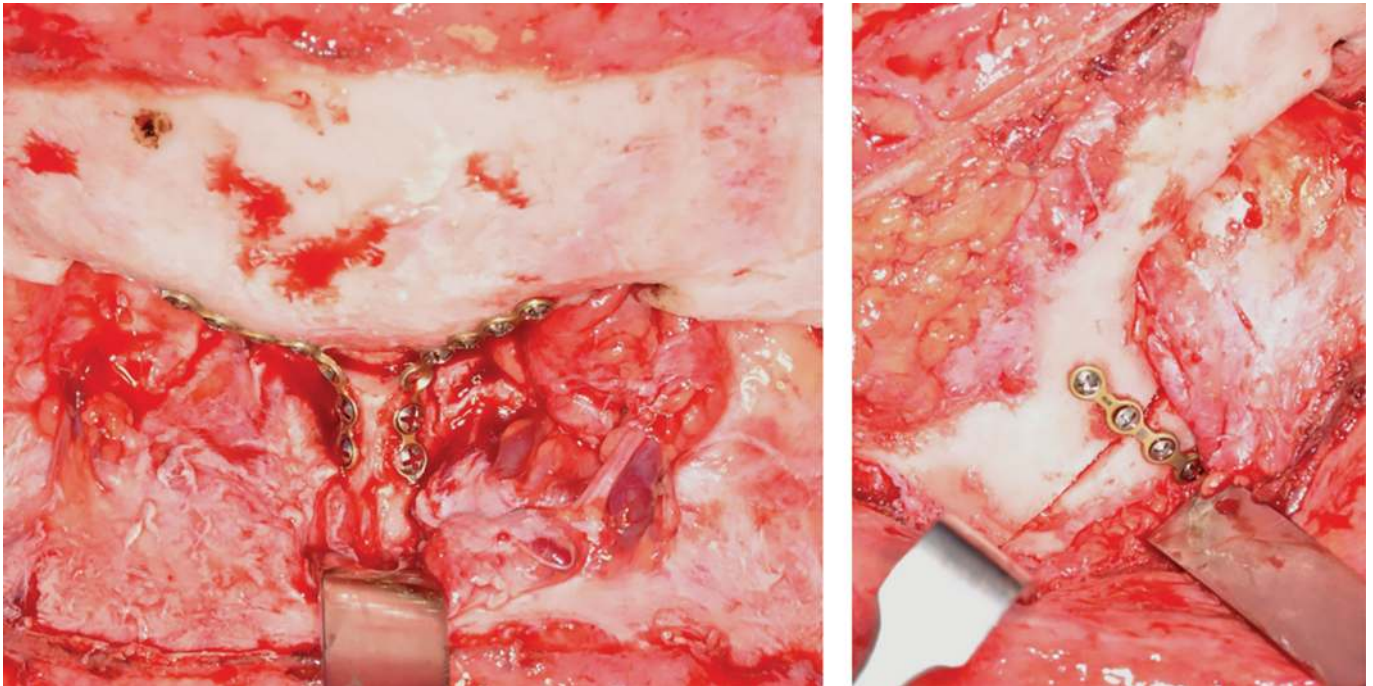
The case planning was performed through prediction tracings and mounting of models in the semi-adjustable articulator to define the drives for surgery:

4-mm midface advance, 5-mm maxilla advance and 7-mm mandible setback with medium line correction and genioplasty to a 6-mm vertical reduction. The model surgery was performed with the models repositioning in

three segments to make the surgery splints: intermediate splint 1 (after midface reposition), intermediate splint 2 (midface and maxilla operated) and final splint (Figure 2).



**Figure 3.** A) Horizontal osteotomy below the fronto-nasal suture. B) Oblique osteotomy of the zygomatic bone (right side).



**Figure 4.** Stable internal fixation. A) In the fronto-nasal region. B) In oblique osteotomy.

### Operative technique

The surgery was begun through bicoronal access; the incision line was drawn with methylene blue through the head vertex to the preauricular area bilaterally. After subcutaneous infiltration (bupivacaine 0.5% with

epinephrine 1:200.000 U.I.), the incision was begun until the subgaleal plan. To control the bleeding, Raney clips and electrocautery were used. The dissection followed the subgaleal plan to 2 cm above the supraorbital area, and then, a pericranium incision between the temporal

lines was performed. The dissection continued under the periosteum, and the supraorbital vascular-nervous bundle was released from its foramen through an osteotomy with the piezoelectric motor; the orbital content was moved away to perform detachment of the orbital borders until the inferior orbital fissure was identified. During periorbital dissection, the cantal ligament remained intact, and the dissection extended back to the lacrimal apparatus.

Sideways, the outer layer of the deep temporal fascia was incised superiorly to the zygomatic arch and continuously joined with the incision of the pericranium. The dissection was then performed through the layer of fat to achieve the zygomatic arch and extended back to the anterior to expose the zygoma and the lateral wall of the orbit. Afterwards, subperiosteal detachment was conducted over the nasal bones.

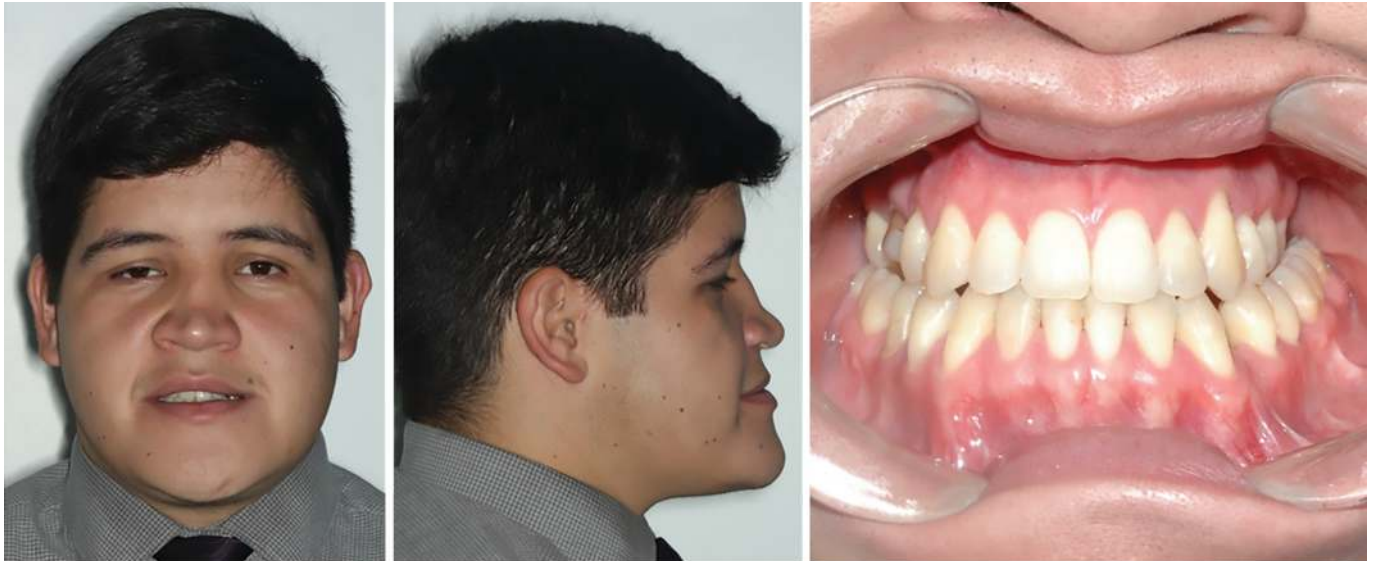

Figure 5. Photos in the postoperative period of 03 years. A) Front view. B) Profile view. C) Occlusal view.

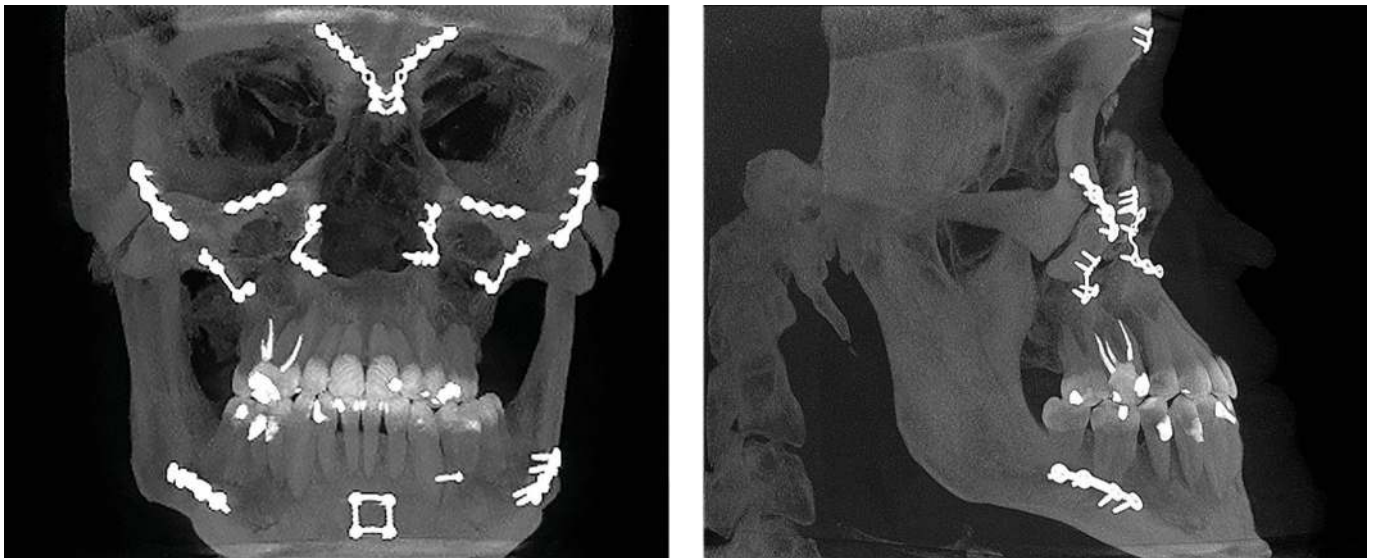


Figure 6. Postoperative CT.

A horizontal osteotomy was performed right below the frontonasal suture, extending laterally through the median orbital surface and posteriorly to the lacrimal

fossa (Figure 3A). On the basis of the tear duct, the osteotomy was directed to the orbital floor. The lacrimal sac was protected with tissue retractors. Then, the oblique

osteotomy was performed on the side of the orbita to the zygomatic bone inferior area (Figure 3B). Through the transconjunctival access bilaterally, a third osteotomy was performed, joining the other two osteotomies through the orbital floor carefully so as not to rupture the infraorbital branch. All osteotomies were performed with the piezoelectric motor and completed with chisels. The chisel was introduced in the nasal bone, perpendicular to the cribriform plate when the separation of the nasal septum from the skull was performed.

In order, the maxilla, mandible and chin were infiltrated with a local anesthetic, and the maxilla was incised bilaterally (Figure 4A, B). The detachment was extended to expose the side walls in the nasal cavity, the posterior area of the maxilla and the inferior area of the zygoma. Using chisels, the osteotomy was completed in the inferior area of the zygoma and posteriorly of the maxilla tuberosity on both sides. A curved chisel was used to promote the pterygoid plates' disjunction.

Rowe forceps were used to mobilize the segment. After the complete manipulation, the maxillo-mandible block with the intermediate split 1 was performed, promoting a 4-mm midface straightforward (including the maxilla). The fixation was performed with two plates and monocortical screws in the frontonasal suture and one straight plate in the oblique osteotomy in the zygoma body bilaterally. A small undesirable fracture occurred in the infraorbital rim on both sides and requiring fixation with miniplates and screws. The maxillo-mandible block was removed, and intermediate occlusion, the symmetry of the advance and the segment stability were checked.

This was followed by the Le Fort I osteotomy and maxilla down fracture to 5 mm advance planned, using as a reference intermediate splint 2, which was fixed with four L plates and screws. After the maxillo-mandible lock was removed, the positioning of the maxilla, upper-incisor exposure and new intermediate occlusion were checked. In order, through BSSO, the mandible was set back to 7 mm, correcting the midline deviation. The segments were fixed with a straight plate and monocortical screws bilaterally. Finally, the genioplasty was held with a 6-mm vertical reduction, and the fixation was performed with plate and monocortical screws. The blocking was removed, and the final occlusion was checked.

The intraoral and transconjunctival approaches were sutured with continuous sutures and absorbable thread. The bicoronal approach was repositioned, and after suspensory sutures in the cantal lateral ligament and

temporal muscle with absorbable thread, the scalp was closed in two layers, the deepest with absorbable sutures and shallowest with nylon 3-0 with portovac drain suction installation. The scalp was held using a compressive bandage around the head and chin.

The patient was kept for the first 48 hours in the intensive care unit. The drain portovac was removed after 48 hours. After five days, the patient was discharged from the hospital.

Currently, after three years of postoperative follow-up he shows significant improvement in chewing ability, denies respiratory and visual complaints and has no pain or functional complaints. In addition, patient reports high satisfaction with the aesthetics (Figure 5A, B, C).

Postoperative computed tomography demonstrates the stability of fixation (Figure 6).

## **DISCUSSION**

Maxilla hypoplasia is a common diagnosis in the spectrum of dentofacial deformities and is usually corrected by a Le Fort I osteotomy to maxilla advance. However, when we encounter a severe midface hypoplasia, we should consider that facial appearance is heavily influenced by the periorbital area. This area includes the eyeballs, eyelids, eyebrows and cheeks. The symmetry, form and position of these components are extremely important because little alterations in this area contribute significantly to an individual's appearance<sup>11</sup>.

Depending on the extent of midface hypoplasia, the surgical treatment of the deformity could be performed by a quadrangular Le Fort I or by Le Fort II osteotomy. However, these techniques do not properly correct the malar hypoplasia that could be presenting<sup>10</sup>. Other approaches have been used, such as the Le Fort I osteotomy with an increased infraorbital region. Procedures like higher Le Fort I osteotomies, without addressing the infraorbital region, can lead to the patient having a sunken appearance in the upper portion of the midface. The simultaneous increase in the infraorbital area with alloplastic associated with Le Fort I, leads to graft communication with the maxillary sinus and may subsequently become infected. Bone grafts used to increase the infraorbital rim are unpredictable in their resorption rate and are uncomfortable to the patient. Thus, for these cases, a Le Fort III osteotomy or one of its modifications is more appropriate<sup>12</sup>.

In non-syndromic cases, the conventional Le Fort III osteotomy, though it will correct deformities at

the naso-orbit-malar level, could result in enophthalmos, and in cases of normal nasal projection, it can result in an undesirable increase in nasal prominence. In addition, even with the greatest advances, a deformity in the lateral orbital arches can be found. To avoid this, modifications in the Le Fort III osteotomy were proposed. In 1971, Kufner<sup>13</sup> proposed a modification to correct midface projection deficiencies without involving the nasal subunit. The modification involves an osteotomy in the orbital lateral border to the zygoma body, through the orbital floor, through the inferior orbital fissure, and through the maxilla to the side wall of the nasal cavity. Other advantages of this modification include midface stabilization, avoiding the need for bone grafting, facilitating the fixing of the plates, allowing greater bone interfacing and the postoperative protection of the orbital sclera.

Cheung et al.<sup>10</sup> described the application of an oblique modified Le Fort III osteotomy that included the bones in the nose in addition to a Le Fort I osteotomy with segmentation for treatment of non-syndromic patients with maxillary hypoplasia in three patients, obtaining satisfactory results.

The patient with the midface deficiency associated with maxillary deficiency has been well described in the literature. Technical problems arise when the maxilla and midface require different movements, when different midline deviation presents or when the maxilla should be segmented<sup>12</sup>. When the maxilla and midface movements are confronted, it is necessary to perform the Le Fort I associated with the Le Fort III osteotomy. Le Fort I osteotomy association is also especially useful in cases in which there is a difference in the extent of the midface hypoplasia in the orbital region in relation to a maxillo-mandibular discrepancy<sup>14</sup>.

The biggest advantage of simultaneous Le Fort III and Le Fort I osteotomies is that both, midface deformity and maxilla, can be addressed in a predictable manner and simultaneously in separate segments, resulting in optimal aesthetic results when the horizontal maxilla deficiency differs significantly from the infraorbital areas<sup>12</sup>. In addition, it minimizes the advancement in the Le Fort III osteotomy, reducing the need for bone grafts<sup>14-15</sup>.

The patient in this report had midface hypoplasia involving the nasal bones, zygoma, inferior orbital rims and maxilla bone. His maxillo-mandibular discrepancy was greater than his midface deficiency, mainly due to its severe mandibular prognathism. However, a very large mandibular

setback could damage the patient's airway. Thus, for the midface approach, the surgical technique was chosen based on the modification performed by Cheung et al.<sup>10</sup> with a Le Fort III osteotomy involving the nasal bones and the Le Fort I osteotomy, allowing further advancement of the maxillary alveolar segment.

The Le Fort III osteotomy is considered a complex technique, representing a challenge to surgeons due to the risk associated with several complications that could be a mild recurrence and extending to blindness and death<sup>14</sup>. Therefore, it should be considered only in specific cases in which it is impossible to resolve the patient's deformity and complaints with other less complex techniques. In addition, the patient must have been in good physical condition to support the procedure due to prolonged operative time and extensive blood loss.

The patient who will be subjected to these extensive reconstructions should be aware of the possible transoperative and postoperative complications. In the preoperative period, the preparation for possible transoperative complications should be performed, a bed should be booked in the intensive care unit and erythrocyte concentrates reservation. The patient should also be accompanied by a multidisciplinary team including an ophthalmologist, otolaryngologist, nutritionist, psychologist, physiotherapist and speech therapist.

Moreover, it is important to clarify that dentofacial deformities arise from skeletal defects involving the three planes of space, and careful planning is required for the correct three-dimensional positioning of all segments. Any planning error can result in subsequent errors, preventing proper correction of the deformity. Thus, both the surgeon and orthodontist have a fundamental function in surgical planning for the correct management before and after the intervention, enabling occlusion, oral function and appropriate aesthetic appearance.

## Collaborators

AM SEBASTIANI was responsible for writing the article. LE KLUPPEL was responsible for performing the reported surgery and organizing the article. F ANTONINI was responsible for the case and performing the planning, clinical documentation and co-supervision of the writing of the article. DJ COSTA, NLB REBELLATO and RS MORAES were responsible for the planning and execution of the treatment and writing the article.

## REFERENCES

1. Santos R, Sebastiani AM, Todero SRB, Moraes RF, Costa DJ, Rebelatto NLB, et al. Complicações associadas à osteotomia sagital dos ramos mandibulares. *Rev Cir Traumatol Bucocomaxillofac.* 2012;12(1):77-84.
2. Vu DD, Tiwana OS. Le Fort III and Le Fort II osteotomies. *Atlas Oral Maxillofacial Surg Clin N Am.* 2016;24:15-25.
3. Hariri F, Lan TH, Cheung LK. Simultaneous Le Fort III and Le Fort I osteotomies for correction of midface hypoplasia in Crouzon syndrome. *Asian J Oral Maxillofac Surg.* 2011;23(3):128-33. doi: 10.1016/j.ajoms.2011.04.002
4. Saltaji H, Altalibi M, Major MP, Al-Nuaimi MH, Tabbaa S, Major PW, et al. Le Fort III distraction osteogenesis versus conventional Le Fort III osteotomy in correction of syndromic midfacial hypoplasia: a systematic review. *J Oral Maxillofac Surg.* 2014;72(5):959-972. doi: 10.1016/j.joms.2013.09.039
5. Dai J, Wang X, Yu H, Cheng J, Yuan H, Gui H, et al. Simultaneous Le Fort I, II, and III osteotomies for correction of midface deficiency in apert disease. *J Craniofac Surg.* 2012;23(5):1391-5. doi: 10.1097/SCS.0b013e3182565a5d
6. Gilles H, Harrison SH. Operative correction by osteotomy of recurred malar-maxillary compound in a case of oxycephaly. *Br J Plast Surg.* 1950;3(2):123.
7. Tessier P. Total osteotomy of the middle third of the face for faciostenosis or for sequelae of Le Fort 3 fractures. *Plast Reconstr Surg.* 1971;48(6):533-41.
8. Magraw CB, Garaas R, Shaw A, Phillips C, Turvey TA. Changes in scleral exposure following modified Le Fort III osteotomy. *Oral Surg Oral Med Oral Pathol Oral Radiol.* 2015 Aug;120(2):119-24. e1. doi: 10.1016/j.oooo.2015.04.005
9. Schmitz JP, Tiner BD, van Sickels JE. Stability of simultaneous modified LeFort III/LeFort I osteotomies. *J Craniomaxillofac Surg.* 1995 Oct;23(5):287-95.
10. Cheung LK, Ow A, Chua HD. Simultaneous modified oblique Le Fort III and segmentalized Le Fort I osteotomies. *J Oral Maxillofac Surg.* 2010 Apr;68(4):915-23. doi: 10.1016/j.joms.2009.06.009
11. Soydan SS, Bayram B, Sar C, Uckan S. Change in inferior sclera exposure following Le Fort I osteotomy in patients with midfacial retrognathia. *J Oral Maxillofac Surg.* 2014;72(166):e161-e165
12. van Sickels JE, Tiner BD. A combined Le Fort I and bilateral zygomatic osteotomy for management of midface and maxillary deficiency. *J Oral Maxillofac Surg.* 1994 Mar;52(3):327-31. doi: 10.1016/0278-2391(94)90312-3
13. Kufner J. Four-year experience with major maxillary osteotomy for retrusion. *J Oral Surg.* 1971;29(8):549-53.
14. Nout E, Cesteleyn LL, van der Wal KG, van Adrichem LN, Mathijssen IM, Wolvius EB. Advancement of the midface, from conventional Le Fort III osteotomy to Le Fort III distraction: review of the literature. *Int J Oral Maxillofac Surg.* 2008 Sep;37(9):781-9. doi: 10.1016/j.ijom.2008.04.006
15. Saltaji H, Altalibi M, Major MP, Al-Nuaimi MH, Tabbaa S, Major PW, et al. Le Fort III distraction osteogenesis versus conventional Le Fort III osteotomy in correction of syndromic midfacial hypoplasia: a systematic review. *J OralMaxillofac Surg.* 2014 May;72(5):959-72. doi: 10.1016/j.joms.2013.09.039

Received on: 16/3/2016

Final version resubmitted on: 23/6/2016

Approved on: 14/9/2016