

# Left atrial tachycardia after circumferential pulmonary vein ablation for atrial fibrillation: incidence, electrophysiological characteristics, and results of radiofrequency ablation

Isabel Deisenhofer\*, Heidi Estner, Bernhard Zrenner, Juergen Schreieck, Sonja Weyerbrock, Gabriele Hessling, Konstanze Scharf, Martin R. Karch, and Claus Schmitt

Deutsches Herzzentrum München and 1. Medizinische Klinik, Klinikum rechts der Isar, Technische Universität München, Lazarettstrasse 36 D-80636 München, Germany

Received 24 December 2005; accepted after revision 5 May 2006

## KEYWORDS

Circumferential pulmonary vein ablation;  
Atrial fibrillation;  
Left atrial tachycardia;  
Proarrhythmia;  
Re-entry;  
Small-loop

**Aims** To investigate the incidence, electrophysiological properties, and ablation results for left atrial (LA) tachycardia as a sequel to the circumferential pulmonary vein ablation (CPVA) for atrial fibrillation (AF).

**Methods and results** Sixty-seven patients with AF underwent CPVA. Sustained LA tachycardia developed in 21/67 (31%) patients and in 16/21 symptomatic patients 55 LA tachycardias ( $3.4 \pm 2.4$  per patient) were mapped: 18 (33%) tachycardias were related to macro-re-entry around the mitral valve (7) or pulmonary vein(s) (11). In 20 tachycardias (36%), a 'small-loop' LA re-entrant tachycardia (LART) was identified; gaps in prior ablation lines (7 LART) or an area of extremely slow conduction adjacent to the CPVA lesions (13 LART) were crucial for these re-entries. Seventeen tachycardias (31%) were too unstable for complete mapping. Ablation was a primary success in 34 of 38 (89%) mapped LART, but in eight of 21 procedures, cardioversion was necessary to achieve sinus rhythm.

**Conclusion** LART develops in a high percentage of patients after CPVA. Small-loop re-entry, which is difficult to map, may arise and patients suffer from several and/or unstable variants of LART. Thus, mapping and ablation of these LART is challenging and the overall success is yet not satisfactory.

## Introduction

In recent years, with the help of an electroanatomical mapping system, the circumferential pulmonary vein ablation (CPVA) technique, aiming at encircling the pulmonary veins (PVs) by linear ablation lesions placed outside the PV ostia, has been used to treat patients with atrial fibrillation (AF).<sup>1</sup> It has been reported that CPVA may cure paroxysmal or persistent AF in a high percentage of patients.<sup>2,3</sup> However, there may be a proarrhythmogenic impact of linear lesions placed in the left atrium with respect to the occurrence of other atrial arrhythmias, particularly left atrial (LA) tachycardias. Experimental studies have shown that surgical lines placed in the LA of a dog (to simulate unilateral or bilateral lung transplantation) created electrophysiological conditions for macro-re-entry and LA flutter.<sup>4</sup> Several clinical studies have described the

development of stable LA tachycardias following radiofrequency ablation for AF.<sup>3,5–8</sup> Furthermore, with respect to linear lesions, several studies have demonstrated that creation of continuous transmural linear lesions in some regions of the LA is difficult and that lesion discontinuities are associated with gap-related atrial tachycardias.<sup>6,8,9</sup>

We undertook this prospective study to assess the incidence of LA re-entrant tachycardia (LART) in patients with AF following the CPVA approach. We performed electroanatomical mapping of sustained LART for identification of the re-entrant circuit and we evaluated the acute success of ablation as well as the outcome in follow-up.

## Methods

### Patients

This prospective study included 67 consecutive patients (43 men, 24 women; mean age  $58.3 \pm 8.1$  years) with symptomatic AF (paroxysmal AF in 57 patients and persistent AF in 10 patients) who

\* Corresponding author. Tel: +49 89 1218 2020; fax: +49 89 12184593.  
E-mail address: deisenhofer@dhm.mhn.de

**Table 1** Baseline characteristics of the patients undergoing CPVA

Patients characteristics	Value	Range
Number of patients ( <i>n</i> )	67	
Male ( <i>n</i> )	43	
Female ( <i>n</i> )	24	
Age (years)	58.3 ± 8.1	38–78
LA diameter (mm)	46 ± 7	36–50
Paroxysmal AF/persistent AF ( <i>n</i> )	57/10	
Duration of AF (years)	5 ± 4	1–14
Antiarrhythmic drugs (number per patient)	2.1 ± 0.7	1–5
Patients on amiodarone	10	
Structural heart disease ( <i>n</i> )	39 (58%)	
Arterial hypertension with LVH	27	
CAD	12	

If applicable, values are shown as mean ± standard deviation; LVH, left ventricular hypertrophy; CAD, coronary artery disease.

underwent CPVA in our hospital between March 2002 and February 2004. The baseline characteristics of the patients are shown in *Table 1*. Structural heart disease was present in 39 of 67 patients (58%) and all patients had drug-refractory AF despite the use of a mean of 2.1 ± 0.7 antiarrhythmic drugs including amiodarone (10 patients). All patients gave written informed consent for recruitment into the study and ablation procedure. The study protocol was approved by the institutional Ethics Committee.

### Initial electroanatomic mapping and ablation procedure

CPVA technique was performed as previously described.<sup>9</sup> After accessing the left atrium through a transseptal puncture (60 patients) or an open foramen ovale (seven patients), the geometry of the left atrium, the PV ostia, and the mitral annulus were reconstructed using an electroanatomical mapping system (CARTO System, Biosense-Webster, Diamond Bar, CA, USA). Two linear lesions encircling the left and right ipsilateral PV, respectively, were created at a minimum distance of 0.8–1 cm from the PV ostia. An additional line, bridging the posterior–inferior part of the left encircling lesion to the mitral annulus (mitral isthmus line), was drawn in all patients. In agreement with the criteria described elsewhere,<sup>9</sup> the endpoint of the ablation procedure was the decrease of the maximum local bipolar electrogram amplitude by ≥80% or to ≤0.1 mV (peak-to-peak potential in the voltage maps of the left atrium) on the ablation line. Therefore, we did not perform testing of completeness of conduction block across the encircling lesions or across the mitral isthmus line. Radiofrequency ablation was performed with an open irrigated tip catheter (45 patients; Navistar thermocouple, Biosense-Webster) at a maximum temperature of 48°C and a maximum power of 55 watts, or with an 8-mm tip ablation catheter (22 patients; Navistar, Biosense-Webster) with a maximal temperature of 60°C and a power limit of 60 watts.

### Follow-up

All patients underwent a meticulous post-ablation follow-up protocol including visits in our arrhythmia outpatient clinic at 1, 3, and subsequently after every 3 months. During each visit, patients were intensively questioned for symptoms suggestive of atrial arrhythmias since the last follow-up visit. Continuous 7-day Holter monitoring was recorded to screen for AF recurrences or occurrence of regular atrial tachycardias 3, 6, and 12 months after the initial procedure.

## Definitions

Atrial tachycardias were defined as stable and regular atrial activations on the 12-lead surface electrocardiogram or 12-lead Holter monitoring recordings with an atrial cycle length of 180–350 ms lasting for at least 10 min.

The diagnosis of LART as opposed to focal tachycardia was based on the coverage of at least 90% of the whole tachycardia cycle length in the electroanatomical Carto-mapping of the left atrium with a continuously increasing delay of local activation time along the presumed re-entrant circuit, until the area with the latest local activation time met the area with the earliest local activation time again ('early meets late'). The possibility to entrain the tachycardia with pacing at a cycle length 20–30 ms shorter than the tachycardia was regarded as an additional indicator of an underlying re-entrant mechanism of the tachycardia.

### Study group

During the follow-up, 29 of 67 patients (43%) had stable atrial tachycardias documented electrocardiographically and in 21 patients, stable atrial tachycardia became incessant. In 16 of 21 patients with sustained and symptomatic tachycardia, a total of 21 mapping and ablation procedures (mean 1.3 ± 0.5; 1 or 2 per patient) was performed under guidance of the electroanatomical mapping system. These patients are referred to as the study group.

### Mapping and ablation procedure for LA tachycardias

EP study was performed in the fasting state, with all antiarrhythmic drugs, other than amiodarone, ceased for 4–5 half lives, after written informed consent was obtained. An octapolar steerable catheter was placed in the coronary sinus. The left atrium was accessed through a transseptal puncture (14 patients) or an open foramen ovale (two patients) with a 7-F roving mapping/ablation catheter (Navistar thermocouple with an open irrigated tip, Biosense-Webster). A heparin bolus of 5000 U was given intravenously followed by a continuous infusion to maintain the activated clotting time at levels of 270–320 s.

### Electroanatomical mapping

Colour-coded electroanatomical maps of the left atrium during spontaneous or induced-atrial tachycardias were performed by inserting electrophysiological information into the 3-D geometry of the left atrium. Early and late activation sites were coloured red and purple, respectively. A minimum of 50 points and coverage of at least 90% of the cycle length was required for a complete map of the LA tachycardia.

### Entrainment mapping

In stable tachycardias showing an activation pattern that indicates an underlying re-entry mechanism, entrainment pacing from at least two locations was performed. Entrainment pacing was regarded 'positive' when the post-pacing interval exceeded the tachycardia cycle length by no more than 20 ms.<sup>10</sup> In case of tachycardias with a short cycle length (<190 ms) or when spontaneous variations in the tachycardia cycle length or morphology were observed, entrainment pacing was not attempted, to avoid degeneration into AF or to another form of tachycardia.

### Classification of re-entrant tachycardia

Macro-re-entry and small-loop re-entry were differentiated according to the mapped activation pattern of the LA and the size of the re-entrant circuit. A macro-re-entry circuit propagated in a large part of the LA with a minimum diameter >3 cm, whereas a small-loop re-entrant circuit showed a diameter <3 cm and coverage of the whole cycle length together with centrifugal activation of the remainder of the LA.<sup>10</sup> Small-loop re-entrant tachycardias were further divided into gap-related tachycardia and extremely slow

conduction related tachycardia. In the gap-related tachycardia, the re-entrant circuit crossed the previously deployed CPVA lesions at least twice (in two gaps or one large gap), whereas in extremely slow conduction related tachycardia, the re-entrant circuit was not located across but adjacent or tangential to the previously deployed CPVA lesions. The characterizing feature of the latter re-entrant tachycardias was a small, distinctive area of markedly slow conduction maintaining the re-entry.

### Ablation

Radiofrequency ablation was performed with an open irrigated tip catheter (Navistar thermocouple, Biosense-Webster) with a maximum temperature of 48°C and a power limit of up to 50 watts. The strategy of ablation differed according to the nature of the atrial tachycardia. In the case of macro-re-entrant LA tachycardias, the intention was to cut the re-entry circuit by connecting two adjacent non-conductive structures with a linear lesion. In the case of small-loop re-entry related to gaps in the prior ablation lines or tangential to prior lines, a closure of gaps or a short line crossing the slow conduction zone of the re-entry was attempted.

Termination of tachycardia during ablation or change to a different atrial tachycardia and non-inducibility with programmed and burst stimulation was considered as a primary success with regard to an individual tachycardia.

Data are presented as counts (proportion of patients or tachycardias) or mean  $\pm$  standard deviation.

## Results

### Incidence of atrial tachycardia after CPVA

Of the 67 patients treated with CPVA for paroxysmal (57 patients) or persistent AF (10 patients), 29 patients (43%) experienced atrial tachycardia  $3.2 \pm 3.1$  months after initial CPVA. In eight of these, LA tachycardia could be observed only transiently. Of the 21 patients with sustained LA tachycardia, 16 highly symptomatic patients (11 men, five women; mean age  $57 \pm 7.7$  years) were willing to undergo a repeat ablation. In these 16 patients, a total of 21 procedures (mean  $1.3 \pm 0.5$  procedure per patient) was performed with five patients requiring a third procedure for recurrent atrial tachycardia. The mapping and ablation procedures for LA tachycardia were performed  $4.4 \pm 3.6$  months after initial ablation procedure. The procedural data are shown in *Table 2*.

### Mapping and ablation of LA tachycardia

In 13 of 16 patients, more than one type of sustained atrial tachycardia (range 2–6) was observed during one mapping/ablation procedure. Thus, a total of 55 different LA tachycardias was observed (mean  $3.4 \pm 2.4$  per patient and  $2.7 \pm 1.5$  per procedure). The mean cycle length of tachycardia was  $264 \pm 41$  ms and an underlying re-entrant mechanism could be proved in all tachycardias in which the entrainment pacing was feasible.

Two types of LART were observed and mapped: macro-re-entrant and small-loop. The latter was related to gaps in formerly deployed ablation lines or to areas of extremely slow conduction located tangential to the CPVA lesions (*Figure 1*).

### Macro-re-entrant LART

Eighteen of the 55 LART (33%) were macro-re-entrant tachycardias around an anatomical conduction barrier. In five, more than one potential loop could be depicted in the

**Table 2** Procedural data of the 21 mapping/ablation procedures for LART

<i>n</i> = 16 patients, <i>n</i> = 21 procedures	Mean $\pm$ standard deviation	Range
Procedures per patient ( <i>n</i> )	$1.3 \pm 0.5$	1–2
Procedure duration (min)	$283.2 \pm 66$	160–390
Fluoroscopy time (min)	$47 \pm 22$	7.2–108
Fluoroscopy dose (Gy/cm <sup>2</sup> )	$49.3 \pm 25.7$	9.8–98.3
Number of LART/patient ( <i>n</i> )	$3.4 \pm 2.4$	1–6
Number of LART/procedure ( <i>n</i> )	$2.7 \pm 1.5$	1–6
Cycle length (ms)	$264 \pm 41.1$	180–330

Carto map. In this situation, entrainment manoeuvres helped to differentiate the active and bystander re-entrant loop. Electroanatomical maps revealed perimitral re-entry in seven of 18 (*Figure 2*). In 11 of 18 macro-re-entrant LART, re-entry around one or both ipsilateral PV was observed. In 17 of 18 macro-re-entrant LART, ablation was primarily successful.

Perimitral re-entry was stopped in three of four instances by redrawing the left isthmus line. In the remaining three perimitral LART, an anterior line connecting the anterolateral mitral annulus to the ostium of the left superior PV stopped the tachycardia.

In nine patients with 11 periPV LART (two patients had periPV re-entry on both sides), a line in the LA roof connecting the two superior PV ostia was created in six patients. In three patients with only perileft PV re-entry, a short line connecting the LA appendage (LAA) to the left superior PV was created. Tachycardia was ablated successfully (stopped or changed to another LART form) in all nine patients and 11 LART. (*Figure 3*)

### Small-loop LART

In 20 of 55 atrial tachycardias (36%), a small-loop re-entry was demonstrated in electroanatomical mapping.

### Gap-related LART

Seven of 20 small-loop LART were related to gaps in the prior ablation lines. The gaps in the ablation lines were located along the left encircling lesions in five cases (anterosuperior aspect or between left superior PV and opening of the LAA in four cases, and posteromedial in one case) and in the right encircling lines in two cases (anterior aspect and infero-posterior aspect) (*Figure 4*).

Ablation was performed successfully in six of seven LART by closing the gaps. The LART related to gaps in the infero-posterior right encircling lesion could not be ablated successfully. Presumably, catheter instability in this location prevented a complete transmural lesion.

### LART due to areas with extremely slow conduction

In 13 LART, the tachycardia was dependent on a small area with extremely slow conduction. In all instances of this form of LART, areas exhibiting extremely slow conduction were found to be located adjacent to but not across the prior ablation lines. Slow conduction areas were located superior to LAA opening (6), posterior to LAA opening (3), inferior to the right inferior PV (RIPV) (2), and antero-septal

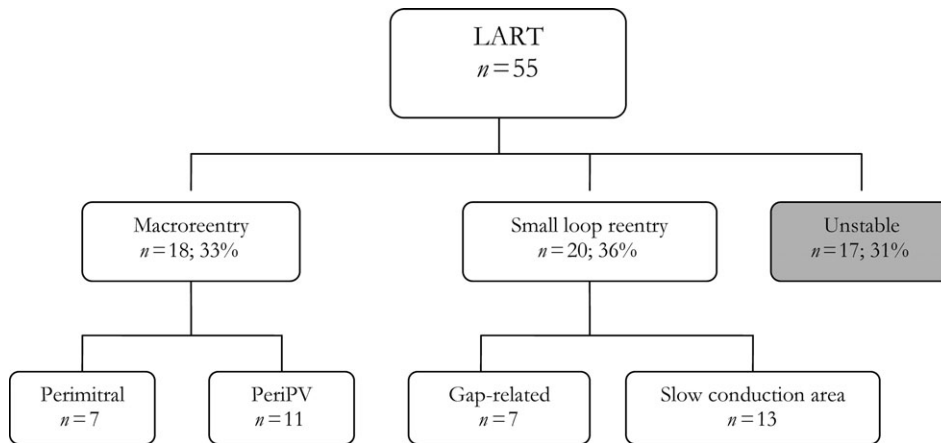


Figure 1 Electrophysiological characterization of LART.

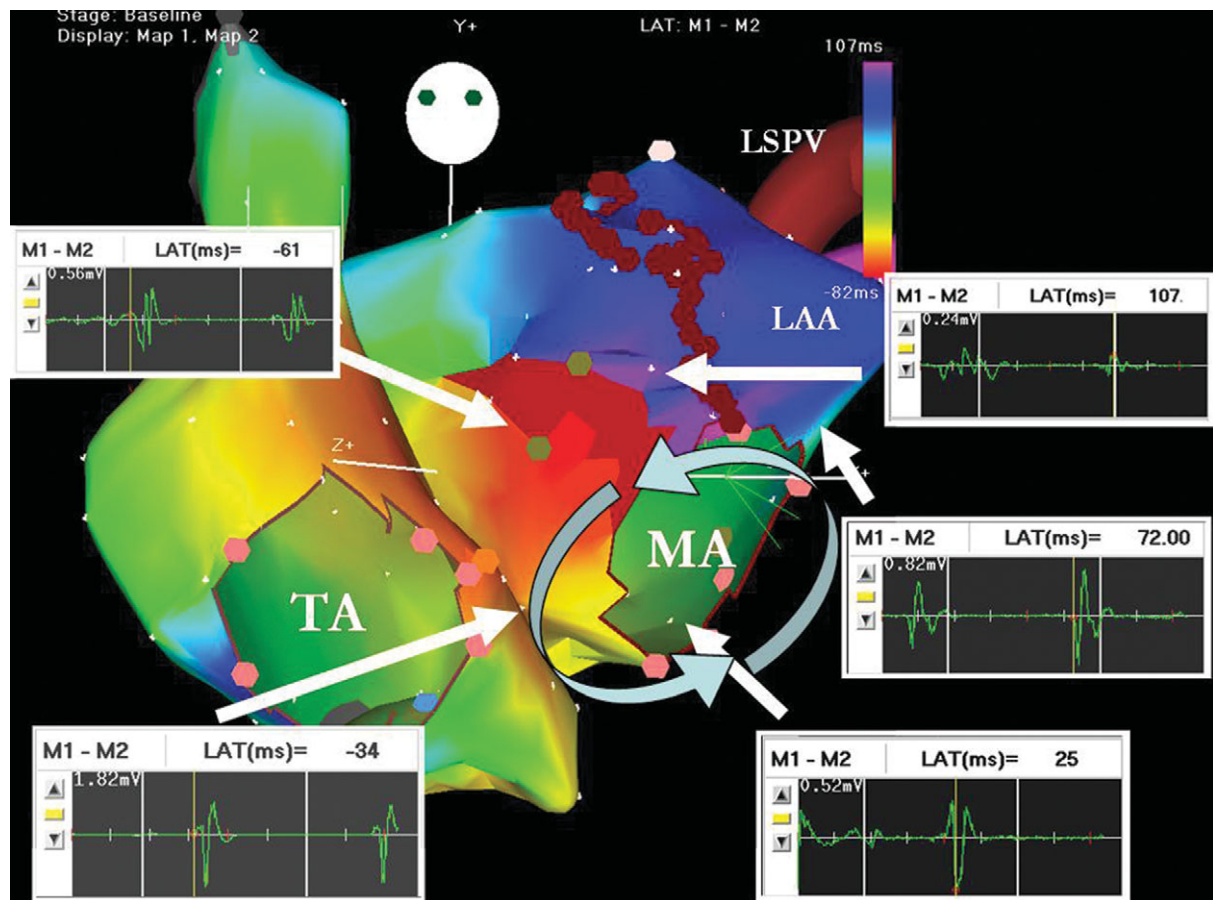
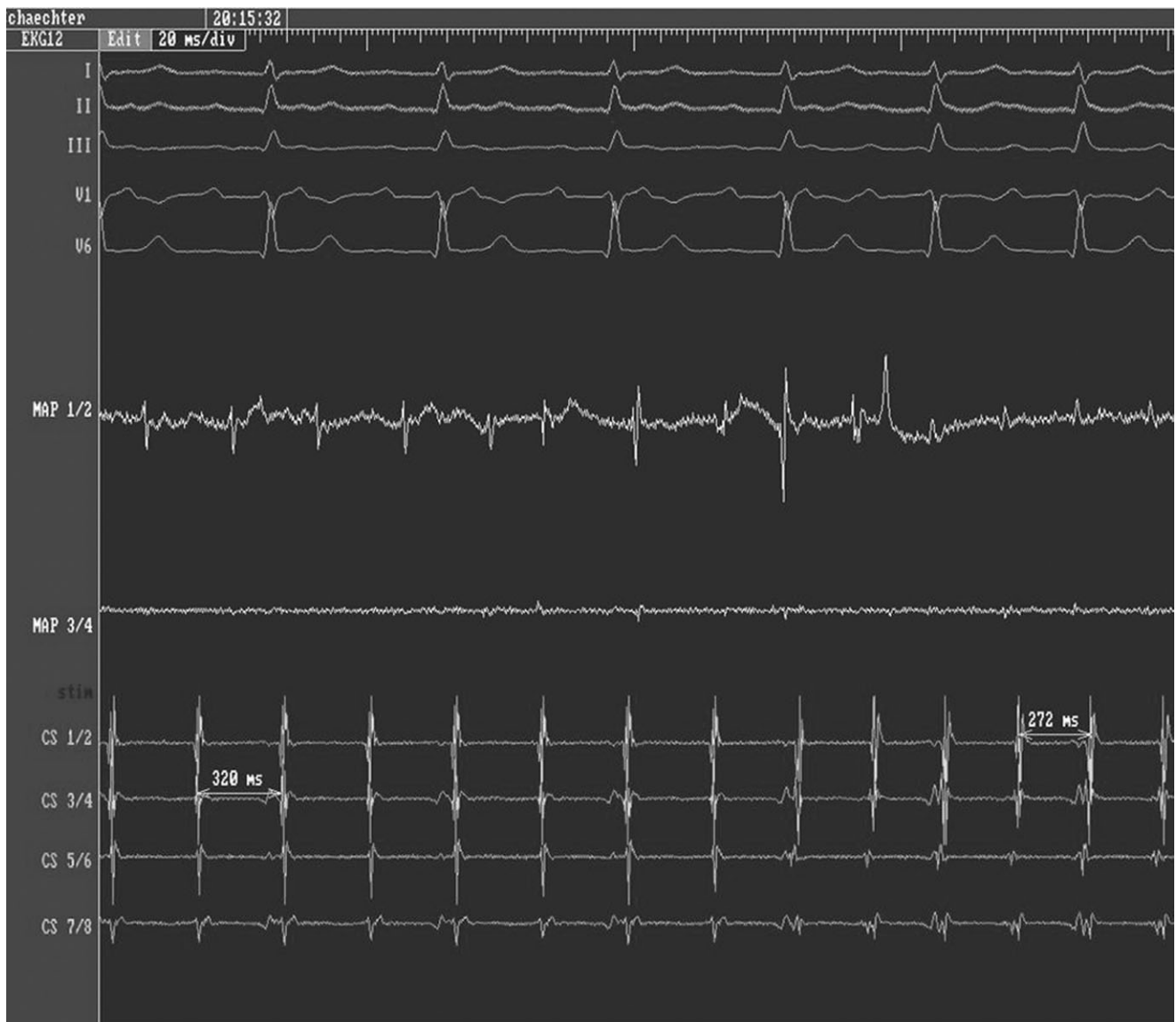


Figure 2 Batrial electroanatomical map of a perimitral re-entry. Modified AP view of the right and left atria. The electroanatomic Carto-mapping shows a re-entry (cycle length = 180 ms) around the mitral valve (MA) with counterclockwise spread of activation around the annulus (rotating arrows). The electrogram inserts show local activation timing measured in the annotation window (limited by the white lines) in representative locations around the mitral annulus. Brown tags depict locations of positive entrainment pacing. The right atrium is activated passively via the interatrial septum. The re-entry was successfully ablated by drawing an anterior ablation line from the anterolateral mitral annulus to the anterior ostium of the left superior PV (red ablation tags). MA, mitral valve annulus; TA, tricuspid valve annulus.

to the right superior PV (RSPV) (2). The rest of the left atrium was activated passively and the whole cycle length could be covered in these very small areas. High-density mapping revealed local electrograms with attributes of

extremely slow conduction. Up to 60% of the cycle length was covered by one fractionated potential lasting up to 140 ms without any appearance of baseline (Figures 5–7). All LART related to extremely slow conduction were



**Figure 3** Change from one LART to another during ablation. Surface ECG tracings and intracardiac recordings during ablation of a perileft PV re-entry by drawing a roofline in between the two superior PVs. The initial cycle length of 320 ms shortens to 270 ms, and the activation sequence in the coronary sinus changes from almost simultaneous to a more proximal to distal activation pattern. A discrete change in the P-wave morphology can also be observed in leads II and III. The roofline was completed (no further change in LART) and a re-map of the LA was performed to delineate the location of the new LART (small-loop posterior to the opening of the LAA).

induced and terminated repeatedly by burst pacing, and entrainment pacing was performed successfully in nine of 13. Because of the small size of the area, the electroanatomical maps, in some instances, did not show a completely clear-cut pattern of a re-entrant circuit. However, the rest of the left atrium was excluded because of post pacing interval (PPI) exceeding the tachycardia cycle length by  $\geq 30$  ms.

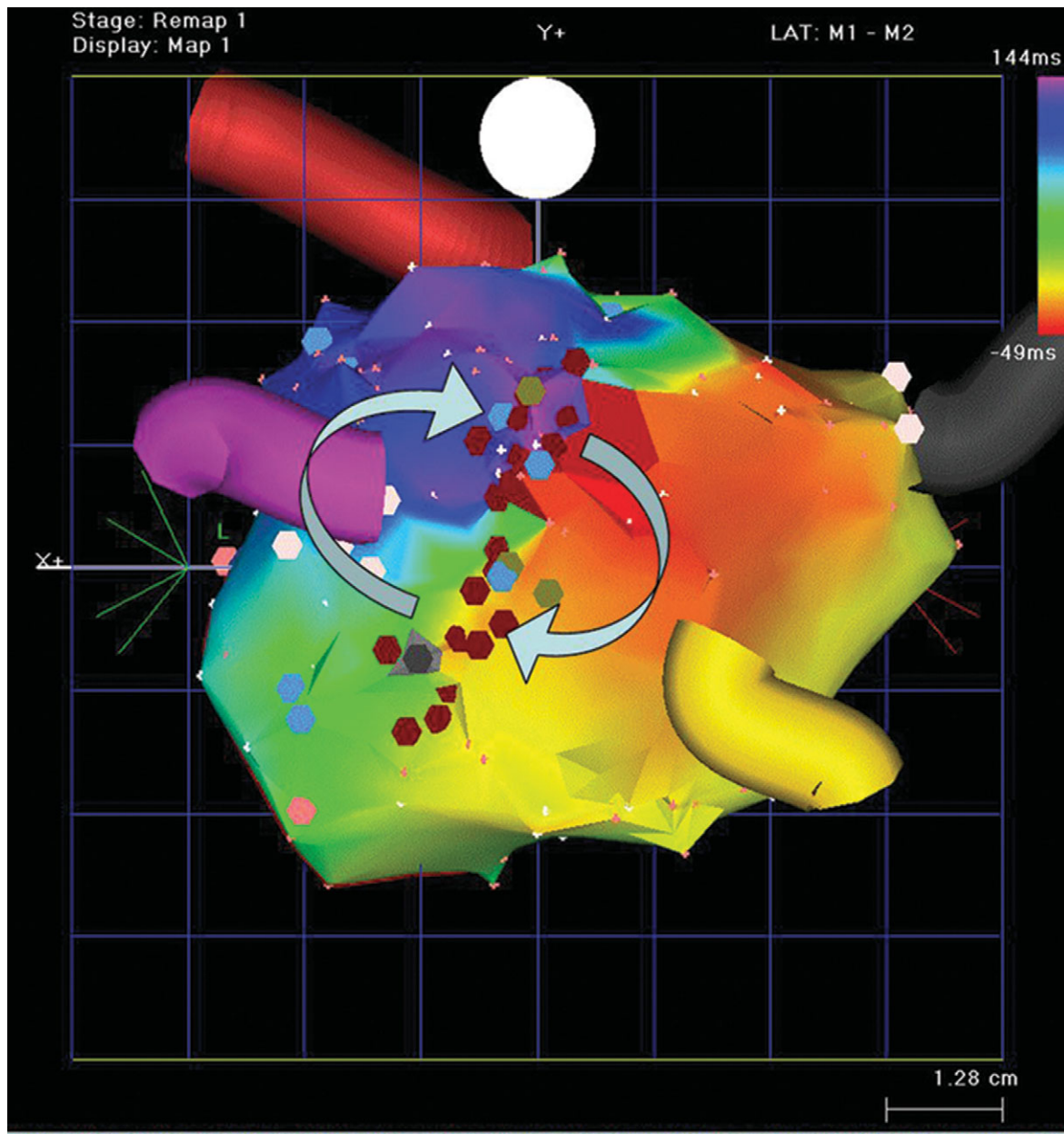
In patients with LART related to extremely slow conduction, a short line in the slow conduction zone terminated the tachycardia in 11 of 13 LART and 10 of 12 patients. Ablation surrounding the opening of the LAA was always successful, whereas one LART located inferior to the ostium of RIPV and one antero-septal to the RSPV could not be successfully ablated: Despite termination of the LART during ablation, the same LART recurred spontaneously or was re-inducible.

### Anatomic locations: the opening of the LAA

With respect to anatomic location, 16 of 38 (42%) completely mapped and analysed LART (three perileft PV, four gap-related, and nine LART related to extremely slow conduction) were dependent on an area of slow conduction in the direct vicinity of the opening of the LAA, mostly between it and the ostium of left superior PV (LSPV). All these LART were successfully ablated in this location.

### Unstable tachycardias

Seventeen of 55 LA tachycardias (31%) could not be adequately mapped using electroanatomical mapping. In 11 of them, the mapping could not be completed due to spontaneous or entrainment-induced change to another tachycardia or AF before completion of the Carto map. In six



**Figure 4** Gap-related re-entry. PA view of the left atrium. The Carto-mapping shows a spread of activation in the clockwise direction on the posterior wall of the left atrium (arrows). This re-entrant circuit (cycle length = 190 ms) is most probably related to two gaps or one large gap in the posterior wall part of the formerly applied ablation line encircling the left-sided PVs. Entrainment mapping confirmed the diagnosis of re-entrant mechanism and the location of re-entry circuit (entrainment was possible in areas tagged brown, small arrows). A short line, redrawing the posterior part of the initially deployed left-sided encircling lesion, stopped the re-entry. Blue tags, double potentials; red tags, ablation sites.

tachycardias, despite complete electroanatomical mapping, the underlying mechanism of tachycardia could not be depicted: A clear 'early-meets-late' area or a focal pattern with passive spread of activation from one focus to the rest of the atria could not be demonstrated. In these tachycardias, entrainment from one location was possible in four, however, radiofrequency application at these sites did not terminate or change the tachycardia.

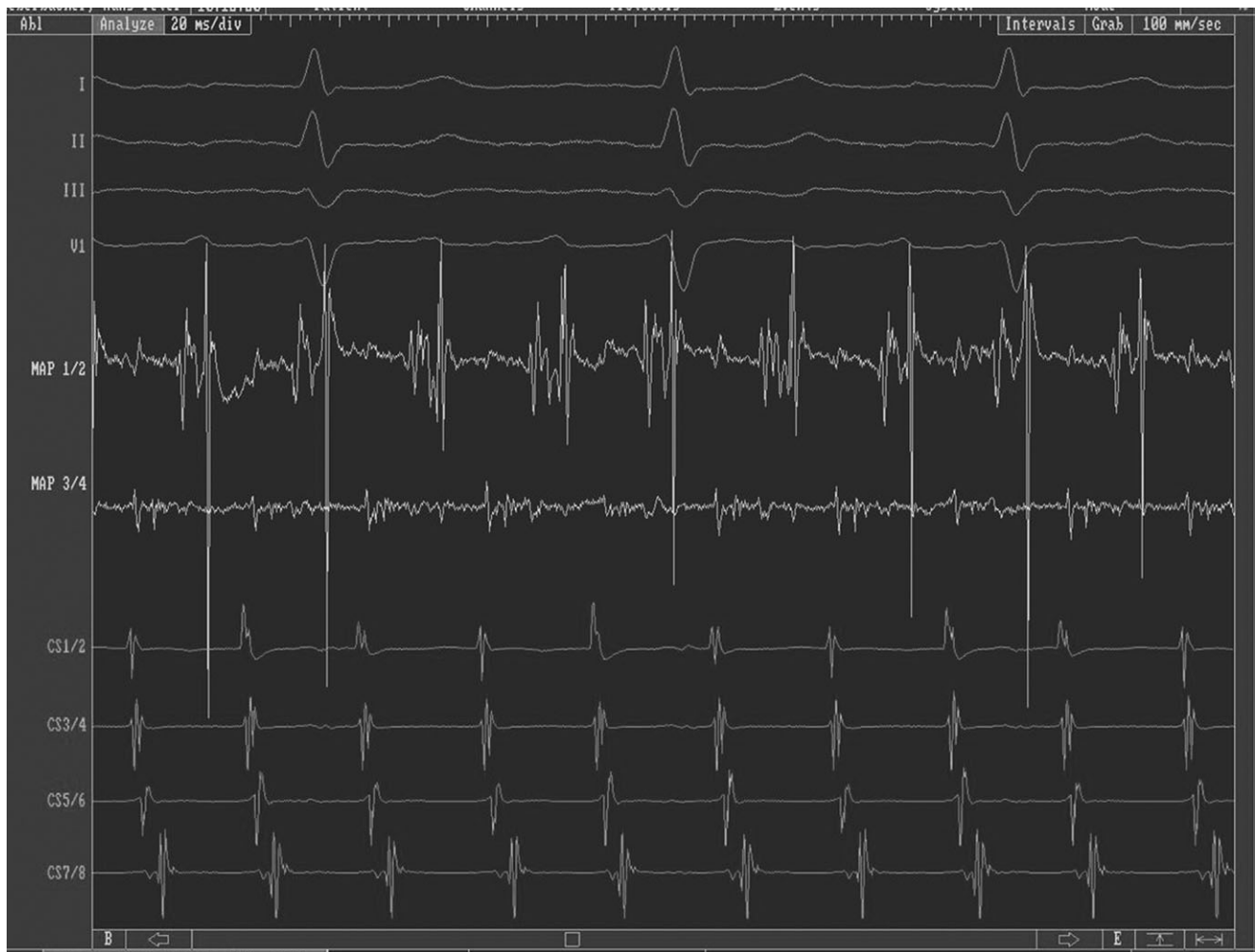#### Procedural success

Overall, 34 of 38 (89%) sustained LART were successfully ablated. Of 21 procedures, 13 (61%) were considered to be

successful in terms of termination (by ablation) of all spontaneous and induced-LART. In eight procedures, LART (five procedures) or AF (three procedures) were still present at the end of the procedure and had to be converted to sinus rhythm by external cardioversion.

#### Follow-up

The 16 patients in the study group were followed-up  $10.4 \pm 6.7$  (range 3–24) months after the ablation procedure for LART. Six of 16 (38%) patients are in stable sinus rhythm (one with flecainide). Paroxysmal AF together



**Figure 5** LART related to an area of extremely slow conduction. Intracardiac recordings and surface ECG tracings of an LART related to an area of extremely slow conduction superior to the opening of the LAA. The electric activity as shown in the two bipolar recordings (MAP 1/2 and 3/4) of the mapping/ablation catheter placed in the slow conduction area covers >60% of the whole cycle length of re-entry. This LART was ablated with four applications forming a very short line across the slow conduction area. Electrograms shown (from top to bottom): surface ECG (leads I, II, III, and VI), intracardiac tracings of the mapping/ablation catheter (MAP 1/2 and 3/4) and of the reference catheter placed in the coronary sinus (CS 1/2 to 7/8).

with LART was documented in 3/16 patients on serial 7-day Holter ECGs.

In 7/16 patients (47%), one or two types of sustained, persistent LART (but no AF) were found. Three patients of the latter group underwent AV node ablation after pacemaker implantation because of ongoing LART with fast AV conduction.

### Complications

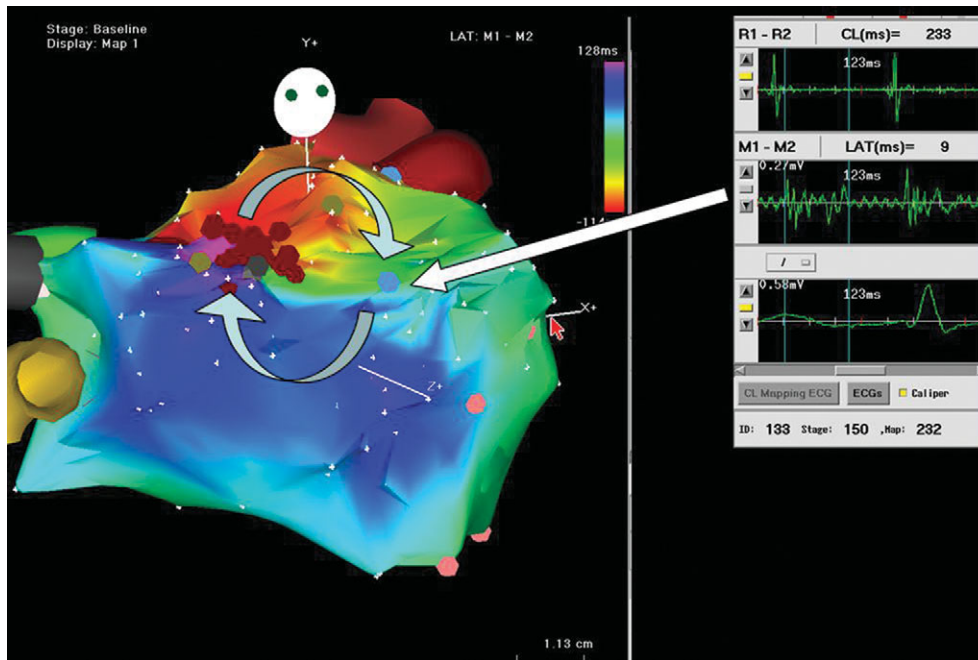
One patient with a perimitral re-entry developed a major stroke with left-sided hemiplegia while redrawing the line between the left inferior PV (LIPV) and the mitral annulus.

### Discussion

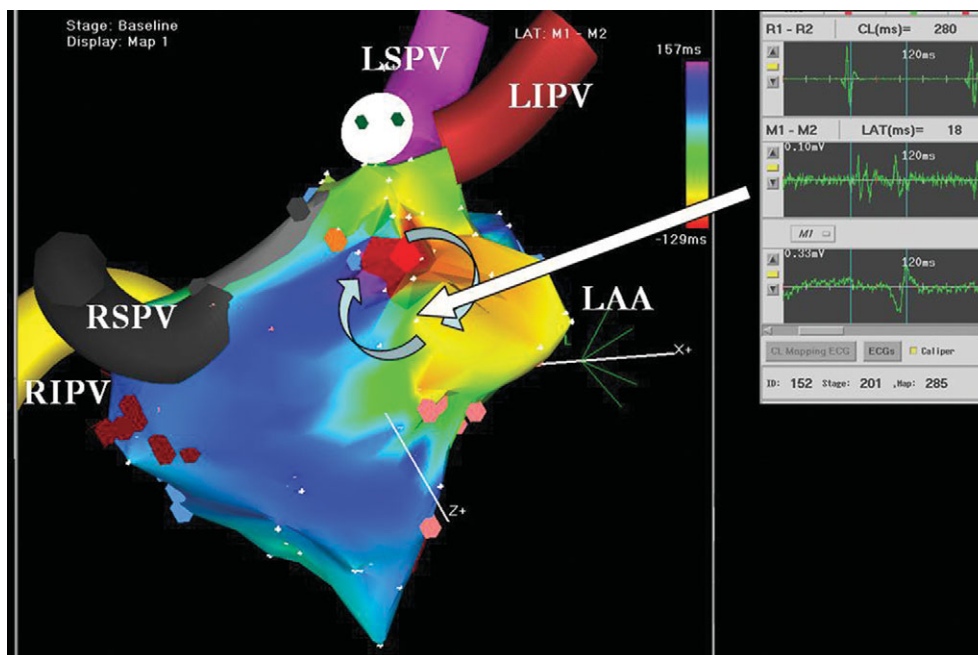
In recent years, the AF ablation technique by the placement of encircling linear lesions outside the PV ostia, i.e. the CPVA approach, has been reported to be an effective curative approach for this arrhythmia.<sup>1-3</sup> Although the technique

might minimize the risk of ablation-related PV stenosis, it is technically demanding and may produce serious, life-threatening complications even in the hands of experienced operators.<sup>11</sup> From a mechanistic point of view, it is believed that CPVA technique not only isolates the PVs known to be the most frequent source of ectopy triggering the initiation of AF,<sup>12</sup> but it also modifies the arrhythmogenic substrate for the maintenance of AF.<sup>9,13-15</sup>

The most important finding of this study was that 31% of the patients having undergone CPVA for AF (21 of 67 patients) developed sustained LA tachycardia with a mean of 3.4 different tachycardias per patient. Our findings support a recent study by Oral *et al.*<sup>3</sup> who reported LA flutter in up to 27% of patients with AF who underwent CPVA plus additional ablation of atrial areas with fractionated electrograms. However, our data are at variance with the data of Mesas *et al.*<sup>8</sup> who reported an incidence of LA flutter after CPVA of 4%. Although the reasons for this discrepancy are not entirely clear, some methodological differences may be of help in this explanation. Our CPVA



**Figure 6** Slow conduction area-related re-entry. Modified AP view. The activation mapping shows an ‘early-meets-late’ zone (colliding of dark red and violet colours) in the anterosuperior part of the LA. The re-entrant circuit of this LART (cycle length is 240 ms) is dependent on an area with highly fractionated local electrograms (see inserted electrogram window on the right), which covers almost 60% of the whole re-entry cycle length and which was recorded in a zone of low-amplitude electrograms. Of note, this area is located close to the opening of the LAA. In 16 of 38 completely mapped LART, a similar slow conduction zone was demonstrated in this anatomic location. Dark red tags mark the ablation area; brown tags, location of positive entrainment pacing, blue tags, fractionated potentials; pink tags, sites on mitral annulus.



**Figure 7** Slow conduction area-related re-entry. LA Carto map (modified RAO view) of a LART related to a slow conduction zone close to the opening of LAA. The cycle length is 280 ms, even though the implicated area of the re-entrant circuit is small. This is mostly due to an area of extremely slow conduction. Local electrogram (insert window on right side) of this area shows markedly fractionated, low amplitude electrical activity lasting as long as 120 ms. The rest of the LA is activated passively. Positive entrainment pace mapping (orange tag) confirmed the diagnosis of the re-entrant nature of this tachycardia. As the very first entrainment mapping attempts briefly destabilized the LART, no second location for entrainment was attempted. Ablation was performed successfully at the exact position of the electrogram shown. To consolidate the ablation effect, it was extended to a short line towards the roof of LA. Blue tags, areas with fractionated electrograms; pink tags, sites on mitral annulus.



linear lesion set did not include posterior linear lesions or linear lesions at the roof of LA that have been found to lower considerably the incidence of LA re-entry.<sup>16</sup> In addition, we used a power limit of 55 watts with an open irrigated tip ablation catheter and of 60 watts with an 8-mm ablation tip, whereas other groups report radiofrequency energy application up to 100 watts (with an 8-mm tip catheter). However, considering the recently reported severe complication of atrio-oesophageal fistula after high-energy ablation especially in the posterior LA,<sup>11</sup> it seems reasonable to restrict the extent of ablation in the posterior part of LA to a necessary minimum and to limit the power during radiofrequency application.

A major finding of this study is related to the underlying mechanisms of LA tachycardia following CPVA. We found that CPVA provides an arrhythmogenic substrate for LA tachycardia by paving the way to re-entry; typically, re-entry around anatomic or ablation-created conduction barriers or through gaps within the linear lesions (gap-related re-entry) was observed after CPVA.<sup>8,17,18</sup> Following the description by Pappone *et al.* of their technique, the lesion set deployed in the CPVA in our study represents more an anatomically guided encircling of the PV than an electric isolation of the PV; thus, the completeness of lines was not the primary objective of the CPVA. However, a recently published study by Ouyang *et al.*<sup>19</sup> with complete circular isolation of the PVs demonstrates impressively the strong correlation between the completeness of linear lesions and the freedom of recurrence of AF and atrial re-entrant tachycardia. Similar to these studies, we could demonstrate that gaps in the previously deployed PV encircling lesions were involved in the genesis of LA tachycardia. As reported,<sup>8,17-19</sup> closure of such gaps by discrete radiofrequency energy application terminated the tachycardia.

We found that a high percentage of LA tachycardias (13/55; 24%) was related to a small area of extremely slow conduction tangential or close to the encircling lesions. Although the exact nature of these rhythms cannot be completely proven in this study, our data suggest that they are of re-entrant nature. Comparable tachycardias with a small re-entrant circuit diameter have been described by Jaïs *et al.*<sup>10</sup> in patients with LA flutter. In a similar manner, we could record, in these tachycardias, areas with extremely slow conduction covering up to 60% of the whole tachycardia cycle length. It is noteworthy that the areas with extremely slow conduction were located on or adjacent to the previously deployed CPVA lesions, suggesting that their occurrence was related to the previous CPVA. The exact link between the CPVA lesions and the occurrence of areas of extremely slow conduction remains a matter of speculation. One hypothesis is that incomplete lesions may create an area of very slowly conducting tissue along the linear lesion that may then serve as a substrate for these re-entrant tachycardias.

We also found that the region between the opening of LAA and the LSPV was frequently a constituent part of re-entrant circuits in patients with LART following the CPVA approach. In nearly all patients in our study group (14 of 16; 88%), a radiofrequency energy application was performed in this area, and at least one form of LART was successfully terminated. This finding may be linked to the anatomic configuration of the area between the LSPV and

the LAA, which is, in most instances, only a small 'rim' of tissue separating these two structures.<sup>20</sup> Thus, it is technically difficult to deploy a transmural lesion on this rim. On the basis of our findings, we recommend that the part of the left encircling lesion between the LAA opening and the LSPV ostium should be given special attention, and that catheter stabilization and thus the transmural nature of the deployed lesions in this area should be given top priority.

## Conclusion

This study demonstrated that CPVA currently in use in patients with AF is associated with the development of sustained LART in more than 30% of patients. The current CPVA scheme with encircling lesions that are not validated for completeness is proarrhythmic because it increases the incidence of sustained LA tachycardia by paving the way to macro-re-entry, gap-related re-entry (discontinuous lesions), and by promoting small-loop re-entrant circuits dependent on areas of extremely slow conduction tangential to the encircling linear lesions.

On the basis of our findings, electrophysiologically assessed completeness of the deployed linear lesions is an indispensable requirement to avoid proarrhythmic complications of CPVA.

## References

1. Pappone C, Rosanio S, Oreto G *et al.* Circumferential radiofrequency ablation of pulmonary vein ostia: a new anatomic approach for curing atrial fibrillation. *Circulation* 2000;102:2619-28.
2. Pappone C, Rosanio S, Augello G *et al.* Mortality, morbidity, and quality of life after circumferential pulmonary vein ablation for atrial fibrillation: outcomes from a controlled nonrandomized long-term study. *J Am Coll Cardiol* 2003;42:185-97.
3. Oral H, Chugh A, Lemola K *et al.* Noninducibility of atrial fibrillation as an end point of left atrial circumferential ablation for paroxysmal atrial fibrillation. A randomized study. *Circulation* 2004;110:2797-801.
4. Gandhi SK, Bromberg BI, Schuessler RB, Boineau JP, Cox JL, Huddleston CB. Left-sided atrial flutter: characterization of a novel complication of pediatric lung transplantation in an acute canine model. *J Thorac Cardiovasc Surg* 1996;112:992-1001.
5. Villacastin J, Perez-Castellano N, Moreno J, Gonzalez R. Left atrial flutter after radiofrequency catheter ablation of focal atrial fibrillation. *J Cardiovasc Electrophysiol* 2003;14:417-21.
6. Ernst S, Ouyang F, Lober F, Antz M, Kuck KH. Catheter-induced linear lesions in the left atrium in patients with atrial fibrillation: an electroanatomic study. *J Am Coll Cardiol* 2003;42:1271-82.
7. Seshadri N, Marrouche NF, Wilber D, Packer D, Natale A. Pulmonary vein isolation for treatment of atrial fibrillation: recent updates. *Pacing Clin Electrophysiol* 2003;26:1636-40.
8. Mesas CE, Pappone C, Lang CC *et al.* Left atrial tachycardia after circumferential pulmonary vein ablation for atrial fibrillation: electroanatomic characterization and treatment. *J Am Coll Cardiol* 2004;44:1071-9.
9. Pappone C, Oreto G, Rosanio S *et al.* Atrial electroanatomic remodeling after circumferential radiofrequency pulmonary vein ablation: efficacy of an anatomic approach in a large cohort of patients with atrial fibrillation. *Circulation* 2001;104:2539-44.
10. Jaïs P, Shah DC, Haïssaguerre M *et al.* Mapping and ablation of left atrial flutters. *Circulation* 2000;101:2928-34.
11. Pappone C, Oral H, Santinelli V *et al.* Atrio-esophageal fistula as a complication of percutaneous transcatheter ablation of atrial fibrillation. *Circulation* 2004;109:2724-6.
12. Haïssaguerre M, Jaïs P, Shah DC *et al.* Spontaneous initiation of atrial fibrillation by ectopic beats originating in the pulmonary veins. *N Engl J Med* 1998;339:59-66.

13. Morillo CA, Klein GJ, Jones DL, Guiraudon CM. Chronic rapid atrial pacing. Structural, functional, and electrophysiological characteristics of a new model of sustained atrial fibrillation. *Circulation* 1995;91:1588-95.
14. Harada A, Sasaki K, Fukushima T *et al.* Atrial activation during chronic atrial fibrillation in patients with isolated mitral valve disease. *Ann Thorac Surg* 1996;61:104-111.
15. Ndrepepa G, Karch MR, Schneider MA *et al.* Characterization of paroxysmal and persistent atrial fibrillation in the human left atrium during initiation and sustained episodes. *J Cardiovasc Electrophysiol* 2002; 13:525-32.
16. Pappone C, Manguso F, Vicedomini G *et al.* Prevention of iatrogenic atrial tachycardia after ablation of atrial fibrillation: a prospective randomized study comparing circumferential pulmonary vein ablation with a modified approach. *Circulation* 2004; 110:3036-42.
17. Scharf C, Oral H, Chugh A *et al.* Acute effects of left atrial radiofrequency ablation on atrial fibrillation. *J Cardiovasc Electrophysiol* 2004; 15:515-21.
18. Hocini M, Sanders P, Jaïs P *et al.* Prevalence of pulmonary vein disconnection after anatomical ablation for atrial fibrillation: consequences of wide atrial encircling of the pulmonary veins. *Eur Heart J* 2005; 26:696-704.
19. Ouyang F, Antz M, Ernst S *et al.* Recovered pulmonary vein conduction as a dominant factor for recurrent atrial tachyarrhythmias after complete circular isolation of the pulmonary veins: lessons from double lasso technique. *Circulation* 2005;111:127-35.
20. Ho SY, Sanchez-Quintana D, Cabrera JA *et al.* Anatomy of the left atrium: implications for radiofrequency ablation of atrial fibrillation. *J Cardiovasc Electrophysiol* 2000;11:758-61.