

Long-term results of cataract extraction with intraocular lens implantation in patients with uveitis

I Rahman and NP Jones

CLINICAL STUDY

Abstract

Objective To investigate the long-term visual results after cataract extraction in patients with uveitis, and to demonstrate the long-term viability of intraocular lenses.

Design In all, 61 patients (72 eyes), with update clinical examination, were retrospectively evaluated. Comparison of preoperative, postoperative, and latest visual function including best-corrected Snellen visual acuity, progression of uveitis and its complications, need for postoperative medical or surgical interventions.

Results After a minimum follow-up of 5 years (mean 7 years 7 months), 82% of eyes maintained a visual improvement of two Snellen lines, 74% maintained 6/9 or better, and 14% had 6/18 or worse. The mode acuity was better than 6/6. The prevalence of macular oedema or scarring was 24%, of posterior capsule opacification 96%, and of glaucoma drainage, 15%.

Conclusions We report the long-term follow-up of cataract extraction and intraocular lens (IOL) implantation performed by a single surgeon on patients with uveitis attending a regional tertiary referral uveitis clinic. Using stringent perioperative and postoperative control of inflammation, patients with uveitis usually maintain high visual acuity over long-term follow-up. The incidence of sight-threatening postoperative complications is low and no ongoing complication has been attributed to IOL implantation.

Eye (2005) 19, 191–197. doi:10.1038/sj.eye.6701450
Published online 2 July 2004

Keywords: uveitis; cataract; cataract surgery; intraocular lens

Introduction

Cataract is a common complication in patients with uveitis. Historically, surgery has been challenging and complications sometimes blinding. However, the evolution of surgical methods and materials, coupled with an appreciation of the need for meticulous pre-operative control of inflammation,^{1–3} has in recent years allowed almost universal intraocular lens (IOL) implantation^{4–26} and has greatly improved short-term visual results in this difficult group. Most complications of cataract extraction and IOL implantation in patients with uveitis are perceived to be peroperative or early in the postoperative period. However, there are several issues for the longer term, not least the tolerability of IOL materials in this predominantly young group of patients, and IOL removal is sometimes necessary.²⁷ Most previous reports of the results of extracapsular cataract extraction (ECCE) or phacoemulsification with IOL implantation have followed up patients for 2 years or less, and information on the longer term is sparse.²⁸ To our knowledge, no previous study has followed a substantial cohort for 5 years or more. We report the long-term follow-up of cataract extraction and IOL implantation performed by a single surgeon on patients with uveitis attending a regional tertiary referral uveitis clinic.

Patients and methods

Since the creation of the Manchester uveitis clinic in 1991, demographic, diagnostic and clinical management details of all patients have been entered onto a database. Following ethics committee approval, patients with uveitis who had undergone cataract extraction with IOL implantation, performed by one of us (NPJ)

The Royal Eye Hospital
Manchester, UK

Correspondence: NP Jones
The Royal Eye Hospital
Oxford Road, Manchester
M13 9WH, UK
Tel: +44 161 276 5628
Fax: +44 161 272 6618
E-mail: njones@cmmc.nhs.uk

Received: 9 September 2003
Accepted: 4 December 2003
Published online: 2 July 2004

The authors have no proprietary or financial interest in any product, drug, instrument, or device discussed in this article

more than 5 years previously, were identified from the database and from operating theatre records. This period included the transition from ECCE to phacoemulsification surgery for patients with uveitis, by this surgeon in 1994–1995. Medical records were reviewed and the following information extracted: age at surgery, gender, uveitis diagnosis, location and treatment, preoperative ocular morbidity, pre- and postoperative treatment regimes, surgical details, time between surgery, and a return to preoperative treatment levels, preoperative and best-corrected postoperative visual acuity.

All patients were invited for review clinical examination by a single observer (IR). At this time, the following information was recorded: current treatment, visual function including best-corrected Snellen visual acuity (VA), near acuity (UK Faculty of Ophthalmologists' reading test types, N5-N48), stereopsis (TNO), anterior segment inflammation, iris features (posterior synechiae (PS), transillumination, corectopia), IOL position, transparency and surface cells, posterior capsule opacification (PCO), vitreous clarity (Nussenblatt grading system),²⁹ macular disease, and optic disc abnormalities. Cystoid macular oedema (CMO) was diagnosed on clinical examination only.

Results

In all, 73 patients with uveitis had undergone 83 cataract extractions with IOL implantation, more than 5 years previously. Three patients had died, two were no longer in the region, and seven discharged patients did not respond to two invitations for clinical review. Data were therefore available for operations on 72 eyes performed on 61 patients; for 65 eyes this included a new review examination.

The anatomical classification and diagnosis of uveitis affecting patients in this study are shown in Table 1. In

all, 35 patients had unilateral uveitis, of which 33 had Fuchs' heterochromic uveitis (FHU). Prior to surgery, 20 eyes were receiving treatment for raised intraocular pressure (IOP) of which two had undergone trabeculectomy. Seven eyes had known preoperative macular damage by retinal pigment epithelial (RPE) scarring or epiretinal membrane (ERM) formation. Three eyes were amblyopic. In all, 35 eyes required no regular treatment preoperatively; of these three had quiescent acute anterior uveitis; two had minimal chronic anterior uveitis (CAU); and the remaining 30 had FHU. The remaining 37 eyes required maintenance topical steroid treatment; of these 10 also required systemic steroid treatment, and of these two also required immunosuppression, both with cyclosporin and one with azathioprine. Patients underwent surgery during periods of absolute or relative quiescence; preoperative control was always diligent but complete quiescence was often not achieved. Prior to surgery, patients received additional antiinflammatory treatment for 1–2 weeks according to a sliding scale (Table 2).

The mean age at surgery was 49.1 years (range 15–79 years). In all, 41 eyes underwent ECCE with IOL

Table 1 Location and diagnosis of uveitis

	AAU	CAU	INT	CPU	Total
Behçet's disease				1	1
Fuch's heterochromic uveitis		33			33
Multiple sclerosis		1			1
Psoriatic arthropathy		1			1
Sarcoidosis		3		7	10
Syphilis		1			1
Tuberculosis		1			1
Cause unknown	2	15	2	5	24
Totals	2	55	2	13	72

AAU, acute anterior uveitis (quiescent, no treatment); CAU, chronic anterior uveitis; INT, intermediate uveitis; CPU, chronic panuveitis.

Table 2 Preoperative antiinflammatory treatment protocol

Type of uveitis	Maintenance treatment	Preoperative treatment ^a
Quiescent uveitis	Nil	Nil
Fuch's heterochromic uveitis	Nil	G. Prednisolone acetate x6/day for 1 week.
Chronic anterior uveitis	Topical steroid	Topical steroid increased to at least G. Prednisolone acetate x6/day. Prednisolone 20–30 mg for 1 week in high-risk cases.
Chronic panuveitis – stable	Topical steroid + prednisolone ± immunosuppression	As above. Oral steroid and immunosuppression unchanged.
Chronic panuveitis – unstable	Topical steroid + prednisolone ± immunosuppression	As above but prednisolone dosage doubled, at least to 20 mg. Immunosuppression unchanged.

^aPreoperative treatment may be modified if the patient is a known steroid responder.

implantation via a corneal approach, of which 14 required sphincterotomy³⁰ or complete iridotomy. In all, 31 eyes underwent phacoemulsification with IOL implantation, the earlier 24 via a scleral tunnel and then following a change in technique, the latter seven via a corneal approach. Of these 31, 12 eyes required iris hooks to maintain an adequate pupil.

Phacoemulsification surgery was combined with trabeculectomy in two cases. PS required division in 22 eyes (30.5%). An IOL was implanted in all 72 eyes, being one-piece polymethylmethacrylate (PMMA) in all cases, 43 of these being heparin surface-modified (HSM). During one phacoemulsification procedure the capsulorrhexis was lost, requiring the unplanned implantation of a 7 mm IOL into the ciliary sulcus. Predictably, anterior chamber haemorrhage was observed in 23 of the 33 eyes with FHU (69.7%) but was significant in only three cases. There were no other surgical complications in any eye. Betamethasone was injected sub-conjunctivally at the end of each procedure.

Postoperatively all 72 eyes were able to return to the baseline presurgical treatment level; the mean delay before this was achieved was 12.4 weeks (range 3–78 weeks). Three patients had postoperative hyphaema, including one patient with FHU (following bleeding during surgery), one with CAU, and one undergoing combined phacoemulsification and trabeculectomy. Six eyes were noted to have CMO postoperatively, of which one was present pre-operatively.

One patient with FHU developed intractable secondary glaucoma within 2 years of cataract surgery and underwent enhanced trabeculectomy; she went on to develop anterior segment ischaemia and rubeotic glaucoma. Despite cyclodestruction she remained in pain and her blind eye was enucleated. All data on the most recent follow-up visit are based on the remaining 71 eyes in 60 patients.

All 71 patients were followed up for a minimum of 5 years, the mean period being 7 years 7 months. At the most recent review examination, uveitis remained present but untreated in 19 of 32 eyes with FHU; in the remaining 13 eyes with this diagnosis the inflammation had become quiescent. No patient with FHU remained on topical steroids at the latest follow-up examination. Of the 39 patients with other forms of uveitis, at the latest follow-up examination 14 eyes had become quiescent and were untreated; 13 eyes were quiescent on treatment; 10 eyes remained active despite treatment; and two eyes had minimal, untreated CAU. At the latest visit there was corectopia or complete iridotomy in 14 eyes, and PS to the capsule in six eyes. In addition, the iris exhibited substantial transillumination in a further 20 eyes, 18 of which had FHU.

At the most recent examination, giant cells were visible on the anterior surface of the IOL in 16 eyes (22.5%). This included seven of 29 PMMA IOLs (24.1%) and nine of 42 HSM IOLs (21.4%). One or two cells only were observed in 10 of the 16 eyes; six IOLs showed three or more giant cells, including one IOL plastered with many giant cells. The six IOLs with three or more giant cells were found in three eyes with FHU and three with CAU. No IOL was significantly decentred. No IOL had required removal or replacement.

One patient with CAU had required Nd-YAG laser division of an anterior capsular phimosis within 1 year of surgery. No other eye had developed significant phimosis. At the latest follow-up examination the posterior capsule was clear in only three of 71 eyes (4.2%). Of the remainder, 38 (53.5%) had already undergone Nd-YAG laser capsulotomy at a mean of 3 years 4 months postoperatively (range 1 month – 9.7 years). No complications arose following Nd-YAG capsulotomy; in particular there were no episodes of CMO. The remaining 30 eyes had PCO; of these, 21 had minor PCO, (not requiring capsulotomy in the context of high VA in a uveitic eye), and nine had more substantial PCO.

The current state of vitreous clarity was assessed; using the Nussenblatt system,²⁹ only four eyes were considered to have completely clear vitreous; 43 eyes had minor (trace or 1 +) vitreous opacification; 20 eyes had 2 + opacification; and four had 3 + opacification. Of those 24 eyes with moderate or severe opacification (2 + or 3 +), 11 eyes had FHU. No eye underwent vitrectomy during the follow-up period.

In all, 20 eyes were treated for glaucoma or ocular hypertension before surgery, of which two had already undergone trabeculectomy. Two underwent trabeculectomy combined with their phacoemulsification surgery. Postoperatively two eyes, which had been hypertensive, regained a normal IOP without medication. Three eyes developed glaucoma postoperatively. A further seven trabeculectomies were performed on seven eyes in the follow-up period, one of which was subsequently enucleated. A total of 11 eyes in this series (15.3% of total, 55% of those with glaucoma) therefore required glaucoma drainage surgery up to the latest follow-up examination.

The macula was assessed visually at the most recent examination and showed abnormality in 17 eyes (23.9%), comprising postinflammatory or postoedematous scarring in nine eyes, ERM formation in four eyes, active CMO in one eye and age-related macular degeneration in three eyes.

Snellen distance VA was measured and compared with preoperative and early best-corrected postoperative VA. The results are shown in Figure 1. The mode (most

frequently occurring) VAs were 6/12 preoperatively (13 eyes), 6/9 postoperatively (27 eyes), and >6/6 at latest follow-up (20 eyes). Patients did well visually after their cataract surgery; 52 eyes (72.2%) improved by two Snellen lines or more and 53 eyes (73.6%) achieved 6/9 or better. This improvement was maintained over the long term; at a mean of 7 years 7 months after surgery, these figures were 59 eyes (81.9%) and 54 eyes (75%), respectively. A total of 13 eyes achieved only 6/18 or worse postoperatively. At latest follow-up this figure was 14, including one enucleated eye. The clinical details of these patients are shown in Table 3. Near acuity was assessed in 65 eyes; 40 (55.5%) achieved an excellent level of N6 or N5 and 52 (72.2%) achieved N10 or better.

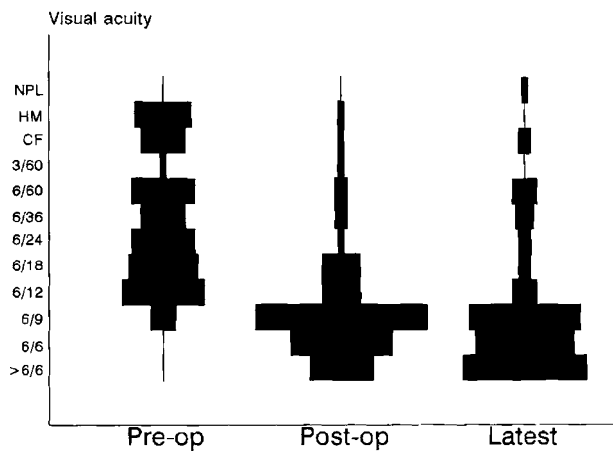


Figure 1 Distribution of best-corrected Snellen visual acuities at three stages: immediately before surgery (preoperative, mode = 6/12, 13 eyes); postoperative (mode = 6/9, 27 patients) and latest (mode = 6/6, 20 patients). HM = hand movements. CF = counting fingers. NPL = no perception of light.

In 10 cases the operated eye was, at latest follow-up, essentially functionless either because of poor VA in comparison to its normal fellow, or because of poor binocular vision; nine of these cases had unilateral FHU. Stereoacuity was found to be absent or rudimentary (Wirt fly only) in 21 patients, and good to moderate (TNO 240 s or arc, or better) in only 27. Bilateral severe visual loss (6/60 or worse in both eyes) and visual handicap registration had occurred in four patients in this cohort, by the most recent visit.

Discussion

Progressive improvement in the management of cataract in patients with uveitis has, over some 40 years, substantially enhanced visual results. This change has been led by the introduction of effective anti-inflammatory medications; by an appreciation that preoperative control of inflammation is mandatory;¹⁻³ by improvements in surgical instrumentation and technique, not least reliable endocapsular IOL fixation ensured by phacoemulsification surgery; and by improvements in IOL design and material,^{1,2,18,21,24-26,31} which have greatly improved tolerability within eyes that may continue to be inflamed for years after surgery. There is now a substantial modern literature on the management of uveitic cataract, which encourages a more aggressive approach to surgery. However, such reports have addressed only the short-term results. Patients with uveitis usually undergo their surgery before the age of 50 years and most have chronic inflammation. They need a long-term reliable outcome. This is the first reported cohort of patients to be followed for a minimum of 5 years following surgery. The early

Table 3 Data on the 14 eyes of 12 patients with a latest visual acuity of 6/18 or worse

Age, sex (side)	Diagnosis	VA			Reason for VA ≤ 6/18
		Pre	Post	Latest	
62, F	CAU	6/60	6/36	6/60	Amblyopia
61, F	FHU	CF	6/6	NPL (enucleated)	Rubeotic glaucoma
86, M	Sarcoidosis	CF	6/18	6/18	Epiretinal membrane
81, M (R)	CPU	6/24	6/18	6/36	Macular scar
81, M (L)	CPU	6/18	6/18	6/36	Macular scar
67, F	CAU	6/60	6/60	6/60	Chronic macular oedema
53, M	FHU	6/36	6/36	6/36	Macular scar
56, F	Sarcoidosis	CF	6/24	6/24	Epiretinal membrane
80, F	CPU	CF	6/18	6/60	Macular scar
49, F	Tuberculosis	6/36	6/60	6/60	Chronic macular oedema
40, M	FHU	CF	6/9	6/24	Glaucoma
61, M (R)	Sarcoidosis	HM	3/60	3/60	Macular scar
61, M (L)	Sarcoidosis	HM	HM	CF	Macular scar
70, F	Sarcoidosis	6/60	6/12	6/18	Epiretinal membrane

Pre, preoperative; Post, postoperative; CAU, chronic anterior uveitis, unknown aetiology; CPU, chronic panuveitis, unknown aetiology; FHU, Fuchs' heterochromic uveitis; HM, hand movements; CF, count fingers; NPL, no perception of light.

postoperative results of 39 of these patients have been previously reported.^{18,25}

This study includes eyes with Fuchs' heterochromic uveitis. In general, reports on cataract surgery in this disease have assumed a fundamental difference between FHU and other forms of uveitis, and a better outcome is often claimed. However, it has been shown²⁵ that significant rates of postoperative inflammation occur in these eyes, and that visual outcomes should not be assumed to be superior to those in other forms of uveitis. This study includes 33 eyes with FHU (46% of total). Seven of the 23 eyes with glaucoma (30%) had FHU, including five of the 11 eyes (45%) undergoing trabeculectomy. Three of the six eyes with significant giant cell deposition on the IOL (43%) had FHU. Three of the 14 eyes, with VA worse than 20/40 (21%), had FHU, including the only blind eye. Macular oedema is rare in FHU either before or after surgery; postoperative CMO was seen in one eye with FHU in this study (3%). Cataract surgery in FHU usually passes uneventfully, but occasional substantial problems of uveitis and glaucoma arise; in some cases high-risk eyes can be identified preoperatively.⁸

We have found that the use of a stringent but pragmatic approach to the preoperative treatment of inflammation²⁵ has enabled the reliable control of postoperative inflammation with few severe episodes of fibrinous uveitis. The return to preoperative baseline treatment in a mean 12.4 weeks (and for patients undergoing phacoemulsification, 8.6 weeks)²⁵ has demonstrated the safety of this approach; in this cohort, 59 eyes (82%) had returned to preoperative treatment levels within 3 months of surgery.

It is important to minimise iris trauma during surgery in patients with anterior uveitis, but this may be difficult; in this series 26 eyes required iris manipulation of some sort; PS required division in 22 eyes, sphincterotomy or complete iridotomy was used in 14 eyes undergoing ECCE, and 12 undergoing phacoemulsification required iris hooks to maintain an adequate pupil, with frequent sphincter rupture; all such steps cause vascular trauma and fibrinogen release. Of the six eyes with PS at the latest examination, five had undergone ECCE requiring division of preoperative PS and iridotomy. In only one instance did an eye undergoing phacoemulsification form postoperative PS, and on this occasion neither were PS divided at surgery nor were hooks used; this PS rate of one in 31 is encouraging. It has been suggested²³ that in order to prevent this complication, a large-optic IOL may be implanted into the ciliary sulcus. However, it is our view that PS are uncommon with phacoemulsification, and that the problems occasioned by chronic iris touch³² in sulcus-implanted IOLs are better avoided in patients with uveitis.

There is now a considerable literature on the short-term viability of IOLs in high-risk eyes^{3-25,28} and the early pathological effects of implantation have been well described.^{33,34} Using stringent perioperative control of inflammation, short-term viability has been good. In this series these trends have been reinforced; no IOL required removal or exchange after a minimum of 5 years; none has been significantly decentred; and the number compromised by adherent inflammatory cells has been small. The optimal IOL material is the continued subject of debate,^{31,34-36} and long-term follow-up studies such as this cannot address such issues (being intrinsically out of date with developments in materials). Nevertheless, the high degree of long-term intraocular tolerance of PMMA IOLs, with or without HSM, is further encouragement to the almost universal use of IOLs in patients with uveitis. The implantation of IOLs in patients with juvenile rheumatoid arthritis and uveitis is a fundamentally different, and contentious issue;³⁷⁻⁴⁰ none of the patients in this series had that diagnosis, and we continue, as a rule, to avoid IOL implantation in these patients.

PCO was virtually universal in this group of patients (96 and 53% lasered). It has been perceived to be more common in patients with uveitis, but the average age at surgery in our cohort was 49 years; it has been persuasively claimed by Dana and *et al*²⁰ that the higher incidence is likely to be age-related rather than disease-related. No study has as yet made a direct comparison of age-matched groups with and without uveitis, and our suspicion is that this long-term high rate is caused by a combination of disease and age.

Owing to the high frequency of PCO it has been suggested by Lam *et al*²² that primary posterior capsulorhexis may be used at the time of cataract surgery. Although that study found no increased incidence of CMO, we would express concern about this potential problem and maintain that postoperative Nd-YAG capsulotomy is intrinsically safer than preoperative primary capsulorhexis.

Vitreous opacification is a common accompaniment to uveitis and contributes to poor vision. It is an under-rated problem in patients with FHU, and a minority of these patients successfully undergo vitrectomy.⁴¹ In a patient with visually significant cataract and vitreous opacification, two main management courses arise; the first is primary cataract surgery with postoperative reassessment and vitrectomy if necessary; the second is simultaneous combined pars plana vitrectomy and cataract extraction. Previously, reports of pars plana lensectomy gave mixed visual results⁴²⁻⁴⁴ but anterior-approach phacoemulsification with pars plana vitrectomy may prove a reliable option. In patients with uveitis, the possibility of enhanced inflammation

resulting from combined surgery is a potential problem. Our current approach is to extract the cataract first and to assess the impact of vitreous opacification postoperatively; only a minority require vitrectomy.

Our incidence of postoperative CMO is low in comparison to other studies (six eyes, 8.3%) but was diagnosed on clinical observation only — our patients do not undergo fluorescein angiography unless VA falls to 6/12 or N10 and the view of the macula is inadequate to diagnose CMO clinically. In contrast, using angiography on a group of patients with uveitis, Krishna *et al*²⁸ reported an incidence of 56%. Notwithstanding the accuracy imparted by angiography, this difference is large and may in part be explained by casemix differences, especially by our inclusion of patients with FHU. A lower incidence (2.3%) has also been reported²⁵ in a cohort of 86 eyes with uveitis undergoing phacoemulsification by one of us (NPJ), albeit with shorter follow-up. The progression of macular disease is difficult to quantify in this study. Preoperative CMO or ERM formation may be difficult to assess in patients with cataract and vitreous opacification. In this study, preoperative macular RPE scarring or ERM formation was known in seven eyes; at 7 years 7 months after surgery this figure was 13. The difference is partly explained by enhanced visibility, and clear evidence of visual deterioration from progressive macular changes is available for only three eyes (4%).

The visual results immediately following surgery in this cohort compare favourably with other reports.^{3–25,28} As shown in Figure 1 these predominantly high visual acuities have been maintained over a mean of 7 years 7 months. A scrutiny of those 14 eyes (19.4% of cohort) with a current VA of 6/18 or worse (Table 3) shows that eight have deteriorated in acuity over the follow-up period; four because of postinflammatory or postCMO macular scarring or ERM formation, one with chronic CMO, two because of glaucoma (one enucleated), and one amblyopic eye with posterior capsule and vitreous opacification. The remaining six had preoperative causes of visual loss such that high VA was not an expected outcome.

In conclusion, after long-term follow-up of patients with uveitis undergoing cataract extraction with IOL implantation, there is evidence of the long-term viability of IOLs in such eyes, providing that patient selection and stringent management procedures are observed. No late postoperative complications were attributable to IOL usage, in a group which included a majority of ECCE operations with frequent iris manipulation during surgery. The evolution to phacoemulsification surgery, which has followed, promises yet more reliable long-term outcomes for this high-risk group of patients.

References

- 1 Hooper PL, Rao NA, Smith RE. Cataract extraction in uveitis patients. *Surv Ophthalmol* 1990; **35**: 120–144.
- 2 Rojas B, Foster CS. Cataract surgery in patients with uveitis. *Curr Opin Ophthalmol* 1996; **7**: 11–16.
- 3 Heger H, Drolsum L, Haaskjold E. Cataract surgery with implantation of IOL in patients with uveitis. *Acta Ophthalmol* 1994; **72**: 478–482.
- 4 Foster CS, Fong LP, Singh G. Cataract surgery and intraocular lens implantation in patients with uveitis. *Ophthalmology* 1989; **96**: 281–288.
- 5 Gee SS, Tabbara KF. Extracapsular cataract extraction in Fuchs heterochromic iridocyclitis. *Am J Ophthalmol* 1989; **108**: 310–314.
- 6 Michelson JB, Friedlaender MH, Nozik R. Lens implant surgery in pars planitis. *Ophthalmology* 1990; **97**: 1023–1026.
- 7 Razzak A, Al Samarrai A. Intraocular lens implantation following cataract extraction in Fuchs heterochromic uveitis. *Ophthalmic Res* 1990; **22**: 134–136.
- 8 Jones NP. Extracapsular cataract surgery with and without intraocular lens implantation in Fuchs heterochromic uveitis. *Eye* 1990; **4**: 145–150.
- 9 Brinkman CJJ, Los GJ, Breebaart AC. Cataract extraction in patients with chronic posterior uveitis. *Acta Ophthalmol* 1990; **68**: 151–154.
- 10 Jakeman CM, Jordan K, Keast-Butler J, Perry S. Cataract surgery with intraocular lens implantation in Fuchs heterochromic cyclitis. *Eye* 1990; **4**: 543–547.
- 11 Baarsma GS, de Vries J, Hammudoglu CD. Extracapsular cataract extraction with posterior chamber lens implantation in Fuchs heterochromic cyclitis. *Br J Ophthalmol* 1991; **75**: 306–308.
- 12 Sherwood DR, Rosenthal RA. Cataract surgery in Fuchs heterochromic iridocyclitis. *Br J Ophthalmol* 1992; **76**: 238–240.
- 13 Foster RE, Lowder CY, Meisler DM, Zakov ZN. Extracapsular cataract extraction and posterior lens implantation in uveitis patients. *Ophthalmology* 1992; **99**: 1234–1241.
- 14 Seamone CD, Deschenes J, Jackson WB. Cataract extraction in uveitis: comparison of aphakia and posterior chamber lens implantation. *Can J Ophthalmol* 1992; **27**: 120–124.
- 15 Kaufman AH, Foster CS. Cataract extraction in patients with pars planitis. *Ophthalmology* 1993; **100**: 1210–1217.
- 16 Akova YA, Foster CS. Cataract surgery in patients with sarcoidosis associated uveitis. *Ophthalmology* 1994; **101**: 473–479.
- 17 Ram J, Jain S, Pandav SS, Gupta A, Mangat G. Postoperative complications of intraocular lens implantation in patients with Fuchs heterochromic cyclitis. *J Cataract Refract Surg* 1995; **21**: 548–551.
- 18 Jones NP. Cataract surgery using heparin surface-modified intraocular lenses in Fuchs heterochromic uveitis. *Ophthalmic Surg* 1995; **26**: 49–52.
- 19 O'Neill D, Murray PI, Patel BC, Hamilton A. Extracapsular cataract surgery with and without intraocular lens implantation in Fuchs heterochromic cyclitis. *Ophthalmology* 1995; **102**: 1362–1368.
- 20 Dana RM, Chatzistefanou K, Schaumberg DA, Foster CS. Posterior capsule opacification after cataract surgery in patients with uveitis. *Ophthalmology* 1997; **104**: 1387–1394.
- 21 Tran VT, Guex-Crosier Y, Herbot CP. Effect of cataract surgery with implantation on inflammation in chronic

- uveitis: a longitudinal laser flare photometry study. *Can J Ophthalmol* 1998; **33**: 264–269.
- 22 Lam DSC, Law RWK, Wong AKK. Phacoemulsification, primary capsulorhexis and capsular intraocular lens implantation for uveitic patients. *J Cataract Refract Surg* 1998; **24**: 1111–1117.
- 23 Holland GN, Van Horn SD, Margolis TP. Cataract surgery with ciliary sulcus fixation of intraocular lenses in patients with uveitis. *Am J Ophthalmol*. 1999; **128**: 21–30.
- 24 Rauz S, Stavrou P, Murray PI. Evaluation of foldable intraocular lenses in patients with uveitis. *Ophthalmology* 2000; **107**: 909–918.
- 25 Suresh PS, Jones NP. Phacoemulsification with intraocular lens implantation in patients with uveitis. *Eye* 2001; **15**: 621–628.
- 26 Abela-Formanek C, Amon M, Schauersberger J, Kruger A, Nepp J, Schild G. Results of hydrophilic acrylic, hydrophobic acrylic, and silicone intraocular lenses in uveitic eyes with cataract. Comparison to a control group (1). *J Cataract Refract Surg* 2002; **28**: 1141–1152.
- 27 Foster CS, Stavrou P, Zafirakis P, Rojas B, Tesavival N, Balratzis S. Intraocular lens removal patients with uveitis. *Am J Ophthalmol* 1999; **128**: 31–37.
- 28 Krishna MD, Meisler DM, Lowder CY, Estafanous M, Foster RE. Long-term follow-up of extracapsular cataract extraction and posterior chamber lens implantation in patients with uveitis. *Ophthalmology* 1998; **105**: 1765–1769.
- 29 Nussenblatt RB, Palestine AG, Chan CC, Roberge F. Standardisation of vitreal inflammatory activity in intermediate and posterior uveitis. *Ophthalmology* 1985; **92**: 467–471.
- 30 Cole MD, Brown R, Ridgway AE. Role of sphincterotomy in extracapsular cataract surgery. *Br J Ophthalmol* 1986; **70**: 692–695.
- 31 Alio JL, Chipont E, BenEzra D, Fakhry MA. Comparative performance of intraocular lenses in eyes with cataract and uveitis. *J Cataract Refract Surg* 2002; **28**: 2096–2108.
- 32 Snyder ME. Cataract surgery with ciliary sulcus fixation of intraocular lenses in patients with uveitis [letter]. *Am J Ophthalmol* 2000; **130**: 257–258.
- 33 Wolter JR. Cytopathology of intraocular lens implantation. *Ophthalmology* 1985; **92**: 135–142.
- 34 Obstbaum SA. Biologic relationship between polymethylmethacrylate intraocular lenses and uveal tissue. *J Cataract Refract Surg* 1992; **18**: 219–231.
- 35 Lin CL, Wang AG, Chou JCK. Heparin-surface-modified intraocular lens implantation in patients with glaucoma, diabetes, or uveitis. *J Cataract Refract Surg* 1994; **20**: 550–553.
- 36 Abela-Formanek C, Amon M, Schild G, Kolodjaschna J, Barisani-Asenbauer T, Kruger A. Uveal and capsular biocompatibility of hydrophilic acrylic, hydrophobic acrylic, and silicone intraocular lenses. *J Cataract Refract Surg* 2002; **28**: 50–61.
- 37 Foster CS, Barrett F. Cataract development and cataract surgery in patients with juvenile rheumatoid arthritis-associated iridocyclitis. *Ophthalmology* 1993; **100**: 809–817.
- 38 Matsuo T, Fujiwara M, Matsuo N. Inflammation after cataract extraction and intraocular lens implantation in patients with rheumatoid arthritis. *Br J Ophthalmol* 1995; **79**: 549–553.
- 39 Probst LE, Holland EJ. Intraocular lens implantation in patients with juvenile rheumatoid arthritis. *Am J Ophthalmol* 1996; **122**: 161–170.
- 40 Holland GN. Intraocular lens implantation in patients with juvenile rheumatoid arthritis-associated uveitis: an unresolved management issue. *Am J Ophthalmol* 1996; **122**: 255–257.
- 41 Waters FM, Goodall K, Jones NP, McLeod D. Vitrectomy for vitreous opacification in Fuchs heterochromic uveitis. *Eye* 2000; **14**: 216–218.
- 42 Diamond JG, Kaplan HJ. Lensectomy and vitrectomy for complicated cataract secondary to uveitis. *Arch Ophthalmol* 1978; **96**: 1798–1804.
- 43 Nobe JR, Kokoris N, Diddie KR, Cherney EF, Smith RE. Lensectomy–vitrectomy in chronic uveitis. *Retina* 1983; **3**: 71–76.
- 44 Petrilli AM, Belfort R, Abreu MT, Lima AL, Amaral MG, Bonomo PP. Ultrasonic fragmentation of cataract in uveitis. *Retina* 1986; **6**: 61–65.