

## REVIEW ARTICLE

## Looking beneath the surface: the importance of subcortical structures in frontotemporal dementia

 Martina Bocchetta,<sup>1</sup>  Maura Malpetti,<sup>2</sup>  Emily G. Todd,<sup>1</sup> James B. Rowe<sup>2,3</sup> and Jonathan D. Rohrer<sup>1</sup>

Whilst initial anatomical studies of frontotemporal dementia focussed on cortical involvement, the relevance of subcortical structures to the pathophysiology of frontotemporal dementia has been increasingly recognized over recent years. Key structures affected include the caudate, putamen, nucleus accumbens, and globus pallidus within the basal ganglia, the hippocampus and amygdala within the medial temporal lobe, the basal forebrain, and the diencephalon structures of the thalamus, hypothalamus and habenula. At the most posterior aspect of the brain, focal involvement of brainstem and cerebellum has recently also been shown in certain subtypes of frontotemporal dementia. Many of the neuroimaging studies on subcortical structures in frontotemporal dementia have been performed in clinically defined sporadic cases. However, investigations of genetically- and pathologically-confirmed forms of frontotemporal dementia are increasingly common and provide molecular specificity to the changes observed. Furthermore, detailed analyses of sub-nuclei and subregions within each subcortical structure are being added to the literature, allowing refinement of the patterns of subcortical involvement. This review focuses on the existing literature on structural imaging and neuropathological studies of subcortical anatomy across the spectrum of frontotemporal dementia, along with investigations of brain-behaviour correlates that examine the cognitive sequelae of specific subcortical involvement: it aims to 'look beneath the surface' and summarize the patterns of subcortical involvement have been described in frontotemporal dementia.

- 1 Dementia Research Centre, Department of Neurodegenerative Disease, UCL Queen Square Institute of Neurology, University College London, London, UK
- 2 Department of Clinical Neurosciences and Cambridge University Hospitals NHS Trust, University of Cambridge, Cambridge, UK
- 3 Medical Research Council Cognition and Brain Sciences Unit, University of Cambridge, Cambridge, UK

Correspondence to: Dr Martina Bocchetta, Dementia Research Centre, Department of Neurodegenerative Disease, UCL Queen Square Institute of Neurology, 8-11 Queen Square, London WC1N 3BG, UK  
E-mail: m.bocchetta@ucl.ac.uk

**Keywords:** frontotemporal dementia; MR imaging; subcortical structures

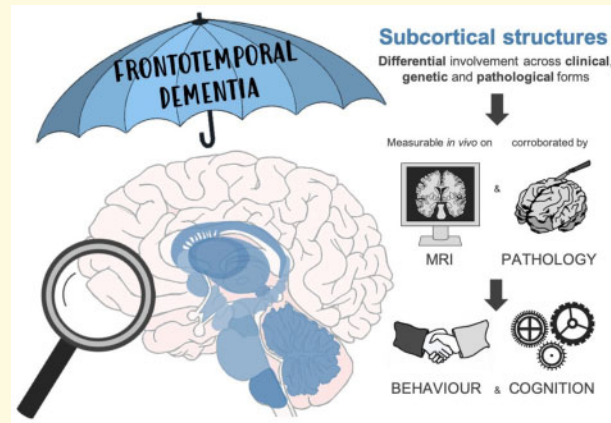
**Abbreviations:** ALS = amyotrophic lateral sclerosis; bvFTD = behavioural variant frontotemporal dementia; CA = cornu ammonis; CBD = corticobasal degeneration; CBS = corticobasal syndrome; *C9orf72* = chromosome 9 open reading frame 72; FTD = frontotemporal dementia; FTDP-17 = frontotemporal dementia with parkinsonism linked to chromosome 17; FTLD = frontotemporal lobar degeneration; FUS = fused-in-sarcoma; GRN = progranulin; lvPPA = logopenic variant of primary progressive aphasia; MAPT = microtubule-associated protein tau; nfvPPA = non-fluent variant of primary progressive aphasia; PPA = primary progressive aphasia; PSP = progressive supranuclear palsy; svPPA = semantic variant of primary progressive aphasia; TDP-43 = TAR DNA-binding protein 43

Accepted May 21, 2021. Advance Access publication July 16, 2021

© The Author(s) (2021). Published by Oxford University Press on behalf of the Guarantors of Brain.

This is an Open Access article distributed under the terms of the Creative Commons Attribution License (<http://creativecommons.org/licenses/by/4.0/>), which permits unrestricted reuse, distribution, and reproduction in any medium, provided the original work is properly cited.

## Graphical Abstract



## Introduction

Frontotemporal dementia (FTD) is a common cause of early onset dementia, approximately equal in frequency to Alzheimer's disease in people under the age of 65. It is clinically heterogeneous with symptoms, including behavioural, language, cognitive and motor deficits. Behavioural variant FTD (bvFTD) is the most common presentation, with impaired social conduct and personality changes,<sup>1</sup> whilst less frequently, people present with progressive decline in speech and language functions [primary progressive aphasia (PPA)], of which there are multiple variants: semantic variant (svPPA), non-fluent variant (nfvPPA) and logopenic variant (lvPPA).<sup>2</sup> People on this spectrum can also develop motor features consistent with either amyotrophic lateral sclerosis (ALS) or parkinsonism [including progressive supranuclear palsy (PSP), or corticobasal syndrome (CBS)].<sup>3</sup> At present the only known risk factors for FTD are age and genetics: about a third of cases are due to an autosomal dominant mutation in microtubule-associated protein tau (*MAPT*), progranulin (*GRN*) or chromosome 9 open reading frame 72 (*C9orf72*) genes.<sup>4</sup> Pathologically, three major groups are described according to the main abnormal protein seen in neuronal or glial inclusions—tau, TAR DNA-binding protein 43 (TDP-43) and fused-in-sarcoma (FUS)<sup>5,6</sup>—with multiple subtypes seen within each main group.

Anatomically, FTD has traditionally been characterized as a cortical dementia with atrophy predominantly of the frontal and temporal lobes, hence its name. However, imaging and neuropathological studies have identified not only other cortical areas (including the insula and anterior cingulate) but also subcortical structures as key areas of FTD-related degeneration,<sup>7</sup> even at the very early stages of the disorder<sup>8–16</sup> and presymptomatic phases.<sup>17</sup>

Behavioural studies have highlighted the relevance of subcortical structures in the development of the typical symptoms of FTD. Subcortical structures contribute to

functional and structural brain networks that are affected in FTD. For example, a reward network related to the limbic system<sup>18</sup> regulates appropriate behaviour for a given context by the evaluation of motivational and emotional content of the stimuli. Abnormal functioning of this circuit in bvFTD leads to abnormal responses to rewards (including food, sex and substance use).<sup>19</sup>

This review aims to provide a comprehensive overview of the involvement of subcortical structures in the FTD spectrum (Fig. 1), identified by structural magnetic resonance (MR) imaging, with neuropathological corroboration of the imaging data.

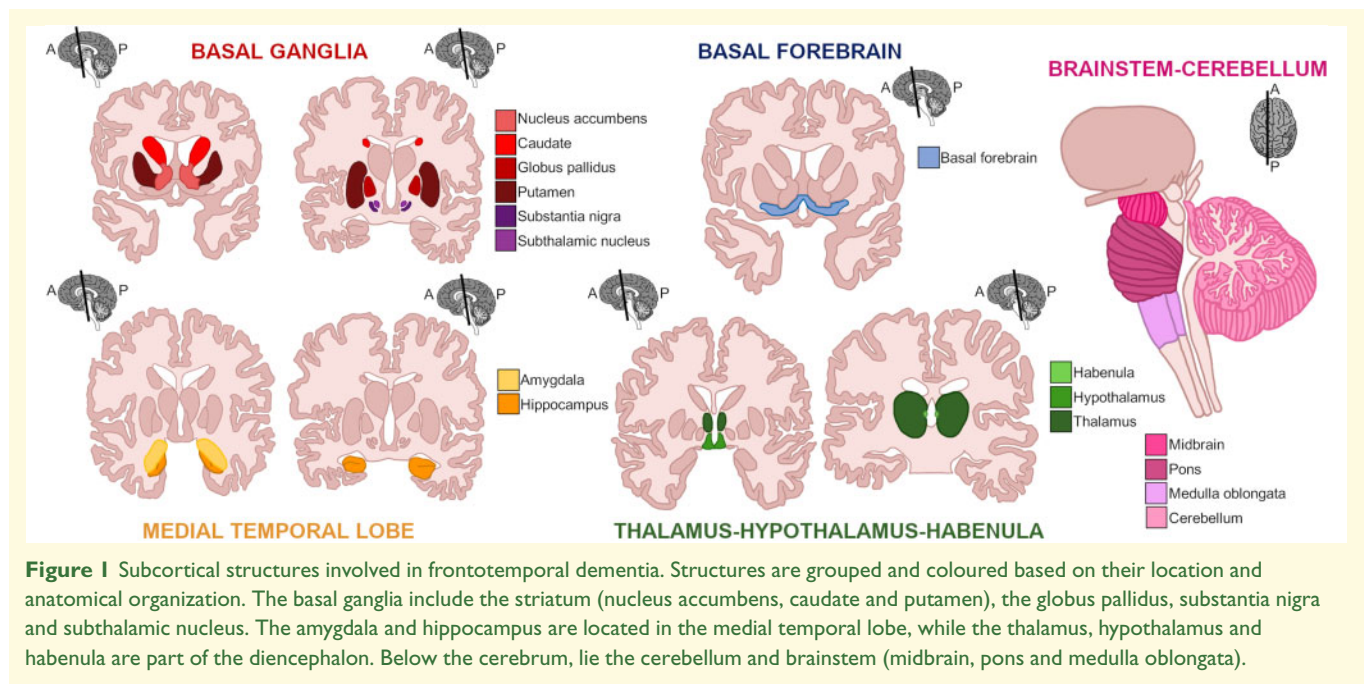
For each of the structures, we first describe their anatomy and structural connections ('Anatomy'), and then report the MRI studies that have investigated changes *in vivo* in their volume or morphology within the genetic, clinical and pathological forms of FTD ('Neuroimaging'). This is followed by the description of which studies have reported abnormal findings at *post mortem* examination ('Neuropathology'), and then finally, in the 'Symptomatology' section, we discuss how such structural changes contribute to the behavioural and cognitive deficits seen in people with FTD.

## Basal ganglia

### Striatum

**Anatomy.** The striatum consists of dorsal and ventral regions. The dorsal striatum comprises the caudate and putamen and is primarily associated with sensorimotor functions, whilst the ventral striatum includes the nucleus accumbens and is a component of the limbic circuit, which modulates behaviour and memory.<sup>20</sup>

The striatum has multiple parallel connections with the prefrontal cortex, anterior cingulate cortex, orbitofrontal cortex, insula, inferior and middle temporal gyrus, and thalamus.<sup>21</sup> Anatomical and physiological studies have identified functionally distinct but anatomically analogous cortico-striato-pallido-thalamic-cortical circuits. These



**Figure 1** Subcortical structures involved in frontotemporal dementia. Structures are grouped and coloured based on their location and anatomical organization. The basal ganglia include the striatum (nucleus accumbens, caudate and putamen), the globus pallidus, substantia nigra and subthalamic nucleus. The amygdala and hippocampus are located in the medial temporal lobe, while the thalamus, hypothalamus and habenula are part of the diencephalon. Below the cerebrum, lie the cerebellum and brainstem (midbrain, pons and medulla oblongata).

process information in parallel and have separate connections and functions.<sup>20,21</sup> In the *motor circuit* and *oculomotor circuit*, the putamen and the caudate receive input from the primary motor, somatosensory, premotor, supplementary motor and posterior parietal cortex, together with the frontal eye fields. They then send their output to the supplementary motor cortex and frontal eye fields, via the globus pallidus (internal segment), substantia nigra (pars reticulata) and thalamus (ventrolateral and ventral anterior and mediodorsal nuclei).<sup>20,22</sup> The other three circuits originate from and end in the frontal cortex, but they have different pathways and have different roles in cognition, emotion and motivation.<sup>21</sup> The *dorsolateral prefrontal circuit* is associated with executive function. The dorsolateral prefrontal cortex, together with the posterior parietal and premotor cortex, is connected to the dorsolateral head of the caudate, to the globus pallidus and substantia nigra, and to the thalamus (ventral anterior and mediodorsal nuclei). The *lateral orbitofrontal circuit* regulates inhibition and impulses. It is connected to the ventral anterior and mediodorsal nuclei of the thalamus via the ventromedial head of the caudate (which also receives inputs from the superior temporal gyrus, inferior temporal gyrus and anterior cingulate) and the globus pallidus and substantia nigra. In the *anterior cingulate circuit*, the nucleus accumbens and ventromedial caudate receive input from the anterior cingulate, and limbic and paralimbic regions (hippocampus, entorhinal cortex, insula, amygdala, superior and inferior temporal gyrus and temporal pole) with output via the globus pallidus and substantia nigra to the mediodorsal thalamus. This is the crucial pathway controlling motivation.<sup>20,21</sup>

The nucleus accumbens additionally projects to the basal forebrain and the lateral preoptic area and lateral hypothalamus.<sup>23</sup> This nucleus can be further divided into a 'shell' and 'core', at least in preclinical models: the shell is connected to the medio-temporal regions (hippocampal cornu ammonis 1—CA1, CA3 and subiculum, entorhinal cortex, basolateral amygdaloid nucleus), the paraventricular thalamic nucleus and the caudal brainstem, while the functionally distinct core is connected to the dorsomedial prefrontal cortex, anterior cingulate, insula, parahippocampal cortex, midline and intralaminar thalamic nuclei, and the basolateral amygdaloid nucleus.

**Neuroimaging.** Clinically, the caudate is affected in both behavioural and language phenotypes of FTD. Compared to controls, the caudate is 11–25% smaller in bvFTD, 21% smaller in nfvPPA (worse on the left) and 8% smaller in svPPA (worse on the left).<sup>7,14,16,24–29</sup> Similarly, the putamen is affected across all clinical syndromes being 7–28% smaller in bvFTD, 13% smaller in nfvPPA (worse on the left) and 11–21% smaller in svPPA (worse on the left) than controls.<sup>7,14,16,26,29,30</sup> The subregions of the putamen may be equally affected by each syndrome.<sup>25</sup>

Among the genetic forms of FTD, *GRN* mutation carriers in particular have shown involvement of the dorsal striatum.<sup>17,31</sup> Patients with *GRN* mutations show especially severe atrophy in the caudate (56% reduction versus controls), while putamen atrophy is similar to sporadic cases (27% reduction versus controls).<sup>32</sup> A recent study in a large cohort of mutation carriers has found that the *GRN* group showed smaller volumes in the putamen (17% difference versus controls) and caudate (5%) only when they were fully symptomatic, but not at earlier stages.<sup>33</sup> In the same study, *C9orf72* expansion

carriers were found to have smaller putaminal volumes in asymptomatic and prodromal stages (1–6%) through to fully symptomatic stages (17%), while *MAPT* mutation carriers were only abnormal at a fully symptomatic stage (17%).

Including pathologically confirmed cases, an early investigation showed no volumetric differences in any brain region comparing tau and TDP-43 cases.<sup>34</sup> However, in a more detailed study looking at pathological subtypes the group of patients with FUS pathology showed the most severe degree of caudate atrophy in comparison with controls (34% difference from controls),<sup>15</sup> aligning with the evidence from multiple prior case series.<sup>35,36</sup> Although with lesser severity, caudate atrophy was also seen across multiple pathologies e.g. Pick's disease (23% difference from controls), corticobasal degeneration (CBD) (15%), TDP-43 type A (14%), frontotemporal dementia with parkinsonism linked to chromosome 17 (FTDP-17) (13%) and TDP-43 type C (11%). Furthermore, in this study, atrophy in the putamen was more marked than in the caudate in most groups (apart from FUS): Pick's disease (38% difference from controls), FUS (33%), FTDP-17 (25%), CBD (24%), TDP-43 type A (25%) and TDP-43 type C (19%).

The ventral striatum, in the form of the nucleus accumbens, has been less studied than the dorsal region. However, atrophy in this region occurs in both bvFTD and svPPA, with volumes from 30% to 50% smaller than controls.<sup>7,14,26,28,29</sup> Among the genetic forms, only symptomatic *MAPT* mutation carriers showed smaller volumes in the nucleus accumbens (11%).<sup>33</sup> There may be asymmetry in the progression of atrophy. For example, in patients with TDP-43 type C pathology, atrophy of the left nucleus accumbens precedes the right.<sup>37</sup> Current studies have not addressed whether the core or shell of the accumbens is more affected in different forms of FTD.

**Pathology.** Several studies have characterized *post mortem* striatal volume loss<sup>38</sup> and histopathology.<sup>39,40</sup> Consistent with neuroimaging evidence, the most severe striatal atrophy has been seen in cases with FUS pathology,<sup>41</sup> especially in the caudate.

Studies focussing on genetic forms of FTD confirm the abnormalities of the basal ganglia, with prevalent involvement of the caudate in cases with *GRN* mutations,<sup>41</sup> and severe neuronal loss and gliosis of the striatum along with TDP-43 inclusions.<sup>42</sup> In FTDP-17, macroscopic atrophy is detectable at the intermediate stage in the caudate nucleus, whilst caudate and putaminal volume loss is evident in advanced illness.<sup>43</sup>

Patients with both tau and TDP-43 pathology show neuron loss, astrogliosis and focal microvacuolation in the ventral striatum, accompanied by tau or TDP-43 immunoreactive neuronal cytoplasmic inclusions and dystrophic neurites. In particular, svPPA patients with TDP-43 type C show abundant and focal neuronal

cytoplasmic inclusions in the accumbens.<sup>26</sup> In these patients with frontotemporal lobar degeneration (FTLD), the greatest amount of TDP-43 pathology is in the ventral striatum, followed by the putamen and the dorsal caudate.<sup>44</sup>

**Symptomatology.** Striatal degeneration determines diverse symptoms of FTD, directly and indirectly via the striatal projections to other regions. For example, striatal lesions are associated with decreased globus pallidus inhibition which leads to enhanced thalamic inhibition and reduced cortical activation. Striatal atrophy is therefore associated with disinhibition,<sup>7,45</sup> binge eating<sup>19,46</sup> and poor memory recall.<sup>47</sup> Loss of the striatum innervation and atrophy can also result in akinesia and parkinsonism, which are reported in over half of the patients with FTD<sup>48</sup> and a third of patients with right-temporal variant FTD.<sup>39</sup> Parkinsonism has also been observed in nvPPA, and linked to the progressive striatal atrophy and dopamine depletion in the putamen and caudate that characterize this syndrome.<sup>49</sup>

The role of the dorsal striatum and its connectivity with the frontal lobe is mirrored between FTD and other lesions to the dorsal fronto-striatal network, with executive dysfunction and behavioural impairment in FTD. In particular, dysexecutive syndromes are also associated with atrophy of the regions connected to the dorsolateral prefrontal cortex (e.g. antero-dorsal head of the caudate). On the other hand, neuropathology in the ventromedial head of the caudate and its connections to the orbitofrontal cortex leads to loss of socially appropriate behaviours, abnormal reward-seeking and disinhibited or impulsive behaviours.<sup>19</sup> The nucleus accumbens has a key role in the representation of rewards associated with response options to stimuli, and it represents the outcome value of actions, weighting short and long-term consequences. Damage alters the representation of risks, for immediate versus delayed gratification.<sup>23</sup> This explains why degeneration of this nucleus leads to impulsivity and disinhibition, typical of bvFTD.<sup>50</sup> In bvFTD and svPPA, this may present with disinhibited sexual behaviours, repetitive or compulsive behaviours, abnormal eating behaviour and substance abuse.<sup>26,51,52</sup> Degeneration of the nucleus accumbens or ventromedial caudate can also lead to apathy, as observed in all FTD syndromes, as a result of reduced motivation.<sup>21,53–55</sup> Moreover, there is an association between reduced putamen volumes and severity of behavioural symptoms in FTD.<sup>14,19,56</sup> Laterality effects may also be present but are less consistently reported. For example, overeating and sweet preference in bvFTD patients has been associated with selective right striatal degeneration.<sup>19,46</sup>

In genetic FTD, impairment of negative, as well as positive, outcome representations may account for the association of striatal atrophy with abnormal pain perception in *C9orf72*-associated FTD.<sup>57</sup> Abnormal reinforcement learning as a result of striatal atrophy may

also underpin psychotic symptoms, which is particularly common in *C9orf72*-associated FTD.<sup>58</sup> In *GRN*- and *MAPT*-associated FTD, striatal atrophy is related to impaired social cognition.<sup>59</sup>

### Globus pallidus

**Anatomy.** Another important nucleus of the basal ganglia is the globus pallidus, which has been closely associated with motor symptoms and signs, but which also mediate cognitive functions.<sup>60</sup> As part of the ‘motor’ circuit, the ventrolateral globus pallidus receives input from the putamen and projects to the ventrolateral thalamic nucleus, which is linked to the supplementary motor cortex. The dorsomedial globus pallidus is connected to the anterior caudate and ventral anterior thalamic nucleus, while the lateral pallidus is connected to the dorsolateral caudate. The latter projects indirectly to the dorsolateral prefrontal cortex, creating a circuit linked to executive function and behavioural control.<sup>20</sup> Ventral and anterolateral regions of the pallidus are also connected to the nucleus accumbens, as part of the limbic system, mediating reward and thereby impulsive or inappropriate actions in FTD.

**Neuroimaging.** In bvFTD, the globus pallidus has been shown to be approximately 10% smaller than controls.<sup>7,26,28</sup> The only study looking at genetic FTD across disease stages has found that fully symptomatic *MAPT* and *GRN* mutation carriers showed smaller volumes compared to controls (12–14%), while *C9orf72* expansion carriers showed reduced volumes (6%) even at a prodromal stage, reaching 16% volumetric difference when fully symptomatic.<sup>33</sup> The relatively small size of the pallidus, and poor contrast to noise in many standard volumetric MRI sequences, means that its importance to FTD symptomatology may have been under-recognised from previous imaging studies.

**Pathology.** In a study on pathologically confirmed cases of FTLT, only few TDP-43 inclusions were found in the globus pallidus and ventral pallidus, compared to other basal ganglia structures.<sup>44</sup> FUS-positive lesions were found in the globus pallidus in bvFTD with neuronal intermediate filament inclusion disease pathology.<sup>61</sup> These were less frequent in bvFTD cases with atypical FTLT with ubiquitinated inclusions. A case study of a patient with bvFTD and TDP-43 type C revealed severe neuronal loss, gliosis and TDP-43 inclusions in the pallidus as for other regions of the basal ganglia.<sup>62</sup> Cases with bvFTD and parkinsonism due to a mutation in *MAPT* showed tau positive inclusions in the pallidus, together with gliosis and neuronal loss.<sup>63</sup>

**Symptomatology.** The pallidus plays an important role in response inhibition, reducing thalamocortical output and consequently the activation in the motor cortex.<sup>64,65</sup> Consequently, pallidus atrophy can be associated with motor perseveration and disinhibition, which are common

symptoms in FTD.<sup>66,67</sup> In particular, pallidus atrophy in these patients has been linked to the ‘applause sign’,<sup>67</sup> and poor performance at the Go/No-Go Task of inhibitory control.<sup>68</sup> In addition, given the role of the ventral pallidus in the reward processing,<sup>69</sup> its degeneration in FTD correlates with higher reward-seeking behaviours.<sup>19</sup> In fact, clinical studies suggested that pallidal lesions can lead to apathy and anhedonia symptoms,<sup>70,71</sup> which are prevalent across all FTD syndromes,<sup>72–74</sup> and emerge even in presymptomatic mutation carriers.<sup>75,76</sup>

### Other parts of the basal ganglia

**Anatomy.** The basal ganglia include the substantia nigra and subthalamic nucleus. The substantia nigra is connected via the subthalamic nucleus to the globus pallidus in the cortico-striato-pallido-thalamic-cortical circuits, regulating motor, reward and executive functions.<sup>20</sup> The subthalamic nucleus is also connected to the amygdala, the orbitofrontal and inferior frontal cortex.<sup>77</sup>

**Neuroimaging.** Given the relatively small size of these nuclei, there are very few studies looking at volumetric differences in the substantia nigra and subthalamic nucleus in the FTD spectrum, and the main ones are related to parkinsonian syndromes. One study investigating the iron content in a cohort of bvFTD and PPA patients failed to find any difference in the substantia nigra,<sup>78</sup> while a *post mortem* 7T MRI study found a significant increase of iron deposition in the subthalamic nucleus of the FTLT-FUS, FTLT-TDP-43 and pure ALS groups, but not in the FTD-tau, while there was no difference in the substantia nigra from controls.<sup>79</sup>

**Pathology.** A case of bvFTD with confirmed TDP-43 type C showed severe neuronal loss and gliosis without TDP-43 inclusions in the subthalamic nucleus, while the substantia nigra was spared.<sup>62</sup> FTDP-17 causes mild neuronal loss and gliosis of subthalamic nucleus and depigmentation of the substantia nigra.<sup>63</sup> Overall, the subthalamic nucleus is typically atrophic with gliosis in the closely related disorder of PSP, while the substantia nigra shows pallor in most FTLT pathological forms.<sup>80</sup>

**Symptomatology.** Nigrostriatal neurons from the substantia nigra pars compacta regulate the subcortical–cortical loops for motor, oculomotor and cognitive control, through their terminations to the striatum. Neurodegeneration of this structure and reduced level of dopamine in the substantia nigra is typically associated with parkinsonian syndromes.<sup>81</sup> Parkinsonism with rigidity and akinesia is commonly seen in bvFTD,<sup>82</sup> in sporadic FTD and especially in FTD arising from mutations in *MAPT*, *GRN* and *C9orf72*. Specifically, in *GRN* mutation carriers, the parkinsonism correlates with the degeneration and neural inclusions in the substantia nigra.<sup>83</sup> Pathology in the subthalamic nucleus and its connections is particularly associated with disinhibition,<sup>64,65</sup> but can

also affect emotion recognition and prosody decoding,<sup>77</sup> all of which are commonly affected in bvFTD.

## Medial temporal lobe

### Hippocampus

**Anatomy.** The hippocampus is a key component of the medial temporal lobe, involved in the formation of new memories and associated with learning and emotion.<sup>84,85</sup> Specifically, the posterior hippocampus is involved in memory processing, through its connections with the medial and lateral parietal, medial prefrontal and posterior cingulate cortex, via a pathway involving the fornix projections to the mamillary bodies of the hypothalamus, anterior thalamic nucleus and anterior cingulate.<sup>86,87</sup> The anterior part is instead more involved in emotion regulation, sensory–motor integration and goal-directed activity, due to the connections with the limbic structures (amygdala, nucleus accumbens, ventromedial prefrontal, orbitofrontal, anterolateral temporal, temporal pole, insula and cingulate cortex).<sup>84,86,88,89</sup>

The hippocampus is composed of different cytoarchitectonic subfields, mainly part of the allocortex, which have specialized functions and distinctive connections.<sup>85,90</sup> Four main systems have been described<sup>87</sup>: an *episodic memory network* (originating in the subiculum and involving the anterior dorsal and lateral dorsal thalamic nuclei, mamillary bodies and retrosplenial cortex); an *emotional–social anterior network* (connecting the anterior CA1 and subiculum with the prefrontal cortex, amygdala and nucleus accumbens); a *sensory processing and integration system* (connecting CA1 and the subiculum with the parahippocampal cortex); and a *network for familiarity signalling and retrieval processing*, with extensive connection between the hippocampus, the prefrontal cortex and the thalamus.

The principal efferents of the hippocampus are the subiculum and CA1, except for the basal forebrain and nucleus accumbens, which are mainly connected with CA3.<sup>87</sup> Further distinction and indirect pathways have been identified. The posterior part of the subiculum is connected to the lateral and medial parietal cortex, the frontal cortex and the striatum, while CA4 and the dentate gyrus are connected with the temporal and posterior cortex.<sup>86,91</sup> The dorsal CA1 and subiculum are connected to the mamillary bodies and anterior thalamic nuclei, important for exploratory behaviour and spatial navigation, while their ventral regions are connected to the amygdala (central, lateral and basolateral nuclei), basal forebrain, medial hypothalamus and shell of the nucleus accumbens to regulate emotions.<sup>89</sup> A resting-state functional study<sup>91</sup> has found that among the hippocampal regions, CA1 was more strongly connected to the amygdala and occipital cortex, while CA2, CA3, CA4 and the dentate gyrus were more strongly connected to the left anterior cingulate, temporal and occipital cortex, while the subiculum

to the angular, precuneus, posterior cingulate, frontal cortex and putamen.

**Neuroimaging.** Hippocampal atrophy has traditionally been described as particularly characteristic of Alzheimer's disease, but many studies over the past 20 years have shown its involvement in some forms of FTD.<sup>9,28,92,93</sup> bvFTD have been reported to have 17–23% smaller hippocampus than controls.<sup>7,28,29</sup> svPPA is associated with a characteristic pattern of asymmetrical atrophy of the anterior hippocampus (left greater than right), with usually 25–39% difference from controls on the left and 12–22% on the right<sup>92–96</sup>; and an annualized rate of atrophy of 0.14 on the left and 0.18 ml per year on the right.<sup>97</sup> In contrast, studies generally report no significant hippocampal atrophy in those with nvPPA.<sup>92</sup>

Looking at the genetic forms of FTD, the hippocampus is particularly atrophic in *MAPT* mutation carriers compared with *C9orf72* and *GRN* mutation carriers.<sup>98–100</sup> Volume loss occurs around 15 years before expected onset in *MAPT* mutation carriers,<sup>17</sup> with a faster annual rate of atrophy compared with other genetic forms of FTD.<sup>31,101</sup>

In patients with pathologically confirmed FTD, the hippocampus has been shown to be significantly smaller in Pick's disease (33% volume difference from controls) as well as in FTDP-17 (i.e. *MAPT* mutations: 43%) and TDP-43 type C cases (usually those with svPPA: 33%). Other pathologies have involvement to a lesser extent: FUS (31%), TDP-43 type A (23%) and CBD (14%).<sup>15</sup>

Hippocampal subfields have also been investigated in FTD. In svPPA, both the CA1 and subiculum regions were significantly smaller in svPPA than controls (27% and 24% volumetric difference, respectively).<sup>96</sup> In a study of genetic FTD, a differential pattern of involvement was seen in the different groups: *MAPT* mutation carriers showed a 24–27% volumetric difference in the hippocampus proper (formed by the CA subfields), whilst *C9orf72* expansion carriers showed most atrophy in the dentate gyrus and CA1/4 (8–11%), and *GRN* mutation carriers were most affected in the subiculum and presubiculum (10–14%).<sup>100</sup> In a larger study looking at different disease stages,<sup>33</sup> all hippocampal regions were smaller than controls for fully symptomatic carriers for mutations in all three major genes. Differences were detected in several regions at asymptomatic and prodromal stages in both *MAPT* (the earliest in subiculum, presubiculum and tail) and *C9orf72* groups (the earliest in dentate gyrus, CA1/4 and presubiculum), and in the presubiculum (8%) in the prodromal stages of *GRN* mutation carriers.

**Pathology.** At *post mortem*, the hippocampus shows mild to severe neuronal loss, with 48% of cases showing hippocampal sclerosis (typically TDP-43 proteinopathies) and 64% showing the classic ubiquitinated inclusions in the dentate gyrus.<sup>12,102</sup> In cases with confirmed TDP-43 pathology, the head of the hippocampus shows an average 57% atrophy in svPPA compared with controls,

while bvFTD has 46% atrophy, more evenly distributed along the hippocampus.<sup>103</sup> Pick's bodies are consistently found in the granule cells of the dentate gyrus, the pyramidal cells of CA1 and the subiculum,<sup>12,13,102</sup> whilst tau-positive grains and pre-tangles are found in the CA1 and dentate gyrus.<sup>12</sup>

Pathological studies in general are consistent with *in vivo* imaging of the genetic groups: tau deposition is extensively found in the hippocampus and other limbic structures in *MAPT* mutations<sup>104</sup>; dipeptide repeat proteins, together or without TDP-43 deposition, are found in the CA subregions in *C9orf72*; while TDP-43 accumulates in the hippocampus and the cortex in *GRN*.<sup>105</sup>

**Symptomatology.** The hippocampus is central to memory. Although significant episodic memory impairment is an exclusion criterion under current diagnostic criteria for bvFTD, improving the distinction from other causes of dementia, episodic memory can be affected in FTD. Indeed, several of Pick's original cases had prominent memory symptoms, and one study reported amnesia in the initial clinical evaluation of 10% of pathologically confirmed cases.<sup>106</sup> In bvFTD, memory deficits can co-occur with executive dysfunction, and involve both retrograde and anterograde memory performance. Similarly, svPPA patients can present episodic memory deficits, while nfvPPA patients generally show only mild autobiographical memory difficulties.<sup>107</sup> Such episodic memory deficits in both bvFTD and svPPA are attributable in part to hippocampal dysfunction. Specifically, there is an association in bvFTD between hippocampal degeneration and deficits in memory recall and storage impairments,<sup>47,108</sup> and episodic future thinking deficits.<sup>109</sup> Hippocampal dysfunctions also relate to reduced mind wandering capacity<sup>110</sup> and scene construction performance.<sup>111</sup> However, despite the presence of hippocampal degeneration, FTD patients typically show preserved spatial navigation capacity in contrast to patients with Alzheimer's disease and structural hippocampal lesions, suggesting that degeneration in the posterior parietal structures and other brain regions may mediate these deficits.<sup>112</sup>

Hippocampal deficits are relevant to more than memory domains in FTD, as this structure is involved in emotion modulation and evaluation of facial emotion.<sup>113</sup> These are impaired not only in bvFTD but also in svPPA, especially right semantic dementia, and 'temporal variant' FTD.<sup>114</sup> Atrophy in the anterior hippocampus in bvFTD and svPPA correlates with the typical symptoms of these two clinical groups: apathy and impaired social conduct in bvFTD, and anomia and impaired single word comprehension with preserved episodic memory in svPPA.<sup>115</sup> Hippocampal volume is also reduced in FTD patients presenting with obsessive-compulsive behaviours.<sup>116</sup> There are genetic influences on the hippocampal pathology and symptomatology. For example, severe medial temporal atrophy is seen in *MAPT* mutation carriers, with the greater involvement of the anterior and

central regions of the hippocampus which form part of the limbic system: this is associated with the difficulties seen in these patients in regulating emotion and goal-directed behaviour.<sup>31</sup>

## Amygdala

**Anatomy.** The amygdala is a limbic structure, composed of several subnuclei with different connections to the rest of the brain.<sup>117,118</sup> The amygdala is involved in motivation, emotion, reward learning and in other cognitive functions (attention, perception and explicit memory).<sup>117</sup>

The nuclei of the amygdala are heterogeneous in composition, connections and roles.<sup>117</sup> The lateral and basal amygdala are considered cortical regions, while the central and medial nuclei are considered ventral extensions of the striatum. The lateral nucleus is the 'gatekeeper' of the amygdala, as the major receiver of inputs from sensory and somatosensory systems, and important for processing of pain, fear learning and memory. The central nucleus is instead the most important output region, key for the control of motivation, emotional and behavioural responses, and connected to the brainstem, striatum, thalamus (mediodorsal, pulvinar and central nucleus), basal forebrain and lateral hypothalamus.<sup>117,118</sup> Together with the central nucleus, the accessory basal, basal and paralaminar nuclei are considered the main component of the reward system within the amygdala, to motivate and reinforce behaviours.<sup>117-121</sup>

**Neuroimaging.** Amygdalar atrophy is common in bvFTD with prior studies reporting a 19–33% volume loss on the right and 22–41% on the left.<sup>122,123</sup> Patients with svPPA show more atrophy than those with nfvPPA and bvFTD,<sup>14,123</sup> with a strong asymmetry: 51–65% volume difference on the left (when left-predominant svPPA), and 33–54% on the right amygdala when compared to controls.<sup>9,94,95,97,123</sup> Volume loss is smaller in bvFTD, around 10–19% smaller than controls in one study, with an annual atrophy rate of 4%.<sup>7,27,28</sup>

Studies of genetic FTD have shown that the amygdala is particularly affected in *MAPT* mutation carriers,<sup>31,99</sup> a decade or more before the symptom onset.<sup>17</sup> With recent developments in imaging technology, the amygdalar subnuclei are now measurable on MR imaging.<sup>124</sup> Symptomatic *MAPT* mutation carriers showed smaller volumes particularly in the superficial and accessory basal regions (44%), which were 2–4% smaller even at an asymptomatic stage.<sup>33</sup> Whilst *GRN* mutation carriers only showed smaller volumes than controls when fully symptomatic, *C9orf72* expansion carriers showed reduced volumes in all amygdalar regions even at the asymptomatic and prodromal stages, with the main reduction being in superior-medial regions.<sup>33</sup>

In pathologically confirmed cohorts, amygdalar atrophy is most marked in cases with FTDP-17 (*MAPT* mutation carriers) and TDP-43 type C (usually svPPA),<sup>15,125,126</sup> with 50% smaller volume than controls.<sup>15</sup> When looking

at the evolution of brain atrophy in svPPA with and without confirmed TDP-43 type C pathology, the amygdala was found to be affected at the very early stages on both sides.<sup>37,126,127</sup> However, there is also significant involvement in those with Pick's disease (45% difference from controls), more so than those with FUS (37%), TDP-43 type A (25%) or CBD (20%) pathology.<sup>15,126</sup> For the amygdalar subregions, a recent study of pathologically confirmed FTD cases reported a differential involvement with the medial subnuclei (particularly the superficial, accessory basal and basal/paralamina subnuclei) being more affected than the lateral subnuclei.<sup>126</sup>

**Pathology.** Neuropathological studies have shown severe amygdalar volume loss of 52% in FTD.<sup>128</sup> One study on TDP-43 pathology showed inclusions in the basolateral nucleus of the amygdala in the earliest stage of the disease.<sup>129</sup>

**Symptomatology.** Amygdala is a key area in the reward and punishment system. The core behavioural features and symptoms of FTD (i.e. lack of insight, impaired personal and social conduct, disinhibition) are consistent with the loss of function of the amygdala, and are regularly seen with all types of FTD-related pathology.<sup>12,13</sup> The subnuclei most affected in FTD are connected to other limbic regions. Across all FTD variants, atrophy of the amygdalar subnuclei relates to a wide range of behavioural and neuropsychiatric scales,<sup>14</sup> either directly or through the deficits in the reward and emotional processing caused by bvFTD and svPPA.<sup>130,131</sup> The medial nuclei are likely related to the development of symptoms associated with abnormal reward and emotional processing, relative to the salience and limbic networks<sup>132,133</sup>; indeed the amygdala plays a role in evaluating the motivation and emotional context of a given stimulus, and feeds back the information to the brainstem to control emotional reaction, and to the striatum to control actions.<sup>117</sup>

Atrophy and hypometabolism of the amygdala relate to deficits in the emotion processing and recognition, and social interaction insight.<sup>134–138</sup> It is also linked to impaired comprehension of intentionality,<sup>139</sup> and insensitivity to negative stimuli.<sup>140</sup> Some reports indicate right sided associations<sup>134,135,137,138</sup> while others reveal left sided associations,<sup>137,141</sup> especially involving the superficial and basolateral nuclei. Deficits in social cognition, interoceptive accuracy or emotion comprehension were found to be related to amygdalar atrophy on the right hemisphere or bilaterally in svPPA<sup>138,142</sup> and the temporal variant of FTD.<sup>114</sup> In patients with the 'right temporal variant of FTD', deficits in facial expression recognition, reduced empathy and emotional reaction are commonly observed.<sup>114</sup> Emotion recognition deficits correlate with atrophy in the left amygdala in patients with nfvPPA.<sup>143</sup>

### Basal forebrain

**Anatomy.** The basal forebrain is a collection of cholinergic nuclei, including the diagonal band of Broca, the

medial septal nucleus and the nucleus basalis of Meynert.<sup>144</sup> Via cholinergic pathways linking the cortex and limbic system, they are essential for different cognitive processes, including memory, learning and attention.<sup>145,146</sup>

**Neuroimaging.** Basal forebrain volume is reduced in both svPPA and nfvPPA as compared to controls, mainly in the posterior part of the nucleus basalis.<sup>147–149</sup> Patients with bvFTD and svPPA were reported to have significantly lower volumes than controls (9–10%) and nfvPPA (4–5%), with FTD-ALS and all PPA variants also having lower volumes than controls (5–9%).<sup>150</sup> Among genetic cases, only fully symptomatic *MAPT* mutation carriers showed significantly smaller basal forebrain volumes than controls (15–18%) and both *GRN* and *C9orf72* groups (14–17%).<sup>33,150</sup> In the same study,<sup>150</sup> pathologically confirmed cases with tau showed the smallest basal forebrain volumes (mainly driven by FTDP-17 and Pick's disease) than controls (10%), while among the TDP-43 proteinopathies, the lower volumes were driven by those with TDP-43 type C pathology.

**Pathology.** In one study, TDP-43 inclusions have been found in the basal forebrain (including the diagonal band of Broca, nucleus basalis of Meynert and substantia innominata).<sup>44</sup> Patients with PPA showed a severe reduction in the cholinergic neurons in the nucleus basalis of Meynert and nucleus subputaminalis.<sup>151</sup>

**Symptomatology.** Atrophy and pathology of the basal forebrain can lead to diverse symptoms in FTD, but a unifying framework for these effects is outstanding. The cholinergic system plays a key role in cognitive processing, and the cholinergic dysfunction seen in bvFTD and PPA arise from the degeneration of the nucleus basalis. For example, language impairment in PPA has been partially attributed to the cholinergic deficits from the basal forebrain pathology.<sup>147,148,152,153</sup> A role of the basal forebrain in social cognition and attachment has been proposed, given the density of receptors for oxytocin and vasopressin.<sup>154</sup> This accords with the association between basal forebrain hypometabolism with abnormal prosocial sentiments in bvFTD (i.e. pity and guilt).<sup>155</sup> Despite these associations, cholinergic dysfunction seems to be more marked in CBS and PSP than other FTD syndromes, which may in part explain why cholinesterase inhibitors have not proven effective to improve cognitive function and behavioural symptoms in bvFTD and PPA.<sup>156,157</sup>

## Thalamus, hypothalamus and habenula

### Thalamus

**Anatomy.** The thalamus is the relay station of the brain, and it is connected to the majority of other regions. It is composed of several nuclei, each of them with specific connections and functional specialization.<sup>158</sup> While the anterior, lateral, ventro-anterior and medio-dorsal nuclei are



considered limbic structures, the ventrolateral and ventromedial are considered motor, and the latero-posterior, ventro-posterior lateral, midline and intralaminar are considered associative and somatosensory (reviewed in Bocchetta et al.<sup>159</sup>). The lateral and medial geniculate nuclei have specific sensory functions in the visual and auditory system, while the pulvinar plays a role in the intramodality integration of somatosensory and visual information, and in the presence of affective and psychotic symptoms, including hallucinations.

**Neuroimaging.** Thalamic atrophy is a common feature across all clinical, genetic and pathological forms of FTD,<sup>17,160–162</sup> and occurs even in the early clinical stages.<sup>8</sup> bvFTD and nfvPPA show bilateral atrophy in the anterior and posterior thalamus.<sup>14,16,28</sup> Both Pick's disease and TDP-43 type A groups showed asymmetric volume loss in the thalamus.<sup>15</sup>

Among the genetic groups, the *C9orf72* expansion carriers have been considered to be the ones where the thalamus was particularly affected, even presymptomatically<sup>17,163</sup> when considering either those between 20 and 40 years of age<sup>164</sup> or those without any clinical symptoms.<sup>33</sup> However, whilst there is more widespread involvement of the thalamus later, it seems that the earliest change is in the pulvinar nucleus,<sup>165–167</sup> even at a presymptomatic stage<sup>168</sup>; this region tends to be less affected in all other forms of FTD.<sup>159</sup> In a detailed study of thalamic subnuclei, the medial dorsal was affected across all clinical, genetic and pathological FTD subgroups.<sup>159</sup> Changes in the thalamic regions only become visible at the fully symptomatic stages in both *GRN* and *MAPT* mutation carriers, with atrophy mainly localized in the medial dorsal, midline and laterodorsal nuclei (22–31%), while the lateral geniculate nucleus was spared in both groups, but atrophic in *C9orf72*.<sup>33</sup>

**Pathology.** *Post mortem* volume analysis of svPPA confirmed 27% loss of volume in the anterior thalamus<sup>103</sup> and 34% reduction for bvFTD, with confirmed TDP-43 pathology. From a subnuclei point of view, pathological studies have shown a marked involvement of the medial dorsal nucleus, with neuronal loss, gliosis and astrocytosis in bvFTD.<sup>169</sup> However, pathological hallmarks of FTD are not evenly distributed in the thalamus. For example, TDP-43 is mainly found in the medial nuclei of thalamus (including anterior, lateral dorsal and dorsomedial nuclei), in the periventricular thalamic neurons, while few inclusions are found in the lateral nuclei of the thalamus.<sup>44</sup>

**Symptomatology.** The heterogeneity of thalamic nuclei and their position within parallel cortico-striato-thalamo-cortical loops for cognition and motor control means that the thalamic pathology in FTD gives rise to diverse symptoms and signs. However, there is ongoing work looking at the specificity of the thalamic origin of the FTD symptoms, trying to accurately localize the thalamic nucleus involved for each clinical phenotypes and genetic forms. It is also challenging to dissociate the direct effects

of pathology of the thalamic nuclei, from changes in their afferent and efferent connections,<sup>19</sup> and degeneration of the cortical projections of each nucleus.

The symptomatology of thalamic changes in FTD follows the functional anatomical circuits discussed above. For example, in *C9orf72* expansion carriers the pulvinar pathology is consistent with impairment of limbic functions and intramodality integration of sensory information,<sup>158</sup> including altered processing of pain, hallucinations, affective and psychotic manifestations of FTD.<sup>170–172</sup> In bvFTD, atrophy in the pulvinar also relates to lower prosocial giving,<sup>173</sup> consistent with an integrative role in social, affective and reward processing. In contrast, pathology in the medial dorsal nucleus in different variants of FTD affects connectivity with widespread brain regions including orbital, lateral and dorsal prefrontal cortex, and other limbic regions. This can exacerbate emotional and executive impairments over and above the cortical pathology. Damage in the thalamic regions forming part of the anterior cingulate circuits have been associated with changes in apathy and memory.<sup>169</sup> As part of the Papez circuit, thalamic degeneration may increase memory deficits, where for example atrophy in the thalamus and fornix has been reported to be associated with severity of amnesia in bvFTD.<sup>162</sup>

## Hypothalamus

**Anatomy.** The hypothalamus plays an important role in food intake, reward and perception of satiety. It also regulates the homeostasis of neuroendocrine, behavioural, and autonomic processes, including circadian rhythm, stress response, sexual and defensive behaviours and thermoregulation.<sup>174,175</sup> It is composed of a number of different subnuclei and is highly interconnected with other parts of the central nervous system, particularly the brainstem, limbic system and cortex. Besides axonal connections, the hypothalamus contains neuropeptide-expressing neurons and neuropeptide receptors, and it engages with the pituitary gland to release hormones into the bloodstream.<sup>175,176</sup> The nuclei involved in the food intake are mainly the lateral hypothalamus, and the arcuate, dorsomedial and paraventricular nuclei.<sup>175</sup>

**Neuroimaging.** In a study of eighteen people with bvFTD, hypothalamic volume was reduced 17% compared with controls, with the main differences localized to the superior parts of the anterior and tuberal regions and the posterior region, which regulate appetite.<sup>177</sup> Another study has confirmed atrophy of the hypothalamus in bvFTD, particularly in its posterior portion, but not in svPPA.<sup>178</sup>

In a small study which included those with genetic FTD, atrophy was significantly more severe than controls in *MAPT* mutation carriers (in superior and posterior areas), but not in those with *C9orf72* expansions. In particular, the posterior part of the hypothalamus was the most affected area, including the mamillary bodies, which

are connected to the amygdala and hippocampus, both structures known to be particularly atrophic in *MAPT* mutation carriers.<sup>177</sup> In a larger study across disease stages,<sup>33</sup> hypothalamic volumes were smaller in fully symptomatic mutation carriers (except for the inferior tubular regions in *C9orf72* and *GRN*), with *MAPT* symptomatic carriers showing up to 29% smaller volumes in the posterior and anterior regions. However, the only group showing smaller volumes before symptom onset was *C9orf72*, especially in the superior anterior and tubular regions.

**Pathology.** Multiple pathologies have shown involvement of the hypothalamus. For example, one study showed a volume reduction of 41% in bvFTD and TDP-43 pathology cases when compared to controls.<sup>103</sup> In a *post mortem* study of 19 cases with TDP-43 pathology, inclusions were found in the lateral hypothalamic area, tuberomammillary nucleus, lateral tubular nucleus, preoptic area, ventromedial and dorsomedial nuclear groups, and in the posterior hypothalamic area. No inclusions were seen in other hypothalamic regions.<sup>44</sup> The hypothalamic lateral tubular nucleus was also shown to be severely affected in Pick's disease.<sup>12</sup> Cases with tau pathology and Pick's disease showed more abnormal protein deposition than cases with TDP-43 type B, with this latter showing more severe posterior hypothalamic atrophy than the tau group.<sup>179</sup>

**Symptomatology.** The key role of the hypothalamus in appetite, food-reward and the perception of satiety is reflected in the symptoms associated with its degeneration in FTD. Abnormal eating behaviours are present in up to 60% of patients with FTD, and particularly prominent in patients with bvFTD and svPPA.<sup>180</sup> Hyper-oralality and sweet tooth are diagnostic criteria for bvFTD,<sup>1</sup> but the specific symptoms vary widely between individuals. bvFTD can present with complex eating behaviours, from overeating to sweet craving, to obsessions for specific foods.<sup>181</sup> Alteration in eating behaviours may be driven by hypothalamic pathology via multiple processes, over and above cortical and striatal mediation of poor impulse control and environmental dependency. Posterior and whole hypothalamic atrophy has been shown to correlate with abnormal eating behaviours.<sup>178,182</sup> Specifically, feeding behaviour alterations are related to localized degeneration in the lateral hypothalamic nuclei, and the arcuate and paraventricular nuclei.<sup>183</sup> In contrast, lesions in posterior hypothalamus contribute to autonomic dysfunction and altered satiety responses.<sup>184</sup>

Structural and functional alterations of the hypothalamus are associated with autonomic deficits in bvFTD, such as lower baseline skin conductance levels.<sup>185</sup> Cardiac, urinary and thermoregulatory dysfunctions have been reported in patients with FTD,<sup>186,187</sup> as described in the original diagnostic criteria.<sup>188</sup> Sleep disturbances are also prevalent in FTD,<sup>189</sup> and might be associated with hypothalamic degeneration and the loss of its connections with the frontotemporal cortex.<sup>190</sup> The direct sleep

disturbances from FTD need to be separated from indirect effects of physical disability, motor deficits, poor sleep hygiene arising from altered lifestyle, and iatrogenic pharmacological impairments. Nonetheless, sleep disturbance as a result of FTD itself is common, including either hypersomnolence or insomnia. These can be refractory to treatment, arising from degeneration of central thalamic or hypothalamic regulators of circadian rhythms.

## Habenula

**Anatomy.** The habenula is a small but key nucleus within the reward network.<sup>191</sup> It integrates information from the other limbic structures and basal ganglia to generate goal-directed behaviours, by processing and balancing reward and adversity.<sup>192,193</sup> The lateral habenula is connected to the lateral hypothalamic and lateral preoptic areas, basal forebrain, ventral pallidus, amygdala, substantia nigra and brainstem.<sup>192</sup> It also receives input from the anterior insula, anterior cingulate and ventral frontal pole.<sup>193</sup> The medial habenula is connected to the basal forebrain and midbrain.<sup>193</sup>

**Neuroimaging.** Only one small study has reported the habenula changes in FTD, showing a 29% lower volume in bvFTD compared with controls.<sup>194</sup> Other studies have not reported this structure in FTD, perhaps due to its small size and the lack of an automated method which currently makes its quantification unfeasible in large cohorts.

**Pathology.** There are currently no studies reporting the presence of pathology or neurodegeneration in the habenula in FTD.

**Symptomatology.** The habenula mediates the processing of negative and aversive information, and suppresses actions when it is anticipated that these will not produce a reward or avoid a negative feedback.<sup>193,195</sup> The habenula is activated by negative feedback.<sup>196</sup> Given this function, neurodegeneration in the habenula can lead to perseveration (due to inconsistency use of negative feedback) or disinhibition and impulsivity (due to inability to avoid an action),<sup>192</sup> and to the abnormal reward behaviours often seen in bvFTD patients. In addition, in animal studies, the lateral habenula and its connections with prefrontal regions have been reported as implicated in working memory and other executive functions,<sup>197–199</sup> which are characteristically impaired in patients with bvFTD.<sup>1</sup> The role of habenula in these functions is also supported by its modulatory role on the activity of the dopaminergic system.<sup>200,201</sup> However, further work is required to establish the specific role of habenula dysfunction as a direct cause of behavioural change in FTD.

## Brainstem and cerebellum

### Brainstem

**Anatomy.** The brainstem is divided into the midbrain, pons and medulla oblongata. The midbrain is associated with vision, hearing, sleep and motor control, and it also

forms part of a network that regulates emotion perception with the thalamus and amygdala.<sup>202</sup> The pons is connected to both the cerebrum and the cerebellum, via the cerebellar peduncles, and it is associated with respiration and facial expression. The medulla connects the cerebrum to the spinal cord, and regulates cardiac and respiratory functions, reflexes and integrative functions, such as consciousness, emotional processing, pain and motivation.<sup>203</sup>

**Neuroimaging.** Few imaging studies have focussed on the brainstem in FTD, perhaps because of the exclusion of the brainstem from early imaging atlases of grey matter. However, brainstem changes are typical of other tauopathies, and in particular CBS and PSP, with PSP showing marked atrophy in the midbrain and superior cerebellar peduncle.<sup>204–206</sup> As PSP often overlaps clinically with nfvPPA and bvFTD,<sup>3,207</sup> it is not surprising that patients with these overlapping syndromes present with brainstem involvement in addition to the typical cortical pattern of bvFTD and PPA.<sup>208</sup> A study of 22 FTD patients (5 of whom also met criteria for ALS) reported 10% smaller volumes than controls in the brainstem, including midbrain, pontine tegmentum, superior and inferior colliculi.<sup>161</sup> In a diffusion imaging study, bvFTD, bvFTD with ALS, nfvPPA, and PSP patients showed abnormal measures in the brainstem, while in svPPA the brainstem was spared.<sup>209</sup> This also suggested that patients with probable tau pathology (like nfvPPA and PSP) showed abnormal changes in the brainstem, superior and inferior cerebellar peduncles more than those with probable TDP-43 pathology (svPPA and bvFTD with ALS). However, the brainstem, and specifically the pons, has been found to be atrophic in *GRN* mutation carriers, who typically show TDP-43 pathology.<sup>31</sup> This result was confirmed by a recent large study on genetic FTD,<sup>33</sup> which reported 5–8% smaller volumes of the superior cerebellar peduncle, midbrain and pons in *GRN* mutation carriers, 9% smaller midbrain volumes in *MAPT* mutation carriers, but no difference in *C9orf72* expansion carriers, nor in any presymptomatic carriers.

**Pathology.** TDP-43 pathology and neuronal loss has been found previously in several nuclei of the midbrain and pons in cases with bvFTD, bvFTD and ALS, and PPA variants.<sup>210,211</sup>

**Symptomatology.** Despite the name ‘frontotemporal dementia’, brainstem pathology is commonly associated with functional impairment in FTD. Functional networks responding to salient events and enabling adaptive behaviour include brainstem nuclei, and they are impaired in FTD.<sup>212</sup> The salience network is active in response to stimuli that are emotionally significant.<sup>132</sup> In this way, brainstem degeneration contributes to some of the deficits in social cognition and emotion processing attributed to cortical pathology in FTD. In addition, the thalamus–amygdala axis for emotion and social perception is moderated by brainstem projections,<sup>202</sup> and especially by the midbrain, which is affected in *MAPT* mutation carriers.

The brainstem reticular activating system and its projections to the cerebrum are critical for arousal, and its neurodegeneration is associated with apathy in FTD.<sup>74</sup>

Beyond behavioural symptoms, the clinical overlap between FTD, PSP and other forms of parkinsonism also consists in motor symptoms, which are underpinned by brainstem degeneration, as identified by *post mortem* and imaging studies.<sup>74,82,207</sup> These symptoms include impairment of oculomotor control by the superior colliculus in the midbrain tectum.<sup>213</sup> Atrophy of the tectum occurs in FTD,<sup>161</sup> explaining saccade abnormalities in these patients with and without PSP-aetiology.<sup>214</sup> In particular, in PSP this manifests in slow and hypometric vertical saccades, and later a vertical gaze palsy.

Brainstem nuclei are the main sources of the principal modulatory neurotransmitter systems, including serotonergic, dopaminergic and noradrenergic innervation of the forebrain. FTD affects the serotonergic projections from the raphe nuclei, the dopaminergic projections from the ventral tegmental area and the noradrenergic projections from the locus coeruleus.<sup>81</sup> Changes to such fundamental distributed systems are expected to have widespread consequences on cognition and behaviour. Indeed, serotonin dysfunction in FTD is confirmed by reduced transmission and postsynaptic receptor density, and relates to behavioural changes, such as aggression, impulsivity and increased appetite.<sup>215–216</sup> In many patients, FTD is associated with depletion of nigrostriatal dopamine projections, loss of pre-synaptic dopaminergic neurons and altered dopamine receptor binding in the striatum. This leads to cognitive change, motor parkinsonism and vulnerability to iatrogenic extra-pyramidal symptoms.<sup>82,217</sup> Impairment in the noradrenergic system from degeneration in the locus coeruleus is likely to contribute to the dysregulation of attention, memory and decision-making, although specific associations in FTD are yet to be established as they have been for PSP.<sup>218–220</sup>

## Cerebellum

**Anatomy.** Traditionally, cerebellar function has been associated only with the coordination of movement, but recent studies have found that the cerebellum is important in cognitive and emotional processing.<sup>221,222</sup> The cerebellum has several connections with key areas involved in FTD, in particular to the prefrontal cortex via the thalamus,<sup>223,224</sup> and to the limbic system via a direct cerebello-limbic pathway.<sup>225–227</sup> More specifically, the superior–posterior cortex (lobule VI, VIIa-Crus I, VIIa-Crus II, VIIIb), connected to the ventrolateral and ventro-anterior thalamus to the prefrontal cortex, has been associated with cognitive processing (executive functions, language, attention) and social cognition.<sup>221,222,224</sup> The vermis is instead also called the ‘limbic cerebellum’, as it plays a role in the modulation of emotional and social behaviours.<sup>221,225–227</sup> The anterior cerebellum is instead the area linked with motor/sensorimotor functions.<sup>221</sup> The deep cerebellar nuclei (dentate,

interposed and fastigial nuclei) receive intrinsic inputs from the cerebellar cortex to be sent to the other cortical regions via the ventro-anterior and ventrolateral thalamic nuclei.<sup>221</sup>

**Neuroimaging.** Differential involvement of the cerebellum has been shown in FTD, as also highlighted in a recent meta-analysis of neuroimaging studies.<sup>228</sup> Overall, in bvFTD changes were found in the Crus bilaterally, in the left lobule VI, in the right lobules VIIb and VIIIb, and part of the vermis.<sup>229,230</sup> In svPPA, changes were asymmetric, and mainly located in the left Crus I and lobule VI,<sup>228</sup> but also in the left lobules IV–V.<sup>229</sup> Cerebellar atrophy was also observed in nvPPA, localized bilaterally in the lobules VI, right Crus I and VIIb.<sup>229,230</sup>

The involvement of the cerebellum in *C9orf72* expansion carriers has been well characterized,<sup>17,99,231,232</sup> with the lobule VIIa-Crus I and VIIa-Crus II in the superior–posterior region of the cerebellum particularly involved, even at the earliest presymptomatic stages.<sup>33,233</sup> A small cohort of symptomatic mutation carriers<sup>233</sup> found the cerebellum to be relatively spared in those with *GRN* mutations, and localized to the vermis in *MAPT* mutation carriers, the ‘limbic cerebellum’ involved in the modulation of emotions and social behaviours, as already mentioned.<sup>221,225</sup> However, a larger cohort using the same methods did not confirm such differences in the *MAPT* group, but reported 8–13% smaller volumes in lobules VIIa-Crus II, VIIb and VIIIa in fully symptomatic *GRN* mutation carriers.<sup>33</sup>

**Pathology.** Interestingly, dipeptide repeat proteins, the characteristic pathology of *C9orf72* expansion carriers, are found throughout the cerebellum, in case with or without ALS phenotype.<sup>5,232,234–236</sup> *Post mortem* examination of two siblings with bvFTD showed massive abnormal tau deposition in astrocytes in the cerebellum.<sup>237</sup>

**Symptomatology.** The cerebellum has long been associated with motor control, and its lesions with ataxia. Although uncommon, ataxia has been described in patients with *C9orf72* expansions.<sup>238,239</sup>

Beyond motor control and movement, cerebellar functions extend to all areas of cognition, including affective, social and executive domains. Its role in cognitive and emotional processing in FTD is now emerging. For example, in bvFTD, Tan et al.<sup>240</sup> found an association between lobules V and VII (Crus I) and memory, language, executive and emotion deficits, together with an association between the vermis and memory and language dysfunction. Areas of cerebellar atrophy were linked with attention and working memory in bvFTD, visuospatial function in svPPA, and language-motor function in nvPPA.<sup>230</sup> Atrophy in the Crus and lobule VI was commonly associated with cognitive deficits in all FTD phenotypes, and in the Crus I and Crus II were associated with both behavioural disruption and cognitive dysfunctions.<sup>228</sup>

Changes in cerebellar connections have been linked with loss of episodic memory, attention, working

memory, visuospatial, executive function and emotion in bvFTD; with working memory, language and emotion in svPPA; and with attention, language, executive function, working memory, visuospatial and emotion in nvPPA.<sup>241</sup> Altered emotion processing and motivation have been described in patients with cerebellar damage,<sup>240,242,243</sup> and found related to cerebellar degeneration and disconnection in all FTD variants.<sup>240,241</sup> Cerebellar degeneration also correlates with eating behaviours in both bvFTD and svPPA,<sup>244</sup> and with decision making and theory of mind in bvFTD.<sup>245–247</sup> In *C9orf72*, structural changes in the cerebello-thalamic-cortical network are seen early presymptomatically, and by the time *C9orf72* expansion carriers reach the symptomatic stage, they have disturbances of body schema and related neuropsychiatric symptoms related to cerebellar disease.<sup>248</sup>

## Conclusion

Existing studies reveal extensive involvement of subcortical structures in the clinical, genetic and pathological forms of FTD. As summarized in Fig. 2, there is a complex differential pattern of atrophy in the different structures across the FTD spectrum. In general, bvFTD is associated with multiple regions of the reward network, including the nucleus accumbens, amygdala, hypothalamus and habenula. More specifically, by genetic and pathological group, the limbic structures (such as the amygdala, the hypothalamus, the posterior hypothalamus and the nucleus accumbens) are mainly affected in those with *MAPT* mutations as well as Pick’s disease, while the basal ganglia are mainly involved in those with *GRN* mutations and *FUS* pathology. *C9orf72* expansion carriers have a particular involvement in the pulvinar nucleus of the thalamus and the cerebellum, forming part of a cerebello-thalamic-cortical network related to neuropsychiatric symptoms in this group. Further studies are needed to explore and fully understand the role of these nuclei in all the forms of FTD, and in particular how their place within wider networks is lost as connections are broken down with disease progression.

The studies included in this review differ in a number of characteristics, including the imaging techniques used (manual or automated segmentation, volumetric region of interest or voxel-based morphometry), the sample size, the inclusion criteria for patients, the quality of MR images and the covariates included in the comparisons (disease duration, severity of symptoms, global atrophy). Therefore, results are not always directly comparable, or amenable to meta-analysis. Collaborative studies investigating multiple structures at the same time on large cohorts will be better able to provide a clearer picture of subcortical changes in FTD, including disease progression and variants. Adequately powered longitudinal studies, including sample size estimates, are essential to understand the variability of subcortical structures, especially

Subcortical structures:	Clinical diagnosis			Genetic diagnosis			Pathological diagnosis		
	bvFTD	svPPA	nvfPPA	GRN	C9orf72	MAPT	tauopathies	TDP-43opathies	FUSopathies
Nucleus accumbens	***	***		*	-	**	***	***	
Caudate	**	*	**	**	-	*	**	*	***
Putamen	**	**	*	**	*	*	**	**	***
Globus pallidus	**			*	*	*	*	*	
Substantia nigra	-	-	-						
Subthalamic nucleus								***	***
Hippocampus	**	***	-	*	**	***	***	***	**
Amygdala	**	***	*	*	*	***	***	***	**
Basal forebrain	**	**	**	-	-	***	***	***	-
Thalamus	**	*	**	*	***	*	*	**	*
Hypothalamus	***	-		*	*	**		*	
Habenula	**								
Brainstem	*	-	*	*	-	*	**	-	
Cerebellum	**	*	*	*	**	*	*	**	
	no evidence	spared -	mild *	moderate **	severe ***				

**Figure 2** Overview of the involvement of the subcortical structures in the clinical, genetic and pathological groups of FTD.

small but critical structures, such as the habenula and subthalamic nucleus. These are difficult to identify using automated methods or from clinical-grade images. The anatomical definition of the boundaries of some of these structures is also a relevant source of heterogeneity, not only across neuroimaging studies, but also *post mortem* investigations. Initiatives like the harmonization of hippocampal subfields ([www.hippocampalsubfields.com](http://www.hippocampalsubfields.com) Accessed on 21 July 2021)<sup>249</sup> are underway and will provide relevant resources to accurately address sources of variability. These investigations will be fundamental to develop MRI markers that include subcortical regions that are reproducible across studies, and for single subject assessments for stratification and monitoring in clinical trials.

With this review, we draw attention to the important role that the subcortical structures play in the spectrum of FTD, which has often been overlooked in the past. These regions are affected differently across the FTD disorders, and show clear early changes in the disease process.

## Funding

The Dementia Research Centre is supported by Alzheimer's Research UK, Brain Research Trust and The Wolfson Foundation. This work was supported by the National Institute for Health Research (NIHR) Queen Square Dementia Biomedical Research Unit, the NIHR UCL/H Biomedical Research Centre and the Leonard Wolfson Experimental Neurology Centre (LWENC) Clinical Research Facility as well as an Alzheimer's Society grant (AS-PG-16-007). MB is supported by a Fellowship award from the Alzheimer's Society, UK (AS-JF-19a-004-517). MB's work is also supported by the UK Dementia Research Institute which receives its funding

from DRI Ltd, funded by the UK Medical Research Council (MRC), Alzheimer's Society and Alzheimer's Research UK. JDR is supported by an MRC Clinician Scientist Fellowship (MR/M008525/1) and has received funding from the NIHR Rare Disease Translational Research Collaboration (BRC149/NS/MH). JBR and MM were supported by the Cambridge University Centre for Parkinson-Plus, the Medical Research Council (SUAG/051 G101400) and the NIHR Cambridge Biomedical Research Centre (BRC-1215-20014). The views expressed are those of the authors and not necessarily those of the NIHR or the Department of Health and Social Care.

## Competing interests

The authors report no competing interests.

## Data availability

Data sharing is not applicable to this review article as no new data were generated or analysed in this study. Source study data may be available from the authors cited.

## References

1. Rascofsky K, Hodges JR, Knopman D, et al. Sensitivity of revised diagnostic criteria for the behavioural variant of frontotemporal dementia. *Brain*. 2011;134(9):2456–2477.
2. Gorno-Tempini ML, Hillis AE, Weintraub S, et al. Classification of primary progressive aphasia and its variants. *Neurology*. 2011;76(11):1006–1014.
3. Woollacott IO, Rohrer JD. The clinical spectrum of sporadic and familial forms of frontotemporal dementia. *J Neurochem*. 2016; 138 (Suppl 1):6–31.

4. Warren JD, Rohrer JD, Rossor MN. Clinical review. Frontotemporal dementia. *BMJ*. 2013;347:f4827-
5. Mackenzie IR, Neumann M. Molecular neuropathology of frontotemporal dementia: Insights into disease mechanisms from post-mortem studies. *J Neurochem*. 2016;138 (Suppl 1):54–70.
6. Lashley T, Rohrer JD, Mead S, Revesz T. Review: An update on clinical, genetic and pathological aspects of frontotemporal lobar degenerations. *Neuropathol Appl Neurobiol*. 2015;41(7): 858–881.
7. Möller C, Dieleman N, van der Flier WM, et al. More atrophy of deep gray matter structures in frontotemporal dementia compared to Alzheimer's disease. *J Alzheimers Dis*. 2015;44(2): 635–647.
8. Seeley WW, Crawford R, Rascovsky K, et al. Frontal paralimbic network atrophy in very mild behavioral variant frontotemporal dementia. *Arch Neurol*. 2008;65(2):249–255.
9. Schroeter ML, Raczka K, Neumann J, Yves von Cramon D. Towards a nosology for frontotemporal lobar degenerations-a meta-analysis involving 267 subjects. *Neuroimage*. 2007;36(3): 497–510.
10. Kril JJ, Halliday GM. Clinicopathological staging of frontotemporal dementia severity: Correlation with regional atrophy. *Dement Geriatr Cogn Disord*. 2004;17(4):311–315.
11. Broe M, Hodges JR, Schofield E, Shepherd CE, Kril JJ, Halliday GM. Staging disease severity in pathologically confirmed cases of frontotemporal dementia. *Neurology*. 2003; 60(6):1005–1011.
12. Munoz DG, Dickson DW, Bergeron C, Mackenzie IR, Delacourte A, Zhukareva V. The neuropathology and biochemistry of frontotemporal dementia. *Ann Neurol*. 2003;54 (Suppl 5): S24–8.
13. Hodges JR, Miller B. The classification, genetics and neuropathology of frontotemporal dementia. Introduction to the special topic papers: Part I. *Neurocase*. 2001;7(1):31–35.
14. Garibotto V, Borroni B, Agosti C, et al. Subcortical and deep cortical atrophy in frontotemporal lobar degeneration. *Neurobiol Aging*. 2011;32(5):875–884.
15. Rohrer JD, Lashley T, Schott JM, et al. Clinical and neuroanatomical signatures of tissue pathology in frontotemporal lobar degeneration. *Brain*. 2011;134(Pt 9):2565–2581.
16. Chow TW, Izenberg A, Binns MA, et al. Magnetic resonance imaging in frontotemporal dementia shows subcortical atrophy. *Dement Geriatr Cogn Disord*. 2008;26(1):79–88.
17. Rohrer JD, Nicholas JM, Cash DM, van Swieten J, Dopper E, et al. Presymptomatic cognitive and neuroanatomical changes in genetic frontotemporal dementia in the Genetic Frontotemporal Dementia Initiative (GENFI) study: A cross-sectional analysis. *Lancet Neurol*. 2015;14(3):253–262.
18. Boccardi M, Sabatoli F, Laakso MP, et al. Frontotemporal dementia as a neural system disease. *Neurobiol Aging*. 2005;26(1): 37–44.
19. Perry DC, Sturm VE, Seeley WW, Miller BL, Kramer JH, Rosen HJ. Anatomical correlates of reward-seeking behaviours in behavioural variant frontotemporal dementia. *Brain*. 2014;137(Pt 6):1621–1626.
20. Alexander GE, DeLong MR, Strick PL. Parallel organization of functionally segregated circuits linking basal ganglia and cortex. *Annu Rev Neurosci*. 1986;9:357–e381.
21. Looi JCL, Walterfang M. Striatal morphology as a biomarker in neurodegenerative disease. *Mol Psychiatry*. 2013;18(4):417–424.
22. Utter AA, Basso MA. The basal ganglia: An overview of circuits and function. *Neurosci Biobehav Rev*. 2008;32(3):333–342.
23. Basar K, Sesia T, Groenewegen H, Steinbusch HW, Visser-Vandewalle V, Temel Y. Nucleus accumbens and impulsivity. *Prog Neurobiol*. 2010;92(4):533–557.
24. Looi JCL, Lindberg O, Zandbelt BB, et al. Caudate nucleus volumes in frontotemporal lobar degeneration: Differential atrophy in subtypes. *AJNR Am J Neuroradiol*. 2008;29(8):1537–1543.
25. Looi JCL, Walterfang M, Styner M, et al. Shape analysis of the neostriatum in subtypes of frontotemporal lobar degeneration: Neuroanatomically significant regional morphologic change. *Psychiatry Res*. 2011;191(2):98–111.
26. Halabi C, Halabi A, Dean DL, et al. Patterns of striatal degeneration in frontotemporal dementia. *Alzheimer Dis Assoc Disord*. 2013;27(1):74–83.
27. Frings L, Yew B, Flanagan E, et al. Longitudinal grey and white matter changes in frontotemporal dementia and Alzheimer's disease. *PLoS One*. 2014;9(3):e90814.
28. Landin-Romero R, Kumfor F, Leyton CE, Irish M, Hodges JR, Piguet O. Disease-specific patterns of cortical and subcortical degeneration in a longitudinal study of Alzheimer's disease and behavioural-variant frontotemporal dementia. *Neuroimage*. 2017; 151:72–80.
29. Möller C, Hafkemeijer A, Pijnenburg YA, et al. Joint assessment of white matter integrity, cortical and subcortical atrophy to distinguish AD from behavioral variant FTD: A two-center study. *Neuroimage Clin*. 2015;9:418–429.
30. Looi JCL, Svensson L, Lindberg O, et al. Putaminal volume in frontotemporal lobar degeneration and Alzheimer disease: Differential volumes in dementia subtypes and controls. *AJNR Am J Neuroradiol*. 2009;30(8):1552–1560.
31. Rohrer JD, Ridgway GR, Modat M, et al. Distinct profiles of brain atrophy in frontotemporal lobar degeneration caused by progranulin and tau mutations. *Neuroimage*. 2010;53(3):1070–1076.
32. Premi E, Garibotto V, Gazzina S, et al. Subcortical and deep cortical atrophy in frontotemporal dementia due to granulin mutations. *Dement Geriatr Cogn Dis Extra*. 2014;4(1):95–102.
33. Bocchetta M, Todd EG, Peakman G, et al. on behalf of the Genetic Frontotemporal Dementia Initiative (GENFI). Differential early subcortical involvement in genetic FTD within the GENFI cohort. *Neuroimage Clin*. 2021;30:102646.
34. Whitwell JL, Jack CR Jr, Senjem ML, et al. MRI correlates of protein deposition and disease severity in postmortem frontotemporal lobar degeneration. *Neurodegener Dis*. 2009;6(3):106–117.
35. Josephs KA, Whitwell JL, Parisi JE, et al. Caudate atrophy on MRI is a characteristic feature of FTL-D-FUS. *Eur J Neurol*. 2010;17(7):969–975.
36. Seelaar H, Rohrer JD, Pijnenburg YA, Fox NC, van Swieten JC. Clinical, genetic and pathological heterogeneity of frontotemporal dementia: A review. *J Neurol Neurosurg Psychiatry*. 2011;82(5): 476–486.
37. Bocchetta M, Iglesias Espinosa M, Lashley T, Warren JD, Rohrer JD. In vivo staging of frontotemporal lobar degeneration TDP-43 type C pathology. *Alzheimers Res Ther*. 2020;12(1):34-
38. Kril JJ, Macdonald V, Patel S, Png F, Halliday GM. Distribution of brain atrophy in behavioral variant frontotemporal dementia. *J Neurol Sci*. 2005;232(1-2):83–90.
39. Josephs KA, Stroh A, Dugger B, Dickson DW. Evaluation of subcortical pathology and clinical correlations in FTL-D-U subtypes. *Acta Neuropathol*. 2009;118(3):349–358.
40. Tsuchiya K, Ikeda K. Basal ganglia lesions in 'Pick complex': A topographic neuropathological study of 19 autopsy cases. *Neuropathology*. 2002;22(4):323–336.
41. Mackenzie IR, Baker M, Pickering-Brown S, et al. The neuropathology of frontotemporal lobar degeneration caused by mutations in the progranulin gene. *Brain*. 2006;129(Pt 11): 3081–3090.
42. Leverenz JB, Yu CE, Montine TJ, et al. A novel progranulin mutation associated with variable clinical presentation and tau, TDP43 and alpha-synuclein pathology. *Brain*. 2007;130(Pt 5): 1360–1374.
43. Ghetti B, Hutton ML, Wszolek ZK. Frontotemporal dementia and Parkinsonism linked to chromosome 17 associated with the tau gene mutations (FTDP-17T). In: DW Dickson, ed. *Neurodegeneration: The molecular pathology of dementia and movement disorders*. Basel: ISN Neuropath Press; 2003:86–102.

44. Cykowski MD, Takei H, Van Eldik LJ, et al. Hippocampal sclerosis but not normal aging or Alzheimer disease is associated with TDP-43 pathology in the basal forebrain of aged persons. *J Neuropathol Exp Neurol.* 2016;75(5):397–407.
45. Rosen HJ, Allison SC, Schauer GF, Gorno-Tempini ML, Weiner MW, Miller BL. Neuroanatomical correlates of behavioural disorders in dementia. *Brain.* 2005;128(Pt 11):2612–2625.
46. Woolley JD, Gorno-Tempini ML, Seeley WW, et al. Binge eating is associated with right orbitofrontal-insular-striatal atrophy in frontotemporal dementia. *Neurology.* 2007;69(14):1424–1433.
47. Bertoux M, Flanagan EC, Hobbs M, et al. Structural anatomical investigation of long-term memory deficit in behavioral frontotemporal dementia. *J Alzheimers Dis.* 2018;62(4):1887–1900.
48. Coyle-Gilchrist IT, Dick KM, Patterson K, et al. Prevalence, characteristics, and survival of frontotemporal lobar degeneration syndromes. *Neurology.* 2016;86(18):1736–1743.
49. Montembeault M, Brambati SM, Gorno-Tempini ML, Migliaccio R. Clinical, anatomical, and pathological features in the three variants of primary progressive aphasia: A Review. *Front Neurol.* 2018;9:692.
50. Zamboni G, Huey ED, Krueger F, Nichelli PF, Grafman J. Apathy and disinhibition in frontotemporal dementia: Insights into their neural correlates. *Neurology.* 2008;71(10):736–742.
51. Snowden JS, Bathgate D, Varma A, Blackshaw A, Gibbons ZC, Neary D. Distinct behavioural profiles in frontotemporal dementia and semantic dementia. *J Neurol Neurosurg Psychiatry.* 2001;70(3):323–332.
52. Rosen HJ, Allison SC, Ogar JM, et al. Behavioral features in semantic dementia vs other forms of progressive aphasia. *Neurology.* 2006;67(10):1752–1756.
53. Dalley JW, Everitt BJ, Robbins TW. Impulsivity, compulsivity, and top-down cognitive control. *Neuron.* 2011;69(4):680–694.
54. Eslinger PJ, Moore P, Antani S, Anderson C, Grossman M. Apathy in frontotemporal dementia: Behavioral and neuroimaging correlates. *Behav Neurol.* 2012;25(2):127–136.
55. Bonelli RM, Cummings JL. Frontal-subcortical circuitry and behavior. *Dialogues Clin Neurosci.* 2007;9(2):141–151.
56. Macfarlane MD, Jakabek D, Walterfang M, et al. Striatal atrophy in the behavioural variant of frontotemporal dementia: Correlation with diagnosis, negative symptoms and disease severity. *PLoS One.* 2015;10(6):e0129692.
57. Convery RS, Bocchetta M, Greaves CV, et al. on behalf of the Genetic FTD Initiative, GENFI. Abnormal pain perception is associated with thalamo-cortico-striatal atrophy in C9orf72 expansion carriers in the GENFI cohort. *J Neurol Neurosurg Psychiatry.* 2020;91(12):1325–1328.
58. Devenney EM, Landin-Romero R, Irish M, et al. The neural correlates and clinical characteristics of psychosis in the frontotemporal dementia continuum and the C9orf72 expansion. *Neuroimage Clin.* 2017;13:439–445.
59. Russell LL, Greaves CV, Bocchetta M, et al. Genetic FTD Initiative, GENFI. Social cognition impairment in genetic frontotemporal dementia within the GENFI cohort. *Cortex.* 2020;133:384–398.
60. Rowe J, Rittman T. The basal ganglia in cognitive disorders. In: M Husain, J Schott, eds. *Oxford textbook of cognitive neurology and dementia.* Oxford: Oxford University Press; 2016:69–80.
61. Lashley T, Rohrer JD, Bandopadhyay R, et al. A comparative clinical, pathological, biochemical and genetic study of fused in sarcoma proteinopathies. *Brain.* 2011;134(Pt 9):2548–2564.
62. Watanabe R, Kawakami I, Onaya M, et al. Frontotemporal dementia with trans-activation response DNA-binding protein 43 presenting with catatonic syndrome. *Neuropathology.* 2018;38(3):281–287.
63. Slowinski J, Dominik J, Uitti RJ, Ahmed Z, Dickson DD, Wszolek ZK. Frontotemporal dementia and Parkinsonism linked to chromosome 17 with the N279K tau mutation. *Neuropathology.* 2007;27(1):73–80.
64. Aron AR, Durston S, Eagle DM, Logan GD, Stinear CM, Stuphorn V. Converging evidence for a fronto-basal-ganglia network for inhibitory control of action and cognition. *J Neurosci.* 2007;27(44):11860–11864.
65. Jahanshahi M, Obeso I, Rothwell JC, Obeso JA. A fronto-striato-subthalamic-pallidal network for goal-directed and habitual inhibition. *Nat Rev Neurosci.* 2015;16(12):719–732.
66. McKhann GM, Albert MS, Grossman M, Miller B, Dickson D, Trojanowski JQ, Work Group on Frontotemporal Dementia and Pick's Disease. Clinical and pathological diagnosis of frontotemporal dementia: Report of the Work Group on Frontotemporal Dementia and Pick's Disease. *Arch Neurol.* 2001;58(11):1803–1809.
67. Schönecker S, Hell F, Bötzel K, et al. German FTLD Consortium. The applause sign in frontotemporal lobar degeneration and related conditions. *J Neurol.* 2019;266(2):330–338.
68. O'Callaghan C, Naismith SL, Hodges JR, Lewis SJG, Hornberger M. Fronto-striatal atrophy correlates of inhibitory dysfunction in parkinson's disease versus behavioural variant frontotemporal dementia. *Cortex.* 2013;49(7):1833–1843.
69. Smith KS, Tindell AJ, Aldridge JW, Berridge KC. Ventral pallidum roles in reward and motivation. *Behav Brain Res.* 2009;196(2):155–167.
70. Miller JM, Vorel SR, Tranguch AJ, et al. Anhedonia after a selective bilateral lesion of the globus pallidus. *Am J Psychiatry.* 2006;163(5):786–788.
71. Levy R, Dubois B. Apathy and the functional anatomy of the prefrontal cortex-basal ganglia circuits. *Cereb Cortex.* 2006;16(7):916–928.
72. Shaw SR, El-Omar H, Roquet D, et al. Uncovering the prevalence and neural substrates of anhedonia in frontotemporal dementia. *Brain.* 2021;144(5):1551–1564. awab032.
73. Husain M, Roiser JP. Neuroscience of apathy and anhedonia: A transdiagnostic approach. *Nat Rev Neurosci.* 2018;19(8):470–484.
74. Lansdall CJ, Coyle-Gilchrist ITS, Jones PS, et al. Apathy and impulsivity in frontotemporal lobar degeneration syndromes. *Brain.* 2017;140(6):1792–1807.
75. Malpetti M, Jones PS, Tsvetanov KA, et al. Genfi OBOTGFI. Apathy in presymptomatic genetic frontotemporal dementia predicts cognitive decline and is driven by structural brain changes. *Alzheimers Dement.* 2020;17(6):969–983.
76. Tavares TP, Mitchell DGV, Coleman KK, et al. Early symptoms in symptomatic and preclinical genetic frontotemporal lobar degeneration. *J Neurol Neurosurg Psychiatry.* 2020;91(9):975–984.
77. Péron J, Frühholz S, Ceravolo L, Grandjean D. Structural and functional connectivity of the subthalamic nucleus during vocal emotion decoding. *Soc Cogn Affect Neurosci.* 2016;11(2):349–356.
78. Sheelakumari R, Kesavadas C, Varghese T, et al. Assessment of iron deposition in the brain in frontotemporal dementia and its correlation with behavioral traits. *AJNR Am J Neuroradiol.* 2017;38(10):1953–1958.
79. De Reuck J, Devos D, Moreau C, Auger F, et al. Topographic distribution of brain iron deposition and small cerebrovascular lesions in amyotrophic lateral sclerosis and in frontotemporal lobar degeneration: A post-mortem 7.0-tesla magnetic resonance imaging study with neuropathological correlates. *Acta Neurol Belg.* 2017;117(4):873–878.
80. Bigio EH. Making the diagnosis of frontotemporal lobar degeneration. *Arch Pathol Lab Med.* 2013;137(3):314–325.
81. Murley A, Rowe JB. Neurotransmitter deficits from frontotemporal lobar degeneration. *Brain.* 2018;141(5):1263–1285.
82. Rowe JB. Parkinsonism in frontotemporal dementias. *Int Rev Neurobiol.* 2019;149:249–275.
83. Josephs KA, Ahmed Z, Katsuse O, et al. Neuropathologic features of frontotemporal lobar degeneration with ubiquitin-

- positive inclusions with progranulin gene (PGRN) mutations. *J Neuropathol Exp Neurol.* 2007;66(2):142–151.
84. Small SA, Schobel SA, Buxton RB, Witter MP, Barnes CA. A pathophysiological framework of hippocampal dysfunction in ageing and disease. *Nat Rev Neurosci.* 2011;12(10):585–601.
  85. Duvernoy HM. The human hippocampus: functional anatomy, vascularization, and serial sections with MRI. 3rd ed. Berlin; New York: Springer; 2005.
  86. Adnan A, Barnett A, Moayed M, McCormick C, Cohn M, McAndrews MP. Distinct hippocampal functional networks revealed by tractography-based parcellation. *Brain Struct Funct.* 2016;221(6):2999–3012.
  87. Aggleton JP. Multiple anatomical systems embedded within the primate medial temporal lobe: Implications for hippocampal function. *Neurosci Biobehav Rev.* 2012;36(7):1579–1596.
  88. Moser MB, Moser EI. Functional differentiation in the hippocampus. *Hippocampus.* 1998;8(6):608–619.
  89. Fanselow MS, Dong HW. Are the dorsal and ventral hippocampus functionally distinct structures? *Neuron.* 2010;65(1):7–19.
  90. Mueller SG, Stables L, Du AT, et al. Measurement of hippocampal subfields and age-related changes with high resolution MRI at 4T. *Neurobiol Aging.* 2007;28(5):719–726.
  91. de Flores R, Mutlu J, Bejanin A, et al. Intrinsic connectivity of hippocampal subfields in normal elderly and mild cognitive impairment patients. *Hum Brain Mapp.* 2017;38(10):4922–4932.
  92. van de Pol LA, Hensel A, van der Flier WM, et al. Hippocampal atrophy on MRI in frontotemporal lobar degeneration and Alzheimer's disease. *J Neurol Neurosurg Psychiatry.* 2006;77(4):439–442.
  93. Barnes J, Whitwell JL, Frost C, Josephs KA, Rossor M, Fox NC. Measurements of the amygdala and hippocampus in pathologically confirmed Alzheimer disease and frontotemporal lobar degeneration. *Arch Neurol.* 2006;63(10):1434–1439.
  94. Chan D, Fox NC, Scahill RI, et al. Patterns of temporal lobe atrophy in semantic dementia and Alzheimer's disease. *Ann Neurol.* 2001;49(4):433–442.
  95. Lehmann M, Douiri A, Kim LG, et al. Atrophy patterns in Alzheimer's disease and semantic dementia: A comparison of FreeSurfer and manual volumetric measurements. *Neuroimage.* 2010;49(3):2264–2274.
  96. La Joie R, Perrotin A, de La Sayette V, et al. Hippocampal subfield volumetry in mild cognitive impairment, Alzheimer's disease and semantic dementia. *Neuroimage Clin.* 2013;3:155–162.
  97. Rohrer JD, McNaught E, Foster J, et al. Tracking progression in frontotemporal lobar degeneration: Serial MRI in semantic dementia. *Neurology.* 2008;71(18):1445–1451.
  98. Miyoshi M, Shinotoh H, Wszolek ZK, et al. In vivo detection of neuropathologic changes in presymptomatic MAPT mutation carriers: A PET and MRI study. *Parkinsonism Relat Disord.* 2010;16(6):404–408.
  99. Whitwell JL, Weigand SD, Boeve BF, et al. Neuroimaging signatures of frontotemporal dementia genetics: C9ORF72, tau, progranulin and sporadics. *Brain.* 2012;135(Pt 3):794–806.
  100. Bocchetta M, Iglesias JE, Scelsi MA, et al. Hippocampal subfield volumetry: Differential pattern of atrophy in different forms of genetic frontotemporal dementia. *J Alzheimers Dis.* 2018;64(2):497–504.
  101. Whitwell JL, Weigand SD, Gunter JL, et al. Trajectories of brain and hippocampal atrophy in FTD with mutations in MAPT or GRN. *Neurology.* 2011;77(4):393–398.
  102. Cairns NJ, Bigio EH, Mackenzie IR, et al. Consortium for Frontotemporal Lobar Degeneration. Neuropathologic diagnostic and nosologic criteria for frontotemporal lobar degeneration: Consensus of the Consortium for Frontotemporal Lobar Degeneration. *Acta Neuropathol.* 2007;114(1):5–22.
  103. Tan RH, Wong S, Kril JJ, et al. Beyond the temporal pole: Limbic memory circuit in the semantic variant of primary progressive aphasia. *Brain.* 2014;137(Pt 7):2065–2076.
  104. Ghetti B, Oblak AL, Boeve BF, Johnson KA, Dickerson BC, Goedert M. Invited review: Frontotemporal dementia caused by microtubule-associated protein tau gene (MAPT) mutations: A chameleon for neuropathology and neuroimaging. *Neuropathol Appl Neurobiol.* 2015;41(1):24–46.
  105. Mann DMA, Snowden JS. Frontotemporal lobar degeneration: Pathogenesis, pathology and pathways to phenotype. *Brain Pathol.* 2017;27(6):723–736.
  106. Hodges JR, Davies RR, Xuereb JH, et al. Clinicopathological correlates in frontotemporal dementia. *Ann Neurol.* 2004;56(3):399–406.
  107. Hornberger M, Piguet O. Episodic memory in frontotemporal dementia: A critical review. *Brain.* 2012;135(Pt 3):678–692.
  108. Irish M, Piguet O, Hodges JR, Hornberger M. Common and unique gray matter correlates of episodic memory dysfunction in frontotemporal dementia and Alzheimer's disease. *Hum Brain Mapp.* 2014;35(4):1422–1435.
  109. Irish M, Hodges JR, Piguet O. Episodic future thinking is impaired in the behavioural variant of frontotemporal dementia. *Cortex.* 2013;49(9):2377–2388.
  110. O'Callaghan C, Shine JM, Hodges JR, Andrews-Hanna JR, Irish M. Hippocampal atrophy and intrinsic brain network dysfunction relate to alterations in mind wandering in neurodegeneration. *Proc Natl Acad Sci U S A.* 2019;116(8):3316–3321.
  111. Wilson NA, Ramanan S, Roquet D, et al. Scene construction impairments in frontotemporal dementia: Evidence for a primary hippocampal contribution. *Neuropsychologia.* 2020;137:107327–
  112. Tu S, Wong S, Hodges JR, Irish M, Piguet O, Hornberger M. Lost in spatial translation - A novel tool to objectively assess spatial disorientation in Alzheimer's disease and frontotemporal dementia. *Cortex.* 2015;67:83–94.
  113. Anderson AK, Spencer DD, Fulbright RK, Phelps EA. Contribution of the anteromedial temporal lobes to the evaluation of facial emotion. *Neuropsychology.* 2000;14(4):526–536.
  114. Rosen HJ, Perry RJ, Murphy J, et al. Emotion comprehension in the temporal variant of frontotemporal dementia. *Brain.* 2002;125(Pt 10):2286–2295.
  115. Moodley KK, Chan D. The hippocampus in neurodegenerative disease. *Front Neurol Neurosci.* 2014;34:95–108.
  116. Mitchell E, Tavares TP, Palaniyappan L, Finger EC. Hoarding and obsessive-compulsive behaviours in frontotemporal dementia: Clinical and neuroanatomic associations. *Cortex.* 2019;121:443–453.
  117. LeDoux J. The amygdala. *Curr Biol.* 2007;17(20):R868–74.
  118. Swanson LW, Petrovich GD. What is the amygdala? *Trends Neurosci.* 1998;21(8):323–331.
  119. deCampo DM, Fudge JL. Where and what is the paralaminar nucleus? A review on a unique and frequently overlooked area of the primate amygdala. *Neurosci Biobehav Rev.* 2012;36(1):520–535.
  120. Solano-Castiella E, Anwender A, Lohmann G, et al. Diffusion tensor imaging segments the human amygdala in vivo. *Neuroimage.* 2010;49(4):2958–2965.
  121. Saygin ZM, Osher DE, Augustinack J, Fischl B, Gabrieli JD. Connectivity-based segmentation of human amygdala nuclei using probabilistic tractography. *Neuroimage.* 2011;56(3):1353–1361.
  122. Boccardi M, Pennanen C, Laakso MP, Testa C, et al. Amygdaloid atrophy in frontotemporal dementia and Alzheimer's disease. *Neurosci Lett.* 2002;335(2):139–143.
  123. Whitwell JL, Sampson EL, Watt HC, Harvey RJ, Rossor MN, Fox NC. A volumetric magnetic resonance imaging study of the amygdala in frontotemporal lobar degeneration and Alzheimer's disease. *Dement Geriatr Cogn Disord.* 2005;20(4):238–244.
  124. Saygin ZM, Kliemann D, Iglesias JE, et al. Alzheimer's Disease Neuroimaging Initiative. High-resolution magnetic resonance imaging reveals nuclei of the human amygdala: Manual segmentation to automatic atlas. *Neuroimage.* 2017;155:370–382.



125. Whitwell JL, Josephs KA, Rossor MN, et al. Magnetic resonance imaging signatures of tissue pathology in frontotemporal dementia. *Arch Neurol*. 2005;62(9):1402–1408.
126. Bocchetta M, Iglesias JE, Cash DM, Warren JD, Rohrer JD. Amygdala subnuclei are differentially affected in the different genetic and pathological forms of frontotemporal dementia. *Alzheimers Dement*. 2019;11(1):136–141.
127. Bocchetta M, Iglesias JE, Russell LL, et al. Segmentation of medial temporal subregions reveals early right-sided involvement in semantic variant PPA. *Alzheimers Res Ther*. 2019;11(1):41.
128. Mann DM, South PW. The topographic distribution of brain atrophy in frontal lobe dementia. *Acta Neuropathol*. 1993;85(3):334–340.
129. Bretschneider J, Del Tredici K, Irwin DJ, et al. Sequential distribution of pTDP-43 pathology in behavioral variant frontotemporal dementia (bvFTD). *Acta Neuropathol*. 2014;127(3):423–439.
130. Sollberger M, Rosen HJ, Shany-Ur T, et al. Neural substrates of socioemotional self-awareness in neurodegenerative disease. *Brain Behav*. 2014;4(2):201–214.
131. Kumfor F, Irish M, Hodges JR, Piguet O. Discrete neural correlates for the recognition of negative emotions: Insights from frontotemporal dementia. *PLoS One*. 2013;8(6):e67457.
132. Seeley WW, Menon V, Schatzberg AF, et al. Dissociable intrinsic connectivity networks for salience processing and executive control. *J Neurosci*. 2007;27(9):2349–2356.
133. Rankin KP. Brain networks supporting social cognition in dementia. *Curr Behav Neurosci Rep*. 2020;7(4):203–211.
134. Kipps CM, Nestor PJ, Acosta-Cabronero J, Arnold R, Hodges JR. Understanding social dysfunction in the behavioural variant of frontotemporal dementia: The role of emotion and sarcasm processing. *Brain*. 2009;132(Pt 3):592–603.
135. Cerami C, Dodich A, Canessa N, et al. Cappa SFNeural correlates of empathic impairment in the behavioral variant of frontotemporal dementia. *Alzheimers Dement*. 2014;10(6):827–834.
136. Cerami C, Dodich A, Iannaccone S, et al. Right limbic FDG-PET hypometabolism correlates with emotion recognition and attribution in probable behavioral variant of frontotemporal dementia patients. *PLoS One*. 2015;10(10):e0141672.
137. Hornberger M, Yew B, Gilardoni S, et al. Ventromedial-frontopolar prefrontal cortex atrophy correlates with insight loss in frontotemporal dementia and Alzheimer's disease. *Hum Brain Mapp*. 2014;35(2):616–626.
138. Irish M, Hodges JR, Piguet O. Right anterior temporal lobe dysfunction underlies theory of mind impairments in semantic dementia. *Brain*. 2014;137(Pt 4):1241–1253.
139. Baez S, Morales JP, Slachevsky A, et al. Orbitofrontal and limbic signatures of empathic concern and intentional harm in the behavioral variant frontotemporal dementia. *Cortex*. 2016;75:20–32.
140. Perry DC, Datta S, Sturm VE, et al. Reward deficits in behavioural variant frontotemporal dementia include insensitivity to negative stimuli. *Brain*. 2017;140(12):3346–3356.
141. De Winter FL, Van den Stock J, de Gelder B, et al. Amygdala atrophy affects emotion-related activity in face-responsive regions in frontotemporal degeneration. *Cortex*. 2016;82:179–191.
142. Marshall CR, Hardy CJD, Russell LL, et al. Impaired interoceptive accuracy in semantic variant primary progressive aphasia. *Front Neurol*. 2017;8:1–6.
143. Couto B, Manes F, Montañés P, et al. Structural neuroimaging of social cognition in progressive non-fluent aphasia and behavioral variant of frontotemporal dementia. *Front Hum Neurosci*. 2013;7:1–11.
144. Mesulam MM. The cholinergic innervation of the human cerebral cortex. *Prog Brain Res*. 2004;145:67–78.
145. Sarter M, Bruno JP, Givens B. Attentional functions of cortical cholinergic inputs: What does it mean for learning and memory? *Neurobiol Learn Mem*. 2003;80(3):245–256.
146. Baxter MG, Chiba AA. Cognitive functions of the basal forebrain. *Curr Opin Neurobiol*. 1999;9(2):178–183.
147. Teipel SJ, Flatz W, Ackl N, et al. Brain atrophy in primary progressive aphasia involves the cholinergic basal forebrain and Ayala's nucleus. *Psychiatry Res*. 2014;221(3):187–194.
148. Teipel S, Raiser T, Riedl L, et al. Danek A; FTLDc study group. Atrophy and structural covariance of the cholinergic basal forebrain in primary progressive aphasia. *Cortex*. 2016;83:124–135.
149. Schaefferbeke J, Evenepoel C, Bruffaerts R, et al. Cholinergic depletion and basal forebrain volume in primary progressive aphasia. *Neuroimage Clin*. 2017;13:271–279.
150. Convery RS, Neason MR, Cash DM, et al. Basal forebrain atrophy in frontotemporal dementia. *Neuroimage Clin*. 2020;26:102210.
151. Hamodat H, Fisk JD, Darvesh S. Cholinergic neurons in nucleus subputaminalis in primary progressive aphasia. *Can J Neurol Sci*. 2019;46(2):174–183.
152. Simić G, Mrzljak L, Fucić A, Winblad B, Lovrić H, Kostović I. Nucleus subputaminalis (Ayala): The still disregarded magnocellular component of the basal forebrain may be human specific and connected with the cortical speech area. *Neuroscience*. 1999;89(1):73–89.
153. Amunts K, Lenzen M, Friederici AD, et al. Broca's region: Novel organizational principles and Multiple Receptor Mapping. *PLoS Biol*. 2010;8(9):e1000489.
154. Insel TR, Young LJ. The neurobiology of attachment. *Nat Rev Neurosci*. 2001;2(2):129–136.
155. Moll J, Zahn R, de Oliveira-Souza R, et al. Impairment of prosocial sentiments is associated with frontopolar and septal damage in frontotemporal dementia. *Neuroimage*. 2011;54(2):1735–1742.
156. Kertesz A, Morlog D, Light M, et al. Galantamine in frontotemporal dementia and primary progressive aphasia. *Dement Geriatr Cogn Disord*. 2008;25(2):178–185.
157. Mendez MF, Shapira JS, McMurtry A, Licht E. Preliminary findings: Behavioral worsening on donepezil in patients with frontotemporal dementia. *Am J Geriatr Psychiatry*. 2007;15(1):84–87.
158. Schmahmann JD. Vascular syndromes of the thalamus. *Stroke*. 2003;34(9):2264–2278.
159. Bocchetta M, Iglesias JE, Neason M, Cash DM, Warren JD, Rohrer JD. Thalamic nuclei in frontotemporal dementia: Mediodorsal nucleus involvement is universal but pulvinar atrophy is unique to C9orf72. *Hum Brain Mapp*. 2020;41(4):1006–1016.
160. Bocchetta M, Gordon E, Cardoso MJ, et al. Thalamic atrophy in frontotemporal dementia - Not just a C9orf72 problem. *Neuroimage Clin*. 2018;18:675–681.
161. Cardenas VA, Boxer AL, Chao LL, et al. Deformation-based morphometry reveals brain atrophy in frontotemporal dementia. *Arch Neurol*. 2007;64(6):873–877.
162. Hornberger M, Wong S, Tan R, et al. In vivo and post-mortem memory circuit integrity in frontotemporal dementia and Alzheimer's disease. *Brain*. 2012;135(Pt 10):3015–3025.
163. Cash DM, Bocchetta M, Thomas D, et al. on behalf of the Genetic FTD Initiative, GENFI. Patterns of grey matter atrophy in genetic frontotemporal dementia: Results from the GENFI study. *Neurobiol Aging*. 2018;62:191–196.
164. Bertrand A, Wen J, Rinaldi D, et al. Predict to Prevent Frontotemporal Lobar Degeneration and Amyotrophic Lateral Sclerosis (PREV-DEMALS) Study Group. Early Cognitive, Structural, and Microstructural Changes in Presymptomatic C9orf72 Carriers Younger Than 40 Years. *JAMA Neurol*. 2018;75(2):236–245.
165. Vatsavayai SC, Yoon SJ, Gardner RC, et al. Timing and significance of pathological features in C9orf72 expansion-associated frontotemporal dementia. *Brain*. 2016;139(Pt 12):3202–3216.
166. Yang Y, Halliday GM, Hodges JR, Tan RH. von Economo neuron density and thalamus volumes in behavioral deficits in

- frontotemporal dementia cases with and without a C9ORF72 repeat expansion. *J Alzheimers Dis.* 2017;58(3):701–709.
167. Lee SE, Khazenzon AM, Trujillo AJ, et al. Altered network connectivity in frontotemporal dementia with C9orf72 hexanucleotide repeat expansion. *Brain.* 2014;137(Pt 11):3047–3060.
  168. Lee SE, Sias AC, Mandelli ML, et al. Network degeneration and dysfunction in presymptomatic C9ORF72 expansion carriers. *Neuroimage Clin.* 2017;14(14):286–297.
  169. Radanovic M, Rosemberg S, Adas R, et al. Frontotemporal dementia with severe thalamic involvement: A clinical and neuropathological study. *Arq Neuropsiquiatr.* 2003;61(4):930–935.
  170. Ducharme S, Bajestan S, Dickerson BC, Voon V. Psychiatric presentations of C9orf72 mutation: What are the diagnostic implications for clinicians? *J Neuropsychiatry Clin Neurosci.* 2017; 29(3):195–205.
  171. Fletcher PD, Downey LE, Golden HL, et al. Pain and temperature processing in dementia: A clinical and neuroanatomical analysis. *Brain.* 2015;138(11):3360–3372.
  172. Kertesz A, Ang LC, Jesso S, et al. Psychosis and hallucinations in frontotemporal dementia with the C9ORF72 mutation: A detailed clinical cohort. *Cogn Behav Neurol.* 2013;26(3):146–154.
  173. Sturm VE, Perry DC, Wood K, et al. Prosocial deficits in behavioral variant frontotemporal dementia relate to reward network atrophy. *Brain Behav.* 2017;7(10):e00807.
  174. Morton GJ, Cummings DE, Baskin DG, Barsh GS, Schwartz MW. Central nervous system control of food intake and body weight. *Nature.* 2006;443(7109):289–295.
  175. Neudorfer C, Germann J, Elias GJB, Gramer R, Boutet A, Lozano AM. A high-resolution in vivo magnetic resonance imaging atlas of the human hypothalamic region. *Sci Data.* 2020;77(1):305.
  176. Parker JA, Bloom SR. Hypothalamic neuropeptides and the regulation of appetite. *Neuropharmacology.* 2012;63(1):18–30.
  177. Bocchetta M, Gordon E, Manning E, et al. Detailed volumetric analysis of the hypothalamus in behavioral variant frontotemporal dementia. *J Neurol.* 2015;262(12):2635–2642.
  178. Ahmed RM, Latheef S, Bartley L, et al. Eating behavior in frontotemporal dementia: Peripheral hormones vs hypothalamic pathology. *Neurology.* 2015;85(15):1310–1317.
  179. Piguet O, Petersen A, Yin Ka Lam B, et al. Eating and hypothalamus changes in behavioral-variant frontotemporal dementia. *Ann Neurol.* 2011;69(2):312–319.
  180. Ahmed RM, Irish M, Kam J, et al. Quantifying the eating abnormalities in frontotemporal dementia. *JAMA Neurol.* 2014; 71(12):1540–1546.
  181. Ikeda M, Brown J, Holland AJ, Fukuhara R, Hodges JR. Changes in appetite, food preference, and eating habits in frontotemporal dementia and Alzheimer's disease. *J Neurol Neurosurg Psychiatry.* 2002;73(4):371–376.
  182. Piguet O. Eating disturbance in behavioural-variant frontotemporal dementia. *J Mol Neurosci.* 2011;45(3):589–593.
  183. Coll AP, Farooqi IS, O'Rahilly S. The hormonal control of food intake. *Cell.* 2007;129(2):251–262.
  184. Ahmed RM, Iodice V, Daveson N, Kiernan MC, Piguet O, Hodges JR. Autonomic dysregulation in frontotemporal dementia. *J Neurol Neurosurg Psychiatry.* 2015;86(9):1048–1049.
  185. Sturm VE, Brown JA, Hua AY, et al. Network architecture underlying basal autonomic outflow: Evidence from frontotemporal dementia. *J Neurosci.* 2018;38(42):8943–8955.
  186. Robles Bayón A, Gude Sampedro F, Torregrosa Quesada JM. Bradycardia in frontotemporal dementia. *Neurologia.* 2014; 29(2):76–85.
  187. Pernecky R, Diehl-Schmid J, Förstl H, Drzezga A, May F, Kurz A. Urinary incontinence and its functional anatomy in frontotemporal lobar degenerations. *Eur J Nucl Med Mol Imaging.* 2008; 35(3):605–610.
  188. Neary D, Snowden JS, Gustafson L, et al. Frontotemporal lobar degeneration: A consensus on clinical diagnostic criteria. *Neurology.* 1998;51(6):1546–1554.
  189. McCarter SJ, St Louis EK, Boeve BF. Sleep disturbances in frontotemporal dementia. *Curr Neurol Neurosci Rep.* 2016;16(9):85–
  190. Warren JD, Clark CN. A new hypnic paradigm of neurodegenerative proteinopathies. *Sleep Med.* 2017;32:282–283.
  191. Haber SN, Knutson B. The reward circuit: Linking primate anatomy and human imaging. *Neuropsychopharmacology.* 2010; 35(1):4–26.
  192. Hikosaka O, Sesack SR, Lecourtier L, Shepard PD. Habenula: Crossroad between the basal ganglia and the limbic system. *J Neurosci.* 2008;28(46):11825–11829.
  193. Benarroch EE. Habenula: Recently recognized functions and potential clinical relevance. *Neurology.* 2015;85(11):992–1000.
  194. Bocchetta M, Gordon E, Marshall CR, et al. The habenula: An under-recognised area of importance in frontotemporal dementia? *J Neurol Neurosurg Psychiatry.* 2016;87(8):910–912.
  195. Hikosaka O. The habenula: From stress evasion to value-based decision-making. *Nat Rev Neurosci.* 2010;11(7):503–513.
  196. Ullsperger M, von Cramon DY. Error monitoring using external feedback: Specific roles of the habenular complex, the reward system, and the cingulate motor area revealed by functional magnetic resonance imaging. *J Neurosci.* 2003;23(10):4308–4314.
  197. Stopper CM, Floresco SB. What's better for me? Fundamental role for lateral habenula in promoting subjective decision biases. *Nat Neurosci.* 2014;17(1):33–35.
  198. Baker PM, Raynor SA, Francis NT, Mizumori SJY. Lateral habenula integration of proactive and retroactive information mediates behavioral flexibility. *Neuroscience.* 2017;345:89–98.
  199. Mathis V, Barbelivien A, Majchrzak M, Mathis C, Cassel JC, Lecourtier L. The lateral habenula as a relay of cortical information to process working memory. *Cereb Cortex.* 2017;27(12): 5485–5495.
  200. Lammel S, Lim BK, Ran C, et al. Input-specific control of reward and aversion in the ventral tegmental area. *Nature.* 2012; 491(7423):212–217.
  201. Stopper CM, Tse MTL, Montes DR, Wiedman CR, Floresco SB. Overriding phasic dopamine signals redirects action selection during risk/reward decision making. *Neuron.* 2014;84(1):177–189.
  202. Liddell BJ, Brown KJ, Kemp AH, et al. A direct brainstem-amygdala-cortical 'alarm' system for subliminal signals of fear. *Neuroimage.* 2005;24(1):235–243.
  203. Rushmore RJ, Wilson-Braun P, Papadimitriou G, et al. 3D Exploration of the Brainstem in 50-Micron Resolution MRI. *Front Neuroanat.* 2020;23(14):40.
  204. Whitwell JL, Höglinger GU, Antonini A, et al. Movement Disorder Society-endorsed PSP Study Group. Radiological biomarkers for diagnosis in PSP: Where are we and where do we need to be? *Mov Disord.* 2017;32(7):955–971.
  205. Massey LA, Micallef C, Paviour DC, et al. Conventional magnetic resonance imaging in confirmed progressive supranuclear palsy and multiple system atrophy. *Mov Disord.* 2012;27(14): 1754–1762.
  206. Lee SE, Rabinovici GD, Mayo MC, et al. Clinicopathological correlations in corticobasal degeneration. *Ann Neurol.* 2011; 70(2):327–340.
  207. Murley AG, Coyle-Gilchrist I, Rouse MA, et al. Redefining the multidimensional clinical phenotypes of frontotemporal lobar degeneration syndromes. *Brain.* 2020;143(5):1555–1571.
  208. Ljubenkov PA, Miller BL. A clinical guide to frontotemporal dementias. *Focus (Am Psychiatr Publ).* 2016;14(4):448–464.
  209. Agosta F, Galantucci S, Magnani G, et al. MRI signatures of the frontotemporal lobar degeneration continuum. *Hum Brain Mapp.* 2015;36(7):2602–2614.
  210. Grinberg LT, Rueb U, Heinsen H. Brainstem: Neglected locus in neurodegenerative diseases. *Front Neurol.* 2011;1(2):42.
  211. Yang Y, Schmitt HP. Frontotemporal dementia: Evidence for impairment of ascending serotonergic but not noradrenergic innervation. Immunocytochemical and quantitative study using a graph method. *Acta Neuropathol.* 2001;101(3):256–270.

212. Zhou J, Greicius MD, Gennatas ED, et al. Divergent network connectivity changes in behavioural variant frontotemporal dementia and Alzheimer's disease. *Brain*. 2010;133(Pt 5):1352–1367.
213. Rüb U, Heinsen H, Brunt ER, et al. The human premotor oculomotor brainstem system - can it help to understand oculomotor symptoms in Huntington's disease? *Neuropathol Appl Neurobiol*. 2009;35(1):4–15.
214. Meyniel C, Rivaud-Péchoux S, Damier P, Gaymard B. Saccade impairments in patients with fronto-temporal dementia. *J Neurol Neurosurg Psychiatry*. 2005;76(11):1581–1584.
215. Huey ED, Putnam KT, Grafman J. A systematic review of neurotransmitter deficits and treatments in frontotemporal dementia. *Neurology*. 2006;66(1):17–22.
216. Hughes LE, Rittman T, Regenthal R, Robbins TW, Rowe JB. Improving response inhibition systems in frontotemporal dementia with citalopram. *Brain*. 2015;138(Pt 7):1961–1975.
217. Sedaghat F, Gotzamani-Psarrakou A, Dedousi E, et al. Evaluation of dopaminergic function in frontotemporal dementia using 123I-FP-CIT single photon emission computed tomography. *Neurodegener Dis*. 2007;4(5):382–385.
218. Sara SJ. The locus coeruleus and noradrenergic modulation of cognition. *Nat Rev Neurosci*. 2009;10(3):211–223.
219. Aston-Jones G, Waterhouse B. Locus coeruleus: From global projection system to adaptive regulation of behavior. *Brain Res*. 2016;1645:75–78.
220. Kaalund SS, Passamonti L, Allinson KSJ, et al. Locus coeruleus pathology in progressive supranuclear palsy, and its relation to disease severity. *Acta Neuropathol Commun*. 2020;8(1):11–
221. Makris N, Hodge SM, Haselgrove C, et al. Human cerebellum: Surface-assisted cortical parcellation and volumetry with magnetic resonance imaging. *J Cogn Neurosci*. 2003;15(4):584–599.
222. D'Angelo E, Casali S. Seeking a unified framework for cerebellar function and dysfunction: From circuit operations to cognition. *Front Neural Circuits*. 2013;6:116–
223. Behrens TE, Johansen-Berg H, Woolrich MW, et al. Non-invasive mapping of connections between human thalamus and cortex using diffusion imaging. *Nat Neurosci*. 2003;6(7):750–757.
224. Palesi F, Tournier JD, Calamante F, et al. Contralateral cerebello-thalamo-cortical pathways with prominent involvement of associative areas in humans in vivo. *Brain Struct Funct*. 2015;220(6):3369–3384.
225. Arrigo A, Mormina E, Anastasi GP, et al. Constrained spherical deconvolution analysis of the limbic network in human, with emphasis on a direct cerebello-limbic pathway. *Front Hum Neurosci*. 2014;8:987–
226. Schmahmann JD. The role of the cerebellum in affect and psychosis. *J Neurolinguistics*. 2000;13(2-3):189–214.
227. Stoodley CJ, Schmahmann JD. Evidence for topographic organization in the cerebellum of motor control versus cognitive and affective processing. *Cortex*. 2010;46(7):831–844.
228. Chen Y, Kumfor F, Landin-Romero R, Irish M, Piguet O. The cerebellum in frontotemporal dementia: A meta-analysis of neuroimaging studies. *Neuropsychol Rev*. 2019;29(4):450–464.
229. Guo CC, Tan R, Hodges JR, Hu X, Sami S, Hornberger M. Network-selective vulnerability of the human cerebellum to Alzheimer's disease and frontotemporal dementia. *Brain*. 2016;139(Pt 5):1527–1538.
230. Chen Y, Kumfor F, Landin-Romero R, Irish M, Hodges JR, Piguet O. Cerebellar atrophy and its contribution to cognition in frontotemporal dementias. *Ann Neurol*. 2018;84(1):98–109.
231. Irwin DJ, McMillan CT, Brettschneider J, et al. Cognitive decline and reduced survival in C9orf72 expansion frontotemporal degeneration and amyotrophic lateral sclerosis. *J Neurol Neurosurg Psychiatry*. 2013;84(2):163–169.
232. Mahoney CJ, Beck J, Rohrer JD, et al. Frontotemporal dementia with the C9ORF72 hexanucleotide repeat expansion: Clinical, neuroanatomical and neuropathological features. *Brain*. 2012;135(Pt 3):736–750.
233. Bocchetta M, Cardoso MJ, Cash DM, Ourselin S, Warren JD, Rohrer JD. Patterns of regional cerebellar atrophy in genetic frontotemporal dementia. *Neuroimage Clin*. 2016;11:287–290.
234. Al-Sarraj S, King A, Troakes C, et al. p62 positive, TDP-43 negative, neuronal cytoplasmic and intranuclear inclusions in the cerebellum and hippocampus define the pathology of C9orf72-linked FTL and MND/ALS. *Acta Neuropathol*. 2011;122(6):691–702.
235. Hsiung GY, DeJesus-Hernandez M, Feldman HH, et al. Clinical and pathological features of familial frontotemporal dementia caused by C9ORF72 mutation on chromosome 9p. *Brain*. 2012;135(Pt 3):709–722.
236. Troakes C, Maekawa S, Wijesekera L, et al. An MND/ALS phenotype associated with C9orf72 repeat expansion: Abundant p62-positive, TDP-43-negative inclusions in cerebral cortex, hippocampus and cerebellum but without associated cognitive decline. *Neuropathology*. 2012;32(5):505–514.
237. Ferrer I, Legati A, García-Monco JC, et al. Familial behavioral variant frontotemporal dementia associated with astrocyte-predominant tauopathy. *J Neuropathol Exp Neurol*. 2015;74(4):370–379.
238. Corcia P, Vourc'h P, Guennoc AM, et al. Pure cerebellar ataxia linked to large C9orf72 repeat expansion. *Amyotroph Lateral Scler Frontotemporal Degener*. 2016;17(3-4):301–303.
239. Lindquist SG, Duno M, Batbayli M, et al. Corticobasal and ataxia syndromes widen the spectrum of C9ORF72 hexanucleotide expansion disease. *Clin Genet*. 2013;83(3):279–283.
240. Tan RH, Devenney E, Kiernan MC, Halliday GM, Hodges JR, Hornberger M. Terra incognita-cerebellar contributions to neuropsychiatric and cognitive dysfunction in behavioral variant frontotemporal dementia. *Front Aging Neurosci*. 2015;7:121.
241. Chen Y, Landin-Romero R, Kumfor F, Irish M, Hodges JR, Piguet O. Cerebellar structural connectivity and contributions to cognition in frontotemporal dementias. *Cortex*. 2020;129:57–67.
242. Leroi I, O'Hearn E, Marsh L, et al. Psychopathology in patients with degenerative cerebellar diseases: A comparison to Huntington's disease. *Am J Psychiatry*. 2002;159(8):1306–1314.
243. Schmahmann JD. Disorders of the cerebellum: Ataxia, dysmetria of thought, and the cerebellar cognitive affective syndrome. *J Neuropsychiatr*. 2004;16(3):367–378.
244. Ahmed RM, Irish M, Henning E, et al. Assessment of eating behavior disturbance and associated neural networks in frontotemporal dementia. *JAMA Neurol*. 2016;73(3):282–290.
245. Strenziok M, Pulaski S, Krueger F, Zamboni G, Clawson D, Grafman J. Regional brain atrophy and impaired decision making on the balloon analog risk task in behavioral variant frontotemporal dementia. *Cogn Behav Neurol*. 2011;24(2):59–67.
246. Synn A, Mothakunnel A, Kumfor F, et al. Mental states in moving shapes: Distinct cortical and subcortical contributions to theory of mind impairments in dementia. *J Alzheimers Dis*. 2018;61(2):521–535.
247. Van den Stock J, De Winter FL, Stam D, et al. Reduced tendency to attribute mental states to abstract shapes in behavioral variant frontotemporal dementia links with cerebellar structural integrity. *Neuroimage Clin*. 2019;22:101770.
248. Downey LE, Fletcher PD, Golden HL, et al. Altered body schema processing in frontotemporal dementia with C9ORF72 mutations. *J Neurol Neurosurg Psychiatry*. 2014;85(9):1016–1023.
249. Wisse LEM, Daugherty AM, Olsen RK, et al. for the Hippocampal Subfields Group. A harmonized segmentation protocol for hippocampal and parahippocampal subregions: Why do we need one and what are the key goals? *Hippocampus*. 2017;27(1):3–11.