

## CLINICAL PRACTICE

## Lumbar Spinal Stenosis

Jeffrey N. Katz, M.D., M.Sc., and Mitchel B. Harris, M.D.

*This Journal feature begins with a case vignette highlighting a common clinical problem. Evidence supporting various strategies is then presented, followed by a review of formal guidelines, when they exist. The article ends with the authors' clinical recommendations.*

**A 72-year-old woman with hypertension presents with a 4-month history of lower back discomfort that radiates to both buttocks and lateral thighs. Previously, she had walked 2 miles (3.2 km) a day; now she has difficulty walking 2 blocks and standing up for more than 15 minutes at a time. Her physical examination is notable only for a slightly stooped posture and a reduction of vibratory sensibility in both great toes. How should she be evaluated and treated?**

## THE CLINICAL PROBLEM

From the Department of Orthopedic Surgery (J.N.K., M.B.H.) and the Division of Rheumatology, Immunology, and Allergy, Department of Medicine, Brigham and Women's Hospital (J.N.K.); Harvard Medical School (J.N.K., M.B.H.); and Harvard School of Public Health (J.N.K.) — all in Boston. Address reprint requests to Dr. Katz at the Center for Orthopedic and Arthritis Outcomes Research, Brigham and Women's Hospital, 75 Francis St., B3, Boston, MA 02115, or at [jnkatz@partners.org](mailto:jnkatz@partners.org).

N Engl J Med 2008;358:818-25.  
Copyright © 2008 Massachusetts Medical Society.

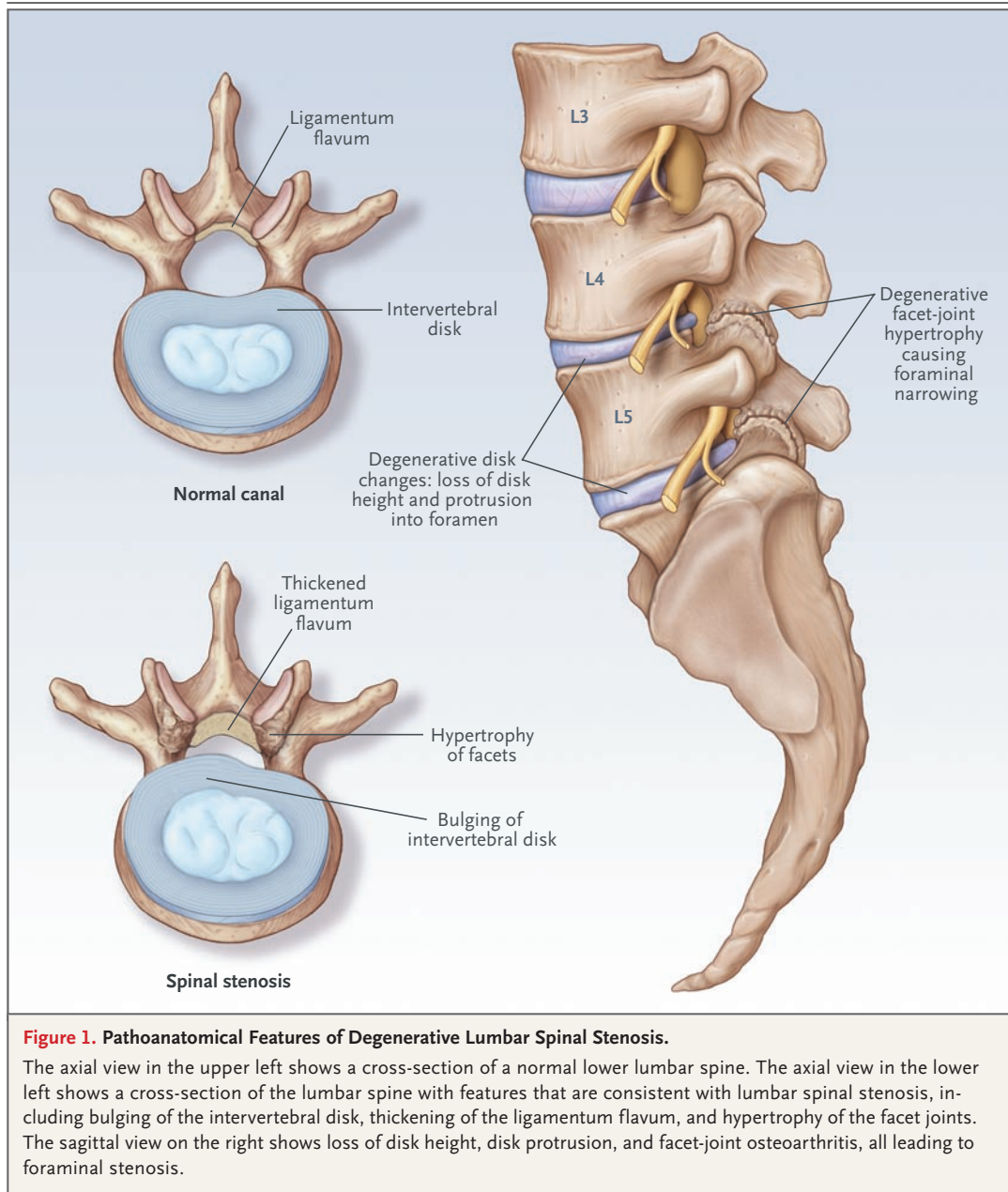
The clinical syndrome of neurogenic claudication due to lumbar spinal stenosis is a frequent source of pain in the lower back and extremities, impaired walking, and other forms of disability in the elderly. Although the incidence and prevalence of symptomatic lumbar spinal stenosis have not been established, this condition is the most frequent indication for spinal surgery in patients older than 65 years of age.<sup>1</sup>

The radiographic and anatomical finding of lumbar spinal stenosis is characterized by narrowing of the spinal canal. Narrowing may occur in the central spinal canal, in the area under the facet joints (subarticular stenosis), or more laterally, in the neural foramina (Fig. 1). Compression of nerve roots causes symptomatic lumbar spinal stenosis, which can be categorized into several distinct entities defined by the underlying reasons for the spinal nerve-root compression. One commonly used classification system is shown in Table 1, with minor modification.<sup>2</sup>

Congenital stenosis is characterized by a narrow canal resulting from congenitally short pedicles. Patients with this condition tend to become symptomatic in the third, fourth, or fifth decade of life, when mild degenerative changes that would otherwise be tolerated result in narrowing sufficient to cause symptoms.

Acquired degenerative stenosis is the most frequently observed type of spinal stenosis. It arises in conjunction with age-associated degeneration of the lumbar disks and facet joints. The degenerative process leads to a loss of disk height with associated bulging of the disk and infolding of the ligamentum flavum. Facet osteoarthritis and hypertrophy (from the increased stresses associated with disk degeneration) often lead to osteophyte formation and thickening of the joint capsule (Fig. 1). With advanced osteoarthritis of the facet joints, cysts originating from these joints can protrude into the spinal canal, further compromising the space available for the neural elements.

Stenosis may also arise in the setting of degenerative spondylolisthesis or spondylolisthesis arising from a prior spondylolysis (disruption in pars interarticularis). In such cases, back pain typically predominates, with neurogenic claudication as a secondary symptom. Stenosis can also occur at the level adjacent to a prior spinal fusion. Other recognized causes of spinal stenosis include an excess of corticosteroids, either endogenous (e.g., Cushing's syndrome) or iatrogenic, as well as Paget's disease, acromegaly, and several other conditions (Table 1).



**Figure 1. Pathoanatomical Features of Degenerative Lumbar Spinal Stenosis.**

The axial view in the upper left shows a cross-section of a normal lower lumbar spine. The axial view in the lower left shows a cross-section of the lumbar spine with features that are consistent with lumbar spinal stenosis, including bulging of the intervertebral disk, thickening of the ligamentum flavum, and hypertrophy of the facet joints. The sagittal view on the right shows loss of disk height, disk protrusion, and facet-joint osteoarthritis, all leading to foraminal stenosis.

The mechanism whereby compression of spinal nerve roots results in the typical symptoms and signs of spinal stenosis has not been fully elucidated. Evidence suggests that in the presence of stenosis and nerve-root compression, lumbar extension reduces the cross-sectional area of the central canal as well as the neural foramina, exerting further pressure on the venules surrounding the nerve roots. This process, in turn, leads to engorgement and ischemic nerve impairment.<sup>3-10</sup> This ischemic mechanism may account

for the typical reversibility of symptoms when patients flex their spines forward.

#### STRATEGIES AND EVIDENCE

##### DIAGNOSIS

###### History

The most common symptom associated with lumbar spinal stenosis is neurogenic claudication — discomfort that radiates beyond the spinal area into the buttocks and frequently into the thigh

Category	Comments
Congenital stenosis (developmental)	Congenitally shortened pedicles; typical age at symptom onset, 20s–40s
Idiopathic	
Achondroplastic	Frequently seen in achondroplastic dwarves
Acquired stenosis	
Degenerative	
Central canal	Disk degeneration, facet osteoarthritis, ligamentum flavum hypertrophy; typical age at symptom onset, 60s–90s
Peripheral canal, lateral recesses	Sciatica-like presentation in patients with lateral recess stenosis
Spondylolisthesis	Back pain may predominate
Combinations of congenital and degenerative stenosis	
Iatrogenic	
Postlaminectomy	Stenosis typically at adjacent level but may recur at operated level
Postfusion	
Spondylolytic	Typical age of symptom onset, teens–20s, associated with spondylolisthesis
Post-traumatic	
Miscellaneous	
Corticosteroid excess (Cushing's syndrome or exogenous source)	Goal of management is to treat underlying condition
Paget's disease, acromegaly	

\* The classification is adapted from Arnoldi et al.<sup>2</sup>

and lower leg; it is exacerbated by lumbar extension and improves with lumbar flexion. In a study of 93 adults with back pain, the finding of pain radiating into the buttocks or more distally had a sensitivity of 88% for the diagnosis of lumbar spinal stenosis but a specificity of only 34%.<sup>11</sup> Patients with symptomatic stenosis are generally comfortable when sitting and have worsening pain with prolonged walking. In the same study, a history of back pain while the patient was standing but no pain at all when the patient was sitting had a specificity for lumbar spinal stenosis of 93% and a sensitivity of 46%.<sup>11</sup>

#### *Physical Examination*

The Romberg maneuver, in which the patient, with eyes closed, stands and is observed for imbalance, may reveal a wide-based gait and unsteadiness. These findings reflect involvement of proprioceptive fibers in the posterior columns. In the previously mentioned study, the finding of a

wide-based gait among patients with back pain had a specificity exceeding 90% for lumbar spinal stenosis.<sup>11</sup> Active lumbar extension may provoke discomfort that is relieved with flexion. A sensory or motor deficit occurs in about half of patients with symptomatic lumbar stenosis; the specificity of this finding is about 80%. The deficit may occur bilaterally and in a polyradicular pattern.<sup>11</sup> Motor findings are typically mild, and functionally limiting weakness is uncommon.

#### *Differential Diagnosis*

Some simple maneuvers during physical examination and elements of the history can often distinguish symptomatic spinal stenosis from other conditions that may cause similar symptoms, such as hip osteoarthritis, trochanteric bursitis, peripheral neuropathy, and vascular claudication. Hip osteoarthritis is associated with pain — typically in the groin — provoked by internal rotation of the hip. Trochanteric bursitis is associated with

tenderness over the greater trochanter. Vascular claudication is not influenced by lumbar extension or flexion or by standing but is exacerbated by walking, especially uphill.

The process of distinguishing these conditions may be complicated by their frequent coexistence; osteoarthritis and peripheral vascular disease, like spinal stenosis, are prevalent in the elderly, and trochanteric bursitis is observed frequently in patients with symptomatic lumbar spinal stenosis. Selective injection of the trochanteric bursa or the hip joint with an anesthetic and corticosteroid may be useful in determining the degree to which each condition may be contributing to pain and disability.

### *Imaging*

In many patients, the history and physical examination provide sufficient evidence to make a presumptive diagnosis of symptomatic lumbar spinal stenosis. Although plain radiographs can be useful, they are not routinely needed. The radiograph may show spondylolisthesis, a common predisposing lesion. It provides an estimate of the extent of disk-space narrowing, end-plate sclerosis, and facet-joint hypertrophy. The neural foramina may reveal osteophytes, suggesting foraminal stenosis.

Either magnetic resonance imaging (MRI) or computed tomography (CT) may confirm the presence of spinal stenosis, since both can detect the cardinal features of stenosis — reductions in the cross-sectional area of the central canal and neural foramina due to a combination of disk protrusion, redundancy and hypertrophy of the ligamentum flavum, and hypertrophy of facet joints, with accompanying osteophytes. The presence of facet cysts (synovial outpouchings) may further compromise the space available for the dura and neural elements. Bony findings such as facet arthropathy can be seen more clearly on CT scans, whereas soft-tissue lesions involving ligaments and disks are more detectable on MRI scans. Imaging studies are especially useful in determining whether surgery or epidural corticosteroid injections are therapeutic options and in guiding the implementation of these procedures.

Whereas the sensitivities of CT and MRI for lumbar spinal stenosis exceed 70%,<sup>12,13</sup> it is important to recognize that more than 20% of persons older than 60 years of age who have no symptoms or functional limitations may have findings of spinal stenosis on imaging studies.

Thus, the specificity of these tests is difficult to estimate.<sup>14,15</sup> The quality of the studies evaluating the use of imaging and other diagnostic tests for spinal stenosis is relatively poor, so the results should be viewed cautiously.<sup>12</sup>

A lumbar myelogram may be obtained before CT scanning to improve visualization of both the bony detail and the nerve-root compression. Because myelography is invasive and requires intrathecal contrast material, MRI is generally preferred. CT myelography continues to have a role in diagnosis for patients who are not candidates for MRI (e.g., because of claustrophobia or metallic implants) and in rare, specific clinical situations.

### *Other Testing*

Electromyography is not routinely warranted. It may occasionally be useful in patients who also have diabetes or in those with other types of neuropathy. Its usefulness is limited by the fact that spinal stenosis and peripheral neuropathy may coexist. In such cases, electromyography will not help determine which process is responsible for symptoms.

### **TREATMENT**

An understanding of the natural history of lumbar spinal stenosis is critical to treatment decisions. The majority of symptomatic patients whose care is managed nonoperatively report no substantial change over the course of 1 year.<sup>16-18</sup> Since it is unlikely that symptoms will worsen or that neurologic function will deteriorate rapidly, prophylactic treatment is not warranted. However, dramatic spontaneous improvement is also uncommon, making watchful waiting an unsatisfactory strategy for patients with intolerable symptoms.

### *Nonoperative Management*

There have been no high-quality trials of most nonoperative approaches to the management of spinal stenosis.<sup>19</sup> Consequently, nonoperative treatment is typically guided by clinical judgment, observational literature, and analogy to other spinal conditions.

Clinical experience indicates that exercises performed during lumbar flexion, such as bicycling, are typically better tolerated than walking. Exercises that strengthen the abdominal musculature may help patients avoid excessive lumbar extension. Although there are no trial data to

guide decisions about the use of lumbar corsets in patients with symptomatic spinal stenosis, corsets may help patients maintain a posture of slight lumbar flexion and are worth trying. To avoid atrophy of paraspinal muscles, the corset should be worn only for a limited number of hours per day.

The pain of lumbar stenosis is typically managed with acetaminophen and, if this fails, nonsteroidal antiinflammatory drugs (NSAIDs). If pain is not responsive to NSAIDs, or if they cannot be tolerated, mild narcotic analgesics can be used. None of these agents has been tested in randomized, controlled trials designed specifically to assess their use in patients with symptomatic spinal stenosis.

Lumbar epidural corticosteroid injections are offered on the assumption that symptoms may result from inflammation at the interface between the nerve root and the compressing tissues. Data on the efficacy of epidural injections are sparse and mixed.<sup>20-24</sup> In small, randomized trials comparing the effectiveness of epidural corticosteroid injections with that of local anesthetic injections in relieving lumbar radicular pain (in cohorts that included patients with spinal stenosis)<sup>20</sup> or improving walking ability (specifically among patients with scoliotic spinal stenosis),<sup>23</sup> the corticosteroid injections did not result in significant improvement. Limited observational data have suggested that epidural injections may relieve leg pain for weeks to months but do not influence functional status or the need for surgery at 1 year.<sup>24</sup> The use of epidural injections in older patients is increasing rapidly, despite the lack of consistent evidence of efficacy.<sup>24,25</sup>

#### *Operative Management*

Patients with symptoms arising from spinal stenosis that persist despite conservative therapy should be given the opportunity to consider surgical management. The principal goal of surgery is to decompress the central spinal canal and the neural foramina, eliminating pressure on the spinal nerve roots. The traditional approach is a laminectomy and partial facetectomy.

There is controversy over whether the decompression should be supplemented by a lumbar arthrodesis (fusion procedure). Observational data suggest that the combination of decompression and fusion is more effective than decompression alone for relieving pain and increasing functional

status in patients with stenosis accompanied by spondylolisthesis<sup>26</sup> but not in patients without associated spondylolisthesis.<sup>27</sup> It is uncertain whether instrumentation (i.e., use of pedicle screws and plates or metal cages to help fuse adjacent vertebrae) or biologic agents (e.g., bone morphogenetic protein) should be used to enhance osseous fusion.<sup>28</sup> Although the use of either instrumentation or biologic agents increases the likelihood of successful fusion, it is not known whether technical success in achieving osseous fusion is associated with improved clinical outcomes. Fusion procedures, especially those involving instrumentation, are associated with increases in cost and complications.<sup>29</sup>

Two randomized trials have compared the efficacy of decompressive laminectomy with that of nonoperative therapy in patients with lumbar spinal stenosis. In one trial, involving 94 patients, those assigned to surgery had significantly greater improvement, both statistically and clinically, in leg and back pain at 1 year than those in the nonoperative group. These differences narrowed at 2 years, although the patients who had surgery continued to report less pain and better functional status than those who had nonoperative treatment.<sup>30</sup> Elsewhere in this issue of the *Journal*, Weinstein et al. report the results of another randomized trial comparing surgery with nonoperative therapy, which involved 289 patients with symptomatic lumbar spinal stenosis.<sup>31</sup> The large number of crossovers (from nonoperative therapy to surgery and vice versa) in this randomized trial make the intention-to-treat analysis difficult to interpret. As-treated analyses support the data from the earlier trial<sup>30</sup> and a high-quality observational study<sup>32</sup> showed that surgery for spinal stenosis affords earlier and greater pain relief and improvement in functional status and that these gains begin to narrow over the course of follow-up.

Cohort studies indicate that although more than 80% of patients have some degree of symptomatic relief after surgery for spinal stenosis,<sup>33</sup> 7 to 10 years later, at least one third of patients report back pain.<sup>32-34</sup> Patients with the most severe nerve-root compression preoperatively are the most likely to have symptomatic relief.<sup>34</sup> Reoperation rates are on the order of 10 to 23% over a period of 7 to 10 years of follow-up.<sup>32,33,35,36</sup> The inpatient mortality rate for spinal-stenosis surgery is less than 1%.<sup>37,38</sup> Deep infections occur in another 1% of patients.<sup>38</sup> Complications and

deaths are more common among patients who are older and who have multiple coexisting conditions.<sup>1</sup>

A less invasive alternative to decompressive laminectomy, called interspinous distraction, is also available for patients with spinal stenosis. In this approach, instrumentation is used to distract (pull apart) adjacent spinous processes, thus imposing lumbar flexion. In a multicenter, randomized trial involving 191 patients, this procedure was associated with greater pain relief than non-operative therapy,<sup>39,40</sup> but data from long-term studies are lacking.

Over the past several years, minimally invasive surgical techniques have been introduced that use smaller incisions and more limited removal of the laminae and facet joints to achieve decompression. Early results from small observational studies are promising,<sup>41-43</sup> but randomized trials are needed.

#### AREAS OF UNCERTAINTY

Data from randomized, controlled trials are insufficient to assess the efficacy of nonsurgical interventions — including education, exercise, lumbar support, and epidural corticosteroid injections — in the treatment of spinal stenosis. Randomized trials comparing surgical decompression with nonsurgical management have suggested that surgery leads to more rapid resolution of symptoms, although the high rate of crossover has been a limitation. Careful studies are needed to establish the appropriate role of minimally invasive surgical approaches and of lumbar arthrodesis.

#### GUIDELINES FROM PROFESSIONAL SOCIETIES

The Agency for Healthcare Research and Quality issued an evidence report in 2001 that emphasized the lack of controlled trials relating to spinal stenosis.<sup>19</sup> Although this report antedated the above-mentioned surgical trials, the National Institute for Health and Clinical Excellence in the United

Kingdom issued a guideline in 2006 on spinal distraction procedures for lumbar spinal stenosis<sup>44</sup> that supported the intervention but emphasized that the studies completed to date were short term (maximum, 2 years) and involved just one type of device.

#### CONCLUSIONS AND RECOMMENDATIONS

The 72-year-old woman described in the vignette has symptoms that are characteristic of symptomatic lumbar spinal stenosis. A more detailed history and physical examination should help to determine whether there are other findings associated with this condition (e.g., a report of pain relief with lumbar flexion and evidence from physical examination of exacerbation with lumbar extension) and to rule out other causes, such as trochanteric bursitis and hip osteoarthritis.

It would be reasonable to refer the patient to a physical therapist, who could suggest ways of modifying activities to avoid lumbar extension and show the patient exercises to strengthen the abdominal muscles. If the condition does not respond to these interventions, along with the use of acetaminophen or NSAIDs, epidural corticosteroid injections might be considered, although data on their efficacy are limited and inconsistent. The possibility of surgery should be discussed with the patient as well. If these more invasive therapies are being considered, imaging (generally an MRI scan) is warranted to evaluate the relevant anatomy. Patients should understand that nonoperative measures will probably result in slight-to-moderate improvement for a time and that surgery typically leads to more rapid relief of symptoms and improvement in functional status. However, symptoms may recur with either approach.

Dr. Katz reports receiving grant support from Novartis, and Dr. Harris reports receiving grant support from Synthes. No other potential conflict of interest relevant to this article was reported.

Supported by grants from the National Institutes of Health (K24 AR02123 and P60 AR47788).

#### REFERENCES

1. Ciol MA, Deyo RA, Howell E, Kreif S, et al. Lumbar spinal stenosis and nerve root entrapment syndromes: definition and classification. *Clin Orthop Relat Res* 1976;115:4-5.
2. Arnoldi CC, Brodsky AE, Cauchoix J, et al. Two-level spinal stenosis in minipigs: hemodynamic effects of exercise. *Spine* 1995;20:2765-73.
3. Jespersen SM, Hansen ES, Høy K, et al. Two-level spinal stenosis in minipigs: hemodynamic effects of exercise. *Spine* 1995;20:2765-73.
4. Porter RW. Spinal stenosis and neurogenic claudication. *Spine* 1996;21:2046-52.
5. Sekiguchi M, Kikuchi S. Experimental

- tal studies of lumbar spinal stenosis. *Clin Calcium* 2005;15:51-6. (In Japanese.)
6. Takenobu Y, Katsube N, Marsala M, Kondo K. Model of neuropathic intermittent claudication in the rat: methodology and application. *J Neurosci Methods* 2001; 104:191-8.
  7. Olmarker K, Holm S, Rosenqvist AL, Rydevik B. Experimental nerve root compression: a model of acute, graded compression of the porcine cauda equina and an analysis of neural and vascular anatomy. *Spine* 1991;16:61-9.
  8. Olmarker K, Rydevik B. Single- versus double-level nerve root compression: an experimental study on the porcine cauda equina with analyses of nerve impulse conduction properties. *Clin Orthop Relat Res* 1992;279:35-9.
  9. Olmarker K, Rydevik B, Holm S. Edema formation in spinal nerve roots induced by experimental, graded compression: an experimental study on the pig cauda equina with special reference to differences in effects between rapid and slow onset of compression. *Spine* 1989;14: 569-73.
  10. Olmarker K, Rydevik B, Holm S, Bagge U. Effects of experimental graded compression on blood flow in spinal nerve roots: a vital microscopic study on the porcine cauda equina. *J Orthop Res* 1989;7:817-23.
  11. Katz JN, Dalgas M, Stucki G, et al. Degenerative lumbar spinal stenosis: diagnostic value of the history and physical examination. *Arthritis Rheum* 1995;38: 1236-41.
  12. de Graaf I, Prak A, Bierma-Zeinstra S, Thomas S, Peul W, Koes B. Diagnosis of lumbar spinal stenosis: a systematic review of the accuracy of diagnostic tests. *Spine* 2006;31:1168-76.
  13. Kent DL, Haynor DR, Larson EB, Deyo RA. Diagnosis of lumbar spinal stenosis in adults: a metaanalysis of the accuracy of CT, MR, and myelography. *AJR Am J Roentgenol* 1992;158:1135-44.
  14. Boden SD, McCowin PR, Davis DO, Dina TS, Mark AS, Wiesel S. Abnormal magnetic-resonance scans of the cervical spine in asymptomatic subjects: a prospective investigation. *J Bone Joint Surg Am* 1990;72:1178-84.
  15. Jensen MC, Brant-Zawadzki MN, Obuchowski N, Modic MT, Malkasian D, Ross JS. Magnetic resonance imaging of the lumbar spine in people without back pain. *N Engl J Med* 1994;331:69-73.
  16. Atlas SJ, Keller RB, Robson D, Deyo RA, Singer DE. Surgical and nonsurgical management of lumbar spinal stenosis: four-year outcomes from the Maine Lumbar Spine Study. *Spine* 2000;25:556-62.
  17. Benoist M. The natural history of lumbar degenerative spinal stenosis. *Joint Bone Spine* 2002;69:450-7.
  18. Simotas AC, Dorey FJ, Hansraj KK, Cammisia F Jr. Nonoperative treatment for lumbar spinal stenosis: clinical and outcome results and a 3-year survivorship analysis. *Spine* 2000;25:197-204.
  19. Treatment of degenerative lumbar spinal stenosis: summary. Evidence report/technology assessment number 32. Rockville, MD: Agency for Healthcare Research and Quality, June 2001. (AHRQ publication no. 01-E047.) (Accessed January 28, 2008, at <http://www.ahrq.gov/clinic/epcsums/stenosis.htm>.)
  20. Cuckler JM, Bernini PA, Wiesel SW, Booth RE Jr, Rothman RH, Pickens GT. The use of epidural steroids in the treatment of lumbar radicular pain: a prospective, randomized, double-blind study. *J Bone Joint Surg Am* 1985;67:63-6.
  21. Rivest C, Katz JN, Ferrante FM, Jamison RN. Effects of epidural steroid injection on pain due to lumbar spinal stenosis or herniated disks: a prospective study. *Arthritis Care Res* 1998;11:291-7.
  22. Cooper G, Lutz GE, Boachie-Adjei O, Lin J. Effectiveness of transforaminal epidural steroid injections in patients with degenerative lumbar scoliotic stenosis and radiculopathy. *Pain Physician* 2004;7:311-7.
  23. Fukusaki M, Kobayashi I, Hara T, Sumikawa K. Symptoms of spinal stenosis do not improve after epidural steroid injection. *Clin J Pain* 1998;14:148-51.
  24. Armon C, Argoff CE, Samuels J, Backonja MM. Assessment: use of epidural steroid injections to treat radicular lumbosacral pain: report of the Therapeutics and Technology Assessment Subcommittee of the American Academy of Neurology. *Neurology* 2007;68:723-9.
  25. Friedly J, Chan L, Deyo R. Increases in lumbosacral injections in the Medicare population: 1994 to 2001. *Spine* 2007;32: 1754-60.
  26. Herkowitz HN, Kurz LT. Degenerative lumbar spondylolisthesis with spinal stenosis: a prospective study comparing decompression with decompression and intertransverse process arthrodesis. *J Bone Joint Surg Am* 1991;73:802-8.
  27. Grob D, Humke T, Dvorak J. Significance of simultaneous fusion and surgical decompression in lumbar spinal stenosis. *Orthopade* 1993;22:243-9. (In German.)
  28. Fischgrund JS, Mackay M, Herkowitz HN, Brower R, Montgomery DM, Kurz LT. Degenerative lumbar spondylolisthesis with spinal stenosis: a prospective, randomized study comparing decompressive laminectomy and arthrodesis with and without spinal instrumentation. *Spine* 1997;22:2807-12.
  29. Katz JN, Lipson SJ, Lew RA, et al. Lumbar laminectomy alone or with instrumented or noninstrumented arthrodesis in degenerative lumbar spinal stenosis: patient selection, costs, and surgical outcomes. *Spine* 1997;22:1123-31.
  30. Malmivaara A, Slätis P, Heliövaara M, et al. Surgical or nonoperative treatment for lumbar spinal stenosis? A randomized controlled trial. *Spine* 2007;32:1-8.
  31. Weinstein JN, Tosteson TD, Lurie JD, et al. Surgical versus nonsurgical therapy for lumbar spinal stenosis. *N Engl J Med* 2008;358:794-810.
  32. Atlas SJ, Keller RB, Wu YA, Deyo RA, Singer DE. Long-term outcomes of surgical and nonsurgical management of lumbar spinal stenosis: 8 to 10 year results from the Maine Lumbar Spine Study. *Spine* 2005;30:936-43.
  33. Katz JN, Lipson SJ, Chang LC, Levine SA, Fossel AH, Liang MH. Seven- to 10-year outcome of decompressive surgery for degenerative lumbar spinal stenosis. *Spine* 1996;21:92-8.
  34. Herno A. Surgical results of lumbar spinal stenosis. *Ann Chir Gynaecol Suppl* 1995;210:1-969.
  35. Ciol MA, Deyo RA, Kreuter W, Bigos SJ. Characteristics in Medicare beneficiaries associated with reoperation after lumbar spine surgery. *Spine* 1994;19:1329-34.
  36. Herno A, Airaksinen O, Saari T. Long-term results of surgical treatment of lumbar spinal stenosis. *Spine* 1993;18:1471-4.
  37. Deyo RA, Cherkin DC, Loeser JD, Bigos SJ, Ciol MA. Morbidity and mortality in association with operations on the lumbar spine: the influence of age, diagnosis, and procedure. *J Bone Joint Surg Am* 1992;74:536-43.
  38. Turner JA, Ersek M, Herron L, Deyo R. Surgery for lumbar spinal stenosis: attempted meta-analysis of the literature. *Spine* 1992;17:1-8.
  39. Zucherman JF, Hsu KY, Hartjen CA, et al. A prospective randomized multi-center study for the treatment of lumbar spinal stenosis with the X STOP interspinous implant: 1-year results. *Eur Spine J* 2004; 13:22-31.
  40. Zucherman JF, Hsu KY, Hartjen CA, et al. A multicenter, prospective, randomized trial evaluating the X STOP interspinous process decompression system for the treatment of neurogenic intermittent claudication: two-year follow-up results. *Spine* 2005;30:1351-8.
  41. Rosen DS, O'Toole JE, Eichholz KM, et al. Minimally invasive lumbar spinal decompression in the elderly: outcomes of 50 patients aged 75 years and older. *Neurosurgery* 2007;60:503-10.
  42. Iwatsuki K, Yoshimine T, Aoki M. Bilateral interlaminar fenestration and unroofing for the decompression of nerve roots by using a unilateral approach in lumbar canal stenosis. *Surg Neurol* 2007;68:487-92.
  43. Podichetty VK, Spears J, Isaacs RE,

Booher J, Biscup RS. Complications associated with minimally invasive decompression for lumbar spinal stenosis. *J Spinal Disord Tech* 2006;19:161-6.

44. Interspinous distraction procedures for spinal stenosis causing neurogenic claudication in the lumbar spine. National Institute for Clinical Excellence, IPG 165,

March 22, 2006. (Accessed January 26, 2008, at <http://www.nice.org.uk/guidance/index.jsp?action=byID&r=true&o=11162>.)  
Copyright © 2008 Massachusetts Medical Society.