

LYMPHATIC DRAINAGE OF THE HEART IN THE LABORATORY RAT

S.M. Maurice, A.S. Palmer, A.J. Miller, R. Greene

Cardiology and Cardiothoracic Surgery Divisions, Northwestern University Medical School, Chicago, Illinois USA

ABSTRACT

We showed in the Sprague Dawley rat that the principal ascending cardiac lymphatic is similar in location to that of man and dog and can be readily visualized by injection of a small amount of T1824 blue dye (Evans) into the apex of the left ventricle. We also showed that it is possible to ligate and thereby obstruct this principal cardiac lymphatic near its entry beneath the left atrial appendage. This latter technique may be useful for studying in a small relatively inexpensive laboratory animal the effects of blocking cardiac lymph drainage on inflammatory and infectious processes implicated in myocardial and coronary artery disease.

Interference with lymph flow from an organ predisposes to inflammation, infection, and fibrosis (1-4). Injury to arterial walls and the accompanying inflammatory reaction has been implicated in the development of atherosclerotic plaque (5-10). More recently, infection (e.g., *Chlamydia pneumoniae* and Cytomegalic inclusion virus or CMV) has also been implicated as contributing to the inflammatory process integral to formation of atherosclerotic lesions (8,11-16). We have previously suggested that impaired lymph drainage of the heart predisposes to inflammatory and possibly infectious factors in the pathogenesis of atherosclerosis (1,17). In this regard, it is noteworthy that cardiac

allograft vasculopathy, marked by intimal proliferation and frequent atheroma formation (and possibly related to CMV infection), is common after cardiac transplantation (18,19), an operation that acutely disrupts efferent lymphatics of the heart.

To study the effects of lymphatic obstruction on inflammation, infection, and wound healing with regard to atherogenesis requires an animal model suitable for molecular biologic and immunologic analysis. The rat is such a valuable experimental animal being relatively inexpensive, of small size, and one in which considerable experience has accrued using the tools of modern molecular medicine. An extensive subepicardial lymphatic capillary network and a valved main lymphatic trunk running from the apex to the base of the heart have been demonstrated by scanning electron microscopy in the post-mortem rat heart (20). However, visualization of rodent cardiac lymphatics *in vivo* has not been previously described, nor the feasibility of ligating its principal ascending cardiac lymphatic.

MATERIALS AND METHODS

Seven male Sprague Dawley rats were studied. The rats, 200-530g in body weight, were operated upon as "acute" experiments. The animal care complied with the "Principles of Laboratory Animal Care" and the "Guide for the Care and Use of

Laboratory Animals" (NIH Publication No. 80-23, revised 1985). Each rat was operated on in the Cardiothoracic Surgery Laboratory of the Feinberg Cardiovascular Institute at the Northwestern University Medical School.

Anesthesia was induced by an intraperitoneal injection of pentobarbital, 30-50 mg/kg (5) or by intraperitoneal injections of ketamine, 75-180 mg/kg, and xylazine, 5-10 mg/kg (2 rats). Each rat was placed in a supine position and secured to a wooden operating platform. After the trachea was exposed via a midline cervical incision, the overlying strap muscles were retracted and a small longitudinal incision was made in the trachea. A PE-90 polythene tube was then inserted into the tracheal incision over an 18 gauge blunt-en needle and connected to a rodent ventilator (Harvard Rodent Ventilator Model 683). The ventilator was set at a tidal volume of 2.5 to 3.9 ml per stroke at a rate of 50 to 60 breaths per minute. Periodic adjustments were made in the depth and rate of ventilation depending on the extent of lung expansion.

The heart was exposed by a median sternotomy. The chest wall was retracted with a Codman 09 chest retractor (50-5625, stainless steel). A small amount of T1824 (Evans blue dye) diluted 1:1 with isotonic saline was injected subepicardially near the apex of the left ventricle to visualize the cardiac lymphatics. Photographs were taken and sketches were made of the ascending lymphatics displayed. Dissection of the mediastinum was also performed in an attempt to trace the pathways of the lymphatics leaving the base of the heart. Visualization of the ascending lymphatics was aided by the use of a dissecting microscope (Leica, StereoZoom6) and a light source (E Light Company, mdl FOI-1).

In two rats, the principal ascending cardiac lymphatic was ligated near the left atrial appendage and photographs taken thereafter.

RESULTS

Similar to man and the dog, the principal ascending cardiac lymphatic of the rat ascended along the interventricular groove toward the left atrial appendage (*Fig. 1, upper*), but unlike man and the dog, it did not course with the left anterior descending artery. As has previously been noted (22), the rat left coronary artery, a *ramus medianus*, descends over the anterior lateral wall of the left ventricle parallel to the interventricular sulcus. Attempts to visualize the mediastinal drainage pathway(s) of the lymphatics leaving the base of the heart were unsuccessful.

In 2 rats in which we ligated the principal ascending lymphatic near where it passed under the left atrial appendage, the distal lymphatic portion rapidly dilated (*Fig. 1, lower panels*).

DISCUSSION

This rodent study shows the Sprague Dawley rat to be an excellent experimental preparation to study the effects of interference with cardiac lymph flow on inflammatory and/or wound healing processes implicated in coronary artery atherosclerosis. As we previously hypothesized (17), congenital hypoplasia of the cardiac lymphatic system could predispose to cellular infiltration, infection and the deposition of fibrous tissue, each or all of which may contribute to the pathogenesis of the atherosclerotic plaque. Acquired impaired cardiac lymph drainage, as occurs with allogeneic heart transplantation, on the other hand, may play a role in the development of post-transplant vasculopathy that often destroys function in the transplanted heart. To examine the interplay of lymphatic structure and (dys)function with infection, inflammation, and wound healing requires an inexpensive, small-size animal model suitable for immunologic and molecular biologic studies. The clear visualization of the principal ascending cardiac lymphatic in the Sprague Dawley rat after the injection of a coloring marker and

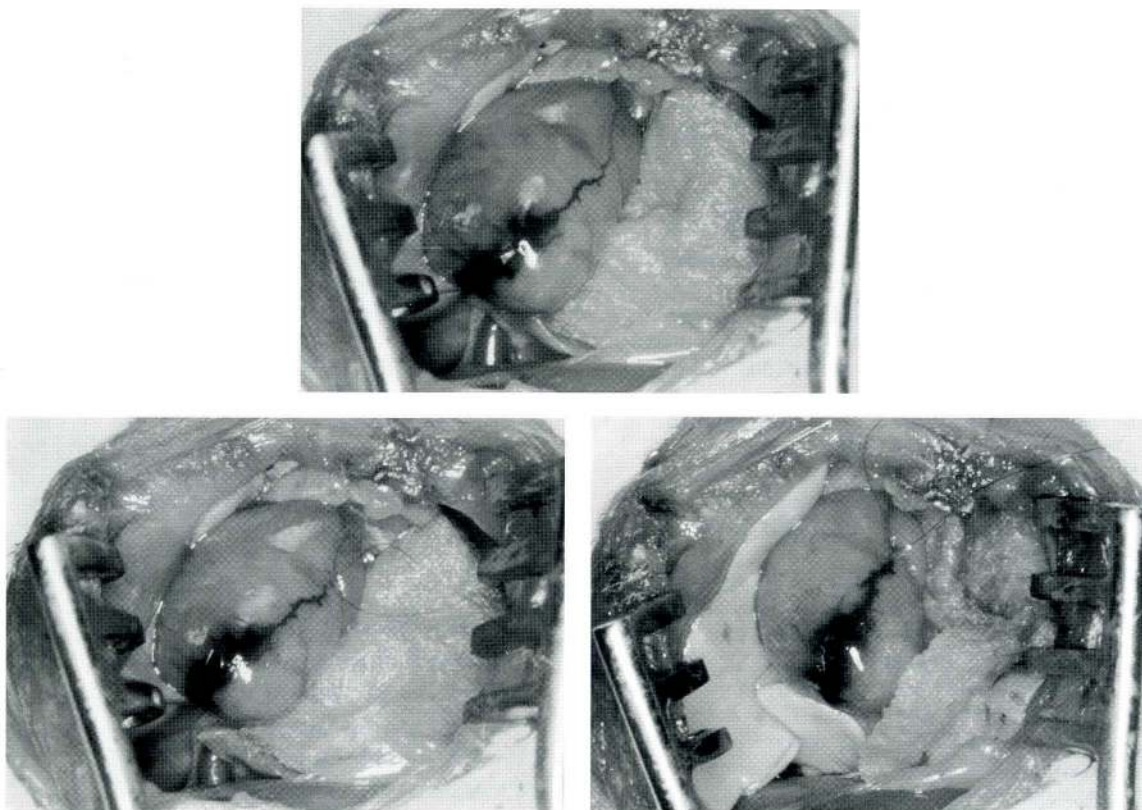


Fig. 1. Upper: Visualization of principal ascending cardiac lymphatic (PACL) in the rat after injection of a small amount of T1824 blue dye (Evans) into the apex of the left ventricle. After ligation of the PACL, it is seen to dilate 2 min later (lower left) and even more markedly 10 min later (lower right). In each figure, there is a gauze pad on the left side of the heart retracting it anteriorly and to the right to improve visualization of the lymphatic for the photograph.

its successful ligation with resulting distal dilation shows that obstruction of the efferent lymphatic pathways is feasible for this research purpose.

REFERENCES

1. Miller, AJ: *The Lymphatics of the Heart*. Raven Press, New York City, 1982.
2. Drinker, CK, JM Yoffey: *Lymphatics, Lymph and Lymphoid Tissue*. Harvard University Press, Cambridge, 1941.
3. Rusznyák, I, M Földi, G Szabó: *Lymphatics and Lymph Circulation*. Pergamon Press, New York, 1960.
4. Drinker, CK, ME Field, FW Maurer, et al: The flow, pressure, and composition of cardiac lymph. *Am. J. Physiol.* 130 (1940), 43-55.
5. Ross, R: The pathogenesis of atherosclerosis: A perspective for the 1990s. *Nature* 362 (1993), 801-809.
6. Ross, R: Atherosclerosis is an inflammatory disease. *Am Heart J.* 138 (1999), S419-S420.
7. Hansson, GK, J Holm, L Jonasson: Detection of activated T lymphocytes in the human atherosclerotic plaque. *Am. J. Pathol.* 135 (1989), 169-175.
8. de Boer, OJ, AC van der Wal, AE Becker: Atherosclerosis, inflammation, and infection. *J. Pathol.* 190 (2000), 237-243.
9. Gerszten, RE, F Mach, A Sauty, et al: Chemokines, leukocytes, and atherosclerosis. *J. Laboratory & Clinical Medicine* 136(2) (2000), 87-92.
10. Frostegård, J, AK Ulfgrén, P Nyberg, et al: Cytokine expression in advanced human atherosclerotic plaques: Dominance of pro-inflammatory (Th1) and macrophage-

- stimulating cytokines. *Atherosclerosis* 145 (1999), 33-43.
11. Fong, IW: Emerging relations between infectious diseases and coronary artery disease and atherosclerosis. *CMAJ* 163(1) (2000), 49-56.
 12. Epstein, SE, J Zhu, MS Burnett, et al: Infection and atherosclerosis: Potential roles of pathogen burden and molecular mimicry. *Atherosclerosis, Thrombosis and Vascular Biology* 20(6) (2000), 1417-1420.
 13. Bachmaier, K, N Neu, LM de la Maza, et al: Chlamydia infections and heart disease linked through antigenic mimicry. *Science* 283 (1999), 1335-1339.
 14. Epstein, SE, YE Zhou, J Zhu: Infection and atherosclerosis: Emerging mechanistic paradigms. *Circulation* 100 (1999), e20-28.
 15. Bruggeman, C: Cytomegalovirus is involved in vascular pathology. *Am. Heart J.* 138 (1999), S473-475.
 16. Kalayoglu, MV, Indrawati, RP Morrison, et al: Chlamydial virulence determinants in atherosclerosis: The role of chlamydial lipopolysaccharide and heat shock protein 60 in macrophage-lipoprotein interactions. *J. Inf. Dis.* 181 (2000), S483-489.
 17. Miller, AJ, A DeBoer, A Palmer: The role of the lymphatic system in coronary atherosclerosis. *Medical Hypotheses* 37 (1992), 31-36.
 18. Hosenpud, JD: Coronary artery disease after heart transplantation and its relation to cytomegalovirus. *American Heart J.* 138 (1999), S469-472.
 19. Weis, M, W von Scheidt: Cardiac allograft vasculopathy: A review. *Circulation* 96 (1997), 2069-2077.
 20. Shimada, T, T Noguchi, T Kaoruko, et al: Morphology of lymphatics of the mammalian heart with special reference to the architecture and distribution of the subepicardial lymphatic system. *Acta Anat.* 139 (1989), 16-20.
 21. Patek, PR: The morphology of the lymphatics of the mammalian heart. *Am. J. Anat.* 64 (1939), 203-249.
 22. Bishop, SP: Cardiovascular research. In: *The Laboratory Rat, Vol. II*. Baker, HJ, JR Lindsey, SH Weisbroth (Eds.), Academic Press, New York, 1980.

Arthur S. Palmer, MD
Division of Cardiothoracic Surgery
Northwestern Memorial Hospital
251 East Huron Street
Wesley Pavilion 628
Chicago, Illinois 60611 USA