

Images in Neurology

Magnetic Resonance Imaging Alteration of the Brain in a Patient With Coronavirus Disease 2019 (COVID-19) and Anosmia

Letterio S. Politi, MD; Ettore Salsano, MD; Marco Grimaldi, MD

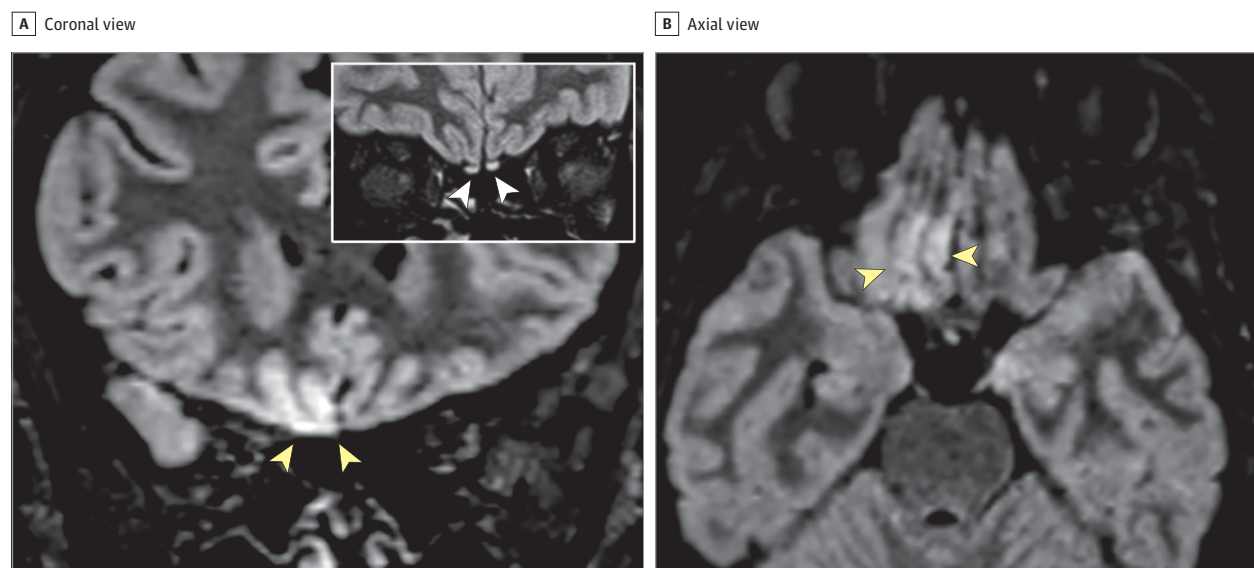
The neurotropism of human coronaviruses has already been demonstrated in small animals, and in autopsic studies the severe acute respiratory syndrome coronavirus (SARS-CoV), which was responsible for the SARS outbreak during 2002 to 2003, was found in the brains of patients with infection.¹ It has been proposed that the neuroinvasive potential of the novel SARS-CoV-2, responsible for coronavirus disease 2019 (COVID-19), may be at least partially responsible for the respiratory failure of patients with COVID-19.² In this article, we share the magnetic resonance imaging (MRI) evidence of in vivo brain alteration presumably due to SARS-CoV-2 and demonstrate that anosmia can represent the predominant symptom in COVID-19.

A 25-year-old female radiographer with no significant medical history who had been working in a COVID-19 ward presented with a mild dry cough that lasted for 1 day, followed by persistent severe anosmia and dysgeusia. She did not have a fever. She had no trauma, seizure, or hypoglycemic event. Three days later, nasal fibroscopic evaluation results were unremarkable, and noncontrast chest and maxillofacial computed tomography results were negative. On the same day, a brain MRI was also performed. On 3-dimensional and 2-dimensional fluid-attenuated inversion recovery images, a cortical hyperintensity was evident in the right gyrus rectus (Figure 1) and a subtle hyperintensity was present in the olfactory bulbs (Figure 1).

Because many patients in Italy are experiencing anosmia³ and the cortical signal alteration was suggestive of viral infection, a swab test was performed and reverse transcription–polymerase chain reaction analysis yielded positive results for SARS-CoV-2. During a follow-up MRI performed 28 days later, the signal alteration in the cortex completely disappeared and the olfactory bulbs were thinner and slightly less hyperintense (Figure 2⁴). The patient recovered from anosmia. No brain abnormalities were seen in 2 other patients with COVID-19 presenting anosmia who underwent brain MRI 12 and 25 days from symptom onset.

To our knowledge, this is the first report of in vivo human brain involvement in a patient with COVID-19 showing a signal alteration compatible with viral brain invasion in a cortical region (ie, posterior gyrus rectus) that is associated with olfaction. Alternative diagnoses (eg, status epilepticus, posterior reversible encephalopathy syndrome–like alterations, other viral infections, and anti-*N*-methyl-D-aspartate receptor encephalitis) are unlikely given the clinical context. Based on the MRI findings, including the slight olfactory bulb changes, we can speculate that SARS-CoV-2 might invade the brain through the olfactory pathway and cause an olfactory dysfunction of sensorineural origin; cerebrospinal fluid and pathology studies are required to confirm this hypothesis. Ours and others' observations of normal brain imaging in

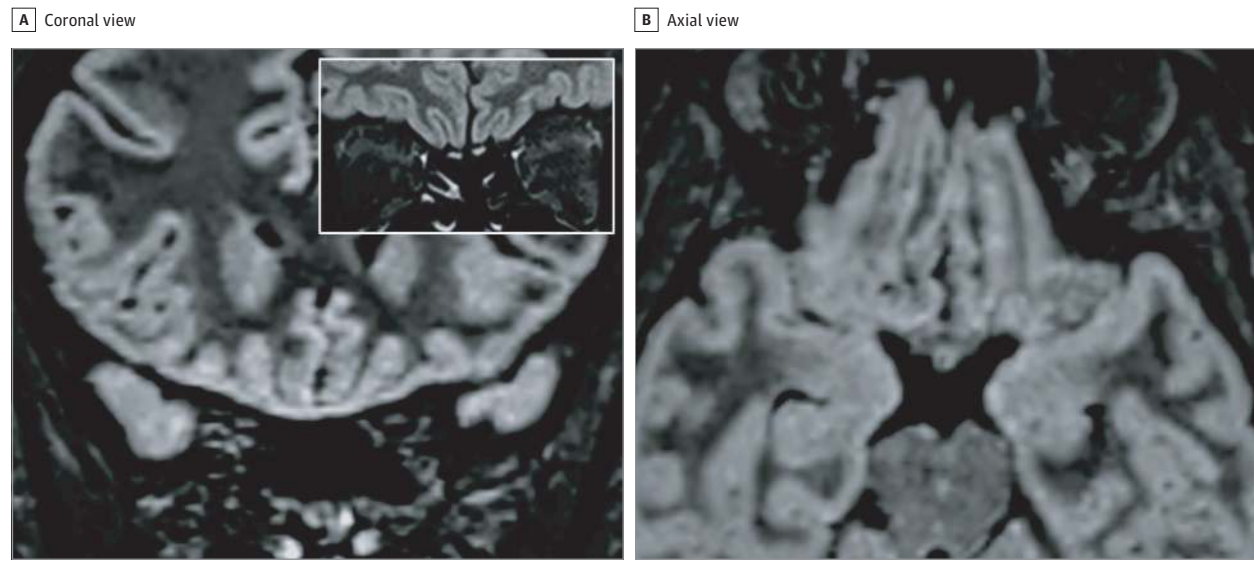
Figure 1. Brain Magnetic Resonance Imaging Alterations in a Patient With Coronavirus Disease 2019 (COVID-19) Presenting With Anosmia 4 Days From Symptom Onset



Coronal (A) and axial (B) reformatted 3-dimensional fluid-attenuated inversion recovery (FLAIR) images showing cortical hyperintensity in the right gyrus rectus (yellow arrowheads in A and B). In the inset in A, a coronal 2-dimensional FLAIR image shows subtle hyperintensity in the bilateral olfactory bulbs (white

arrowheads). The cortical hyperintensity is present only in the posterior portion of the right gyrus rectus (B). Accordingly, the cortical hyperintensity of the right gyrus rectus is evident in the more posterior coronal image (A) and not in the anterior coronal one (inset).

Figure 2. Follow-up Magnetic Resonance Imaging Study in the Same Patient 28 Days From Symptom Onset



Coronal (A) and axial (B) reformatted 3-dimensional fluid-attenuated inversion recover (FLAIR) images showing complete resolution of the previously seen signal alteration within the cortex of the right gyrus rectus. In the inset, a coronal

2-dimensional FLAIR image shows a slight reduction of the hyperintensity and the thickness of the olfactory bulbs, suggesting a postinfection olfactory loss.⁴

other patients with COVID-19-associated olfactory dysfunctions⁴ and the disappearance of the cortical MRI abnormalities in the follow-up study of this patient suggest that imaging changes are not always present in COVID-19 or might be limited to the very

early phase of the infection. Further, anosmia can be the predominant COVID-19 manifestation, and this should be considered for the identification and isolation of patients with infection to avoid disease spread.

ARTICLE INFORMATION

Author Affiliations: Department of Neuroradiology, IRCCS Istituto Clinico Humanitas and Humanitas University, Milan, Italy (Politi, Grimaldi); Department of Radiology and Hematology & Oncology Division, Boston Children's Hospital, Boston, Massachusetts (Politi); Department of Radiology and Advanced MRI Center, University of Massachusetts Medical School and Medical Center, Worcester, Massachusetts (Politi); UOC Malattie Neurodegenerative e Neurometaboliche Rare, Fondazione IRCCS Istituto Neurologico Carlo Besta, Milan, Italy (Salsano).

Corresponding Author: Letterio S. Politi, MD, IRCCS Istituto Clinico Humanitas, via Alessandro Manzoni 56, Rozzano 20089, Italy (letterio.politi@hunimed.eu).

Published Online: May 29, 2020.
doi:10.1001/jamaneurol.2020.2125

Conflict of Interest Disclosures: None reported.

Additional Contributions: We thank Simona Superbi and Cristiana Lucarini (Department of Neuroradiology, IRCCS Istituto Clinico Humanitas) for technical support and the patient for granting permission to publish this information. No compensation was provided.

REFERENCES

1. Gu J, Gong E, Zhang B, et al. Multiple organ infection and the pathogenesis of SARS. *J Exp Med*. 2005;202(3):415-424. doi:10.1084/jem.20050828
2. Li YC, Bai WZ, Hashikawa T. The neuroinvasive potential of SARS-CoV2 may play a role in the

respiratory failure of COVID-19 patients. *J Med Virol*. 2020. doi:10.1002/jmv.25824

3. Giacomelli A, Pezzati L, Conti F, et al. Self-reported olfactory and taste disorders in SARS-CoV-2 patients: a cross-sectional study. *Clin Infect Dis*. 2020;ciaa330. doi:10.1093/cid/ciaa330

4. Eliezer M, Hautefort C, Hamel AL, et al. Sudden and complete olfactory loss function as a possible symptom of COVID-19. *JAMA Otolaryngol Head Neck Surg*. 2020. doi:10.1001/jamaoto.2020.0832