

# Clinical review

## Management and referral for trigger finger/thumb

Sohail Akhtar, Mary J Bradley, David N Quinton, Frank D Burke

27 Belle Vue  
Avenue, Oakwood,  
Leeds LS8 2NN  
Sohail Akhtar  
clinical/research  
fellow

Pulvertaft Hand  
Centre, Derbyshire  
Royal Infirmary,  
Derby

Mary J Bradley  
research and  
postgraduate  
manager

David N Quinton  
consultant hand  
surgeon

Frank D Burke  
professor of hand  
surgery

Correspondence to:  
S Akhtar  
sohailakhtar001@  
yahoo.co.uk

BMJ 2005;331:30-3

Trigger finger is a common cause of pain and disability in the hand. It is also the fourth most common reason for referral to the hand outpatient clinic and accounts for 1 in 18 of all referrals to our unit. The condition is, however, not solely managed by hand surgeons as it is often treated in the community and by specialist practitioners such as rheumatologists and endocrinologists who encounter it as a secondary manifestation of a primary systemic disorder. From a review of the literature we highlight the presentation of trigger finger, describe the processes involved in developing the condition, and rationalise the treatment options available. We have suggested guidelines and key points of note to aid practitioners in the management and referral of trigger finger and thumb in adults.

### Sources and search criteria

We searched Medline and PubMed for relevant English language literature. We used the search terms “trigger finger” and “stenosing tenosynovitis.” We identified additional literature from the references of these papers.

### Presentation and progression

Trigger finger presents with discomfort in the palm during movement of the involved digits. Gradually, or in some cases acutely, the flexor tendon causes a painful click as the patient flexes and extends the digit. The patient may present with a digit locked in a particular position, usually in flexion, which may need gentle passive manipulation into full extension. Spontaneous resolution of symptoms can occur in patients with trigger thumb.<sup>w1</sup>

### Epidemiology

The condition has a reported incidence of 28 cases per 100 000 population per year, or a lifetime risk of 2.6% in the general population.<sup>1</sup> This rises to 10% in patients with diabetes. Two peaks in incidence occur—the first under the age of eight and the second (more common) in the fifth and sixth decades of life. This bimodal distribution represents two different clinical groups, not only for age but also in incidence, sex distribution, digit affected, treatment, and outcome (table).

### Pathophysiology

Trigger finger arises through a discrepancy in the diameter of the flexor tendon and its sheath at the level

### Summary points

Children can present with trigger finger/thumb, but it is less common than in adults; presentation is usually a fixed flexion deformity of the thumb

In patients with diabetes, trigger finger is more common and less likely to respond to treatment than in patients without diabetes

Steroid injection can produce a cure rate in excess of 90% in patients with a palpable nodule or with symptoms present for less than six months

With a suitable knowledge of the anatomy, giving a single steroid injection is safe and has few complications

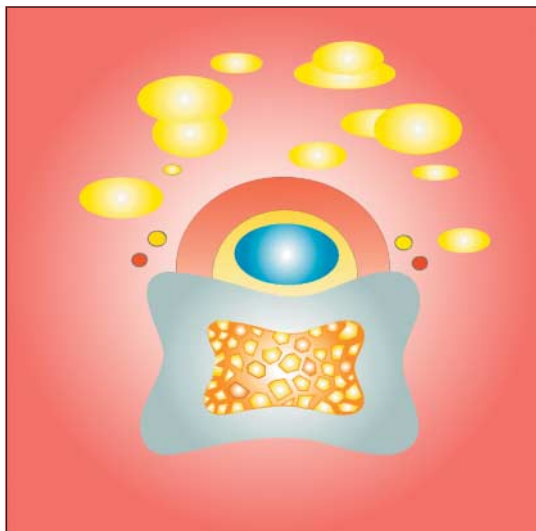
Percutaneous trigger release is a safe and effective means of treating trigger finger and can be done in the outpatient clinic

of the metacarpal head. High pressures occur at the proximal edge of the A1 pulley on maximal flexion and during tight grip. Pressure is more evenly distributed in the remainder of the pulley system. In some patients this seems to have an adverse effect, causing changes in the macroscopic appearance of the A1 pulley with hypertrophy and fibrocartilaginous metaplasia at the tendon-pulley interface (fig 1 and fig 2).<sup>2</sup>

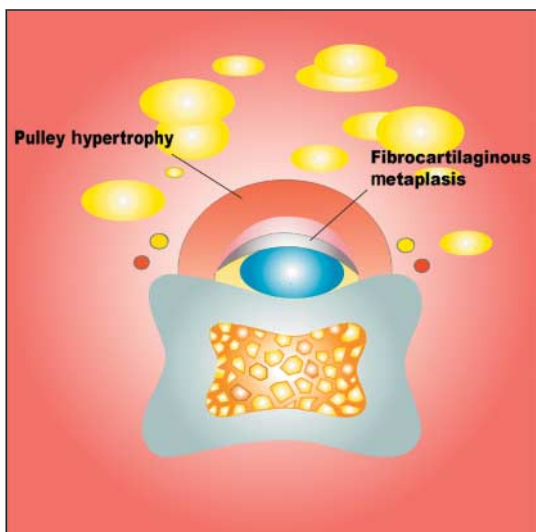
The thickening of the sheath, along with some localised tendon thickening, can result in a narrowed tunnel for tendon excursion and ultimately lead to a block to movement; the flexors are usually powerful enough to overcome this obstruction, whereas the weaker extensors are less able to counteract the block, resulting in the finger being locked in flexion. The A1 pulley is the site of disease in nearly all cases, owing to the high local forces and a steep pressure gradient; it is also the site of maximal tendon excursion. Alternative sites of tendon triggering have been described, including the A2 and A3 pulleys and the palmar aponeurosis.<sup>w2-w4</sup>



Extra references are on [bmj.com](http://bmj.com)



**Fig 1** Cross sectional view of flexor tendon passing through a normal A1 pulley



**Fig 2** Cross sectional view of flexor tendon passing through an A1 pulley that has undergone changes associated with trigger finger disease

### Causes

Various causes of trigger finger have been proposed, including repetitive finger movements or compressive forces at the A1 pulley and repetitive local trauma.<sup>3-5</sup> In such circumstances, occupation could be a major predisposing factor. However the available literature only partially supports that view. Bonnici and Spencer reported that 14/36 of their patients had occupations involving repetitive movement,<sup>3</sup> and Fahey and Bollinger observed that trigger finger was often seen in workers doing unaccustomed tasks in the workplace.<sup>6</sup> However, neither Anderson and Kaye nor Trazies et al found a correlation between the incidence of trigger finger and the workplace.<sup>7 8</sup>

### Associated conditions

Incidence of trigger finger is increased in patients with diabetes.<sup>9-11</sup> In type 1 diabetes this correlation relates to duration of diabetes and not to diabetic control.<sup>10</sup> The prevalence is similar for type 1 and type 2 diabetes.<sup>12</sup> Patients with type 1 diabetes are more likely to have multiple digit involvement.<sup>11</sup> Patients with diabetes, especially type 1, are more difficult to treat and more likely to need surgery and protracted periods of physiotherapy than people without diabetes.<sup>11 13</sup> Patients with other common medical conditions such as hypothyroidism,<sup>11 14</sup> rheumatoid arthritis,<sup>9 w5</sup> gout, or renal failure, or rarer conditions such as amyloidosis,<sup>w6</sup> are at higher risk of developing a trigger finger. Trigger finger also commonly coexists with local disorders such as carpal tunnel syndrome, de Quervain's tenovaginitis, and Dupuytren's contracture.<sup>11 12 14</sup> No association with pregnancy has been reported.<sup>w7</sup>

### Anatomy

The flexor sheath is a membranous structure, which surrounds the flexor tendons from the metacarpal neck to the volar plate of the distal interphalangeal joint and is attached longitudinally to the underlying bony structures. The sheath is thick over the bones (the annular pulley portion of the system) and thin in areas overlying the joints (cruciform pulley portion) to permit digital flexion. In maximal digital flexion, the edges of the annular pulleys approximate and in parts telescope while the cruciform pulleys concertina.

The A1 pulley marks the proximal border of the flexor sheath, and its surface markings can be identified from cadaver studies. If the distance between the proximal digital crease and the corresponding finger proximal interphalangeal joint crease is X cm, measuring X cm proximally from the proximal digital crease identifies the surface markings of the proximal border of the A1 pulley. The length of the A1 pulley has been found to be 1.17 cm ± 0.02 cm for the adult index, middle, and ring fingers and 0.98 cm ± 0.02 cm for the little finger (fig 3).<sup>15</sup>

The longitudinal axis of the neurovascular bundles follows the line of the digit in the ring finger and middle finger; however, the neurovascular bundles of the index and little fingers lie in a more diagonal axis, as they are situated beyond the medial and lateral edges of the distal end of the carpal tunnel. Consequently, the neurovascular bundles for these digits may cross over the A1 pulley (fig 4). A practitioner must be alert to this if invasive interventions are being considered, as the radial digital nerve to the index finger and the ulnar digital nerve to the little finger will be particularly close to the pulley, putting them at risk of inadvertent damage.<sup>16</sup>

### Treatment

Various methods have been used to treat trigger finger. We have reviewed the literature to obtain the evidence

#### Bimodal distribution of trigger finger/thumb

Age (years)	Prevalence (%)	Sex ratio (female:male)	Laterality	Digit affected	Treatment
<8	0.2	1:1	Equal; 25% bilateral	Thumb 90%	Various modes
40-60*	2.6	6:1	Dominant hand	Thumb 33%; ring 27%	Various modes

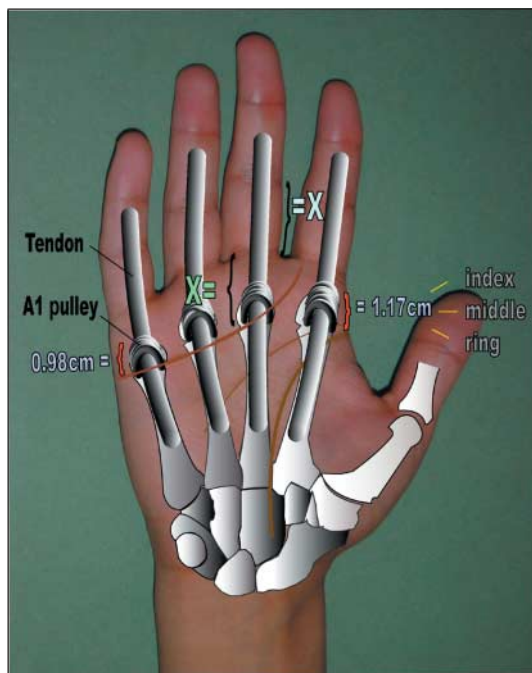


Fig 3 Lengths and landmarks of the A1 pulley

for each method of treatment to guide practitioners in the best care pathway for individual patients (fig 5).

**Non-steroidal anti-inflammatory drugs**

No evidence exists in the literature to suggest that non-steroidal anti-inflammatory drugs alone have any benefit other than temporary relief of pain in the palm.

**Splintage**

The aim of splintage is to reduce or remove tendon excursion through the A1 pulley for a long enough time to allow the synovitis around the pulley to resolve. Rodgers et al found that treating manual workers, who used repetitive hand movements, with splintage of the

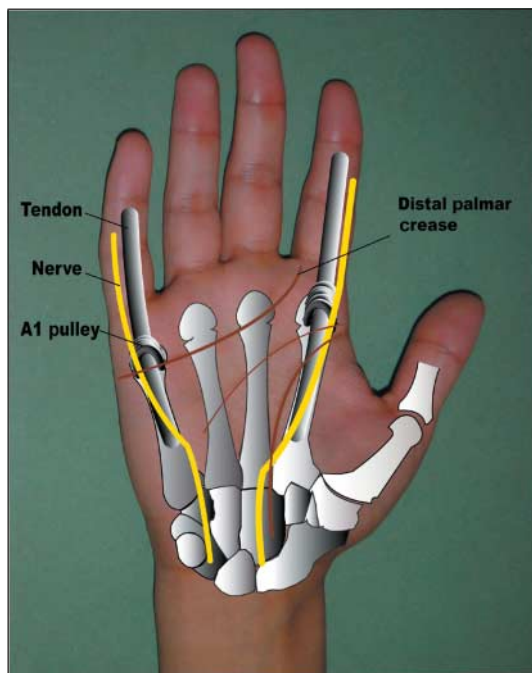


Fig 4 Proximity of border digital nerves to the A1 pulley

distal interphalangeal joint for six weeks resulted in resolution of symptoms in 53% of patients.<sup>17</sup> Patel et al successfully treated 70% of digits by means of splintage of the metacarpophalangeal joint but were successful in treating only 50% of thumbs in this way.<sup>18</sup> In both studies, those patients with more severe disease and longer duration of symptoms were less likely to benefit from splintage.

**Steroid injection**

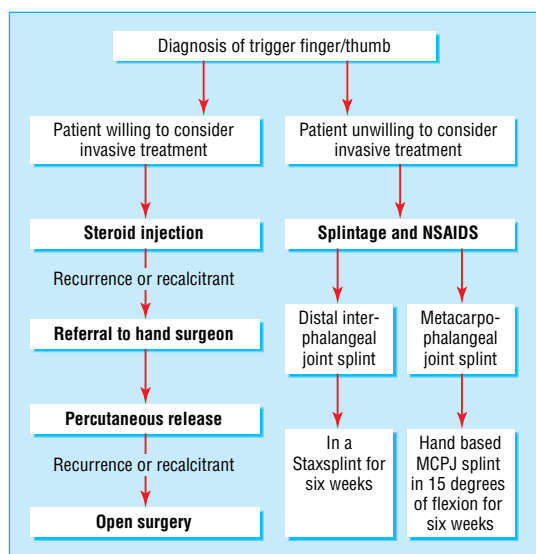
The injection of steroid into the flexor sheath was advocated as a method of treatment in 1950. Success rates between 38% and 93% have been reported.<sup>7 9 14</sup> Higher success rates are seen when injecting the thumb and in patients in whom a well defined nodule was palpable or whose symptoms had been present for less than six months. In patients in whom treatment fails or who have a recurrence of symptoms, a second steroid injection offers approximately half the efficacy of the first injection.<sup>9 14 w8</sup>

No studies have shown that the steroid must be placed within the sheath to be effective; on the contrary, Taras et al showed that steroid injected into the subcutaneous tissue around the A1 pulley gave better clinical outcomes than that injected into the sheath alone.<sup>9</sup> Injecting into the flexor sheath can prove difficult, as shown by Kamhin et al, who injected trigger fingers with dye and then went on to do an open A1 pulley release. They noted that only half of the injected fingers had dye within the sheath and that failure to introduce dye into the flexor sheath was higher in those patients with a longer duration of symptoms.<sup>19</sup> Complications include dermal or subcutaneous atrophy, skin hypopigmentation, infection, and in one rare case tendon rupture.<sup>w10</sup>

**Percutaneous trigger finger release**

Lorthioir first described percutaneous trigger finger release in 1958, and authors have since described its successful use in the outpatient department.<sup>20</sup> The technique involves placing the extended hand palm up with the metacarpophalangeal joints in a hyperextended position. The extended position facilitates access and ensures that the A2 pulley is held out to length and a maximal distance from the A1 pulley. The A1 pulley is stretched out and held stable in extension. The position also presents the pulley in a more superficial position, with the neurovascular bundles drawn medially and laterally away from the sheath. The tip of a 16/18 gauge needle is introduced through the skin on to the surface of the A1 pulley; the sharp tip of the needle is then used to incise the A1 pulley. Pope and Wolfe do not advise this method for release of a trigger index finger owing to proximity of the radial neurovascular bundle,<sup>21</sup> and Bain et al apply the same rationale (proximity of the ulnar digital nerve) for not using this technique for the little finger.<sup>22</sup> Cadaver studies, however, show that safe landmarks are available for percutaneous release for both little finger and index finger.<sup>15 16</sup>

Success rates are over 90%.<sup>23 w11 w12</sup> Complications are rare but include digital nerve injury, bowstringing (if release extends into the A2 pulley), infection, haematoma, and persistent pain.<sup>21-23 w11</sup>



**Fig 5** Suggested management algorithm for adult patients. MCPJ=metacarpophalangeal joint; NSAIDs=non-steroidal anti-inflammatory drugs

### Surgery

Surgery is done under local anaesthetic in the operating theatre. The A1 pulley is exposed through a palmar skin incision, and the pulley is divided under direct vision. Success rates vary from 60% to 97%. Complication rates can be high; complications include long term scar tenderness, inadequate release, nerve damage, and flexor sheath infection.<sup>24 25</sup>

### Treatment in children

Children represent a distinct group of patients not only epidemiologically but also for treatment. The thumb is involved in 90% of cases. Treatment has traditionally entailed surgical release, but this has become increasingly controversial as authors have presented good results with non-operative methods of treatment.<sup>5 w13- w15</sup>

Non-operative methods of treatment include physiotherapy administered by the parents with or without splintage. With physiotherapy alone, success rates of between 52% and 80% cure have been reported in patients whose thumb is not fixed in flexion or extension.<sup>w13 w14</sup> With splintage, reports give success rates of 77-89%. In both groups, success rates seem to be higher in younger children and decrease with age.<sup>w14 w15</sup>

Contributors: FDB and DNQ provided the initial idea and goals to be achieved by the paper, MJB and SA reviewed the literature, and SA was responsible for collecting data and drafting the manuscript. All authors contributed to interpreting and revising the data.

Funding: None.

Competing interests: None declared.

- 1 Strom L. Trigger finger in diabetes. *J Med Soc Nj* 1977;74:951-4.
- 2 Sampson SP, Badalamente MA, Hurst LC, Seidman J. Pathobiology of the human A1 pulley in trigger finger. *J Hand Surg (Am)* 1991;16:714-21.
- 3 Bonnici AV, Spencer JD. A survey of 'trigger finger' in adults. *J Hand Surg (Br)* 1988;13:202-3.
- 4 Verdon ME. Overuse syndromes of the hand and wrist. *Prim Care* 1996;23:305-19.
- 5 Ametewee K. Trigger thumb in adults after hyperextension injury. *Hand* 1983;15:103-5.
- 6 Fahey JJ, Bollinger JA. Trigger finger in adults and children. *J Bone Joint Surg* 1954;36:1200-18.
- 7 Anderson B, Kaye S. Treatment of flexor tenosynovitis of the hand with corticosteroids: a prospective study of the response to local injection. *Arch Intern Med* 1991;151:153-6.
- 8 Trezies AJ, Lyons AR, Fielding K, Davis TR. Is occupation an aetiological factor in the development of trigger finger? *J Hand Surg (Br)* 1998;23:539-40.
- 9 Clark DD, Ricker JH, MacCollum MS. The efficacy of local steroid injection in the treatment of stenosing tenosynovitis. *Plast Reconstr Surg* 1973;51:179-80.
- 10 Yosipovich G, Yosipovich Z, Karp M, Mukamel M. Trigger finger in young patients with insulin dependent diabetes. *J Rheumatol* 1990;17:951-2.
- 11 Chammas M, Bousquet P, Renard E, Poirier JL, Jaffiol C, Allieu Y. Dupuytren's disease, carpal tunnel syndrome, trigger finger and diabetes mellitus. *J Hand Surg (Am)* 1995;20:109-14.
- 12 Griggs SM, Weiss APC, Lane LB, Schwenker C, Akeiman E, Sacher K. Treatment of trigger finger in patients with diabetes mellitus. *J Hand Surg (Am)* 1995;20:787-9.
- 13 Stahl S, Kanter Y, Karnielli. Outcome of trigger finger treatment in diabetes. *J Diabetes Complicat* 1997;11:287-90.
- 14 Newport ML, Lane LB, Stuchin SA. Treatment of trigger finger by steroid injection. *J Hand Surg (Am)* 1990;15:748-50.
- 15 Wilhelmi BJ, Snyder N 4th, Verbesey JE, Ganchi PA, Lee WP. Trigger finger release with hand surface landmark ratios: an anatomic and clinical study. *Plast Reconstr Surg* 2001;108:908-15.
- 16 Wilhelmi BJ, Mowlavi A, Neumeister MW, Bueno R, Lee WP. Safe treatment of trigger finger with longitudinal and transverse landmarks: an anatomic study of the border fingers for percutaneous release. *Plast Reconstr Surg* 2003;112:993-9.
- 17 Rodgers JA, McCarthy JA, Tiedeman JJ. Functional distal interphalangeal joint splinting for trigger finger in labourers: a review and cadaver investigation. *Orthopedics* 1998;21:305-9.
- 18 Patel MR, Bassini L. Trigger fingers and thumb: when to splint, inject, or operate. *J Hand Surg (Am)* 1992;17:110-3.
- 19 Kamhin M, Engel J, Heim M. The fate of injected trigger fingers. *Hand* 1983;15:218-20.
- 20 Lorthioir J. Surgical treatment of trigger finger by a subcutaneous method. *J Bone Joint Surg (Am)* 1958;40:793-5.
- 21 Pope DF, Wolfe SW. Safety and efficacy of percutaneous trigger finger release. *J Hand Surg (Am)* 1995;20:280-3.
- 22 Bain GI, Turnbull J, Charles MN, Roth JH, Richards RS. Percutaneous A1 pulley release: a cadaveric study. *J Hand Surg (Am)* 1995;20:781-4.
- 23 Park MJ, Oh I, Ha KI. A1 pulley release of locked trigger digit by percutaneous technique. *J Hand Surg (Br)* 2004;29:502-5.
- 24 Thorpe AP. Results of surgery for trigger finger. *J Hand Surg (Br)* 1988;13:199-201.
- 25 Lapidus PW, Guidotti EP. Stenosing tenosynovitis of the wrist and fingers. *Clin Orthop* 1972;83:87-90.

## People who influenced my practice

Many doctors influence what we do by what they teach us. A few have disproportionate effects because they do not necessarily intend at that moment to instruct. This has happened to me on more than one occasion, and at least one affected my lifetime practice.

In the days when rigid bronchoscopy was current (the marvels of the flexible instrument had yet to be developed) the late Dr R Machray taught a method, ghastly to contemplate now, of local anaesthesia. He had just supervised my administration of cocaine to a conscious patient. The bronchoscopist, with whom he worked regularly, was Sir Clement Price Thomas, a doyen of both

thoracic surgery and of bronchoscopy, who was, I thought, unlikely to need support from a tyro anaesthetist.

I therefore left the operating room, but Dr Machray hustled me back with his never to be forgotten words, "Make encouraging noises, my boy, make encouraging noises." From this I learnt that, to be successful with regional anaesthesia in a conscious patient, it is important to maintain contact with the patient, and thus sustain their confidence.

That lesson is simple and widely practised today. But it was his phraseology that struck me and has never left me since.

John Lunn *retired academic anaesthetist, Chepstow*