

Piotr Rutkowski, Dorota Kiprian, Monika Dudzisz-Śledź, Tomasz Świtaj, Radosław Michalik, Mateusz Spałek, Katarzyna Kozak, Tomasz Mandat

Maria Skłodowska-Curie Institute — Oncology Centre, Warsaw, Poland

Management of brain metastases in melanoma

Address for correspondence:

Dr n. med. Monika Dudzisz-Śledź
 Klinika Nowotworów Tkanek Miękkich,
 Kości i Czerniaków
 Centrum Onkologii — Instytut
 im. Marii Skłodowskiej-Curie
 ul. W.K. Rentgena 5, 02–781 Warszawa
 Phone: 22 546 20 31
 e-mail: monika.dudzisz-sledz@coi.pl

Oncology in Clinical Practice
 2019, Vol. 15, No. 1, 51–61
 DOI: 10.5603/OCP.2018.0031
 Translation:

dr n. med. Monika Dudzisz-Śledź
 Copyright © 2019 Via Medica
 ISSN 2450–1654

ABSTRACT

Melanoma is the third malignant cancer after breast and lung cancer in terms of the incidence of brain metastases. Currently, brain metastases are diagnosed in asymptomatic patients using radiological examinations as a part of the follow-up or qualification for systemic treatment. Treatment of melanoma patients with brain metastases is currently one of the biggest challenges in caring for advanced melanoma patients. The aim of this paper is to provide a multidisciplinary guide to diagnostic and therapeutic management of this group of patients. Treatment of melanoma patients with brain metastases includes local treatment and/or systemic therapy as well as symptomatic treatment, depending on the clinical situation. Therapeutic decisions should be made in teams, which should include at least a clinical oncologist, neurosurgeon, and radiation oncologist.

Key words: melanoma, brain metastases, immunotherapy, neurosurgery, radiotherapy, targeted therapy

Oncol Clin Pract 2019; 15, 1: 51–61

Introduction

Melanoma is the third malignant cancer after breast and lung cancer in terms of the incidence of brain metastases. It is estimated that in the course of advanced melanoma, about 50–60% of patients develop cerebral metastases (about 75% of them are initial diagnosis multiple metastases, often asymptomatic). At the time of diagnosis of melanoma, cerebral metastases are present in 7% of patients. In 3% of patients with metastasis of melanoma in the brain the primary tumour cannot be found. It should be noted that only in 8–46% of melanoma patients metastases to the brain are found intravitaly; however, in the autopsy material they are detected in about 75% of cases. In the latest cancer staging system, the eighth edition according to the American Joint Committee on Cancer (AJCC), brain metastases are separated as a last category in stage IV — M1d [1]. The risk of metastasis to the brain increases with the disease stage [2]. Currently, there are no unequivocal prognostic factors in determining the risk of metastases to the central nervous system

(CNS) in melanoma patients. Nevertheless, it is known that certain factors are associated with greater risk of CNS metastases (primary focus in the head and neck area, elevated lactate dehydrogenase [LDH], primary tumour ulceration, mutations in the *BRAF*, *NRAS*, and *PTEN* genes) [3]. The presence of brain metastases worsens the prognosis. Brain metastases contribute to death in 20–50% of patients, and symptomatic tumours are the direct cause of death in about 90% of patients. Historically, median overall survival (OS) after diagnosis of brain metastasis was 5–7 months, in symptomatic patients undergoing whole brain radiotherapy (WBRT, currently rarely used) median OS was 2–5 months, and in patients undergoing surgical treatment or stereotactic radiotherapy (SRS, stereotactic radiosurgery)/radiosurgery was twice as long [4].

The aim of this paper is to present multidisciplinary guidelines on diagnostic and therapeutic management in melanoma patients with brain metastases. This is currently one of the biggest challenges in caring for advanced melanoma patients.

New therapies introduced to everyday clinical practice mean that the current way of proceeding in cases of metastatic melanoma has little in common with clinical practice from five years ago. Increasingly, brain metastases are diagnosed in the asymptomatic stage using routine magnetic resonance imaging (MRI) and/or computed tomography (CT) of the brain as part of the follow-up or staging evaluation before systemic treatment. Advanced SRS techniques have come to the forefront in local treatment. In the last five years, 10 new drugs have been registered in Europe for advanced melanoma treatment: vemurafenib, dabrafenib, trametinib, cobimetinib, binimetinib, encorafenib, ipilimumab, nivolumab, pembrolizumab, and talimogene laherparepvec (T-VEC). In Poland, as part of drug programs, seven novel drugs are currently available within therapeutic (drug) programs — vemurafenib, cobimetinib, dabrafenib, trametinib, ipilimumab, pembrolizumab, and nivolumab. The median OS in the whole group of patients with metastatic melanoma with the presence of *BRAF* mutation treated with pembrolizumab/nivolumab or combination therapy with BRAF inhibitors (BRAFi) and MEK inhibitors (MEKi), based on data from clinical trials, is now around two years (about four times longer than it was five years ago). Perhaps the best results could be achieved with the use of dual immunotherapy (anti-CTLA-4 and anti-PD-1, as indicated by preliminary results) or other combination therapies (e.g., T-VEC + pembrolizumab) or even combinations of BRAFi, MEKi, and anti-PD-1 or anti-PD-L1. It is obligatory to test the *BRAF* mutation in the fixed tissue in each case of confirmed brain metastases (if not done previously) [5, 6].

The basic and applicable rule in the situation of finding brain metastasis from melanoma should be management carried out under multidisciplinary teams whose members have experience in the diagnosis and treatment of melanoma. Such teams should include at least a neurosurgeon, radiation oncologist, and clinical oncologist [7].

Diagnosics

Signs and symptoms of brain metastases can be subtle and difficult to diagnose. They depend among others on the number, size, and location of metastases. Metastases are most often localised in the cerebrum, less often in the cerebellum (15%) and in the brainstem (5%). The most common symptoms include headaches, sometimes with accompanying nausea and/or vomiting, epileptic seizures, speech, comprehension, and vision disorders, numbness, and movement disorders. Occurrence of clinical symptoms related to brain metastases is associated with worse results of treatment.

In patients with melanoma in stage I and II, the risk of developing brain metastases is smaller than in patients with stage III and IV [8]. In younger patients, the risk of late development of brain metastases in the case of thicker primary lesions is higher [9]. Based on analysis of data from the S0008 retrospective large multicentre study, the risk of brain metastases in melanoma stage IIIB and IIIC was 15%; they were found mainly during the first three years after surgery [10]. The time from primary tumour treatment can be relatively long — up to 3.4 years (median) [11].

Therefore, in patients with melanoma stage III and IV it is important to detect the brain metastases in the absence of clinical symptoms by using imaging technics. Brain MRI should be the standard of care within the staging process in patients diagnosed with stage IV melanoma. In asymptomatic patients with stage IIIC melanoma and higher, brain CT or brain MRI should be considered [6]. In patients with signs and/or symptoms, including even minor intensities, indicating the possibility of the presence of lesions in the brain it is advisable to perform an MRI scan [12]. Magnetic resonance imaging is the most sensitive test to detect brain metastases and has advantages over contrast-enhanced CT. However, it is less available and more expensive. Therefore, in patients with brain metastases confirmed on CT, MRI can be considered as a complementary test to obtain information necessary to determine further management (number and/or location of lesions). This examination is necessary in the case of clinical symptoms and simultaneous absence of changes in contrast-enhanced CT scan [13]. It should be noted that melanoma brain metastases have a tendency to be multiple and are associated with a high risk of intratumoral bleeding [14].

Therapeutic management

Therapeutic management depends on the clinical situation and includes systemic treatment, local treatment (radiotherapy and/or surgery), or symptomatic treatment. In the treatment of melanoma brain metastases, in addition to clinical symptoms, the numerous parameters related to the disease and patient, such as number, size, and location of metastases, presence and control of extracranial disease, previous melanoma treatment and treatment results, presence of *BRAF* gene mutation, general condition of the patient, age, and co-morbidities and treatment, play an important role. In the symptomatic treatment of brain metastases anti-oedematous drugs are used, including primarily glucocorticoids, but also diuretics (loop diuretics, mannitol) and possibly hypertonic fluids. In the case of an epileptic seizure, anti-epileptic treatment should be

Table 1. Prognostic score RPA (recursive partitioning analysis, n = 1200) [15]

	Class I	Class II	Class III
KPS (points)	≥ 70	≥ 70	< 70
Primary lesion	Controlled	Active	Active
Age	< 65	< 65	Any
Extracranial disease	No	Yes	Yes
Incidence	15%	65%	20%
Overall survival (median)	7.1	4.2	2.3

KPS — Karnofsky Performance Status

Table 2. Prognostic assessment of the survival of melanoma patients with brain metastases — DS-GPA scale (diagnosis-specific Graded Prognostic Assessment) [16]

KPS (points)	< 70	70–80	90–100	
Number of brain metastases	> 3	2–3	1	
Points	0	1	2	
Based on the sum of the number of points awarded for KPS and the number of metastases:				
DS-GPA	0–1.0	1.5–2.5	2.5–3.0	3.5–4.0
Median overall survival (months)	3.4	4.7	8.8	13.2

KPS — Karnofsky Performance Status

initiated, remembering about interactions with other medicines used in the patient, including glucocorticoids.

Tables 1 and 2 summarise data on two prognostic scales in patients with brain metastases; the recursive partitioning analysis (RPA) scale refers to all neoplasms, and the DS-GPA (diagnosis-specific graded prognostic assessment) scale exclusively to melanoma patients. However, it must be remembered that these scales were developed before the introduction of new therapies systemic in the treatment of generalised melanoma.

The algorithm of management of melanoma patients with brain metastases is presented in Figure 1.

Local treatment of melanoma brain metastases

In the case of symptomatic melanoma brain metastases, the expected survival without treatment is 2–3 months, and only in 13% of patients OS will be longer than one year (more favourable prognosis in the group of patients below 65 years of age and with Karnofsky scale performance status [KPS] score > 70 points). The removal or irradiation of all metastatic foci has an impact on the prognosis. Leaving one of several lesions means that prognosis is the same as in the case of no treatment [16].

There are still no unambiguous prognostic factors of occurrence of melanoma brain metastases. It is known, however, that certain factors are associated with an increased risk. These include:

- primary focus within the head and neck;
- elevated LDH;
- ulceration of the primary tumour;
- molecular changes in *BRAF*, *NRAS*, and *PTEN* [3].

In patients with brain metastases, *BRAF* mutation occurs in 24–58% of cases, and *NRAS* mutation in 23% of cases.

Surgical treatment

Eligibility criteria for surgical treatment of melanoma brain metastases (EBM [evidence-based medicine], 2010, level 1);

- newly identified, single lesions up to four;
- the size of the lesion precluding SRS (above 3 cm);
- location of the lesion available surgically;
- symptomatic tumours:
 - causing neurological deficits and/or
 - symptoms of increased intracranial pressure due to its volume and / or with an accompanying haemorrhagic focus and/or secondary to obstruction of fluid pathways, leading to hydrocephalus (lesions located in the back bottom of the skull);
- KPS > 70, age < 65 years;
- progression after prior stereotactic radiotherapy.

The goals of surgical treatment

The goals of surgical treatment are as follows:

- histological verification;
- radical excision of all lesions, which has an impact on OS (no justification for performing a biopsy) — it is possible to use hybrid therapy in the case of multiple metastatic tumours — resection of large surgically available lesions in combination with SRS for smaller tumours located in deep brain structures;
- improvement or stabilisation of the neurological condition (occurrence of new neurological deficits shortens OS by four months);
- enabling further oncological treatment;
- resection of symptomatic radionecrotic lesions after SRS.

Irradiation

Stereotactic radiotherapy

Stereotactic radiation consists of delivering a biologically high radiation dose to a precisely defined small volume with a significant decrease of the dispersed

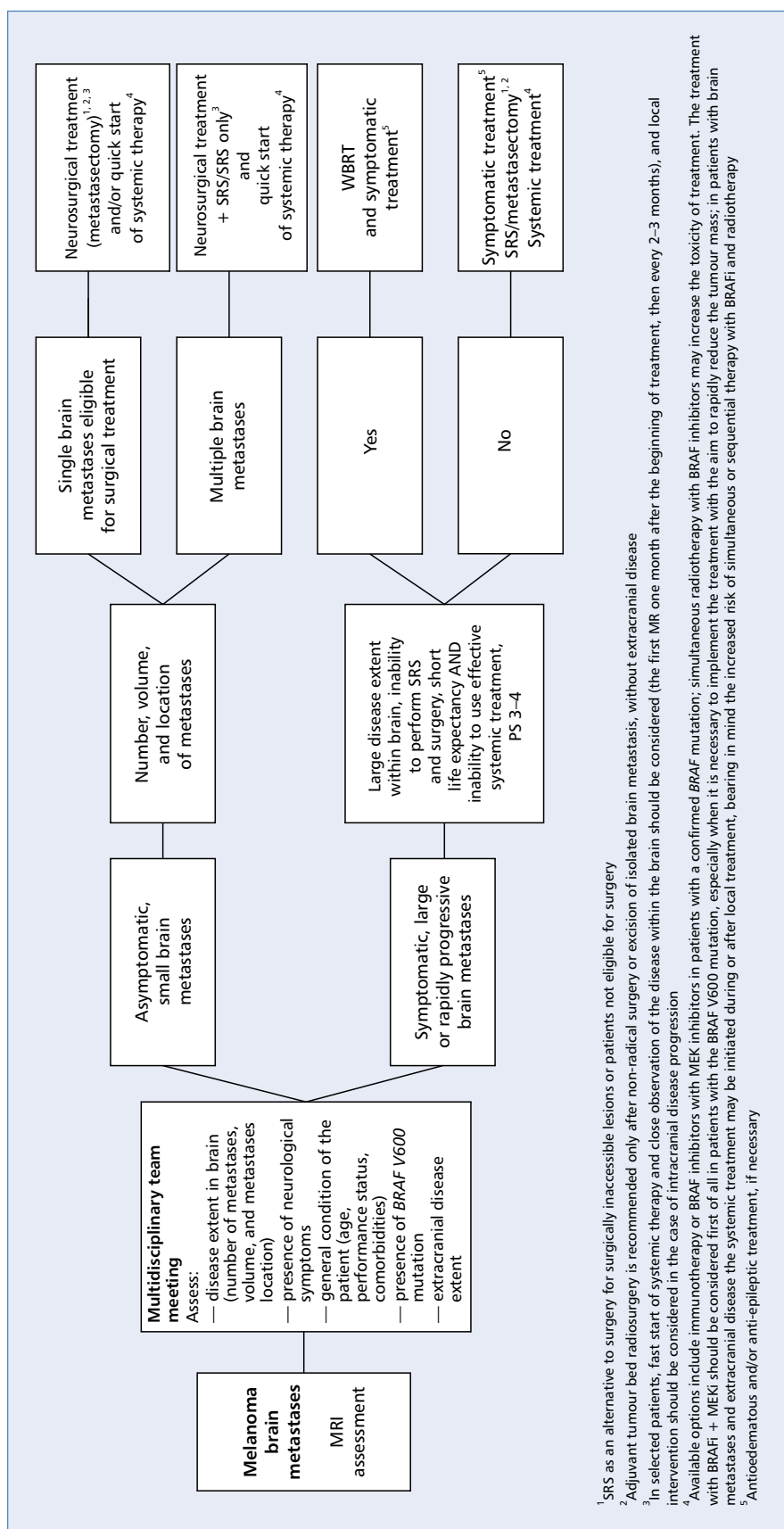


Figure 1. Algorithm for management of patients with melanoma brain metastases

dose outside the target volume. Treatment can be implemented with one fractional dose (radiosurgery) or 3–5 fractions (fractionated stereotactic radiation therapy). Irradiation can be done using several types of equipment dedicated to such treatment (GammaKnife, CyberKnife, EDGE) as well as conventional linear accelerators equipped with high-resolution multi-leaf collimators. The prescribed total dose and the selection of the fractionation regimen depends on the location of the metastatic lesions and their volume. In order to obtain high local efficacy of treatment the aim should be to give the total dose, the value of which, after conversion into a biologically equivalent dose (BED), will be higher than 100 Gy. SRS efficacy in the treatment of small melanoma metastases to the brain has been confirmed in many studies and is similar to that obtained through metastasectomy. Correct qualification of patients for treatment is essential and should be done in multidisciplinary teams.

Qualification for SRS:

- general condition of the patient 0–2 in the scale of the World Health Organisation (WHO);
- single metastasis with a diameter < 3 cm;
- number of metastases > 1, when the total volume of irradiated healthy brain with a dose of 12 Gy does not exceed 10 cm³;
- no extracranial progression or situation when potentially effective systemic treatment is available;
- irradiation of the post-operative bed [17, 18];
- possible repeated local irradiation in the case of progression;
- life expectancy > 6 months.

Recently, the indications for SRS have been extended, which was originally reserved for patients with one to three brain metastases [22–24]. Optimally the number of lesions should not be greater than five, none of which is more than 3 cm in diameter; however, cautious qualification of patients who do not meet such criteria is possible [19]. Currently, the number of metastases is of less importance, and the limitation to stereotactic irradiation has become the volume of all lesions and the volume of the brain that receives the total dose of 12 Gy [25, 26]. It has been proven that the volume of healthy tissue above 10 cm³ receiving a dose of 12 Gy is associated with a high risk of radionecrosis. In such clinical situations, reducing the therapeutic dose or disqualifying the patient from stereotactic radiotherapy should be considered, as well as qualifying the patient to WBRT, especially in the presence of numerous metastases. With appropriate qualifications local efficacy of SRS (no progression in irradiated volume) can be achieved in 90–95% of melanoma patients [20, 21]. In addition, in half of patients a radiologically significant tumour response has been observed [20]. The local efficacy is closely related to the lesion location and its size.

Whole brain radiotherapy

Melanoma is considered to be a tumour resistant to radiation and sensitive only to higher fractional doses. The fractionation regimens used at WBRT (5 × 4 Gy, 10 × 3 Gy) do not provide an adequate biological dose allowing long-term control of the disease within the CNS. Irradiation of the whole the brain is associated with neurological toxicity. Cognitive function impairment is mainly responsible for the deterioration of the quality of the patient's life [27, 28].

Whole brain radiotherapy should be reserved exclusively for patients:

- with a predicted short survival time;
- in poor condition: WHO 3–4;
- disqualified from surgery and SRS;
- with a large volume of neoplastic lesions within the CNS;
- with their rapid progression and lack of possibility to conduct effective systemic treatment;
- with leptomeningeal metastases, in good general condition.

Patients in very poor general condition (performance status WHO 4) with symptoms of brain oedema that do not yield to anti-oedematous treatment should be disqualified from any form of radiotherapy. Proceeding the choice is to provide symptomatic treatment, such as: effective anti-oedema treatment and antiepileptic, as well as fighting the symptoms often accompanying progression within the CNS.

Systemic treatment

Systemic treatment is the basis of the management of patients with disseminated, including patients with brain metastases. As in the case of molecular targeted therapy (BRAFi and MEKi), the use of immunotherapy, including anti-CTLA4 and anti-PD1 drugs, significantly improves the prognosis of melanoma patients with metastases to the CNS. More and more often long-term remissions in patients who respond to immunotherapy are observed [29]. Depending on previously used treatment, the presence of *V600 BRAF* mutation, and the patient's condition and his clinical situation, the appropriate systemic therapy should be implemented, in the majority of cases supplemented by local treatment. In a situation of a few small metastases in the CNS exclusive systemic treatment remains an option.

Molecular targeted therapy

The efficacy of molecularly targeted drugs (BRAFi/MEKi) in patients with metastatic skin melanoma with brain metastases has been proven in

several prospective clinical trials. In the first clinical trials conducted exclusively in this group of patients the effectiveness of BRAFi monotherapy was assessed. In the largest of them, including as many as 172 patients with asymptomatic metastases, the efficacy of dabrafenib (study phase II BREAK-MB) was assessed. The patients participating in the study were divided into two groups based on the previous local treatment due to brain metastases (without prior local treatment vs. progression after prior local treatment). The intracranial response rates were 39.2% and 30.8%, respectively. The median OS in both groups was over eight months [2]. In a similar clinical trial on the use of vemurafenib in 146 patients with skin melanoma with brain metastases (phase II trial) the intracranial response rate was 18% regardless of previous local treatment. Median OS was about nine months [30]. If we take into account the response assessment done by an independent committee (IRC, independent review committee), the rates of intracranial responses in both these studies were very similar (around 18%). In both studies a high rate of disease control has been shown (about 70–80%). This is due to the fact that the reduction of metastatic lesions in the brain was observed in the majority of patients, but only in some of them were the criteria of partial response met.

A difficult clinical situation is the occurrence of symptomatic brain metastases. This stage of disease is associated with a particularly poor prognosis (median OS 3–4 months). The only clinical trial including only this group of patients concerned the use vemurafenib in monotherapy [31]. This was a small study, including 24 patients not eligible for neurosurgery, after previous treatment due to brain metastases, and requiring the use of glucocorticoids to control symptoms. The percentage of intracranial responses was 16%, and the median OS was 5.3 months. During treatment, a reduction in pain symptoms was observed, improvement of patients' performance status, and reduction of the demand for glucocorticoids. Unfortunately, the treatment effect was short-term, and the disease progressed quickly.

Improvement in the results of targeted treatment has been achieved with combination therapy with BRAFi and MEKi. The only prospective clinical trial evaluating the activity of this therapy in patients with brain metastases is the phase II COMBI-MB study with dabrafenib and trametinib [32]. A total of 125 patients with performance status 0–2 according to the Eastern Cooperative Oncology Group (ECOG) with or without prior local treatment due to brain metastases were enrolled. Intracranial response rate was 56–59% regardless of the previous local treatment and presence of symptomatic metastases. Longer duration of response was observed in patients with asymptomatic brain metastases. The median duration of the response was, however, considerably shorter than that observed in phase III clinical

trials without the participation of patients with brain metastases (about 6 months vs. 12–14 months) [33–35]. However, no significant differences in treatment tolerance were reported. The most common were fever and gastrointestinal disorders.

The results of the studies mentioned above confirm the activity of BRAFi/MEKi in patients with brain metastases. The response to treatment appears quickly, and the reduction in tumour lesions occurs in the majority of patients. This is not only important for improvement of OS in this group of patients with poor prognosis, but also to improve the quality of life. In particular, this applies to patients with symptomatic brain metastases. Unfortunately, the above data also indicate a short-term therapeutic effect of targeted treatment. Resistance appears faster than in patients without brain metastases. From here, attempts are being made to combine BRAFi/MEKi with other kinase inhibitors or immunotherapy to improve treatment outcomes. Results of studies with BRAFi/MEKi in melanoma patients with brain metastases are presented in Table 3.

Radiotherapy in combination with targeted therapy

High initial BRAFi/MEKi activity in patients with melanoma with brain metastases has slightly changed the approach to the use of radiotherapy. Increasingly used, SRS gives a high rate of local disease control. However, it has not been proven to protect against further disease spreading within the CNS. Therefore, with the exception of patients with isolated metastases to the brain, SRS has little effect on the OS. Therefore, radiotherapy is often used only during BRAFi/MEKi treatment. Data on the purposefulness of combining medicines from the BRAFi group with simultaneous irradiation are contradictory. On the one hand, the potential benefits of such a strategy in the form of sensitisation of melanoma cells to radiotherapy after BRAFi administration has been emphasised, as described in *in vitro* studies [36]. On the other hand, the radiation-sensitising BRAFi action can lead to increased side effects, which has been confirmed by several described case studies of significant skin toxicity during simultaneous use of a combination of irradiation with these drugs, also WBRT. So far no similar radiosensitising effect has been described while using BRAFi with MEKi. There is no clear evidence of increased risk of neurotoxicity, haemorrhage, or radiation necrosis for the combination of targeted treatment with radiotherapy [37–39]. Combination of targeted therapy with radiosurgery to the CNS area gives fewer side effects compared to conventional radiotherapy. In the case of conventional radiotherapy the most common side effect is skin toxicity (more severe when using vemurafenib) [40].

Table 3. Trials dedicated to the evaluation of the efficacy of molecularly targeted therapies in the treatment of melanoma patients with brain metastases

Study	Patients' characteristics	Number of patients	PFS (median, months)	OS (median, months)
II phase study [30] (NCT01378975) vemurafenib	Previously untreated brain metastases	90	3.7	8.9
	Previously treated brain metastases	56	4.0	9.6
Pilot study [31] (NCT01253564) vemurafenib	Previously treated, symptomatic brain metastases	24	3.9	5.3
II phase study BREAK-MB [2] (NCT01266967) dabrafenib	Previously untreated brain metastases	89	~4 ^a	~8 ^a
	Progression after previous local treatment	83	~4 ^a	~8 ^a
II phase study COMBI-MB [32] (NCT02039947) dabrafenib + trametinib	Asymptomatic brain metastases without previous local treatment ECOG PS 0–1	76	5.6	0.8
	Asymptomatic brain metastases after previous local treatment ECOG PS 0–1	16	7.2	24.3
	Asymptomatic brain metastases with/without previous local treatment ECOG PS 0–1	16	4.2	10.1
	Symptomatic brain metastases with/without previous local treatment ECOG PS 0–2	17	5.5	11.5

^aMedian for patients with *BRAF V600E* mutation

PFS — progression-free survival; OS — overall survival; ECOG PS — Eastern Cooperative Oncology Group performance status

Irradiation during targeted therapy increases the risk of grade 2 and 3 dermatitis. Its severity depends on the dose of irradiation; therefore, doses ≥ 4 Gy are not recommended in the case of conventional radiotherapy. It is currently recommended that use of BRAFi and MEKi be stopped at least three days before the beginning of radiotherapy and taking the drugs be resumed at the earliest three days after radiotherapy completion [37]. The exception is SRS OUN, in which case a sufficient break in the use of BRAFi and MEKi before and after radiotherapy is one day.

Immunotherapy

Immunotherapy is the main option of treatment in patients with melanoma with CNS metastases in the absence of the *V600* mutation of the *BRAF* gene. In patients with the *BRAF* mutation the decision regarding the choice of using immunotherapy or treatment with BRAFi and MEKi depends on the clinical situation.

In an open-label, phase II clinical trial with ipilimumab (NCT00623766) the highest response rates were observed in asymptomatic patients who did not receive steroids. Based on IRR criteria (immune related response), median intracranial progression-free

survival (PFS) was 1.9 months in the asymptomatic group vs. 1.2 months in a group requiring glucocorticosteroids due to clinical symptoms of brain metastases, and OS, respectively, 7.0 vs. 3.7 months [41]. In the CheckMate 204 study (NCT02320058) with nivolumab and ipilimumab which enrolled patients with melanoma and asymptomatic brain metastases (0.5–3.0 cm) who were not receiving steroids, the primary endpoint was the intracranial clinical benefit (combined endpoint including complete response [CR], partial response [PR], and stable disease [SD] for over six months). The intracranial objective response rate (ORR) was 55% and was CR was 21%. Extracranial responses were similar to those observed in the CNS, and the PFS rate at six months of treatment was 67%. The results of this study confirm that, as in the case of treatment of extracranial disease, in patients with brain metastases it is possible to achieve a similar response to treatment of lesions in the CNS [41]. Similarly, in the Australian ABC study (NCT02374242), in which the efficacy of nivolumab versus nivolumab plus ipilimumab in melanoma patients with brain metastases ($n = 79$) was investigated, the efficacy of immunotherapy was demonstrated, including the advantage of dual therapy in melanoma patients with asymptomatic brain metastases. In this study, the patients were assigned to three cohorts: cohort A ($n = 36$,

Table 4. Studies on the effectiveness of immunotherapy in the treatment of patients with melanoma with CNS metastases

Treatment	Patients	Patients' characteristics	IC DCR	IC ORR	IC DOR (months)	mPFS (months)	mOS (months)
IPI: CA184-042 [41]	51 (A)	Asymptomatic	24%	16%	–	1.4	7.0
	21 (B)	Symptomatic	10%	5%	–	1.2	3.7
IPI + fotemustine: NIBIT-M1 [43]	20	Asymptomatic	50%	40%	30.3	4.5	12.7
Pembrolizumab: (NCT02085070) [44]	18	Untreated or progressive brain metastases	44%	22%	–	–	NR
NIVO: ABC; CA209-170 [42] (NCT02374242)	27 (B)	Asymptomatic brain metastases without previous local treatment	20%	20%	NR	2.5 (intracranial)	18.5
	16 (C)	Previously treated or symptomatic	19%	6%	NR	2.3 (intracranial)	5.1
NIVO + IPI: ABC; CA209-170 [42]	36 (A)	Asymptomatic brain metastases without previous local treatment	57%	46%	NR	NR	NR
NIVO + IPI: CheckMate 204 [45] (NCT02320058)	75	Asymptomatic, previously treated, ≤ brain metastases	60%	55%	NR	NR	–

IPI — ipilimumab; NIVO — nivolumab; NR — not reached; IC DCR — disease control rate, intracranial disease; IC DOR — duration of response, intracranial disease; IC ORR — objective response rate, intracranial disease; mPFS — median progression-free survival; mOS — median overall survival

a group of asymptomatic patients without local treatment due to brain metastases, receiving ipilimumab with nivolumab); cohort B (n = 27, group of asymptomatic patients without local treatment due to metastases to the CNS, receiving nivolumab); and cohort C (n = 16, patients after local treatment due to brain metastases failure and symptomatic patients with brain metastases and patients with leptomeningeal disease, receiving nivolumab). Complete responses to treatment were observed in 17% of patients in cohort A, 12% in cohort B, and none in cohort C [42]. In the CheckMate 204 study and in the ABC study, grade 3 and 4 treatment-related adverse events in patients receiving dual therapy occurred in 52% and 54% of patients, respectively.

In the situation of the availability of combination therapy with anti-PD-1 plus anti-CTLA-4 (nivolumab with ipilimumab) and in the case of good performance status of the patient this combination is the treatment of choice for asymptomatic melanoma patients with brain metastases.

The results of clinical studies with immunotherapy in patients with melanoma brain metastases are summarised in Table 4.

Combination of radiotherapy with immunotherapy

There are more and more reports related to beneficial effect of combining radiotherapy with immunotherapy. The works published so far have shown

an increased incidence of abscopal effect (response of untreated lesions to local treatment of other lesions) after adding radiotherapy to immunotherapy [46]. This is explained by the local stimulation of the immune system and the enhancement of the antigenic effect, where dendritic cells probably play a large role. There are many clinical trials ongoing in which radiotherapy and immunotherapy are combined with each other. There are no contraindications for combining SRS/WBRT with immunotherapy; the decision should be taken at the multidisciplinary meeting individually for each patient. Attention should be paid to the accompanying radiotherapy prophylactic anti-oedema treatment in the form of high doses of glucocorticoids that can reduce the efficacy of immunotherapy. According to current recommendations, indications for glucocorticoids use as part of anti-oedema treatment during SRS are significantly limited.

It seems that combining immunotherapy or molecularly targeted therapy with SRS is generally well tolerated, as demonstrated in the previously conducted clinical trials and analysis. In 2016, the results of the retrospective analysis done in the subgroup of patients participating in two prospective studies with nivolumab for unresectable or metastatic disease were published [47]. Twenty-six patients treated due to melanoma and undergoing SRS due to brain metastases were included in this analysis. The analysis included patients in whom brain metastases were diagnosed and treated with SRS within six months after treatment with nivolumab (before, after, or during immunotherapy). In total 73 lesions

in the CNS were identified in these patients. The primary endpoint of the analysis was treatment tolerability, and secondary endpoints were intracranial disease control and extracranial disease control as well as OS. Most of the metastases were treated using single-fraction radiosurgery, and only 12 lesions in CNS were subjected to fractionated SRS. Grade 2 headaches that resolved after using steroids were observed in one patient. No other neurological complications related to the treatment were observed. In the case of eight lesions in the CNS (11%) the failure of treatment in the form of an increase of lesion volume of by at least 20% was observed. Local control rates after six and 12 months were, respectively, 91% and 85%. The median OS was 12.0 months from the beginning of treatment with nivolumab and 11.8 months from SRS.

In 2017, a systematic review was published dedicated to the assessment of the tolerability of combination treatment with immunotherapy or targeted therapy and SRS. In the overview six retrospective studies and two case studies of patients treated with SRS and ipilimumab were included. Based on the analysis of these data, combination therapy with ipilimumab and SRS for intracranial lesions can be considered as a safe method of treatment [48].

New systemic therapies for melanoma brain metastases

In relation to often short-term or insufficient response to systemic treatment of melanoma in patients with metastases to the CNS, with the use of immunotherapy or molecularly targeted therapy, there are currently attempts to combine BRAFi/MEKi with other kinase inhibitors or immunotherapy to improve the treatment results. An example of such a study is the TRIDeNT study with the use of nivolumab in combination with dabrafenib and/or trametinib in melanoma patients with metastases to the CNS and patients with melanoma with leptomeningeal metastases (NCT02910700) [49].

Surveillance of patients after local treatment of brain metastases and treatment options after progression

Patients undergoing surgical treatment or SRS should be monitored with magnetic resonance imaging of the brain to enable early detection of disease progression. The first MRI scan should be done within one month of surgery/SRS and then every 2–3 months. The imaging test results should be interpreted cautiously, especially in patients undergoing immunotherapy due to the possibility of pseudoprogression and changes after

treatment, which can be difficult to distinguish from disease progression. The occurrence of brain metastases from melanoma increases the risk of new metastases in the CNS; therefore, in patients after treatment due to brain metastases from melanoma more frequent brain MRIs are recommended [6]. In about 50% of patients new metastases or progression within previously treated lesions will be detected (recurrence in the lodge, progression after SRS/WBRT) [50]. However, these are not situations disqualifying from further therapy; it is usually possible to use one of the rescue methods of local treatment (surgery, SRS, WBRT) after discussing the patient's case at a multidisciplinary meeting [51–53]. After confirming the progression of lesions in the CNS after SRS or radiotherapy, while retaining the previously described eligibility criteria for neurosurgical treatment, surgical treatment remains the therapy of choice. It can be difficult to distinguish, despite the introduction of modern neuroimaging techniques, whether observed progression is secondary to active cancer or secondary to radionecrosis. In doubtful situations, the treatment of choice should be resection of the lesion because, as well as oncological indications, the removal of necrotic tissues has an antioedematous impact.

Leptomeningeal metastases

The prognosis in this group of patients is bad; survival usually does not exceed a few weeks. Data on the effectiveness of novel systemic treatment in the case of meningitis are limited, and there are no evidence-based treatment standards. Recently published results of retrospective analyses indicate that molecular-targeted therapy and immunotherapy may improve the prognosis in these patients [54, 55]. A phase I clinical trial is being conducted (NCT03025256) with intravenous and intrathecal nivolumab in patients with leptomeningeal disease.

Data on the systemic use of interleukin 2 are encouraging: 1-, 2-, and 5-year survival rates in 43 patients, were 36%, 26%, and 13%, respectively. However, due to the high toxicity of interleukin 2 this is not considered to be the standard of management [56].

WBRT including meninges up to C2 level is a palliative treatment and should be used only in the selected group of patients (good performance status, active systemic treatment).

Summary

The main and valid principle in the situation of brain metastases from melanoma should be multidisciplinary management within the team that includes at least

a neurosurgeon, a radiation oncologist, and a clinical oncologist experienced in melanoma and brain metastases from melanoma treatment. There are no unambiguous risk factors for brain metastases in melanoma patients. The diagnosis of brain metastases is associated with poor prognosis; metastasis to the brain are the cause of death in 20–50% of patients, and symptomatic tumours are the direct cause of death in about 90% of patients. Historical data indicated the median OS after the diagnosis of brain metastases was between five and seven months. Currently, more brain metastases are diagnosed at the asymptomatic stage using routine brain imaging as part of the patient's follow-up and staging evaluation before systemic treatment. Treatment of melanoma patients with brain metastases includes local treatment and/or systemic therapy as well as symptomatic treatment depending on the clinical situation. Advanced SRS techniques have come to the forefront in local treatment. In the last five years 10 new drugs have been registered in Europe for advanced melanoma treatment. Thanks to the introduction of modern systemic therapies the median OS based on clinical trial data has significantly increased. In the situation of the availability of dual anti-PD-1 and anti-CTLA-4 (nivolumab with ipilimumab) blockade and good patient condition, this is the treatment of choice for asymptomatic patients with melanoma brain metastases. In the presence of the *BRAF* mutation and asymptomatic brain metastases from melanoma BRAFi and MEKi systemic treatment can be the first-choice treatment.

Summary of management of patients with brain metastases from melanoma is shown in Figure 1.

References

- Gershenwald JE, Scolyer RA, Hess KR, et al. Melanoma Staging: American Joint Committee on Cancer (AJCC) 8th Edition and Beyond. *Ann Surg Oncol*. 2018; 25(8): 2105–2110, doi: [10.1245/s10434-018-6513-7](https://doi.org/10.1245/s10434-018-6513-7).
- Long GV, Trefzer U, Davies MA, et al. Dabrafenib in patients with Val-600Glu or Val600Lys BRAF-mutant melanoma metastatic to the brain (BREAK-MB): a multicentre, open-label, phase 2 trial. *Lancet Oncol*. 2012; 13(11): 1087–1095, doi: [10.1016/S1470-2045\(12\)70431-X](https://doi.org/10.1016/S1470-2045(12)70431-X), indexed in Pubmed: 23051966.
- Ramakrishna N, Margolin KA. Multidisciplinary approach to brain metastasis from melanoma; local therapies for central nervous system metastases. *Am Soc Clin Oncol Educ Book*. 2013: 399–403, doi: [10.1200/EdBook_AM.2013.33.399](https://doi.org/10.1200/EdBook_AM.2013.33.399), indexed in Pubmed: 23714560.
- Davies MA, Liu P, McIntyre S, et al. Prognostic factors for survival in melanoma patients with brain metastases. *Cancer*. 2011; 117(8): 1687–1696, doi: [10.1002/ncr.25634](https://doi.org/10.1002/ncr.25634), indexed in Pubmed: 20960525.
- Rutkowski P, Wysocki P, Nasierowska-Guttmejer A, et al. Cutaneous melanomas. *Oncol Clin Pract*. 2017; 13: 241–258, doi: [10.5603/OCP.2017.0038](https://doi.org/10.5603/OCP.2017.0038).
- National Comprehensive Cancer Network (NCCN). Melanoma. NCCN Guidelines. 2018; 3: 1–102.
- Tawbi HA, Boutros C, Kok D, et al. New era in the management of melanoma brain metastases. *Am Soc Clin Oncol Educ Book*. 2018(38): 741–750, doi: [10.1200/EDBK_200819](https://doi.org/10.1200/EDBK_200819), indexed in Pubmed: 30231345.
- Zakrzewski J, Geraghty LN, Rose AE, et al. Clinical variables and primary tumor characteristics predictive of the development of melanoma brain metastases and post-brain metastases survival. *Cancer*. 2011; 117(8): 1711–1720, doi: [10.1002/ncr.25643](https://doi.org/10.1002/ncr.25643), indexed in Pubmed: 21472718.
- Osella-Abate S, Ribero S, Sanlorenzo M, et al. Risk factors related to late metastases in 1,372 melanoma patients disease free more than 10 years. *Int J Cancer*. 2015; 136(10): 2453–2457, doi: [10.1002/ijc.29281](https://doi.org/10.1002/ijc.29281), indexed in Pubmed: 25331444.
- Samlowski WE, Moon J, Witter M, et al. High frequency of brain metastases after adjuvant therapy for high-risk melanoma. *Cancer Med*. 2017; 6(11): 2576–2585, doi: [10.1002/cam4.1223](https://doi.org/10.1002/cam4.1223), indexed in Pubmed: 28994212.
- Salvati M, Cervoni L, Caruso R, et al. Solitary cerebral metastasis from melanoma: value of the 'en bloc' resection. *Clin Neurol Neurosurg*. 1996; 98(1): 12–14, indexed in Pubmed: 8681471.
- Fink KR, Fink JR. Imaging of brain metastases. *Surg Neurol Int*. 2013; 4(Suppl 4): 209–219, doi: [10.4103/2152-7806.111298](https://doi.org/10.4103/2152-7806.111298), indexed in Pubmed: 23717792.
- Premkumar A, Marincola F, Taubenberger J, et al. Metastatic melanoma: correlation of MRI characteristics and histopathology. *J Magn Reson Imaging*. 1996; 6(1): 190–194, indexed in Pubmed: 8851427.
- Nayak L, Lee EQ, Wen PY. Epidemiology of brain metastases. *Curr Oncol Rep*. 2012; 14(1): 48–54, doi: [10.1007/s11912-011-0203-y](https://doi.org/10.1007/s11912-011-0203-y), indexed in Pubmed: 22012633.
- Gaspar L, Scott C, Rotman M, et al. Recursive partitioning analysis (RPA) of prognostic factors in three Radiation Therapy Oncology Group (RTOG) brain metastases trials. *Int J Radiat Oncol Biol Phys*. 1997; 37(4): 745–751, indexed in Pubmed: 9128946.
- Sperduto PW, Kased N, Roberge D, et al. Summary report on the graded prognostic assessment: an accurate and facile diagnosis-specific tool to estimate survival for patients with brain metastases. *J Clin Oncol*. 2012; 30(4): 419–425, doi: [10.1200/JCO.2011.38.0527](https://doi.org/10.1200/JCO.2011.38.0527), indexed in Pubmed: 22203767.
- Ling DC, Vargo JA, Wegner RE, et al. Postoperative stereotactic radiosurgery to the resection cavity for large brain metastases: clinical outcomes, predictors of intracranial failure, and implications for optimal patient selection. *Neurosurgery*. 2015; 76(2): 150–156, doi: [10.1227/NEU.0000000000000584](https://doi.org/10.1227/NEU.0000000000000584), indexed in Pubmed: 25549189.
- Choi CYH, Chang SD, Gibbs IC, et al. Stereotactic radiosurgery of the postoperative resection cavity for brain metastases: prospective evaluation of target margin on tumor control. *Int J Radiat Oncol Biol Phys*. 2012; 84(2): 336–342, doi: [10.1016/j.ijrobp.2011.12.009](https://doi.org/10.1016/j.ijrobp.2011.12.009), indexed in Pubmed: 22652105.
- Minniti G, Paolini S, D'Andrea G, et al. Outcomes of postoperative stereotactic radiosurgery to the resection cavity versus stereotactic radiosurgery alone for melanoma brain metastases. *J Neurooncol*. 2017; 132(3): 455–462, doi: [10.1007/s11060-017-2394-z](https://doi.org/10.1007/s11060-017-2394-z), indexed in Pubmed: 28260130.
- Mori Y, Kondziolka D, Flickinger JC, et al. Stereotactic radiosurgery for cerebral metastatic melanoma: factors affecting local disease control and survival. *Int J Radiat Oncol Biol Phys*. 1998; 42(3): 581–589, indexed in Pubmed: 9806518.
- Yu C, Chen JCT, Apuzzo MLJ, et al. Metastatic melanoma to the brain: prognostic factors after gamma knife radiosurgery. *Int J Radiat Oncol Biol Phys*. 2002; 52(5): 1277–1287, indexed in Pubmed: 11955740.
- Salvetti DJ, Nagaraja TG, McNeill IT, et al. Gamma knife surgery for the treatment of 5 to 15 metastases to the brain: clinical article. *J Neurosurg*. 2013; 118(6): 1250–1257, doi: [10.3171/2013.2.JNS121213](https://doi.org/10.3171/2013.2.JNS121213), indexed in Pubmed: 23540265.
- Rava P, Leonard K, Sioshansi S, et al. Survival among patients with 10 or more brain metastases treated with stereotactic radiosurgery. *J Neurosurg*. 2013; 119(2): 457–462, doi: [10.3171/2013.4.JNS121751](https://doi.org/10.3171/2013.4.JNS121751), indexed in Pubmed: 23662828.
- Yamamoto M, Serizawa T, Higuchi Y, et al. Stereotactic radiosurgery for patients with multiple brain metastases (JLKG0901): a multi-institutional prospective observational study. *Lancet Oncol*. 2014; 15(4): 387–395, doi: [10.1016/S1470-2045\(14\)70061-0](https://doi.org/10.1016/S1470-2045(14)70061-0), indexed in Pubmed: 24621620.
- Skeie BS, Skeie GO, Enger PØ, et al. Gamma knife surgery in brain melanomas: absence of extracranial metastases and tumor volume strongest indicators of prolonged survival. *World Neurosurg*. 2011; 75(5–6): 684–91; discussion 598, doi: [10.1016/j.wneu.2010.12.054](https://doi.org/10.1016/j.wneu.2010.12.054), indexed in Pubmed: 21704936.
- Hunter GK, Suh JH, Reuther AM, et al. Treatment of five or more brain metastases with stereotactic radiosurgery. *Int J Radiat Oncol Biol Phys*. 2012; 83(5): 1394–1398, doi: [10.1016/j.ijrobp.2011.10.026](https://doi.org/10.1016/j.ijrobp.2011.10.026), indexed in Pubmed: 22209150.
- Li J, Bentzen SM, Li J, et al. Relationship between neurocognitive function and quality of life after whole-brain radiotherapy in patients with brain metastasis. *Int J Radiat Oncol Biol Phys*. 2008; 71(1): 64–70, doi: [10.1016/j.ijrobp.2007.09.059](https://doi.org/10.1016/j.ijrobp.2007.09.059), indexed in Pubmed: 18406884.
- Welzel G, Fleckenstein K, Schaefer J, et al. Memory function before and after whole brain radiotherapy in patients with and without brain metastases. *Int J Radiat Oncol Biol Phys*. 2008; 72(5): 1311–1318, doi: [10.1016/j.ijrobp.2008.03.009](https://doi.org/10.1016/j.ijrobp.2008.03.009), indexed in Pubmed: 18448270.

29. Slott S, Chen YA, Zhao X, et al. Improved survival of patients with melanoma brain metastases in the era of targeted BRAF and immune checkpoint therapies. *Cancer*. 2018; 124(2): 297–305, doi: [10.1002/ncr.30946](https://doi.org/10.1002/ncr.30946), indexed in Pubmed: [29023643](https://pubmed.ncbi.nlm.nih.gov/29023643/).
30. McArthur GA, Maio M, Arance A, et al. Vemurafenib in metastatic melanoma patients with brain metastases: an open-label, single-arm, phase 2, multicentre study. *Ann Oncol*. 2017; 28(3): 634–641, doi: [10.1093/annonc/mdw641](https://doi.org/10.1093/annonc/mdw641), indexed in Pubmed: [27993793](https://pubmed.ncbi.nlm.nih.gov/27993793/).
31. Dummer R, Goldinger SM, Turttschi CP, et al. Vemurafenib in patients with BRAF(V600) mutation-positive melanoma with symptomatic brain metastases: final results of an open-label pilot study. *Eur J Cancer*. 2014; 50(3): 611–621, doi: [10.1016/j.ejca.2013.11.002](https://doi.org/10.1016/j.ejca.2013.11.002), indexed in Pubmed: [24295639](https://pubmed.ncbi.nlm.nih.gov/24295639/).
32. Davies MA, Saiag P, Robert C, et al. Dabrafenib plus trametinib in patients with BRAF-mutant melanoma brain metastases (COMBI-MB): a multicentre, multicohort, open-label, phase 2 trial. *Lancet Oncol*. 2017; 18(7): 863–873, doi: [10.1016/S1470-2045\(17\)30429-1](https://doi.org/10.1016/S1470-2045(17)30429-1), indexed in Pubmed: [28592387](https://pubmed.ncbi.nlm.nih.gov/28592387/).
33. Long GV, Flaherty KT, Stroyakovskiy D, et al. Dabrafenib plus trametinib versus dabrafenib monotherapy in patients with metastatic BRAF V600E/K-mutant melanoma: long-term survival and safety analysis of a phase 3 study. *Ann Oncol*. 2017; 28(7): 1631–1639, doi: [10.1093/annonc/mdx176](https://doi.org/10.1093/annonc/mdx176), indexed in Pubmed: [28475671](https://pubmed.ncbi.nlm.nih.gov/28475671/).
34. Long GV, Stroyakovskiy D, Gogas H, et al. Dabrafenib and trametinib versus dabrafenib and placebo for Val600 BRAF-mutant melanoma: a multicentre, double-blind, phase 3 randomised controlled trial. *Lancet*. 2015; 386(9992): 444–451, doi: [10.1016/S0140-6736\(15\)60898-4](https://doi.org/10.1016/S0140-6736(15)60898-4), indexed in Pubmed: [26037941](https://pubmed.ncbi.nlm.nih.gov/26037941/).
35. Robert C, Karaszewska B, Schachter J, et al. Three-year estimate of overall survival in COMBI-v, a randomized phase 3 study evaluating first-line dabrafenib (D) + trametinib (T) in patients (pts) with unresectable or metastatic BRAF V600E/K-mutant cutaneous melanoma. *Ann Oncol*. 2016; 27(Suppl 6): 552–587 (abstr LBA40), doi: [10.1093/annonc/mdw435.37](https://doi.org/10.1093/annonc/mdw435.37).
36. Ugurel S, Thirumaran RK, Bloethner S, et al. B-RAF and N-RAS mutations are preserved during short time in vitro propagation and differentially impact prognosis. *PLoS One*. 2007; 2(2): e236, doi: [10.1371/journal.pone.0000236](https://doi.org/10.1371/journal.pone.0000236), indexed in Pubmed: [17311103](https://pubmed.ncbi.nlm.nih.gov/17311103/).
37. Anker CJ, Grossmann KF, Atkins MB, et al. Avoiding severe toxicity from combined BRAF inhibitor and radiation treatment: consensus guidelines from the Eastern Cooperative Oncology Group (ECOG). *Int J Radiat Oncol Biol Phys*. 2016; 95(2): 632–646, doi: [10.1016/j.ijrobp.2016.01.038](https://doi.org/10.1016/j.ijrobp.2016.01.038), indexed in Pubmed: [27131079](https://pubmed.ncbi.nlm.nih.gov/27131079/).
38. Ly D, Bagshaw HP, Anker CJ, et al. Local control after stereotactic radiosurgery for brain metastases in patients with melanoma with and without BRAF mutation and treatment. *J Neurosurg*. 2015; 123(2): 395–401, doi: [10.3171/2014.9.JNS141425](https://doi.org/10.3171/2014.9.JNS141425), indexed in Pubmed: [25768829](https://pubmed.ncbi.nlm.nih.gov/25768829/).
39. Rompoti N, Schilling B, Livingstone E, et al. Combination of BRAF inhibitors and brain radiotherapy in patients with metastatic melanoma shows minimal acute toxicity. *J Clin Oncol*. 2013; 31(30): 3844–3845, doi: [10.1200/JCO.2013.50.8473](https://doi.org/10.1200/JCO.2013.50.8473), indexed in Pubmed: [24062392](https://pubmed.ncbi.nlm.nih.gov/24062392/).
40. Hecht M, Zimmer L, Loquai C, et al. Radiosensitization by BRAF inhibitor therapy-mechanism and frequency of toxicity in melanoma patients. *Ann Oncol*. 2015; 26(6): 1238–1244, doi: [10.1093/annonc/mdv139](https://doi.org/10.1093/annonc/mdv139), indexed in Pubmed: [25762352](https://pubmed.ncbi.nlm.nih.gov/25762352/).
41. Margolin K, Ernstoff MS, Hamid O, et al. Ipilimumab in patients with melanoma and brain metastases: an open-label, phase 2 trial. *Lancet Oncol*. 2012; 13(5): 459–465, doi: [10.1016/S1470-2045\(12\)70090-6](https://doi.org/10.1016/S1470-2045(12)70090-6), indexed in Pubmed: [22456429](https://pubmed.ncbi.nlm.nih.gov/22456429/).
42. Long G, Atkinson V, Lo S, et al. Combination nivolumab and ipilimumab or nivolumab alone in melanoma brain metastases: a multicentre randomised phase 2 study. *Lancet Oncol*. 2018; 19(5): 672–681, doi: [10.1016/s1470-2045\(18\)30139-6](https://doi.org/10.1016/s1470-2045(18)30139-6).
43. Di Giacomo AM, Ascierto PA, Queirolo P, et al. Three-year follow-up of advanced melanoma patients who received ipilimumab plus fotemustine in the Italian Network for Tumor Biotherapy (NIBIT)-M1 phase II study. *Ann Oncol*. 2015; 26(4): 798–803, doi: [10.1093/annonc/mdu577](https://doi.org/10.1093/annonc/mdu577), indexed in Pubmed: [25538176](https://pubmed.ncbi.nlm.nih.gov/25538176/).
44. Goldberg SB, Gettinger SN, Mahajan A, et al. Pembrolizumab for patients with melanoma or non-small-cell lung cancer and untreated brain metastases: early analysis of a non-randomised, open-label, phase 2 trial. *Lancet Oncol*. 2016; 17(7): 976–983, doi: [10.1016/S1470-2045\(16\)30053-5](https://doi.org/10.1016/S1470-2045(16)30053-5), indexed in Pubmed: [27267608](https://pubmed.ncbi.nlm.nih.gov/27267608/).
45. Tawbi HH, Forsyth P, Algazi A, et al. Efficacy and safety of nivolumab (NIVO) plus ipilimumab (IPI) in patients with melanoma (MEL) metastatic to the brain: Results of the phase II study CheckMate 204. *J Clin Oncol*. 2017; 35(Suppl 15): 9507–9507, doi: [10.1200/jco.2017.35.15_suppl.9507](https://doi.org/10.1200/jco.2017.35.15_suppl.9507).
46. Park SS, Dong H, Liu X, et al. PD-1 restrains radiotherapy-induced abscopal effect. *Cancer Immunol Res*. 2015; 3(6): 610–619, doi: [10.1158/2326-6066.CCR-14-0138](https://doi.org/10.1158/2326-6066.CCR-14-0138), indexed in Pubmed: [25701325](https://pubmed.ncbi.nlm.nih.gov/25701325/).
47. Ahmed KA, Abuodeh YA, Echevarria MI, et al. Clinical outcomes of melanoma brain metastases treated with stereotactic radiation and anti-PD-1 therapy. *Ann Oncol*. 2016; 27(3): 434–441, doi: [10.1093/annonc/mdv622](https://doi.org/10.1093/annonc/mdv622), indexed in Pubmed: [26712903](https://pubmed.ncbi.nlm.nih.gov/26712903/).
48. Kroeze SGC, Fritz C, Hoyer M, et al. Toxicity of concurrent stereotactic radiotherapy and targeted therapy or immunotherapy: A systematic review. *Cancer Treat Rev*. 2017; 53: 25–37, doi: [10.1016/j.ctrv.2016.11.013](https://doi.org/10.1016/j.ctrv.2016.11.013), indexed in Pubmed: [28056412](https://pubmed.ncbi.nlm.nih.gov/28056412/).
49. Study of the anti-PD-1 antibody nivolumab in combination with dabrafenib and/or trametinib in patients with BRAF or NRAS-mutated metastatic melanoma. <https://clinicaltrials.gov/ct2/show/NCT02357732> (11.10.2018).
50. Samlowski WE, Watson GA, Wang M, et al. Multimodality treatment of melanoma brain metastases incorporating stereotactic radiosurgery (SRS). *Cancer*. 2007; 109(9): 1855–1862, doi: [10.1002/ncr.22605](https://doi.org/10.1002/ncr.22605), indexed in Pubmed: [17351953](https://pubmed.ncbi.nlm.nih.gov/17351953/).
51. Noël G, Proudhon MA, Valery CA, et al. Radiosurgery for re-irradiation of brain metastasis: results in 54 patients. *Radiother Oncol*. 2001; 60(1): 61–67, indexed in Pubmed: [11410305](https://pubmed.ncbi.nlm.nih.gov/11410305/).
52. Chao ST, Barnett GH, Vogelbaum MA, et al. Salvage stereotactic radiosurgery effectively treats recurrences from whole-brain radiation therapy. *Cancer*. 2008; 113(8): 2198–2204, doi: [10.1002/ncr.23821](https://doi.org/10.1002/ncr.23821), indexed in Pubmed: [18780319](https://pubmed.ncbi.nlm.nih.gov/18780319/).
53. Ammirati M, Cobbs CS, Linskey ME, et al. The role of retreatment in the management of recurrent/progressive brain metastases: a systematic review and evidence-based clinical practice guideline. *J Neurooncol*. 2010; 96(1): 85–96, doi: [10.1007/s11060-009-0055-6](https://doi.org/10.1007/s11060-009-0055-6), indexed in Pubmed: [19957016](https://pubmed.ncbi.nlm.nih.gov/19957016/).
54. Geukes Foppen MH, Brandsma D, Blank CU, et al. Targeted treatment and immunotherapy in leptomeningeal metastases from melanoma. *Ann Oncol*. 2016; 27(6): 1138–1142, doi: [10.1093/annonc/mdw134](https://doi.org/10.1093/annonc/mdw134), indexed in Pubmed: [26961150](https://pubmed.ncbi.nlm.nih.gov/26961150/).
55. Smalley KSM, Fedorenko IV, Kenchappa RS, et al. Managing leptomeningeal melanoma metastases in the era of immune and targeted therapy. *Int J Cancer*. 2016; 139(6): 1195–1201, doi: [10.1002/ijc.30147](https://doi.org/10.1002/ijc.30147), indexed in Pubmed: [27084046](https://pubmed.ncbi.nlm.nih.gov/27084046/).
56. Glitza IC, Rohlfis M, Guha-Thakurta N, et al. Retrospective review of metastatic melanoma patients with leptomeningeal disease treated with intrathecal interleukin-2. *ESMO Open*. 2018; 3(1): e000283, doi: [10.1136/esmoopen-2017-000283](https://doi.org/10.1136/esmoopen-2017-000283), indexed in Pubmed: [29387478](https://pubmed.ncbi.nlm.nih.gov/29387478/).