

Management of Simple Nodular Goiter: Current Status and Future Perspectives

LASZLO HEGEDÜS, STEEN J. BONNEMA, AND FINN N. BENNEDBÆK

Department of Endocrinology and Metabolism, Odense University Hospital, DK-5000 Odense C, Denmark

The simple nodular goiter, the etiology of which is multifactorial, encompasses the spectrum from the incidental asymptomatic small solitary nodule to the large intrathoracic goiter, causing pressure symptoms as well as cosmetic complaints. Its management is still the cause of considerable controversy.

The mainstay in the diagnostic evaluation is related to functional and morphological characterization with serum TSH and (some kind of) imaging. Because malignancy is just as common in patients with a multinodular goiter as patients with a solitary nodule, we support the increasing use of fine-needle aspiration biopsy (cytology).

Most patients need no treatment after malignancy is ruled out. In case of cosmetic or pressure symptoms, the choice in multinodular goiter stands between surgery, which is still the

first choice, and radioiodine if uptake is adequate. In addition to surgery, the solitary nodule, whether hot or cold, can be treated with percutaneous ethanol injection therapy. If hot, radioiodine is the therapy of choice. Randomized studies are scarce, and the side effects of nonsurgical therapy are coming into focus. Therefore, the use of the optimum option in the individual patient cannot at present be based on evidence. However, we are of the view that levothyroxine, although widely used, should no longer be recommended routinely for this condition.

Within a few years, the introduction of recombinant human TSH and laser therapy may profoundly alter the nonsurgical treatment of simple nodular goiter. (*Endocrine Reviews* 24: 102–132, 2003)

- I. Introduction
- II. Etiology
- III. Epidemiology
- IV. Natural History
- V. Diagnosis
 - A. Clinical evaluation
 - B. Laboratory investigations
 - C. Diagnostic imaging
 - D. Fine-needle aspiration biopsy
- VI. Treatment
 - A. Multinodular nontoxic goiter
 - B. The solitary nontoxic nodule
- VII. Unresolved Issues and Future Perspectives

I. Introduction

NODULAR GOITERS ARE clinically recognizable enlargements of the thyroid gland characterized by excessive growth and structural and/or functional transformation of one or several areas within the normal thyroid tissue. In the absence of thyroid dysfunction, autoimmune thyroid disease, thyroiditis, and thyroid malignancy, they constitute an entity described as simple nodular goiter (SNG; Ref. 1).

Simple goiter occurs both endemically, mainly related to iodine deficiency when goiter prevalence in children 6–12 yr

of age within a population is more than 5%, and sporadically, when this number is 5% or less. The clinical evaluation of size, morphology, and function is highly inaccurate (2) as illustrated, for example, by up to 50% of subjects with a solitary palpable nodule or a diffusely enlarged gland actually having multiple nodules when investigated by sonography (3–5). Additionally, up to 50% of the general population has thyroid nodules by sonography, even when the gland is normal to palpation (3–5). This may be one of the explanations for the increasing tendency, at least for thyroidologists, to use diagnostic imaging in the evaluation of such patients, in addition to functional characterization with serum TSH (6–9).

SNG covers a spectrum from the clinically normal gland to diffuse, uninodular, or multinodular and cystic enlargement of the thyroid, using the most sensitive of imaging techniques (4, 10). The clinical manifestations are related to those of growth and functional autonomy, unpredictable in the individual patient, leading to cosmetic and pressure symptoms on the one hand and that of hypersecretion of thyroid hormone on the other (1). The latter is increasingly recognized as a health hazard (11, 12). Another question is the risk of thyroid cancer in SNG. Although concern of an increased prevalence in SNG seems unfounded (3, 5), accumulating evidence suggests that the risk of cancer in SNG, approximately 3–5%, is no different whether the gland contains a single nodule or multiple nodules (3, 5).

Pathogenesis of SNG, excellently reviewed in recent publications (1, 13–17), is considered beyond the scope of this article. We will, however, in brief, comment on etiological aspects of this condition (1, 13–18), because consideration of possible preventive measures is a prerequisite for cost-effective management. Consequently, the discussion will emphasize management aspects, *i.e.*, diagnostic and thera-

Abbreviations: ATA, American Thyroid Association; CI, confidence interval; ETA, European Thyroid Association; FNAB, fine-needle aspiration biopsy; ¹³¹I, radioiodine; ILP, interstitial laser photocoagulation; L-T₄, levothyroxine; MNG-1, multinodular goiter 1; MR, magnetic resonance; MTC, medullary thyroid carcinoma; NIS, sodium iodide symporter; PEIT, percutaneous ethanol injection therapy; PET, positron emission tomography; SNG, simple nodular goiter; Tg, thyroglobulin; TPO, thyroid peroxidase; TSHR, TSH receptor; US, ultrasonography.

peutic aspects. For this, we rely heavily on our recent questionnaire studies among clinician members of the European Thyroid Association (ETA) and the American Thyroid Association (ATA). A number of issues are unresolved, and it should be evident from the following that major controversies exist (6–9, 19, 20). Despite this, we aim at providing a balanced recommendation and point at future therapeutic perspectives whenever this is at all possible. Although a distinction between the solitary nontoxic nodule and the multinodular nontoxic goiter is not always straightforward, we have in the following, whenever appropriate, tried to separate the two.

II. Etiology

Familial clustering of simple goiter has long been recognized, but classical genetic analysis based on Mendelian principles has shown no simple mode of transmission. In recent years, it has become clear that both endemic and sporadic simple goiter belong to the group of diseases referred to as complex diseases (18, 21) along with, for example, autoimmune thyroid disease (Graves' disease and Hashimoto's thyroiditis; Refs. 22 and 23). These conditions are common, vary in their severity, and are multifactorial, with the clinical phenotype representing the net effect of all the contributing genetic and environmental factors. In these conditions, it has been difficult to separate environmental influences from genetic susceptibility (Fig. 1).

It is generally accepted that iodine deficiency is a major environmental factor contributing to both endemic and sporadic simple goiter (24). In fact, thyroid size is negatively correlated to urinary iodine excretion (25). Constitutional factors such as gender are clearly implicated in the etiology, because the ratio of females to males in nonendemic goiter regions may exceed from 5:1 to 10:1. Other suggested risk factors include cigarette smoking (26, 27), naturally occurring goitrogens (28), emotional stress (29), certain drugs (30, 31),

and infections (32). Interestingly, alcohol seems to have the opposite effect. It is associated with a decrease in thyroid volume, possibly related to a direct toxic effect of alcohol (33, 34).

Although familial aggregation of simple goiter has repeatedly been demonstrated (35–37), family studies cannot determine whether this results from shared genes or shared environment. However, because concordance rates for simple goiter in female monozygotic twins have been reported higher in endemic (80%; Refs. 38 and 39) as well as nonendemic areas (42%; Ref. 21) as compared with female dizygotic twins [40–50% (Refs. 38 and 39) and 13% (Ref. 21), respectively], evidence of a genetic component in the etiology of simple goiter is provided. In an endemic goiter area, the heritability of the liability to goiter development in females has been calculated to 39% [95% confidence interval (CI), 0–79%; Ref. 39]. On the basis of path analysis (structural equation modeling), Brix *et al.* (21) estimated this heritability to be 82% (95% CI, 67–92%) in a nonendemic goiter area. The remaining 18% (95% CI, 8–33%) of the phenotypic variance resulted from individual-specific environmental factors not shared by the twins (21). Although the twin data cannot uncritically be interpreted as the relative importance of heredity and environment, in any population, both endemic and sporadic simple goiter seems to develop on the basis of genetic susceptibility interacting with environmental factors, the two most important being level of iodine intake and cigarette smoking. Consequently, possible susceptibility genes or genetic markers will be recognized more easily in nonendemic than endemic goiter areas.

Studies assessing the role of specific candidate genes in the etiology of simple goiter have given conflicting results. Corral *et al.* (40) demonstrated a thyroglobulin (Tg) gene point mutation in chromosome 8 associated with nonendemic goiter, which could, however, not be confirmed by others (41). Using classic linkage analysis in combination with a genome-wide screening in a large French-Canadian pedigree, Bignell

Etiology of simple nodular goiter

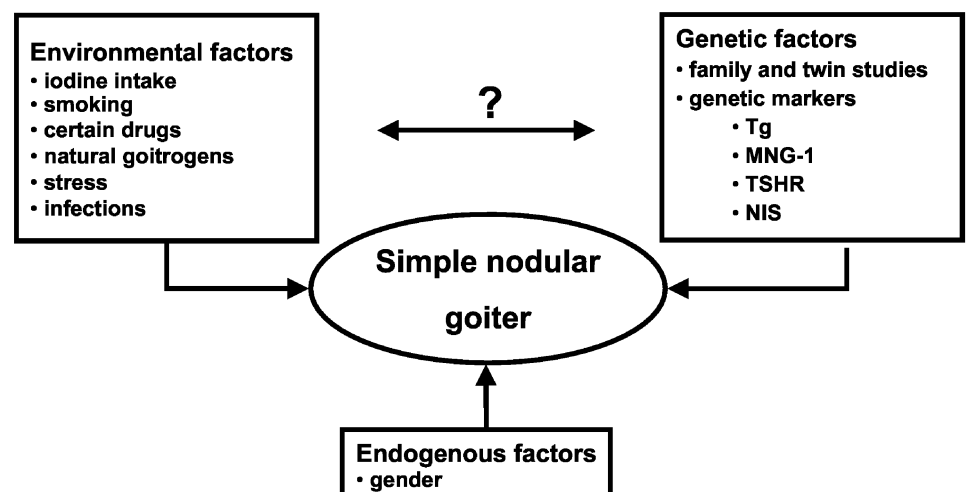


FIG. 1. The development of simple nodular goiter seems to involve complex interactions between environmental, genetic, and endogenous factors. At present, it is not clear how and to what degree the susceptibility genes interact with the environmental risk factors.

et al. (42) identified a region of interest on chromosome 14, multinodular goiter 1 (MNG-1). Two other studies (41, 43) have examined the role of MNG-1 and other possible candidate genes/markers, including Tg, TSH receptor (TSHR), and sodium iodide symporter (NIS), in the etiology of simple goiter, with conflicting results. Recently, Capon *et al.* (44) mapped a dominant form of multinodular goiter to chromosome Xp22. This finding awaits confirmation. It follows that genetic heterogeneity, *i.e.*, no single gene being either necessary or sufficient for disease development, is highly likely. The results of these studies, all in single or small groups of families, cannot at present be extrapolated to the general population. It is likely that single genes play a role in certain families. However, studies in larger numbers of pedigrees, taking gene-environment interaction into consideration, are necessary.

In light of the observed linkage between MNG-1 and goiter (41, 42), it is intriguing that Tomer *et al.* (45) have found linkage of Graves' disease to another locus on chromosome 14, Graves' disease 1. If confirmed, this could indicate the presence of a gene complex on chromosome 14, etiologically related to thyroid disease in general. However, as pointed out in *Section I*, simple goiter certainly comprises a number of phenotypes, complicating any comparison between available studies. This, in addition to the small number of families studied, hinders any firm conclusion on possible candidate genes in SNG.

III. Epidemiology

Epidemiological studies of nodular goiter are hampered by problems such as selection criteria (*e.g.*, age, sex), influence of environmental factors (*e.g.*, iodine and drug intake, smoking and drinking habits), evaluation of size and morphology (palpation, sonography, scintigraphy), and determination of thyroid function and whether subjects with subclinical thyroid dysfunction are included (46). Most studies have focused on middle-aged women and the elderly, whereas only a few have documented the prevalence of nodular thyroid disease in a population-based manner. Large-scale population-based longitudinal studies using diagnostic imaging allowing distinction between uninodular and multinodular disease and morphological as well as functional characterization do not exist. Therefore, adequate data on prevalence, incidence, etiological risk factors, and the natural history are lacking. These limitations should be born in mind when considering the available data. Despite these shortcomings, a pattern of increased thyroid volume and nodularity in areas with iodine deficiency is the rule (46–50). Furthermore, it has been suggested that relatively small differences in the iodine intake of a population may lead to notable differences in median thyroid volume, goiter prevalence, and nodule size (51). There are insufficient data allowing estimation of the optimum level of iodine intake to minimize goiter occurrence. Additionally, it is emphasized that goiter and thyroid nodules also exist in the face of iodine sufficiency, and even in the case of iodine excess (52, 53).

In the Whickham survey of a representative sample of the adult population from a geographic area of the United King-

dom, 15.5% of the participants had a palpable goiter (8.6% had a small goiter), with a female to male ratio of 4.5:1 (54). There was a weak association between goiter and thyroid autoantibodies and no relation to urinary iodine excretion. In Framingham, Massachusetts, where iodine intake was also sufficient, 1% of persons between 30 and 59 yr of age had multinodular goiter by palpation (55). In Connecticut, 2% of adults were reported to have nodular glands (56, 57). In Denmark, palpable goiter was demonstrated in 9.8% of a mildly iodine-deficient population and 14.6% of a moderately iodine-deficient population (49). This frequency increased to 15.0% and 22.6%, respectively, when goiter was defined by sonographic determination of thyroid volume (49). There are a vast number of such studies underscoring the inaccuracy of and also the large observer variation in the determination of goiter and thyroid size by clinical examination (2, 58, 59).

In the Whickham survey (54), solitary thyroid nodules were estimated to be present in 5.3% of women and 0.8% of men (ratio, 6.6:1). No details were given about nodule size, function, or their association with goiter. In Framingham, this frequency was 4.6% in all (6.4% in women and 1.6% in men; Ref. 55). However, these numbers are markedly changed if sonography is used. Then, the prevalence of thyroid nodules, even if defined as more than 10 mm in diameter, is usually 20–30% in unselected populations (46, 49, 60, 61) and even higher in older age groups and in areas with insufficient iodine intake (46, 62). These findings are substantiated by autopsy studies demonstrating that half the population had either single or multiple thyroid nodules (46, 63).

Little is known of the functionality of these solitary nodules. Although not systematically investigated, available data suggest that approximately 5% are toxic, 10% are warm, and 85% are cold (49, 64).

IV. Natural History

It is often stated that the natural history of nodular goiter is that of gradually increasing size with development of multiple nodules, local compression symptoms, and/or cosmetic complaints. However, the natural history with respect to growth and function varies and is difficult to predict in a given patient because no specific growth parameters exist. Therefore, it is difficult to decide whether an individual patient can be monitored without treatment or should have treatment before the goiter grows any further and possibly affects treatment outcome adversely (65). This dilemma is clearly illustrated by recent European and North American questionnaire surveys dealing with the solitary (6, 7) as well as the multinodular goiter (8, 9), disclosing profound differences within and between countries in the proneness to offer treatment, once malignancy has been ruled out.

In the Whickham survey (66), 20% of the women and 5% of the men who had goiters in the initial survey had no goiter in the follow-up survey, whereas only 4% of the women and none of the men acquired a goiter between the two surveys. In a 20-yr follow-up study of 11- to 18-yr-old subjects in the southwestern United States, 60% of the 92 subjects who had

diffuse goiters initially had spontaneous regression by the age of 30 yr (67). In a large epidemiological study, Knudsen *et al.* (51) only found an increase of thyroid volume up to the age of 40 yr. On the basis of cross-sectional data and ultrasonic scanning, an average annual growth rate of 4.5% in multinodular goiter has been reported (68). In patients referred because of SNG and who qualified for treatment, it has been estimated to be up to 20% yearly in a noniodine-deficient region (69) but is usually much lower. The suggested decreasing frequency of goiter with age could possibly be explained by a fall in lean body mass with age, known to be related to thyroid volume (70). A fall with age in IGF-I and GH, which is associated in the elderly (71), in patients with anorexia nervosa (72), and in pygmies (73) with a decrease in goiter frequency and thyroid volume, is another possibility. At least in women, the loss of estradiol-mediated increase in proliferation and down-regulation of the NIS gene may be of importance (74).

The natural history of thyroid nodules is poorly understood. In the Framingham survey, new nodules appeared with an incidence of 1 per 1000 per year (57), leading to an estimated lifetime risk for developing a nodule to between 5 and 10%. In a study of 140 selected Japanese patients who had not been treated and were reexamined 15 yr later (75), 13% had an increase in nodule size, 34% were unchanged, 23% had decreased, and in 30% the nodule was no longer palpable. The nodules that increased were originally predominantly solid, whereas those that disappeared were predominantly cystic. With the same reservations, that is the patients with rapid growth, for example, symptoms and clinical suspicion of malignancy were offered treatment, others have found that nodules on average do not change significantly over time (49).

Patients with nontoxic nodular goiter can become hyperthyroid or, less commonly, hypothyroid. However, thyroid dysfunction usually develops only after the nontoxic goiter has existed for many years. Hyperthyroidism often develops insidiously, in contrast to that of Graves' disease. It often begins with a prolonged period of subclinical hyperthyroidism characterized by low serum TSH and normal serum free T₄ and free T₃ concentrations (76). Increasing nodularity and size are related to a decrease in serum TSH (68). The true rate of progression from normal thyroid function to subclinical and finally overt hyperthyroidism is poorly described. However, two studies suggest an incidence of 9–10% of overt hyperthyroidism during a 7- to 12-yr follow-up period (77, 78). In part, this progression depends on genetic predisposition (21), somatic mutations in individual nodules (17), and extrinsic factors such as iodine intake (52). The latter may be alimental or related to iodine-containing drugs such as disinfectants and amiodarone or from radiographic contrast agents, which, in a goiter with increasing autonomous iodine metabolism, leads to the production of excessive amounts of thyroid hormone. In autonomously functioning solitary nodules (hot nodules), the evolution into a toxic nodule has been estimated at annual rates of 0–6% (79, 80). In one study, 67 of 375 patients developed hyperthyroidism over a mean follow-up of 53 months, corresponding to 4.1% per year (80). Size of the nodule seems crucial because Hamburger (81), during a 6-yr follow-up, demonstrated that nodules greater

than 3 cm in size at diagnosis carried a 20% risk of developing hyperthyroidism, whereas nodules less than 2.5 cm in size had only a 2–5% risk of developing hyperthyroidism within the same time frame.

V. Diagnosis

A. Clinical evaluation

1. Manifestations. There is no clear-cut relation between thyroid size, morphology, and function of the thyroid gland on one hand and the complaints of the individual patient on the other hand. The majority of patients with SNG have few or no clinical symptoms (Table 1). Therefore, given euthyroidism and exclusion of malignancy, many need no treatment. A simple management algorithm for the majority of patients with a solitary or a dominant nodule (index nodule, *i.e.*, the palpable nodule in a thyroid gland with other nodules found incidentally by imaging or a growing nodule in a preexisting multinodular gland) is given in Fig. 2.

When present, the most important symptoms and signs of SNG are caused by compression of vital structures in the neck or upper thoracic cavity. Besides various degrees of neck disfigurement, which in itself can merit treatment, the symptoms are related to compression of the trachea or esophagus. These compression symptoms are more often seen when there is an intrathoracic extension of the goiter. Such a goiter develops insidiously often in the elderly with long-standing goiter. When there is substantial growth into the thorax, usually into the anterior mediastinum, the thoracic inlet may become occluded. This is known as "the thyroid cork phe-

TABLE 1. Clinical symptoms, signs, and investigations in the diagnosis of SNG

Symptoms and signs	
Often family history of benign thyroid disease	
Slowly growing anterior neck mass	
Uni- or multinodularity on examination	
Enlargement during pregnancy	
Cosmetic complaints	
Asymmetry, tracheal deviation, and/or compression	
Occasionally upper airway obstruction, dyspnea, cough, and dysphagia	
Sudden transient pain or enlargement secondary to hemorrhage	
Gradually developing hyperthyroidism	
Superior vena cava obstruction syndrome (rare)	
Recurrent nerve palsy (rare)	
Horner's syndrome (rare)	
No adenopathy	
Investigations	
TSH normal or decreased, free T ₄ and free T ₃ normal	
Tg usually elevated	
Calcitonin normal	
Thyroid autoantibodies (TPO and Tg) negative in approximately 90%	
Scintigraphy with solitary or multiple hot and/or cold areas	
Ultrasound finding of solitary or multiple nodules with varying echogenicity (nonhomogeneity)	
Computed tomography and MR imaging demonstrating solitary or multiple nodules with varying echogenicity (nonhomogeneity)	
Lung function testing may demonstrate impaired inspiratory capacity	
Fine-needle aspiration of solitary or dominant nodules—benign cytology	

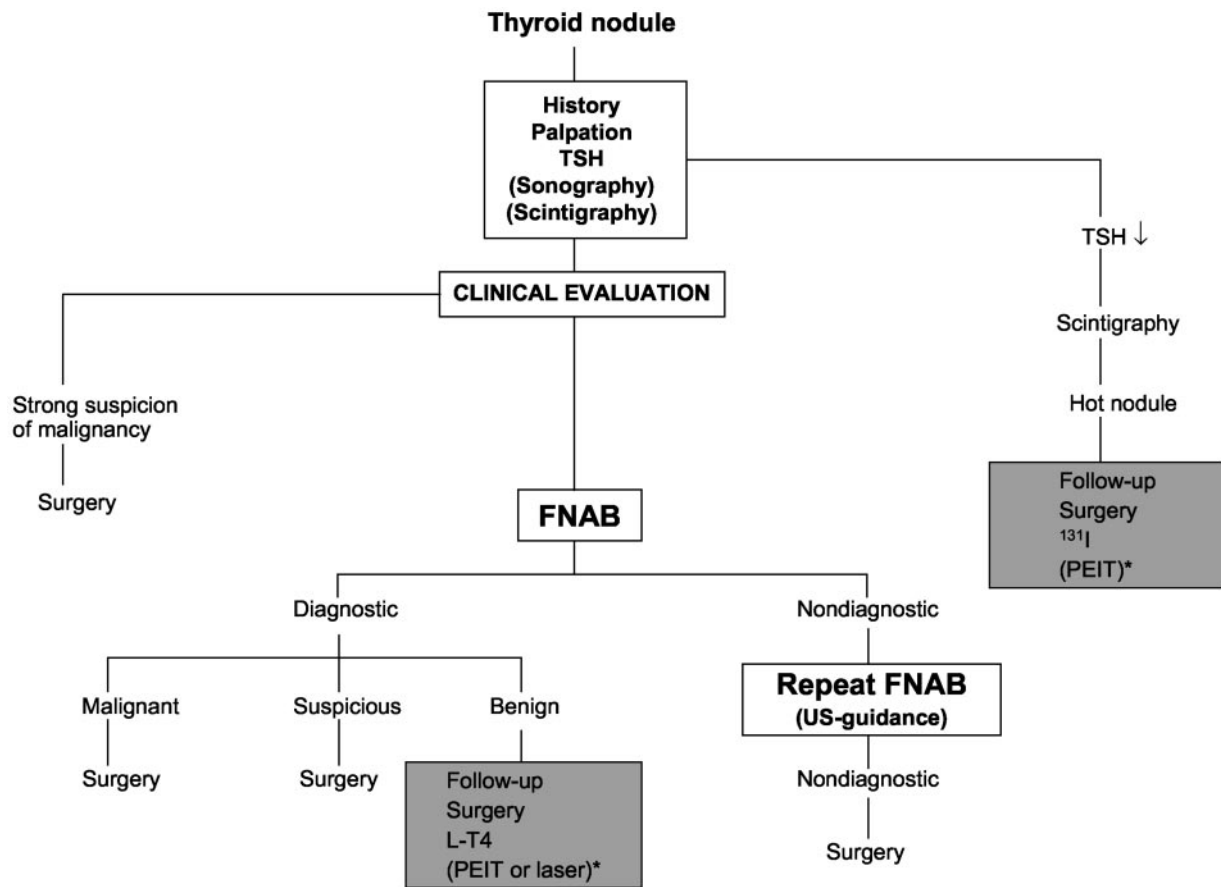


FIG. 2. Algorithm outlining a cost-effective evaluation and treatment of the solitary or dominant thyroid nodule. In case of strong suspicion of malignancy, surgery is advised irrespective of FNAB results. In case of a nondiagnostic result, repeat FNAB yields a satisfactory aspirate in 50%. FNAB guided by US (US-guidance) allows sampling from the periphery of a solid nodule or solid part of a mixed solid-cystic nodule, increasing the sufficiency rate. The options in case of a diagnostic FNAB cover both solid and cystic nodules. In case of recurrent cysts, the possibilities are reaspiration, surgery, or ethanol injection. The shaded boxes indicate treatment options. *, PEIT or ILP.

nomenon" (82). Evidence of venous outflow obstruction, *i.e.*, compression or thrombosis of the jugular or subclavian veins or the superior vena cava, can be provided by Pemberton's sign (83). Extending the arms over the head (Pemberton's maneuver) raises the goiter into the thoracic inlet, resulting in shortness of breath, stridor, distension of neck veins, or facial plethora.

The symptoms of tracheal compression are dyspnea, stridor, cough, and choking sensation. With an intrathoracic localization, respiratory distress is present in 30–85% of patients referred to surgery (84–87). However, such goiters are often very large, and it is unsettled whether the tracheal compression is related to the goiter size or the substernal localization *per se*. The detrimental influence by the goiter on the respiration is amplified in the recumbent position (88). Concomitant with tracheal narrowing, dyspnea and stridor develop initially only on exertion, but later also at rest. An acute exacerbation in upper airway obstruction may have a benign origin like hemorrhage into a nodule or cyst or upper respiratory infections causing endotracheal swelling. In patients with severe or acute airway distress, often requiring acute intubation, 20–50% may be caused by thyroid malignancy (89, 90). Even in asymptomatic individuals, attention should be paid to the trachea. Thus, Gittoes *et al.* (91) found

that in patients referred with a moderately enlarged goiter, flow-volume loops revealed upper airway obstruction among a third, and correlated poorly with symptoms. Complaints due to esophageal compression are less common and most prevalent in patients with large and partly intrathoracic goiters (86, 87). Even rarer is vocal cord paralysis, which can be transient or permanent, caused by stretching or compression of one or both recurrent laryngeal nerves (86, 87, 92). Phrenic nerve paralysis (93) and Horner's syndrome (94), due to compression of the cervical sympathetic chain, have been described but are extremely rare. If present, malignancy should always be suspected.

Toxic nodular goiter is beyond the scope of SNG; therefore, symptoms and signs of thyrotoxicosis have not been included. However, a number of patients with SNG certainly have subclinical hyperthyroidism biochemically (17% in one study; Ref. 95), and some of these patients have symptoms compatible with thyroid hyperfunction. Treatment aspects of these conditions will be dealt with subsequently.

2. Clinical examination. The evaluation of a patient with SNG comprises initially a careful history and physical examination focusing on inspection of the neck (including regional lymph nodes) and the upper thorax and palpation of the

goiter to determine its size and nodularity. This clinical evaluation, preferably done with the patient swallowing gulps of water and the head tilted slightly backward, essential for deciding on subsequent investigations and treatment, seems to be a lost or unlearned art for many physicians, as demonstrated by the considerable inter- and intraobserver variation regarding size and morphology of the thyroid (2, 59, 96). Recognition of this may well be one of the reasons for the increasing use of diagnostic imaging by European as well as North American thyroidologists in the evaluation of SNG (6–9).

With practice, the thyroid gland can also be palpated when of normal size, but to most the thyroid gland does not become palpable until the volume has doubled. A visibly diffusely enlarged goiter has often reached a volume of 30–40 ml. In general, the size of smaller goiters is overestimated, and the size of larger goiters is underestimated (2). Detection of nodules depends on their size, morphology, location within the thyroid parenchyma, anatomy of the patient's neck, and most of all the training of the physician. The patient is usually unaware of the presence of a nodule smaller than 1.5–2 cm in diameter. Awareness may, however, depend on localization, speed of growth, and the possible pain or discomfort related to, for example, hemorrhage into a nodule. Most goiters remain stable or increase in size slowly. Disregarding the possibility of malignancy, rapid increases may also be due to menstrual cycle-related alterations (97) or release of norepinephrine from a pheochromocytoma (98).

3. *Assessment of risk of malignancy.* SNG does not include thyroid cancer, but one of the main aims of the clinical evaluation is to exclude or at least minimize the risk of overlooking thyroid cancer. Table 2 lists the most important factors suggesting thyroid malignancy.

A family history of benign goiter usually suggests a benign disorder but is no proof thereof. Familial medullary thyroid cancer, with or without multiple endocrine neoplasia, should lead to exclusion of this possibility. The occurrence of familial papillary thyroid tumors occurring independently or in

TABLE 2. Factors suggesting the diagnosis of thyroid carcinoma in patients with nodular thyroid disease, according to degree of suspicion

High suspicion

- Family history of MTC or multiple endocrine neoplasia
- Rapid tumor growth (especially during L-T₄ therapy)
- Very firm nodule(s)
- Fixation to adjacent structures
- Vocal cord paralysis (laryngoscopy)
- Regional lymphadenopathy
- Distant metastasis (lungs or bones)

Moderate suspicion

- Age <20 yr or >60 yr
- Male sex
- Solitary nodule
- History of head and neck irradiation
- Firm texture, possible fixation
- Nodule >4 cm in diameter and partially cystic
- Compression symptoms: dysphagia, dysphonia, hoarseness, dyspnea, cough

Low suspicion

- All others

Cowden's disease, Gardner's syndrome, or familial polyposis coli (99) is important in risk assessment.

The risk of harboring thyroid cancer is highest in the young and the old, and therefore the diagnostic approach should be more aggressive in these age groups. Nodular thyroid disease is 5–10 times more common in females, whereas the rates of thyroid carcinoma are nearly equal in men and women. Therefore, nodular goiter in a man is more likely to be a carcinoma. Head and neck irradiation in infancy or childhood, for a number of benign conditions, is strongly associated with a subsequent occurrence of carcinoma (100). The possibility that many naturally occurring thyroid carcinomas may be due to fallout radiation from various radiation sources or natural background is strengthened by the observed epidemic of childhood papillary thyroid cancer seen in Belarus and Ukraine after the Chernobyl nuclear accident (101).

Rate of growth is of the essence. Thyroid carcinomas usually grow slowly over a period of weeks or, more often, months. Growth during thyroid hormone therapy is particularly worrisome. Sudden growth is most likely a thyroid cyst or a previously undetected nodule into which a hemorrhage has occurred. Rapid enlargement is also encountered in cases of anaplastic carcinoma or the development of lymphoma in a patient with previous chronic autoimmune thyroiditis.

The presence of discomfort in the neck, jaw, or ear and dysphagia, hoarseness, or dyspnea can occur in patients with benign thyroid nodules, particularly in those with large multinodular goiters, but may also indicate thyroid carcinoma. A hard and fixed nodule is suggestive of thyroid carcinoma, as is paralysis of the vocal cords and ipsilateral lymphadenopathy. Although virtually all patients with thyroid carcinoma are euthyroid (as are most patients with benign thyroid nodules), a suppressed serum TSH suggests subclinical hyperthyroidism. Usually, this rules out clinically significant malignancy, but it should be noted that coexisting hyperthyroidism does not exclude malignancy in the multinodular goiter. Thus, in one large series of operated hyperthyroid patients, thyroid cancer was found in 1.6% of patients with a toxic multinodular goiter, contrasting with none among those with Graves' disease (102).

It should be remembered that glands that harbor malignancy are in many cases indistinguishable from those that do not. In case of a high clinical suspicion of malignancy (Table 2), thyroidectomy should be advocated irrespective of a benign cytology because the likelihood of malignancy is very high (Ref. 103; Fig. 2). When two factors suggesting high suspicion are present, the likelihood of thyroid malignancy approaches 100% (103).

B. Laboratory investigations

Serum TSH is by far the most used test in the initial evaluation of SNG (6–9). This approach is indeed justifiable, because present TSH assays are very sensitive in detecting thyroid dysfunction. Although preferred by more than half of clinicians (Table 3), it can be strongly questioned whether an initial measurement of thyroid hormones adds further information in this setting, provided the serum TSH is within

the normal range. When it comes to the use of other biochemical tests than TSH, North American clinicians are clearly more restrictive than are Europeans (Table 3; Refs. 6–9).

Antithyroid peroxidase (anti-TPO) antibodies are measured by more than half of clinicians (6–9). This seems relevant because thyroid antibodies are found in approximately 10% of the population (104, 105), and consequently, autoimmunity may well coexist within a goiter. On the other hand, diffuse or focal lymphocytic infiltrates in an enlarged gland may represent chronic autoimmune thyroiditis and not merely simple goiter (4). This can be confirmed by fine-needle aspiration biopsy (FNAB), and subsequently, L-T₄ therapy may be considered in these cases, particularly if the serum TSH level is located in the upper normal range. Additionally, knowledge of the anti-TPO status is relevant for therapy with radioiodine (¹³¹I), because these antibodies constitute a risk factor for thyroiditis, hypothyroidism, and transition into Graves' disease (106).

Although serum Tg correlates with the iodine status and/or the size of the thyroid gland, this marker is too inaccurate at the individual level to have any independent value in the diagnosis of goiter (107, 108). This is reflected by less than 10% of clinicians measuring serum Tg (6–9).

A test giving rise to much discussion during recent years is serum calcitonin. This hormone is a marker of medullary thyroid carcinoma (MTC), and the serum levels correlate with the tumor burden (109). MTC accounts for less than 10% of all thyroid cancers and is supposed to be present in less

than 0.5% of all thyroid nodules (16). Of particular interest is its use in the early diagnosis of MTC. A two-site immunometric calcitonin assay should be used (110), but presence of heterophilic antibodies may still cause falsely elevated values (111). With modern assays, serum calcitonin is below 10 pg/ml in 99% of healthy subjects (112) and is slightly higher in men than in women (113). Raised levels of calcitonin not related to thyroid diseases are seen in conditions such as impaired renal function (114), pseudohypoparathyroidism (115), or treatment with proton pump inhibitors (116). Pentagastrin-stimulated calcitonin was much used in the past to test family members for MTC associated to the multiple endocrine neoplasia 2 syndrome, but this can now easily be done by genetic test for mutations in the RET proto-oncogene (117). Pentagastrin stimulation may still have a role in sporadic cases in which basal calcitonin exceeds 10 pg/ml (118). In the United States, where pentagastrin is no longer available, the calcium-calcitonin test may be used instead (119). The normal upper limit of serum calcitonin after stimulation with pentagastrin is approximately 40 pg/ml (113). If the level exceeds 100 pg/ml, this strongly indicates the presence of MTC or C cell hyperplasia (120). In case of familial disposition, C cell hyperplasia is considered as carcinoma *in situ*. In other cases, the significance of C cell hyperplasia is unclear, because it is a common finding in the elderly, present in 20% at autopsy (121). The results of six large-scale studies (112, 118, 122–125) of the routine use of serum calcitonin in patients with nodular thyroid disease are summarized in Table 4. The studies vary with regard to the diagnostic set-up and the fraction of patients with histological verification. The prevalence of MTC was up to 1.4% in a large French study (123) in which 41% of 34 patients with an elevated basal calcitonin had MTC, but also included two false-negative cases. In the study of Hahm *et al.* (112), 56 of 1448 patients (3.9%) with nodular thyroid diseases had a serum calcitonin level above 10 pg/ml. Ten patients (0.7%) proved to have MTC. Half of these subjects had a basal serum calcitonin level above 100 pg/ml. Vierhapper *et al.* (118) found 3 of 1062 patients having a basal calcitonin level exceeding 100 pg/ml. More important, in 10 of 31 patients with basal calcitonin ranging from 10–100 pg/ml, a pentagastrin-stimulation increased calcitonin above 100 pg/ml (118). MTC was found in three patients, and another six had C cell hyperplasia. Basal or stimulated calcitonin levels were generally more sensitive than FNAB in detecting MTC, and the routine use of serum calcitonin was recommended by all authors of these studies (112, 118, 122–125). However, a clear conclusion is not easy to draw from the existing data. Cost-benefit must be taken into consideration, and a high false-

TABLE 3. Routine biochemical tests used by ATA and ETA members, according to questionnaire surveys (6–9), in the diagnostic evaluation of a patient with a nontoxic solitary nodule or a nontoxic multinodular goiter and no suspicion of malignancy

	Solitary nodule		Multinodular goiter	
	ATA (n = 142)	ETA (n = 110)	ATA (n = 140)	ETA (n = 120)
TSH	99	99	100	100
Total T ₄	12	20	21	17
Total T ₃	9	25	23	23
Free T ₄ /index	49	53	54	74
Free T ₃ /index	6	31	11	43
TPO antibodies	30	41	61	65
Microsomal antibodies	6	11	17	10
Tg antibodies	18	26	34	49
TSHR antibodies	0	6	0	8
Calcitonin	5	43	4	32
Tg	4	14	2	8
Sedimentation rate	6	16	9	13

Numbers are percentage of clinicians in the two organizations.

TABLE 4. Studies of the routine use of serum calcitonin (CT) in patients with nodular goiter

Author	No. of patients	Use of pentagastrin test	Prevalence of MTC (%)
Pacini <i>et al.</i> (124)	1385	Yes, if elevated basal CT	0.57
Rieu <i>et al.</i> (122)	469	Yes, if elevated basal CT	0.84 ^a
Niccoli <i>et al.</i> (123)	1167	Yes, in 121 patients with normal basal CT	1.37
Vierhapper <i>et al.</i> (118)	1062	Yes, if elevated basal CT	1.13 ^b
Özgen <i>et al.</i> (125)	773	No	0.52
Hahm <i>et al.</i> (112)	1448	Yes, in 39 patients with elevated basal CT or disposing factors	0.69

^a Demonstrated histologically or by immunostaining with anti-CT antibodies.

^b Including C cell hyperplasia.

positive rate of 60–80% (112, 123) will result in many unnecessary thyroidectomies. It is also evident from our surveys (6–9) that there is no consensus on this issue (Table 3). Thus, more than 30% of Europeans measure basal serum calcitonin routinely (6, 8), perhaps reflecting that five of the six large studies mentioned (118, 122–125) were performed in Europe. In contrast, only very few clinicians in North America routinely use basal calcitonin measurement, except in the case of a family history of thyroid cancer (7, 9). This approach is in accordance with existing ATA guidelines (126) as well as guidelines published by the American Association of Clinical Endocrinologists (127).

In agreement with the attitudes of most ETA and ATA clinicians (6–9), we conclude that serum TSH and anti-TPO are mandatory in the evaluation of SNG. If TSH is found outside the normal range, assays for T₄ and T₃ are also justified. In contrast, the routine use of calcitonin in all patients with a nodular thyroid gland is controversial (6–9) and can be questioned, but it seems clear that if a basal plasma calcitonin level above 10 pg/ml is found, this must elicit further investigations. We find no place for the routine assessment of serum Tg and only rarely for Tg antibodies.

C. Diagnostic imaging

Although simple and cheap, neck palpation is notoriously imprecise with regard to both thyroid gland morphology (2,

58, 128) and size determination (2, 96, 129). For this purpose, several imaging methods are available: sonography, scintigraphy, computed tomography scan, magnetic resonance (MR) imaging, and perhaps positron emission tomography (PET). Table 5 lists characteristics, advantages, and disadvantages of these imaging modalities. Of these, sonography clearly has first priority among clinicians (6–9).

1. Sonography. Introduction of thyroid sonography has had a dramatic impact on clinical practice. It was shown by Marqusee *et al.* (5) that in patients referred to a thyroid clinic due to palpable thyroid abnormalities, sonography altered the clinical management in two thirds of the cases. The main reasons for the widespread use of thyroid sonography are availability, low cost, limited discomfort to the patient, and the nonionizing nature. Some years ago, the routine use of sonography was not recommended in the management of nodular goiters (126, 130), but today this attitude is rapidly changing (6–9). Also, sonography has many favorable features, such as detection of nonpalpable nodules, estimation of nodule size/goiter volume (*e.g.*, monitoring the effect of therapy), and guidance for FNAB (Table 5). However, the high sensitivity can also lead to detection of clinically insignificant nodules and to unnecessary work-up and anxiety for the patient. Some of the above advantages have led more than 80% of ETA members and 60% of ATA members to

TABLE 5. Characteristics of imaging procedures in relation to nodular thyroid disease

	Advantages	Disadvantages
Sonography	High availability High morphologic resolution No ionizing irradiation Dynamic picture Blood flow visualization (Doppler) Biopsy guidance, also of lymph nodes Moderate precision in volume estimation Low patient discomfort “Bed-side” investigation	Operator dependency No information of functionality Not feasible in substernal goiter Poor prediction of malignancy
Scintigraphy	Information of functionality Differentiates between destructive and hyperthyroid conditions Measurement of thyroid iodine uptake Predictive of feasibility of ¹³¹ I therapy Detects ectopic thyroid tissue	Requires nuclear medicine units Ionizing irradiation Poor resolution Poor differentiation between solid and cystic cold nodules Volume estimation inaccurate ^{99m} Tc may falsely show nodular uptake Invalidated by iodine contamination
CT scan	Good availability High morphologic resolution Visualization of adjacent structures Ideal for substernal goiter Planimetric volume estimation Volume estimation probably accurate	Ionizing irradiation No information of functionality Poor prediction of malignancy
MR imaging	No ionizing irradiation High morphologic resolution Visualization of adjacent structures Ideal for substernal goiter Planimetric volume estimation Volume estimation with high precision, probably with high accuracy	Moderate availability Long procedure time Not usable with metallic objects inside patient No information of functionality Poor prediction of malignancy Claustrophobia
PET	Information of functionality Metabolic investigations Good prediction of malignancy	Low availability Requires specialized units Ionizing irradiation Poorly evaluated

CT, Computed tomography.

include sonography routinely in the initial management of the patient with nodular goiter (6–9). Thyroid sonography has recently been comprehensively reviewed (4). First of all, high-resolution sonography with great certainty distinguishes solid from cystic lesions. Furthermore, it is very sensitive in the detection of thyroid nodules, for which purpose the interobserver variation is low (131). Sonography detects five times as many nodules as thyroid palpation and twice as many when only nodules larger than 2 cm are considered (132). Thus, after the introduction of sonography, it has become clear that nodules in the thyroid gland are very prevalent, ranging from 17% to as much as 67% in a given population (51, 133–135). As a consequence, the term “thyroid incidentaloma” has emerged. Some authors recommend regular sonographic follow-up of such incidentalomas (61, 126), although the growth rate does not seem useful in distinguishing malignant from benign nodules (136). Sonographic characteristics like hypoechogenicity, microcalcifications, and increased nodular flow visualized by Doppler are all to some extent predictive of malignancy (Table 6). However, the low accuracy in most studies disqualifies sonography in the differentiation between benign and cancerous lesions (4), and it is clearly inferior to FNAB in this setting.

The possibility of measuring thyroid volume is another highly useful feature of sonography, particularly where diagnosis and monitoring of goiter size are of crucial importance. The validity of sonographic volume measurement depends on the principle used. The ellipsoid method (length * width * depth * $\pi/6$) has an interobserver coefficient of variation of 10% (131), and the measurement error is 10–16% compared with postmortem specimens (131, 137). When compared with MR planimetry, the ellipsoid method underestimates the thyroid volume by 22.7%, independent of the thyroid size. This difference is halved, however, if the MR estimates are also based on the ellipsoid formula (138). The problem with an irregularly shaped goiter, increasing with size and invalidating the ellipsoid method, can be overcome by a planimetric method. Precision and accuracy of this principle are sufficiently high for most purposes. The interobserver coefficient of variation is 5% (47, 139), and the measurement error is 7% (139). In a comparison between the planimetric and the ellipsoid methods, Nygaard *et al.* (140) recently revealed that the latter technique underestimates the thyroid volume by a median of 9% and also has a lower reproducibility (median variation, 10% *vs.* 5.5% for the planimetric method). Sonographic planimetry for thyroid volume estimation has been compared with computed tomography [small to moderate enlarged goiters (140)] as well as MR imaging [very large goiters (141)]. In these cases, sonography

clearly underestimates the goiter size by 17% (140) and 19.5% (141), respectively. In the latter study (141), the difference between the estimates was found to expand with increasing volumes. Also, use of sonography is hampered by the sub-sternal extension frequently encountered with large goiters. A new three-dimensional sonographic technique introduced recently for thyroid volume estimation has a significantly higher accuracy than conventional sonographic methods (142). Additional studies are needed to evaluate this promising technology.

2. *Scintigraphy.* Thyroid isotope imaging has been used for many years. Although the scintigraphic resolution can be enhanced to 6–7 mm by tomography (SPECT; Ref. 143), this is still far below that of sonography. Therefore, scintigraphy at present has little place in the anatomotopographic evaluation of the nodular goiter (Table 5). However, scintigraphy is very helpful in the determination of the functionality of the thyroid nodules. TSH suppression by levothyroxine (L-T₄) administration emphasizes autonomous nodular function (144), but is not routinely used (6–9). Nodules with a high uptake by scintigraphy almost never harbor clinically significant malignancy, although exceptions have been reported (145). ^{99m}Tc used as a tracer may result in falsely positive uptake in 3–8% of thyroid nodules (146), whereas iodine isotopes are devoid of this problem. This may explain why the use of ¹²³I is favored by 63% (solitary nodule) and 49% (multinodular goiter) of ATA members (7, 9). The fact that ^{99m}Tc is inexpensive and easier to use, in addition to several studies being unable to demonstrate any significant dissimilarities between the two tracers (147–149), may explain why this isotope is recommended by 85% of ETA members (6, 8).

The fraction of inactive or “cold” lesions constitutes 77–94% of nodules in consecutive series of thyroid scintigrams (150–152). The *a priori* risk of malignancy among cold nodules is reported to be 8–25% or even higher (151, 153–155). However, such risk estimates are without a doubt heavily influenced by selection bias, because cold scintigraphic nodules greater than 10 mm are found in 2.4% of the subjects living in a borderline iodine deficient area (49). Tracers like ²⁰¹Thallium and ^{99m}Tc-MIBI have an increased uptake in differentiated malignant thyroid nodules, but the sensitivity and specificity do not support their general use (156–159). Thyroid scintigrams have been used through the decades for measurement of the thyroid volume. However, in comparison with modern imaging techniques, it is very inaccurate (160–162) and cannot be recommended for this purpose.

Many disregard thyroid scintigraphy in the initial evaluation of patients with nontoxic nodular goiter (16, 126). Nevertheless, more than two thirds of ETA members (6, 8) rou-

TABLE 6. Ultrasonographic features in subjects with nodular thyroid disease suggestive of malignancy

Benign	Malignant
Normal echogenicity or hyperechogenicity	Hypoechogenicity
Coarse calcifications	Microcalcifications
Thin, well defined halo	Thick, irregular, or absent halo
Regular margin	Irregular margin
Lack of invasive growth	Invasive growth
No regional lymphadenopathy	Regional lymphadenopathy
Low intranodular flow by Doppler	High intranodular flow by Doppler

tinely use scintigraphy, whereas less than 25% of ATA members prefer such a strategy in this condition (7, 9). Indisputable indications for scintigraphy in the setting of a nodular goiter are hyperthyroidism (to visualize hot nodules suitable for ^{131}I therapy) and a follicular neoplasm shown by FNAB, because warm nodules with great certainty are benign (163).

3. Computed tomography and MR imaging. Computed tomography and MR provide high-resolution three-dimensional visualization of the thyroid gland. Some aspects of MR and computed tomography for thyroid imaging have recently been reviewed (164). None of these methods have any advantages over sonography when it comes to detailed visualization of the intrathyroidal structure (Table 5). The major strength of computed tomography and MR is their ability to diagnose and assess the extent of substernal goiters much more precisely than any other method (Fig. 3). However, in this situation, only 15–20% of clinicians use these techniques (8, 9). The only comparative study done so far showed that MR is more precise than computed tomography in the anatomotopographic evaluation of the substernal goiter (165). However, whether computed tomography or MR is preferred probably depends on cost and availability. Another advantage of computed tomography and MR is the possibility for planimetric volume estimations, especially useful in

irregularly enlarged goiters. For this purpose, the observer variation of MR imaging is 2–4% (141, 161). Interestingly, MR measurements based on the ellipsoid principle underestimate the thyroid volume by approximately 12% in comparison with MR planimetry (138). With regard to computed tomography planimetric estimates, the median intra- and interobserver variations are 5% and 11%, respectively (140), and compared with surgical specimens, computed tomography overestimates the volume by up to 57% (mean, 12%; Ref. 166). The volume of surgical and postmortem thyroid specimens may, however, be dissimilar to *in vivo* determinations due to the influence of thyroid perfusion. The agreement between computed tomography and MR estimates is unknown, and little is known about the accuracies of the methods, because no gold standard is attainable.

All of the methods described above have little value in the differentiation between malignant and benign thyroid lesions, but new techniques are promising in this respect. An increased glucose metabolism as measured by [18F]-2-deoxy-2-fluoro-D-glucose PET (FDG-PET) can with high precision differentiate malignant from benign thyroid nodules (167, 168). A recent study showed that nearly 50% of thyroid nodules detected incidentally by FDG-PET harbor cancer (169). Although this technique seems promising in the diagnosis of thyroid malignancy, its use is hampered by cost and limited accessibility to most clinicians.

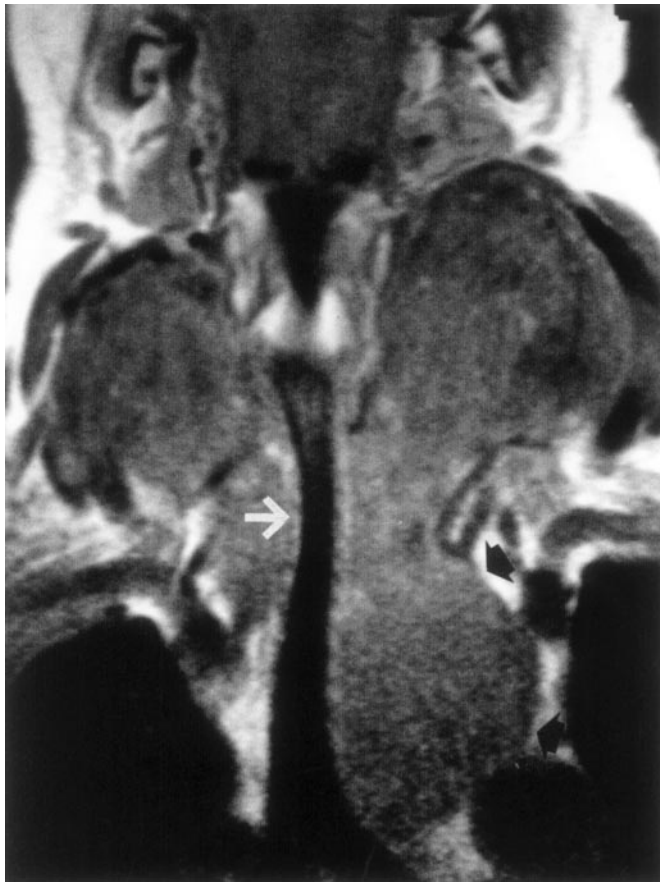


FIG. 3. Coronal MR image of a large goiter, demonstrating narrowing of the trachea (white arrow) and left-sided substernal extension (black arrows).

4. Tracheal imaging and relation to goiter size and lung function. The air flow rate, particularly in the inspiratory phase, will obviously be critically compromised if the lumen of the trachea is reduced beyond a certain point. Imaging of the trachea can be done by plain x-ray, computed tomography, or MR imaging. Plain x-ray has a poor sensitivity with regard to detection of airway obstruction and shows poor correlation with air flow rate (91, 170–173). However, the tracheal area, which can be measured by computed tomography or MR imaging, is a more relevant variable. Melissant *et al.* (173) found that computed tomography estimates of the smallest cross-sectional tracheal area, as well as plain tracheal radiograms, were unrelated to the lung function. In contrast, a relationship between the corresponding MR estimates and the inspiratory capacity has been demonstrated in large goiters (65). Changes in goiter volume and the tracheal area resulting from ^{131}I therapy also correlated well in the study by Huysmans *et al.* (174). However, results have been inconsistent, maybe due to the low precision of the imaging of the small tracheal dimensions (141). Other sources of error may be changes of the tracheal lumen caused by the respiration itself, the applied intrathoracic pressure, and the position of the patient (175–177). Furthermore, even with a small increase of the tracheal area, the flow rate becomes much less dependent of the luminal space. Thus, tracheal imaging cannot stand alone in the evaluation of respiration in the patient with a goiter. Because asymptomatic tracheal compression is prevalent (91), a flow volume loop should be considered, in particular if the goiter is very large, but in this case less than 15% of ATA members and even fewer of ETA members include a lung function test in the diagnostic setup (8, 9).

D. Fine-needle aspiration biopsy

FNAB provides the most direct and specific information about a thyroid nodule, and it is used by the majority of thyroidologists given a solitary nodule or a dominant nodule in a multinodular goiter (Table 7; Refs. 6–9). As the cornerstone in the evaluation, it is virtually without complications, inexpensive, and easy to learn. Figure 2 depicts the central role of FNAB in the investigation of nodular thyroid disease, with special emphasis on the solitary or the dominant nodule. The use of FNAB reduces the number of thyroidectomies by approximately 50% (178), roughly doubles the surgical yield of carcinoma, and reduces the overall cost of medical care in these patients by 25% (163).

The technique involves the use of a 5- to 20-ml plastic syringe with a 21- to 27-gauge needle. The skin is cleaned with alcohol and may be infiltrated with 1–2 ml of 1% lidocaine. The needle, attached to the syringe, is inserted perpendicular to the anterior surface of the neck. Negative pressure is applied, and as soon as bloody fluid in the hub of the needle appears, pressure is released and the needle withdrawn. No fluid should enter the syringe. If the nodule is a cyst or partly cystic, the aspiration should be followed by FNAB of any residual solid component. Investigation of the cyst sediment rarely gives useful information. After withdrawal, the needle is detached, and the specimen is evacuated onto a slide.

Diagnostically useful FNAB specimens are obtained in approximately 80% of the cases (Table 8; Refs. 130 and 179). The number of insufficient samples depends on operator experience, number of aspirations, the character of the nodule (cystic or solid), the experience of the cytopathologist, and especially the criteria used for adequacy of a sample. The number of sufficient samples increases if FNAB is guided by ultrasonography (US; Refs. 180 and 181). Rebiopsy will typically halve the number of insufficient FNABs (130, 182). Needle-steering devices and pistol-grip equipment are used by some. The specimens should be smeared immediately (pull-apart technique); most use air drying and staining with May-Giemsa-Grünwald stain, good for cytoplasmic details, or alternatively Papanicolaou's stain, good for nuclear details (183).

Diagnostic accuracy of FNAB depends on the handling of suspicious lesions. If considered negative, sensitivity will decrease, and specificity will increase. If suspicious results are regarded as positive, the converse is true. In our opinion, patients with suspicious, malignant, and nondiagnostic cytology (after reaspiration) should be operated (Fig. 2). The relevant question is what the false-negative rate is in the

TABLE 7. Frequency of use (%) of FNAB in nodular thyroid disease

	ATA	ETA
Solitary nodule: using FNAB	100	99
Guided only by palpation ^a	87	58
Guided by sonography ^a	13	42
Multinodular goiter: using FNAB	74	94
Guided only by palpation ^a	64	33
Guided by sonography ^a	36	67

Results are from ATA and ETA questionnaire surveys (6–9).

^a Percentage of clinicians performing biopsy.

TABLE 8. Causes of thyroid nodules and the relative distribution of FNAB results

	Frequency (range)
Benign (no evidence of malignancy)	69% (53–90%)
Colloid nodule	
Thyroiditis (chronic, acute, or subacute)	
Cyst	
Suspicious	10% (5–23%)
Follicular neoplasm	
Normofollicular (simple)	
Macrofollicular	
Microfollicular (fetal)	
Trabecular and solid (embryonal)	
Oxyphilic cell type (Hürtle cell)	
Malignant	4% (1–10%)
Follicular carcinoma	
Papillary carcinoma	
Medullary carcinoma (C cell carcinoma)	
Undifferentiated (anaplastic) carcinoma	
Lymphoma	
Metastasis (rare)	
Nondiagnostic (insufficient)	17% (15–20%) ^a

Adapted from Gharib and Goellner (130) and Burch (179).

^a This amount can be halved by rebiopsy.

remaining 70–80% of the cases in which nonsurgical treatment is an option. This has generally been estimated at 1% (184). Repeated FNAB during follow-up, to decrease the false-negative rate, will virtually eliminate the risk of overlooking thyroid malignancy (185). At worst, the diagnosis of low-grade thyroid malignancy (papillary or follicular thyroid carcinoma) is postponed.

Most cytopathologists agree that it is nearly impossible to distinguish benign from malignant follicular neoplasms on the basis of fine-needle aspiration cytology. In a large 3-yr prospective study from The Mayo Clinic comprising nearly 2000 patients, 17% had suspicious cytological findings, and in 24% of these patients malignancy was found (186). If scintigraphy of the cytologically suspicious nodule suggests that it is hyperfunctioning, also indicated by a suppressed TSH in case of the solitary nodule, such a lesion almost never harbors malignancy. In this situation, as also supported by others (16, 163), surgery can be avoided. In fact, clinicians should refrain from FNAB in scintigraphically hot nodules. Figure 2 shows our suggestion for the role of FNAB in the diagnostic setup. The application of a more complex cytological classification system to follicular lesions has been suggested by one group, but they were unable to demonstrate improved cancer yield with this cumbersome system (187). Large-needle biopsy does not have a higher diagnostic accuracy, *i.e.*, correctly identifying follicular carcinomas, than FNAB; furthermore, large-needle biopsy is more likely to yield an insufficient specimen, and more often hematomas are seen due to this procedure (188). In a smaller prospective study, a smaller needle size seemed to provide more cellular specimens, but diagnostic accuracy was unrelated to needle size (189).

Sonography has the advantage of providing multiple axial, longitudinal, and oblique planes of section and, most importantly continuous real-time needle localization. The maneuver can be performed by freehand, with the needle being inserted through the skin directly into the plane of view of the transducer without a guide or by the use of

built-in or attachable needle slots. US guidance is reliable because it allows the maneuver to be performed quickly, with no exposure to x-rays and under permanent visual surveillance. US-guided FNAB dramatically reduces the risk of sampling error, and the rate of adequate material aspirated during the procedure greatly increases (180, 190). In a retrospective Italian study by Danese *et al.* (181) comparing conventional FNAB with US-guided FNAB in 4697 and 9683 patients, respectively, sensitivity, specificity, and overall diagnostic accuracy were significantly improved when using US guidance. In another retrospective study from California, sensitivity and specificity improved to 100%, and adequacy rate improved from 84% to 93% when compared with conventional FNAB (191).

The true risk of malignancy in the cystic or mixed cystic/solid thyroid lesion is enigmatic to many clinicians. The usefulness of FNAB in thyroid cysts is hampered by the fact that specimens suitable for cytological examination cannot be collected from all cystic lesions. Attempts to add biochemical analysis of thyroid cyst fluid obtained by FNAB to analyze various enzyme concentrations, Tg, and other components has not given clear evidence of any simple test that distinguishes benign from malignant lesions (192, 193). Given clinical factors (Table 2) or cytological findings increasing the likelihood of thyroid malignancy in a euthyroid patient with a cystic hypofunctioning nodule, the risk of neoplasia and cancer is the same as in solid hypofunctioning nodules, and surgery should be recommended (Fig. 2; Refs. 194 and 195). Certain sonographic features (Table 6) are at best suggestive but are no proof of malignancy (4, 10, 196), and the macroscopic appearance of the cyst fluid, cyst resolution after one aspiration, or other characteristics of the cyst provide no additional information in the context of ruling out malignancy (195, 197, 198). Some report of a low rate of accurate diagnosis for the cystic malignant lesion (199) with a high false-negative rate (200), whereas others have been able to obtain diagnostic FNAB in 71% of patients with cystic nodules with no false-negative results (198). If the solid portion of a cystic mass is aspirated under US guidance and cytology is performed after centrifugation of the aspirated fluid, diagnostic accuracy may be improved (199).

The risk of malignancy in thyroid nodules occurring within a multinodular goiter has not been completely clarified, but some authors find a similar frequency in uni- and multinodular goiters (62, 201). This is consistent with the low accuracy of physical examination in detecting thyroid nodules. When diagnostic errors occur in identifying the number of nodules, the results are biased toward classifying multiple nodules as single because the sensitivity of the physical examination is rather low, in the range of 30% (202). The single nodule, if identified by palpation, will often be reclassified as a dominant (or prominent) nodule within a multinodular thyroid gland if sonography is used. Additional nodule(s) identified by sonography will not decrease the *a priori* risk of malignancy in the index nodule. For example, in nodules larger than 10 mm, the prevalence of cancer is unrelated to whether they can be detected by palpation (203). The possibility of thyroid malignancy should be considered in all patients with multinodular goiters, and the use of US guidance has been shown to enhance the diagnostic efficacy of

FNAB (204). It has been recommended that nodules less than 10 mm, detected incidentally, do not require a FNAB (61, 126). However, in the recent study by Papini *et al.* (205), thyroid malignancy was found in 6% of nonpalpable lesions of 8–15 mm in size in multinodular goiters (9% in solitary thyroid nodules). The risk was similar in nodules smaller or greater than 10 mm. A similar independency of size with regard to malignancy in nonpalpable nodules was found in an earlier study (190). However, whether carcinomas found in nodules other than the index nodule constitute clinically significant cancers or just incidental microcarcinomas remains an unsolved issue, leaving the clinician with no clear-cut guidelines for management. Sonographic features (205) may guide the clinician to include FNAB in nodules other than the index nodule. If scintigraphy is performed, we recommend FNAB in up to two nodules, provided these are scintigraphically cold. This strategy is based purely on pragmatism and not evidence.

So far, results clearly indicate that FNAB remains superior to other diagnostic tests. Further improvement of diagnostic sensitivity could arise from TPO immunodetection as a tool to assist diagnosis of thyroid nodules by FNAB (206, 207). Immunodetection of other candidate molecules, such as the lectin-related molecules, as markers of malignantly transformed thyrocytes may add valuable information in the selection of those nodules that need to be surgically resected, but confirmatory studies are needed (208). At present, telomerase assays do not add significant information to that of FNAB alone (209, 210).

VI. Treatment

A. Multinodular nontoxic goiter

There is no ideal treatment for the simple goiter. This is reflected by the fact that one third of clinicians would refrain from treatment facing a patient with moderate discomfort due to a multinodular nontoxic goiter of 50–80 g in which malignancy has been ruled out (Refs. 8 and 9; Fig. 4).

At first glance, iodine supplementation seems to be an adequate approach, because goiter development is strongly associated with even mild iodine insufficiency (24). The efficacy of iodine supplementation, once a nodular goiter has developed, has only very scarcely been evaluated. In a controlled trial, performed in an iodine-deficient area, a daily dose of 400 μg iodine during 8 months was as effective as 150 μg L-T₄ in reducing the size of diffuse goiter (211). A major hindrance in the use of iodine supplementation, however, is the fact that a sudden increase of the iodine intake may induce thyrotoxicosis in predisposed individuals (212, 213). Of further concern is that iodine supplementation appears to increase the incidence of papillary thyroid cancers and lymphoid thyroiditis (214). Due to these drawbacks, iodine supplementation in the context of nodular goiters is disregarded as an option, both in Europe (except in Germany) and in North America (8, 9). This leaves in essence three kinds of therapy: L-T₄ suppressive therapy, surgery, and ¹³¹I therapy. These options are quite dissimilar as to their mode of action and adverse effects. In Table 9, we have tried to list advan-

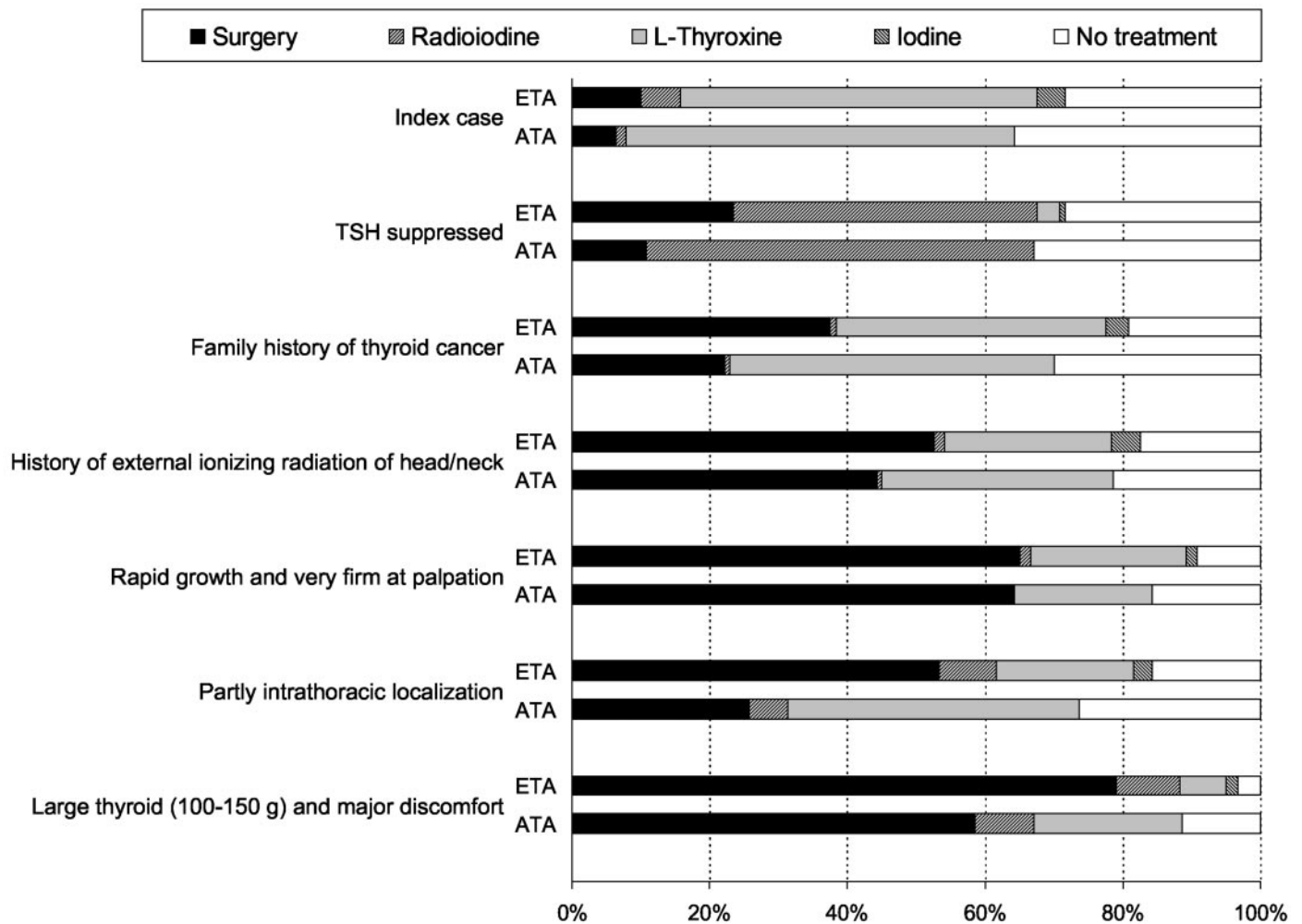


FIG. 4. Treatment options in nontoxic multinodular goiter and preferences among ATA and ETA members according to questionnaire surveys (8, 9). Index case: "A 42-yr-old premenopausal Caucasian woman admitted to your hospital/clinic due to an irregular nontender bilaterally enlarged thyroid. Clinically judged to be 50–80 g, absence of lymphadenopathy. No family history of thyroid disease. No previous external irradiation. No symptoms of thyroid dysfunction or anterior neck pain. The goiter has been present for 3–5 yr, and the patient reports of moderate local neck discomfort. Your investigations, whatever these have been, have demonstrated a benign condition." In the six listed variations, only one variable has been changed.

tages and disadvantages of the treatment options in benign nontoxic multinodular goiter.

1. T_4 therapy. In thyroid tissue that has not undergone autonomous degeneration, TSH suppression during treatment with thyroid hormones is supposed to slow or even revert growth of the thyroid gland. Indeed, a beneficial effect of thyroid hormones in diffuse goiters has been demonstrated in several controlled trials (211, 215–221). In general, a goiter reduction of 15–40% can be expected within 3 months, but the gland returns to the pretreatment size just as soon after withdrawal (215, 216). Treatment effect with T_3 or in combination with $L-T_4$ does not differ from that of $L-T_4$ alone (216, 217), but the effect may be more sustained after cessation of T_3 therapy (216). The efficacy of thyroid hormones is shown to depend on the degree of TSH suppression (216, 217), although results have been conflicting (218). In some of the studies in which $L-T_4$ was compared (211, 218, 220) or combined (211, 220, 221) with iodine supplementation, no substantial differences were found between the regimens, but

$L-T_4$ resulted in a more pronounced depression of serum TSH than did iodine (211, 218, 221). It has been recommended that diffuse euthyroid endemic goiters are treated with 200 μ g iodine combined with 100 μ g $L-T_4$ for at least 6 months, followed by iodine alone (222). Comparing nodular and diffuse goiters, the effect of $L-T_4$ is clearly more convincing in diffuse glands (219).

When it comes to the nontoxic multinodular goiter, there are only three controlled studies (69, 223, 224) in which sonography was used for objective size monitoring (Table 10). In the nonrandomized study of Lima *et al.* (223), the control group only comprised 15 patients. Thirty per cent of patients were regarded as responders (>50% reduction of the total nodular volume), whereas partial responders (20–50% reduction) constituted 23%. In the control group, 87% showed no change or an increase in goiter size. Berghout *et al.* (69), in a randomized double-blind trial, showed that the goiter volume was only reduced by 25% within a period of 9 months in the subgroup comprising 58% of the patients,

TABLE 9. Advantages and disadvantages of the treatment options in nontoxic multinodular goiter

	Advantages	Disadvantages
Surgery	Significant goiter reduction Rapid decompression of trachea Prompt relief of symptoms Definite histological diagnosis	Inpatient High cost Surgical risk Vocal cord paralysis: ~1% Hypoparathyroidism: ~1% Risk of hypothyroidism dependent of resection Risk of recurrence dependent of resection
¹³¹ I	Most often outpatient If outpatient: low cost Few subjective side effects Goiter reduction: 50% within 1 yr Improves inspiratory capacity in long term Can be repeated successfully	Limitation of administrated radioactivity Restricted proximity to other persons Contraceptives needed in fertile women Gradual reduction of the goiter Decreasing effect with increasing size Small risk of acute goiter enlargement Risk of thyroiditis: 3% Risk of transition into Graves' disease: 5% 1 yr risk of hypothyroidism: 15–20% Long-term cancer risk unknown
L-T ₄	Outpatient Low cost May prevent new nodule formation	Low efficacy Lifelong treatment Adverse effects (bone, heart) Not feasible when TSH is suppressed

TABLE 10. Controlled studies of L-T₄ therapy in nontoxic multinodular goiter using an objective thyroid size determination

Author	Randomized	n	Duration of therapy (months)	Dose of L-T ₄	Outcome: L-T ₄	Treatment in control group	Outcome: control group
Berghout <i>et al.</i> (69)	Yes	55	9	2.5 µg/kg (adjusted)	25% reduction among responders (58% of patients) ^a	Placebo (double blind)	20% increase ^a
Lima <i>et al.</i> (223)	No	62	12	200 µg	30% responders ^b	No treatment	0% responders ^b
Wesche <i>et al.</i> (224)	Yes	57	24	2.5 µg/kg (adjusted)	22% reduction among responders (43% of patients) ^{a, c}	¹³¹ I	44% reduction

^a Responders were patients achieving a goiter reduction more than 13% (>2 SD of the coefficient of variation).

^b Responders defined as goiter reduction >50%.

^c Reduction by 1% including nonresponders.

who responded significantly to L-T₄ therapy (>13% decrease of volume). In the placebo group, the goiter continued to increase in size by more than 20% on average after 9 months. If this rather high growth rate in the placebo group was taken into account, L-T₄ therapy caused a 45% size reduction. In the L-T₄ group, the goiter volume returned to baseline values 9 months after discontinuation of the therapy. Finally, Wesche *et al.* (224) compared L-T₄ with ¹³¹I therapy in a randomized trial (Fig. 5). Among ¹³¹I-treated patients, L-T₄ was commenced in 45% in the follow-up period due to increasing serum TSH levels. The median reduction of goiter volume in the ¹³¹I-treated group was 38% and 44% after 1 and 2 yr, respectively, whereas the corresponding values in the L-T₄-treated group were 7% and 1%, respectively. The difference in number of responders, 97% (¹³¹I) vs. 43% (L-T₄), was highly significant (224). Disfavoring L-T₄ therapy, more than one third developed symptoms of thyrotoxicosis, and a significant bone mineral loss as evaluated by dual-energy x-ray absorptiometry scanning was also noticed in that group (224). The above-mentioned trials (69, 223, 224) show that the effect of L-T₄ is at best very modest and that a sufficient goiter reduction can only be expected in a minority of the patients.

Other problems also raise concern. L-T₄ dose is often targeted toward a partly suppressed serum TSH level (8, 9). The

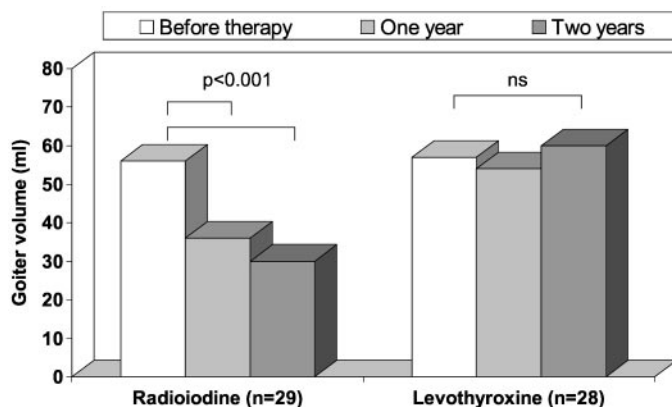


FIG. 5. Comparison of ¹³¹I therapy and L-T₄ in the treatment of nontoxic multinodular goiter. Bars represent median goiter volumes. Adapted from Wesche *et al.* (224).

consequence is subclinical hyperthyroidism. This condition affects the skeleton and the cardiovascular system adversely, and abnormalities in other organ systems have also been reported (11, 12). There is no evidence that patients with subclinical hyperthyroidism have an increase in fractures (225, 226), but a significant reduction in bone density in

postmenopausal women is seen (227, 228). In addition, there is a documented risk of atrial fibrillation in patients with subclinical hyperthyroidism, and the cumulative incidence is inversely related to the TSH concentration (229, 230). Low serum TSH in individuals aged 60 yr or older is associated with increased mortality from all causes, and in particular mortality due to circulatory and cardiovascular diseases (11, 12). Because lifelong therapy is probably needed to avoid goiter recurrence (69) and the natural history of the disease is progression toward hyperthyroidism due to autonomous function of the thyroid nodules (77, 78), L-T₄ treatment is unfeasible in many patients.

With these considerations in mind, it must be strongly questioned whether L-T₄ suppressive therapy has any role in the treatment of the nontoxic multinodular goiter. Although L-T₄ seems to be the prime therapy according to recent surveys (8, 9), this therapy cannot be recommended, except in small diffuse goiters in the young where it is least necessary. In our own country (Denmark), this therapy has been abandoned (231).

2. Surgery. Although L-T₄ appears to be the main treatment for small to moderately enlarged nontoxic goiters, several complicating factors, in particular a large goiter and suspicion of thyroid malignancy, cause most clinicians to recommend surgery (Refs. 8 and 9; Fig. 4). The advantage of surgery is the significant goiter reduction with prompt relief of symptoms and definite tissue diagnosis, but problems have to be taken into account (Table 9). Numerous reports, of which many include various kinds of thyroid diseases, have described the short- and long-term results of surgery. Specific complications related to thyroid surgery are injury to the recurrent laryngeal nerve and injury to the parathyroid glands. Permanent lesions of these structures occur in less than 1% of the patients in specialized units (232). Complications are related to the goiter size and extent of the resection (232, 233).

Surgical removal of large goiters may be followed by postoperative respiratory complications in up to 30% of cases (234). Furthermore, large goiters often exhibit a substernal extension, found among 5–17% of patients referred for thyroidectomy (232, 235). Although removal of substernal goiters is mostly accomplished through a collar incision, resection of substernal goiters is nevertheless followed by a higher complication rate (232, 235, 236). Postoperative tracheomalacia, necessitating intubation, may ensue in 5–10% of patients operated for large, substernal goiters (234, 237). A matter of concern is the apparently high prevalence (7–17%) of thyroid carcinomas in substernal goiters (86, 236, 238). However, this seemingly high frequency may be heavily influenced by selection bias. It thus remains to be confirmed whether a substernal goiter localization *per se* is associated with a higher risk of malignancy.

Recurrence of the nontoxic multinodular goiter is seen in 15–40% of patients with long-term follow-up (239–241). The risk is inversely correlated with the volume of the postoperative remnant (239), whereas possible factors such as age, duration of goiter, and serum TSH level during follow-up do not seem to be of importance (241). With this high probability of goiter recurrence, prophylactic measures clearly are jus-

tified. Postoperative use of L-T₄ is preferred by more than 50% of clinicians (8, 9). However, of four randomized trials (239, 242–244), only one (244) demonstrated a beneficial effect of L-T₄. Hence, in concert with the treatment issue discussed above, the postoperative use of L-T₄ can generally not be recommended. Iodine prophylaxis has also been tested in iodine-deficient areas, but the effect on goiter recurrence after surgery does not differ from that of L-T₄ (245).

A reoperation for the recurrent goiter accounts for approximately 10% of thyroidectomies (232, 246) and results in a 3- to 10-fold increase in risk of permanent vocal cord paralysis or hypoparathyroidism (232, 233, 246). Although the absolute risk still may be relatively low, ¹³¹I therapy seems to be a favorable alternative in these cases. Goiter recurrence can be completely avoided if a total thyroidectomy is performed initially. Such an approach is now the standard procedure for the multinodular goiter at some centers, apparently with the same low rate of complications as with subtotal thyroidectomy (247–250).

The long-term risk of hypothyroidism after subtotal resection of nontoxic multinodular goiters is insufficiently described, but it is probably not significantly different from the 10–20% reported for toxic multinodular goiters (251).

3. ¹³¹I therapy. During more than half a century, ¹³¹I therapy has been used to treat hyperthyroid disorders, primarily Graves' disease. It became evident early that ¹³¹I therapy also results in shrinkage of the thyroid gland, even if hyperthyroidism persists. Due to this effect on gland volume, ¹³¹I has been used during the last two decades in the treatment of compressive nontoxic nodular goiters, but in most countries, ¹³¹I is restricted to hyperthyroid patients (8, 9). With one exception (224), all studies dealing with the effect of ¹³¹I therapy on goiter reduction lack a control group. Nevertheless, the results have been very consistent. In 1988, Hegedüs *et al.* (252), using sonography, demonstrated a mean thyroid volume reduction from 73–43 ml 1 yr after ¹³¹I treatment of nontoxic multinodular goiters. Similar results have been obtained in subsequent studies (253–255), showing a goiter size reduction ranging from 40% to 60% within 1–2 yr of ¹³¹I therapy (Table 11). Half of the effect appears within the first 3 months (253). A second ¹³¹I dose may cause thyroid volume reduction similar to that obtained by the first dose (253, 254). The superiority of ¹³¹I over L-T₄ has been demonstrated recently in the earlier mentioned study by Wesche *et al.* (Ref. 224; Fig. 5). Only a few studies have been performed in large goiters beyond 100 ml (Table 11). In such large goiters, a considerable amount of ¹³¹I is needed, which in most cases requires hospitalization and isolation. Although the treatment with 100–150 mCi (3700–5550 MBq) ¹³¹I in an outpatient setting may be accepted by various states in the United States, this is certainly not the rule. In the three studies in which a valid goiter monitoring was applied (*i.e.*, computed tomography or MR imaging; Refs. 65, 162, and 174), the mean thyroid volume reduction was 30–40% with considerable individual variations. Fractionated therapy can be given to outpatients and might be an option in large goiters (256). However, the doses should probably be given with wide intervals to rule out thyroid stunning (257), which makes this treatment modality even more cumbersome. It has recently

TABLE 11. Studies of ¹³¹I therapy in nontoxic multinodular goiter

Author	n	Age (yr)	Goiter size (ml)	¹³¹ I dose (per gram thyroid) (MBq)	Follow-up (yr)	Evaluation	Goiter reduction (%) ^a
Hegedüs <i>et al.</i> (252)	25	56 (41–79)	73 ± 6 SEM	3.7	1	Sonography	41 ^b
Verelst <i>et al.</i> (262)	15	67 (62–86)	175 ± 13 SEM	2.8–3.7	2.5	Scintigraphy	39
Nygaard <i>et al.</i> (253)	69	57 (30–81)	74 (21–326)	3.7	2	Sonography	55 ^b
Huysmans <i>et al.</i> (174)	19	66 ± 14 SD	269 ± 153 SD	3.7	1	MRI	40
Wesche <i>et al.</i> (255)	10	48 (40–74)	88 ± 15 SEM	4.4	1	Sonography	48
de Klerk <i>et al.</i> (162)	27	60 (36–81)	194 ± 138 SD	1.1–4.8	1	CT	34
Le Moli <i>et al.</i> (254)	50	53 (30–82)	82 (17–325)	4.4	2	Sonography	49
Bonnema <i>et al.</i> (65)	23	67 (42–86)	311 ± 133 SD	3.7–5.5	1	MRI	34
Wesche <i>et al.</i> (224) ^c	29	50 ± 13 SD	56 (17–198)	4.4	2	Sonography	44

Values are given as mean ± SD/SEM or median (range). CT, Computed tomography; MRI, MR imaging.

^a Mean or median values.

^b Some patients were treated with more than a single ¹³¹I dose.

^c Randomized study including a control group treated with L-T₄.

been shown that patients with a substernal goiter may also benefit from ¹³¹I therapy (258). Because thyroid malignancy may be more prevalent in goiters with a substernal component (86, 236, 238), some risk of overlooking a cancer must be taken with this approach. The benign nature should be confirmed by FNAB of accessible dominant nodules and interpreted in the light of relevant clinical factors (firmness of the gland, growth rate, presence of lymphadenopathy, *etc.*).

Two small uncontrolled studies of ¹³¹I therapy of diffuse nontoxic goiter are available (259, 260). The median thyroid volume was reduced by 62% within 1 yr of therapy. Thus, it seems that the goiter reduction is more pronounced than in the multinodular goiter and comparable to what is seen in Graves' disease (261). Future long-term studies will clarify the role of ¹³¹I in this disease.

In general, patients are satisfied with the outcome of ¹³¹I therapy, but quantitative analyses of the improvement in symptoms are scarce (Table 12). Little is known of the rate of goiter recurrence after ¹³¹I therapy. Le Moli *et al.* (254) found that 8% of the patients had recurrent goiter growth 3–5 yr after therapy, apparently due to large goiters and/or a lower ¹³¹I dose administered. However, a controlled study comparing surgery and ¹³¹I, including the aspect of persistent or recurrent disease, is indeed needed. Two studies (65, 254) have demonstrated that the relative goiter reduction after ¹³¹I therapy is inversely correlated with initial goiter size, despite aiming at the same absorbed dose (Fig. 6). Such a relationship is plausible, because a larger fraction of the gland may become inert and subsequently less susceptible to ¹³¹I. The goiter reduction might be augmented by increasing the amount of radioactivity, as suggested by data from Le Moli *et al.* (254), but no dose-response study has been performed to clarify this issue specifically. In most studies of nontoxic goiters (65, 162, 174, 224, 252–254, 262), the administered ¹³¹I activity was 3.7–5.5 MBq/g thyroid tissue corrected for ¹³¹I thyroid uptake, aiming at an absorbed dose of approximately 100 Gy. However, it should be noticed that dose calculation based on 24-h ¹³¹I uptake and not half-life may strongly overestimate the intended dose to nodular goiters (263). In fact, an elaborated algorithm for dose calculation may not be worthwhile, as is also evident in the case of hyperthyroidism (264, 265). Besides a poorly defined individual susceptibility to ¹³¹I, which remains to be identified, the thyroid ¹³¹I uptake displays a considerable variation with time (266, 267). The

iodine biokinetics is probably also affected by the ¹³¹I therapy itself (266). Finally, the absorbed dose may be influenced by shrinkage of the gland during therapy (268).

The efficacy of ¹³¹I therapy on the whole gland is hampered by the irregular ¹³¹I uptake in the multinodular goiter. The number of suppressed nodules and extent of degenerated tissue probably set an upper limit for the obtainable reduction with this treatment. The fact that so few thyroidologists routinely recommend ¹³¹I therapy in the euthyroid patient is bewildering (Refs. 8 and 9; Fig. 4), especially when 40–55% of clinicians will turn to ¹³¹I therapy facing a patient with a suppressed serum TSH level (Refs. 8 and 9; Fig. 4). In this situation, goiter volume reduction is no better than that observed in the euthyroid patient (269). However, the recent advent of recombinant human TSH having the potential of doubling the 24-h ¹³¹I uptake (270) opens new avenues. In addition, pretreatment with recombinant human TSH causes a more homogeneous distribution of ¹³¹I within the nodular gland by stimulating the ¹³¹I uptake relatively more in cold areas than in hot areas (271). These potential benefits of recombinant human TSH are very intriguing in the context of an amplification of the ¹³¹I therapy, but whether the goiter reduction can be improved and whether this leads to a change in attitude among clinicians remains to be proven.

Only in very few European countries, like Denmark and to some extent The Netherlands, is ¹³¹I now the routine choice as treatment of the benign nontoxic multinodular goiter (8, 9). In North America, for example, the thyroid iodine uptake is rather low due to the high dietary iodine intake. Thus, if ¹³¹I therapy is to be used, a relatively high amount of radioactivity is needed, and this may hinder outpatient treatment. Other reasons for the reluctance to use ¹³¹I therapy in nontoxic goiters may be lack of experience and fear of side effects (Table 9). There has been concern of an early goiter enlargement caused by the radiation, thereby leading to a possible exacerbation of the tracheal compression. A general reservation is not justified because, on average, ¹³¹I therapy is not followed by any significant acute thyroid enlargement (65, 272), either in moderate or in very large multinodular goiters. However, because a goiter increment of 15–25% occasionally may be seen (65, 272), caution should be taken if severe tracheal compression is present. ¹³¹I therapy is generally well tolerated. A radiation-induced thyroiditis may be seen in a few percentage of cases (106), occurring within the first

TABLE 12. Goiter-related symptoms and signs before and after ^{131}I therapy in 50 patients with nontoxic goiter

	Baseline (% of patients)	2 yr after ^{131}I (% of patients)
Symptoms		
Cosmetic complaints	28	7
No obstructive symptoms	24	83
Globulus sensation	64	16
Shortness of breath	40	6
Difficulties in swallowing	24	5
Signs		
No obstructive signs	64	81
Deviation of trachea	36	5
Inspiratory stridor	12	0
Hoarseness	6	0

Adapted from Le Moli *et al.* (254).

month after therapy. This self-limiting condition is characterized by severe tenderness of the thyroid, elevated sedimentation rate, and fever. Antiphlogistics are helpful until the thyroiditis resolves, which usually happens within a few weeks. In addition, β -blockade for a short period of time may be indicated due to the concomitant hyperthyroidism caused by dumping of stored thyroid hormones into the circulation. The fact that ^{131}I therapy may trigger a transition into Graves' disease in 5% of patients (106, 273), occasionally associated with ophthalmopathy (274), is a matter of great concern. Presence of anti-TPO antibodies is a risk marker for this autoimmune response (106) and can thus to some extent be anticipated. This Graves'-like disease, occurring typically within 1–3 months after treatment, is associated with the *de novo* appearance of TSHR antibodies, probably triggered by the release of antigenic components from follicular cells during the ^{131}I therapy. This complication is mostly transitory but in the occasionally persistent cases, therapy of the hyperthyroidism and the ophthalmopathy can be troublesome.

^{131}I therapy of any thyroid disorder always includes a certain risk of thyroid hypofunction, increasing with time. In patients with diffuse nontoxic goiters treated with ^{131}I , permanent hypothyroidism occurs in 14% after 1 yr (259, 260), whereas long-term follow-up data are not available. The incidence of permanent hypothyroidism after ^{131}I therapy in moderately enlarged multinodular nontoxic goiters ranges from 22% to 58% within 5–8 yr (253, 254), occurring more commonly in those patients with an initially smaller goiter size and with the presence of anti-TPO antibodies (254). The cumulated risk of hypothyroidism after treating large goiters is theoretically the same as in smaller goiters, because the administered radioactivity is targeted at the same absorbed dose. Indeed, the 1-yr incidence of hypothyroidism of 14–22% is not particularly high (65, 162).

When giving therapeutical amounts of radioactivity, the cancer risk is of paramount concern. ^{131}I therapy, given for Graves' disease for decades, is not followed by any clinically significant increased risk of cancer deaths according to several long-term studies (275, 276). In a study from the United Kingdom (275), a slightly increased incidence of thyroid cancers was observed (nine *vs.* an expected three), but the overall cancer mortality was actually reduced. Data on the multinodular goiter are more sparse. In the study by Ron *et al.* (276), 1089 patients were treated for a toxic nodular goiter,

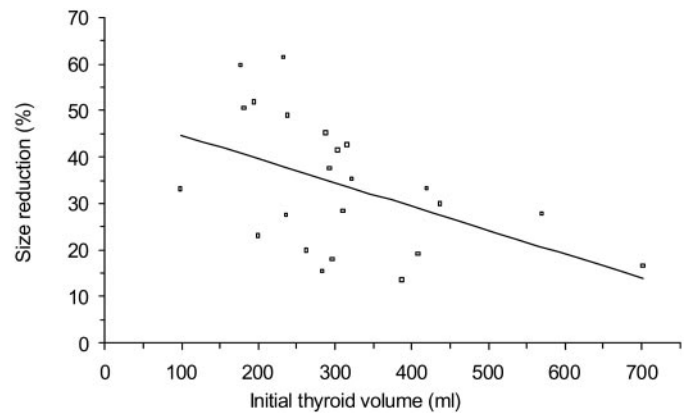


FIG. 6. Relation between initial goiter size and effect of ^{131}I in nontoxic multinodular goiter. Adapted from Bonnema *et al.* (65).

and these individuals had a 31% increase in overall cancer mortality, nearly exclusively attributable to thyroid malignancy. However, a similar pattern was seen in patients having the same disease but not treated with ^{131}I . In a Swedish study (277), the corresponding mortality rate was increased by more than 26% in 4,000 patients. Most of the increased mortality among patients with nodular thyroid diseases was due to thyroid cancer deaths, and this mortality diminished during prolonged follow-up (277). Hence, the disclosure of a thyroid cancer in a nodular goiter after ^{131}I therapy raises the question whether malignancy in a nodule was overlooked at the time of therapy. A recent study (278) including more than 5000 patients previously treated with ^{131}I for toxic nodular thyroid diseases is reassuring, because no significantly increased incidence of thyroid cancers was found during the 27 yr of follow-up. Nonetheless, the absolute number of cancers that may occur after ^{131}I is small in all studies and seems of minor clinical importance. The risk of thyroid cancer due to ^{131}I therapy should not be different when treating small or large thyroid glands. During high-dose ^{131}I therapy of large goiters, Huysmans *et al.* (279) calculated the theoretical lifetime risk of an extrathyroidal cancer to be 1.6% and a little lower (0.5%) when given to persons aged 65 yr (279).

For nontoxic goiter, we restrict the use of ^{131}I therapy to patients above 20 yr old. In case of a very large goiter, surgery clearly should be preferred to high-dose ^{131}I therapy, and until long-term data on the actual cancer risk are available, this latter therapy should not be given to patients younger than 40 yr, unless surgery is absolutely contraindicated.

4. Effect of treatment on tracheal compression and lung function. That treatment of the goiter has a favorable effect on the tracheal air flow was reported 25 yr ago (170) and has been verified in subsequent studies. Geraghty *et al.* (171) found a 25% increase in the maximal inspiratory flow rate after thyroidectomy, even in patients with a normal tracheal radiogram preoperatively. Similar results have been found in other studies (172, 280). Also, ^{131}I therapy has proven its efficacy (281). In the study of large goiters by Bonnema *et al.* (65), the smallest tracheal cross-sectional area was diminished by 9% 1 wk after therapy due to goiter enlargement in some patients, but no significant deterioration of the inspiratory capacity was observed in that study. If severe tracheal

compression is known to be present before therapy, in principal documented by a flow-volume curve, or clinical worsening of the cervical compression should occur post treatment, glucocorticoids (prednisone 25 mg/d for a few weeks) to reduce thyroid edema might be of benefit, although this strategy is not documented by any controlled trial. In the long term after ¹³¹I therapy, the smallest cross-sectional tracheal area has been shown to increase by 17–36% (65, 174), and the tracheal deviation decreases by 20% (174). The individual changes of the inspiratory capacity may show wide variations, but on average a 20–25% increase of this variable can be expected (65, 174).

The possible effect of L-T₄ suppressive therapy on the respiratory function or the tracheal anatomy has not been evaluated in any large-scale study (170).

B. The solitary nontoxic nodule

Because the aspects of surgery, ¹³¹I, and L-T₄ therapy bear much resemblance to what has been detailed regarding the

multinodular goiter, we will focus on the newest (experimental) modalities regarding treatment of the solitary nodule. Much of the evidence of current treatment preferences, as with multinodular nontoxic goiter (8, 9), stems from recent ATA and ETA questionnaire studies (Refs. 6 and 7; Fig. 7). Whenever applicable, we will refer to these studies. The solitary nontoxic nodule is also covered by the algorithm in Fig. 2. Table 13 summarizes advantages and disadvantages of the various treatment options in the patient with a solitary nontoxic benign nodule.

1. Incidentaloma. Nodules measuring 1–1.5 cm or larger are usually palpable when located superficially and should undergo FNAB. Therefore, it is reasonable to offer nonpalpable nodules of the same size US-guided FNAB (128, 190). The proportion of malignancies among incidentalomas smaller than 1.5 cm ranges from 3–6%, similar to the frequency for palpable nodules (181, 203), thus suggesting that incidentalomas cannot be left untreated with impunity. However, only 1 of 15 occult thyroid cancers will progress to a clinical stage,

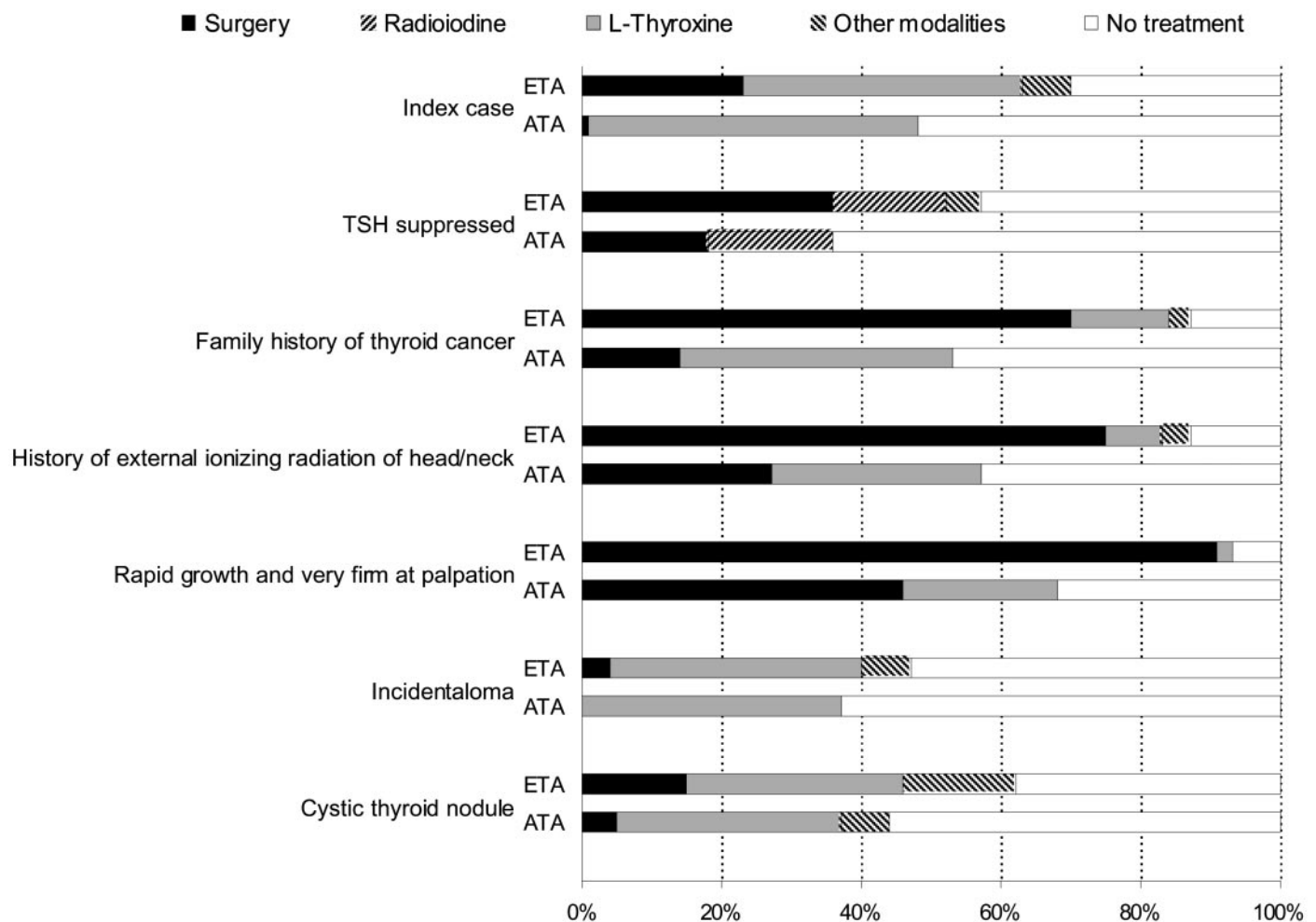


FIG. 7. Treatment options in nontoxic solitary thyroid nodules and preferences among ATA and ETA members according to questionnaire surveys (6, 7). Index case: “A 42-yr-old Caucasian woman is seen in your hospital/clinic due to a palpable mass in the left thyroid lobe. It is clinically judged to be a solitary 2 × 3-cm mobile nodule. There is no lymphadenopathy and no symptoms of thyroid dysfunction or anterior neck pain. The nodule has been present for 3 months, and the patient reports of moderate local neck discomfort. There is no family history of thyroid disease and no positive information of previous external irradiation. Your investigations, whatever these have been, have demonstrated a benign condition.” In the six listed variations, only one variable has been changed. Other modalities: Iodine, iodine together with L-T₄, or PEIT.

TABLE 13. Advantages and disadvantages of the treatment options in nontoxic solitary thyroid nodules

	Advantages	Disadvantages
Surgery	Nodule ablation Complete relief of symptoms Definite histological diagnosis	Inpatient High cost Surgical risk Vocal cord paralysis: ~1% Hypoparathyroidism: <1% Hypothyroidism: 1% ^a
Ethanol injection	Outpatient Relatively low cost No hypothyroidism	Repeat injections needed Low efficacy in larger nodules (>15 ml) Operator dependency Painful, causing reduced patient compliance Transient dysphonia: 1–2% Thyrotoxicosis (autoimmune response): ~1% Seepage of ethanol ^b Cytological/histological interpretation impeded in treated nodules
¹³¹ I ^c	Outpatient Low cost Few subjective side effects Nodule reduction: 45% within 2 yr	Contraceptives needed in fertile women Gradual reduction of the nodule Hypothyroidism: 10% within 5 yr Radiation thyroiditis: 1–2% Autoimmune response: <1% Long-term cancer risk unknown
L-T ₄	Outpatient Low cost Nodule growth slowed Prevents in part new nodule formation	Low efficacy Lifelong treatment Regrowth after cessation Adverse effects (bone, heart) Not feasible when TSH is suppressed

^a Hemithyroidectomy.

^b Side effects due to ethanol escaping outside the nodule or drainage of ethanol are rare (<1%) and comprise nerve damage, perinodular/periglandular fibrosis jeopardizing subsequent surgery, thrombosis of the jugular vein, and neck hematomas.

^c Treatment of the autonomous thyroid nodule.

and the vast majority will remain occult throughout life (46). In the centimetric incidentaloma, sized 1 × 1 cm, and without clinical suspicion of malignancy, the majority of North American and European thyroidologists (63% and 53%, respectively) prefer the conservative strategy of surveillance, including FNAB in case of growth (6, 7). One third support the use of TSH suppressive therapy (Fig. 7). We do not routinely perform FNAB in the subcentimetric nodule.

2. Solitary hot nodule. In the clinically euthyroid patient, autonomous thyroid nodules may present as a hot lesion on scintigraphy with varying degrees of extranodular suppression. The majority of these patients have subnormal or suppressed serum TSH levels. Treatment may be indicated due to either nodule size, causing compression of the adjacent structures, or cosmetic complaints. Additionally, treatment may prevent hyperthyroidism [annual risk, 4% (80)], particularly in patients with heart disease or in the elderly (282). The prevalence of carcinoma in the autonomous nodules (with or without hyperthyroidism) is low (283–286). Therefore, risk of cancer does not enter into the choice of therapy (282). These patients with subclinical hyperthyroidism (subnormal serum TSH but normal serum T₄ and T₃) have few or no symptoms or signs of hyperthyroidism, but the natural history is progression to overt hyperthyroidism with an annual risk of 4% (80). Because subclinical hyperthyroidism also has a detrimental effect on particularly the skeleton and the cardiovascular system (11, 12, 227–229), as discussed earlier, there is no reason to postpone treatment when facing this condition. Still, the majority of clinicians would refrain

from therapy until biochemical hyperthyroidism ensues (Fig. 7; Refs. 6 and 7).

a. ¹³¹I therapy. ¹³¹I is a simple, cost-effective, and safe procedure. A cure rate (normalization of scintigraphy and serum TSH) of 75% and a thyroid volume reduction of 40% (total as well as nodule volume) after a single dose of ¹³¹I can be anticipated (282). This is similar to that observed in toxic solitary thyroid nodules (287, 288). Side effects are few, consist of hypothyroidism in approximately 10% after 5 yr, and seem unrelated to any type of dose planning (282). The frequency of hypothyroidism is higher among patients who also have thyroid autoimmunity (289) or persistent uptake by extranodular thyroid tissue (290).

b. Surgery. Surgery and ¹³¹I are both effective, and the choice among them depends largely on their availability, some clinical features, and the personal preference of the patient and the physician. Either can also result in hypothyroidism. Surgery is often preferred for younger patients and those with larger nodules or in case of clinical or cytological suspicion of malignancy (Figs. 2 and 7). ¹³¹I is preferred for older patients and those with smaller nodules.

The preferred operation is a unilateral subtotal lobectomy. The frequency of complications due to surgery depends on several factors, and experience tends to reduce the rates with specialized training (232). Recurrence after surgery is rare, and the frequency of hypothyroidism is low, although up to 22% of patients with a toxic nodule develop hypothyroidism (291). Such a high frequency is probably explained by the fact

that one third of the patients in that study (291) had a bilateral subtotal thyroidectomy.

c. Other treatment. Reluctance to use radioactive tracers has been the incentive for numerous Italian centers to introduce percutaneous ethanol injection therapy (PEIT) during the last 12 yr, but none has compared PEIT with standard therapy (^{131}I or surgery), and the studies comprise only selected patients (292–311). The sclerosing properties of ethanol have been recognized for many years, and the mechanism of action is a coagulative necrosis and concomitant small vessel thrombosis. Disappearance of nodular hypervascularity is visualized during treatment and at follow-up by means of color or power Doppler sonography (displays the Doppler signal in color) and may improve the accuracy of the procedure (310). The procedure is performed under US guidance and on an outpatient basis. Markers of efficacy comprise thyroid function, thyroid scintigraphy, and sonography including changes in nodular volume. Complete cure, defined as normalization of serum TSH and scintigraphic reactivation of extranodular tissue, is achieved in 68–100% of solitary hot nodules (312). Partial cure, defined as detectable serum TSH and partial reactivation of extranodular tissue, is achieved in 0–39% (312). In the largest series comprising 429 patients from 5 Italian centers followed for 12 months, complete cure was achieved in 83% of the pretoxic nodules with a concomitant reduction in nodule volume of approximately 50% (301). The most important factors in predicting a clinically relevant response to PEIT are pretreatment nodule volume, thyroid hormone and TSH levels, and the experience of the operator. PEIT seems less effective in larger nodules (>15 ml; Refs. 294, 297, and 301).

One of the limitations is clearly the need of repeat ethanol injections to achieve complete cure, *e.g.*, a median of 4 sessions (range, 2–12), in the largest study (301). Side effects comprise radiating pain in 90% (and called for interruption of the treatment in 5%), hyperpyrexia in 8%, transient dysphonia in 5%, neck hematoma in 4%, and thrombosis of the ipsilateral jugular vein in one patient (301). Despite release of thyroid antigen after the injection procedure, formation of autoantibodies was seen in only 3% in one study with 5-yr follow-up (302). Hypothyroidism is rarely encountered (0–3%; Refs. 292–311), and appearance of Graves' disease has only been described in a case story (313). Long-term effects and side effects are reported scantily. The risk of fibrosis and adhesion to periglandular structures may seriously jeopardize subsequent surgery, a fact that has been given little attention (312, 314). One percent of ETA members recommend this treatment routinely, and it still remains to be introduced in North America (Fig. 7; Refs. 6 and 7). Although the complication rate seems low, the treatment is often uncomfortable, and its efficacy is operator dependent. PEIT seems most effective in small nodules and still requires multiple injections, and introduction into routine use cannot be recommended until comparative randomized studies testing PEIT against standard therapy have been undertaken.

Recently, a feasibility study from Rome described US-guided percutaneous interstitial laser photocoagulation (ILP) in two patients with huge autonomously functioning nodules, before thyroidectomy (315). Using low-energy out-

put (2–5 W), a significant coagulative necrosis in well defined areas was caused in the treated nodule. This novel approach appears feasible but needs confirmation in additional studies.

3. Solitary solid cold nodule

a. T_4 therapy. It is still common practice to use thyroid suppression in the management of solid thyroid nodules in the euthyroid patient (Fig. 7; Refs. 6 and 7). This treatment is intended to shrink existing nodules, considered to be a favorable sign, indicating that the nodules are benign and therefore do not require surgery. The method is also used to prevent the occurrence of new nodules. Most evidence suggests that changes in nodule size are independent of serum TSH levels, and treatment seems at best beneficial in a subgroup of patients with smaller solid nodules (316). Twenty percent or less of solitary nodules will actually regress significantly as a result of $L-T_4$ treatment, and regrowth is seen after cessation of therapy (316, 317). A 5-yr follow-up study confirms that the nodule-reducing effect of $L-T_4$ is insignificant (318). Likewise, a recent review suggests that only a subset of patients have a clinically significant ($\geq 50\%$) reduction of nodule size or arrest of nodule growth (319). It seems probable that a beneficial effect on pressure symptoms and/or cosmetic complaints in the responders is due also to the reduction in perinodular thyroid volume explained by a preserved TSH responsiveness of the tissue (320). In a recent meta-analysis of 6 randomized controlled trials comprising 346 patients, it was found that only 22% of patients treated with $L-T_4$, compared with 10% in the control groups, had a nodule volume decrease by more than 50% (321). Overall treatment response did not achieve statistical significance but was associated with a trend toward a reduction of more than 50% in nodule volume after 6–12 months of $L-T_4$ therapy.

Nodule growth may be suppressed or slowed, and the formation of new nodules may be prevented. Nodules grow less if serum TSH is suppressed below 0.1 mU/liter than if TSH is greater than 0.1 mU/liter (318). This degree of TSH suppression may, however, have adverse effects. Because suppressive therapy results (by definition) in subclinical hyperthyroidism, treated patients are at increased risk of atrial fibrillation, other cardiac abnormalities, and reduced bone density (11, 12, 228). These side effects, combined with the questionable efficacy, have led to recommendations that vary depending upon the age, sex, and menopausal status of the patient. $L-T_4$ suppressive therapy is least tempting in elderly patients and in postmenopausal women. If used at all, it should be reserved for small nodules (223) in which treatment is least necessary, *i.e.*, in younger patients. Although this treatment has been abandoned in our country (Denmark) (322), it is still the routine choice of nearly half of ATA and ETA members (Fig. 7). In view of the potential side effects and the questionable efficacy, it is surprising that 50–70% would aim at subnormal serum TSH levels and treat more than 1 yr (6, 7).

b. Surgery. The main indications for surgery are malignant or suspicious cytological features and symptoms due to the nodule itself, be it pressure related or cosmetic (Figs. 2 and

7). Certain clinical features raising the suspicion of thyroid malignancy (Table 2) are an indication for surgery, despite benign cytological features, as recommended by the majority of European and half of the American thyroidologists (Refs. 6 and 7; Fig. 7). In the clinically and cytologically benign thyroid nodule, surgery is recommended as the therapy of choice by 23% of European thyroidologists but hardly ever by North American thyroidologists (Refs. 6 and 7; Fig. 7).

Patients with a single thyroid nodule who are offered surgery will generally be managed with hemithyroidectomy (lobectomy; Ref. 179). The clinical recurrence rate is approximately 10% (323). Residual nodules, overlooked if imaging has been left out in the diagnostic approach, are a common cause of recurrence (178). Total thyroidectomy is not routinely indicated, although some authors choose this approach in case of a history of head and neck irradiation to avoid reoperation and to eliminate any subsequent risk of malignancy in irradiated thyroid glands (324). Postoperative thyroid suppression to avoid recurrence is questionable (239, 323, 325). The incidence of complications, particularly postoperative hypocalcemia and injuries to the recurrent laryngeal nerve, is low in the case of lobectomy (1% and 1–3%, respectively; Refs. 232, 326); correlates with the extent of the surgical procedure; and decreases with increasing experience and specialized training (327). Minimally invasive video-assisted thyroid lobectomy using endoscopic techniques may also affect the practice of thyroid surgery (328–330), but it is still implemented in only a few centers.

c. Other treatment. Absolute ethanol (70–100%) can cause permanent tissue ablation due to coagulative necrosis and local small vessel thrombosis. A single small dose of ethanol injected into benign cold solitary solid thyroid nodules results in relief of clinical symptoms in 50% of patients, based on a nodule volume reduction of approximately 50% (320, 331). Repeat (*i.e.*, seven or more) injections result in a reduction in nodule volume of 80% (332, 333). In one study, the total amount of ethanol administered per patient was on average 1.3 ml/ml nodular volume and never exceeded 20% of the nodule volume in each session (332). In this study, nodule reduction was unrelated to absolute or relative amount of ethanol injected but closely negatively related to pretreatment volume, although similar effects were obtained whether pretreatment nodule volume was larger or smaller than 15 ml. A limitation is the need of repeat ethanol injections to prevent renewed growth in solid cold nodules. Furthermore, the procedure is often painful despite local anesthesia, and complications such as periglandular adherence (impeding subsequent surgery in case of failure of the treatment), dysphonia, or mild fever must be anticipated in some (331). An autoimmune response with development of thyroid autoantibodies can be seen in up to 11% of treated patients (332). To minimize the risk of complications due to sudden increase in intranodular pressure and extranodular seepage of ethanol, each dose should probably not be higher than 20% of the pretreatment nodule volume. The special technical skill obtained at a center familiar with interventional sonography is required to reduce the risk of complications. The procedure should still be considered experimental and reserved for those who cannot or will not

undergo standard therapy. The experimental status is illustrated by only 1% of the ETA clinicians (6) and none of the ATA clinicians (7) advocating this therapy (Fig. 7).

Recently, we introduced US-guided ILP (Fig. 8; Ref. 334). In 16 patients treated with 1–3 W for a median of 8 min, one treatment resulted in an overall reduction in nodule volume of 46% and significant relief of pressure symptoms. This is surprisingly similar to results obtained with ethanol therapy (331). Apart from mild transient pain, the treatment was well tolerated. The advantage of thermal destruction is that the spread of energy, and thus the extent of tissue ablation, can be controlled as opposed to chemical destruction by injection of a fluid, *e.g.*, absolute ethanol. So far, therapy must be individualized on the basis of the patient's preference and risk of adverse effects. Additional data, including dose-response, preferably from prospective, randomized studies are needed before evaluating the possible future of this technique.

4. Solitary cyst. Evaluated by sonography, 15–25% of solitary thyroid nodules are cystic or predominantly cystic (163). The literature on thyroid cysts varies due to definitions depending on whether it is based on sonographic findings alone or addition of some descriptive cytological features, often indicating degenerative changes in a benign or neoplastic lesion (195). The main concern is the fear of malignancy. The inconsistency in malignancy rates is most likely due to the results being based on retrospective data in selected patients and different selection criteria for performing surgery (195). Although data indicate a lower frequency of malignancy in a cystic than in a solid thyroid lesion (195), it is certainly high enough to warrant considerable attention.

In an unselected population of patients with nodular thyroid disease, most cysts arise from benign thyroid tissue (335). In case of a benign lesion, simple aspiration is the treatment of choice, but the recurrence rate is 10–80% depending on the number of aspirations and the cyst volume (336, 337). That is, the greater the volume, the greater is the risk of recurrence (312). Still, the fact that a number of benign cystic nodules resolve spontaneously, given sufficient time (338), makes therapy superfluous in some. Indications for therapy are symptoms of compression or cosmetic complaints. Smaller cysts (<2–3 ml) are generally best left untreated (312). If larger, we always perform aspiration and FNAB of any residual nodule. Rarely (1–3%), supposed thyroid cysts do not originate from the follicular epithelium, but from the parathyroids. Such cysts often contain fluid that is transparent like water. Diagnosis is based on high concentrations of PTH and low or undetectable concentration of Tg in the aspirate (339).

a. T₄ therapy. In a prospective double-blind randomized study including only 20 patients, no effect on the recurrence of thyroid cysts after aspiration was seen in patients treated with L-T₄ when compared with patients receiving placebo (340). Thus, the use of L-T₄ by nearly one third of ATA and ETA thyroidologists is not based on evidence of its efficacy (Fig. 7; Refs. 6 and 7).

b. Surgery. Surgery should be considered, given certain clinical features (Table 2; Refs. 194 and 197). Some authors,

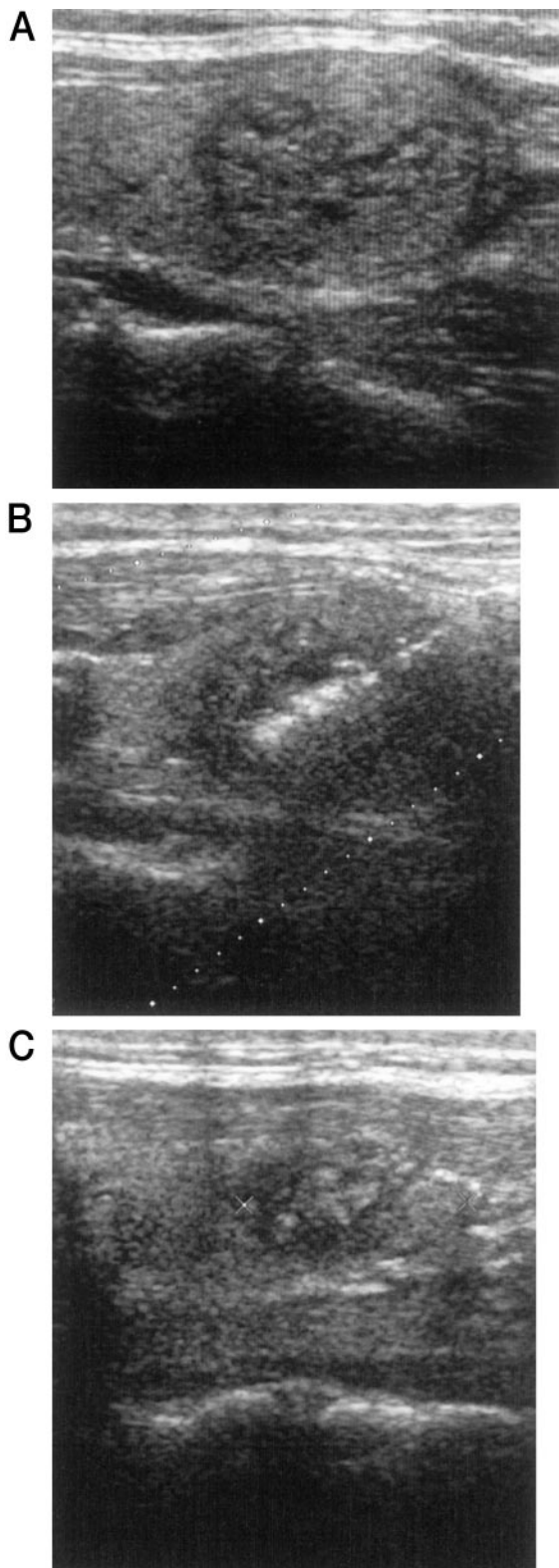


FIG. 8. Longitudinal ultrasonographic scan of the neck showing a solid nodule in the left thyroid lobe before ILP (A), during ILP (B), and at the follow-up 1 month after ILP (C). In B (60 sec after ILP has been initiated), a cylindrical echogenic area is seen centrally. In C, a hyperechogenic area representing scar tissue is seen in the center of the nodule. A small rim is untreated in the proximal and caudal part of the nodule.

as suggested by 5% and 15% of ATA and ETA thyroidologists, respectively (Fig. 7; Refs. 6 and 7), recommend thyroid lobectomy for histological verification even with benign cytology (341). Surgery is advisable in case of suspicious or persistently nondiagnostic cytology (198) after repeat aspiration, including a possible solid component and the wall of the lesion. It is evident that this is best obtained by US-guided FNAB (199). Surgical removal should indeed be considered if large cysts more than 3 cm recur after aspiration, because more than 10% of these lesions are reported to harbor thyroid cancer (342), despite a benign FNAB initially.

c. Other treatment. In 1981, Bean (343) suggested that renal cysts can be treated by PEIT. This success was the basis for introducing the new technique in the treatment of cystic lesions in other parenchymatous organs or soft tissues such as in the thyroid gland (312).

Various sclerosing agents, such as tetracycline, have been suggested, but results have been conflicting (344–352). In one nonrandomized study, instillation of tetracycline hydrochloride resulted in the cure of 91% of patients with recurrent thyroid cysts, but on the other hand, 86% were cured after aspiration alone (351). However, in the only randomized study, Hegedüs *et al.* (349) demonstrated that tetracycline treatment and isotonic saline were equally effective. Reported complications comprise local or radiating pain and transitory hyperpyrexia (349–352).

Seven studies using ethanol instillation in thyroid cysts have been published (306, 353–358), comprising 214 patients treated with PEIT. The success rate, defined as near disappearance or marked (>50%) size reduction, varies from 61–95%. In the only placebo-controlled study with just one treatment, the short-term (1 month) success rate was 80% in the group treated with ethanol and 30% in the group treated with simple aspiration (353). Long-term follow-up (12 months) in 32 consecutive patients treated once with ethanol confirms the preliminary results obtained in the smaller randomized study (353). Other studies lack an evaluation of success rate based on the number of ethanol instillations and an adequate control group (306, 354–358).

Side effects of ethanol instillation into cystic thyroid nodules seem to be few and are generally described as mild and transient, and pain is less pronounced than that described after injections into solid structures (312). However, serious side effects due to seepage outside the capsule causing considerable fibrosis and thrombosis of the jugular vein have been described (359). PEIT should still be regarded as an experimental treatment and be performed only by skilled operators. Five percent of ETA members have already introduced this option in a routine clinical setting (Fig. 7; Refs. 11 and 12).

Data from experimental treatment, whether in autonomously functioning nodules, solid cold nodules, or cystic nodules, are at large based on nonrandomized studies comprising selected patients. What is needed now is cost-benefit studies comparing a standardized ethanol regimen with standard treatment in properly conducted comparative randomized studies. The same certainly holds for future research into laser therapy.

Table 13 summarizes advantages and drawbacks of the

therapeutical options in the treatment of solitary hot, cold, and cystic thyroid nodules.

VII. Unresolved Issues and Future Perspectives

Although SNG affects millions of individuals, also in iodine-sufficient regions, many fundamental aspects pertaining to etiology, natural history, and diagnostic as well as therapeutic management of the disorder remain unclarified.

Although major environmental risk factors such as iodine deficiency and cigarette smoking are involved in the etiology, an increasing body of evidence suggests that heredity is equally, if not more, important. Current strategies, including whole genome scanning in multiply affected families, aim at clarifying the molecular basis of the genetic susceptibility and aspects of the gene-environment interaction, thereby possibly leading to more focused preventive actions in the future.

Until such strategies bear fruit, an intensified debate on cost-effective management of nodular thyroid disease is necessary. There is agreement on the central role of FNAB in addition to serum TSH determination in the initial evaluation of such individuals. Evidence suggests that US guidance increases adequacy of sampling. An increasing number of specialists use diagnostic imaging (mainly sonography and scintigraphy), which is pertinent when selecting patients for nonsurgical therapy. Although new isotopes, contrast media, Doppler technology, and three-dimensional investigations have increased sensitivity, specificity for detecting thyroid malignancy still needs to be improved. More promising, however, is the search for non-TSH related growth factors. The combination of new molecular genetic techniques applied on the easily attainable thyroid tissue, by FNAB, should lead to an increasing understanding of the pathogenesis of nodular thyroid disease and a better characterization of phenotypes.

Treatment still focuses very much on L-T₄, although at best this treatment slows growth for a limited time period in a minority of patients at the cost of significant side effects related to bone and the cardiovascular system. The available evidence suggests that L-T₄ should be abandoned in the euthyroid individual. Surgery should be recommended for younger patients, for those with a large goiter (especially if intrathoracic), and in case of clinical or cytological suspicion of malignancy. However, in our opinion, ¹³¹I should have a higher priority in the treatment hierarchy. At present, this option is sparsely used. It needs to be clarified whether this is based on tradition, availability, fear of thyroid or nonthyroid malignancy, or regulations allowing a low outpatient ¹³¹I-dose. The latter can to some extent be overcome by the recently available recombinant human TSH, which seems to be able to double the iodine uptake in multinodular nontoxic goiter. When it comes to the benign solitary nodule, the research focus is on ethanol injection and laser photocoagulation as nonsurgical alternatives to L-T₄ therapy, which should be abandoned.

Independent of phenotype, much of the discrepancy in treatment recommendations stems from the lack of adequately performed prospective randomized studies, taking

effect, side effects, patient satisfaction, and cost into consideration. For such studies to have any impact, the development and use of disease-specific quality-of-life questionnaires are mandatory.

Finally, it should be emphasized that much of our knowledge is based on what experts advise. We have little idea of whether the large majority of patients, managed by family doctors and nonthyroid specialists, are treated according to this advice, which in this case, is not even very clear.

Acknowledgments

We thank a number of colleagues who during the years have contributed to a large number of studies that, to a high degree, form the basis of this review. In particular, we thank Thomas H. Brix, M.D., from our own institution, as well as Jens Faber, M.D.; Jens M. Hansen, M.D.; Steen Karstrup, M.D.; Anne Jarlov, M.D.; and Birte Nygaard, M.D., all from the University of Copenhagen. We are indebted to all of the clinician colleagues of the ETA and the ATA, as well as the Danish Endocrine Society, who by answering extensive questionnaires provided valuable data on management aspects of nodular thyroid diseases.

Address all correspondence and requests for reprints to: Laszlo Hegedüs, M.D., D.M.Sc., Department of Endocrinology and Metabolism, Odense University Hospital, DK-5000 Odense C, Denmark. E-mail: laszlo.hegedus@ouh.fyns-amt.dk

This work was supported by the Agnes and Knut Mørks Foundation, The A.P. Møller Support Foundation, The Novo Nordisk Foundation, and K.A. Rohde's Foundation.

References

1. **Hegedüs L, Gerber H** 2000 Multinodular goiter. In: de Groot LJ, Jameson JL, eds. *Endocrinology*. Philadelphia: WB Saunders: 1517–1528
2. **Jarlov AE, Nygaard B, Hegedüs L, Hartling SG, Hansen JM** 1998 Observer variation in the clinical and laboratory evaluation of patients with thyroid dysfunction and goiter. *Thyroid* 8:393–398
3. **Giuffrida D, Gharib H** 1995 Controversies in the management of cold, hot, and occult thyroid nodules. *Am J Med* 99:642–650
4. **Hegedüs L** 2001 Thyroid ultrasound. *Endocrinol Metab Clin North Am* 30:339–360
5. **Marqusee E, Benson CB, Frates MC, Doubilet PM, Larsen PR, Cibas ES, Mandel SJ** 2000 Usefulness of ultrasonography in the management of nodular thyroid disease. *Ann Intern Med* 133: 696–700
6. **Bennedbæk FN, Perrild H, Hegedüs L** 1999 Diagnosis and treatment of the solitary thyroid nodule. Results of a European survey. *Clin Endocrinol (Oxf)* 50:357–363
7. **Bennedbæk FN, Hegedüs L** 2000 Management of the solitary thyroid nodule: results of a North American survey. *J Clin Endocrinol Metab* 85:2493–2498
8. **Bonnema SJ, Bennedbæk FN, Wiersinga WM, Hegedüs L** 2000 Management of the nontoxic multinodular goitre: a European questionnaire study. *Clin Endocrinol (Oxf)* 53:5–12
9. **Bonnema SJ, Bennedbæk FN, Ladenson PW, Hegedüs L** 2002 Management of the nontoxic multinodular goiter: a North American survey. *J Clin Endocrinol Metab* 87:112–117
10. **Hegedüs L** 2000 Nonisotopic techniques of thyroid imaging. In: Braverman LE, Utiger R, eds. *The thyroid: a fundamental and clinical text*. Philadelphia: Lippincott, Williams and Williams; 432–440
11. **Parle JV, Maisonneuve P, Sheppard MC, Boyle P, Franklyn JA** 2001 Prediction of all-cause and cardiovascular mortality in elderly people from one low serum thyrotropin result: a 10-year cohort study. *Lancet* 358:861–865
12. **Toft AD** 2001 Clinical practice Subclinical hyperthyroidism. *N Engl J Med* 345:512–516
13. **Derwahl M, Broecker M, Kraiem Z** 1999 Clinical review 101:

- thyrotropin may not be the dominant growth factor in benign and malignant thyroid tumors. *J Clin Endocrinol Metab* 84:829–834
14. **Derwahl M, Studer H** 2000 Multinodular goitre: 'much more to it than simply iodine deficiency'. *Baillieres Clin Endocrinol Metab* 14:577–600
 15. **Studer H, Derwahl M** 1995 Mechanisms of nonneoplastic endocrine hyperplasia—a changing concept: a review focused on the thyroid gland. *Endocr Rev* 16:411–426
 16. **Meier CA** 2000 Thyroid nodules: pathogenesis, diagnosis and treatment. *Baillieres Clin Endocrinol Metab* 14:559–575
 17. **Krohn K, Paschke R** 2001 Progress in understanding the etiology of thyroid autonomy. *J Clin Endocrinol Metab* 86:3336–3345
 18. **Brix TH, Hegedüs L** 2000 Genetic and environmental factors in the aetiology of simple goitre. *Ann Med* 32:153–156
 19. **Samuels MH** 2001 Evaluation and treatment of sporadic nontoxic goitre—some answers and more questions. *J Clin Endocrinol Metab* 86:994–997
 20. **Franklyn JA** 2000 Lack of consensus in Europe in the management of multinodular goitre. *Clin Endocrinol (Oxf)* 53:3–4
 21. **Brix TH, Kyvik KO, Hegedüs L** 1999 Major role of genes in the etiology of simple goiter in females: a population-based twin study. *J Clin Endocrinol Metab* 84:3071–3075
 22. **Brix TH, Kyvik KO, Hegedüs L** 2000 A population-based study of chronic autoimmune hypothyroidism in Danish twins. *J Clin Endocrinol Metab* 85:536–539
 23. **Brix TH, Kyvik KO, Christensen K, Hegedüs L** 2001 Evidence for a major role of heredity in Graves' disease: a population-based study of two Danish twin cohorts. *J Clin Endocrinol Metab* 86:930–934
 24. **Medeiros-Neto G** 2000 Iodine deficiency disorders. In: de Groot LJ, Jameson JL, eds. *Endocrinology*. Philadelphia: WB Saunders; 1529–1539
 25. **Hegedüs L** 1990 Thyroid size determined by ultrasound. Influence of physiological factors and non-thyroidal disease. *Dan Med Bull* 37:249–263
 26. **Bertelsen JB, Hegedüs L** 1994 Cigarette smoking and the thyroid. *Thyroid* 4:327–331
 27. **Brix TH, Hansen PS, Kyvik KO, Hegedüs L** 2000 Cigarette smoking and risk of clinically overt thyroid disease: a population-based twin case-control study. *Arch Intern Med* 160:661–666
 28. **Gaitan E** 2000 Environmental natural goitrogens. In: Peter F, Wiersinga WM, Hostalek U, eds. *The thyroid and environment*. New York: Schattauer; 69–78
 29. **Orenstein H, Peskind A, Raskind MA** 1988 Thyroid disorders in female psychiatric patients with panic disorder or agoraphobia. *Am J Psychiatry* 145:1428–1430
 30. **Gittoes NJ, Franklyn JA, Sarne OH, Refetoff S, Sheppard MC** 2000 Iodine deficiency disorders. In: de Groot LJ, Jameson JL, eds. *Endocrinology*. Philadelphia: WB Saunders; 1361–1398
 31. **Surks MI, Sievert R** 1995 Drugs and thyroid function. *N Engl J Med* 333:1688–1694
 32. **Farwell AP, Braverman LE** 1996 Inflammatory thyroid disorders. *Otolaryngol Clin North Am* 29:541–556
 33. **Knudsen N, Bülow I, Laurberg P, Perrild H, Ovesen L, Jørgensen T** 2001 Alcohol consumption is associated with reduced prevalence of goitre and solitary thyroid nodules. *Clin Endocrinol (Oxf)* 55:41–46
 34. **Hegedüs L, Rasmussen N, Ravn V, Kastrup J, Krogsgaard K, Aldershvile J** 1988 Independent effects of liver disease and chronic alcoholism on thyroid function and size: the possibility of a toxic effect of alcohol on the thyroid gland. *Metabolism* 37:229–233
 35. **Malamos B, Koutras DA, Kostamis P, Kralios AC, Rigopoulos G, Zerefos N** 1966 Endemic goiter in Greece: epidemiologic and genetic studies. *J Clin Endocrinol Metab* 26:688–695
 36. **Bartels ED** 1941 Heredity in Graves' disease. With remarks on heredity in toxic adenoma in the thyroid, non-toxic goitre and myxoedema. Dissertation, University of Copenhagen
 37. **Martin L, Fisher RA** 1945 The hereditary and familial aspects of exophthalmic goitre and nodular goitre. *Q J Med* 14:207–219
 38. **Malamos B, Koutras DA, Kostamis P, Rigopoulos GA, Zerefos NS, Yataganas XA** 1967 Endemic goitre in Greece: a study of 379 twin pairs. *J Med Genet* 4:16–18
 39. **Greig WR, Boyle JA, Duncan A, Nicol J, Gray MJ, Buchanan WW, McGirr EM** 1967 Genetic and non-genetic factors in simple goitre formation: evidence from a twin study. *Q J Med* 36:175–188
 40. **Corral J, Martin C, Perez R, Sanchez I, Mories MT, San Millan JL, Miralles JM, Gonzalez-Sarmiento R** 1993 Thyroglobulin gene point mutation associated with non-endemic simple goitre. *Lancet* 341:462–464
 41. **Neumann S, Willgerodt H, Ackermann F, Reske A, Jung M, Reis A, Paschke R** 1999 Linkage of familial euthyroid goiter to the multinodular goiter-1 locus and exclusion of the candidate genes thyroglobulin, thyroperoxidase, and Na⁺/I⁻ symporter. *J Clin Endocrinol Metab* 84:3750–3756
 42. **Bignell GR, Canzian F, Shayeghi M, Stark M, Shugart YY, Biggs P, Mangion J, Hamoudi R, Rosenblatt J, Buu P, Sun S, Stoffer SS, Goldgar DE, Romeo G, Houlston RS, Narod SA, Stratton MR, Foulkes WD** 1997 Familial nontoxic multinodular thyroid goiter locus maps to chromosome 14q but does not account for familial nonmedullary thyroid cancer. *Am J Hum Genet* 61:1123–1130
 43. **McKay JD, Williamson J, Lesueur F, Stark M, Duffield A, Canzian F, Romeo G, Hoffman L** 1999 At least three genes account for familial papillary thyroid carcinoma: TCO and MNG1 excluded as susceptibility loci from a large Tasmanian family. *Eur J Endocrinol* 141:122–125
 44. **Capon F, Tacconelli A, Giardina E, Sciacchitano S, Bruno R, Tassi V, Trischitta V, Filetti S, Dallapiccola B, Novelli G** 2000 Mapping a dominant form of multinodular goiter to chromosome Xp22. *Am J Hum Genet* 67:1004–1007
 45. **Tomer Y, Barbesino G, Keddache M, Greenberg DA, Davies TF** 1997 Mapping of a major susceptibility locus for Graves' disease (GD-1) to chromosome 14q31. *J Clin Endocrinol Metab* 82:1645–1648
 46. **Wang C, Crapo LM** 1997 The epidemiology of thyroid disease and implications for screening. *Endocrinol Metab Clin North Am* 26:189–218
 47. **Berghout A, Wiersinga WM, Smits NJ, Touber JL** 1987 Determinants of thyroid volume as measured by ultrasonography in healthy adults in a non-iodine deficient area. *Clin Endocrinol (Oxf)* 26:273–280
 48. **Gutekunst R, Smolarek H, Hasenpusch U, Stubbe P, Friedrich HJ, Wood WG, Scriba PC** 1986 Goitre epidemiology: thyroid volume, iodine excretion, thyroglobulin and thyrotropin in Germany and Sweden. *Acta Endocrinol (Copenh)* 112:494–501
 49. **Knudsen N, Perrild H, Christiansen E, Rasmussen S, Dige-Petersen H, Jørgensen T** 2000 Thyroid structure and size and two-year follow-up of solitary cold thyroid nodules in an unselected population with borderline iodine deficiency. *Eur J Endocrinol* 142:224–230
 50. **Nygaard B, Gideon P, Dige-Petersen H, Jespersen N, Sølling K, Veje A** 1993 Thyroid volume and morphology and urinary iodine excretion in a Danish municipality. *Acta Endocrinol (Copenh)* 129:505–510
 51. **Knudsen N, Bülow I, Jørgensen T, Laurberg P, Ovesen L, Perrild H** 2000 Goitre prevalence and thyroid abnormalities at ultrasonography: a comparative epidemiological study in two regions with slightly different iodine status. *Clin Endocrinol (Oxf)* 53:479–485
 52. **Laurberg P, Pedersen IB, Knudsen N, Ovesen L, Andersen S** 2001 Environmental iodine intake affects the type of non-malignant thyroid disease. *Thyroid* 11:457–469
 53. **Li M, Liu DR, Qu CY, Zhang PY, Qian QD, Zhang CD, Jia QZ, Wang HX, Eastman CJ, Boyages SC** 1987 Endemic goitre in central China caused by excessive iodine intake. *Lancet* 2:257–259
 54. **Tunbridge WM, Evered DC, Hall R, Appleton D, Brewis M, Clark F, Evans JG, Young E, Bird T, Smith PA** 1977 The spectrum of thyroid disease in a community: the Wickham survey. *Clin Endocrinol (Oxf)* 7:481–493
 55. **Vander JB, Gaston EA, Dawber TR** 1954 Significance of solitary nontoxic thyroid nodules. Preliminary report. *N Engl J Med* 251:970
 56. **Baldwin DB, Rowett D** 1978 Incidence of thyroid disorders in Connecticut. *JAMA* 239:742–744
 57. **Vander JB, Gaston EA, Dawber TR** 1968 The significance of nontoxic thyroid nodules. Final report of a 15-year study of the incidence of thyroid malignancy. *Ann Intern Med* 69:537–540
 58. **Jarlov AE, Hegedüs L, Gjørup T, Hansen JM** 1991 Observer vari-

- ation in the clinical assessment of the thyroid gland. *J Intern Med* 229:159–161
59. **Jarlov EA, Hegedüs L, Gjørup T, Hansen MJ** 1992 Inadequacy of the WHO classification of the thyroid gland. *Thyroidology* 4: 107–110
 60. **Brander A, Viikinkoski P, Nickels J, Kivisaari L** 1991 Thyroid gland: US screening in a random adult population. *Radiology* 181: 683–687
 61. **Tan GH, Gharib H** 1997 Thyroid incidentalomas: management approaches to nonpalpable nodules discovered incidentally on thyroid imaging. *Ann Intern Med* 126:226–231
 62. **Belfiore A, La Rosa GL, La Porta GA, Giuffrida D, Milazzo G, Lupo L, Regalbuto C, Vigneri R** 1992 Cancer risk in patients with cold thyroid nodules: relevance of iodine intake, sex, age, and multinodularity. *Am J Med* 93:363–369
 63. **Mortensen JD, Woolner LB, Bennett WA** 1955 Gross and microscopic findings in clinically normal thyroid glands. *J Clin Endocrinol Metab* 15:1270–1280
 64. **Ashcraft MW, Van Herle AJ** 1981 Management of thyroid nodules. I. History and physical examination, blood tests, x-ray tests, and ultrasonography. *Head Neck Surg* 3:216–230
 65. **Bonnema SJ, Bertelsen H, Mortensen J, Andersen PB, Knudsen DU, Bastholt L, Hegedüs L** 1999 The feasibility of high dose iodine 131 treatment as an alternative to surgery in patients with a very large goiter: effect on thyroid function and size and pulmonary function. *J Clin Endocrinol Metab* 84:3636–3641
 66. **Vanderpump MP, Tunbridge WM, French JM, Appleton D, Bates D, Clark F, Grimley EJ, Hasan DM, Rodgers H, Tunbridge F** 1995 The incidence of thyroid disorders in the community: a twenty-year follow-up of the Whickham Survey. *Clin Endocrinol (Oxf)* 43:55–68
 67. **Rallison ML, Dobyns BM, Meikle AW, Bishop M, Lyon JL, Stevens W** 1991 Natural history of thyroid abnormalities: prevalence, incidence, and regression of thyroid diseases in adolescents and young adults. *Am J Med* 91:363–370
 68. **Berghout A, Wiersinga WM, Smits NJ, Touber JL** 1990 Interrelationships between age, thyroid volume, thyroid nodularity, and thyroid function in patients with sporadic nontoxic goiter. *Am J Med* 89:602–608
 69. **Berghout A, Wiersinga WM, Drexhage HA, Smits NJ, Touber JL** 1990 Comparison of placebo with L-thyroxine alone or with carbimazole for treatment of sporadic non-toxic goitre. *Lancet* 336: 193–197
 70. **Wesche MF, Wiersinga WM, Smits NJ** 1998 Lean body mass as a determinant of thyroid size. *Clin Endocrinol (Oxf)* 48:701–706
 71. **Andersen-Ranberg K, Jeune B, Høier-Madsen M, Hegedüs L** 1999 Thyroid function, morphology and prevalence of thyroid disease in a population-based study of Danish centenarians. *J Am Geriatr Soc* 47:1238–1243
 72. **Støvning RK, Bennedbæk FN, Hegedüs L, Hagen C** 2001 Evidence of diffuse atrophy of the thyroid gland in patients with anorexia nervosa. *Int J Eat Disord* 29:230–235
 73. **Dormitzer PR, Ellison PT, Bode HH** 1989 Anomalously low endemic goiter prevalence among Efe pygmies. *Am J Phys Anthropol* 78:527–531
 74. **Furlanetto TW, Nguyen LQ, Jameson JL** 1999 Estradiol increases proliferation and down-regulates the sodium/iodide symporter gene in FRTL-5 cells. *Endocrinology* 140:5705–5711
 75. **Kuma K, Matsuzuka F, Kobayashi A, Hirai K, Morita S, Miyauchi A, Katayama S, Sugawara M** 1992 Outcome of long standing solitary thyroid nodules. *World J Surg* 16:583–587
 76. **Gemsensjager E, Staub JJ, Girard J, Heitz P** 1976 Preclinical hyperthyroidism in multinodular goiter. *J Clin Endocrinol Metab* 43:810–816
 77. **Elte JW, Bussemaker JK, Haak A** 1990 The natural history of euthyroid multinodular goitre. *Postgrad Med J* 66:186–190
 78. **Wiener JD, de Vries AA** 1979 On the natural history of Plummer's disease. *Clin Nucl Med* 4:181–190
 79. **Belfiore A, Sava L, Runello F, Tomaselli L, Vigneri R** 1983 Solitary autonomously functioning thyroid nodules and iodine deficiency. *J Clin Endocrinol Metab* 56:283–287
 80. **Sandrock D, Olbricht T, Emrich D, Benker G, Reinwein D** 1993 Long-term follow-up in patients with autonomous thyroid adenoma. *Acta Endocrinol (Copenh)* 128:51–55
 81. **Hamburger JI** 1980 Evolution of toxicity in solitary nontoxic autonomously functioning thyroid nodules. *J Clin Endocrinol Metab* 50:1089–1093
 82. **Blum M, Biller BJ, Bergman DA** 1974 The thyroid cork. Obstruction of the thoracic inlet due to retroclavicular goiter. *JAMA* 227: 189–191
 83. **Wallace C, Siminoski K** 1996 The Pemberton sign. *Ann Intern Med* 125:568–569
 84. **Shaha AR, Alfonso AE, Jaffe BM** 1989 Operative treatment of substernal goiters. *Head Neck* 11:325–330
 85. **Katlic MR, Grillo HC, Wang CA** 1985 Substernal goiter. Analysis of 80 patients from Massachusetts General Hospital. *Am J Surg* 149:283–287
 86. **Netterville JL, Coleman SC, Smith JC, Smith MM, Day TA, Burkey BB** 1998 Management of substernal goiter. *Laryngoscope* 108: 1611–1617
 87. **Moron JC, Singer JA, Sardi A** 1998 Retrosternal goiter: a six-year institutional review. *Am Surg* 64:889–893
 88. **Meysman M, Noppen M, Vincken W** 1996 Effect of posture on the flow-volume loop in two patients with euthyroid goiter. *Chest* 110:1615–1618
 89. **Shaha A, Alfonso A, Jaffe BM** 1987 Acute airway distress due to thyroid pathology. *Surgery* 102:1068–1074
 90. **Mellièrè D, Saada F, Etienne G, Becquemin JP, Bonnet F** 1988 Goiter with severe respiratory compromise: evaluation and treatment. *Surgery* 103:367–373
 91. **Gittoes NJ, Miller MR, Daykin J, Sheppard MC, Franklyn JA** 1996 Upper airways obstruction in 153 consecutive patients presenting with thyroid enlargement. *Br Med J* 312:484
 92. **Anders HJ** 1998 Compression syndromes caused by substernal goitres. *Postgrad Med J* 74:327–329
 93. **van Doorn LG, Kranendonk SE** 1996 Partial unilateral phrenic nerve paralysis caused by a large intrathoracic goitre. *Neth J Med* 48:216–219
 94. **Gurlek A, Usman A, Bayraktar M, Ozenc A** 2000 Horner's syndrome: recovery after surgical excision of intrathoracic benign multinodular goiter. *Endocr J* 47:643–644
 95. **Rieu M, Bekka S, Sambor B, Berrod JL, Fombeur JP** 1993 Prevalence of subclinical hyperthyroidism and relationship between thyroid hormonal status and thyroid ultrasonographic parameters in patients with non-toxic nodular goitre. *Clin Endocrinol (Oxf)* 39:67–71
 96. **Jarlov AE, Hegedüs L, Gjørup T, Hansen JE** 1991 Accuracy of the clinical assessment of thyroid size. *Dan Med Bull* 38:87–89
 97. **Hegedüs L, Karstrup S, Rasmussen N** 1986 Evidence of cyclic alterations of thyroid size during the menstrual cycle in healthy women. *Am J Obstet Gynecol* 155:142–145
 98. **Buckels JA, Webb AM, Rhodes A** 1983 Is paroxysmal thyroid swelling due to phaeochromocytoma a forgotten physical sign? *Br Med J (Clin Res Ed)* 287:1206–1207
 99. **Loh KC** 1997 Familial nonmedullary thyroid carcinoma: a meta-review of case series. *Thyroid* 7:107–113
 100. **Refetoff S, Harrison J, Karanfilski BT, Kaplan EL, de Groot LJ, Bekerman C** 1975 Continuing occurrence of thyroid carcinoma after irradiation to the neck in infancy and childhood. *N Engl J Med* 292:171–175
 101. **Shibata Y, Yamashita S, Masyakin VB, Panasyuk GD, Nagataki S** 2001 15 Years after Chernobyl: new evidence of thyroid cancer. *Lancet* 358:1965–1966
 102. **Rieger R, Pimpl W, Money S, Rettenbacher L, Galvan G** 1989 Hyperthyroidism and concurrent thyroid malignancies. *Surgery* 106:6–10
 103. **Hamming JF, Goslings BM, van Steenis GJ, van Ravenswaay CH, Hermans J, van de Velde CJ** 1990 The value of fine-needle aspiration biopsy in patients with nodular thyroid disease divided into groups of suspicion of malignant neoplasms on clinical grounds. *Arch Intern Med* 150:113–116
 104. **Laurberg P, Pedersen KM, Hreidarsson A, Sigfusson N, Iversen E, Knudsen PR** 1998 Iodine intake and the pattern of thyroid disorders: a comparative epidemiological study of thyroid abnormalities in the elderly in Iceland and in Jutland, Denmark. *J Clin Endocrinol Metab* 83:765–769
 105. **Aghini-Lombardi F, Antonangeli L, Martino E, Vitti P, Mac-**

- cherini D, Leoli F, Rago T, Grasso L, Valeriano R, Balestrieri A, Pinchera A 1999 The spectrum of thyroid disorders in an iodine-deficient community: the Pescopagano survey. *J Clin Endocrinol Metab* 84:561–566
106. Nygaard B, Knudsen JH, Hegedüs L, Veje A, Hansen JE 1997 Thyrotropin receptor antibodies and Graves' disease, a side-effect of 131I treatment in patients with nontoxic goiter. *J Clin Endocrinol Metab* 82:2926–2930
 107. Feldt-Rasmussen U, Bech K, Date J 1979 Serum thyroglobulin in patients with toxic and non-toxic goitres compared to sex- and age-matched control subjects. *Acta Endocrinol (Copenh)* 91:264–270
 108. Date J, Feldt-Rasmussen U, Blichert-Toft M, Hegedüs L, Graversen HP 1996 Long-term observation of serum thyroglobulin after resection of nontoxic goiter and relation to ultrasonographically demonstrated relapse. *World J Surg* 20:351–356
 109. Cohen R, Campos JM, Salaun C, Heshmati HM, Kraimps JL, Proye C, Sarfati E, Henry JF, Niccoli-Sire P, Modigliani E 2000 Preoperative calcitonin levels are predictive of tumor size and postoperative calcitonin normalization in medullary thyroid carcinoma. Groupe d'Etudes des Tumeurs a Calcitonine (GETC). *J Clin Endocrinol Metab* 85:919–922
 110. Uwaifo GI, Remaley AT, Stene M, Reynolds JC, Yen PM, Snider RH, Becker KL, Sarris NJ 2001 A case of spurious hypercalcitoninemia: a cautionary tale on the use of plasma calcitonin assays in the screening of patients with thyroid nodules for neoplasia. *J Endocrinol Invest* 24:361–369
 111. Tommasi M, Brocchi A, Cappellini A, Raspanti S, Mannelli M 2001 False serum calcitonin high levels using a non-competitive two-site IRMA. *J Endocrinol Invest* 24:356–360
 112. Hahm JR, Lee MS, Min YK, Lee MK, Kim KW, Nam SJ, Yang JH, Chung JH 2001 Routine measurement of serum calcitonin is useful for early detection of medullary thyroid carcinoma in patients with nodular thyroid diseases. *Thyroid* 11:73–80
 113. Grauer A, Raue F, Ziegler R 1998 Clinical usefulness of a new chemiluminescent two-site immunoassay for human calcitonin. *Exp Clin Endocrinol Diabetes* 106:353–359
 114. Kotzmann H, Schmidt A, Scheuba C, Kaserer K, Watschinger B, Soeregi G, Niederle B, Vierhapper H 1999 Basal calcitonin levels and the response to pentagastrin stimulation in patients after kidney transplantation or on chronic hemodialysis as indicators of medullary carcinoma. *Thyroid* 9:943–947
 115. Vlaeminck-Guillem V, D'herbomez M, Pigny P, Fayard A, Batters C, Decoux M, Wemeau JL 2001 Pseudohypoparathyroidism Ia and hypercalcitoninemia. *J Clin Endocrinol Metab* 86:3091–3096
 116. Erdogan MF, Guellue S, Baskal N, Uysal AR, Kamel N, Erdogan G 1997 Omeprazole: calcitonin stimulation test for the diagnosis follow-up and family screening in medullary thyroid carcinoma. *J Clin Endocrinol Metab* 82:897–899
 117. Marsh DJ, Mulligan LM, Eng C 1997 RET proto-oncogene mutations in multiple endocrine neoplasia type 2 and medullary thyroid carcinoma. *Horm Res* 47:168–178
 118. Vierhapper H, Raber W, Bieglmayer C, Kaserer K, Weinhausl A, Niederle B 1997 Routine measurement of plasma calcitonin in nodular thyroid diseases. *J Clin Endocrinol Metab* 82:1589–1593
 119. Rude RK, Singer FR 1977 Comparison of serum calcitonin levels after a 1-minute calcium injection and after pentagastrin injection in the diagnosis of medullary thyroid carcinoma. *J Clin Endocrinol Metab* 44:980–983
 120. Kaserer K, Scheuba C, Neuhold N, Weinhaeusel A, Vierhapper H, Haas OA, Niederle B 1998 C-cell hyperplasia and medullary thyroid carcinoma in patients routinely screened for serum calcitonin. *Am J Surg Pathol* 22:722–728
 121. Gibson WC, Peng TC, Croker BP 1981 C-cell nodules in adult human thyroid. A common autopsy finding. *Am J Clin Pathol* 75:347–350
 122. Rieu M, Lame MC, Richard A, Lissak B, Sambort B, Vuong-Ngoc P, Berrod JL, Fombeur JP 1995 Prevalence of sporadic medullary thyroid carcinoma: the importance of routine measurement of serum calcitonin in the diagnostic evaluation of thyroid nodules. *Clin Endocrinol (Oxf)* 42:453–460
 123. Niccoli P, Wion-Barbot N, Caron P, Henry JF, de Micco C, Saint Andre JP, Bigorgne JC, Modigliani E, Conte-Devolx B 1997 Interest of routine measurement of serum calcitonin: study in a large series of thyroidectomized patients. The French Medullary Study Group. *J Clin Endocrinol Metab* 82:338–341
 124. Pacini F, Fontanelli M, Fugazzola L, Elisei R, Romei C, Di Coscio G, Miccoli P, Pinchera A 1994 Routine measurement of serum calcitonin in nodular thyroid diseases allows the preoperative diagnosis of unsuspected sporadic medullary thyroid carcinoma. *J Clin Endocrinol Metab* 78:826–829
 125. Ozgen AG, Hamulu F, Bayraktar F, Yilmaz C, Tuzun M, Yetkin E, Tuncyurek M, Kabalak T 1999 Evaluation of routine basal serum calcitonin measurement for early diagnosis of medullary thyroid carcinoma in seven hundred seventy-three patients with nodular goiter. *Thyroid* 9:579–582
 126. Singer PA, Cooper DS, Daniels GH, Ladenson PW, Greenspan FS, Levy EG, Braverman LE, Clark OH, McDougall IR, Ain KV, Dorfman SG 1996 Treatment guidelines for patients with thyroid nodules and well-differentiated thyroid cancer. American Thyroid Association. *Arch Intern Med* 156:2165–2172
 127. 2001 AACE/AAES medical/surgical guidelines for clinical practice: management of thyroid carcinoma. American Association of Clinical Endocrinologists. American College of Endocrinology. *Endocr Pract* 7:202–220
 128. Tan GH, Gharib H, Reading CC 1995 Solitary thyroid nodule. Comparison between palpation and ultrasonography. *Arch Intern Med* 155:2418–2423
 129. Berghout A, Wiersinga WM, Smits NJ, Touber JL 1988 The value of thyroid volume measured by ultrasonography in the diagnosis of goitre. *Clin Endocrinol (Oxf)* 28:409–414
 130. Gharib H, Goellner JR 1993 Fine-needle aspiration biopsy of the thyroid: an appraisal. *Ann Intern Med* 118:282–289
 131. Knudsen N, Bols B, Bülow I, Jørgensen T, Perrild H, Ovesen L, Laurberg P 1999 Validation of ultrasonography of the thyroid gland for epidemiological purposes. *Thyroid* 9:1069–1074
 132. Wiest PW, Hartshorne MF, Inskip PD, Crooks LA, Vela BS, Telepak RJ, Williamson MR, Blumhardt R, Bauman JM, Tekkel M 1998 Thyroid palpation vs. high-resolution thyroid ultrasonography in the detection of nodules. *J Ultrasound Med* 17:487–496
 133. Ezzat S, Sarti DA, Cain DR, Braunstein GD 1994 Thyroid incidentalomas. Prevalence by palpation and ultrasonography. *Arch Intern Med* 154:1838–1840
 134. Tomimori E, Pedrinola F, Cavaliere H, Knobel M, Medeiros-Neto G 1995 Prevalence of incidental thyroid disease in a relatively low iodine intake area. *Thyroid* 5:273–276
 135. Brander A, Viikinkoski P, Nickels J, Kivisaari L 1989 Thyroid gland: US screening in middle-aged women with no previous thyroid disease. *Radiology* 173:507–510
 136. Asanuma K, Kobayashi S, Shingu K, Hama Y, Yokoyama S, Fujimori M, Amano J 2001 The rate of tumour growth does not distinguish between malignant and benign thyroid nodules. *Eur J Surg* 167:102–105
 137. Brunn J, Block U, Ruf G, Bos I, Kunze WP, Scriba PC 1981 [Volumetric analysis of thyroid lobes by real-time ultrasound.] *Dtsch Med Wochenschr* 106:1338–1340
 138. Reinartz P, Sabri O, Zimny M, Nowak B, Cremerius U, Setani K, Bull U 2002 Thyroid volume measurement in patients prior to radioiodine therapy: comparison between three-dimensional magnetic resonance imaging and ultrasonography. *Thyroid* 12:713–717
 139. Hegedüs L, Perrild H, Poulsen LR, Andersen JR, Holm B, Schnohr P, Jensen G, Hansen JM 1983 The determination of thyroid volume by ultrasound and its relationship to body weight, age, and sex in normal subjects. *J Clin Endocrinol Metab* 56:260–263
 140. Nygaard B, Nygaard T, Court-Payen, Jensen LI, Soe-Jensen P, Gerhard NK, Fugl M, Hegedüs L 2002 Thyroid volume measured by ultrasonography and CT. *Acta Radiol* 43:269–274
 141. Bonnema SJ, Andersen PB, Knudsen DU, Hegedüs L 2002 MR imaging of large multinodular goiters: observer agreement on volume vs. observer disagreement on dimensions of the involved trachea. *AJR Am J Roentgenol* 179:259–266
 142. Schlogl S, Werner E, Lassmann M, Terekhova J, Muffert S, Seybold S, Reiners C 2001 The use of three-dimensional ultrasound for thyroid volumetry. *Thyroid* 11:569–574
 143. Wanet PM, Sand A, Abramovici J 1996 Physical and clinical eval-

- uation of high-resolution thyroid pinhole tomography. *J Nucl Med* 37:2017–2020
144. Ramos CD, Zantut-Wittmann DE, Tambascia MA, Assumpcao L, Etchebehere EC, Camargo EE 2000 Thyroid suppression test with L-thyroxine and [99 mTc] pertechnetate. *Clin Endocrinol (Oxf)* 52:471–477
 145. Hoving J, Piers DA, Vermey A, Oosterhuis JW 1981 Carcinoma in hyperfunctioning thyroid nodule in recurrent hyperthyroidism. *Eur J Nucl Med* 6:131–132
 146. Hays MT, Wesselosky B 1973 Simultaneous measurement of thyroidal trapping (99 mTcO₄⁻) and binding (131I⁻): clinical and experimental studies in man. *J Nucl Med* 14:785–792
 147. Arnold JE, Pinsky S 1976 Comparison of 99 mTc and 123I for thyroid imaging. *J Nucl Med* 17:261–267
 148. Dige-Petersen H, Kroon S, Vadstrup S, Andersen ML, Roy-Poulsen NO 1978 A comparison of 99Tc and 123I scintigraphy in nodular thyroid disorders. *Eur J Nucl Med* 3:1–4
 149. Ryo UY, Vaidya PV, Schneider AB, Bekerman C, Pinsky SM 1983 Thyroid imaging agents: a comparison of I-123 and Tc-99m pertechnetate. *Radiology* 148:819–822
 150. Kumar A, Ahuja MM, Chattopadhyay TK, Padhy AK, Gupta AK, Kapila K, Goel AK, Karmarker MG 1992 Fine needle aspiration cytology, sonography and radionuclide scanning in solitary thyroid nodule. *J Assoc Physicians India* 40:302–306
 151. Loy TJ, Sundram FX 1989 Diagnostic management of solitary thyroid nodules. *Ann Acad Med Singapore* 6:658–664
 152. Ashcraft MW, Van Herle AJ 1981 Management of thyroid nodules. II. Scanning techniques, thyroid suppressive therapy, and fine needle aspiration. *Head Neck Surg* 3:297–322
 153. Christensen SB, Bondeson L, Ericsson UB, Lindholm K 1984 Prediction of malignancy in the solitary thyroid nodule by physical examination, thyroid scan, fine-needle biopsy and serum thyroglobulin. A prospective study of 100 surgically treated patients. *Acta Chir Scand* 150:433–439
 154. Cox MR, Marshall SG, Spence RA 1991 Solitary thyroid nodule: a prospective evaluation of nuclear scanning and ultrasonography. *Br J Surg* 78:90–93
 155. Oommen R, Walter NM, Tulasi NR 1994 Scintigraphic diagnosis of thyroid cancer. Correlation of thyroid scintigraphy and histopathology. *Acta Radiol* 35:222–225
 156. Okumura Y, Takeda Y, Sato S, Komatsu M, Nakagawa T, Akaki S, Kuroda M, Joja I, Hiraki Y 1999 Comparison of differential diagnostic capabilities of 201Tl scintigraphy and fine-needle aspiration of thyroid nodules. *J Nucl Med* 40:1971–1977
 157. Sinha PS, Beeby DI, Ryan P 2001 An evaluation of thallium imaging for detection of carcinoma in clinically palpable solitary, nonfunctioning thyroid nodules. *Thyroid* 11:85–89
 158. Kresnik E, Gallowitsch HJ, Mikosch P, Gomez I, Lind P 1997 Technetium-99 m-MIBI scintigraphy of thyroid nodules in an endemic goiter area. *J Nucl Med* 38:62–65
 159. Sathkege MM, Mageza RB, Muthuphei MN, Modiba MC, Clauss RC 2001 Evaluation of thyroid nodules with technetium-99 m MIBI and technetium-99m pertechnetate. *Head Neck* 23:305–310
 160. Wesche MF, Tiel-Van Buul MM, Smits NJ, Wiersinga WM 1998 Ultrasonographic vs. scintigraphic measurement of thyroid volume in patients referred for 131I therapy. *Nucl Med Commun* 19:341–346
 161. Huysmans DA, de Haas MM, van den Broek WJ, Hermus AR, Barentsz JO, Corstens FH, Ruijs SH 1994 Magnetic resonance imaging for volume estimation of large multinodular goitres: a comparison with scintigraphy. *Br J Radiol* 67:519–523
 162. de Klerk JM, Van Isselt JW, van Dijk A, Hakman ME, Pameijer FA, Koppeschaar HP, Zelissen PM, van Schaik JP, Van Rijk PP 1997 Iodine-131 therapy in sporadic nontoxic goiter. *J Nucl Med* 38:372–376
 163. Mazzaferrri EL 1993 Management of a solitary thyroid nodule. *N Engl J Med* 328:553–559
 164. Jennings A 2001 Evaluation of substernal goiters using computed tomography and MR imaging. *Endocrinol Metab Clin North Am* 30:401–414
 165. Belardinelli L, Gualdi G, Ceroni L, Guadalaxara A, Polettini E, Pappalardo G 1995 Comparison between computed tomography and magnetic resonance data and pathologic findings in substernal goiters. *Int Surg* 80:65–69
 166. Hermans R, Bouillon R, Laga K, Delaere PR, Foer BD, Marchal G, Baert AL 1997 Estimation of thyroid gland volume by spiral computed tomography. *Eur Radiol* 7:214–216
 167. Bloom AD, Adler LP, Shuck JM 1993 Determination of malignancy of thyroid nodules with positron emission tomography. *Surgery* 114:728–734
 168. Uematsu H, Sadato N, Ohtsubo T, Tsuchida T, Nakamura S, Sugimoto K, Waki A, Takahashi N, Yonekura Y, Tsuda G, Saito H, Hayashi N, Yamamoto K, Ishii Y 1998 Fluorine-18-fluorodeoxyglucose PET vs. thallium-201 scintigraphy evaluation of thyroid tumors. *J Nucl Med* 39:453–459
 169. Cohen MS, Arslan N, Dehdashti F, Doherty GM, Lairmore TC, Brunt LM, Moley JF 2001 Risk of malignancy in thyroid incidentalomas identified by fluorodeoxyglucose-positron emission tomography. *Surgery* 130:941–946
 170. Jauregui R, Lilker ES, Bayley A 1977 Upper airway obstruction in euthyroid goiter. *JAMA* 238:2163–2166
 171. Geraghty JG, Coveney EC, Kiernan M, O'Higgins NJ 1992 Flow volume loops in patients with goiters. *Ann Surg* 215:83–86
 172. Thusoo TK, Gupta U, Kochhar K, Hira HS 2000 Upper airway obstruction in patients with goiter studies by flow volume loops and effect of thyroidectomy. *World J Surg* 24:1570–1572
 173. Melissant CF, Smith SJ, Perlberger R, Verschakelen J, Lammers JW, Demedts M 1994 Lung function, CT-scan and x-ray in upper airway obstruction due to thyroid goitre. *Eur Respir J* 7:1782–1787
 174. Huysmans DA, Hermus AR, Corstens FH, Barentsz JO, Kloppeborg PW 1994 Large, compressive goiters treated with radioiodine. *Ann Intern Med* 121:757–762
 175. Hoffstein V 1986 Relationship between lung volume, maximal expiratory flow, forced expiratory volume in one second, and tracheal area in normal men and women. *Am Rev Respir Dis* 134:956–961
 176. Brown IG, Webster PM, Zamel N, Hoffstein V 1986 Changes in tracheal cross-sectional area during Mueller and Valsalva maneuvers in humans. *J Appl Physiol* 60:1865–1870
 177. Fouke JM, Strohl KP 1987 Effect of position and lung volume on upper airway geometry. *J Appl Physiol* 63:375–380
 178. Korun N, Asci C, Yilmazlar T, Duman H, Zorluoglu A, Tuncel E, Erturk E, Yerci O 1997 Total thyroidectomy or lobectomy in benign nodular disease of the thyroid: changing trends in surgery. *Int Surg* 82:417–419
 179. Burch HB 1995 Evaluation and management of the solid thyroid nodule. *Endocrinol Metab Clin North Am* 24:663–710
 180. Cochand-Priollet B, Guillausseau PJ, Chagnon S, Hoang C, Guillausseau-Scholer C, Chanson P, Dahan H, Warnet A, Tran Ba Huy PT, Valleu P 1994 The diagnostic value of fine-needle aspiration biopsy under ultrasonography in nonfunctional thyroid nodules: a prospective study comparing cytologic and histologic findings. *Am J Med* 97:152–157
 181. Danese D, Sciacchitano S, Farsetti A, Andreoli M, Pontecorvi A 1998 Diagnostic accuracy of conventional vs. sonography-guided fine-needle aspiration biopsy of thyroid nodules. *Thyroid* 8:15–21
 182. Goellner JR, Gharib H, Grant CS, Johnson DA 1987 Fine needle aspiration cytology of the thyroid, 1980 to 1986. *Acta Cytol* 31:587–590
 183. Yang GC, Liebeskind D, Messina AV 2001 Ultrasound-guided fine-needle aspiration of the thyroid assessed by Ultrafast Papanicolaou stain: data from 1135 biopsies with a two- to six-year follow-up. *Thyroid* 11:581–589
 184. Hamburger JI 1994 Diagnosis of thyroid nodules by fine needle biopsy: use and abuse. *J Clin Endocrinol Metab* 79:335–339
 185. Dwarakanathan AA, Staren ED, D'Amore MJ, Kluskens LF, Martirano M, Economou SG 1993 Importance of repeat fine-needle biopsy in the management of thyroid nodules. *Am J Surg* 166:350–352
 186. Gharib H, Goellner JR, Zinsmeister AR, Grant CS, van Heerden JA 1984 Fine-needle aspiration biopsy of the thyroid. The problem of suspicious cytologic findings. *Ann Intern Med* 101:25–28
 187. Busseniers AE, Oertel YC 1993 "Cellular adenomatoid nodules" of the thyroid: review of 219 fine-needle aspirates. *Diagn Cytopathol* 9:581–589

188. Silverman JF, West RL, Finley JL, Larkin EW, Park HK, Swanson MS, Fore WW 1986 Fine-needle aspiration *vs.* large-needle biopsy or cutting biopsy in evaluation of thyroid nodules. *Diagn Cytopathol* 2:25–30
189. Tangpricha V, Chen BJ, Swan NC, Sweeney AT, de las Morenas A, Safer JD 2001 Twenty-one-gauge needles provide more cellular samples than twenty-five-gauge needles in fine-needle aspiration biopsy of the thyroid but may not provide increased diagnostic accuracy. *Thyroid* 11:973–976
190. Leenhardt L, Hejblum G, Franc B, Fediaevsky LD, Delbot T, Le Guillouzic D, Menegaux F, Guillausseau C, Hoang C, Turpin G, Aurengo A 1999 Indications and limits of ultrasound-guided cytology in the management of nonpalpable thyroid nodules. *J Clin Endocrinol Metab* 84:24–28
191. Carmeci C, Jeffrey RB, McDougall IR, Nowels KW, Weigel RJ 1998 Ultrasound-guided fine-needle aspiration biopsy of thyroid masses. *Thyroid* 8:283–289
192. Rehak NN, Oertel YC, Herp A, Chiang BT, Csako G 1993 Biochemical analysis of thyroid cyst fluid obtained by fine-needle aspiration. *Arch Pathol Lab Med* 117:625–630
193. Morita M, Noguchi S, Kawamoto H, Tajiri J, Tamaru M, Murakami N 1994 Thyroglobulin and lactic dehydrogenase isozymes in cystic fluid of thyroid nodules. *Endocr J* 41:227–233
194. Rosen IB, Provias JP, Walfish PG 1986 Pathologic nature of cystic thyroid nodules selected for surgery by needle aspiration biopsy. *Surgery* 100:606–613
195. los Santos ET, Keyhani-Rofagha S, Cunningham JJ, Mazzaferri EL 1990 Cystic thyroid nodules. The dilemma of malignant lesions. *Arch Intern Med* 150:1422–1427
196. Hatabu H, Kasagi K, Yamamoto K, Iida Y, Misaki T, Hidaka A, Shibata T, Shibata T, Shoji K, Higuchi K 1991 Cystic papillary carcinoma of the thyroid gland: a new sonographic sign. *Clin Radiol* 43:121–124
197. Sarda AK, Bal S, Dutta GS, Kapur MM 1988 Diagnosis and treatment of cystic disease of the thyroid by aspiration. *Surgery* 103:593–596
198. McHenry CR, Slusarczyk SJ, Khiyami A 1999 Recommendations for management of cystic thyroid disease. *Surgery* 126:1167–1171
199. Lin JD, Huang BY 1998 Comparison of the results of diagnosis and treatment between solid and cystic well-differentiated thyroid carcinomas. *Thyroid* 8:661–666
200. Müller N, Cooperberg PL, Suen KC, Thorson SC 1985 Needle aspiration biopsy in cystic papillary carcinoma of the thyroid. *AJR Am J Roentgenol* 144:251–253
201. Pelizzo MR, Bernante P, Toniato A, Fassina A 1997 Frequency of thyroid carcinoma in a recent series of 539 consecutive thyroidectomies for multinodular goiter. *Tumori* 83:653–655
202. Rojas MT, Gharib H 1985 Nodular thyroid disease. Evaluation and management. *N Engl J Med* 313:428–436
203. Hagag P, Strauss S, Weiss M 1998 Role of ultrasound-guided fine-needle aspiration biopsy in evaluation of nonpalpable thyroid nodules. *Thyroid* 8:989–995
204. Tollin SR, Mery GM, Jelveh N, Fallon EF, Mikhail M, Blumenfeld W, Perlmutter S 2000 The use of fine-needle aspiration biopsy under ultrasound guidance to assess the risk of malignancy in patients with a multinodular goiter. *Thyroid* 10:235–241
205. Papini E, Guglielmi R, Bianchini A, Crescenzi A, Taccogna S, Nardi F, Panunzi C, Rinaldi R, Toscano V, Pacella CM 2002 Risk of malignancy in nonpalpable thyroid nodules: predictive value of ultrasound and color-Doppler features. *J Clin Endocrinol Metab* 87:1941–1946
206. de Micco C, Zoro P, Garcia S, Skoog L, Tani EM, Carayon P, Henry JF 1994 Thyroid peroxidase immunodetection as a tool to assist diagnosis of thyroid nodules on fine-needle aspiration biopsy. *Eur J Endocrinol* 131:474–479
207. Christensen L, Blichert-Toft M, Brandt M, Lange M, Bjerregaard SS, Ravnsbæk J, Møllerup CL, Strange L, Jensen F, Kirkegaard J, Sand HH, Sørensen SS, Feldt-Rasmussen U 2000 Thyroperoxidase (TPO) immunostaining of the solitary cold thyroid nodule. *Clin Endocrinol (Oxf)* 53:161–169
208. Gasbarri A, Martegani MP, Del Prete F, Lucante T, Natali PG, Bartolazzi A 1999 Galectin-3 and CD44v6 isoforms in the preoperative evaluation of thyroid nodules. *J Clin Oncol* 17:3494–3502
209. Sebesta J, Brown T, Williard W, Dehart MJ, Aldous W, Kavolius J, Azarow K 2001 Does telomerase activity add to the value of fine needle aspirations in evaluating thyroid nodules? *Am J Surg* 181:420–422
210. Siddiqui MT, Greene KL, Clark DP, Xydias S, Udelsman R, Smallridge RC, Zeiger MA, Saji M 2001 Human telomerase reverse transcriptase expression in Diff-Quik-stained FNA samples from thyroid nodules. *Diagn Mol Pathol* 10:123–129
211. Hintze G, Kobberling J 1992 Treatment of iodine deficiency goiter with iodine, levothyroxine or a combination of both. *Thyroidology* 4:37–40
212. Roti E, Uberti ED 2001 Iodine excess and hyperthyroidism. *Thyroid* 11:493–500
213. Stanbury JB, Ermans AE, Bourdoux P, Todd C, Oken E, Tonglet R, Vidor G, Braverman LE, Medeiros-Neto G 1998 Iodine-induced hyperthyroidism: occurrence and epidemiology. *Thyroid* 8:83–100
214. Harach HR, Williams ED 1995 Thyroid cancer and thyroiditis in the goitrous region of Salta, Argentina, before and after iodine prophylaxis. *Clin Endocrinol (Oxf)* 43:701–706
215. Hansen JM, Kampmann J, Madsen SN, Skovsted L, Solgaard S, Grytter C, Grøntvedt T, Rasmussen SN 1979 L-Thyroxine treatment of diffuse non-toxic goitre evaluated by ultrasonic determination of thyroid volume. *Clin Endocrinol (Oxf)* 10:1–6
216. Perrild H, Hansen JM, Hegedüs L, Rytter L, Holm B, Gundtofte E, Johansen K 1982 Triiodothyronine and thyroxine treatment of diffuse non-toxic goitre evaluated by ultrasonic scanning. *Acta Endocrinol (Copenh)* 100:382–387
217. Bongers H, Hotze LA, Schmitz R, Joseph K 1986 LT4-monopreparation *vs.* LT4-LT3-compound preparation in the treatment of diffuse endemic goitre. *Acta Endocrinol (Copenh)* 113:242–248
218. Wilders-Truschning MM, Warnkross H, Leb G, Langsteger W, Eber O, Tiran A, Dobnig H, Passath A, Lanzer G, Drexhage HA 1993 The effect of treatment with levothyroxine or iodine on thyroid size and thyroid growth stimulating immunoglobulins in endemic goitre patients. *Clin Endocrinol (Oxf)* 39:281–286
219. Gullu S, Gurses MA, Baskal N, Uysal AR, Kamel AN, Erdogan G 1999 Suppressive therapy with levothyroxine for euthyroid diffuse and nodular goiter. *Endocr J* 46:221–226
220. Peters H, Hackel D, Schleusener H 1997 [Treatment of euthyroid struma. Comparable volume reduction with 400 micrograms iodine, 100 micrograms levothyroxine combined with 100 micrograms iodine or individually dosed levothyroxine]. *Med Klin* 92:63–67
221. Kreissl M, Tiemann M, Hanscheid H, Rendl J, Reiners C 2001 [Comparison of the effectiveness of two different dosages of levothyroxine-iodide combinations for the therapy of euthyroid diffuse goiter.] *Dtsch Med Wochenschr* 126:227–231
222. Schumm-Draeger PM 1993 [Drug therapy of goiter. Iodine, thyroid hormones or combined therapy.] *Z Gesamte Inn Med* 48:592–598
223. Lima N, Knobel M, Cavaliere H, Szejtajn C, Tomimori E, Medeiros-Neto G 1997 Levothyroxine suppressive therapy is partially effective in treating patients with benign, solid thyroid nodules and multinodular goiters. *Thyroid* 7:691–697
224. Wesche MF, Tiel-Van Buul MM, Lips P, Smits NJ, Wiersinga WM 2001 A randomized trial comparing levothyroxine with radioactive iodine in the treatment of sporadic nontoxic goiter. *J Clin Endocrinol Metab* 86:998–1005
225. Leese GP, Jung RT, Guthrie C, Waugh N, Browning MC 1992 Morbidity in patients on L-thyroxine: a comparison of those with a normal TSH to those with a suppressed TSH. *Clin Endocrinol (Oxf)* 37:500–503
226. Solomon BL, Wartofsky L, Burman KD 1993 Prevalence of fractures in postmenopausal women with thyroid disease. *Thyroid* 3:17–23
227. Uzzan B, Campos J, Cucherat M, Nony P, Boissel JP, Perret GY 1996 Effects on bone mass of long term treatment with thyroid hormones: a meta-analysis. *J Clin Endocrinol Metab* 81:4278–4289
228. Faber J, Galloe AM 1994 Changes in bone mass during prolonged subclinical hyperthyroidism due to L-thyroxine treatment: a meta-analysis. *Eur J Endocrinol* 130:350–356
229. Sawin CT, Geller A, Wolf PA, Belanger AJ, Baker E, Bacharach P, Wilson PW, Benjamin EJ, D'Agostino RB 1994 Low serum

- thyrotropin concentrations as a risk factor for atrial fibrillation in older persons. *N Engl J Med* 331:1249–1252
230. **Tenerz A, Forberg R, Jansson R** 1990 Is a more active attitude warranted in patients with subclinical thyrotoxicosis? *J Intern Med* 228:229–233
 231. **Bonnema SJ, Bennedbæk FN, Hegedüs L** 2001 [Danish endocrinologists' examination and treatment of non-toxic multinodular goiter. A questionnaire study]. *Ugeskr Laeger* 163:1265–1269
 232. **al Suliman NN, Rytto NF, Qvist N, Blichert-Toft M, Graversen HP** 1997 Experience in a specialist thyroid surgery unit: a demographic study, surgical complications, and outcome. *Eur J Surg* 163:13–20
 233. **Thomusch O, Machens A, Sekulla C, Ukkat J, Lippert H, Gastinger I, Dralle H** 2000 Multivariate analysis of risk factors for postoperative complications in benign goiter surgery: prospective multicenter study in Germany. *World J Surg* 24:1335–1341
 234. **Abdel Rahim AA, Ahmed ME, Hassan MA** 1999 Respiratory complications after thyroidectomy and the need for tracheostomy in patients with a large goitre. *Br J Surg* 86:88–90
 235. **Maruotti RA, Zannini P, Viani MP, Voci C, Pezzuoli G** 1991 Surgical treatment of substernal goiters. *Int Surg* 76:12–17
 236. **Torre G, Borgonovo G, Amato A, Arezzo A, Ansaldo G, De Negri A, Ughe M, Mattioli F** 1995 Surgical management of substernal goiter: analysis of 237 patients. *Am Surg* 61:826–831
 237. **Vadasz P, Kotsis L** 1998 Surgical aspects of 175 mediastinal goiters. *Eur J Cardiothorac Surg* 14:393–397
 238. **Allo MD, Thompson NW** 1983 Rationale for the operative management of substernal goiters. *Surgery* 94:969–977
 239. **Hegedüs L, Nygaard B, Hansen JM** 1999 Is routine thyroxine treatment to hinder postoperative recurrence of nontoxic goiter justified? *J Clin Endocrinol Metab* 84:756–760
 240. **Röjdmärk J, Järhult J** 1995 High long term recurrence rate after subtotal thyroidectomy for nodular goitre. *Eur J Surg* 161:725–727
 241. **Berghout A, Wiersinga WM, Drexhage HA, van Trotsenburg P, Smits NJ, van der Gaag RD, Touber JL** 1989 The long-term outcome of thyroidectomy for sporadic non-toxic goitre. *Clin Endocrinol (Oxf)* 31:193–199
 242. **Geerdsen JP, Frølund L** 1986 Thyroid function after surgical treatment of nontoxic goitre. A randomized study of postoperative thyroxine administration. *Acta Med Scand* 220:341–345
 243. **Bistrup C, Nielsen JD, Gregersen G, Franch P** 1994 Preventive effect of levothyroxine in patients operated for non-toxic goitre: a randomized trial of one hundred patients with nine years follow-up. *Clin Endocrinol (Oxf)* 40:323–327
 244. **Miccoli P, Antonelli A, Iacconi P, Alberti B, Gambuzza C, Baschieri L** 1993 Prospective, randomized, double-blind study about effectiveness of levothyroxine suppressive therapy in prevention of recurrence after operation: result at the third year of follow-up. *Surgery* 114:1097–1101
 245. **Feldkamp J, Seppel T, Becker A, Klisch A, Schlaghecke R, Goretzki PE, Roher HD** 1997 Iodide or L-thyroxine to prevent recurrent goiter in an iodine-deficient area: prospective sonographic study. *World J Surg* 21:10–14
 246. **Seiler CA, Glaser C, Wagner HE** 1996 Thyroid gland surgery in an endemic region. *World J Surg* 20:593–596
 247. **Reeve TS, Delbridge L, Cohen A, Crummer P** 1987 Total thyroidectomy. The preferred option for multinodular goiter. *Ann Surg* 206:782–786
 248. **Mishra A, Agarwal A, Agarwal G, Mishra SK** 2001 Total thyroidectomy for benign thyroid disorders in an endemic region. *World J Surg* 25:307–310
 249. **Pappalardo G, Guadalaxara A, Frattaroli FM, Illomei G, Falaschi P** 1998 Total compared with subtotal thyroidectomy in benign nodular disease: personal series and review of published reports. *Eur J Surg* 164:501–506
 250. **Hisham AN, Azlina AF, Aina EN, Sarojah A** 2001 Total thyroidectomy: the procedure of choice for multinodular goitre. *Eur J Surg* 167:403–405
 251. **Hermus AR, Huysmans DA** 1998 Treatment of benign nodular thyroid disease. *N Engl J Med* 338:1438–1447
 252. **Hegedüs L, Hansen BM, Knudsen N, Hansen JM** 1988 Reduction of size of thyroid with radioactive iodine in multinodular non-toxic goitre. *Br Med J* 297:661–662
 253. **Nygaard B, Hegedüs L, Gervil M, Hjalgrim H, Søb-Jensen P, Hansen JM** 1993 Radioiodine treatment of multinodular non-toxic goitre. *Br Med J* 307:828–832
 254. **Le Moli R, Wesche MF, Tiel-Van Buul MM, Wiersinga WM** 1999 Determinants of longterm outcome of radioiodine therapy of sporadic non-toxic goitre. *Clin Endocrinol (Oxf)* 50:783–789
 255. **Wesche MF, Buul MM, Smits NJ, Wiersinga WM** 1995 Reduction in goiter size by ¹³¹I therapy in patients with non-toxic multinodular goiter. *Eur J Endocrinol* 132:86–87
 256. **Howarth DM, Epstein MT, Thomas PA, Allen LW, Akerman R, Lan L** 1997 Outpatient management of patients with large multinodular goiters treated with fractionated radioiodine. *Eur J Nucl Med* 24:1465–1469
 257. **Sabri O, Zimny M, Schreckenberger M, Meyer-Oelmann A, Reinartz P, Buell U** 2000 Does thyroid stunning exist? A model with benign thyroid disease. *Eur J Nucl Med* 27:1591–1597
 258. **Bonnema SJ, Knudsen DU, Bertelsen H, Mortensen J, Andersen PB, Bastholt L, Hegedüs L** 2002 Does radioiodine therapy have an equal effect on substernal and cervical goiter volumes? Evaluation by magnetic resonance imaging. *Thyroid* 12:313–317
 259. **Hegedüs L, Bennedbæk FN** 1997 Radioiodine for non-toxic diffuse goitre. *Lancet* 350:409–410
 260. **Nygaard B, Faber J, Veje A, Hansen JE** 1997 Thyroid volume and function after ¹³¹I treatment of diffuse non-toxic goitre. *Clin Endocrinol (Oxf)* 46:493–496
 261. **Nygaard B, Hegedüs L, Gervil M, Hjalgrim H, Hansen BM, Søb-Jensen P, Hansen JM** 1995 Influence of compensated radioiodine therapy on thyroid volume and incidence of hypothyroidism in Graves' disease. *J Intern Med* 238:491–497
 262. **Verelst J, Bonnyns M, Glinoeer D** 1990 Radioiodine therapy in voluminous multinodular non-toxic goitre. *Acta Endocrinol (Copenh)* 122:417–421
 263. **Berg GE, Michanek AM, Holmberg EC, Fink M** 1996 Iodine-131 treatment of hyperthyroidism: significance of effective half-life measurements. *J Nucl Med* 37:228–232
 264. **Kok SW, Smit JW, de Craen AJ, Goslings BM, Eck-Smit BL, Romijn JA** 2000 Clinical outcome after standardized *vs.* dosimetric radioiodine treatment of hyperthyroidism: an equivalence study. *Nucl Med Commun* 21:1071–1078
 265. **Jarlov AE, Hegedüs L, Kristensen LØ, Nygaard B, Hansen JM** 1995 Is calculation of the dose in radioiodine therapy of hyperthyroidism worthwhile? *Clin Endocrinol (Oxf)* 43:325–329
 266. **Khandani A, Schicha H** 1999 [Two-step radioiodine therapy in benign thyroid diseases during a single hospital visit—observations on 100 patients.] *Nuklearmedizin* 38:140–143
 267. **Van Isselt JW, de Klerk JM, Koppeschaar HP, Van Rijk PP** 2000 Iodine-131 uptake and turnover rate vary over short intervals in Graves' disease. *Nucl Med Commun* 21:609–616
 268. **Traino AC, Di Martino F, Lazzeri M, Stabin MG** 2000 Influence of thyroid volume reduction on calculated dose in radioiodine therapy of Graves' hyperthyroidism. *Phys Med Biol* 45:121–129
 269. **Nygaard B, Hegedüs L, Ulriksen P, Nielsen KG, Hansen JM** 1999 Radioiodine therapy for multinodular toxic goiter. *Arch Intern Med* 159:1364–1368
 270. **Huysmans DA, Nieuwlaet W, Erdtsieck J, Schellekens AP, Bus JW, Bravenboer B, Hermus AR** 2000 Administration of a single low dose of recombinant human thyrotropin significantly enhances thyroid radioiodine uptake in nontoxic nodular goiter. *J Clin Endocrinol Metab* 85:3592–3596
 271. **Nieuwlaet WA, Hermus AR, Sivo-Prndelj F, Corstens FH, Huysmans DA** 2001 Pretreatment with recombinant human TSH changes the regional distribution of radioiodine on thyroid scintigrams of nodular goiters. *J Clin Endocrinol Metab* 86:5330–5336
 272. **Nygaard B, Faber J, Hegedüs L** 1994 Acute changes in thyroid volume and function following ¹³¹I therapy of multinodular goitre. *Clin Endocrinol (Oxf)* 41:715–718
 273. **Huysmans AK, Hermus RM, Edelbroek MA, Tjabbes T, Oostdijk W, Ross HA, Corstens FH, Kloppenborg PW** 1997 Autoimmune hyperthyroidism occurring late after radioiodine treatment for volume reduction of large multinodular goiters. *Thyroid* 7:535–539
 274. **Nygaard B, Metcalfe RA, Phipps J, Weetman AP, Hegedüs L** 1999 Graves' disease and thyroid associated ophthalmopathy triggered

- by 131I treatment of non-toxic goiter. *J Endocrinol Invest* 22:481–485
275. Franklyn JA, Maisonneuve P, Sheppard M, Betteridge J, Boyle P 1999 Cancer incidence and mortality after radioiodine treatment for hyperthyroidism: a population-based cohort study. *Lancet* 353:2111–2115
 276. Ron E, Doody MM, Becker DV, Brill AB, Curtis RE, Goldman MB, Harris III BS, Hoffman DA, McConahey WM, Maxon HR, Preston-Martin S, Warshauer ME, Wong FL, Boice Jr JD 1998 Cancer mortality following treatment for adult hyperthyroidism. Cooperative Thyrotoxicosis Therapy Follow-up Study Group. *JAMA* 280:347–355
 277. Hall P, Berg G, Bjelkengren G, Boice Jr JD, Ericsson UB, Hallquist A, Lidberg M, Lundell G, Tennvall J, Wiklund K 1992 Cancer mortality after iodine-131 therapy for hyperthyroidism. *Int J Cancer* 50:886–890
 278. Angusti T, Codegone A, Pellerito R, Favero A 2000 Thyroid cancer prevalence after radioiodine treatment of hyperthyroidism. *J Nucl Med* 41:1006–1009
 279. Huysmans DA, Buijs WC, van de Ven MT, van den Broek WJ, Kloppenborg PW, Hermus AR, Corstens FH 1996 Dosimetry and risk estimates of radioiodine therapy for large, multinodular goiters. *J Nucl Med* 37:2072–2079
 280. Miller MR, Pincock AC, Oates GD, Wilkinson R, Skene-Smith H 1990 Upper airway obstruction due to goitre: detection, prevalence and results of surgical management. *Q J Med* 74:177–188
 281. Nygaard B, Soes-Petersen U, Høiland-Carlsen PE, Veje A, Holst PE, Vestergaard A, Sølling K 1996 Improvement of upper airway obstruction after 131I-treatment of multinodular nontoxic goiter evaluated by flow volume loop curves. *J Endocrinol Invest* 19:71–75
 282. Ferrari C, Reschini E, Paracchi A 1996 Treatment of the autonomous thyroid nodule: a review. *Eur J Endocrinol* 135:383–390
 283. Hamburger JI 1987 The autonomously functioning thyroid nodule: Goetsch's disease. *Endocr Rev* 8:439–447
 284. Wiener JD 1987 Plummer's disease: localized thyroid autonomy. *J Endocrinol Invest* 10:207–224
 285. Michigishi T, Mizukami Y, Shuke N, Satake R, Noguchi M, Aburano T, Tonami N, Hisada K 1992 An autonomously functioning thyroid carcinoma associated with euthyroid Graves' disease. *J Nucl Med* 33:2024–2026
 286. Liel Y 1999 The yield of adequate and conclusive fine-needle aspiration results in thyroid nodules is uniform across functional and goiter types. *Thyroid* 9:25–28
 287. Hegedüs L, Veiergang D, Karstrup S, Hansen JM 1986 Compensated 131I-therapy of solitary autonomous thyroid nodules: effect on thyroid size and early hypothyroidism. *Acta Endocrinol (Copenh)* 113:226–232
 288. Nygaard B, Hegedüs L, Nielsen KG, Ulriksen P, Hansen JM 1999 Long-term effect of radioactive iodine on thyroid function and size in patients with solitary autonomously functioning toxic thyroid nodules. *Clin Endocrinol (Oxf)* 50:197–202
 289. Mariotti S, Martino E, Francesconi M, Ceccarelli C, Grasso L, Lippi F, Baschieri L, Pinchera A 1986 Serum thyroid autoantibodies as a risk factor for development of hypothyroidism after radioactive iodine therapy for single thyroid 'hot' nodule. *Acta Endocrinol (Copenh)* 113:500–507
 290. Goldstein R, Hart IR 1983 Follow-up of solitary autonomous thyroid nodules treated with 131I. *N Engl J Med* 309:1473–1476
 291. O'Brien T, Gharib H, Suman VJ, van Heerden JA 1992 Treatment of toxic solitary thyroid nodules: surgery *vs.* radioactive iodine. *Surgery* 112:1166–1170
 292. Livraghi T, Paracchi A, Ferrari C, Bergonzi M, Garavaglia G, Raineri P, Vettori C 1990 Treatment of autonomous thyroid nodules with percutaneous ethanol injection: preliminary results. Work in progress. *Radiology* 175:827–829
 293. Goletti O, Monzani F, Caraccio N, Del Guerra P, Lippolis PV, Pucciarelli M, Seccia M, Carmassi F, Cavina E, Baschieri L 1992 Percutaneous ethanol injection treatment of autonomously functioning single thyroid nodules: optimization of treatment and short term outcome. *World J Surg* 16:784–789
 294. Di Lelio A, Rivolta M, Casati M, Capra M 1995 Treatment of autonomous thyroid nodules: value of percutaneous ethanol injection. *AJR Am J Roentgenol* 164:207–213
 295. Livraghi T, Paracchi A, Ferrari C, Reschini E, Macchi RM, Bonifacino A 1994 Treatment of autonomous thyroid nodules with percutaneous ethanol injection: 4-year experience. *Radiology* 190:529–533
 296. Martino E, Murtas ML, Loviselli A, Piga M, Petrini L, Miccoli P, Pacini F 1992 Percutaneous intranodular ethanol injection for treatment of autonomously functioning thyroid nodules. *Surgery* 112:1161–1164
 297. Mazzeo S, Toni MG, De Gaudio C, Caramella D, Pinto F, Lencioni R, Sanguinetti F, Bartolozzi C 1993 Percutaneous injection of ethanol to treat autonomous thyroid nodules. *AJR Am J Roentgenol* 161:871–876
 298. Monzani F, Goletti O, Caraccio N, Del Guerra P, Ferdeghini M, Pucci E, Baschieri L 1992 Percutaneous ethanol injection treatment of autonomous thyroid adenoma: hormonal and clinical evaluation. *Clin Endocrinol (Oxf)* 36:491–497
 299. Özdemir H, Ilgit ET, Yucel C, Atilla S, Isik S, Cakir N, Gokcora N 1994 Treatment of autonomous thyroid nodules: safety and efficacy of sonographically guided percutaneous injection of ethanol. *AJR Am J Roentgenol* 163:929–932
 300. Papini E, Panunzi C, Pacella CM, Bizzarri G, Fabbrini R, Petrucci L, Pisicchio G, Nardi F 1993 Percutaneous ultrasound-guided ethanol injection: a new treatment of toxic autonomously functioning thyroid nodules? *J Clin Endocrinol Metab* 76:411–416
 301. Lippi F, Ferrari C, Manetti L, Rago T, Santini F, Monzani F, Belliotti P, Papini E, Busnardo B, Angelini F, Pinchera A 1996 Treatment of solitary autonomous thyroid nodules by percutaneous ethanol injection: results of an Italian multicenter study. The Multicenter Study Group. *J Clin Endocrinol Metab* 81:3261–3264
 302. Monzani F, Caraccio N, Goletti O, Lippolis PV, Casolaro A, Del Guerra P, Cavina E, Miccoli P 1997 Five-year follow-up of percutaneous ethanol injection for the treatment of hyperfunctioning thyroid nodules: a study of 117 patients. *Clin Endocrinol (Oxf)* 46:9–15
 303. Nakada K, Katoh C, Kanegae K, Tsukamoto E, Itoh K, Tamaki N 1996 Percutaneous ethanol injection therapy for autonomously functioning thyroid nodule. *Ann Nucl Med* 10:171–176
 304. Brkljacic B, Sucic M, Bozikov V, Hauser M, Hebrang A 2001 Treatment of autonomous and toxic thyroid adenomas by percutaneous ultrasound-guided ethanol injection. *Acta Radiol* 42:477–481
 305. Cerbone G, Spiezia S, Colao A, Marzullo P, Assanti AP, Lucci R, Zarrilli S, Siciliani M, Fenzi G, Lombardi G 1999 Percutaneous ethanol injection under Power Doppler ultrasound assistance in the treatment of autonomously functioning thyroid nodules. *J Endocrinol Invest* 22:752–759
 306. Komorowski J, Kuzdak K, Pomorski L, Bartos M, Stepień H 1998 Percutaneous ethanol injection in treatment of benign nonfunctional and hyperfunctional thyroid nodules. *Cytobios* 95:143–150
 307. Mincheva L, Simeonov S, Troev D, Mitkov M, Pavlova M, Iliev D, Botushanov N 1997 Percutaneous ethanol sclerotherapy of autonomous thyroid nodules: preliminary results. *Folia Med (Plovdiv)* 39:49–54
 308. Monzani F, Caraccio N, Goletti O, Casolaro A, Lippolis PV, Cavina E, Miccoli P 1998 Treatment of hyperfunctioning thyroid nodules with percutaneous ethanol injection: eight years' experience. *Exp Clin Endocrinol Diabetes* 106(Suppl 4):S54–S58
 309. Sardanelli F, Giordano GD, Melani E, Parodi RC, Giusti M, Garlaschi G 1997 Magnetic resonance evaluation of autonomous thyroid nodules treated by percutaneous ethanol injection. *MAGMA* 5:267–274
 310. Spiezia S, Cerbone G, Assanti AP, Colao A, Siciliani M, Lombardi G 2000 Power Doppler ultrasonographic assistance in percutaneous ethanol injection of autonomously functioning thyroid nodules. *J Ultrasound Med* 19:39–46
 311. Tarantino L, Giorgio A, Mariniello N, de Stefano G, Perrotta A, Aloisio V, Tamasi S, Forestieri MC, Esposito F, Esposito F, Finizia L, Voza A 2000 Percutaneous ethanol injection of large autonomous hyperfunctioning thyroid nodules. *Radiology* 214:143–148
 312. Bennedbæk FN, Karstrup S, Hegedüs L 1997 Percutaneous ethanol injection therapy in the treatment of thyroid and parathyroid diseases. *Eur J Endocrinol* 136:240–250
 313. Monzani F, Del Guerra P, Caraccio N, Casolaro A, Lippolis PV,

- Goletti O 1997 Appearance of Graves' disease after percutaneous ethanol injection for the treatment of hyperfunctioning thyroid adenoma. *J Endocrinol Invest* 20:294–298
314. Miccoli P, Bendinelli C, Monzani F 1998 Surgical aspects of thyroid nodules previously treated by ethanol injection. *Exp Clin Endocrinol Diabetes* 106(Suppl 4):S75–S77
315. Pacella CM, Bizzarri G, Guglielmi R, Anelli V, Bianchini A, Crescenzi A, Pacella S, Papini E 2000 Thyroid tissue: US-guided percutaneous interstitial laser ablation—a feasibility study. *Radiology* 217:673–677
316. Zelmanovitz F, Genro S, Gross JL 1998 Suppressive therapy with levothyroxine for solitary thyroid nodules: a double-blind controlled clinical study and cumulative meta-analyses. *J Clin Endocrinol Metab* 83:3881–3885
317. Gharib H, Mazzaferri EL 1998 Thyroxine suppressive therapy in patients with nodular thyroid disease. *Ann Intern Med* 128:386–394
318. Papini E, Petrucci L, Guglielmi R, Panunzi C, Rinaldi R, Bacci V, Crescenzi A, Nardi F, Fabbrini R, Pacella CM 1998 Long-term changes in nodular goiter: a 5-year prospective randomized trial of levothyroxine suppressive therapy for benign cold thyroid nodules. *J Clin Endocrinol Metab* 83:780–783
319. Csako G, Byrd D, Wesley RA, Sarlis NJ, Skarulis MC, Nieman LK, Pucino F 2000 Assessing the effects of thyroid suppression on benign solitary thyroid nodules. A model for using quantitative research synthesis. *Medicine (Baltimore)* 79:9–26
320. Bennedbæk FN, Nielsen LK, Hegedüs L 1998 Effect of percutaneous ethanol injection therapy *vs.* suppressive doses of L-thyroxine on benign solitary solid cold thyroid nodules: a randomized trial. *J Clin Endocrinol Metab* 83:830–835
321. Castro MR, Caraballo PJ, Morris JC 2002 Effectiveness of thyroid hormone suppressive therapy in benign solitary thyroid nodules: a meta-analysis. *J Clin Endocrinol Metab* 87:4154–4159
322. Bennedbæk FN, Perrild HJ, Hegedüs L 1999 [Investigation and treatment of solitary thyroid gland nodules by Danish endocrinologists. A questionnaire study.] *Ugeskr Laeger* 161:1264–1269
323. Wadström C, Zedenius J, Guinea A, Reeve T, Delbridge L 1999 Multinodular goitre presenting as a clinical single nodule: how effective is hemithyroidectomy? *Aust N Z J Surg* 69:34–36
324. Liu Q, Djuricin G, Prinz RA 1998 Total thyroidectomy for benign thyroid disease. *Surgery* 123:2–7
325. Krouse RS, McCarty T, Weiss LM, Wagman LD 2000 Postoperative suppressive therapy for thyroid adenomas. *Am Surg* 66:751–755
326. Songun I, Kievit J, Wobbles T, Peerdeman A, van de Velde CJ 1999 Extent of thyroidectomy in nodular thyroid disease. *Eur J Surg* 165:839–842
327. Sosa JA, Bowman HM, Tielsch JM, Powe NR, Gordon TA, Udelsman R 1998 The importance of surgeon experience for clinical and economic outcomes from thyroidectomy. *Ann Surg* 228:320–330
328. Bellantone R, Lombardi CP, Raffaelli M, Rubino F, Boscherini M, Perilli W 1999 Minimally invasive, totally gasless video-assisted thyroid lobectomy. *Am J Surg* 177:342–343
329. Bliss RD, Gauger PG, Delbridge LW 2000 Surgeon's approach to the thyroid gland: surgical anatomy and the importance of technique. *World J Surg* 24:891–897
330. Gagner M, Inabnet III WB 2001 Endoscopic thyroidectomy for solitary thyroid nodules. *Thyroid* 11:161–163
331. Bennedbæk FN, Hegedüs L 1999 Percutaneous ethanol injection therapy in benign solitary solid cold thyroid nodules: a randomized trial comparing one injection with three injections. *Thyroid* 9:225–233
332. Caraccio N, Goletti O, Lippolis PV, Casolaro A, Cavina E, Miccoli P, Monzani F 1997 Is percutaneous ethanol injection a useful alternative for the treatment of the cold benign thyroid nodule? Five years' experience. *Thyroid* 7:699–704
333. Zingrillo M, Collura D, Ghiggi MR, Nirchio V, Trischitta V 1998 Treatment of large cold benign thyroid nodules not eligible for surgery with percutaneous ethanol injection. *J Clin Endocrinol Metab* 83:3905–3907
334. Dössing H, Bennedbæk FN, Karstrup S, Hegedüs L 2002 Benign solitary solid cold thyroid nodules: US-guided interstitial laser photocoagulation—initial experience. *Radiology* 225:53–57
335. Lo GP, Ting W 1983 Method for biopsy of the wall of a thyroid cyst. *Am J Surg* 146:383–384
336. Clark OH, Okerlund MD, Cavalieri RR, Greenspan FS 1979 Diagnosis and treatment of thyroid, parathyroid, and thyroglossal duct cysts. *J Clin Endocrinol Metab* 48:983–988
337. Jensen F, Rasmussen SN 1976 The treatment of thyroid cysts by ultrasonically guided fine needle aspiration. *Acta Chir Scand* 142: 209–211
338. Kuma K, Matsuzuka F, Yokozawa T, Miyauchi A, Sugawara M 1994 Fate of untreated benign thyroid nodules: results of long-term follow-up. *World J Surg* 18:495–498
339. Pacini F, Antonelli A, Lari R, Gasperini L, Baschieri L, Pinchera A 1985 Unsuspected parathyroid cysts diagnosed by measurement of thyroglobulin and parathyroid hormone concentrations in fluid aspirates. *Ann Intern Med* 102:793–794
340. McCowen KD, Reed JW, Fariss BL 1980 The role of thyroid therapy in patients with thyroid cysts. *Am J Med* 68:853–855
341. Meko JB, Norton JA 1995 Large cystic/solid thyroid nodules: a potential false-negative fine-needle aspiration. *Surgery* 118:996–1003
342. Abbas G, Heller KS, Khoynzhad A, Dubner S, Szynter LA 2001 The incidence of carcinoma in cytologically benign thyroid cysts. *Surgery* 130:1035–1038
343. Bean WJ 1981 Renal cysts: treatment with alcohol. *Radiology* 138: 329–331
344. Ryan WG, Schwartz TB, Harris J 1983 Sclerosis of thyroid cyst with tetracycline. *N Engl J Med* 308:157
345. Edmonds CJ, Tellez M 1987 Treatment of thyroid cysts by aspiration and injection of sclerosant. *Br Med J (Clin Res Ed)* 295:529
346. Treece GL, Georgitis WJ, Hofeldt FD 1983 Resolution of recurrent thyroid cysts with tetracycline instillation. *Arch Intern Med* 143: 2285–2287
347. DeYoung JP, Kahn A, Lerman S, Ferenczy AS 1986 Tetracycline instillation for recurrent cystic thyroid nodules. *Can J Surg* 29: 118–119
348. Goldfarb WB, Bigos ST, Nishiyama RH 1987 Percutaneous tetracycline instillation for sclerosis of recurrent thyroid cysts. *Surgery* 102:1096–1100
349. Hegedüs L, Hansen JM, Karstrup S, Torp-Pedersen S, Juul N 1988 Tetracycline for sclerosis of thyroid cysts. A randomized study. *Arch Intern Med* 148:1116–1118
350. Lee JK, Tai FT, Lin HD, Chou YH, Kaplan MM, Ching KN 1989 Treatment of recurrent thyroid cysts by injection of tetracycline or minocycline. *Arch Intern Med* 149:599–601
351. Rajatanavin R, Chailurkit L, Chiemchanya S 1994 The efficacy of percutaneous tetracycline instillation for sclerosis of recurrent thyroid cysts: a multivariate analysis. *J Endocrinol Invest* 17:123–125
352. Garg MK, Satija L, Khanna SK, Saini JS 2000 Intracystic tetracycline therapy for hypofunctioning cystic thyroid nodules. *J Assoc Physicians India* 48:891–894
353. Verde G, Papini E, Pacella CM, Gallotti C, Delpiano S, Strada S, Fabbrini R, Bizzarri G, Rinaldi R, Panunzi C 1994 Ultrasound guided percutaneous ethanol injection in the treatment of cystic thyroid nodules. *Clin Endocrinol (Oxf)* 41:719–724
354. Yasuda K, Ozaki O, Sugino K, Yamashita T, Toshima K, Ito K, Harada T 1992 Treatment of cystic lesions of the thyroid by ethanol instillation. *World J Surg* 16:958–961
355. Antonelli A, Campatelli A, Di Vito A, Alberti B, Baldi V, Salvioni G, Fallahi P, Baschieri L 1994 Comparison between ethanol sclerotherapy and emptying with injection of saline in treatment of thyroid cysts. *Clin Investig* 72:971–974
356. Cho YS, Lee HK, Ahn IM, Lim SM, Kim DH, Choi CG, Suh DC 2000 Sonographically guided ethanol sclerotherapy for benign thyroid cysts: results in 22 patients. *AJR Am J Roentgenol* 174:213–216
357. Monzani F, Lippi F, Goletti O, Del Guerra P, Caraccio N, Lippolis PV, Baschieri L, Pinchera A 1994 Percutaneous aspiration and ethanol sclerotherapy for thyroid cysts. *J Clin Endocrinol Metab* 78:800–802
358. Zingrillo M, Torlontano M, Ghiggi MR, D'Aloiso L, Nirchio V, Bisceglia M, Liuzzi A 1996 Percutaneous ethanol injection of large thyroid cystic nodules. *Thyroid* 6:403–408
359. Iacconi P, Spinelli C, Monzani F, Miccoli P 1996 Percutaneous ethanol injection for thyroid cysts: a word of caution. *Clin Endocrinol (Oxf)* 44:126