

University of Dundee

Managing carious lesions

Schwendicke, F.; Frencken, J. E.; Bjørndal, L.; Maltz, M.; Manton, D. J.; Ricketts, David

Published in:

Advances in Dental Research: an E-Supplement to Journal of Dental Research

DOI:

[10.1177/0022034516639271](https://doi.org/10.1177/0022034516639271)

Publication date:

2016

Document Version

Peer reviewed version

[Link to publication in Discovery Research Portal](#)

Citation for published version (APA):

Schwendicke, F., Frencken, J. E., Bjørndal, L., Maltz, M., Manton, D. J., Ricketts, D., Van Landuyt, K., Banderjee, A., Campus, G., Doméjean, S., Fontana, M., Leal, S., Lo, E., Machiulskiene, V., Schulte, A., Splieth, C., Zandona, A. F., & Innes, N. P. T. (2016). Managing carious lesions: consensus recommendations on carious tissue removal. *Advances in Dental Research: an E-Supplement to Journal of Dental Research*, 28(2), 58-67. <https://doi.org/10.1177/0022034516639271>

General rights

Copyright and moral rights for the publications made accessible in Discovery Research Portal are retained by the authors and/or other copyright owners and it is a condition of accessing publications that users recognise and abide by the legal requirements associated with these rights.

- Users may download and print one copy of any publication from Discovery Research Portal for the purpose of private study or research.
- You may not further distribute the material or use it for any profit-making activity or commercial gain.
- You may freely distribute the URL identifying the publication in the public portal.

Take down policy

If you believe that this document breaches copyright please contact us providing details, and we will remove access to the work immediately and investigate your claim.

Managing carious lesions: Consensus recommendations on carious tissue removal

Falk Schwendicke¹, Jo E. Frencken², Lars Bjørndal³, Marisa Maltz⁴, David J. Manton⁵, David Ricketts⁶, Kirsten Van Landuyt⁷, Avijit Banderjee⁸, Guglielmo Campus⁹, Sophie Doméjean¹⁰, Margherita Fontana¹¹, Soraya Leal¹², Edward Lo¹³, Vita Machiulskiene¹⁴, Andreas Schulte¹⁵, Christian Splieth¹⁶, Andrea Ferreira Zandona¹⁷, Nicola P.T. Innes¹⁸

¹ Department of Operative and Preventive Dentistry, Charité - Universitätsmedizin Berlin, Germany

² Department of Oral Function and Prosthetic Dentistry, College of Dental Sciences, Radboud University Medical Center, Nijmegen, The Netherlands

³ Department of Cariology & Endodontics, Faculty of Health and Medical Sciences, University of Copenhagen, Denmark

⁴ Department of Preventive and Social Dentistry, Faculty of Odontology, Federal University of Rio Grande do Sul, Brazil

⁵ Melbourne Dental School, University of Melbourne, Australia

⁶ Section of Operative Dentistry, Fixed Prosthodontics and Endodontology, Dundee Dental Hospital and School, University of Dundee, Dundee, UK

⁷ KULeuven BIOMAT, Department of Oral Health Sciences, University of Leuven & Dentistry University Hospitals Leuven, Kapucijnenvoer 7, 3000 Leuven, Belgium;

⁸ Conservative & MI Dentistry, King's College London Dental Institute at Guy's Hospital, King's Health Partners, London, UK.

⁹ Department of Surgery, Microsurgery and Medicine Sciences, School of Dentistry, University of Sassari, Italy, WHO Collaborating Centre for Epidemiology and Community Dentistry, University of Milan, Milan, Italy

¹⁰ CHU Clermont-Ferrand, Service d'Odontologie, Hôtel-Dieu, F-63001 Univ Clermont1, UFR d'Odontologie; Centre de Recherche en Odontologie Clinique EA 4847, F-63000 Clermont-Ferrand, France.

¹¹ Department of Cariology, Restorative Sciences and Endodontics, School of Dentistry, University of Michigan; Ann Arbor, Michigan, USA

¹² Department of Dentistry, Faculty of Health Sciences, University of Brasília, Brazil

¹³ Faculty of Dentistry, University of Hong Kong

¹⁴ Department of Dental and Oral Pathology, Faculty of Odontology, Lithuanian University of Health Sciences, Kaunas, Lithuania

¹⁵ Department of Special Care Dentistry, Faculty of Health, University of Witten/Herdecke, Witten, Germany

¹⁶ Preventive & Pediatric Dentistry, University of Greifswald, Greifswald, Germany

¹⁷ Department of Operative Dentistry, University of North Carolina at Chapel Hill School of Dentistry, Chapel Hill, North Carolina, USA

¹⁸ Paediatric Dentistry, Dundee Dental Hospital and School, University of Dundee, Dundee, UK

Running title: Recommendations on carious tissue removal

Keywords: dental caries; stepwise excavation; selective excavation; incomplete excavation; caries sealing

Corresponding author: Dr. Falk Schwendicke
Department of Operative and Preventive Dentistry
Charité – Universitätsmedizin Berlin
Aßmannshauser Str. 4-6
14197 Berlin
Tel.: (+49) 30 450 562 556
Fax: (+49) 30 450 562 932
Email: falk.schwendicke@charite.de

Declaration of interests:

The authors' declaration of interest forms are available in the Supplementary file. The conference was kindly sponsored by GC Europe (Leuven, Belgium), DMG (Hamburg, Germany), 3M Espe (Seefeld, Germany) and Dentsply DeTrey (Konstanz, Germany). The sponsors had no role in design or conduct of the conference or the content of this manuscript, and were not present during the conference. Travel to the meeting and accommodation for LB, WB, SD, EK, MM, DM, KvL, AB, GC, MF, SL, EL, VM, BN, AS, CS and AZ were supported by the sponsors. No honoraria were given to any of the participants.

Abstract

The International Caries Consensus Collaboration undertook a consensus process and present clinical recommendations for carious tissue removal and managing cavitated carious lesions including restoration, based on texture of demineralized dentine.

Dentists should manage the disease dental caries, and control activity of existing cavitated lesions, to preserve hard tissues and retain teeth long-term. Entering the restorative cycle should be avoided as far as possible. Controlling the disease in cavitated carious lesions should be attempted by cleansable methods first. Only when cavitated carious lesions are either non-cleansable or can no longer be sealed, are restorative interventions indicated. When a restoration is indicated, the priorities are: preserving healthy and remineralizable tissue; achieving a restorative seal; maintaining pulpal health; and maximizing restoration success. Carious tissue is removed purely to create conditions for long lasting restorations. Bacterially contaminated or demineralized tissues close to the pulp do not need to be removed. In deeper lesions in teeth with sensible (vital) pulps, preserving pulpal health should be prioritized, whilst in shallow or moderately deep lesions, restoration longevity becomes more important.

For teeth with shallow or moderately deep cavitated lesions, carious tissue removal is performed according to *Selective Removal to Firm Dentine*. In deep cavitated lesions in primary or permanent teeth, *Selective Removal to Soft Dentine* should be performed although in permanent teeth, *Stepwise Removal* is an option.

The evidence, and therefore these recommendations, support less invasive carious lesion management, delaying entry to, and slowing down, the restorative cycle by preserving tooth tissue and retaining teeth long-term.

Introduction

This consensus paper is a report from the International Caries Consensus Collaboration (ICCC) meeting, held in Leuven, Belgium in February 2015, comprising 21 experts in cariology from 12 different countries covering North and South America, Europe, and Australasia. The ICCC group compiled expert consensus on terminology and recommendations for dealing with carious tooth tissue removal and managing cavitated carious lesions.

The background to this consensus collaboration meeting is the ongoing debate surrounding strategies for removing carious tissue; the growing number of studies and their synthesis into systematic reviews questioning conventional carious tissue removal and confusion around terms, which refer to these strategies. Recommendations on managing dental caries are often related to specific stages of carious lesion extension, i.e. the enamel lesion, the cavitated dentine lesion or the lesion reaching the pulp. Whilst it might be practical to separate the various stages of pathology for investigative and descriptive purposes, this separation results in isolated scientific “circles” where different views of treatment and names of concepts exist. Thus, there is a need for consensus, both on terminology (reported elsewhere) and clinical recommendation regarding management of cavitated carious lesions. Consensus around these recommendations was reached after assessment of compiled and appraised evidence and through discussion. The strength of clinical recommendations was derived from this evidence and discussion and classified as being for or against an intervention, with further separation of weak and strong recommendations.

This report lays out the ICCC group’s clinical recommendations for carious tissue removal and cavity management including restoration. The focus is on carious teeth that could be retained and with pulps responding positively to sensitivity testing (called “sensible pulps” for ease of communication in this paper) or those with reversible pulpitis (i.e. pulps with the ability to heal). There is an overview of the management of dental caries and carious lesions, defining and justifying thresholds for each management strategy. Next, carious tissue removal is discussed, and management options for lesions requiring a restoration with different strategies are detailed. For each of these issues, clinical recommendations are presented and the areas where deeper or broader evidence are still needed are identified. Finally, the clinical recommendations and knowledge gaps are summarized.

1 Managing dental caries and carious lesions

1.1 What is dental caries?

Dental caries is the name of a disease resulting from an ecologic shift within the dental biofilm, from a balanced population of micro-organisms to an acidogenic, acidoduric and cariogenic microbiological population developed and maintained by frequent consumption of fermentable dietary carbohydrates. The resulting activity shift in the biofilm is associated with an imbalance between de- and remineralization leading to net mineral loss within dental hard tissues, the sign and symptom being a carious lesion (Fejerskov et al. 2015).

Consequently, dental caries is not an infectious disease which needs to be “cured” by removing bacteria or, even less so, a particular bacterial species. Instead, dental caries can be managed behaviorally by controlling its causative factors, i.e. the supply of fermentable carbohydrates and the presence and maturation of bacterial dental biofilms. If, however, such management is neither provided nor adhered to by the patient, i.e. the lesion activity is not controlled, the remaining cariogenic biofilm promotes progression of the lesion, which may eventually lead to both chronic pulp inflammation and the irreversible stages of pulp necrosis and apical periodontitis following bacterial penetration into the pulp cavity (Bjørndal and Ricucci, 2014).

1.2 How to manage dental caries and carious lesions?

The tenets of minimal intervention dentistry (Frencken et al. 2012b; Banerjee and Domejean 2013) allow dentists to pursue holistic and cause-based management of the disease ‘dental caries’, with the aim of maintaining healthy functional teeth for life. Effective management of the *disease* caries is characterized by detection of early lesions and subsequent accurate diagnosis, caries activity and caries risk assessment, and preventing occurrence of new carious lesions. The management of cavitated carious *lesions* focuses on arresting or controlling (including restoring) existing lesions through minimal invasive restorative treatments, evidence-informed, including repairing rather than replacing defective restorations.

Given the pathological basis for dental caries as a biofilm disease, both prevention of new lesions and management of existing lesions should focus primarily on control or management rather than tissue removal. For existing carious lesions, different lesion stages and activities might require different management, all of which should aim towards:

- inactivation/control of the disease process;
- preservation of dental hard tissue;
- avoidance of initiating the cycle of re-restorations; and

- preservation of the tooth for as long as possible.

The decision around when to use which management strategy should follow a rational pathway (as described here), with the single most important question being “When do I need to intervene restoratively (invasively)?”

Non-cavitated (i.e. cleansable) lesions can be managed using biofilm removal (toothbrushing) and/or remineralization, or by fissure sealing over them (Griffin et al. 2008; Hilgert et al. 2015). Cavitated dentine carious lesions that are accessible to visual-tactile inspection and activity evaluation are potentially cleansable lesions (i.e. assessed as being cleansable by the patient). These can be inactivated, i.e. not require further treatment as their progression is unlikely and can be managed non-restoratively (non-invasively), i.e. via biofilm removal or remineralization. These lesions that are not cleansable are likely to be active and progress, but might be transformed into cleansable lesions by widening the opening and encouraging effective oral hygiene practices in the individual including a fluoridated toothpaste and healthy dietary practices (‘Non-Restorative Cavity Control’). This is more widely performed in the primary dentition (Lo et al. 1998; Gruythuysen 2010; Mijan et al. 2014).

The line between a cleansable and non-cleansable lesion is not a clear one but this is an important point because when surface cavitation has occurred lesions should be considered to be non-cleansable and active until proven otherwise. Occlusal lesions can be assessed visually, but whether or not the surface is cavitated is not always clear. For proximal lesions it can be even more difficult to carry out a clear visual-tactile evaluation. Tooth separation may be useful for direct visualization and radiographs or fiber-optic transillumination can be valuable adjuncts but usually don’t always lead to a definitive diagnosis on surface cavitation (Bader et al. 2001; Mialhe et al. 2009; Baelum et al. 2012). Other factors, including the patient’s caries risk and the lesion’s depth radiographically, should be considered in the decision as to whether proximal surface cavitation is likely and whether the lesion is therefore non-cleansable. The number of bacteria within the lesion increases as the lesion extends into dentine. Lesions with a surface breach that is not clearly detectable to the naked eye progress to clearly cavitated lesions (Ricketts et al. 1995; Ricketts et al. 1997). Sometimes the stage at which a surface breach has taken place, but is not considered to be a frankly cavitated lesion, is called micro-cavitation. This term is not agreed upon and seems to mean different things, from a breach in the enamel that is not clearly detectable to the naked eye, to being defined as when a CPITN probe will drop into a breach in the enamel. Preventing lesions with a surface breach from progressing might be difficult using biofilm removal and/or remineralization (Fusayama and Kurosaki 1972; Ricketts et al. 1997; Munson et al. 2004) but fissure sealing over them and depriving the bacteria within the lesion of carbohydrates might arrest them

(Griffin et al. 2008; Oong et al. 2008). Just as there is no clear line between cleansable and non-cleansable, there is no clear line between a 'micro-cavitation' that can be fissure sealed and when the breach becomes frank cavitation and may require restoration. The mechanical demands required of sealing materials increase with the size of the cavitation, which limits the options for fissure sealing clearly cavitated lesions. A decision has to be made, with all tooth and patient factors in mind, as to when a sealant, or restoration which seals the carious lesion into the tooth, might be required.

In summary, there are a variety of options for managing the disease or managing carious lesions non-restoratively (non-invasively). However, for certain lesion stages or under certain conditions, restorative interventions are unavoidable. To allow practical implementation of these recommendations, the group has defined cut-offs to aid the decision on when to intervene restoratively. The consensus that emerged was that:

- non-cleansable cavitated dentine carious lesions cannot be managed by biofilm removal, remineralization or fissure sealing alone. However, in the primary dentition these lesions might be transformable into cleansable lesions and managed via Non-Restorative Cavity Control;
- certain occlusal lesions might appear clinically non-cavitated but radiographically extend significantly into dentine. If such lesions cannot be arrested through biofilm control alone, fissure sealing can be carried out but the integrity of the sealant needs to be monitored and there is a possibility, until more evidence has emerged, that a 'trampoline' effect may lead to failure of the sealant and a restoration will be required.

Recommendations

We have not made more detailed recommendations for managing non-cavitated lesions, as this was not the focus of this meeting of the collaboration. Similarly, options like sealing over lesions or the Hall Technique have not been discussed extensively, as they do not require carious tissue removal.

1. Preventing carious lesions from occurring means managing the disease dental caries. For existing carious lesions, dentists should work with the patient to manage the disease and as a consequence to control the lesion activity, i.e. aiming for lesion arrest/inactivation, to preserve dental hard tissues, avoid initiation of the restorative cycle (Elderton 1993; Qvist 2015) and retain the tooth for as long as possible (strong recommendation).

2. When cavitated carious lesions are non-cleansable and sealing is no longer an option, restorative interventions are indicated (strong recommendation).

2 Restorative management of carious lesions

2.1 *Why do we restore teeth?*

The aims of restorative management are to:

- aid plaque control and thereby manage caries activity at this specific location;
- protect the pulp-dentine complex and arrest the lesion by sealing it; and
- restore the function, form and aesthetics of the tooth (Kidd 2004).

Restorative management conventionally involves carious tissue removal and the reasons for this have historically included to:

- withstand packing of materials and retaining the restoration. This applies only to dental amalgam. Using adhesive materials, removal of dental hard tissues is not justified;
- remove bacteria. Given the pathology of dental caries and the effects of a tight seal on the viability of remaining bacteria together with the biodiversity and cariogenicity of the remaining biofilm, tissue removal simply to remove bacteria is not logical or justified (Going et al. 1978; Banerjee et al. 2002; Paddick et al. 2005). It is currently not completely understood whether remaining bacteria or their metabolites have any detrimental effect on the pulp on subclinical level. However, the number of viable long-term remaining bacteria in proximity to the pulp does not seem to be increased in sealed lesions (Paddick et al. 2005) or when compared to traditionally treated carious lesions (Maltz et al. 2012b), and clinical studies consequently have not found detrimental effects to the pulp by sealing in bacteria (Ricketts et al. 2013).
- remove demineralized dentine. Demineralized but structurally intact dentine that can be remineralized (Ogawa et al. 1983; Ngo et al. 2006) should be preserved. Some studies have even reported remineralization of infected, disorganised dentine (Wambier et al. 2007; Chibinski et al. 2013; Corralo and Maltz 2013). In any case, clinical discrimination between these layers is difficult (see below).

In conclusion, the only evidence-based reason why removal of carious tissue is carried out today is to create a sufficiently large surface to bond to and thus optimizing the longevity of a restoration.

2.2 *What guiding principles should be used during removal of carious tissue?*

The guiding principles for the removal of carious tissue are to:

- preserve non-demineralized and remineralisable tissue;
- achieve an adequate seal by placing the peripheral restoration onto sound dentine and/or enamel, thus controlling the lesion and inactivating remaining bacteria;
- avoid discomfort/pain and dental anxiety as both impact significantly on treatment / care planning and outcomes. Methods that are less likely to lead to dental anxiety are preferable;
- maintain pulpal health by preserving residual dentine (avoiding unnecessary pulpal irritation/insult) and preventing pulp exposure, i.e. leave soft dentine in proximity to the pulp if required. Avoiding pulpal exposure has great impact both on the lifetime prognosis of the tooth and long-term treatment costs (Whitworth et al. 2005; Bjørndal et al. 2010; Schwendicke et al. 2013b). The thickness of residual dentine cannot be assessed clinically, but its preservation has been found to be a significant factor in avoiding pulpal distress (Smith et al. 2001; Whitworth et al. 2005). This preservation is more likely to occur even if the softer, bacterial containing, dentine is left over the pulpal aspect of the cavity;
- maximize longevity of the restoration by removing enough soft dentine to place a durable restoration of sufficient bulk and resilience.

When dealing with teeth with sensible (vital) pulps, free from pathologic signs and symptoms, these last two aims, maintaining pulpal health and maximizing restoration longevity, might need to be balanced against each other. In deep lesions (radiographically involving the inner pulpal third or quarter of dentine, or with clinically assessed risk of pulpal exposure), preservation of pulpal health should be prioritized. In shallow or moderately deep lesions (those not reaching the inner third or quarter of the dentine), restoration longevity might be more important.

There are significant doubts around the validity of methods for assessing pulpal sensibility and pulpal health (Mejare et al. 2012). However, when weighing up the chance of preserving pulpal health against the potential disadvantages of pulpal necrosis and infection associated with delaying endodontic therapy (potentially decreased prognosis compared with root-canal therapy of vital pulps), current evidence indicates that maintaining pulpal health might be prioritized (Schwendicke and Stolpe 2014).

Recommendations:

3. Restorative treatments are carried out to aid biofilm control, protect the pulp-dentine complex and restore the function, form and aesthetics of the tooth, whilst causing no unnecessary harm. The carious tissue removal stage aims to create conditions for a

long lasting restoration, preserve healthy and remineralizable tissue, achieve a sufficient seal, maintain pulpal health and maximize success of the restoration. However, this does not necessarily mean that close to the pulp, all bacterially contaminated or demineralized tissues need to be removed (strong recommendation).

4. In deeper lesions in teeth with pulps that are sensible (vital), preserving pulpal health should be prioritized, whilst in shallow or moderately deep lesions, restoration longevity might be more important factor (strong recommendation).

2.3 How to remove carious tissue in teeth with sensible, asymptomatic pulps?

To remove carious tissue in teeth with sensible (vital) pulps and no symptomatic/irreversible pulpitis, five main strategies are available that are based on the level of hardness of the remaining dentine (Ricketts et al. 2013). The decision between these strategies will be guided by the lesion depth and the dentition (Fig. 1).

Non-Selective Removal to Hard Dentine (formerly complete excavation or complete caries removal) uses the same criterion in assessing the endpoint of carious tissue removal for all parts of the cavity, i.e. peripherally and pulpally. Only hard dentine is left so that demineralized dentine 'free' of bacteria is completely removed. *This is considered over-treatment and no longer advocated.*

Selective Removal to Firm Dentine leaves 'leathery' dentine pulpally; there is a feeling of resistance to a hand excavator whilst the cavity margins, peripheral dentine, is left hard (scratchy) after removal. Selective Removal to Firm Dentine is the treatment of choice for both dentitions, in shallow or moderately deep cavitated dentinal lesions (i.e. lesions radiographically extending less than the pulpal third or quarter of dentine). *In deeper lesions, Selective Removal to Firm Dentine bears significant risks for the pulp, which is why other strategies should be considered.*

Selective Removal to Soft Dentine is recommended in deep cavitated lesions (i.e. extending into pulpal third or quarter of the dentine). Soft carious tissue is left over the pulp to avoid exposure and "stress" to the pulp, promoting pulpal health, whilst peripheral enamel and dentine are prepared to hard dentine, to allow a tight seal and placement of a durable restoration. *Selective Removal to Soft Dentine reduces the risk of pulpal exposure significantly compared with Non-Selective Removal to Hard or Selective Removal to Firm Dentine.*

Stepwise Removal is carious tissue removal in two stages (visits) (Bjørndal et al. 1997; Bjørndal and Larsen, 2000; Paddick et al. 2005). Soft carious tissue is left over the pulp in the first step, whilst peripheral dentine is prepared to hard dentine, to allow a complete and durable seal of the lesion. A provisional restoration is placed, which should be sufficiently durable to last up to 12 months to allow changes in the dentine and pulp to take place, also because

patients may not return to complete the treatment (Maltz et al. 2012a). The reasoning for stepwise removal is the expectation that in the first step, tertiary dentine is formed, demineralized dentin becomes remineralized and the amount of viable bacteria is reduced. When re-entering, the restoration is removed and there is an opportunity to re-evaluate changes in intra-lesion color and hardness. A calibrated color classification scale may also be used to gauge changes in the cariogenic environment (Bjørndal et al. 1997; Orhan et al. 2008; Bjørndal et al. 2014; Petrou et al. 2014). Drier lesions can also indicate less activity (Kidd et al. 1993). Carious tissue removal is only continued until 'leathery' dentine remains over the pulp. There is some evidence that in such deep lesions, the second removal step may be omitted as it increases risks of pulpal exposure and is thus detrimental to pulpal health (Maltz et al. 2012a; Ricketts et al. 2013; Schwendicke et al. 2013a). The second step also adds additional cost, time and discomfort to the patient. In the primary dentition, teeth have a limited lifespan so Stepwise Removal is not considered necessary for primary teeth and Selective Removal to Soft Dentine should be carried out.

Recommendations

Recommendations for removal of carious tissue apply only to teeth where restorative interventions are deemed unavoidable:

5. For teeth with shallow or moderately deep lesions, Selective Removal to Firm Dentine should be carried out (weak recommendation);
6. In deep lesions (radiographically extending into pulpal third or quarter of the dentine) in primary and permanent teeth, Selective Removal to Soft Dentine should be performed (strong recommendation);
7. In permanent teeth, Stepwise Removal might also be an option for deep lesions (strong recommendation).

2.4 How to assess removal of carious tissue?

To assess carious tissue removal, a variety of criteria have been suggested, including hardness, moisture, color, fluorescence properties, and dye stainability. Furthermore, carious tissue removal methods have been developed which attempt to define this endpoint, e.g. self-limiting burs, chemo-mechanical removal. Most of these have been validated *in vitro*, but lack sufficient clinical validation, whilst some of them (stainability via caries-detector dyes) are even detrimental (Schwendicke et al. 2014).

All described criteria for assessing or describing the dentine remaining after carious tissue removal are surrogate measures. These need to be validated against relevant outcomes (pain, maintenance of pulpal health, retention of the tooth). Only surrogate measures associated with such outcomes should be used by dentists during clinical assessment. As previously

described in Section 2.3, harder, darker, and drier dentine reflect lesion arrest (Kidd et al. 1993; Bjørndal et al. 1997; Orhan et al. 2010; Petrou et al. 2013).

Recommendations

8. Hardness (e.g. soft, leathery, firm or scratchy, or hard) dentine should be the primary criterion for assessing, describing and reporting on carious tissue and their removal (weak recommendation).
9. Moisture (wet, moist or dry), color (pale/yellow, dark brown/black) and additional optical characteristics of dentine or measures of different bacterial metabolic products might be useful as additional indicators (weak recommendation).

2.5 How to perform carious tissue removal?

There are a large number of methods for carious tissue removal, including; hand excavators, tungsten carbide burs, ceramic burs, air-abrasion, sono-abrasion, chemo-mechanical carious tissue removal, polymer burs, lasers. Most of these are also used to define an endpoint for carious tissue removal (see above), however, the endpoints have only been validated to a limited extent (Banerjee et al. 2000; Boston 2003; Celiberti et al. 2006; Neves Ade et al. 2011). As a result, information on clinical advantages or disadvantages of different excavation methods is sparse, with very weak evidence finding hand or chemo-mechanical excavation potentially advantageous (Frencken et al. 2012b), although this is stronger for patient-reported outcomes like pain and discomfort during removal, especially when undertaken by generalists (Rahimtoola et al. 2000; Nadanovsky et al. 2001; Rafique et al. 2003; Schriks and van Amerongen 2003; de Menezes Abreu et al. 2011).

Recommendations

10. There is insufficient evidence to recommend any single method for carious tissue removal. Hand or chemo-mechanical excavation might reduce pain and discomfort during treatment and could thus positively impact on dental anxiety, especially when treating children (weak recommendation).

2.6 How to manage the resulting cavity?

Various steps such as cavity disinfection and cavity lining have been carried out traditionally after removing carious tissue but before restoring the cavity.

Cavity disinfection has been advocated to reduce the number of remaining bacteria. Given that the number of bacteria might be of limited importance if a tight restorative seal has been achieved, and that the effects of disinfection methods might be limited to superficial dentine only, this concepts underlying this procedure are likely to be theoretically flawed, and could unnecessarily increase treatment time and cost. There is insufficient evidence to support

cavity disinfection. Additional putative benefits such as chlorhexidine application or stannous fluoride, to inactivate dentinal matrix metallo-proteinase or remineralize dentine, have not yet been substantiated through clinical trials (Farag et al. 2009).

Cavity lining has been traditionally used when treating deep carious lesions, (most commonly calcium hydroxide) to: reduce the number of residual viable bacteria; remineralize dentine; induce reactionary dentine; isolate the pulp; and protect pulpal cells from noxious stimuli (About et al. 2001). As already discussed, reducing bacterial numbers might not be relevant if cavity sealing is achieved, and current evidence regarding the antibacterial effects of different dental materials is ambiguous (do Amaral et al. 2015; Schwendicke et al. 2015). Remineralization of remaining demineralized dentine seems to be mediated by pulpal activities and might not require separate liners (Corralo and Maltz 2013). Although certain liners seem capable of inducing dentinogenesis and reducing pulpal inflammation (Fusayama 1997), the evidence is sparse and the clinical relevance unclear (Hebling et al. 1999; Schwendicke et al. 2013a; Dalpian et al. 2014). With the advent of new materials such as calcium silicates etc. and clinical studies investigating these, evidence of patient benefit may emerge (Hashem et al. 2015).

The isolation of the pulp against thermal insult is relevant when placing thermally conductive material (dental amalgam). Isolating the pulp when placing resin restorations might be beneficial as monomers penetrate through dentine into the pulp (Galler et al. 2005; Modena et al. 2009). In addition, the expected effects of liners might depend on which removal strategy for carious tissue is performed. Caries-affected dentine has a lower elastic modulus and is intrinsically less resistant to tensile forces; it may thus not be able to withstand shrinkage forces during bonding, leading to fracture lines within the dentine which may facilitate pulp damage (Perdigão 2010; Tjaderhane 2015).

Recommendations

11. Cavity disinfection procedures currently have no evidence of patient benefit to support their use (weak recommendation).
12. Placement of cavity lining materials are not necessary to control the sealed lesion, but might be beneficial in impeding monomer penetration and avoidance of fracture of the remaining dentine when resin composite is the restorative material (weak recommendation).

2.7 How to restore the cavity?

Once the decision has been made to manage a carious lesion with a restoration, it must be of the highest possible quality to guarantee durability and avoid the need for replacement.

Of the various direct restorative materials available to restore cavities, historically, dental amalgam has been accepted as the standard for restoration of carious lesions in posterior teeth. Although it is unaesthetic, amalgam restorations have good longevity, and are especially successful in high-carries-risk patients (Opdam et al. 2010). This has been attributed to the corrosion products, which are able to seal the margin soon after placement, have antibacterial properties and may protect against secondary carious lesions. However, for environmental reasons, many countries have committed themselves to phase down the use of amalgam and the Minamata Treaty on Mercury was signed in October 2013 (United Nations Environmental Programme, 2013).

Conversely, resin composite use has been increasing with their longevity now being similar to amalgam restorations, although composites in high-carries risk patients seem more prone to secondary carious lesions (Opdam et al. 2010; Kopperud et al. 2012). The reasons for this are probably multifactorial and not yet well understood. Resin composites are bonded to dental hard tissue using adhesives. These adhesives have been increasingly optimized, and are important to seal the resin composite restoration, withstand polymerization shrinkage forces and ensure retention to the cavity walls when functionally loaded (De Munck et al. 2003). In-vitro, when bond quality is quantitatively assessed using mechanical tests, such as tensile and shear bond strength tests, there is a correlation between the retention rate of cervical restorations and the bond strength (Van Meerbeek et al. 2010). On the other hand, in-vitro tests used to assess the sealing ability of composite restorations seem to have little clinical significance (Heintze 2013). It is generally accepted that the bond to sound dental hard tissues is important to guarantee good sealing of the resin composite (De Munck et al. 2003). In spite of the formation of much thicker hybrid layers in carious dentine, immediate bond strengths have been found to be significantly lower than those to sound dentine (Yoshiyama et al. 2002). This has been attributed to the low elastic modulus and the increased wetness typical of carious dentine. Clinically, this does not seem to present a problem if only limited amounts of carious dentine are left beneath a restoration (Schwendicke et al. 2013a). Since bond strength is proportional to the area of the bonded surface, carious dentine being left in order to preserve pulpal health, should be limited to areas over the dental pulp in the cavity: it is especially important that the periphery of the cavity should support the restoration sufficiently and allow a tight seal.

The third main alternative is glass-ionomer cement (GIC), which has been generally viewed, until recently, as a temporary/interim restorative material or limited to use in primary teeth or when other materials cannot be used. This material has good biocompatibility, releases fluoride and bonds chemically to dental hard tissues. However, compared to resin composites, glass ionomers are less esthetic, have higher 'early' wear, and results from older and non-

controlled trials (Manhart et al. 2004) have shown them to be prone to mechanical failure, particularly in large proximal-occlusally loaded cavities. More recent systematic reviews have reported no difference in survival rates of high-viscosity GIC (when used in Atraumatic Restorative Treatment) and amalgam (Mickenautsch and Yengopal 2012) or resin composite restorations in children (Raggio et al. 2013). Overall, a growing body of evidence finds high-viscosity GIC a valuable alternative for primary teeth and in single-surface cavities in permanent teeth (Frencken et al. 2012a).

Apart from these materials, metal or ceramic indirect restorations (inlays, onlays, crowns) can be used. These, however, usually require more invasive tooth preparation with sacrifice of additional sound tooth tissue and are more expensive (Kelly and Smales 2004).

When assessing the performance of all materials, decisions around replacement or re-intervention should still follow the guiding principles for restorative interventions. For example, detection of a radiolucency beneath a restoration where there is an intact seal and no pulpal symptoms would not warrant replacement of the restoration and monitoring would be more suitable. Similarly, once the decision to re-intervene has been made, sound tooth tissues should be preserved during replacement to preserve pulpal health, reduce costs and limit the subjective burden to the patient. Thus, resealing, refurbishing, repolishing and repairing restorations should be performed whenever possible and complete restoration replacement avoided (Green et al. 2015).

Recommendations

13. The choice of materials for restoring cavities should be guided by the location and extent of the lesion, the caries risk, carious lesion activity and the specific patient conditions and setting. There is no definitive evidence to support particular materials as more suitable than others for restoring teeth after selective carious tissue removal to soft or firm dentine (weak recommendation).
14. Re-treatment of restorations should aim to repair by resealing, refurbishing, or repolishing where possible and replacement should be a last resort (strong recommendation).

3 Recommendations and knowledge gaps

3.1 Clinical recommendations

1. Preventing carious lesions from occurring means managing the disease dental caries. For existing carious lesions, dentists should work with the patient to manage the disease and as a consequence to control the lesion activity, i.e. aiming for lesion arrest/inactivation, to preserve dental hard tissues, avoid initiation of the restorative

- cycle (Elderton 1993; Qvist 2015) and retain the tooth for as long as possible (strong recommendation).
2. When cavitated carious lesions are non-cleansable and sealing is no longer an option, restorative interventions are indicated (strong recommendation).
 3. Restorative treatments are carried out to aid biofilm control, protect the pulp-dentine complex and restore the function, form and aesthetics of the tooth, whilst causing no unnecessary harm. The carious tissue removal stage aims to create conditions for a long lasting restoration, preserve healthy and remineralisable tissue, achieve a sufficient seal, maintain pulpal health and maximize success of the restoration. However, this does not necessarily mean that close to the pulp, all bacterially contaminated or demineralized tissues need to be removed (strong recommendation).
 4. In deeper lesions in teeth with still sensible (vital) pulps, preserving pulpal health should be prioritized over restoration success, whilst in shallow or moderately deep lesions, restoration longevity might be more important factor (strong recommendation).
 5. For teeth with shallow or moderately deep lesions, Selective Removal to Firm Dentine should be carried out (weak recommendation);
 6. In deep lesions (radiographically extending into pulpal third or quarter of the dentine) in primary and permanent teeth, Selective Removal to Soft Dentine should be performed (strong recommendation);
 7. In permanent teeth, Stepwise Removal might also be an option for deep lesions (strong recommendation).
 8. Hardness (e.g. soft, leathery, firm or scratchy, or hard) dentine should be the primary criterion for assessing, describing and reporting on carious tissue and their removal (weak recommendation).
 9. Moisture (wet, moist, dry), color (pale/yellow, dark brown/black) and additional optical characteristics of dentine or measures of different bacterial metabolic products might be useful as additional indicators (weak recommendation).
 10. There is insufficient evidence to recommend any single method for carious tissue removal. Hand or chemo-mechanical excavation might reduce pain and discomfort during treatment and could thus positively impact on dental anxiety, especially when treating children (weak recommendation).
 11. Cavity disinfection procedures currently have no evidence of patient benefit to support their use (weak recommendation).
 12. Placement of cavity lining materials are not necessary to control the sealed lesion, but might be beneficial in impeding monomer penetration and avoidance of fracture of the remaining dentine when resin composite is the restorative material (weak recommendation).

13. The choice of materials for restoring cavities should be guided by the location and extent of the lesion, the caries risk, carious lesion activity and the specific patient conditions and setting. There is no definitive evidence to support particular materials as more suitable than others for restoring teeth after selective carious tissue removal to soft or firm dentine (weak recommendation).
14. Re-treatment of restorations should aim to repair by resealing, refurbishing, or repolishing where possible and replacement should be a last resort (strong recommendation).

3.2 Knowledge gaps

15. Clinical trials investigating management of cavitated carious lesions should report full details, using agreed terms of:
 - lesion depth, activity, and extent
 - patients (caries risk and age), setting, who carried out the treatment and
 - how treatment was performed.

Journals should insist on this reporting and enforce use of appropriate terms (strong recommendation).

16. For trials investigating management of cavitated carious lesions both in clinical and laboratory settings, outcomes with sufficient validity and relevance to stakeholders, such as patients, dentists and healthcare regulators/funders, should be used. If surrogate measures are used, these should be validated against such outcomes (strong recommendation).
17. Clinical trials should clearly report a primary outcome (on which the study is powered), seek long-term follow-up, report on events and harms in detail, and continue to follow-up teeth after any event to allow judgment of the impact of different events on the described outcomes. Trials should be conducted with as high internal and external validity as possibly. These should be interpreted with an understanding of where true risk of bias lies given the limitations particularly in operator, participant and assessor blinding in some study designs and also of studies set in primary care and community settings. Limitations should be clearly expressed (strong recommendation).
18. Clinical trials should evaluate the combined effect of carious removal strategies and restorative procedures, including liners, adhesive strategies and restorative materials, as different strategy combinations are expected to impact differently on outcomes (strong recommendation).

19. Basic research should aim to answer the questions around the histological and immuno-pathological reaction of the pulp towards different carious tissue removal strategies, methods, and restorative procedures (strong recommendation).
20. Research efforts should endeavor to develop a method(s) that precisely and accurately ascertains pulpal health status in clinical settings (strong recommendation).

Declaration of Interests

The corresponding author formally requested a declaration of possible conflicts of interest from each of the consensus conference members. Declaration of interest at the organizational and individual levels are available from the lead author. The conference was kindly sponsored by GC Europe (Leuven, Belgium), DMG (Hamburg, Germany), 3M Espe (Seefeld, Germany) and Dentsply DeTrey (Konstanz, Germany). The sponsors had no role in design or conduct of the conference or the content of this manuscript, and were not present during the conference. Travel to the meeting and accommodation for LB, WB, SD, EK, MM, DM, KvL, AB, GC, MF, SL, EL, VM, AS, CS and AZ were supported by the sponsors. No honoraria were given to any of the participants.

Acknowledgements

ICCC would like to thank Lisbet Brike and Amy Caldwell-Nichols for organising travel and accommodation for the conference in Leuven and to Amy Caldwell-Nichols for additional document and manuscript preparation support. Thank you also to GC for the use of their premises in Leuven.

Grateful thanks also go to Professor Edwina Kidd, for her presentation, invaluable discussions at the meeting in Leuven and for her input into improving this manuscript and finally, for so generously sharing their wisdom and experience. We thank Prof. W. Buchalla for his contribution to the meeting and respect his decision not to support the content of the manuscript.

We thank the sponsors of this conference GC Europe (Leuven, Belgium), DMG (Hamburg, Germany), 3M Espe (Seefeld, Germany) and Dentsply DeTrey (Konstanz, Germany). Thanks also to GC Europe for the use of their premises in Leuven.

Authors contribution

Initiated and organized the consensus process: FS, JF, NI

Prepared abstracts for the meeting and held presentations: FS, LB, MM, DM, DR, KvL, NI

Contributed to the workshop and the consensus process before and after the workshop: all authors.

Wrote the initial draft of the manuscript: FS, JF, NI

Read, amended and approved the manuscript: all authors.

References

- About I, Murray PE, Franquin JC, Remusat M, Smith AJ. 2001. The effect of cavity restoration variables on odontoblast cell numbers and dental repair. *J Dent.* 29(2):109-117.
- Bader JD, Shugars DA, Bonito AJ. 2001. Systematic reviews of selected dental caries diagnostic and management methods. *J Dent Edu.* 65(10):960-968.
- Baelum V, Hintze H, Wenzel A, Danielsen B, Nyvad B. 2012. Implications of caries diagnostic strategies for clinical management decisions. *Community Dent Oral Epidemiol.* 40(3):257-266.
- Banerjee A, Domejean S. 2013. The contemporary approach to tooth preservation: minimum intervention (MI) caries management in general practice. *Prim Dent J.* 2(3):30-37.
- Banerjee A, Kidd EA, Watson TF. 2000. In vitro evaluation of five alternative methods of carious dentine excavation. *Caries Res.* 34(2):144-150.
- Banerjee A, Yasserli M, Munson M. 2002. A method for the detection and quantification of bacteria in human carious dentine using fluorescent in situ hybridisation. *J Dent.* 30:359-363.
- Bjørndal L, Demant S, Dabelsteen S. 2014. Depth and activity of carious lesions as indicators for the regenerative potential of dental pulp after intervention. *J Endod.* 40(4 Suppl):76S-81S.
- Bjørndal L, Larsen T. 2000. Changes in the cultivable flora in deep carious lesions following a stepwise excavation procedure. *Caries Res.* 34(6):502-508.
- Bjørndal L, Larsen T, Thylstrup A. 1997. A clinical and microbiological study of deep carious lesions during stepwise excavation using long treatment intervals. *Caries Res.* 31(6):411-417.
- Bjørndal L, Reit C, Bruun G, Markvart M, Kjaeldgaard M, Nasman P, Thordrup M, Dige I, Nyvad B, Fransson H et al. 2010. Treatment of deep caries lesions in adults: randomized clinical trials comparing stepwise vs. direct complete excavation, and direct pulp capping vs. partial pulpotomy. *Eur J Oral Sci.* 118(3):290-297.
- Bjørndal L, Ricucci D. 2014. Pulp inflammation: From the reversible inflammation to pulp necrosis during caries progression. In: Michel Goldberg, editor. *The dental pulp biology, pathology, and regenerative therapies.* Berlin Heidelberg, Springer. p 125-139.
- Boston DW. 2003. New device for selective dentin caries removal. *Quintessenz Int.* 34(9):678-685.

Celiberti P, Francescut P, Lussi A. 2006. Performance of four dentine excavation methods in deciduous teeth. *Caries Res.* 40(2):117-123.

Chibinski AC, Reis A, Kreich EM, Tanaka JL, Wambier DS. 2013. Evaluation of primary carious dentin after cavity sealing in deep lesions: A 10- to 13-month follow-up. *Pediatr Dent.* 35(3):E107-112.

Corralo DJ, Maltz M. 2013. Clinical and ultrastructural effects of different liners/restorative materials on deep carious dentin: A randomized clinical trial. *Caries Res.* 47(3):243-250.

Dalpian DM, Ardenghi TM, Demarco FF, Garcia-Godoy F, De Araujo FB, Casagrande L. 2014. Clinical and radiographic outcomes of partial caries removal restorations performed in primary teeth. *Am J Dent.* 27(2):68-72.

de Menezes Abreu DM, Leal SC, Mulder J, Frencken JE. 2011. Pain experience after conventional, atraumatic, and ultraconservative restorative treatments in 6- to 7-yr-old children. *Eur J Oral Sci.* 119(2):163-168.

De Munck J, Van Meerbeek B, Yoshida Y, Inoue S, Vargas M, Suzuki K, Lambrechts P, Vanherle G. 2003. Four-year water degradation of total-etch adhesives bonded to dentin. *J Dent Res.* 82(2):136-140.

do Amaral GS, de Cassia Negrini T, Maltz M, Arthur RA. 2015. Restorative materials containing antimicrobial agents: Is there evidence for their antimicrobial and anti-caries effects? - a systematic-review. *Austr Dent J.* doi: 10.1111/adj.12338. (Epub ahead of print)

Elderton RJ. 1993. Overtreatment with restorative dentistry: When to intervene? *Int Dent J.* 43(1):17-24.

Farag A, van der Sanden WJ, Abdelwahab H, Mulder J, Frencken JE. 2009. 5-year survival of art restorations with and without cavity disinfection. *J Dent.* 37(6):468-474.

Fejerskov O, Nyvad B, Kidd EA. 2015. Pathology of dental caries. In Fejerskov O, Nyvad B, Kidd EAM, editors: *Dental caries: The disease and its clinical management*. 3rd ed. Oxford, Wiley Blackwell. p 7-9.

Frencken J, Leal S, de Lima Navarro M. 2012a. Twenty-five-year atraumatic restorative treatment (ART) approach: A comprehensive overview. *Clin Oral Investig.* 16(5):1337-1346.

Frencken JE, Peters MC, Manton DJ, Leal SC, Gordan VV, Eden E. 2012b. Minimal intervention dentistry for managing dental caries - a review: Report of a FDI task group. *Int Dent J.* 62(5):223-243.

Fusayama T. 1997. The process and results of revolution in dental caries treatment. *Int Dent J.* 47(3):157-166.

Fusayama T, Kurosaki N. 1972. Structure and removal of carious dentin. *Int Dent J.* 22(3):401-411.

Galler K, Hiller KA, Ettl T, Schmalz G. 2005. Selective influence of dentin thickness upon cytotoxicity of dentin contacting materials. *J Endod.* 31(5):396-399.

Going RE, Loesche WJ, Grainger DA, Syed SA. 1978. The viability of microorganisms in carious lesions five years after covering with a fissure sealant. *J Amer Dent Assoc.* 97(3):455-462.

Green D, Mackenzie L, Banerjee A. 2015. Minimally invasive long term management of direct restorations: The "5rs". *Dent Update.* 42:413-426.

Griffin SO, Oong E, Kohn W, Vidakovic B, Gooch BF, Bader J, Clarkson J, Fontana MR, Meyer DM, Rozier RG et al. 2008. The effectiveness of sealants in managing caries lesions. *J Dent Res.* 87(2):169-174.

Gruythuysen R. 2010. Non-restorative cavity treatment. Managing rather than masking caries activity. *Nederlands tijdschrift voor tandheelkunde.* 117(3):173-180.

Hashem D, Mannocci F, Patel S, Manoharan A, Brown JE, Watson TF, Banerjee A. 2015. Clinical and radiographic assessment of the efficacy of calcium silicate indirect pulp capping: A randomized controlled clinical trial. *J Dent Res.* 94(4):562-568.

Hebling J, Giro EM, Costa CA. 1999. Biocompatibility of an adhesive system applied to exposed human dental pulp. *J Endod.* 25(10):676-682.

Heintze SD. 2013. Clinical relevance of tests on bond strength, microleakage and marginal adaptation. *Dent Mater.* 29(1):59-84.

Hilgert L, Leal S, Mulder J, Creugers N, Frencken J. 2015. Caries-preventive effect of supervised toothbrushing and sealants. *J Dent Res.* 94(9):1218-1224.

Kelly PG, Smales RJ. 2004. Long-term cost-effectiveness of single indirect restorations in selected dental practices. *Br Dent J.* 196(10):639-643; discussion 627.

Kidd EA: How 'clean' must a cavity be before restoration? 2004. *Caries Res.* 38(3):305-313.

Kidd EA, Joyston-Bechal S, Beighton D. 1993. Microbiological validation of assessments of caries activity during cavity preparation. *Caries Res.* 27(5):402-408.

Kopperud SE, Tveit AB, Gaarden T, Sandvik L, Espelid I. 2012. Longevity of posterior dental restorations and reasons for failure. *Eur J Oral Sci.* 120(6):539-548.

Lo EC, Schwarz E, Wong MC. 1998. Arresting dentine caries in Chinese preschool children. *Int J Paed Dent.* 8(4):253-260.

Maltz M, Garcia R, Jardim JJ, de Paula LM, Yamaguti PM, Moura MS, Garcia F, Nascimento C, Oliveira A, Mestrinho HD. 2012a. Randomized trial of partial vs. Stepwise caries removal: 3-year follow-up. *J Dent Res.* 91(11):1026-1031.

Maltz M, Henz SL, de Oliveira EF, Jardim JJ. 2012b. Conventional caries removal and sealed caries in permanent teeth: A microbiological evaluation. *J Dent.* 40(9):776-782.

Manhart J, Chen HY, Hamm G, Hickel, R. 2004. Review of the clinical survival of direct and indirect restorations in posterior teeth of the permanent dentition. *Oper Dent.* 29(5):481-508.

Mejare IA, Axelsson S, Davidson T, Frisk F, Hakeberg M, Kvist T, Norlund A, Petersson A, Portenier I, Sandberg H et al. 2012. Diagnosis of the condition of the dental pulp: A systematic review. *Int Endod J.* 45(7):597-613.

Mialhe FL, Pereira AC, Meneghim Mde C, Ambrosano GM, Pardi V. 2009. The relative diagnostic yields of clinical, fof and radiographic examinations for the detection of approximal caries in youngsters. *Indian J Dent Res.* 20(2):136-140.

Mickenautsch S, Yengopal V. 2012. Failure rate of high-viscosity gic based art compared with that of conventional amalgam restorations--evidence from an update of a systematic review. *SADJ.* 67(7):329-331.

Mijan M, de Amorim RG, Leal SC, Mulder J, Oliveira L, Creugers NH, Frencken JE. 2014. The 3.5-year survival rates of primary molars treated according to three treatment protocols: A controlled clinical trial. *Clin Oral Investig.* 18(4):1061-1069.

Modena KC, Casas-Apayco LC, Atta MT, Costa CA, Hebling J, Sipert CR, Navarro MF, Santos CF. 2009. Cytotoxicity and biocompatibility of direct and indirect pulp capping materials. *J Appl Oral Sci.* 17(6):544-554.

Munson MA, Banerjee A, Watson TF, Wade WG. 2004. Molecular analysis of the microflora associated with dental caries. *J Clin Microbiol.* 42(7):3023-3029.

Nadanovsky P, Cohen Carneiro F, Souza de Mello F. 2001. Removal of caries using only hand instruments: A comparison of mechanical and chemo-mechanical methods. *Caries Res.* 35(5):384-389.

- Neves Ade A, Coutinho E, De Munck J, Van Meerbeek B. 2011. Caries-removal effectiveness and minimal-invasiveness potential of caries-excavation techniques: A micro-ct investigation. *J Dent.* 39(2):154-162.
- Ngo HC, Mount G, Mc Intyre J, Tuisuva J, Von Doussa RJ. 2006. Chemical exchange between glass-ionomer restorations and residual carious dentine in permanent molars: An in vivo study. *J Dent.* 34(8):608-613.
- Ogawa K, Yamashita Y, Ichijo T, Fusayama T. 1983. The ultrastructure and hardness of the transparent layer of human carious dentin. *J Dent Res.* 62(1):7-10.
- Oong EM, Griffin SO, Kohn WG, Gooch BF, Caufield PW. 2008. The effect of dental sealants on bacteria levels in caries lesions. *J Amer Dent Assoc.* 139(3):271-278.
- Opdam NJ, Bronkhorst EM, Loomans BA, Huysmans MC. 2010. 12-year survival of composite vs. Amalgam restorations. *J Dent Res.* 89(10):1063-1067.
- Orhan A, Oz F, Ozcelik B, Orhan K. 2008. A clinical and microbiological comparative study of deep carious lesion treatment in deciduous and young permanent molars. *Clin Oral Investig.* 12(4):369-378.
- Orhan AI, Oz FT, Orhan K. 2010. Pulp exposure occurrence and outcomes after 1- or 2-visit indirect pulp therapy vs complete caries removal in primary and permanent molars. *Pediatr Dent.* 32(4):347-355.
- Paddick JS, Brailsford SR, Kidd EA, Beighton D. 2005. Phenotypic and genotypic selection of microbiota surviving under dental restorations. *Appl Environ Microbiol.* 71(5):2467-2472.
- Perdigão J. 2010. Dentin bonding—variables related to the clinical situation and the substrate treatment. *Dent Mater.* 26(2):e24-e37.
- Petrou M, Alhamoui F, Welk A, Altarabulsi M, Alkilzy M, H. Splieth C. 2014. A randomized clinical trial on the use of medical portland cement, MTA and calcium hydroxide in indirect pulp treatment. *Clin Oral Investig.* 18(5):1383-1389.
- Qvist V. 2015. Longevity of restorations: The 'death spiral'. In: Fejerskov O, Kidd EAM. (eds). *Dental caries: The disease and its clinical management.* 3rd ed. Oxford, Blackwell Munksgaard. P388.
- Rafique S, Fiske J, Banerjee A. 2003. Clinical trial of an air-abrasion/chemomechanical operative procedure for the restorative treatment of dental patients. *Caries Res.* 37(5):360-364.

- Raggio DP, Hesse D, Lenzi TL, C ABG, Braga MM. 2013. Is atraumatic restorative treatment an option for restoring occlusoproximal caries lesions in primary teeth? A systematic review and meta-analysis. *Int J Paed Dent.* 23(6):435-443.
- Rahimtoola S, van Amerongen E, Maher R, Groen H. 2000. Pain related to different ways of minimal intervention in the treatment of small caries lesions. *ASDC.* 67(2):123-127, 183.
- Ricketts D, Kidd E, Weerheijm K, de Soet H. 1997. Hidden caries: What is it? Does it exist? Does it matter? *Int Dent J.* 47(5):259-265.
- Ricketts D, Lamont T, Innes NP, Kidd E, Clarkson JE. 2013. Operative caries management in adults and children. *Cochrane Database Syst Rev.* 28:CD003808.
- Ricketts DN, Kidd EA, Beighton D. 1995. Operative and microbiological validation of visual, radiographic and electronic diagnosis of occlusal caries in non-cavitated teeth judged to be in need of operative care. *Br Dent J.* 179(6):214-220.
- Schriks MC, van Amerongen WE. 2003. Atraumatic perspectives of art: Psychological and physiological aspects of treatment with and without rotary instruments. *Community Dent Oral Epidemiol.* 31(1):15-20.
- Schwendicke F, Meyer-Lückel H, Dorfer C, Paris S. 2013a. Failure of incompletely excavated teeth - a systematic review. *J Dent.* 41(7):569-580.
- Schwendicke F, Paris S, Tu Y. 2014. Effects of using different criteria and methods for caries removal: A systematic review and network meta-analysis. *J Dent.* 43(1):1-15.
- Schwendicke F, Stolpe M. 2014. Direct pulp capping after a carious exposure versus root canal treatment: A cost-effectiveness analysis. *J Endod.* 40(11):1764-1770.
- Schwendicke F, Stolpe M, Meyer-Lueckel H, Paris S, Dörfer CE. 2013b. Cost-effectiveness of one- and two-step incomplete and complete excavations. *J Dent Res.* 92(10):880-887.
- Schwendicke F, Tu YK, Hsu LY, Gostemeyer G. 2015. Antibacterial effects of cavity lining: A systematic review and network meta-analysis. *J Dent.* 43(11):1298-1307
- Smith AJ, Murray PE, Sloan AJ, Matthews JB, Zhao S. 2001. Trans-dentinal stimulation of tertiary dentinogenesis. *Adv Dent Res.* 15:51-54.
- Tjaderhane L. 2015. Dentin bonding: Can we make it last? *Oper Dent.* 40(1):4-18.
- United Nations Environmental Programme: Minamata convention on mercury. 2013. New York, United Nations.

Van Meerbeek B, Peumans M, Poitevin A, Mine A, Van Ende A, Neves A, De Munck J. 2010. Relationship between bond-strength tests and clinical outcomes. *Dent Mater.* 26(2):e100-e121.

Wambier DS, dos Santos F, bio A, Guedes-Pinto AC, Jaeger RG, Simionato MRL. 2007. Ultrastructural and microbiological analysis of the dentin layers affected by caries lesions in primary molars treated by minimal intervention. *Pediatr Dent.* 29(3):228-234.

Whitworth JM, Myers PM, Smith J, Walls AW, McCabe JF. 2005. Endodontic complications after plastic restorations in general practice. *Int Endod J.* 38(6):409-416.

Yoshiyama M, Tay FR, Doi J, Nishitani Y, Yamada T, Ito K, Carvalho RM, Nakajima M, Pashley DH. 2002. Bonding of self-etch and total-etch adhesives to carious dentin. *J Dent Res.* 81(8):556-560.

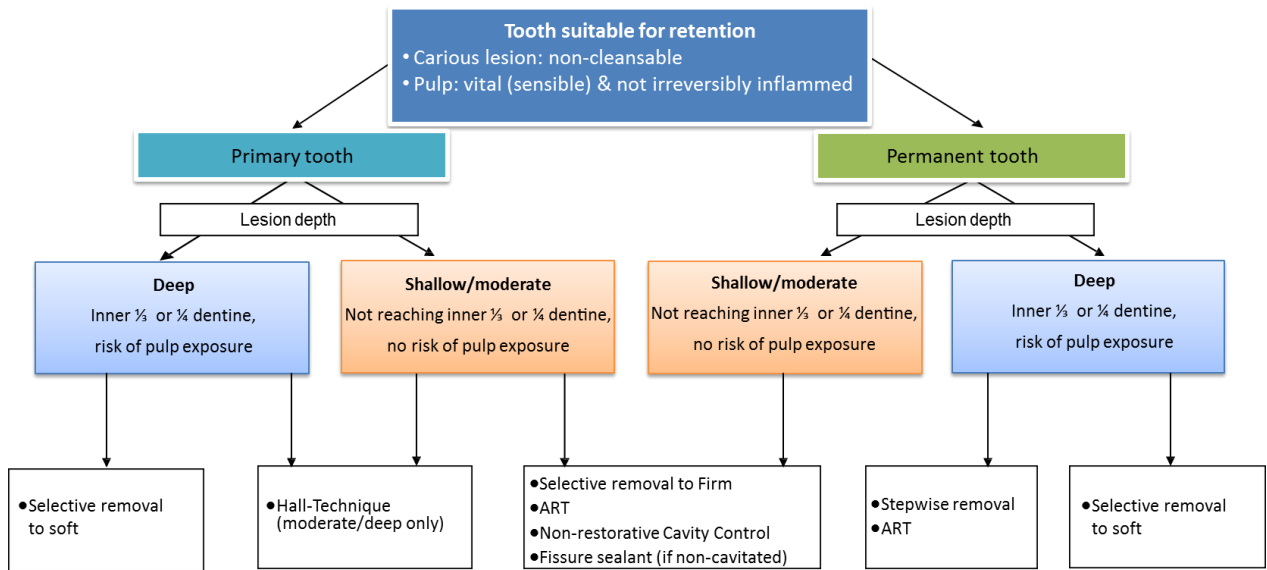


Figure 1. Decision-making for non-cleansable carious lesions in retainable teeth with vital pulps