

## Mandibular asymmetry in unilateral and bilateral posterior crossbite patients using cone-beam computed tomography

Ilknur Veli<sup>a</sup>; Tancan Uysal<sup>b</sup>; Torun Ozer<sup>c</sup>; Faruk Izzet Ucar<sup>d</sup>; Murat Erüz<sup>d</sup>

### ABSTRACT

**Objective:** To test the hypotheses that (1) there is no difference in mandibular asymmetry between the crossbite and normal side in a unilateral crossbite group (UCG) and between the right and left sides in a bilateral crossbite group (BCG) and a control group (CG); and (2) there is no significant difference in mandibular asymmetry among crossbite groups and control group.

**Materials and Methods:** The cone-beam computed tomography scans of three groups were studied: (1) 15 patients (6 male, 9 female; mean age:  $13.51 \pm 2.03$  years) with unilateral posterior crossbite; (2) 15 patients (8 male, 7 female; mean age:  $13.36 \pm 2.12$  years) with bilateral posterior crossbite; and (3) 15 patients (8 male, 7 female; mean age:  $13.46 \pm 1.53$  years) as a control group. Fourteen parameters (eight linear, three surface, and three volumetric) were measured. Side comparisons were analyzed with paired samples *t*-test, and for the intergroup comparison, analysis of variance (ANOVA) and Tukey tests were used at the  $P < .05$  level.

**Results:** According to side comparisons, no statistically significant difference was found in the UCG. There were statistically significant differences in hemimandibular ( $P = .008$ ) and ramal ( $P = .004$ ) volumes for the BCG and in ramal height ( $P = .024$ ) and body length ( $P = .021$ ) for the CG. Intergroup comparisons revealed significant differences in hemimandibular ( $P = .002$ ) and body volume ( $P < .001$ ) for the normal side of the UCG and left sides of the other groups, and in angular unit length ( $P = .025$ ) and condylar width ( $P = .007$ ) for the crossbite side of the UCG and the right sides of the other groups.

**Conclusions:** Contrary to UCG, CG and BCG were found to have side-specific asymmetry. Skeletal components of the mandible have significant asymmetry among the crossbite groups and the CG. (*Angle Orthod.* 2011;81:966–974.)

**KEY WORDS:** Asymmetry; Cone-beam computed tomography; Crossbite

### INTRODUCTION

Posterior crossbite has been defined as a transversal arch discrepancy in which the palatal cusps of one

or more of the upper posterior teeth do not occlude in the central fossae of the opposing lower teeth.<sup>1</sup> A posterior crossbite may be unilateral or bilateral when the patient bites into maximum intercuspation.<sup>2</sup>

Possible etiologies of crossbites include prolonged retention or premature loss of deciduous teeth, crowding, palatal cleft, genetic control, arch deficiencies, abnormalities in tooth anatomy or eruption sequence, oral digit habits, oral respiration during growth periods, and malfunctioning temporomandibular joints.<sup>3</sup>

Posterior crossbite may have long-term effects on the growth and development of the teeth and jaws.<sup>2,4</sup> The abnormal movement of the lower jaw may place strain on the orofacial structures, causing adverse effects on the temporomandibular joints and masticatory system. Also, the asymmetrical function and activity of the jaws and muscles in posterior crossbite patients were reported to cause different development of the right and left sides of the mandible.<sup>5</sup> The studies

<sup>a</sup> Research Assistant, Department of Orthodontics, Faculty of Dentistry, Dicle University, Diyarbakir, Turkey.

<sup>b</sup> Professor and Head, Department of Orthodontics, Faculty of Dentistry, Izmir Katip Celebi University, Izmir, Turkey; Professor, Department of Pediatric Dentistry and Orthodontics, College of Dentistry, King Saud University, Riyadh, Saudi Arabia.

<sup>c</sup> Associate Professor, Department of Orthodontics, Faculty of Dentistry, Dicle University, Diyarbakir, Turkey.

<sup>d</sup> Research Assistant, Department of Orthodontics, Faculty of Dentistry, Erciyes University, Kayseri, Turkey.

Corresponding author: Dr Tancan Uysal, Izmir Katip Celebi Üniversitesi, Diş Hekimliği Fakültesi, Ortodonti AD Cıgli, Izmir, Turkey

(e-mail: tancan.uysal@ikc.edu.tr)

Accepted: April 2011. Submitted: February 2011.

Published Online: May 18, 2011.

© 2011 by The EH Angle Education and Research Foundation, Inc.

**Table 1.** Inclusion Criteria for Sample Selection

Control Group	Unilateral Crossbite Group	Bilateral Crossbite Group
*Skeletal and dental Class I relationship with well-aligned maxillary and mandibular dental arches	*Skeletal and dental Class I relationship with unilateral posterior crossbites involving at least two posterior teeth in crossbite	*Skeletal and dental Class I relationship with at least two teeth in reverse occlusion in the posterior teeth on both sides
*No significant medical history, systemic disease, or neuromuscular deformities	*No significant medical history, systemic disease, or neuromuscular deformities	*No significant medical history, systemic disease, or neuromuscular deformities
*No history of trauma or previous orthodontic or prosthodontic treatment, or maxillofacial or plastic surgery	*No history of trauma or previous orthodontic or prosthodontic treatment, or maxillofacial or plastic surgery	*No history of trauma or previous orthodontic or prosthodontic treatment, or maxillofacial or plastic surgery
*All teeth present except the third molars	*All teeth present except the third molars	*All teeth present except the third molars
*No functional deviation of the mandible	*Functional deviation of the mandible	*No carious lesions, extensive restorations, or pathologic periodontal status
*No carious lesions, extensive restorations, or pathologic periodontal status	*No carious lesions, extensive restorations, or pathologic periodontal status	
*No signs or symptoms of TMD <sup>a</sup>	*No signs or symptoms of TMD <sup>a</sup>	*No signs or symptoms of TMD <sup>a</sup>

<sup>a</sup> TMD indicates temporomandibular disorder.

of adolescents and adults have revealed that patients with posterior crossbite have an increased risk to develop craniomandibular disorders, showing more signs and symptoms of these problems.<sup>6</sup> In most cases, the crossbite is accompanied by a mandibular shift, a so-called forced crossbite, which causes midline deviation.<sup>7</sup> A forced bite will cause alterations in the activity of the jaw muscles<sup>8</sup> and may lead to skeletal changes with asymmetry of the face in the course of facial growth.<sup>9</sup> Although perfect facial symmetry does not exist in nature, asymmetry ranges from clinically undetectable to gross abnormality.<sup>10</sup>

In literature, mandibular asymmetry has been assessed by a combination of tools. These include clinical examination followed by photographs of frontal and side views, in addition to two-dimensional (2D) radiographs such as lateral and posteroanterior cephalograms, oblique radiographs of the mandible taken at 45°, and panoramic radiographs.<sup>10,11</sup>

One of the great shortcomings of the 2D radiographs is that they are 2D representations of three-dimensional (3D) structures. However, 2D images are not a good representation of the patient's 3D anatomic truth. Cone-beam computed tomography (CBCT) technology makes it possible to create anatomically true (1:1 in size) images devoid of magnification and superimposition.<sup>12</sup> Enlow<sup>13</sup> reported that, "The near-future will be based on the actual biology of an individual's own craniofacial growth and development, and it will be determined by a 3D evaluation based on that person's actual morphogenic characteristics, not simply developmentally irrelevant radiographic landmarks."

Although the assessment of mandibular asymmetry has been of great interest in orthodontic literature,<sup>10,12</sup> no published study has compared the mandibular asymmetry by using CBCT in unilateral and bilateral crossbite patients with a normal occlusion sample. Therefore, the aim of this study was to test the null

hypotheses that: (1) there is no significant difference in mandibular asymmetry between the crossbite and normal side in a unilateral crossbite group (UCG) and the right and left sides in a bilateral crossbite group (BCG) and control group (CG); and (2) there is no significant difference in mandibular asymmetry among the crossbite groups and CG.

## MATERIALS AND METHODS

The present study was carried out on the CBCT scans of three groups selected from the archives of the Oral and Maxillofacial Radiology Department of Faculty of Dentistry, Dicle University. By January 2011, 1520 sets of images were in the database of the department, and subjects who fulfilled the inclusion criteria (Table 1) were selected from the initial sample of CBCT scans.

The CBCT scans of three groups were studied: (1) 15 patients (6 male, 9 female; mean age: 13.51 ± 2.03 years) with unilateral posterior crossbite; (2) 15 patients (8 male, 7 female; mean age: 13.36 ± 2.12 years) with bilateral posterior crossbite; and (3) 15 patients (8 male, 7 female; mean age: 13.46 ± 1.53 years) as a control group.

CBCT scans of these patients were obtained as a part of the diagnostic records gathered for comprehensive orthodontic treatment; therefore, they were not unnecessarily subjected to additional radiation. Because this study was an archive study, ethics committee approval was not needed. Also in our university as a usual protocol, all patients or the parents already signed an informed consent form recording their agreement for CBCT exposure.

All CBCT images were acquired with an iCAT 3D imaging device (Imaging Sciences International, Hatfield, Pa). The device was set for 5.0 mA and 120 kV. A 9.6-second scan with a single 360 degree rotation created images with a voxel size of 0.3 mm. As a

**Table 2.** Description of Mandibular Landmarks

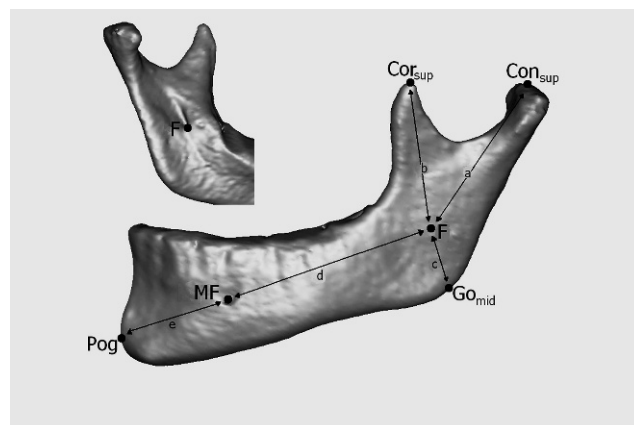
Landmark	Definition
Consup (condyion superius)	The most superior point of the condylar head
Conmed (condyion medialis)	The most medial point of the condylar head
Conlat (condyion lateralis)	The most lateral point of the condylar head
Corsup (coronoid superius)	The most superior point of the coronoid process
F (fossa of mandibular foramen)	The most inferior point on the fossa of the mandibular foramen
Jlat	The most lateral and deepest point of the curvature formed at the junction of the mandibular ramus and body
Jmed	The most medial and deepest point of the curvature formed at the junction of the mandibular ramus and body
Gopost (gonion posterius)	The most posterior point on the mandibular angle
Gomid (gonion midpoint)	The midpoint between Gopost and Goinf on the mandibular angle
Goinf (gonion inferius)	The most inferior point on the mandibular angle
MF (mental foramen)	The entrance of the mental foramen
Me (menton)	The most inferior midpoint on the symphysis
Pog (pogonion)	The most anterior midpoint on the symphysis
B (supramentale)	The midpoint of the greatest concavity on the anterior border of the symphysis
G (genial tubercle)	The midpoint on genial tubercle

routine image exposure protocol, the patients' heads were oriented by adjusting the Frankfort plane parallel to the horizontal plane, and the CBCT scans were taken while the patients bit into maximum intercuspation.

Digital Imaging and Communications in Medicine (DICOM) files obtained from the CBCT scans were reconstructed by Mimics 10.0 (Materialise NV, Leuven, Belgium) software. By using the manual-segmentation function of the software, the mandibles were separated from the whole images, and the teeth above the alveolar bone in the mandibles were removed. All landmark identifications and measurements were made using this software.

Assessment of mandibular asymmetry was performed in a manner similar to the study by You et al.<sup>14</sup>

In their study, reconstructed 3D surface models of the mandibles were separated into two parts by a midsagittal reference line passing through menton and B point. Landmarks were designated on the reconstructed 3D surface models, and linear and volumetric measurements were performed in hemimandibles.

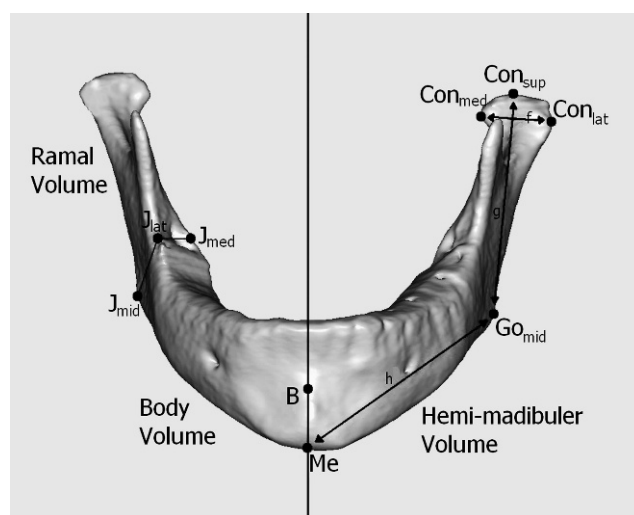


**Figure 1.** Landmarks and measurements used in this study. (a) Condylar unit length: Consup-F. (b) Coronoid unit length: Corsup-F. (c) Angular unit length: F-Gomid. (d) Body unit length: F-MF. (e) Chin unit length: MF-Pog.

Landmarks (Table 2) and measurements used in this study are shown in Figures 1 through 3. Also, surface areas of mandibular parts were calculated. All linear measurements were performed by controlling the localization of the landmarks in all dimensions on the reconstructed 3D surface models. To prevent interobserver variability, all landmark identifications and measurements were made by one author.

### Statistical Analyses

To study the measurement errors, 15 CBCT images were randomly selected and remeasured 4 weeks after the first measurements. A Bland and Altman plot was



**Figure 2.** Landmarks and measurements used in this study. (f) Condylar width: Conmed-Conlat. (g) Ramal height: Consup-Gomid. (h) Body length: Gomid-Me; hemimandibular volume: the division of mandibular volume into two hemimandibular volumes by the plane connecting Me, B, and G. Ramal and body volumes: the division of hemimandibular volume into ramal and body volumes by the plane connecting Gomid, Jlat, and Jmed.

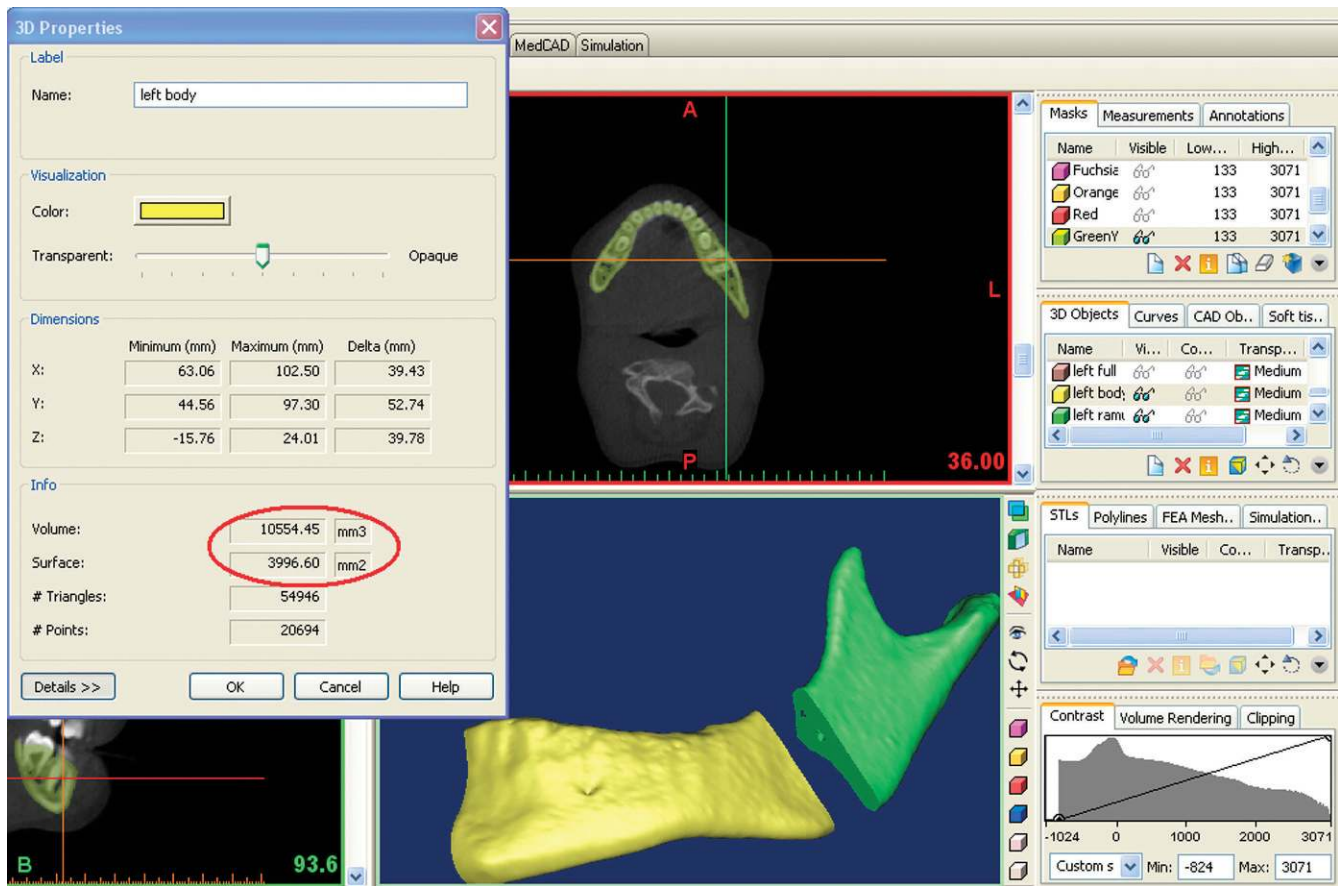


Figure 3. Surface and volumetric measurements.

applied to assess the repeatability, and no significant differences were found between the first and second measurements (Table 3).

The data analyses and statistical significance were checked by using the Statistical Package for the Social Sciences (SPSS), version 13.0 (SPSS Inc, Chicago, Ill) at the level of  $P < .05$ . The normality test of Shapiro-Wilks and Levene's variance homogeneity

test were applied to the data, and all data were found normally distributed. Thus, the statistical evaluations of these data were performed using parametric tests.

The paired samples *t*-test was used to determine possible statistically significant differences between the crossbite and normal sides in the UCG and right and left sides in the other two groups. One-way analysis of variance (ANOVA) and Tukey Honestly

Table 3. Bland and Altman Plot to Assess the Repeatability<sup>a</sup>

Measurements	Correlation	Bias	95% CI	Standard Error	Standard Deviation
Condylar unit length	-0.30	0.661	0.580 to 0.742	0.038	2.947
Body unit length	0.19	0.213	0.153 to 0.272	0.028	0.107
Coronoid unit length	-0.19	0.663	0.590 to 0.735	0.033	6.042
Angular unit length	0.20	0.677	0.603 to 0.751	0.035	9.731
Chin unit length	-0.21	0.168	0.116 to 0.220	0.024	0.094
Condylar width	0.03	0.177	0.112 to 0.242	0.030	0.117
Ramal height	-0.08	0.433	0.197 to 0.670	0.110	0.427
Body length	-0.02	0.385	0.282 to 0.487	0.048	0.185
Hemimandibular volume	-0.45	0.760	0.597 to 0.923	0.076	0.295
Hemimandibular surface	0.04	9.059	-2.857 to 20.97	5.556	2.151
Ramal volume	-0.18	0.867	0.667 to 1.066	0.093	0.360
Ramal surface	-0.40	1.046	0.801 to 1.291	0.114	0.442
Body volume	-0.16	1.133	0.886 to 1.381	0.115	0.447
Body surface	-0.34	1.313	1.158 to 1.468	0.072	0.280

<sup>a</sup> CI indicates confidence interval.

**Table 4.** Side Comparison of the Linear, Surface, and Volumetric Measurements in All Subjects<sup>a</sup>

Measurements	Control Group					Unilateral Crossbite Group					Bilateral Crossbite Group				
	Left Side		Right Side		P Value	Normal Side		Crossbite Side		P Value	Left Side		Right Side		P Value
	Mean	SD	Mean	SD		Mean	SD	Mean	SD		Mean	SD	Mean	SD	
Condylar unit length, mm	41.98	3.84	43.53	6.68	.130 NS	42.34	3.19	42.96	4.57	.484 NS	41.94	3.69	42.59	4.44	.309 NS
Body unit length, mm	56.80	4.92	55.76	4.47	.359 NS	57.23	3.29	56.78	4.40	.600 NS	53.76	3.36	53.76	3.98	.986 NS
Coronoid unit length, mm	37.72	8.03	38.80	5.06	.685 NS	38.99	4.29	39.54	4.67	.455 NS	39.04	5.51	39.11	4.78	.909 NS
Angular unit length, mm	22.81	9.58	20.79	2.90	.487 NS	22.68	10.53	19.68	3.79	.290 NS	20.32	10.24	17.50	2.94	.245 NS
Chin unit length, mm	27.49	4.87	26.64	2.92	.538 NS	28.90	2.24	28.89	2.14	.983 NS	30.45	3.06	29.16	1.62	.110 NS
Condylar width, mm	17.28	2.02	17.24	1.83	.885 NS	18.67	2.69	19.05	2.22	.465 NS	17.29	1.69	16.85	1.62	.202 NS
Ramal height, mm	58.77	5.16	61.10	5.09	.024 *	56.97	5.01	57.30	5.61	.700 NS	54.94	4.24	54.86	4.57	.889 NS
Body length, mm	77.67	9.34	72.12	11.83	.021 *	81.55	6.20	81.46	4.95	.919 NS	79.74	4.91	79.39	3.95	.625 NS
Hemimandibular volume, cm <sup>3</sup>	28.16	4.46	28.42	4.72	.743 NS	25.34	3.09	25.38	3.41	.944 NS	23.11	2.90	22.57	3.00	.008 **
Hemimandibular surface, cm <sup>2</sup>	13.78	3.12	13.23	1.72	.288 NS	12.34	2.06	12.12	1.82	.490 NS	12.02	1.51	12.06	1.36	.760 NS
Ramal volume, cm <sup>3</sup>	8.04	1.72	7.95	1.60	.598 NS	8.26	3.35	8.47	2.90	.839 NS	7.72	1.55	7.13	1.77	.004 **
Ramal surface, cm <sup>2</sup>	5.01	1.93	4.90	1.09	.770 NS	4.81	1.21	4.70	1.00	.669 NS	4.77	0.79	4.66	0.75	.151 NS
Body volume, cm <sup>3</sup>	20.73	3.52	20.39	3.37	.425 NS	17.08	2.95	17.99	2.29	.232 NS	15.63	2.03	15.78	2.17	.485 NS
Body surface, cm <sup>2</sup>	8.77	1.40	8.55	1.59	.263 NS	7.51	1.55	7.64	1.45	.512 NS	7.24	0.88	7.38	0.78	.248 NS

<sup>a</sup> SD indicates standard deviation.

\*  $P < .05$ ; \*\*  $P < .01$ . NS indicates not statistically significant.

Significant Difference (HSD) test were used to determine statistically significant differences among groups for all measurements. Probability values less than .05 were accepted as significant.

## RESULTS

Means, standard deviations, and comparisons of the linear, surface, and volumetric measurements for the crossbite and normal sides in the UCG and the right and left sides in the other groups are given in Table 4.

The results of the Student's *t*-test showed no statistically significant side differences in UCG. BCG showed statistically significant side differences in hemimandibular volume ( $P = .008$ ) and ramal volume ( $P = .004$ ) measurements. Both measurements were found greater on the left side than on the right side. Comparison of the measurements between the right and left sides in the CG revealed significant differences in ramal height ( $P = .024$ ) and body length ( $P = .021$ ). Although the ramal height was found longer on the right side, the body length was longer on the left side than that on the right side. Thus, the first null hypotheses of this study were partially rejected.

The intergroup comparisons for the left and right sides are given in Tables 5 and 6, respectively. For the normal side of the UCG and the left sides of the other groups, one-way ANOVA showed significant differences in body unit length ( $P = .040$ ), hemimandibular volume ( $P = .002$ ), body volume ( $P < .001$ ), and body surface ( $P = .006$ ). Hemimandibular volume was found significantly greater in CG than BCG ( $P = .001$ ). Also, body volume and body surface measurements were significantly different between the CG and UCG ( $P < .001$ ), as well as between the CG and BCG ( $P = .006$ ).

For the crossbite side of the UCG and the right sides of the other groups, significantly greater differences were found in angular unit length ( $P = .025$ ), chin unit length ( $P = .008$ ), condylar width ( $P = .007$ ), ramal height ( $P = .007$ ), body length ( $P = .005$ ), hemimandibular volume ( $P = .001$ ), and body volume ( $P < .001$ ) measurements. The angular unit length was found longer in the CG than in BCG ( $P = .021$ ). Chin unit length was shorter in the CG than in the UCG ( $P = .028$ ) and BCG ( $P = .012$ ). The condylar width was wider in the UCG than in the CG ( $P = .034$ ) and BCG

**Table 5.** Descriptive Statistics and Statistical Comparisons of Measurements Between Groups for the Left Sides and Normal Side<sup>a</sup>

Measurements	Control Group (CG)		Unilateral Crossbite Group (UCG)		Bilateral Crossbite Group (BCG)		ANOVA	Multiple Comparison Tukey HSD Test (P Value)		
	Mean	SD	Mean	SD	Mean	SD		CG-UCG	CG-BCG	UCG-BCG
Condylar unit length, mm	42.08	3.51	41.98	3.84	41.94	3.69	NS	.959	1.000	.951
Body unit length, mm	56.80	4.92	57.23	3.29	53.76	3.36	*	.951	.099	.051
Coronoid unit length, mm	37.72	8.03	38.99	4.29	39.04	5.51	NS	.838	.826	1.000
Angular unit length, mm	22.81	9.58	22.68	10.5	20.32	10.24	NS	.999	.780	.799
Chin unit length, mm	27.49	4.87	28.90	2.24	30.45	3.06	NS	.531	.071	.464
Condylar width, mm	17.28	2.02	18.67	2.69	17.26	1.69	NS	.201	1.000	.205
Ramal height, mm	58.77	5.16	56.97	5.01	54.94	4.24	NS	.569	.088	.488
Body length, mm	77.67	9.34	81.55	6.20	79.74	4.91	NS	.300	0.703	.765
Hemimandibular volume, cm <sup>3</sup>	28.16	4.46	25.30	3.09	23.11	2.90	**	.087	.001	.211
Hemimandibular surface, cm <sup>2</sup>	13.78	3.12	12.34	2.06	12.02	1.51	NS	.221	.110	.926
Ramal volume, cm <sup>3</sup>	8.040	1.72	8.260	3.35	7.720	1.55	NS	.965	.928	.807
Ramal surface, cm <sup>2</sup>	5.010	1.93	4.810	1.21	4.770	0.79	NS	.924	.889	.996
Body volume, cm <sup>3</sup>	20.73	3.52	17.08	2.95	15.63	2.03	***	.004	.000	.365
Body surface, cm <sup>2</sup>	8.770	1.40	7.510	1.55	7.240	0.88	**	.032	.008	.840

<sup>a</sup> SD indicates standard deviation; ANOVA, analysis of variance.  
 \*  $P < .05$ ; \*\*  $P < .01$ ; \*\*\*  $P < .001$ . NS indicates not statistically significant.

**Table 6.** Descriptive Statistics and Statistical Comparisons of Measurements Between Groups for the Right and Crossbite Sides<sup>a</sup>

Measurements	Control Group (CG)		Unilateral Crossbite Group (UCG)		Bilateral Crossbite Group (BCG)		ANOVA	Multiple Comparison Tukey HSD Test (P Value)		
	Mean	SD	Mean	SD	Mean	SD		CG-UCG	CG-BCG	UCG-BCG
Condylar unit length, mm	43.53	6.68	42.96	4.57	42.59	4.44	NS	.954	.881	.981
Body unit length, mm	55.76	4.47	56.78	4.40	53.76	3.98	NS	.791	.415	.142
Coronoid unit length, mm	38.80	5.06	39.54	4.67	39.11	4.78	NS	.910	.983	.969
Angular unit length, mm	20.79	2.90	19.68	3.79	17.50	2.94	*	.619	.021	.166
Chin unit length, mm	26.64	2.92	28.89	2.14	29.16	1.62	**	.028	.012	.942
Condylar width, mm	17.24	1.83	19.05	2.22	16.85	1.62	**	.034	.841	.008
Ramal height, mm	61.11	5.09	57.30	5.61	54.86	4.57	**	.116	.005	.399
Body length, mm	72.12	11.83	81.46	4.95	79.39	3.95	**	.006	.036	.747
Hemimandibular volume, cm <sup>3</sup>	28.42	4.72	25.38	3.41	22.57	3.00	***	.083	.000	.117
Hemimandibular surface, cm <sup>2</sup>	13.23	1.72	12.12	1.82	12.06	1.36	NS	.170	.140	.994
Ramal volume, cm <sup>3</sup>	7.95	1.60	8.47	2.90	7.13	1.77	NS	.792	.560	.222
Ramal surface, cm <sup>2</sup>	4.90	1.09	4.70	1.00	4.66	0.75	NS	.831	.760	.991
Body volume, cm <sup>3</sup>	20.39	3.37	17.99	2.29	15.78	2.17	***	.047	.000	.071
Body surface, cm <sup>2</sup>	8.55	1.59	7.64	1.45	7.38	0.78	NS	.156	.052	.859

<sup>a</sup> SD indicates standard deviation; ANOVA, analysis of variance.  
 \*  $P < .05$ ; \*\*  $P < .01$ ; \*\*\*  $P < .001$ . NS indicates not statistically significant.

( $P = .008$ ). Also, ramal height was longer in the CG than in the BCG ( $P = .005$ ). The body length was found longer in the UCG than in the CG ( $P = .006$ ) and BCG ( $P = .036$ ). Hemimandibular volume was significantly greater in the CG than in the BCG ( $P < .001$ ), and body volume was greater in the CG than in the UCG ( $P = .047$ ) and BCG ( $P < .001$ ). According to present findings, the second null hypothesis was rejected.

## DISCUSSION

Several authors have attempted to find a relationship between mandibular asymmetry and malocclusion in general<sup>15</sup> and between mandibular asymmetry and crossbite.<sup>16</sup> However, most of these studies mainly focused on 2D radiographic evidence.<sup>17</sup> These 2D radiographs can be misleading since complex 3D structures are projected onto flat 2D surfaces, creating distortion and magnification errors.<sup>10</sup> Therefore, the aim of the present study was to assess the mandibular asymmetry in crossbite patients by using CBCT-derived 3D images.

CBCT allows 3D reconstructions of craniofacial structures from acquired volumetric data.<sup>18</sup> For accurate 3D representations of the craniofacial complex, reconstructed 3D images were used in this study. All DICOM data were reconstructed by Mimics 10.0 (Materialise NV). In this software, the threshold value can be set from the scan using the manual-segmentation function of the software. By this way, the required structure can be separated from its surrounding structures, and this allows us to visualize an area that was superimposed by other structures and to evaluate its actual dimensions. Also, volumetric and surface measurements of an object can be performed by using the same software.

The method of this study involved the landmarks used in the study of You et al.<sup>14</sup> They examined the mandibular morphology according to condylar, coronoid, angular, body, and chin units and used the mandibular and mental foramen as the reference points located at the junction of these skeletal units. Fossa of the foramen (point F) was used as the reference point for the exact location of the mandibular foramen in 3D,<sup>19</sup> and because the primary intramembranous ossification begins in mental foramen, it has been used for the division of the mandibular corpus into body and chin units. Therefore, in the current study, the skeletal unit lengths were measured on the guide of point F and the mental foramen similar to the study of You et al.<sup>14</sup>

Liukkonen et al.<sup>11</sup> investigated mandibular asymmetry using orthopantomograms taken from the same healthy children at ages 7 and 16 years and found a

statistically significant difference between the right and left sides in condylar height at age 7 years, in ramus height at both ages, and in the condylar and ramus height at age 16 years. Melnik<sup>20</sup> reported that the left side of the mandible is longer at age 6 years, while the right side of the mandible becomes longer by the age of 12 years in girls and by the age of 16 years in boys. It also was concluded that there is almost an equal probability for improvement or worsening of a child's mandibular asymmetry between the ages of 6 and 16 years. The fluctuation in the course of the growth period may indicate that functional forces to the joints and mandibular gonial regions are not necessarily in balance, which may lead to unequal growth of the condyle and ramus heights on the right and left sides.<sup>11</sup> In the current study, patients between the ages of 11 and 16 years were included, and side specific differences were found in the CG and in the BCG. In literature there is no longitudinal published study that evaluated the longitudinal skeletal changes of untreated crossbite patients during the growth period. We think that if crossbite remains untreated during the period of growth and development, a child's mandibular asymmetry may easily worsen?

Comparison of the measurements between the right and left sides in the CG revealed statistically significant differences in ramal height and body length. It was reported that a so-called symmetrical face consisted of minor asymmetrical components.<sup>17</sup> This has been demonstrated in different studies mostly based on anthropometric<sup>21</sup> and radiographic<sup>22</sup> assessments. Uysal et al.<sup>5</sup> found similar condylar, ramal, and condylar-plus-ramal height measurements in posterior crossbite and normo-occlusion patients, but also reported condylar asymmetry in the side-comparison of the normal occlusion subjects according to the asymmetry index formula.<sup>22</sup> Also, in another study, facial asymmetry is reported to be a naturally occurring phenomenon, and there is no truly symmetrical face regardless of the age of the individual.<sup>11</sup> In the current study, patients with clinically determined good facial symmetry were included as a control group. Therefore, we attribute the differences in some parameters to the asymmetry in nature.

In the side comparison of the groups, no statistically significant differences were found in the UCG. Letzer and Kronman<sup>15</sup> found no relation between posterior crossbite and asymmetry by using posteroanterior radiographs. On the other hand, some authors reported vertical mandibular asymmetry in unilateral posterior crossbite patients by using 2D radiographs.<sup>16,23</sup> Pinto et al.<sup>16</sup> found radiographically that the mandible, especially the ramus, was significantly longer on the noncrossbite side than on the crossbite side. However, current findings are not compatible with these studies.

In the BCG, both hemimandibular and ramal volume measurements were greater on the left side than on the right side. The results revealed that bilateral crossbite patients had asymmetrical mandibles in general. Although there are a lot of studies concerning mandibular morphological and functional asymmetries in crossbite patients,<sup>5,16,23</sup> no published study including the volumetric assessment of the mandible and its components in bilateral crossbite patients was found in the literature. Thus, we could not compare the present findings with those of any other study. However, we think that the side differences in the BCG resulted from the effort of patients to fulfill the chewing function.

According to the intergroup comparison, the angular unit length on the right side was found longer in the CG than in the BCG. This difference might result from the decrease in bite force in the BCG group. The angular unit is affected by the masseter and medial pterygoid muscles,<sup>24</sup> and bite force was reported to have an influence on muscle efficiency.<sup>25</sup> However, it is difficult to explain the precise etiology of this elongation because bite force was not assessed in the current study.

The condylar width on the right side was wider in the UCG than in the CG and BCG. A consequence of an untreated UCG was reported to be the displacement of the ipsilateral condyle toward the crossbite side and an increased growth of the contralateral condyle.<sup>26</sup> Inui et al.<sup>27</sup> reported that continuous condylar displacement resulting from occlusal problems in the glenoid fossa during the growth period caused differential growth of the left and right condyles. Therefore, one possible explanation of this finding may be the lateral displacement of the condyle to the crossbite side and the resultant appositional changes.

The weaknesses of this study are the small sample size and deficiency in the assessment of muscles and bite force. To overcome the limitation of the small sample size, patient age and gender were homogenized, and the same author performed all measurements. In addition, the high accuracy of linear and volumetric measurements<sup>28</sup> on CBCT images contributed to the reliability of the outcomes and made the small sample size acceptable. However, future longitudinal studies with a large sample size and muscle and bite force assessment are needed for further evaluation.

## CONCLUSIONS

- The current study shows that the healthy young subjects in the CG have asymmetrical mandibles.
- Contrary to the UCG, the BCG was found to have side-specific differences.
- Skeletal components of mandibles have significant asymmetry between the crossbite groups and control group.

- The posterior crossbite may be a predisposing factor for mandibular asymmetry.

## REFERENCES

1. Ninou S, Stephens C. The early treatment of posterior crossbites: a review of continuing controversies. *Dent Update*. 1994;10:420–426.
2. Proffit WR, Ackerman JL. *Contemporary Orthodontics*. 3rd ed. St Louis, Mo: Mosby; 2000:187–188, 435–439.
3. Kutin G, Hawes R. Posterior crossbites in the deciduous and mixed dentitions. *Am J Orthod*. 1969;56:491–504.
4. McNamara JA. Early intervention in the transverse dimension: is it worth the effort? *Am J Orthod Dentofacial Orthop*. 2002;121:572–574.
5. Uysal T, Sisman Y, Kurt G, Ramoglu SI. Condylar and ramal vertical asymmetry in unilateral and bilateral posterior crossbite patients and a normal occlusion sample. *Am J Orthod Dentofacial Orthop*. 2009;136:37–43.
6. Egermark-Eriksson I, Carlsson GE, Magnusson T, Thilander B. A longitudinal study on malocclusion in relation to signs and symptoms of cranio-mandibular disorders in children and adolescents. *Eur J Orthod*. 1990;12:399–407.
7. Kurol J, Berglund L. Longitudinal study and cost-benefit analysis of the effect of early treatment of posterior crossbites in the primary dentition. *Eur J Orthod*. 1992;14:173–179.
8. Ingervall B, Thilander B. Activity of temporal and masseter muscles in children with a lateral forced bite. *Angle Orthod*. 1975;45:249–258.
9. Pullinger A, Thurston M, Turley P. Condylar adaptation to unilateral posterior crossbite in adults. *J Dent Res*. 1985;64:269.
10. Van Eslande DC, Russett SJ, Major PW, Flores-Mi C. Mandibular asymmetry diagnosis with panoramic imaging. *Am J Orthod Dentofacial Orthop*. 2008;134:183–192.
11. Liukkonen M, Sillanmäki L, Peltomäki T. Mandibular asymmetry in healthy children. *Acta Odontol Scand*. 2005;63:168–172.
12. Schlueter BA. *Cone Beam Computed Tomography Three-dimensional Reconstruction for Evaluation of the Mandibular Condyle* [thesis]. St Louis, Mo: Saint Louis University; 2007.
13. Enlow D. Discussion. *Am J Orthod Dentofacial Orthop*. 2000;117:147.
14. You KH, Lee KJ, Lee SH, Baik HS. Three-dimensional computed tomography analysis of mandibular morphology in patients with facial asymmetry and mandibular prognathism. *Am J Orthod Dentofacial Orthop*. 2010;138:540.e1–540.e8.
15. Letzer GM, Kronman JH. A posteroanterior cephalometric evaluation of craniofacial asymmetry. *Angle Orthod*. 1967;37:205–211.
16. Pinto AS, Buschang PH, Throckmorton GS, Chen P. Morphological and positional asymmetries of young children with functional unilateral posterior crossbite. *Am J Orthod Dentofacial Orthop*. 2001;120:513–520.
17. Van Keulen C, Martens G, Dermaut L. Unilateral posterior crossbite and chin deviation: is there a correlation? *Eur J Orthod*. 2004;26:283–288.
18. Lagravère MO, Carey J, Toogood RW, Major PW. Three-dimensional accuracy of measurements made with software on cone-beam computed tomography images. *Am J Orthod Dentofacial Orthop*. 2008;134:112–116.
19. Sanders DA, Rigali PH, Neace WP, Uribe F, Nanda R. Skeletal and dental asymmetries in Class II subdivision



- malocclusions using cone-beam computed tomography. *Am J Orthod Dentofacial Orthop.* 2010;138:542.e1–542.e20.
20. Melnik AK. A cephalometric study of mandibular asymmetry in a longitudinally followed sample of growing children. *Am J Orthod Dentofacial Orthop.* 1992;101:355–366.
  21. Farkas LG, Cheung G. Facial asymmetry in healthy North American Caucasians. An anthropometrical study. *Angle Orthod.* 1981;51:70–77.
  22. Habets LL, Bezuur JN, Naeiji M, Hansson TL. The orthopantomogram, an aid in diagnosis of temporomandibular joint problems. II. The vertical symmetry. *J Oral Rehabil.* 1988;15:465–471.
  23. Lam PH, Sadowsky C, Omerza F. Mandibular asymmetry and condylar position in children with unilateral posterior crossbite. *Am J Orthod Dentofacial Orthop.* 1999;115:569–575.
  24. Ingervall B, Helkimo E. Masticatory muscle force and facial morphology in man. *Arch Oral Biol.* 1978;23:203–206.
  25. Johnson BE. A study of bite force, part 1: relationship to various physical characteristics. *Angle Orthod.* 1995;65:367–372.
  26. Solberg WK, Bibb CA, Nordstrom BB, Hansson TL. Malocclusion associated with temporomandibular joint changes in young adults at autopsy. *Am J Orthod.* 1986;89:326–330.
  27. Inui M, Fushima K, Sato S. Facial asymmetry in temporomandibular joint disorders. *J Oral Rehabil.* 1999;26:402–406.
  28. Lascalea CA, Panella J, Marques MM. Analysis of the accuracy of linear measurements obtained by cone beam computed tomography (CBCT-NewTom). *Dentomaxillofac Radiol.* 2004;33:291–294.