

Massive Pulmonary Embolism During Pregnancy Successfully Treated With Recombinant Tissue Plasminogen Activator

A Case Report and Review of Treatment Options

Gregory S. Ahearn, MD; Denis Hadjiliadis, MD; Joseph A. Govert, MD; Victor F. Tapson, MD

Thromboembolic disease is an important cause of morbidity and mortality during pregnancy.¹ Berg and colleagues² found that 11% of maternal deaths during pregnancy were related to pulmonary embolism (PE). Another study revealed that up to 40% of pregnant women with asymptomatic deep vein thrombosis (DVT) may also have concurrent PE.³ Women are at increased risk for DVT and PE during pregnancy for several reasons. Pregnancy is a thrombophilic state; fibrinogen levels are increased, and during the final trimester there is a decrease in fibrinolytic activity. In addition, the gravid uterus causes compression and stasis in the lower extremities and pelvic veins favoring thrombosis.³ Finally, women with a history of thrombotic complications during pregnancy have an increased prevalence of genetic mutations related to coagulation.⁴

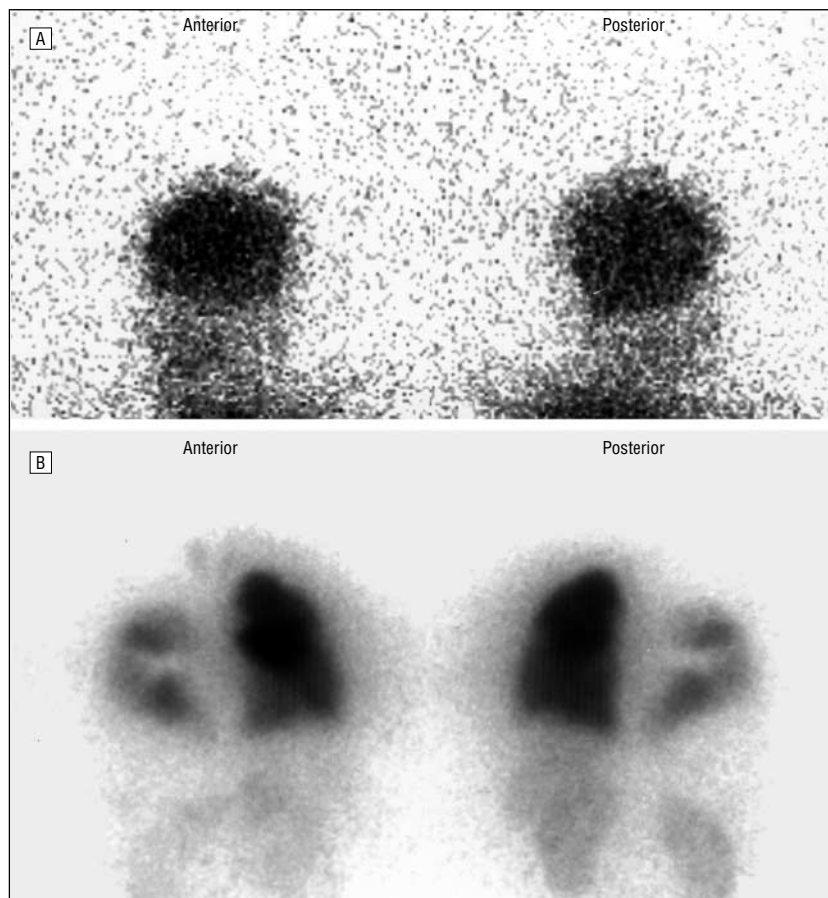
Traditionally, thromboembolic disease during pregnancy has been treated with unfractionated⁵ and, more recently, low-molecular-weight heparin.^{1,6} A strong negative charge keeps heparins from crossing the placenta and affecting the fetus. The treatment options available for patients with massive, life-threatening PE in whom conservative heparin therapy has failed include embolectomy, thrombolytic therapy, and localized catheter-directed thrombolytic therapy. Inferior vena cava (IVC) filters are often part of the management of severe PE and have been used safely during pregnancy, although their long-term safety remains uncertain. Thrombolytic agents are relatively contraindicated during pregnancy because of the presumed risk of maternal bleeding and fetal loss. The teratogenicity for these agents in humans is also uncertain. There is some concern that increased levels of plasmin may precipitate premature labor, although this has never been convincingly demonstrated in clinical practice.⁷ The risk of bleeding post partum may be further increased after thrombolytic therapy because of uterine atony induced by elevated levels of fibrin

split products, which are present after thrombolytic therapy.⁷ The decision to embark on high-risk therapy for PE is difficult because of early observations that patients who do not die immediately usually do well once adequate anticoagulant therapy has been started.⁸ Treatment decisions are further complicated by pregnancy, in which the outcome of the fetus is also at stake. This article will discuss each of these treatment modalities and relate them to the pregnant patient.

REPORT OF A CASE

A 12-week pregnant, 36-year-old African American woman with acute dyspnea and substernal chest pain was brought to the emergency department by ambulance. She was having dyspnea on exertion and trouble climbing stairs for the past week. She had been seen the day prior for pain in her left leg, which was treated with acetaminophen. She was diaphoretic and lethargic with a systolic blood pressure of 82/50 mm Hg and a pulse rate of 135/min. Her neck veins were not visible, and her lung fields were clear. Findings from cardiac examination were remarkable for tachycardia with a 2/4 high-pitched systolic murmur heard along the upper left

From the Department of Medicine, Division of Pulmonary and Critical Care, Duke University Medical Center, Durham, NC.



High-probability perfusion scan showing bilateral defects as well as evidence of right to left shunting. A, Intense tracer uptake in the head consistent with a right to left shunt. B, Bilateral perfusion defects as well as uptake in the kidneys, which is indicative of right to left shunting. The uptake in the kidneys is more pronounced in the posterior view.

sternal border. An intermittent third heart sound along the left sternal border was also present. Abdominal examination findings were benign, with the uterine fundus barely palpable. There was no peripheral edema. Pelvic and neurologic examination results were normal. Initial pulse oximetry on room air was 80%, which increased to 95% on 100% oxygen by face mask. Her electrocardiogram revealed sinus tachycardia at a rate of 120 beats per minute with a Q wave and inverted T wave in lead III. Because of the high suspicion for PE, therapeutic intravenous heparin was begun immediately. The ventilation-perfusion scan was consistent with massive PE, with almost no perfusion to the left lung and multiple filling defects in the right lung. Radioactive tracer was also noted in the brain and kidney, suggestive of a right to left shunt (**Figure**). Echocardiography with a bubble study confirmed the presence of a right to left shunt through

a patent foramen ovale as well as a dilated, hypokinetic right ventricle. Her left ventricular function was normal. A Doppler ultrasound study of her lower extremities revealed acute DVT in the left leg, extending from the popliteal vein proximally through the common femoral vein.

The patient was brought to the medical intensive care unit. Despite aggressive fluid resuscitation, she remained hemodynamically tenuous with systolic blood pressures ranging from 80 to 89 mm Hg. Because of the perceived high risk of a fatal PE and the possibility of paradoxical emboli through her patent foramen, she was given 100 mg of recombinant tissue plasminogen activator (rtPA) over 2 hours. The patient had an excellent response to thrombolytic therapy. After several hours, supplemental oxygen was discontinued, the chest pain and tachycardia resolved, and her blood pressure stabilized. She had no clinically apparent bleeding compli-

cations, no evidence of fetal compromise, and was discharged home in good condition on hospital day 4 with a prescription for subcutaneous enoxaparin sodium, 1 mg/kg every 12 hours. She subsequently delivered a normal-term infant without complication.

EMBOLECTOMY

Early experience with embolectomy was associated with exceedingly high mortality and neurologic complications.⁹ Technological advances such as extracorporeal bypass significantly reduced the morbidity and mortality from the procedure.⁸ Since the development of extracorporeal bypass, several series have been reported, with mortality rates ranging from 0% to 86%.¹⁰⁻²¹ The variability in these series stems from variable patient populations and selection criteria for surgery.

Recommendations and criteria for patients suitable for embolectomy have been controversial, with some authors advocating a conservative approach of maximizing medical therapy^{8,22,23} and other authors proposing early and aggressive surgical management¹² of patients with PE. In a more contemporary review, the role of embolectomy⁹ was downplayed in favor of making every effort to maximize medical therapy. With several randomized trials demonstrating the efficacy of thrombolytic therapy in the reduction of acute clot burden and restoration of hemodynamics,²⁴⁻²⁹ the role of embolectomy has been relegated to those in whom heparin therapy has failed and have strong contraindications to the use of thrombolytic therapy.

In pregnancy, however, the role of embolectomy is more problematic because pregnancy is a relative contraindication to the use of thrombolytics because of the risk of hemorrhage and fetal loss. An emergent surgical procedure is clearly associated with risk of maternal and fetal morbidity and mortality as well as the risk of fetal loss.³⁰

Pregnant patients with massive embolism may make more reasonable surgical candidates because they are generally younger than the general medicine popula-

tion and have limited comorbid illness. While there have been no large case series reporting outcomes of embolectomy during pregnancy, Becker³⁰ reported the results of 68 pregnant women undergoing cardiopulmonary bypass. There was an approximately 20% incidence of fetal loss. Only 3 of these 68 cases were embolectomies with no maternal deaths and 1 fetal death.

Published experience with emergent embolectomy in pregnancy is limited to case reports.³¹⁻³³ In 1989, Blegvad et al³³ reported a case of successful embolectomy in a patient during the second trimester and reviewed the predominantly European literature up until that time. They found 10 reported cases with no maternal deaths but 4 fetal deaths. In summary, based on the available evidence, it seems the operative risk to the mother is reasonable; however, the fetal death rate is substantial, ranging from 20% to 40%.

THROMBOLYTIC THERAPY

Up until the early 1970s, surgical embolectomy was the only alternative to heparin therapy for patients with massive PE. In 1970, the Urokinase Pulmonary Embolism Trial (UPET) demonstrated that urokinase was more effective than heparin for thrombolysis over the first 24 hours of treatment for massive PE.³⁴ Because of concerns about bleeding and teratogenicity, pregnant patients were excluded from UPET and other clinical trials of thrombolytics in PE. Thus, the risks of thrombolytic therapy in pregnancy have not been adequately delineated by randomized trials and are unlikely to be in the future.

Currently used thrombolytic agents are streptokinase and rtPA. Both agents activate plasminogen to form the fibrinolytic enzyme plasmin. In addition to cleaving fibrin, plasmin cleaves fibrinogen, factor V, and factor VIII,³⁵ resulting in a systemic "lytic" state. One potential advantage of rtPA over the other 2 agents is that it has a high affinity for plasminogen only in the presence of fibrin.^{36,37} This specificity theoretically results in more localized thrombolysis at the site of thrombosis and less generalized coagulopathy. Ani-

mal models suggest that for a given level of fibrinolytic activity, rtPA results in less hypofibrinogenemia and fewer hemorrhagic complications than streptokinase.³⁸⁻⁴⁰ This localized activity may also account for the observation that the thrombolytic activity of rtPA persists after it has been cleared from the general circulation. However, a clinical advantage of rtPA has not been clearly demonstrated with regard to this fibrin specificity.

Recombinant tissue plasminogen activator is a large polypeptide (72 000 kd) that does not cross the placenta. It is not antigenic, thus patients may receive repeated doses.²² Streptokinase is also a large molecule derived from group C streptococci that does not cross the placenta in sufficient amounts to cause fibrinolysis in the fetus.^{41,42} It is, however, antigenic, and after the first dose, patients should not receive it again for 6 months after the last use. Urokinase is a small nonantigenic molecule purified from human urine that crosses the placenta. At present, limited evidence has not shown coagulopathy in the fetus, although it could be a concern. Tenecteplase has recently become available and appears to be as safe and effective as rtPA in myocardial infarction; however, it has not been studied in thromboembolic disease or in pregnancy.²⁰

Several randomized trials using thrombolytic agents in PE have established that thrombolytic therapy more effectively reduces clot burden and improves hemodynamics more rapidly compared with heparin therapy,^{24,26-28,34,43} but without evidence of long-term survival advantage. No agent has been proven to be clearly superior to the others.^{9,29,44-46} Current recommendations suggest reserving thrombolytic therapy for patients with severe PE with hemodynamic compromise.²³ Others have suggested that evidence of right ventricular dysfunction on echocardiogram should be an indication for thrombolytic therapy. This remains controversial.⁴⁷

The literature on the use of thrombolytic therapy during pregnancy is limited to case reports and case series.^{7,42,44,48-60} The **Table** summarizes reports in the English literature. In 172 women 14- to 40-weeks' pregnant who were treated with

thrombolytic therapy (164 were treated with streptokinase; 3, urokinase, and 5, rtPA), there have been 5 nonfatal maternal bleeding complications (2.9%) and 3 fetal deaths (1.7%). No maternal deaths from thrombolytic therapy have been reported. Most reported experience with streptokinase comes from 2 series reported by Ludwig and Genz⁵⁰ and Ludwig.⁶¹ In 1973, Ludwig⁶¹ reported the results in 24 patients who had received streptokinase for DVT or PE. He reported a good clinical response with no maternal or fetal complications. In 1981, Ludwig and Genz⁵⁰ reported a series of 122 pregnant patients who had received streptokinase for acute DVT. There was a favorable clinical response in 90% of the patients treated; however, 2 women had significant bleeding requiring emergent cesarean section; there was 1 premature rupture of membranes with a good outcome and 1 fetal death.

There is substantially less reported experience with both urokinase and rtPA in pregnancy. It has been reported that 3 pregnant patients have received urokinase for DVT or PE with favorable clinical outcomes and no reported complications.^{51,58} Similarly, there are 6 published reports of pregnant women who have received rtPA for thrombosed prosthetic valves, myocardial infarction, and PE.^{52-54,57,59,60} In these reports there were no adverse maternal outcomes and 1 fetal death that was related to the rethrombosis of a prosthetic valve 2 weeks after treatment with rtPA.

In 1997, Turrentine et al⁶² published a review of thrombolytic therapy in 172 pregnant patients, which included substantial experience from European literature. They reported an overall rate of maternal hemorrhagic complications of 8.1%. Most of these complications occurred with streptokinase, though there were very few patients treated with either urokinase or rtPA. There were 2 maternal deaths (1.2%). However, after careful review of the cases, they were not direct complications of thrombolytic therapy. One developed pyelonephritis and sepsis, and the other had a cardiac arrest attributed to a thrombosed mitral valve. Turrentine et al⁶² reported

Thrombolytic Therapy in Pregnancy*

Study, Year	Drug	Weeks of Gestation	Indication (No. of Patients)	Outcome of Mother	Outcome of Fetus
Pfiefer, ⁴² 1970	SK	NA	DVT (12)	NA	NA
Hall et al, ⁷ 1972	SK	32	PE (1)	11-U blood loss	No complications
Ludwig, ⁶¹ 1973	SK	14-40	DVT (21)/PE (3)	No complications	No complications
McTaggart and Ingram, ⁴⁸ 1977	SK	34	PE (1)	Alive	Death in utero
Witchitz et al, ⁴⁹ 1980	SK	32	Valve (1)	No complications	No complications
Ludwig and Genz, ⁵⁰ 1981	SK	14-38	DVT (122)	2 Severe bleeding	1 Death (separation)
Delclos and Davila, ⁵¹ 1986	UK	28	PE (1)	No complications	No complications
Fagher et al, ⁵² 1990	SK	28	PE (1)	Postpartum hemorrhage	No complications
Baudo et al, ⁵³ 1990	rtPA	35	PE (1)	No complications	No complications
Flossdorf et al, ⁵⁴ 1990	rtPA	31	PE (1)	No complications	No complications
Mazeika and Oakley, ⁵⁵ 1994	SK	25	PE (1)	No complications	No complications
Ramamurthy et al, ⁵⁶ 1994	SK	28	Valve (1)	No complications	No complications
Azzano et al, ⁵⁷ 1995	rtPA	16	Valve (1)	Severe bleeding	Fetal loss after rethrombosis
La Valleur et al, ⁵⁸ 1996	UK	11-33	DVT (2)	No complications	No complications
Schumacher et al, ⁵⁹ 1996	rtPA	21	MI (1)	No complications	No complications
Fleyfe et al, ⁶⁰ 1997	rtPA	28	Valve (1)	No complications	No complications

*SK indicates streptokinase; NA, not available; DVT, deep vein thrombosis; PE, pulmonary embolism; Valve, prosthetic valve thrombosis; rtPA, recombinant tissue plasminogen activator; UK, urokinase; and MI, myocardial infarction.

a 5.8% rate of pregnancy loss and a 5.8% rate of preterm delivery.

Any conclusions about the efficacy and safety of thrombolytic therapy in pregnancy must be drawn with extreme caution. From the available evidence it seems that the maternal bleeding complication rate ranges from 1% to 6%, which is comparable to that of nonpregnant patients who receive thrombolytics. Reported rates of "major bleeding" following thrombolytic therapy in patients with myocardial infarction and DVT and PE have ranged from 1% to 29%, 4% to 25%, and 6% to 45%, respectively.⁶³ Most of these bleeding events occurred around catheter and puncture sites. Importantly, among case reports in pregnant women, there were no intracranial bleeds, and the 2 deaths reported were not secondary to hemorrhage.

CATHETER-DIRECTED THROMBOLYTIC THERAPY

Potential advantages of catheter-directed thrombolytic therapy are more rapid clot lysis because of a higher local concentration drug and less systemic fibrinolysis, thus a lower risk of bleeding complications. Disadvantages are the need for pulmonary artery catheterization with the potential risks of arrhythmia and myocardial rupture.⁶⁴ Another concern unique to pregnancy is the radiation exposure associated with fluoroscopy.

Several reports have demonstrated the feasibility of locally delivered low-dose thrombolytic therapy;^{25,64-66} however, there is no convincing evidence that catheter-directed thrombolytic therapy is superior to treatment with systemic thrombolytics or standard heparin. To our knowledge, there is a single report of catheter-directed thrombolytic therapy for the treatment of thromboembolic disease during pregnancy. Krishnamurthy et al⁶⁷ reported a series of 3 patients, 1 with hemodynamically significant PE and 2 with iliofemoral DVT that had not responded to standard heparin therapy. All patients received 2200 U/kg per hour of urokinase directed at the thrombus with concurrent intravenous heparin. All 3 patients had marked clinical improvement, and their pregnancies proceeded normally.

In summary, local therapy is feasible but requires specialized facilities and expertise. There is no evidence that it is superior to systemic therapy. Further studies examining different dosing strategies are required to determine its role in the management of massive PE. More experience is needed before catheter-directed therapy can be recommended for pregnant patients.

VENA CAVA FILTERS

In the 1960s percutaneous filter devices supplanted surgical interrup-

tion of the vena cava as a mode of PE prevention in high-risk patients. This important advance removed the risk of general anesthesia and an operative procedure in patients who are critically ill. Traditional indications for the placement of a vena cava filter are (1) recurrent embolism on adequate medical therapy, (2) strong contraindications to full anticoagulation after a thromboembolism, and (3) critically ill patients at high risk for recurrent embolism in whom it is believed that a recurrent embolism would likely be fatal. Some authors have advocated prophylactic placement of vena cava filters in trauma patients believed to be at very high risk for thromboembolism; however, this recommendation has not become general practice.^{68,69}

Early experience found that these devices were effective in preventing recurrent thromboembolism, but there were several complications. Up to 85% of patients developed caval thrombosis,⁷⁰ with many of these patients developing chronic venous stasis. In addition, several deaths were attributed to filter migration. Refinements in design culminated in the Greenfield filter, which is currently the most widely used device. Its more conical design allows clot to be funneled to the apex of the device, allowing free blood flow through the cava. Experimental and clinical evidence suggest that free-flowing

blood around trapped clot allows for clot lysis and perpetual cleaning of the filter.⁷⁰ Multiple series have documented long-term patency rates in excess of 95% and a rate of recurrent PE of 2% to 4%.^{71,72}

With widespread use of Greenfield filters, case reports of late complications have emerged^{21,73-89}:

- Duodenal perforation^{21,73,74}
- Caval rupture in aortic mural thrombus^{77,78}
- Penetration into vertebral bodies^{79,80}
- Strut failure resulting in penetration into the retroperitoneum⁸¹
- Distal migration resulting in poor alignment and pulmonary emboli⁷⁶
- Acute myocardial infarction from migration to the right atrium⁸²
- Migration into pulmonary artery⁸³
- Aortic perforation^{77,85}
- Tricuspid insufficiency from intracardiac migration⁸⁷
- Renal pelvis perforation⁸⁸
- Penetration into an aortic aneurysm⁸⁹

In addition, severe complications during filter placement may occur, including intracardiac and intrapulmonary migration.^{90,91} The exact incidence of such complications is unknown, but they serve as a reminder of the potential long-term morbidity associated with filter placement.

The first report of the successful use of a vena cava filter during pregnancy was in 1981.⁹¹ Several case reports and series have reported favorable results using IVC filters.⁹²⁻⁹⁴ In 1986, Hux et al⁹⁴ described 6 pregnant patients with thromboembolic disease who had good maternal and fetal outcomes after Greenfield filter placement.⁹⁴ Thomas et al⁹⁵ described 8 pregnant patients at risk for PE prophylactically treated with Greenfield filters with similarly good outcomes.⁹⁵ Most recently, Aburahma and Boland⁹⁶ published a series of 11 pregnant patients who had filters placed for the management of DVT. There were no serious maternal or fetal complications; however, at a mean follow-up of 61 months, 27% of patients who had filters placed still had significant lower extremity edema.

The indications for IVC filter placement during pregnancy are the same as for the nonpregnant patient. The incidence of late complications of IVC filter placement during pregnancy is unknown because there are limited long-term follow-up data addressing this point. To our knowledge, there is only 1 report of a woman who, 7 years after the placement of a Greenfield filter, developed thrombosis involving her IVC, bilateral common iliac veins, and right renal vein after delivery of a healthy child.⁹⁷ When considering IVC filter placement in a young and otherwise healthy patient, the physician must be mindful of the many potential complications that may occur over the patient's lifetime. Additionally, compression from the gravid uterus during the current and future pregnancies may increase the risk for complications. One potential option is to place the filter above the renal veins, which prevents contact with gravid uterus. The concern with this approach is the possibility of clot forming on the filter and propagating proximally with subsequent compromise of the renal veins. One series reports favorable results in 11 patients with this approach;⁹⁸ however, the risk of renal compromise remains a concern.

Because of long-term safety concerns, an attractive alternative to permanent IVC filters is to place a retrievable filter. Such a device would protect the patient from thromboembolism during the high-risk period around the acute event. Over time, clot lysis as well as organization occur, and the risk of embolism is substantially reduced. At this time the device could be removed. Two case reports have emerged from European literature in which pregnant women with PE and DVT have had such filters placed to prevent thromboembolism during delivery or cesarean section.^{99,100} One limitation is that the device must be removed within 10 days, which limits its usefulness in situations that need long-term protection from PE.

Another potential disadvantage of IVC filters is their inability to block small communicating veins between the upper and lower parts of the body. Small emboli can still occur. These emboli can have devas-

tating consequences in patients with a patent foramen ovale. After an initial pulmonary embolus, the closed patent foramen ovale frequently opens because of the pulmonary hypertension that follows the embolus. This in turn causes blood to shunt from right to left in the heart. Subsequent emboli have a significant chance of traveling to the brain or coronary arteries via the systemic circulation, causing devastating strokes or myocardial infarction.

CONCLUSIONS

Pulmonary embolism in pregnancy remains a rare but significant cause of morbidity and mortality among pregnant women. Most patients with DVT and/or PE can be safely and successfully treated with unfractionated or low-molecular-weight heparin for the duration of the pregnancy. Unfortunately, there are no conclusive data on the appropriate treatment of massive PE. Our current review summarizes the data supporting each of the different treatment modalities. Embolectomy appears to be safe for the mother, but is associated with a high rate of fetal loss (about 20%). Pregnancy is a relative contraindication to thrombolytic therapy, but a careful review of the literature reveals that approximately 200 patients were successfully treated, with a very low maternal mortality (approximately 1%) and a low rate of fetal loss (6%) or premature delivery (6%). Thrombolytic therapy appears to be the more easily and safely administered treatment when medical therapy fails or when there is a patent foramen ovale with a right to left shunt. The use of IVC filters appears to be the safest short-term method of treating massive PE during pregnancy, but it can have significant future complications.

Accepted for publication October 15, 2001.

Corresponding author and reprints: Victor F. Tapson, MD, Department of Medicine, Division of Pulmonary and Critical Care Medicine, Duke University Medical Center, Box 31175, Durham, NC 27710 (e-mail: taps001@mc.duke.edu).

REFERENCES

- Ginsberg JS, Greer I, Hirsh J. Use of antithrombotic agents during pregnancy. *Chest*. 2001; 119(1 suppl):122S-131S.
- Berg CJ, Atrash HK, Koonin LM, Tucker M. Pregnancy-related mortality in the United States, 1987-1990. *Obstet Gynecol*. 1996;88:161-167.
- Moser KM, Fedullo PF, LitteJohn JK, Crawford R. Frequent asymptomatic pulmonary embolism in patients with deep venous thrombosis. *JAMA*. 1994;271:223-225.
- Dilley A, Austin H, El Jamil M, et al. Genetic factors associated with thrombosis in pregnancy in a United States population. *Am J Obstet Gynecol*. 2000;183:1271-1277.
- Ramin SM, Ramin KD, Gilstrap LC. Anticoagulants and thrombolytics during pregnancy. *Semin Perinatol*. 1997;21:149-153.
- Sanson BJ, Lensing AW, Prins MH, et al. Safety of low-molecular-weight heparin in pregnancy: a systematic review. *Thromb Haemost*. 1999; 81:668-672.
- Hall RJ, Young C, Sutton GC, Cambell S. Treatment of acute massive pulmonary embolism by streptokinase during labour and delivery. *BMJ*. 1972;4:647-649.
- Barrett DW, Jordan SC. Anticoagulant drugs in the treatment of pulmonary embolism: a controlled trial. *Lancet*. 1960;1:1309-1312.
- Sabiston DC Jr, Wolfe WG, Oldham HN Jr, et al. Surgical management of chronic pulmonary embolism. *Ann Surg*. 1977;185:699-712.
- Bauer EP, Laske A, von Segesser LK, Carrel T, Turina MI. Early and late results after surgery for massive pulmonary embolism. *Thorac Cardiovasc Surg*. 1991;39:353-356.
- Beall AC Jr, Cooley DA. Current status of embolectomy for acute massive pulmonary embolism. *Am J Cardiol*. 1965;16:828-833.
- Berger RL. Pulmonary embolectomy with preoperative circulatory support. *Ann Thorac Surg*. 1973;16:217-227.
- Clarke DB, Abrams LD. Pulmonary embolectomy: a 25 year experience. *J Thorac Cardiovasc Surg*. 1986;92:442-445.
- Cross FS, Mowlem A. A survey of the current status of pulmonary embolectomy for massive pulmonary embolism. *Circulation*. 1967;35(4 suppl): 186-191.
- Doerge HC, Schoendube FA, Loeser H, Walter M, Messmer BJ. Pulmonary embolectomy: review of a 15-year experience and role in the age of thrombolytic therapy. *Eur J Cardiothorac Surg*. 1996;10:952-957.
- Gentsch TO, Larsen PB, Daughtry DC, Chesney JG, Spear HC. Community-wide availability of pulmonary embolectomy with cardiopulmonary bypass. *Ann Thorac Surg*. 1969;7:97-103.
- Gray HH, Miller GA, Paneth M. Pulmonary embolectomy: its place in the management of pulmonary embolism. *Lancet*. 1988;1:1441-1445.
- Lund O, Nielsen TT, Schifter S, Roenne K. Treatment of pulmonary embolism with full-dose heparin, streptokinase or embolectomy—results and indications. *Thorac Cardiovasc Surg*. 1986;34: 240-246.
- Lund O, Nielsen TT, Ronne K, Schifter S. Pulmonary embolism: long-term follow-up after treatment with full-dose heparin, streptokinase or embolectomy. *Acta Med Scand*. 1987;221: 61-71.
- Scannell JG. The surgical management of acute massive pulmonary embolism. *Prog Cardiovasc Dis*. 1967;9:488-494.
- Tritsch L, Coumaros D, Sauder P, Kopferschmitt J, Jaeger A, Mantz JM. Duodenal perforations by the hooks of a Kimray-Greenfield filter. *Ann Fr Anesth Reanim*. 1993;12:75-78.
- Crane C, Hartsuck J, Birtch A, et al. The management of major pulmonary embolism. *Surg Gynecol Obstet*. 1969;128:27-36.
- Tapson VF, Carroll BA, Davidson BL, et al, for the American Thoracic Society. The diagnostic approach to acute venous thromboembolism: clinical practice guideline. *Am J Respir Crit Care Med*. 1999;160:1043-1066.
- Tibbutt DA, Davies JA, Anderson JA, et al. Comparison by controlled clinical trial of streptokinase and heparin in treatment of life-threatening pulmonary embolism. *BMJ*. 1974; 1:343-347.
- Petitpretz P, Simmoneau G, Cerrina J, et al. Effects of a single bolus of urokinase in patients with life-threatening pulmonary emboli: a descriptive trial. *Circulation*. 1984;70:861-866.
- Ly B, Arnesen H, Eie H, Hol R. A controlled clinical trial of streptokinase and heparin in the treatment of major pulmonary embolism. *Acta Med Scand*. 1978;203:465-470.
- Jerjes-Sanchez C, Ramirez-Rivera A, de Lourdes GM. Streptokinase and heparin versus heparin alone in massive pulmonary embolism: a randomized controlled trial. *J Thromb Thrombolysis*. 1995;2:227-229.
- Goldhaber SZ, Haire WD, Feldstein ML, et al. Alteplase versus heparin in acute pulmonary embolism: randomised trial assessing right-ventricular function and pulmonary perfusion. *Lancet*. 1993;341:507-511.
- Urokinase-Streptokinase Embolism Trial: phase 2 results: a cooperative study. *JAMA*. 1974;229: 1606-1613.
- Becker RM. Intracardiac surgery in pregnant women. *Ann Thorac Surg*. 1983;36:453-458.
- Marcinkevicius A, Sirvydis V, Triponis V, Baublys A, Martinkenas G, Matulionis A. Pulmonary embolism during pregnancy. *J Cardiovasc Surg (Torino)*. 1970;11:355-358.
- Cohn LH, Shumway NE. Pulmonary embolectomy during pregnancy. *Arch Surg*. 1973;106: 214-215.
- Blegvad S, Lund O, Nielsen TT, Guldholt I. Emergency embolectomy in a patient with massive pulmonary embolism during second trimester pregnancy. *Acta Obstet Gynecol Scand*. 1989;68: 267-270.
- Urokinase Pulmonary Embolism Trial Study Group. Urokinase Pulmonary Embolism Trial: phase 1 results—a cooperative study. *JAMA*. 1970;214:2163-2172.
- Collen D. Tissue-type plasminogen activator: therapeutic potential in thrombotic disease states. *Drugs*. 1986;31:1-5.
- Hoylaerts M, Rijken DC, Lijnen HR, Collen D. Kinetics of the activation of plasminogen by human tissue plasminogen activator: role of fibrin. *J Biol Chem*. 1982;257:2912-2919.
- Loscalzo J, Braunwald E. Tissue plasminogen activator. *N Engl J Med*. 1988;319:925-931.
- Agnelli G, Buchanan MR, Fernandez F, Van Ryn J, Hirsh J. Sustained thrombolysis with DNA-recombinant tissue type plasminogen activator in rabbits. *Blood*. 1985;66:399-401.
- Agnelli G, Buchanan MR, Fernandez F, Hirsh J. The thrombolytic and hemorrhagic effects of tissue type plasminogen activator: influence of dosage regimens in rabbits. *Thromb Res*. 1985;40: 769-777.
- Agnelli G, Buchanan MR, Fernandez F, et al. A comparison of the thrombolytic and hemorrhagic effects of tissue-type plasminogen activator and streptokinase in rabbits. *Circulation*. 1985;72:178-182.
- Pfeifer GW. Distribution and placental transfer of 131-I streptokinase. *Australas Ann Med*. 1970; 19(suppl 1):17-18.
- Pfeifer GW. The use of thrombolytic therapy in obstetrics and gynaecology. *Australas Ann Med*. 1970;19(suppl 1):28-31.
- Research Group on Urokinase and Pulmonary Embolism. Multicenter study of 2 urokinase protocols in severe pulmonary embolism. *Arch Mal Coeur Vaiss*. 1984;77:773-781.
- Meyer G, Sors H, Charbonnier B, et al, for the European Cooperative Study Group for Pulmonary Embolism. Effects of intravenous urokinase versus alteplase on total pulmonary resistance in acute massive pulmonary embolism: a European multicenter double-blind trial. *J Am Coll Cardiol*. 1992;19:239-245.
- Meneveau N, Schiele F, Vuilleminot A, et al. Streptokinase vs alteplase in massive pulmonary embolism: a randomized trial assessing right heart haemodynamics and pulmonary vascular obstruction. *Eur Heart J*. 1997;18:1141-1148.
- Levine M, Hirsh J, Weitz J, et al. A randomized trial of a single bolus dosage regimen of recombinant tissue plasminogen activator in patients with acute pulmonary embolism. *Chest*. 1990; 98:1473-1479.
- Konstantinides S, Geibel A, Olschewski M, et al. Association between thrombolytic treatment and the prognosis of hemodynamically stable patients with major pulmonary embolism: results of a multicenter registry. *Circulation*. 1997;96:882-888.
- McTaggart DR, Ingram TG. Massive pulmonary embolism during pregnancy treated with streptokinase. *Med J Aust*. 1977;1:18-20.
- Witchitz S, Veyrat C, Moisson P, Scheinman N, Rozenstajn L. Fibrinolytic treatment of thrombus on prosthetic heart valves. *Br Heart J*. 1980; 44:545-554.
- Ludwig H, Genz H. Thrombolytic treatment during pregnancy. *Thromb Haemost*. 1981;46:438-445.
- Delclos GL, Davila F. Thrombolytic therapy for pulmonary embolism in pregnancy: a case report. *Am J Obstet Gynecol*. 1986;155:375-376.
- Baudo F, Ahlgren M, Astedt B. Acute massive pulmonary embolism treated with streptokinase during labor and the early puerperium. *Acta Obstet Gynecol Scand*. 1990;69:659-661.
- Baudo F, Caimi TM, Redaelli R, et al. Emergency treatment with recombinant tissue plasminogen activator of pulmonary embolism in a pregnant woman with antithrombin III deficiency. *Am J Obstet Gynecol*. 1990;163:1274-1275.
- Flossdorf T, Breulmann M, Hopf HB. Successful treatment of massive pulmonary embolism with recombinant tissue type plasminogen activator (rt-PA) in a pregnant woman with intact gravidity and preterm labour. *Intensive Care Med*. 1990;16:454-456.
- Mazeika PK, Oakley CM. Massive pulmonary embolism in pregnancy treated with streptokinase and percutaneous catheter fragmentation. *Eur Heart J*. 1994;15:1281-1283.
- Ramamurthy S, Talwar KK, Saxena A, Juneja R, Takkar D. Prosthetic mitral valve thrombosis in pregnancy successfully treated with streptokinase. *Am Heart J*. 1994;127:446-448.
- Azzano O, French P, Robin J, et al. Thrombo-

- lytic therapy with rt-PA for thrombosis of tricuspid valve prosthesis during pregnancy. *Arch Mal Coeur Vaiss.* 1995;88:267-270.
58. La Valleur J, Molina E, Williams PP, Rolnick SJ. Use of urokinase in pregnancy: two success stories. *Postgrad Med.* 1996;99:269-273.
 59. Schumacher B, Belfort MA, Card RJ. Successful treatment of acute myocardial infarction during pregnancy with tissue plasminogen activator. *Am J Obstet Gynecol.* 1997;176:716-719.
 60. Fleyfel M, Bourzoufi K, Huin G, Subtil D, Puech F. Recombinant tissue type plasminogen activator treatment of thrombosed mitral valve prosthesis during pregnancy. *Can J Anaesth.* 1997;44:735-738.
 61. Ludwig H. Results of streptokinase therapy in deep vein thrombosis during pregnancy. *Postgrad Med.* 1973;49(suppl 5):67-68.
 62. Turrentine MA, Braems G, Ramirez MM. Use of thrombolytics for the treatment of thromboembolic disease during pregnancy. *Obstet Gynecol Surv.* 1995;50:534-541.
 63. Fennerty AG, Levine MN, Hirsh J. Hemorrhagic complications of thrombolytic therapy in the treatment of myocardial infarction and venous thromboembolism. *Chest.* 1989;95(2 suppl):88S-97S.
 64. Gallus AS, Hirsch J, Cade JF, Turpie AG, Walker IR, Gent M. Thrombolysis with a combination of small doses of streptokinase and full doses of heparin. *Semin Thromb Hemost.* 1975;2:14-32.
 65. Barberena J. Intraarterial infusion of urokinase in the treatment of acute pulmonary thromboembolism: preliminary observations. *AJR Am J Roentgenol.* 1983;140:883-886.
 66. Vujic I, Young JW, Gobien RP, Dawson WT, Liebscher L, Shelley BE Jr. Massive pulmonary embolism: treatment with full heparinization and topical low-dose streptokinase. *Radiology.* 1983;148:671-675.
 67. Krishnamurthy P, Martin CB, Kay HH, et al. Catheter-directed thrombolysis for thromboembolic disease during pregnancy: a viable option. *J Matern Fetal Med.* 1999;8:24-27.
 68. Khansarinia S, Dennis JW, Veldenz HC, Butcher JL, Hartland L. Prophylactic Greenfield filter placement in selected high-risk trauma patients. *J Vasc Surg.* 1995;22:231-235.
 69. Leach TA, Pastena JA, Swan KG, Tikellis JI, Blackwood JM, Odom JW. Surgical prophylaxis for pulmonary embolism. *Am Surg.* 1994;60:292-295.
 70. Kanter B, Moser KM. The Greenfield vena cava filter. *Chest.* 1988;93:170-175.
 71. Greenfield LJ, Michna BA. Twelve-year clinical experience with the Greenfield vena caval filter. *Surgery.* 1988;104:706-712.
 72. Greenfield LJ, Peyton R, Crute S, Barnes R. Greenfield vena caval filter experience: late results in 156 patients. *Arch Surg.* 1981;116:1451-1456.
 73. Bianchini AU, Mehta SN, Mulder DS, Barkun AN, Mayrand S. Duodenal perforation by a Greenfield filter: endoscopic diagnosis. *Am J Gastroenterol.* 1997;92:686-687.
 74. Appleberg M, Crozier JA. Duodenal penetration by a Greenfield caval filter. *Aust NZ J Surg.* 1991;61:957-960.
 75. Kupferschmid JP, Dickson CS, Townsend RN, Diamond DL. Small-bowel obstruction from an extruded Greenfield filter strut: an unusual late complication. *J Vasc Surg.* 1992;16:113-115.
 76. Sidawy AN, Menzoian JO. Distal migration and deformation of the Greenfield vena cava filter. *Surgery.* 1986;99:369-372.
 77. Chintalapudi UB, Gutierrez OH, Azodo MV. Greenfield filter caval perforation causing an aortic mural thrombus and femoral artery occlusion. *Cathet Cardiovasc Diagn.* 1997;41:53-55.
 78. Lok SY, Adkins J, Asch M. Caval perforation by a Greenfield filter resulting in small-bowel volvulus. *J Vasc Interv Radiol.* 1996;7:95-97.
 79. Shaer JA, Epstein N. An unusual cause of low back pain? a case report. *Spine.* 1998;23:1349-1350.
 80. Wambeen ND, Frazer CK, Kumar A. Penetration of a vertebral body by a limb of the Greenfield filter. *Australas Radiol.* 1996;40:364-366.
 81. Plaus WJ, Hermann G. Structural failure of a Greenfield filter. *Surgery.* 1988;103:662-664.
 82. Puram B, Maley TJ, White NM, Rotman HH, Miller G. Acute myocardial infarction resulting from the migration of a Greenfield filter. *Chest.* 1990;98:1510-1511.
 83. Friedell ML, Goldenkranz RJ, Parsonnet V, et al. Migration of a Greenfield filter to the pulmonary artery: a case report. *J Vasc Surg.* 1986;3:929-931.
 84. Dabbagh A, Chakfe N, Kretz JG, et al. Late complication of a Greenfield filter associating caudal migration and perforation of the abdominal aorta by a ruptured strut. *J Vasc Surg.* 1995;22:182-187.
 85. Angeli E, Paesano PL, Zanello A, Del Maschio A. Perforation of the vena cava with aortic penetration by a Greenfield filter: diagnostic ability of ultrasonography. *Radiol Med (Torino).* 1990;80:929-931.
 86. Howerton RM, Watkins M, Feldman L. Late arterial hemorrhage secondary to a Greenfield filter requiring operative intervention. *Surgery.* 1991;109:265-268.
 87. James KV, Sobolewski AP, Lohr JM, Welling RE. Tricuspid insufficiency after intracardiac migration of a Greenfield filter: case report and review of the literature. *J Vasc Surg.* 1996;24:494-498.
 88. Francannet P, Boiteux JP, Labouz F, Beretvas M, Giraud B. Kidney pelvis perforation due to a Greenfield intra-caval filter. *Ann Urol (Paris).* 1988;22:268-270.
 89. Kurgan A, Nunnelee JD, Auer AI. Penetration of the wall of an abdominal aortic aneurysm by a Greenfield filter prong: a late complication. *J Vasc Surg.* 1993;18:303-306.
 90. Lahey SJ, Meyer LP, Karchmer AW, et al. Misplaced caval filter and subsequent pericardial tamponade. *Ann Thorac Surg.* 1991;51:299-300.
 91. Scurr J, Stannard P, Wright J. Extensive thromboembolic disease in pregnancy treated with a Kimray Greenfield vena cava filter: case report. *Br J Obstet Gynaecol.* 1981;88:778-780.
 92. Arbogast JD, Blessed WB, Lacoste H, Gross WS, Gonda RL Jr, Welch RA. Use of two Greenfield caval filters to prevent recurrent pulmonary embolism in a heparin-allergic gravida. *Obstet Gynecol.* 1994;84:652-654.
 93. Banfield PJ, Pittam M, Marwood R. Recurrent pulmonary embolism in pregnancy managed with the Greenfield vena caval filter. *Int J Gynaecol Obstet.* 1990;33:275-278.
 94. Hux CH, Wapner RJ, Chayen B, Rattan P, Jarrell B, Greenfield L. Use of the Greenfield filter for thromboembolic disease in pregnancy. *Am J Obstet Gynecol.* 1986;155:734-737.
 95. Thomas LA, Summers RR, Cardwell MS. Use of Greenfield filters in pregnant women at risk for pulmonary embolism. *South Med J.* 1997;90:215-217.
 96. Aburahma AF, Boland JP. Management of deep vein thrombosis of the lower extremity in pregnancy: a challenging dilemma. *Am Surg.* 1999;65:164-167.
 97. Kroger K, Rudofsky G. Recurrent thromboses in a 32-year-old pregnant patient with permanent vena cava filter. *Vasa.* 1995;24:385-388.
 98. Greenfield LJ, Cho KJ, Proctor MC, Sobel M, Shah S, Wingo J. Late results of suprarenal Greenfield vena cava filter placement. *Arch Surg.* 1992;127:969-973.
 99. Neill AM, Appleton DS, Richards P. Retrievable inferior vena caval filter for thromboembolic disease in pregnancy. *Br J Obstet Gynaecol.* 1997;104:1416-1418.
 100. Geary M, Lamont R. Retrievable inferior vena cava filter for thrombotic disease in pregnancy [letter]. *Br J Obstet Gynaecol.* 1998;105:1039.