

## Materials used in cranioplasty: a history and analysis

AATMAN M. SHAH, B.S.,<sup>1</sup> HENRY JUNG, M.D.,<sup>1</sup> AND STEPHEN SKIRBOLL, M.D.<sup>1,2</sup>

<sup>1</sup>Department of Neurosurgery, Stanford University; and <sup>2</sup>Neurosurgery Section, VA Palo Alto Health Care System, Stanford, California

Cranioplasty, one of the oldest surgical procedures used to repair cranial defects, has undergone many revolutions over time to find the ideal material to improve patient prognosis. Cranioplasty offers cosmetic and protective benefits for patients with cranial defects. The first primitive cranioplasty procedures date back to 7000 BC and used metal and gourds to repair cranial defects. Cranioplasty was first documented by Fallopius who described repair using gold plates; the first bone graft was documented by van Meekeren. The first significant improvement for this procedure began with experimentation involving bone grafts in the late 19th century as a more natural approach for repairing cranial defects. The next impetus for advancement came because of wartime injuries incurred during World Wars I and II and involved experimentation with synthetic materials to counter the common complications associated with bone grafts. Methyl methacrylate, hydroxyapatite, ceramics, and polyetheretherketone implants among other materials have since been researched and used. Research now has shifted toward molecular biology to improve the ability of the patient to regenerate bone using bone growth factors. This paper reviews the evolution of materials used over time in addition to the various advantages and pitfalls associated with each change. It is important for neurosurgeons to be mindful of how these techniques have evolved in order to gain a better understanding of this procedure and how it has been adapted.

(<http://thejns.org/doi/abs/10.3171/2014.2.FOCUS13561>)

**KEY WORDS** • cranioplasty • allograft • methyl methacrylate • graft • hydroxyapatite • titanium mesh • PEEK implants • alumina ceramics

**C**RANIOPLASTY is defined as the surgical repair of a defect in the cranium. Commonly, cranioplasty is performed after a craniectomy or craniotomy, and generally there is a temporal separation between the onset of the defect and its repair. Often, a different material is used instead of the original bone.<sup>24</sup> Replacing the cranium has cosmetic and protective effects in addition to reversing the altered physiological state postcraniectomy. Cranioplasty has been shown to improve electroencephalographic abnormalities, cerebral blood flow abnormalities, and other neurological abnormalities.<sup>1</sup>

Cranioplasty is mainly performed following craniectomy for traumatic injuries. For all age groups, tumor removal or decompressive craniectomies are the main reasons for cranioplasty. Contraindications for cranioplasty include infection, hydrocephalus, and brain swelling. Delaying cranioplasty could preclude devitalized autograft or allograft infections. Studies suggest that foreign materials should be used after 1 year to allow for spontaneous ossification.<sup>13</sup>

Various materials have been used to repair cranial defects. The ideal material used for cranioplasty would be 1) radiolucent, 2) resistant to infections, 3) not conductive

of heat or cold, 4) resistant to biomechanical processes, 5) malleable to fit defects with complete closure, 6) inexpensive, and 7) ready to use.<sup>1</sup> This review paper presents the evolution of materials including autologous grafts, allografts, xenografts, and a broad spectrum of synthetic materials used for cranioplasty over time.

### Materials Used for Cranioplasty in Ancient Times

Archeological evidence has demonstrated that cranioplasty dates back to 7000 BC.<sup>1</sup> Cranioplasty has been practiced by many ancient civilizations including the Incans, the Britons, the Asiatics, the North Africans, and the Polynesians.<sup>7</sup> One noteworthy example of ancient cranioplasty is from a Peruvian skull dating back to 2000 BC; the skull was found to have a left frontal defect covered with a 1-mm-thick gold plate.<sup>16</sup> The material used for cranioplasty during this time was contingent upon the socioeconomic rank of the patient. Precious metals were used for the nobility, and gourds were used for the common citizen. The materials during these times were chosen as a reflection of status rather than for viability and efficaciousness. The first documented description of cranioplasty came from Fallopius in the 16th century who proposed that bone could be replaced in cranial fractures provided that the dura was not damaged; if the dura were damaged, the bone would be replaced with a gold plate.<sup>7</sup>

Abbreviations used in this paper: MMA = methyl methacrylate; PEEK = polyetheretherketone; PMMA = polymethylmethacrylate.

### Xenografts

Throughout history, physicians have attempted to implant animal tissue to repair cranial defects. Canine to human bone grafts were performed by van Meekeren in 1668.<sup>8</sup> Subsequently, bone grafts from the dog, ape, goose, rabbit, calf, and eagle have been transplanted into humans. Oftentimes the bone was boiled and perforated before placement. In 1901, Marchand reported that animal horns were well tolerated by tissues. Ox horn, buffalo horn, and ivory were used with satisfactory results. Empirically, the better success with autografts and bone substitution techniques provided little justification for further study using xenografts.<sup>8</sup>

### Allograft

Morestin first used cadaver cartilage for cranioplasty in 1915.<sup>8</sup> Cartilage was thought to work well because it molded well to fill defects and was resistant to infection.<sup>23</sup> However, it soon became apparent that cartilage was not strong enough and that no significant calcification occurred. Sicard and Dambrin experimented with cadaveric skull in 1917. The resected bone was treated with sodium carbonate, xylol, alcohol, and ether and subsequently heat sterilized. This reduced the thickness of the bone so that only the outer table remained, which could then be perforated for use.<sup>12</sup> The high rate of infection and bone resorption made cadaver skull allografts a poor choice for cranioplasty. Autologous bone grafts and bone substitutes have garnered more favor than allografts because of these ramifications.

### Autologous Bone Graft

For cranial reconstruction, many types of materials can be used; however, autologous bone flap replacement using the previously removed bone flap is traditionally performed. Autologous bone grafts are preferred because this method reduces foreign materials being introduced into the body, and because the bone flap can be readily accepted by the host and integrated back into the skull (Table 1). In 1821, Walther is credited with the first recorded autologous bone graft cranioplasty.<sup>23</sup> In 1889, plastic reconstruction of the cranium was first recorded by Seydel who used pieces of tibia to cover a left parietal defect with uneventful recovery.<sup>1</sup> Further experimentation with the tibia was performed; however, it was noted that the need for two operative fields, the risk of tibial fracture, and the undue discomfort for the patient made tibial grafts nonoptimal. Many other bone harvest sites were experimented with including the ilium, ribs, sternum, scapula, fascia, and fat.<sup>1</sup> The use of the cranium for autologous bone graft became popular by the Müller-König procedure, which repaired cranial defects by swinging flaps of adjacent tissue that included the skin, periosteum, and outer table.<sup>8</sup>

Re-placement of the original bone removed during craniectomy is optimal as no other graft or foreign materials are introduced (Fig. 1). In pediatric patients, this is preferable as the child's original skull material will become reintegrated as he or she matures.<sup>13</sup> Moreover,

autologous cranial bone grafts can be harvested with ease and have an enhanced survival time relative to other types of bone.<sup>17</sup> When the cranial bone grafts are split, reconstruction of the donor site is greatly simplified, which reduces donor site morbidity. Autologous split-thickness bone grafts have become the graft of choice in craniofacial reconstructions in children.<sup>17</sup>

Autologous bone can be preserved either by cryopreservation or by placement in a subcutaneous abdominal pocket. Both of these methods may be equally efficacious for storage in a non-traumatic brain injury setting.<sup>15</sup> However, in a traumatic brain injury setting, the subcutaneous pocket may be the preferred method of storage because cryopreservation may have a higher surgical site infection rate.<sup>15</sup> Many studies have validated the efficacy, low infection rate, and low cost of storing a cranioplasty flap in the subcutaneous pouch of the abdominal wall.<sup>2,25</sup> Furthermore, in a battlefield setting where injured soldiers are often transported off the battlefield, storage of cranioplasty flaps in the subcutaneous abdominal wall ensures that the flap will not be lost in transport.

Although preferred, autologous bone transplants are not without risks. A common complication in pediatric patients is bone flap resorption, which results in structural breakdown. This necessitates reoperation and replacement with plastic, metal, or other materials.<sup>5,13</sup> In pediatric patients who undergo bone flap resorption, revision cranioplasty is generally quite successful. Bowers et al. demonstrated that success rates were higher with custom synthetic implants than with autologous split-thickness bone grafts.<sup>5</sup> Cranioplasty depends on osteoconduction, whereby the bone graft provides the structure to allow osteoprogenitor cells to enter and take root. This requires a matrix, which could potentially be destroyed when the flap is frozen or autoclaved. This explains the higher resorption rate of autologous bone grafts. In addition to resorption, Matsuno et al. demonstrated that autologous bone grafts had the highest rates of infection at 25.9% when compared with polymethylmethacrylate (PMMA), alumina ceramics, and titanium mesh.<sup>22</sup>

### Synthetic Materials

Although autologous bone graft is preferred because of its cosmetic result, lower cost, and patient incorporation, synthetic materials are largely being considered as an alternative to prevent the complications of bone resorption, infection, donor site morbidity, and reduced strength and malleability for aesthetic contour.<sup>11</sup> Over time, various materials have been adapted to counter these pitfalls.

### Metals

The use of metals dates back to antiquity, with a resurgence in the early 1900s. Metals were largely experimented with because they are strong, can be sterilized, and are malleable. Aluminum was the first metal used in the late 1800s but was prone to infection. Aluminum further proved to be a poor bone substitute because it irritates surrounding tissues, induces seizures, and undergoes a slow disintegration.<sup>4</sup> Although gold did not demonstrate tissue reaction, it is unfavorable because of its high cost and soft-

## Materials used in cranioplasty

**TABLE 1: Analysis of the advantages and disadvantages of common cranioplasty materials**

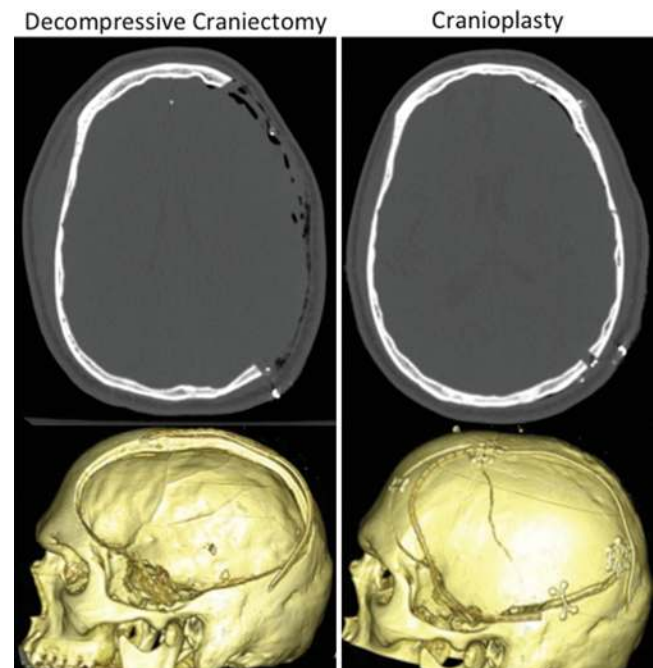
Material	Advantages	Disadvantages
autologous bone	accepted by host, low rate of fracture	bone resorption, infection
MMA	strong, heat resistant, inert, low cost, ease of use	infection, fracture, exothermic burn reaction, inflammation, lack of incorporation
hydroxyapatite	noninflammatory, decent chemical bonding to bone, excellent cosmesis & contouring ability	low tensile strength, brittle, infection, fragmentation, lack of osteointegration
titanium mesh	noninflammatory, noncorrosive, strong, malleability, low infection rate, good cosmesis	expensive, image artifact on imaging
alumina ceramics	hard, chemically stable, tissue compatible, low infection rate	expensive, prone to shatter
PEEK implant	radiolucent, chemically inert, strong, elastic, does not create artifacts on imaging, comfortable, does not conduct temperature	cost, need for additional 3D planning & imaging, difficult to bond to other materials, infection

ness. Silver became popularized by Sebileau in 1903, but it was found to be unsuitable as silver oxide reacts with surrounding tissues and discolors the scalp.<sup>24</sup> Silver was also too soft and was unable to withstand trauma. Gold and silver were tested during World War I but were replaced during World War II with tantalum. Tantalum was resistant to tissue reaction, corrosion, and infection, in addition to being inert and nonabsorbable. However, tantalum was difficult to procure and was, hence, expensive. Another disadvantage with tantalum is that it conducted temperature very well, which led to temperature-dependent headaches. Given the aforementioned challenges of infection, corrosion, and epileptogenicity, focus was eventually shifted away from metals and toward acrylics.

### Methyl Methacrylate

Although tantalum was the chosen material for cranioplasty during World War II, acrylic resins were gaining interest due to their success with dental prostheses. Methyl methacrylate was discovered in 1939 and was extensively experimented with in the 1940s.<sup>27</sup> Methyl methacrylate (MMA) is a polymerized ester of acrylic acid with strength comparable to bone. Furthermore, MMA has been shown to have better compression and stress resistance than hydroxyapatite.<sup>20</sup> Acrylic was shown to adhere to the dura mater without reaction in the underlying tissue. With further experimentation, acrylic became preferable to metal because it is strong, heat resistant, radiolucent, and inert.<sup>14</sup> The radiolucency aspect of MMA had both positive and negative ramifications. On one hand, the cerebral vasculature could still be seen on angiography. One the other hand, the radiolucency made fractures of the plate difficult to detect. To counter this obstacle, a small amount of barium was routinely infused within the plate so that it would be detected by radiographic means. Titanium wire mesh was later used as a supporting lattice for MMA placement to reduce the fracture potential of MMA, particularly with larger cranioplasties.<sup>10</sup> In addition, the underlying mesh may help with cosmesis when using MMA. Despite the advantages, MMA has a high risk of extrusion, decomposition, and infection, and the residual monomer from cold polymerization may be toxic.<sup>3,6,22</sup> When MMA is ready to be used, it is mixed with a

monomer that causes an exothermic reaction. While this makes the substance a malleable paste (Fig. 2), it may also cause burn injuries. The potential fragmentation of MMA leads to little protection long term and may even progress to infection and inflammatory reactions. Blum et al. studied the long-term consequences of MMA usage for cranioplasty and found a 23% complication rate within 8 years of operation.<sup>3</sup> Infection made up a majority of the complications. Matsuno et al. further corroborated these findings and demonstrated that polymethylmethacrylate (PMMA) has a high rate of infection at 12.7%.<sup>22</sup> Although MMA is the most widely used synthetic material due to



**Fig. 1.** Autologous bone graft. Axial (*upper*) and 3D reconstructed (*lower*) CT scans obtained after decompressive craniectomy (*left*) and subsequent autologous bone flap replacement (*right*). Reprinted from Oladunjoye AO, Schrot RJ, Zwienerberg-Lee M, Muizelaar JP, Shahlaie K: Decompressive craniectomy using gelatin film and future bone flap replacement. Technical note. *J Neurosurg* 118:776–782, 2013, with permission.

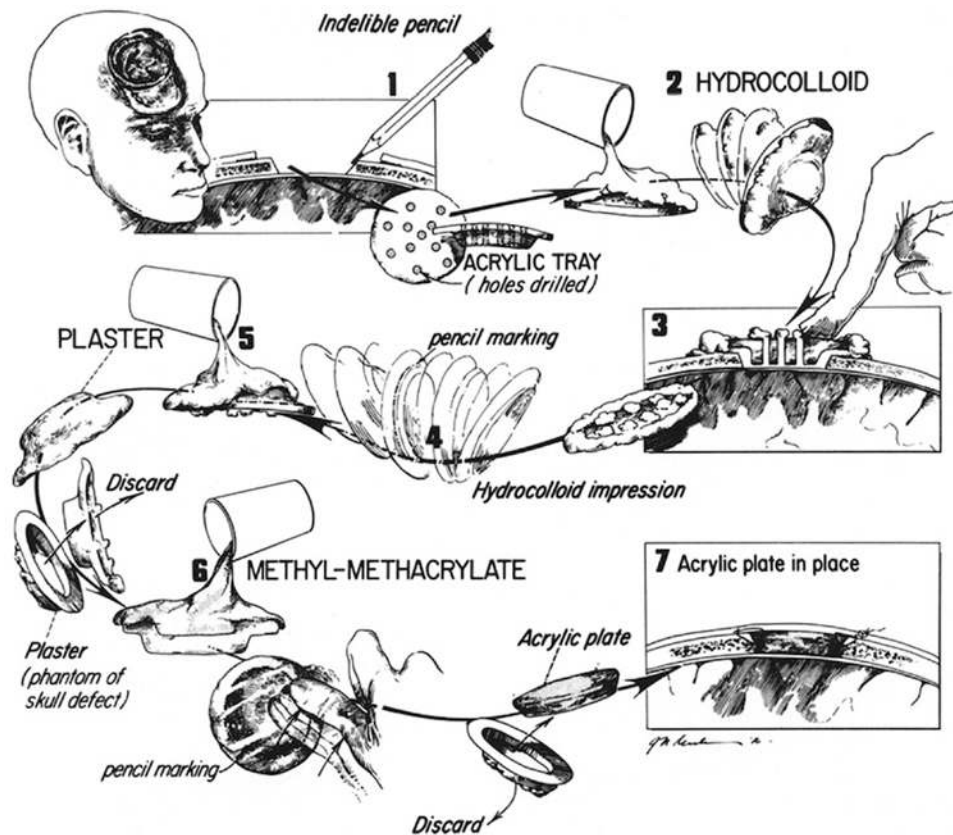


FIG. 2. Preparing MMA. Drawing showing the steps required in molding the MMA to the defect and placing it in position. While being mixed, the substance can cause an exothermic reaction. This makes the substance a malleable paste but may also cause burn injuries. Reprinted from Asimacopoulos TJ, Papadakis N, Mark VH: A new method of cranioplasty. Technical note. *J Neurosurg* 47:790–792, 1977, with permission.

its excellent tensile strength, its fracture susceptibility and lack of incorporation make it difficult to use (Table 1).

#### Hydroxyapatite

The problem with metal and other synthetic compounds is that they are difficult to contour to the natural skull shape and inherently impede brain CT scanning; to counter this problem, hydroxyapatite was introduced. Hydroxyapatite is a calcium phosphate compound found naturally as the mineral component of bone,<sup>24</sup> but it can also be synthetically manufactured as a ceramic. Hydroxyapatite can also be used in conjunction with titanium mesh for stronger prosthesis (Fig. 3). In contrast to MMA, which does not allow expansion of a growing skull, hydroxyapatite can be used in the pediatric population. Hydroxyapatite has little foreign body reaction and has decent chemical bonding to bone. It can also be smoothly contoured for excellent cosmetic results. Despite the advantages, hydroxyapatite use has been limited because of its brittle nature, low tensile strength, and high infection rates (Table 1). Hydroxyapatite has demonstrated osteointegration in animal models;<sup>19,21,26</sup> however, there is not much evidence for osteointegration for humans *in vivo*.<sup>9</sup> Frassanito et al. demonstrated that hydroxyapatite may break down into many fragments over time *in vivo*, and they also demonstrated extremely limited osteointegration that lacked lamellar organization.<sup>9</sup> Repairing larger

defects can be challenging due to the compromised structural integrity of hydroxyapatite when exposed to CSF and blood and due to the lack of osteointegration.<sup>13</sup>

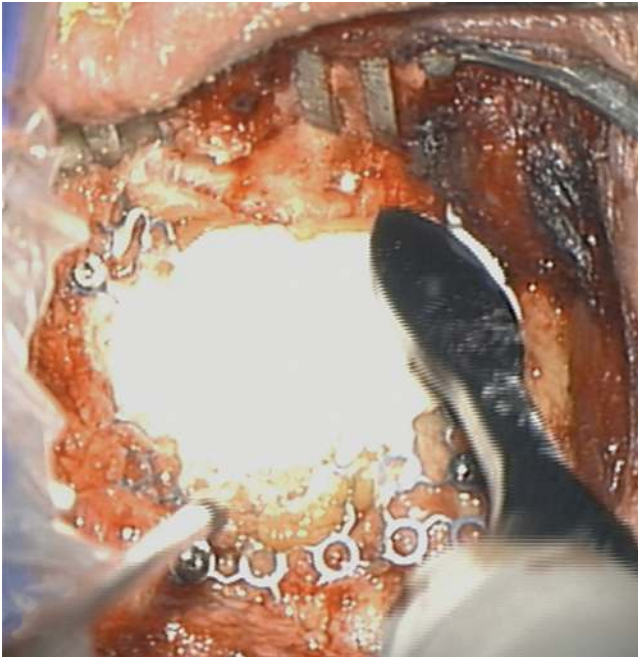
#### Titanium Mesh

Titanium mesh can be used alone or in conjunction with other synthetic materials to strengthen the prosthesis (Fig. 4). Titanium, a metallic alloy, has a high overall strength and malleability. Titanium is noncorrosive and noninflammatory; it has low risk of infection, and can provide superb cosmetic results (Table 1). Matsuno et al. demonstrated that titanium mesh had the lowest rate of graft infection of all cranioplasty materials at 2.6%.<sup>22</sup> Our own experience has corroborated this finding. We have found that the use of titanium mesh cranioplasty has decreased the rate of graft infection in patients who are at increased risk, such as military personnel who suffered extensive scalp wounds and/or underwent craniectomy while serving in the Iraq and Afghanistan Wars (unpublished observations). In addition, computer-assisted 3D modeling can be used to design titanium mesh implants that provide excellent cosmesis, even with large cranial defects (Fig. 5).

#### Alumina Ceramics


Alumina ceramics have been gaining attention for

## Materials used in cranioplasty

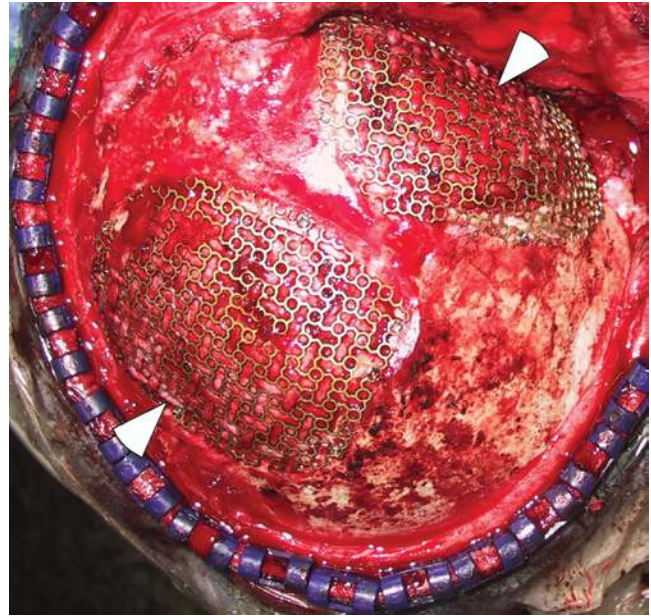


**Fig. 3.** Hydroxyapatite placement. Intraoperative photograph demonstrating hydroxyapatite being placed over titanium mesh and contoured to the defect. Reprinted from Manjila S, Weidenbecher M, Semaan MT, Megerian CA, Bambakidis NC: Prevention of postoperative cerebrospinal fluid leaks with multilayered reconstruction using titanium mesh–hydroxyapatite cement cranioplasty after translabyrinthine resection of acoustic neuroma. Technical note. *J Neurosurg* 119:113–120, 2013, with permission.

cranioplasty within the last decade due to their strength and aesthetic benefits. These ceramics are nearly as hard as diamond, chemically stable, and have comparable tissue compatibility to acrylics.<sup>24</sup> Yttrium is added to make the ceramic material slightly radiopaque. Studies have



**Fig. 4.** Photograph of titanium mesh taken by the author.

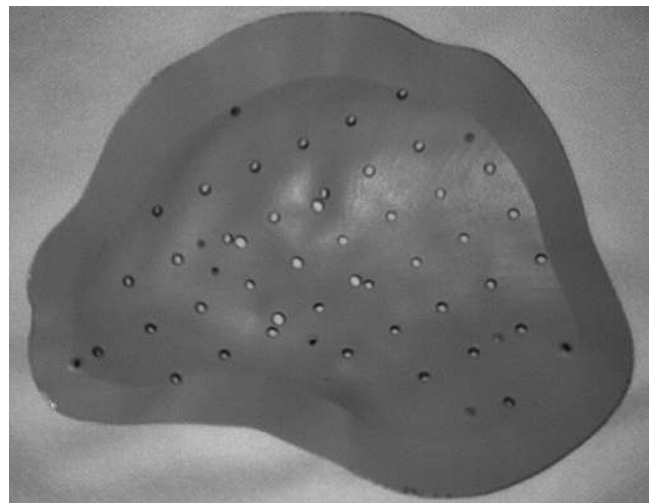


**Fig. 5.** Titanium mesh in vivo. Intraoperative image showing titanium mesh covering skull defects. The *left arrowhead* indicates a left parieto-occipital skull defect with overlying titanium mesh. The *right arrowhead* indicates a left retrosigmoid skull defect with overlying titanium mesh. Reprinted from Mislow JM, Proctor MR, McNeely PD, Greene AK, Rogers GF: Calvarial defects associated with neurofibromatosis Type 1. Report of two cases. *J Neurosurg* 106 (6 Suppl):484–489, 2007, with permission.

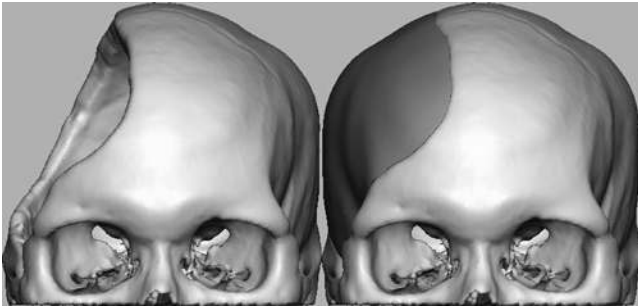
demonstrated that custom-made ceramics have a very low postoperative infection rate of 5.9%.<sup>22</sup> The major drawbacks are that customized ceramics are very expensive, they need to be preformed, and they are prone to shatter despite their hardness.<sup>13</sup>

### PEEK Implants

Polyetheretherketone (PEEK) is a semicrystalline polymer that is radiolucent, chemically inert, and can be sterilized by steam or gamma irradiation (Fig. 6).<sup>18</sup> These implants have strength, thickness, and elasticity comparable to cortical bone and can be incorporated accurately



**Fig. 6.** Photograph of a PEEK implant taken by the author.



**FIG. 7.** PEEK implant with 3D modeling. This image demonstrates how 3D modeling can assist with PEEK implants. Image obtained from and published with permission from the Department of Neurosurgery at the Stanford University School of Medicine.

within the defect without the use of miniplates.<sup>18</sup> Newer technologies such as PEEK implants are commonly used today because they can be designed specific to a patient's craniotomy defect with 3D printing technologies (Figs. 7 and 8). Computer-assisted 3D modeling can be used to design these synthetic implants.<sup>18</sup> The PEEK implants offer 3 main advantages (Table 1). First, they do not create artifacts on CT or MRI because they are translucent to x-rays and are nonmagnetic. Second, PEEK implants are more comfortable because the material is less dense, and therefore lighter weight. Lastly, they do not conduct temperature unlike metallic implants, which can have negative ramifications on the brain.<sup>18</sup> Despite these advantages, PEEK implants are expensive and lack osteointegrative properties. Despite the paucity of literature on the risks of infection with PEEK implants, in our personal experience, PEEK, like other foreign implants, may have a higher than expected infection rate as seen in military personnel who served in the Iraq and the Afghanistan Wars. We have also seen cases in which patients develop foreign body reactions to PEEK implants. Furthermore, because it does not incorporate with surrounding native bone, the implant has the risk of being dislodged or extruded.

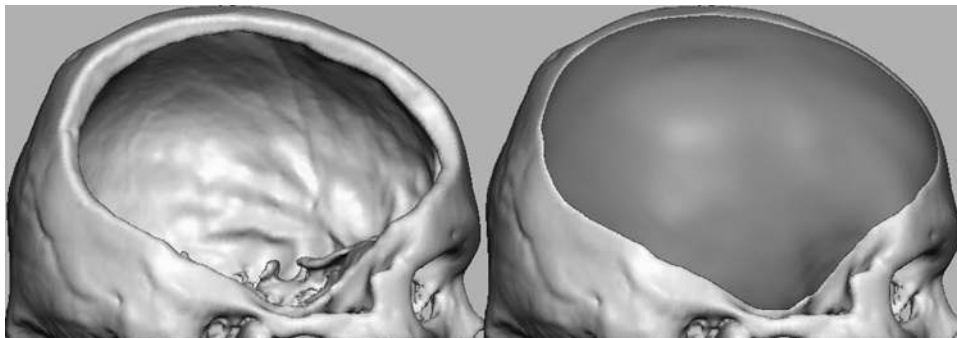
### The Future of Cranioplasty

Research in cranioplasty has had a shift toward molecular biology to aid with bone graft healing. Osteoin-

duction, the process by which undifferentiated mesenchymal cells can be transformed into osteoprogenitor cells, is currently being explored. Bone graft healing is a complicated process involving revascularization and bone formation within the graft. The bone acts as a scaffold for the gradual proliferation of blood vessels and osteoprogenitor cells. With osteoinduction, osteoprogenitor cells would not have to enter from surrounding tissue. Instead, they would be produced in situ with the aid of bone morphogenetic proteins, which would be infused into an implant.<sup>1</sup> These bone growth factors can be integrated into extended release polymers to stimulate cellular responses to encourage bone regeneration.<sup>24</sup> This new technology can provide immediate protection to the cranium, be aesthetically beneficial, and be both osteoconductive and osteoinductive.<sup>1</sup>

### Conclusions

Although metals have been used for cranioplasty since antiquity, autologous bone graft currently persists as the preferred choice for cranioplasty because it reduces the introduction of foreign materials into the body, and because the bone flap can be readily accepted by the host and integrated back into the skull. Despite these advantages, the risk of infection, absorption, and reduced strength have shifted focus toward creating more viable synthetic materials. Methyl methacrylate is a commonly used synthetic material because of its excellent tensile strength, although its fracture susceptibility and infection rates have made this a less viable material long term. To aid with fracture susceptibility, titanium wire mesh has been added as an adjunct modification for MMA. Newer technologies such as PEEK implants and titanium mesh are also commonly used as they can be designed specific to a patient's craniotomy defect with 3D printing technologies. Future advances in cranioplasty will largely involve molecular biological approaches involving the application of bone growth factors to aid with bone formation within a graft. Empirically, there has been no ideal material for cranioplasty; however, materials that are strong, resistant to infection, radiolucent, inexpensive, easy to work with, and able to reincorporate with a patient's craniotomy defect will offer the greatest advantages for such patients.



**FIG. 8.** PEEK implant with 3D modeling (side view). This image demonstrates how 3D modeling can assist with PEEK implants. Image obtained from and published with permission from the Department of Neurosurgery at the Stanford University School of Medicine.

# Materials used in cranioplasty

## Disclosure

The authors report no conflict of interest concerning the materials or methods used in this study or the findings specified in this paper.

Author contributions to the study and manuscript preparation include the following. Conception and design: Shah, Jung. Acquisition of data: Shah. Analysis and interpretation of data: Shah. Drafting the article: Shah. Critically revising the article: Shah, Jung. Reviewed submitted version of manuscript: all authors. Approved the final version of the manuscript on behalf of all authors: Shah. Administrative/technical/material support: Shah, Jung. Study supervision: Shah, Jung.

## References

1. Aydin S, Kucukyuruk B, Abuzayed B, Aydin S, Sanus GZ: Cranioplasty: review of materials and techniques. **J Neurosci Rural Pract** 2:162–167, 2011
2. Baldo S, Tacconi L: Effectiveness and safety of subcutaneous abdominal preservation of autologous bone flap after decompressive craniectomy: a prospective pilot study. **World Neurosurg** 73:552–556, 2010
3. Blum KS, Schneider SJ, Rosenthal AD: Methyl methacrylate cranioplasty in children: long-term results. **Pediatr Neurosurg** 26:33–35, 1997
4. Booth JA, Curtis BF: I. Report of a case of tumor of the left frontal lobe of the cerebrum; operation; recovery. **Ann Surg** 17:127–139, 1893
5. Bowers CA, Riva-Cambrin J, Hertzler DA II, Walker ML: Risk factors and rates of bone flap resorption in pediatric patients after decompressive craniectomy for traumatic brain injury. Clinical article. **J Neurosurg Pediatr** 11:526–532, 2013
6. Chiarini L, Figurelli S, Pollastri G, Torcia E, Ferrari F, Albanese M, et al: Cranioplasty using acrylic material: a new technical procedure. **J Craniomaxillofac Surg** 32:5–9, 2004
7. Courville CB: Cranioplasty in prehistoric times. **Bull Los Angel Neuro Soc** 24:1–8, 1959
8. Durand JL, Renier D, Marchac D: [The history of cranioplasty.] **Ann Chir Plast Esthet** 42:75–83, 1997 (Fr)
9. Frassanito P, De Bonis P, Mattogno PP, Mangiola A, Novello M, Brinchi D, et al: The fate of a macroporous hydroxyapatite cranioplasty four years after implantation: macroscopical and microscopical findings in a case of recurrent atypical meningioma. **Clin Neurol Neurosurg** 115:1496–1498, 2013
10. Galicich JH, Hovind KH: Stainless steel mesh-acrylic cranioplasty. Technical note. **J Neurosurg** 27:376–378, 1967
11. Goldstein JA, Paliga JT, Bartlett SP: Cranioplasty: indications and advances. **Curr Opin Otolaryngol Head Neck Surg** 21:400–409, 2013
12. Grant FC, Norcross NC: Repair of cranial defects by cranioplasty. **Ann Surg** 110:488–512, 1939
13. Grant GA, Jolley M, Ellenbogen RG, Roberts TS, Gruss JR, Loeser JD: Failure of autologous bone-assisted cranioplasty following decompressive craniectomy in children and adolescents. **J Neurosurg** 100 (2 Suppl Pediatrics):163–168, 2004
14. Henry HM, Guerrero C, Moody RA: Cerebrospinal fluid fistula from fractured acrylic cranioplasty plate. Case report. **J Neurosurg** 45:227–228, 1976
15. Inamasu J, Kuramae T, Nakatsukasa M: Does difference in the storage method of bone flaps after decompressive craniectomy affect the incidence of surgical site infection after cranioplasty? Comparison between subcutaneous pocket and cryopreservation. **J Trauma** 68:183–187, 2010
16. Kennedy KAR: Primitive Surgery: Skills Before Science. Spencer L. Rogers. **Am Anthropol** 89:217–218, 1987
17. Koenig WJ, Donovan JM, Pensler JM: Cranial bone grafting in children. **Plast Reconstr Surg** 95:1–4, 1995
18. Lethaus B, Safi Y, ter Laak-Poort M, Kloss-Brandstätter A, Banki F, Robbenmenke C, et al: Cranioplasty with customized titanium and PEEK implants in a mechanical stress model. **J Neurotrauma** 29:1077–1083, 2012
19. Marcacci M, Kon E, Zaffagnini S, Giardino R, Rocca M, Corsi A, et al: Reconstruction of extensive long-bone defects in sheep using porous hydroxyapatite sponges. **Calcif Tissue Int** 64:83–90, 1999
20. Marchac D, Greensmith A: Long-term experience with methylmethacrylate cranioplasty in craniofacial surgery. **J Plast Reconstr Aesthet Surg** 61:744–753, 2008
21. Martini L, Staffa G, Giavaresi G, Salamanna F, Parrilli A, Serchi E, et al: Long-term results following cranial hydroxyapatite prosthesis implantation in a large skull defect model. **Plast Reconstr Surg** 129:625e–635e, 2012
22. Matsuno A, Tanaka H, Iwamuro H, Takanashi S, Miyawaki S, Nakashima M, et al: Analyses of the factors influencing bone graft infection after delayed cranioplasty. **Acta Neurochir (Wien)** 148:535–540, 2006
23. Munroe AR: The operation of cartilage-cranioplasty. **Can Med Assoc J** 14:47–49, 1924
24. Sanan A, Haines SJ: Repairing holes in the head: a history of cranioplasty. **Neurosurgery** 40:588–603, 1997
25. Shoakazemi A, Flannery T, McConnell RS: Long-term outcome of subcutaneously preserved autologous cranioplasty. **Neurosurgery** 65:505–510, 2009
26. Teixeira S, Fernandes H, Leusink A, van Blitterswijk C, Ferraz MP, Monteiro FJ, et al: In vivo evaluation of highly macroporous ceramic scaffolds for bone tissue engineering. **J Biomed Mater Res A** 93:567–575, 2010
27. Woodhall B, Spurling RG: Tantalum Cranioplasty for War Wounds of the Skull. **Ann Surg** 121:649–668, 1945

Manuscript submitted December 14, 2013.

Accepted February 11, 2014.

Please include this information when citing this paper: DOI: 10.3171/2014.2.FOCUS13561.

Address correspondence to: Aatman M. Shah, B.S., Department of Neurosurgery, Stanford University School of Medicine, 1201 Welch Rd., MSLS, Rm. P352, Stanford, CA 94305. email: aatmans@stanford.edu.